https://dspace.org/

Imaging features of triple negative breast cancer in a tertiary hospital in South Africa

Bhana-Nathoo, Deepa

2019
https://hdl.handle.net/10539/28176
Bhana Nathoo, Deepa (2019) Imaging features of triple negative breast cancer in a tertiary hospital in South Africa, University of the Witwatersrand, Johannesburg, <http://hdl.handle.net/10539/28176>

Downloaded from a DSpace repository. https://dspace.org/

IMAGING FEATURES OF TRIPLE NEGATIVE BREAST CANCER IN A TERTIARY HOSPITAL IN SOUTH AFRICA

Dr. D. Bhana-Nathoo

A research report submitted to the Faculty of Health Sciences, University of the Witwatersrand, Johannesburg, in partial fulfilment of the requirements for the degree of Master of Medicine in Diagnostic Radiology

Johannesburg, 2019

Declaration

I, Deepa Bhana-Nathoo, declare that this research report is my own work. It is being submitted for the degree of MMed(RadD) at the University of the Witwatersrand, Johannesburg. It has not been submitted before for any degree or examination at this or any other University.

Dr Deepa Bhana-Nathoo

On this 28th day of March 2019.

To my loving husband who was my rock and strength throughout this entire process.

And to my family, who's support has been unmeasurable.

Publications and presentations

This work has never been published.

It has never been presented at a congress.

Abstract

INTRODUCTION

Breast cancer is one of the leading causes of cancer deaths worldwide. Triple negative breast Cancer (TNBC) is an aggressive subtype, commonly described as presenting at a younger age, in women of African descent and in low socioeconomic groups. Commonly it demonstrates benign imaging features making diagnosis a challenge. Early detection and treatment is imperative.

AIM

To determine the common imaging features of TNBC in South Africa.

METHOD

A retrospective study was conducted at a tertiary institution in South Africa. the study population included all biopsy proven TNBC patients presenting between 01/01/2012 – 30/06/2016. All the initial mammograms were re-read by three independent radiologists using a data collection sheet. Illegible or incomplete reports were excluded from the study.

RESULTS

In our population, TNBC commonly presented in African women with an average age of 54.2 and range 25-95 years, with 47% being pre-menopausal. Typical mammographic features were an oval (27%) or irregular (27%) shaped mass with well circumscribed margins (33%). Our lesions were much larger than those reported in the literature (1). Global asymmetry and architectural distortion were commonly associated features. On ultrasound, the lesions were mostly irregularly shaped (56%) with spiculated borders (29%) and hypoechoic (80%) with axillary adenopathy (81%).

CONCLUSION

The majority of our patient population presented with a clinically palpable mass, that was larger and had more aggressive features than usually described in the literature. This can be attributed to delayed presentation, due to numerous factors. In order to improving the detection rate and reduce mortality, education and screening programs play a major role.

Acknowledgements

Thank you to the following people that made this project possible:

Dr. Lucas for all the patience and constant support.

Dr. Cubasch

Dr. Eshraghi

Dr. Kuehnast

Table of Contents

Declaration ii
Publications and presentations iv
Abstract v
Acknowledgements vi
Table of Contents vii
List of Figures x
List of Tables xi
List of Abbreviations and Terminology xii
1. Introduction 1
1.1. Rationale 1
1.2. Epidemiology of breast cancer worldwide 2
1.3. Epidemiology of breast cancer in Africa 2
1.4. Breast cancer in South Africa 2
1.5. Breast cancer subtypes 2
1.6. Risk factors associated with breast cancer 3
1.7. Mammography and ultrasound in TNBC 4
1.8. Treatment and outcome of TNBC 4
1.9. Risk of metastases and recurrence in TNBC 5
1.10. Preventative measures 6
1.11. Aim 6
1.12. Study Objectives 6
2. Materials and Methods 7
2.1. Study design 7
2.2. Study setting 7
2.3. Study sample 7
2.4. Inclusion and exclusion criteria 7
2.5. Methods of analysis 7
2.6. Classifications and gradings that were used in this project 8
2.7. Reliability and validity 9
2.7.1. Reliability 9
2.7.2. Validity 9

2.7.3. Bias 9
2.8. Statistical analysis 12
2.9. Ethics 12
3. Results 13
3.1. Clinical findings of TNBC 13
3.2. Mammogram findings 15
3.2.1. Breast density 15
3.2.2. Laterality and site of lesions 16
3.2.3. Shape and margins of lesions 17
3.2.4. Size of lesions 18
3.2.5. Additional features 18
3.3. Ultrasound findings 20
3.3.1. Shape and margins 20
3.3.2. Internal echopattern and additional sonographic findings 20
3.4. BI-RAD classification 22
3.5. Histology results 23
4. Discussion 24
4.1. Demographics 24
4.2. Clinical findings 24
4.3. Imaging findings 25
4.3.1. Background density 25
4.3.2. Location 25
4.3.3. Shape 26
4.3.4. Margins 26
4.3.5. Size 26
4.3.6. Asymmetry 27
4.3.7. Internal echogenicity on ultrasound 27
4.3.8. Additional features 27
4.3.9. Unusual appearances of TNBC 28
4.4. BI-RADS final assessment 32
4.5. Comparison of histology findings of triple negative breast cancer 32
4.6. Delayed presentation 33

4.7. Current applications 33
4.8. Limitations of the current study 33
4.9. Future applications 34
5. Conclusion 35
6. References 36
Appendix A: Ethics Clearance Certificate 40
Appendix B: Data collection sheet 41
Appendix C: Note on referencing style 44
Appendix D: Graphical presentation of results 45

List of Figures

Figure 2.1. Examples of some typical mammogram features that were used during data collection 10
Figure 2.2. Examples of some typical ultrasound features that were used during data collection 11
Figure 4.1. Examples of atypical appearance of TNBC in our study population. 29
Figure 4.2. Mammogram features demonstrating unusual appearance of TNBC in our population 30
Figure 4.3. Aggressive presentation of TNBC 31
Figure D.1. Average age seen in our population group 45
Figure D.2. Menopause status commonly encountered in our population group 45
Figure D.3. Additional clinical findings found in our population group 46
Figure D.4. Background density as seen on mammogram 46
Figure D.5. Site of lesions as demonstrated on mammogram 46
Figure D.6. Mass shape and average age of patients with this finding 47
Figure D.7. Mass margins and average age of patients with this finding 47
Figure D.8. Asymmetry as seen on mammogram 48
Figure D.9. Additional features seen on mammogram 48
Figure D.10. Shape of the lesions on ultrasound 49
Figure D.11. Lesion borders on ultrasound 49
Figure D.12. Internal echogenicity of the mass on ultrasound 50
Figure D.13. Additional findings seen on ultrasound 50
Figure D.14. Final BI-RADS classification 51
Figure D.15. Common histology type encountered 51
Figure D.16. Tumour grading according to the Bloom and Richardson grading system 52

List of Tables

Table 3.1. The demographics 13
Table 3.2. The clinical findings 14
Table 3.3. Background density 15
Table 3.4. Laterality and site of the breast mass 16
Table 3.5. The shape and margins of lesions on mammogram 17
Table 3.6. The size of lesions on mammogram 18
Table 3.7. Additional features that were seen on mammogram 18
Table 3.8. The shape and margin of the lesions as seen on ultrasound 20
Table 3.9. The internal echogenicity and additional ultrasound findings 21
Table 3.10. BI-RADS classification 22
Table 3.11. Histology type and tumour grade 23

List of Abbreviations and Terminology

CHBAH	Chris Hani Baragwanath Academic Hospital
ER	Estrogen receptor
FISH	Fluorescence In Situ Hybridisation
HER-2	Human Epidermal Growth Factor Receptor 2
IHC	Immunohistochemistry
ILQ	Inner lower quadrant
NST	No special type
PR	Progesterone receptor
TNBC	Triple negative breast cancer
UOQ	Upper outer quadrant

1. Introduction

1.1. Rationale

Breast cancer is between the most common primary neoplasms diagnosed in women and one of the leading causes of cancer deaths worldwide. It has been shown that early detection and diagnosis leads to improved outcome (2, 3).

Breast cancer can be classified into four different subtypes based on their receptor expression. This helps determine the most appropriate treatment options, predict response to treatment, outcome and prognosis, as well as possible patterns of recurrence and metastases. When the oestrogen, progesterone and Human Epidermal Growth Factor Receptor 2 (HER-2) receptors are all negative the tumour is considered a triple negative breast cancer (TNBC) (4, 5).

TNBC has been associated with more aggressive features compared to the other breast cancer sub-types. It is usually of high grade and affects younger patients that have worse outcome and higher risk of recurrence (4). African women and women of poor socio-economic circumstances were found at higher risk of developing TNBC (1, 6). Since TNBC lacks hormonal receptors there is no targeted hormonal treatment available (7). It has been reported that TNBC may present with benign morphological features on imaging resulting in delayed diagnosis (8). An important aspect to allow for early detection and diagnosis is to study the imaging features of TNBC compared to other breast cancer subtypes (9).

The South African population is predominantly of African ethnicity and a large number of our patients are from disadvantaged socio-economic groups. According to the international literature, this could translate to an increased risk of developing TNBC (6).

The aim of this study was to determine the common imaging features of TNBC in our setting in order to facilitate early diagnosis and treatment.

1.2. Epidemiology of breast cancer worldwide

Breast cancer has become a major health care burden both in developed and developing countries. It is one of the most common primary neoplasms in women and is a major cause of morbidity and mortality in women globally (10).

1.3. Epidemiology of breast cancer in Africa

Africa generally has a lower incidence of breast cancer when compared to other continents. The majority of the morbidity and mortality in the South African population is largely caused by the high burden of HIV and other infectious diseases associated with it, thereby far surpassing the morbidity and mortality associated with breast cancer. However, there is a steady increase in the incidence of breast cancer in Africa, in keeping with the increase of risk factors for breast cancer within the population. Certain subtypes, namely TNBC, are more common in women of African ancestry, however not many studies have been done in African women (1, 2, 6).

1.4. Breast cancer in South Africa

In South Africa, the number of new cases that are being diagnosed yearly is on the rise and as a result it's becoming a significant health care burden. In our setting, the most common risk factors for late presentation and poor outcome are socioeconomic status, cultural beliefs, poor access to health care services and the preferential use of alternative and traditional medicine (10-12). There are conflicting reports about the association between HIV infection and breast cancer in South Africa, but both are more prevalent in the younger population groups (13).

1.5. Breast cancer subtypes

Breast cancer can be divided into different subtypes based on their predominant receptor expression. The three standard molecular markers used to categorize breast cancer are (1, 5):

- Oestrogen receptor (ER) -/+
- Progesterone receptor (PR) -/+
- Human epidermal growth factor receptor 2 (HER2) -/+

When all these markers are negative, the tumour is classified as a triple negative breast cancer. TNBC is thought to be more common in women of African descent and younger patients (presenting before the age of 50) (1, 2).

TNBC is clinically and pathologically more aggressive when compared to the other subtypes. It typically presents in younger women with a clinically palpable mass. Tumours usually are of a higher histological grade and proliferation rate (KI 67) and are associated with a poorer prognosis and a higher risk of developing local recurrence and distal metastasis (14, 15).

1.6. Risk factors associated with breast cancer

As the incidence of breast cancer increases it's important to determine what the contributing factors are. When comparing the risk factors in high versus low income countries they are similar, but due to the lifestyle differences and cultural differences, some risk factors contribute more than others (10).

The common risk factors are (10):

- Gender.
- Early menarche.
- Late onset of menopause.
- Advanced age
- Nuliparity.
- Late age of first pregnancy or child.
- Obesity and lack of physical activity.
- Absent or reduced duration of breastfeeding.
- Low socioeconomic status.
- Increased use of exogenous hormones - contraception and hormone replacement.

In the high income countries the move towards improved lifestyle with the increase in nutrition, reduced physical activity, increased obesity, higher demand for education among women and increased use of exogenous hormones all contribute to an increased risk for the development of breast cancer (10).

In African women, the incidence of breast cancer is on the rise. This can be attributed to the move towards modern lifestyle choices(6) (16). Not many studies have been conducted to evaluate the risk factors contributing towards the development of TNBC in the African

population. Most of the data that is available has come from international studies done on women of African descent (2, 13, 17).

The following risk factors have specifically been associated with an increased risk for the development of TNBC (1):

- Reduced duration or absence of breast feeding.
- Multiparity.
- Obesity - with an increased hip to waist ratio.
- Diet lacking fruits and vegetables.
- Low socioeconomic status.

Socio-economic status plays a major role in the risk of developing TNBC as it is associated with a host of different factors that influence risk such as lifestyle behaviours (diet, exercise), obesity. Cultural believes of reproduction and health seeking behaviour (10, 18) do not impact risk of developing breast cancer, but influence detection and outcome.

1.7. Mammography and ultrasound in TNBC

Imaging findings of breast lesions can be very variable, and malignant lesions may show benign features (19). Particularly TNBC has been shown to have benign features (20). Therefore, awareness of the common presenting features of TNBC it may prevent missed diagnosis (9, 21). The common features include (20, 22):

Mammogram – hyperdense oval or lobular shaped mass or focal asymmetry without micro-calcifications, it may also present with indistinct margins (15, 23).

Ultrasound – hypoechoic nodules without micro-calcifications, commonly with micro-lobulations and commonly parallel orientation (24, 25).

1.8. Treatment and outcome of TNBC

Prognosis and outcome is dependent on many factors, such as, the stage and tumour volume at time of presentation, the epidemiology and associated risk factors, the subtype, whether or not metastases are present. Treatment of TNBC is more challenging as it does not respond to hormonal based treatment, and cytotoxic chemotherapy is indicated. Compared to the other subtypes, TNBC are biologically more aggressive and therefore they progress more rapidly, they generally have a poor outcome and survival rate with a higher

risk of recurrence, commonly presenting with distant recurrence (viscera or brain) rather than local (14, 26-28).

In countries were screening is not available and early diagnosis is a challenge, improved treatment has contributed to improved outcomes. The phenotype of breast cancer is an important contributory factor in determining appropriate treatment and prognosis of breast cancer (17).

There are less treatment options for the TNBC phenotype as it is negative for hormone receptors and does not respond to hormonal based treatment. The mainstay of treatment is chemotherapy (2).

Very little has been done to study the chemo-sensitivity, treatment response and outcome of breast cancer in African women per se, but it has been suggested that there is no significant difference between race and ethnicity in terms of response to therapy and achievement of complete pathological response (1).

1.9. Risk of metastases and recurrence in TNBC

It has been shown that almost 20% of breast cancer patients will eventually develop local recurrence or distant metastases. There is an increasing focus towards hormone receptor expression of breast cancer in determining the pattern, timing and outcome of metastatic disease (14, 29).

Outcome - the outcome of metastatic disease depends on the hormone receptor phenotype of the breast cancer as well as the first site of metastasis. Among all the different subtypes, TNBC is more aggressive and has a higher malignant potential, resulting in a poor outcome and survival rate (22, 25).

Timing - depending on the subtype the 5 year incidence rate of local recurrence is 2% per year. In TNBC there is rapid progression in the first 2 years after diagnosis with a steady decline after 5 years (6).

Pattern - metastasis can occur at any site, bony involvement being the most commonly encountered. In contrast TNBC affects the viscera and central nervous system more commonly than no special type (NST). Bony metastases have a better prognosis whilst central nervous system involvement shows a worse prognosis (6, 30).

Recurrence - TNBC typically recurs within the first few years after diagnosis, and most commonly at a distant site rather than local recurrence. TNBC will more commonly develop distant metastasis before developing local recurrence (6, 23).

1.10. Preventative measures

As risk factors for breast cancer are not easily modifiable, the biggest impact in reducing mortality and morbidity is in the implementation of a screening program (10). However, there are many challenges in setting up a screening program, especially in low and middle income countries. Factors such as funding poses a major challenge, as well as access to health care and breast cancer centers due to remoteness of locations. In areas where screening programs are available, there has been a steady decline in morbidity and mortality of breast cancer. This can be attributed to the early diagnosis of breast cancer. It is clear that screening programs have a large role to play in early detection and improved outcome (12, 31)

1.11. Aim

The aim of this study was to determine the imaging features of TNBC in a tertiary hospital in South Africa.

1.12. Study Objectives

To determine the mammography features of TNBC.

To determine the ultrasound features of TNBC. `

To compare these findings to the international literature.

2. Materials and Methods

2.1. Study design

A retrospective, cross sectional and quantitative study was performed in order to determine the common imaging features of TNBC.

2.2. Study setting

This study was conducted at a tertiary institute in South Africa, Chris Hani Baragwanath Academic Hospital (CHBAH). The imaging reports were obtained from the mammogram department.

2.3. Study sample

The study population included all those patients presenting at the mammogram department between 01/01/2012 – 30/06/2016.

2.4. Inclusion and exclusion criteria

All patients with biopsy proven TNBC were included, provided it was their initial presentation.

Those reports that were illegible or incomplete were excluded from the study.

2.5. Methods of analysis

A pre-existing database from the breast clinic at CHBAH was used to identify the participants. Data was then entered using a data collection sheet (Appendix B).

Participant demographics and clinical information e.g. menopause status and clinical presentation were obtained using the pre-existing database, the mammogram request forms and the clinical questionnaire that is completed at the time of the mammogram.

All the mammograms were read by three independent radiologists with a minimum of 3 years' experience each. All three radiologists' results were combined to form a single score for each participant by taking the majority decision.

Histology reports were obtained from the NHLS and examined with specific reference to hormone status of the tumour as well as the tumour grade.

Figures 2.1. shows some of the mammography features that were used, and figure 2.2. demonstrates ultrasound features.

2.6. Classifications and gradings that were used in this project

A. Oestrogen and progesterone receptor status is determined by using the Allred score. This takes into account the percentage of positive cells as well as the intensity of staining in the visual field. These two scores are added and a total is obtained. Receptor negative cancers have a total score of 0 - 2 and those that are receptor positive have a score of 3 – 8 (32). This score is based on the percentage and intensity of the stain in determining receptor positive cancers. The higher the score the more likely the receptors are positive.

B. HER-2 receptors are normally present in breast tissue and may be amplified in the presence of cancer. This upregulation can be determined by using the IHC (immunohistochemistry) and/or FISH (fluorescence in situ hybridisation) test. The IHC, being the most commonly, uses immunological techniques to identify and localize the receptor proteins. They are graded as follows: 0 and 1+ are negative, 2+ as equivocal and 3+ is positive (33). In our setting, the ICH test is used initially, if the result is equivocal, a FISH is done.

C. Tumour grading was done according to the Bloom and Richardson Classification.
This classification scores the different tumour characteristics individually (tubule formation, nuclear pleomorphism and mitotic count), which is then added together to obtain a total score. A tumour grade is assigned according to this final score (34).

- Grade I – Score of 3 - 5: low grade or well differentiated tumours.
- Grade II – Score of 6 - 7: intermediate grade or moderately differentiated tumour.
- Grade III – Score of 8 - 9: high grade or poorly differentiated tumours.
-

D. BI-RADS (Breast Imaging Reporting and Data System). This classification is a widely accepted risk assessment and quality assurance tool used in mammography, where each visualised lesion is assigned a score (35). Images were analysed using this system.

2.7. Reliability and validity

2.7.1. Reliability

The ultrasound and pathology reports were used, and the slides were not re-read. A large number of pathologists were reading these cases at the time. This could impact on the reliability of the reports, as there is a spectrum of experience present in the doctors working in this departments at the time. The mammograms were re-read by 3 independent radiologists'. Thereafter their findings were analysed and the majority decision was documented. If two or three of the readers recorded a finding, it was counted as a "yes" and, vice versa.

2.7.2. Validity

Ultrasound and mammograms are internationally regarded as accurate imaging modalities when assessing breast cancers (36).

2.7.3. Bias

This study population is drawn from a population that is mostly African. This might introduce bias on the basis of this preselection.

Bias is also introduced by the fact that the 3 reading radiologists knew that all the patients in the study group had a biopsy proven malignancy. However, they were clearly instructed on using the BI-RADS criteria to assess the imaging features and to apply these strictly.

Figure 2.1. Examples of some typical mammogram features that were used during data collection

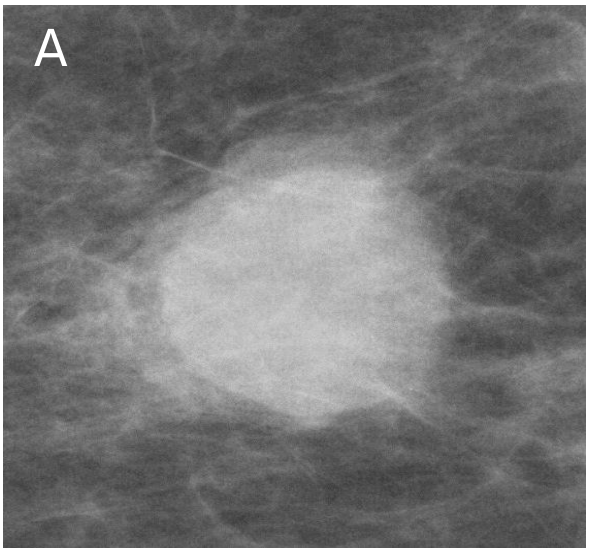

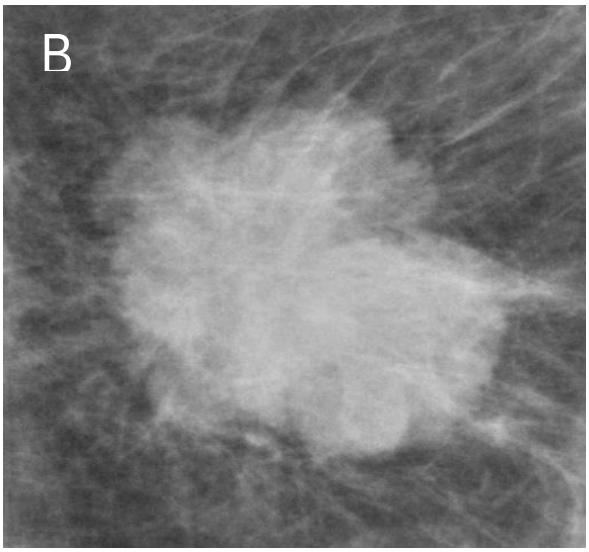

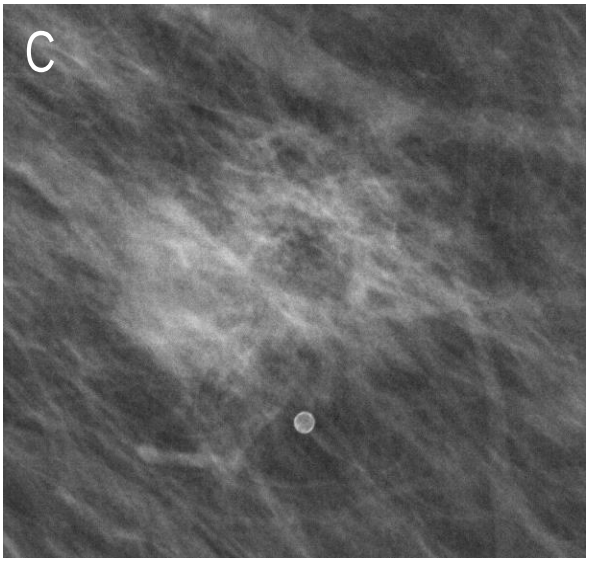

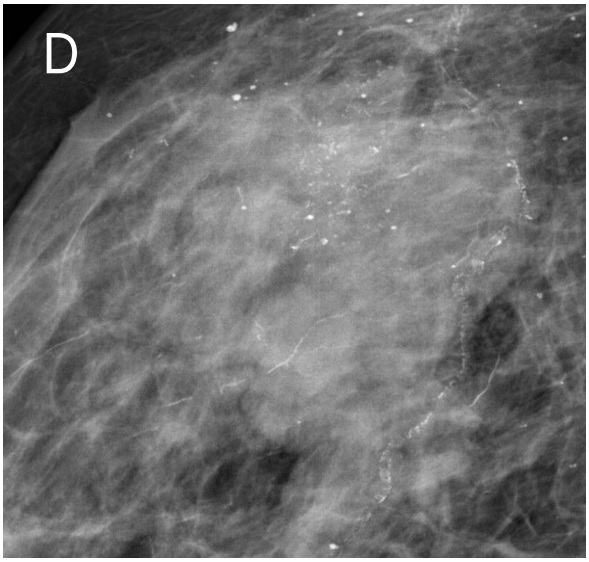

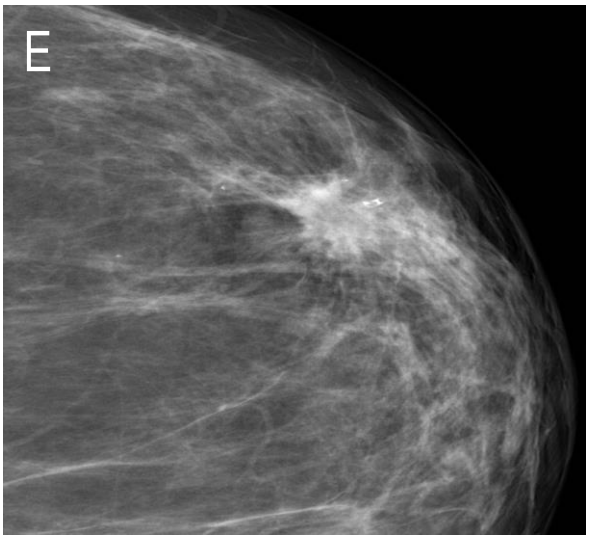

A. Well circumscribed round mass.
B. Lobulated mass with spiculated borders.
C. Irregular mass with indistinct borders.
D. Indistinct mass margins with micro-calcification.
E. Irregular spiculated mass with architectural distortion causing skin tethering and trabecular thickening

Figure 2.2. Examples of some typical ultrasound features that were used during data collection

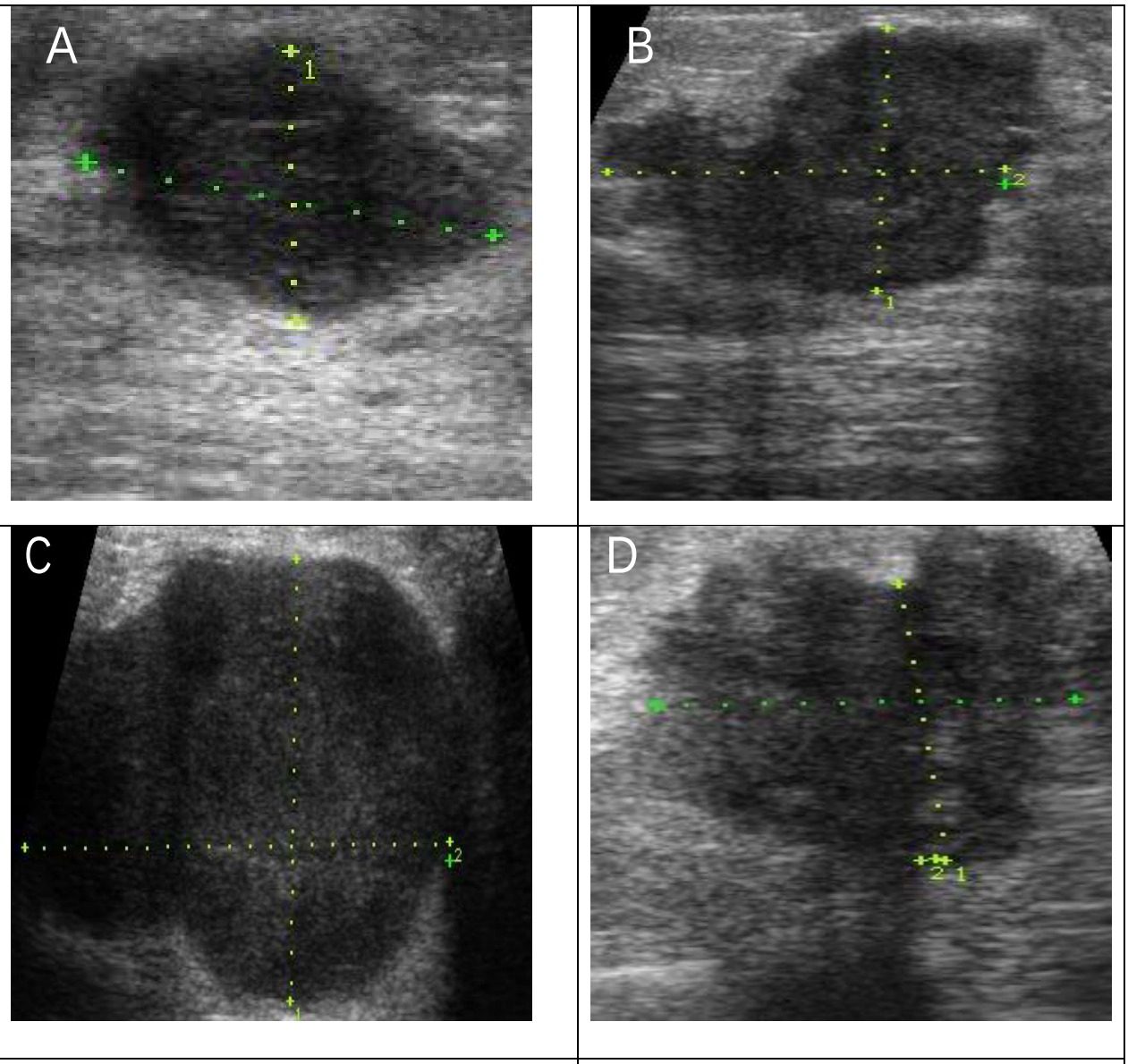

A. A circumscribed oval mass with posterior wall enhancement on ultrasound.
B. Irregular mass which is taller than wider and demonstrates posterior wall shadowing.
C. Matted infiltrated axillary adenopathy
D. Irregular mass with a micro-lobulated margin and posterior wall shadowing.
E. Hypoechoic mass with internal vascularity

2.8. Statistical analysis

Results were expressed as frequencies and percentages for categorical variables.

2.9. Ethics

The study was approved by the Human Research Ethics Committee of the University of the Witwatersrand, approval number M151011 This certificate is attached as Appendix A.

3. Results

100 Patients with biopsy proven TNBC where identified over a period of 4 years at CHBAH. All the patients included in the study were female, no TNBC was diagnosed in a male patient during this time period. The ages ranged from 25 to 95 with a mean of 54.2 years and a median of 56 years

3.1. Clinical findings of TNBC

Table 3.1. The demographics

Category		Frequency
Age	25 - 35	5%
	36 - 45	23%
	46 - 55	31%
	56 - 65	18%
	66 - 75	12%
	76 - 85	9%
	85 - 95	2%
Menopause	Pre	47%
	Post	53%
Gender	Female	100%
	Male	0%
Ethnicity	African	96%
	Other	4%

The most common age group affecting patients with TNBC was 46 – 55 years, with a slight post-menopausal predominance, this is also demonstrated by figure D.1. and D.2. in appendix D. all patients were female and 90% were African.

Table 3.2. The clinical findings

Clinical findings	Frequency
Nipple retraction	0%
Nipple discharge	2%
Palpable mass	87%
Clinical data not available	13%
RVD positive	23%
RVD negative	63%
RVD unknown	14%

The most common clinical findings, as documented, in this study was a palpable mass (87%), while the majority of our population group was RVD negative (63%). Graphical representation of this is present in figure D.3. in appendix D.

3.2. Mammogram findings

The mammogram findings are listed in tables 3.3 to 3.7 below. The findings are listed under the following headings: table 3.3. background density, 3.4. laterality and side of breast mass, 3.5.the shape and margins of lesion on mammogram, 3.6. the size of the lesion on mammogram and 3.7. additional features that were seen on mammogram.

The findings on mammogram are documented below.

3.2.1. Breast density

Breast density plays an important role in determining the likelihood of detecting a mass in the presence of dense breast tissue. In our study, type b breast density (62%) was the most common, followed by type a (18%), type c (16%), with the least common density being type d (4%). These findings are summarised in Table 3.3. below as well as figure D.4. in appendix D.

Table 3.3. Background density

Background density	Frequency
Type a	18%
Type b	62%
Type c	16%
Type d	4%
Total	100%

3.2.2. Laterality and site of lesions

The left breast was marginally more affected than right (51%). The upper outer quadrants (UOQ) (47%) was the most common site. Diffuse involvement was present in 14% and lower inner quadrant (LIQ) involvement in 12% of patients. These findings are shown in table 3.4. below and in figure D.5. in appendix D.

Table 3.4. Laterality and site of the breast mass

	Location	Frequency
Side	Left side	51%
	Right side	49%
Site	Diffuse	14%
	UOQ	47%
	LOQ	1%
	LIQ	12%
	UIQ	5%
	12 O' CLOCK	9%
	6 O' CLOCK	2%
	Retro-areolar	8%
	Axilla	2%

3.2.3. Shape and margins of lesions

The most common mass shape encountered was oval (27%) and irregular (27%).
Well circumscribed (30%) borders were the most commonly visualised margins, followed closely by indistinct margins (28%), the rest was made up of obscured (14%), spiculated (11%) and micro-lobulated (4%) being the least common. There was diffuse involvement of the breast in 13%.

In the 30% of circumscribed margins the average age of presentation was 52.2 years old. These findings are summarised in table 3.5 below.

Table 3.5. The shape and margins of lesions on mammogram

These findings are demonstrated on both the table below as well as figure D.6. and D.7. in appendix D.

	Category	Frequency	Average age
Mass shape	Round	12%	56
	Oval	27%	56
	Lobulated	19%	53
	Irregular	27%	53
	Diffuse	15%	52
Mass margins	Circumscribed	30%	52.2
	Micro-lobulated	4%	56
	Spiculated	11%	66
	Obscured	14%	54.5
	Indistinct	28%	51.3
	Diffuse	13%	52

3.2.4. Size of lesions

The average size of the masses were as follows: length of 56 mm, breadth 45 mm and width of 38 mm. The entire breast was involved in 13% of the cases. The majority of patients (97%) presented with masses equal to and larger than 20 mm, as shown in table 3.6 below.

Table 3.6. The size of lesions on mammogram

Mass size	Range
Length	14 – 177 mm with an average of 56 mm
Breadth	12 – 137 mm with an average of 45 mm
Width	9 – 130 mm with an average of 38 mm
Diffuse involvement	13%

3.2.5. Additional features

Global asymmetry was seen in 48% of patients, with focal asymmetry seen in 27%. Architectural distortion was noted in 88% of cases, and was the most common additional finding with trabecular thickening in 55%. These findings are demonstrated in table 3.7 below. In addition, these findings are demonstrated in figure D.8. and D.9. in appendix D.

Table 3.7. Additional features that were seen on mammogram

Feature	Frequency
Global asymmetry	48%
Focal asymmetry	27%
Architectural distortion	88%
Trabecular thickening	55%
Skin thickening	47%
Axillary nodes	33%
Mass contains micro-calcification	17%

Micro-calcification only	1%

Footnote: this table does not add up to 100% as not all mammograms had additional features.

3.3. Ultrasound findings

The ultrasound findings are listed in tables 3.8 to 3.12 below. The findings are listed under the following headings: table 3.8. the shape and the margin of the masses, 3.9. the echogenicity and additional features on sonar.

3.3.1. Shape and margins

An irregular shaped mass was the most commonly encountered shape (56%), followed by oval masses (26%) and round lesions (18%). Spiculated borders were seen on 29% of patients, followed closely by indistinct masses (27%) and well circumscribed masses (26%). This is shown below in table 3.8.

Table 3.8. The shape and margin of the lesions as seen on ultrasound

	Category	Frequency
Mass shape	Oval	26%
	Round	18%
	Irregular	56%
Borders	Indistinct	27%
	Spiculated	29%
	Well circumscribed	26%
	Micro-lobulated	18%

These findings are also demonstrated in figure D.10. and D.11. in appendix D.

3.3.2. Internal echopattern and additional sonographic findings

Most of the lesions were hypoechoic (80%) followed by a heterogeneous appearance of 19% of the masses. Many patients presented with axillary adenopathy, 81%, however these included malignant appearing nodes as well as reactive appearing nodes. Only 13% of masses presented with posterior wall shadowing and 3% of the masses had an echogenic halo, as demonstrated in table 3.9 below.

Table 3.9. The internal echogenicity and additional ultrasound findings

	Features	Frequency
Internal echogenicity	Hypoechoic	80%
	Heterogeneous	19%
	Anechoic	1%
	Hyperechoic	0%
	Isoechoic	0%
Additional findings	Axillary adenopathy	81%
	Posterior wall shadowing	13%
	Echogenic halo	3%
	Posterior wall enhancement	0%

Footnote: this table does not add up to 100% as not all ultrasounds had additional features.

These findings can also be found in figure D.12. and D.13. in appendix D.

3.4. BI-RAD classification

A final assessment was given for each lesion and is summarised in table 3.10 below. Category 5 was seen in the majority of the cases, (82%), followed by 10% of category 4c and 7 % in category 4b. These findings can be found in figure D.14. in appendix D as well.

Table 3.10. BI-RADS classification

BI-RADS	Frequency
Category 1	0%
Category 2	0%
Category 3	1%
Category 4a	0%
Category 4b	7%
Category 4c	10%
Category 5	82%
Total	100%

3.5. Histology results

The most common histological subtype was invasive ductal carcinoma (96%). Lesions were graded according to the Bloom and Richardson grading system. Grade III (58%) was found in the majority of the tumours. This is also demonstrated in figure D.15. and D.16. in appendix D.

Table 3.11. Histology type and tumour grade

	Category	Frequency
Histology type	DCIS	4%
	IDC	96%
	IDC + DCIS	0%
	ILC	0%
Bloom and Richardson grading	Grade I	1%
	Grade II	41%
	Grade III	58%

4. Discussion

Breast cancer is one of the most common primary neoplasms diagnosed in women and one of the leading causes of cancer deaths worldwide (2). It has been shown that TNBC is an aggressive subtype. TNBC is more common in a younger age group, women of African descent and in poor socioeconomic groups (1). Akarolo-Anthony et al also demonstrated benign imaging features in TNBC, making this a diagnostic challenge (6). Early detection and treatment are imperative.

4.1. Demographics

Although male patients can have TNBC, this is rare. Only 1% of male breast cancers are triple negative, according to Chavez-MacGregor et al (37). We had no male patients that fulfilled the inclusion criteria in our study period, and all of the patients in this study were female.

The most commonly affect age group in our population was between 46-55 years with a mean age of 54. This is similar to what is found in the literature. Bauer et al, conducted a study in 2007 comparing TNBC with NST, and found that TNBC presented at a mean age of 54 year as compared to NST which presented at 60 years (1). Boisserie-Lacroix et al also found that TNBC presented at a significantly younger age of 54 compared to NST at 61 years (31).

Our study demonstrated that a significant amount of our patients were pre-menopausal at the time of presentation, 47%. This is what Bo Li et al suggested in their study conducted in 2014, looking at the imaging features of TNBC (15).

The majority of our patients were African, constituting 96% of the group. CHBAH serves an urban population of mostly African patients, and thus our patient population is representative of the population demographics of this area. Similarly, in the literature, the predominant ethnic group in a study population was dependent on the majority of the population being serviced at that particular hospital (1, 2).

4.2. Clinical findings

There is a high prevalence of HIV patients in Africa as a whole and it is therefore necessary

to ascertain whether this plays a role in the development and progression of breast cancer. In a study done by Cubasch et al in 2013 looked at a study population from the same area, evaluating the relationship between HIV status and breast cancer in 1092 patients. This study found that 20% of patients were HIV infected, similar to our study which showed 23% to be HIV infected (13).

In our study, clinical data was not always well documented. However, all of the patients in our study with documented clinical findings presented with a clinically palpable mass. In contrast, Boisserie-Lacroix's study in 2012 showed that only 34% of their patients presented as a result of a self-detected palpable mass (22). At our centre, this may be attributed to delayed patient presentation, delayed diagnosis, lack of a screening program and lack of breast awareness and education.

4.3. Imaging findings

4.3.1. Background density

The patients' breast density can make identification of a mass more difficult, therefore the more breast tissue presents the more difficult it is to detect a mass (38, 39). Younger patients tend to have denser breast tissue than older patients, and this contributes to the fact that breast masses are more difficult to identify in young patients (38, 39). In our study type B breast density (scattered fibro-glandular tissue) was the most commonly seen, making up 62%. In contrast, the most commonly seen breast density in TNBC in the literature was type C (heterogeneously dense tissue), Kojima et al found 50.6% and Krizmanich-Conniff found 52% to have type C breast density (25, 40). Studies have demonstrated that the general population in Africa are more likely to be obese (41, 42) and that this is associated with fattier, less dense breast tissue (41, 42). This may be the reason why our patients presented with lower breast density.

4.3.2. Location

in our study, the left breast was more frequently involved than the right, and the upper outer quadrants was the most commonly affected sites. This was also demonstrated in other

TNBC studies, e.g.Tulinius et al (43). This is consistent with other breast cancer NST, where the left breast and the UOQs are also the most commonly affected locations (22).

4.3.3. Shape

According to BI-RADS, the mass shape can allude to a mass being more likely benign or malignant. The round, oval and lobulated shapes are commonly seen in benign lesion, whereas an irregularly shaped mass is more likely to represent a malignant lesion. In our study, benign appearing mass shapes was found in 58% of patients, which was in accordance to what Boisserie-Lacroix et al found, showing that 67.7% of his patients demonstrated benign appearance (31).

4.3.4. Margins

A large percentage (30%) of our population demonstrated benign margins (circumscribed masses) on mammogram. This was in keeping with the literature, where Boisserie-Lacroix et al encountered benign margins in 10.8% of masses (31). The average age of our patients with lesions that had benign margins was also significantly less that those patients with spiculated margins (52.2 years vs 66 years).

In our study, circumscribed margins were seen in 26% of ultrasound masses. Kemp et al demonstrated a high rate of malignancy (11%) in young patients with benign appearing masses (19). As young patients usually only have an ultrasound examination, the radiologist needs to keep the possibility of a malignant diagnosis in mind at all times. Additional features should be assessed to distinguish benign from malignant masses, not only lesional margins. Features such as mass shape, skin and nipple changes, trabecular involvement, the presence of asymmetry and calcification should be sought on mammogram. On ultrasound, these additional features include the orientation of the mass, the shape, the internal echogenicity, posterior wall shadowing or the presence of a thick irregular echogenic halo.

4.3.5. Size

Our study showed an average mass size of 56 x 45 x 38 mm, with 97% presenting with a mass size equal to or larger than 20 mm on imaging. This was significantly larger than what was found in the literature. Bauer et al conducted a study in 2007, which showed that the

average mass size of TNBC was 22 mm compared to 17 mm found in NST, Wei-Tse Yang et al found the same, with TNBC with an average size of 33 mm and 25-28 mm in NST (1, 23). These studies are based on screening mammography. As we do not have a screening program, our patients presented late with larger, clinically palpable masses.

4.3.6. Asymmetry

In the literature, it was shown that patients presented with focal asymmetry only (with no associated mass) more commonly than was demonstrated in our study population. In 2010 Dogan et al looked at the imagining features of TNBC and demonstrated that 22% presented with focal asymmetry not associated with a mass (20). Similarly, Sook et al, found that 22% of their patients presented with a focal asymmetry without a mass (9). In our study population, focal and global asymmetry was seen in 76% of cases. However, this asymmetry was also associated with a focal mass. Diffuse breast involvement with no visible mass lesion was seen in only 13% of our study population. This is likely due to the fact that patients in our study presented much later in the disease process allowing for a focal mass to develop from an area of asymmetry.

4.3.7. Internal echogenicity on ultrasound

According to Kim et al (21), TNBC presented more commonly with a hypoechoic (82.2%) mass as compared to NST (10.8%). In our study, the majority of masses were hypoechoic (80%) on ultrasound.

4.3.8. Additional features

Suspicious calcification seen alone or associated with a mass is not a common feature of TNBC. This is shown in the literature by Yang et al, 15% (20, 23) and confirmed by our findings (17%).

Architectural distortion was seen in 88% of cases in our study, which was vastly more than that seen in the literature (20, 22), likely due to the late presentation.

In our study, axillary lymphadenopathy on imaging was seen in 81% of our patients. This was less commonly seen in the literature, where Kim et al found 35.6% had axillary nodal involvement on imaging. However, it must be kept in mind that in our population HIV is

more prevalent and commonly present with reactive axillary adenopathy. Therefore, the axillary adenopathy found in our population may be due to tumour involvement or HIV infection (13).

Comparison between TNBC and NST by Yang et al as well as Kim et al demonstrated that axillary nodal involvement was similar in both NST and TNBC (21, 24).

4.3.9. Unusual appearances of TNBC

Our study population showed some unusual presentations of TNBC. Figure 4.1. to 4.3. below demonstrates some of the unusual imaging features of TNBC in this study population.

Figure 4.1. Examples of atypical appearance of TNBC in our study population.

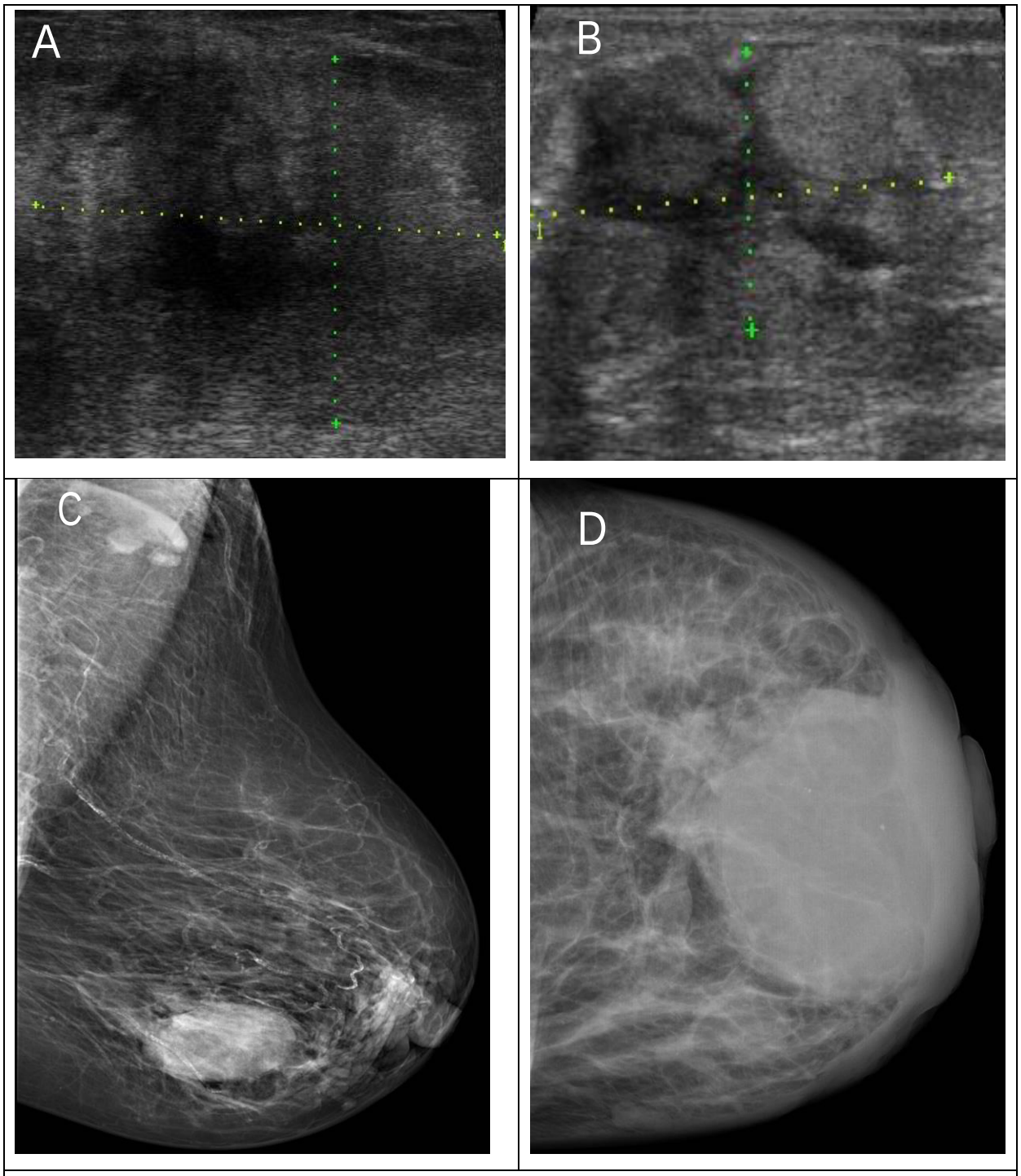

A. Indistinct ill-defined mass seen on ultrasound.
B. Mixed echogenicity mass seen on ultrasound.
C. Well circumscribed oval mass with associated axillary adenopathy.
D. Large oval mass with well circumscribed margins. Additional features of global trabecular thickening and diffuse skin thickening.

Figure 4.2. Mammogram features demonstrating unusual appearance of TNBC in our population

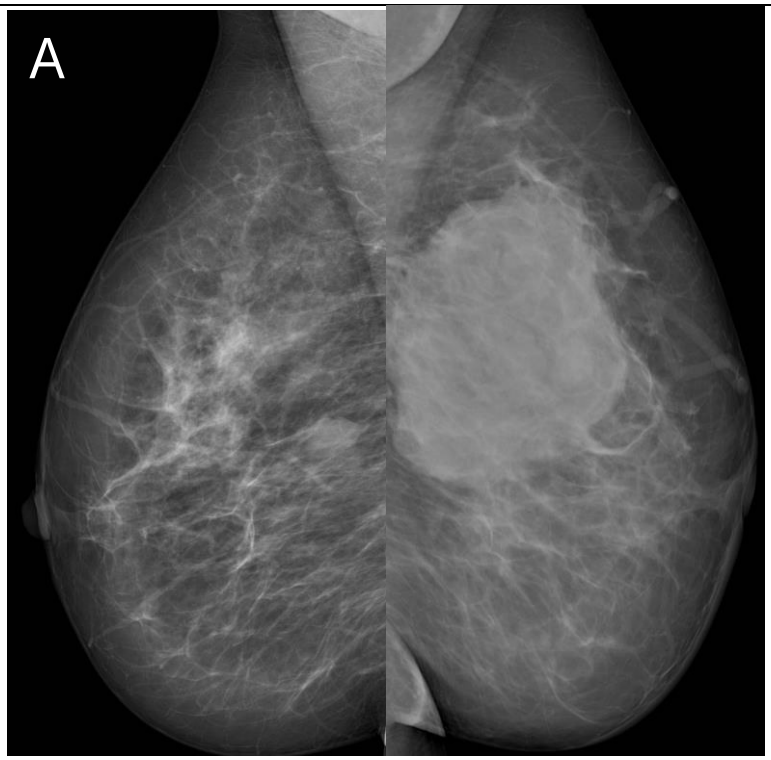

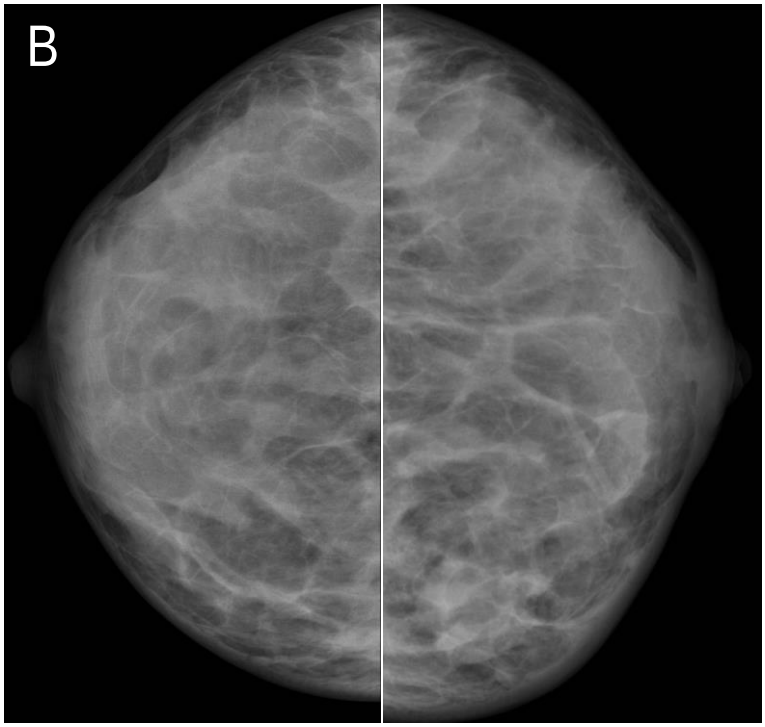

A. A well-defined large circumscribed mass with global trabecular thickening, compared to the normal side.
B. A well-defined small mass in the medial aspect of the left breast in a type d density breast tissue.

Figure 4.3. Aggressive presentation of TNBC

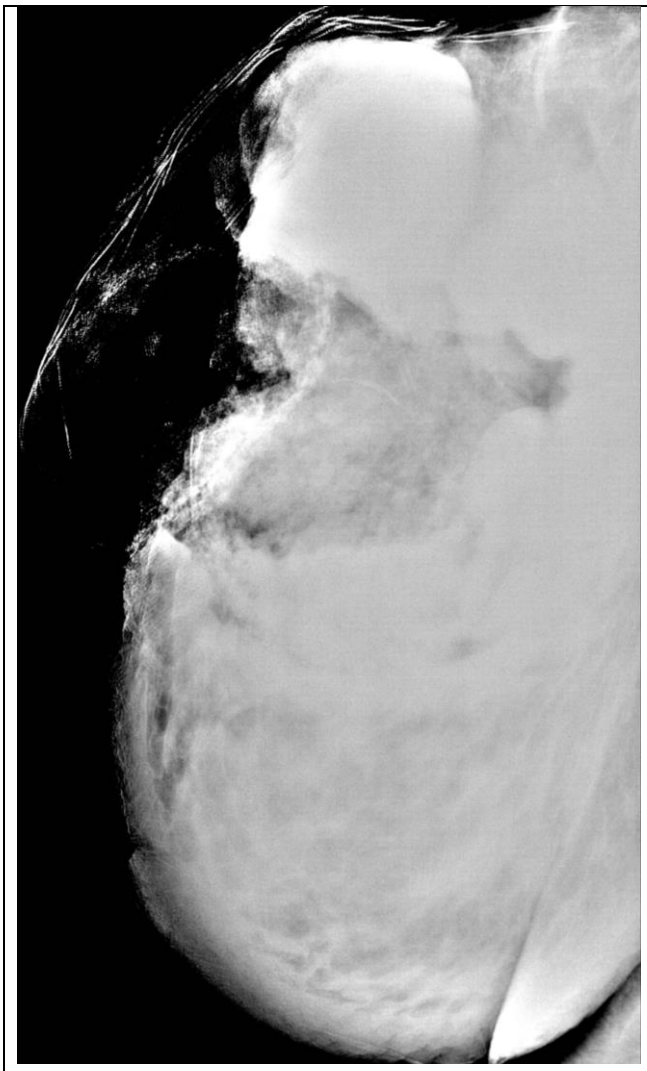

Diffuse involvement of the breast with a large ulcerative, fungating component.

Contralateral breast demonstrates the normal side with no focal lesions.

4.4. BI-RADS final assessment

A final assessment of BI-RADS category 4C or 5 was made in the majority of our patients, making up 92% of all cases. There are many studies in the literature that demonstrate a lower BI-RADS classification. Yang Qi et al showed that 80.5% had a final assessment of Category 4A and Boisserie Lacroix et al showing 65.9% Category 4A – likely benign (24, 31). Our patients presented later, with more advanced disease, accounting for this difference. Many well-circumscribed masses had additional features resulting in a higher Bi-rad score.

4.5. Comparison of histology findings of triple negative breast cancer

	Kojima (2010) (25)	Boisserie-Lacroix et al (2013) (31)	Yang Qi et al (2015) (24)	Our study (2017)
Invasive ductal carcinoma	96.5%	79%	85.4%	96%
Ductal carcinoma in situ	3.5%	21%	14.6%	4%

Table 4.5. above demonstrates that the histological findings of our study was similar to the literature, demonstrating that the majority of TNBC where invasive carcinomas rather than carcinomas in situ (22, 24, 25, 31). In our study patients presented late with a clinically palpable mass and this may be the reason why the majority of our cases also then demonstrated invasive carcinomas. This was similar to what Kojima et al found (25). Delayed presentation may result in a larger percentage of invasive cancers as compared to those who are diagnosed earlier.

The Bloom and Richardson grading system has prognostic significance. There are three different grades and higher grade tumours demonstrate worse the prognosis. Higher grade tumours are more aggressive, tend to grow rapidly and metastasise early (34). In our study 58% of our patients presented with grade 3 breast cancer, confirming the aggressive nature of TNBC.

4.6. Delayed presentation

We have shown that our patients present later, with more advanced disease. Resulting in clinically palpable masses, malignant imaging features, delayed presentation and invasive carcinoma on histology.

The reason for this late presentation in our population could be attributed to several factors such poor health education, poor health seeking behaviour, the preferential use of traditional medicine as well as limited resources and the absence of breast cancer screening programs.

4.7. Current applications

The literature has shown that TNBC is an aggressive tumour, demonstrating a more rapid progression with earlier onset of metastatic disease and a higher risk of recurrence post treatment. They also tend to occur more commonly in the younger population, in premenopausal women and with benign imaging features. Our study demonstrated imaging features comparable to the literature, but also showed that the lesions were larger and more advanced. It is therefore of imperative that a high index of suspicion is maintained by all medical health care practitioners, starting from the primary health care providers to the radiologist and breast surgeons.

4.8. Limitations of the current study

As this was a retrospective study, not all the clinical information was available to us.
No comparison was made between TNBC and receptor positive cancers as this was beyond the scope of this study.
Not all ultrasound images were available for assessment, and documentation of ultrasound findings was suboptimal.
All readers knew that these patients had biopsy proven malignancies.

4.9. Future applications

TNBC is an extremely aggressive subtype of breast cancer and typically presents in younger patients with a more rapid progression compared to other subtypes. They also present with benign features on imaging. In our population patients tend to present late due to many factors, such as poor health care seeking behaviour, the use of alternative medicine, poor access to health care facilities and lacking screening programs.

Education plays a critical role in improving these factors, patient education as well as education of the health care providers from primary health care to dedicated breast care specialists. In an attempt to improve early detection and reduce mortality, a high index of suspicion by health care providers is of utmost importance. A national screening program could be beneficial to the early diagnosis of not only TNBC, but all breast cancers in South Africa.

5. Conclusion

TNBC is an aggressive subtype of breast cancers and tends to occur in a younger population. It typically presents with benign imaging features which can lead to delayed diagnosis and treatment.

In our population, the majority presented with a clinically palpable mass and with larger lesions and more aggressive imaging features than seen in the literature. This can be attributed to delayed presentation, poor health care seeking behaviour and poor accessibility of health care facilities.

Therefore, the most important factor that may help in improving the early detection rate is by education. Firstly, patient education is extremely important, thereby allowing for early detection and more effective treatment. Secondly, education of all health care workers, starting from the primary health care providers all the way to the breast specialists, thereby increasing the index of suspicion and preventing a delay in diagnosis.

6. References

(1) Bauer KR, Brown M, Cress RD, et al. 2007. Descriptive analysis of estrogen receptor (ER)-negative, progesterone receptor (PR)-negative, and HER2-negative invasive breast cancer, the so-called triple-negative phenotype: a population-based study from the California cancer Registry. Cancer, 109(9):1721-8.

(2) Brewster AM, Chavez-MacGregor M, Brown P. 2014. Epidemiology, biology, and treatment of triple-negative breast cancer in women of African ancestry. Lancet Oncol, 15(13):e625-34.

(3) Beatrice LS, Scoccianti C, Loomis D, et al. 2015. Breast-Cancer Screening - Viewpoint of the IARC Working Group. The New England Journal of Medicine, 372(24):2353 - 58.

(4) Schmadeka R, Harmon BE, Singh M. 2014. Triple-negative breast carcinoma: current and emerging concepts. Am J Clin Pathol, 141(4):462-77.

(5) Sperduto PW, Kased N, Roberge D, et al. 2012. Effect of tumor subtype on survival and the graded prognostic assessment for patients with breast cancer and brain metastases. Int J Radiat Oncol Biol Phys, 82(5):2111-7.

(6) Akarolo-Anthony SN, Ogundiran TO, Adebamowo CA. 2010. Emerging Breast Cancer Epidemic: Evidence from Africa. Breast Cancer Res, 12(Suppl 4):S8.

(7) Carey LA. 2010. Directed therapy of subtypes of triple-negative breast cancer. Oncologist, 15 Suppl 5:49-56.

(8) Hammond ME, Hayes DF, Dowsett M, et al. 2010. American Society of Clinical Oncology/College Of American Pathologists guideline recommendations for immunohistochemical testing of estrogen and progesterone receptors in breast cancer. J Clin Oncol, 28(16):2784-95.

(9) Ko ES, Lee BH, Kim HA, et al. 2010. Triple-negative breast cancer: correlation between imaging and pathological findings. Eur Radiol, 20(5):1111-7.

(10) Bray F, McCarron P, Parkin DM. 2004. The changing global patterns of female breast cancer incidence and mortality. Breast Cancer Res, 6:229-39.

(11) NHLS. 2010. South Africa National Cancer Registry. Available: http://www.nioh.ac.za/publications/cancer-statistics/ [Accessed on 17/05/2016].

(12) Vorobiof DA, Sitas F, Vorobiof G. 2001. Breast cancer incidence in South Africa. J Clin Oncol, 19(18 Suppl):125S-27S.

(13) Cubasch H, Joffe M, Hanisch R, et al. 2013. Breast cancer characteristics and HIV among 1,092 women in Soweto, South Africa. Breast Cancer Res Treat, 140(1):177-86.

(14) Chikarmane SA, Tirumani SH, Howard SA, et al. 2015. Metastatic patterns of breast cancer subtypes: what radiologists should know in the era of personalized cancer medicine. Clin Radiol, 70(1):1-10.

(15) Li B, Zhao X, Dai SC, et al. 2014. Associations between mammography and ultrasound imaging features and molecular characteristics of triple-negative breast cancer. Asian Pac J Cancer Prev, 15(8):3555-9.

(16) Sally N Akarolo-Anthony1 TOOaCAA. 2010. Emerging breast cancer epidemic: evidence from Africa. breast cancer research, 12(4).

(17) Herbst MC. 2015. Fact Sheet on the Top Ten Cancers per Population Group. Available: http://www.cansa.org.za/files/2015/05/Fact-Sheet-Top-Ten-Cancers-per-Population-Group-May-2015.pdf [Accessed on 22/05/2017].

(18) Ma GX, Gao W, Lee S, et al. 2012. Health seeking behavioral analysis associated with breast cancer screening among Asian American women. Int J Womens Health, 4:235-43.

(19) Kemp ML, Andronikou S, Lucas S, et al. 2014. Is routine biopsy of sonographically benign breast lesions in black African women under 40 years of age recommended? S Afr J Surg, 52(2):36-40.

(20) Dogan BE, Gonzalez-Angulo AM, Gilcrease M, et al. 2010. Multimodality imaging of triple receptor-negative tumors with mammography, ultrasound, and MRI. AJR Am J Roentgenol, 194(4):1160-6.

(21) Kim MY, Choi N. 2013. Mammographic and ultrasonographic features of triple-negative breast cancer: a comparison with other breast cancer subtypes. Acta Radiol, 54(8):889-94.

(22) Boisserie-Lacroix M, Mac Grogan G, Debled M, et al. 2012. Radiological features of triple-negative breast cancers (73 cases). Diagn Interv Imaging, 93(3):183-90.

(23) Yang WT, Dryden M, Broglio K, et al. 2008. Mammographic features of triple receptor-negative primary breast cancers in young premenopausal women. Breast Cancer Res Treat, 111(3):405-10.

(24) Yang Q, Liu HY, Liu D, et al. 2015. Ultrasonographic features of triple-negative breast cancer: a comparison with other breast cancer subtypes. Asian Pac J Cancer Prev, 16(8):3229-32.

(25) Kojima Y, Tsunoda H. 2011. Mammography and ultrasound features of triple-negative breast cancer. Breast Cancer, 18(3):146-51.

(26) Tsau HS, Yen AM, Fann JC, et al. 2015. Mammographic tumour appearance and triple-negative breast cancer associated with long-term prognosis of breast cancer death: a Swedish Cohort Study. Cancer Epidemiol, 39(2):200-8.

(27) Kast K, Link T, Friedrich K, et al. 2015. Impact of breast cancer subtypes and patterns of metastasis on outcome. Breast Cancer Res Treat, 150(3):621-9.

(28) Reddy KB. 2011. Triple-negative breast cancers: an updated review on treatment options. Curr Oncol, 18(4):e173-9.

(29) Wojcinski S, Soliman AA, Schmidt J, et al. 2012. Sonographic features of triple-negative and non-triple-negative breast cancer. J Ultrasound Med, 31(10):1531-41.

(30) Dogan BE, Turnbull LW. 2012. Imaging of triple-negative breast cancer. Ann Oncol, 23(Suppl 6):vi23-9.

(31) Boisserie-Lacroix M, Macgrogan G, Debled M, et al. 2013. Triple-negative breast cancers: associations between imaging and pathological findings for triple-negative tumors compared with hormone receptor-positive/human epidermal growth factor receptor-2-negative breast cancers. Oncologist, 18(7):802-11.

(32) Segen's Medical Dictionary. 2012. Allred Scoring System. Available: http://medical-dictionary.thefreedictionary.com/Allred+scoring+system [Accessed on 03/02/2016].

(33) Yaziji H, Goldstein LC, Barry TS, et al. 2004. HER-2 testing in breast cancer using parallel tissue-based methods. JAMA, 291(16):1972-7.

(34) Bansal C, Singh US, Misra S, et al. 2012. Comparative evaluation of the modified Scarff-Bloom-Richardson grading system on breast carcinoma aspirates and histopathology. Cytojournal, 9:4.

(35) Eberl MM, Fox CH, Edge SB, et al. 2006. BI-RADS classification for management of abnormal mammograms. J Am Board Fam Med, 19(2):161-4.

(36) Berg WA, Gutierrez L, NessAiver MS, et al. 2004. Diagnostic accuracy of mammography, clinical examination, US, and MR imaging in preoperative assessment of breast cancer. Radiology, 233(3):830-49.

(37) Chavez-Macgregor M, Clarke CA, Lichtensztajn D, et al. 2013. Male breast cancer according to tumor subtype and race: a population-based study. Cancer, 119(9):1611-7.

(38) Boyd NF, Guo H, Martin LJ, et al. 2007. Mammographic density and the risk and detection of breast cancer. N Engl J Med, 356(3):227-36.

(39) Egan RL, Mosteller RC. 1977. Breast cancer mammography patterns. Cancer, 40(5):2087-90.

(40) Krizmanich-Conniff KM, Paramagul C, Patterson SK, et al. 2012. Triple receptor-negative breast cancer: imaging and clinical characteristics. AJR Am J Roentgenol, 199(2):458-64.

(41) Wanders JO, Bakker MF, Veldhuis WB, et al. 2015. The effect of weight change on changes in breast density measures over menopause in a breast cancer screening cohort. Breast Cancer Res, 17:74.

(42) Puoane T, Steyn K, Bradshaw D, et al. 2002. Obesity in South Africa: the South African demographic and health survey. Obes Res, 10(10):1038-48.

(43) Tulinius H, Sigvaldason H, Olafsdottir G. 1990. Left and right sided breast cancer. Pathol Res Pract, 186(1):92-4.

Appendix A: Ethics Clearance Certificate

R14/49 Dr Deepa Bhana-Nathoo

HUMAN RESEARCH ETHICS COMMITTEE (MEDICAL)

CLEARANCE CERTIFICATE NO. M151011

NAME: (Principal Investigator)	Dr Deepa Bhana-Nathoo
DEPARTMENT:	Radiology Chris Hani Baragwanath Academic Hospital
PROJECT TITLE:	Imaging Features of Triple Negative Breast Cancer in a Tertiary Hospital in South Africa
DATE CONSIDERED:	30/10/2015
DECISION:	Approved unconditionally
CONDITIONS:	
SUPERVISOR:	Dr Susan Lucas and Dr H Cubasch
APPROVED BY:	Professor P Cleaton-Jones, Chairperson, HREC (Medical)
DATE OF APPROVAL:	02/03/2016

This clearance certificate is valid for 5 years from date of approval. Extension may be applied for.

DECLARATION OF INVESTIGATORS

To be completed in duplicate and **ONE COPY** returned to the Secretary in Room 10004, 10th floor, Senate House, University.
I/we fully understand the conditions under which I am/we are authorized to carry out the above-mentioned research and I/we undertake to ensure compliance with these conditions. Should any departure be contemplated, from the research protocol as approved, I/we undertake to resubmit the application to the Committee. **I agree to submit a yearly progress report**.

Principal Investigator Signature Date 02/11/2015.

PLEASE QUOTE THE PROTOCOL NUMBER IN ALL ENQUIRIES

Appendix B: Data collection sheet

DATA COLLECTION SHEET						
Study Number						
Date of presentation:			GENDER: M/F		Age	
Clinical Findings						
Menopausal state	Pre	During	Post	LMP		
Symptomatic	YES	NO				
Palpable mass	YES	NO		SIDE		
Nipple discharge	YES	NO		SIDE		
Pain or discomfort	YES	NO		SIDE		
Previous surgery or biopsy	YES	NO		WHEN		
Previous breast imaging	YES	NO		WHEN		
RVD	YES	NO	UNKNOWN		ARV?	
Parity	0	1	2	3	4	5 or more
Family history of breast cancer	YES	NO				
On HRT	YES	NO				
On contraception	YES	NO				
Histology Findings						
Hormone receptor positive (ER OR PR)	YES	NO				

HER-2 receptor positive	YES	NO				
Tumour Type	DCIS	IDC	ILC	IDC+DCIS		OTHER
Bloom and Richardson grading	I	II	III			
BI-RAD classification	1	2	3	4	5	6
Mammography Findings						
Mass Size (mm)	Length		Breadth			
	Width					
Mass Shape	Round	Oval	Lobulated			
Background density	Dense	Heterogeneously dense		Predominantly fatty		
Location	Inner quadrant		Outer quadrant		Diffuse	
	Left		Right			
Calcifications	Only	Mass with calcification				
Borders	Well defined	Lobulated	Spiculated	Obscured	Indistinct	
Asymmetry	Focal	Global	Developing	NAD		
Architectural distortion	Yes	No				
Skin thickening	Yes	No				
Trabecular thickening	Yes	No				
Lymphadenopathy	Axillary	Intra-mammary				
Ultrasound Findings						
Mass Size	< 2cm	> 2cm				

Mass Shape	Oval	Round	Irregular		
Border	Abrupt Interface		Well circumscribed		
Location	Inner quadrant		outer quadrant		
Internal echogenicity	Yes	No			
Posterior wall enhancement	Yes	No			
Posterior wall shadowing	Yes	No			
Echogenic halo	Yes	No			
Vascularity present	Yes	No			

Appendix C: Note on referencing style

Please note that the referencing in this thesis is a modification of the Vancouver Referencing style, done according to the Faculty of Health Sciences Style Guide as set out by the Wits Health Sciences Library.

The information on this WHSL Vancouver Citation Style Guide for Theses, Dissertations and Research Reports is available from http://libguides.wits.ac.za/whsl-vancouver updated on 30 January 2017.

Appendix D: Graphical presentation of results

Figure D.1. Average age seen in our population group

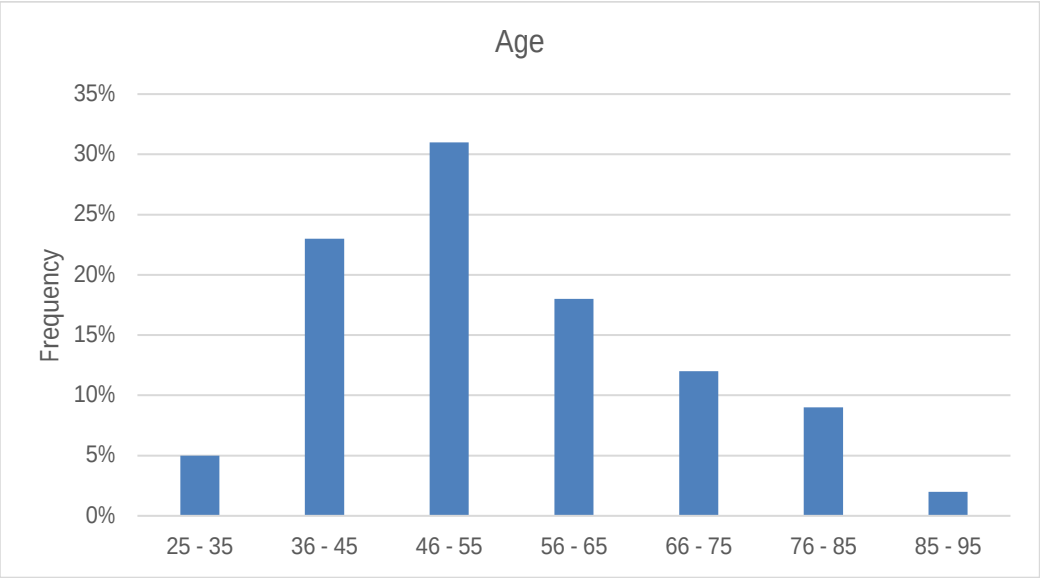

Figure D.2. Menopause status commonly encountered in our population group

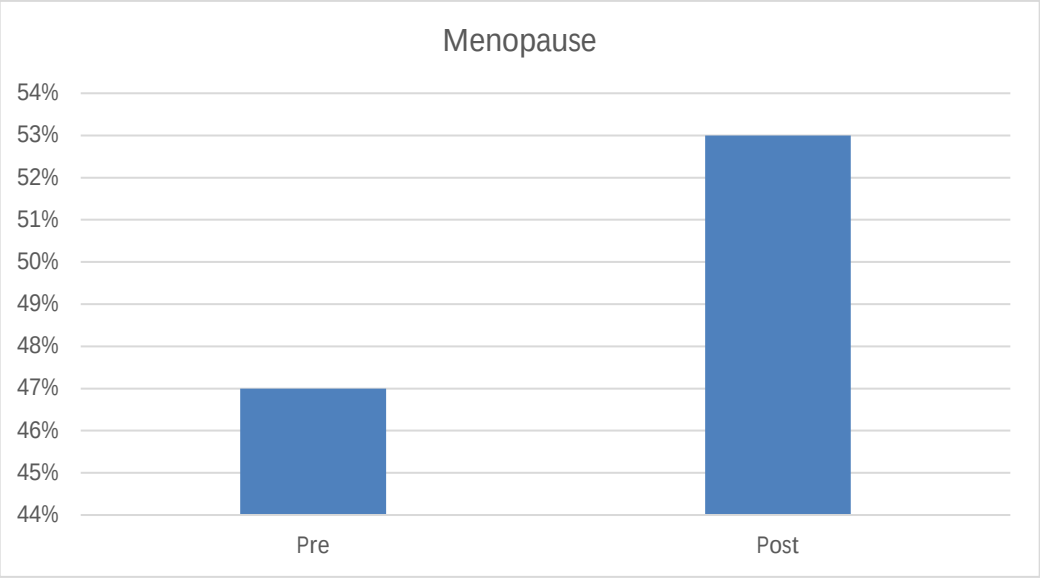

Figure D.3. Additional clinical findings found in our population group

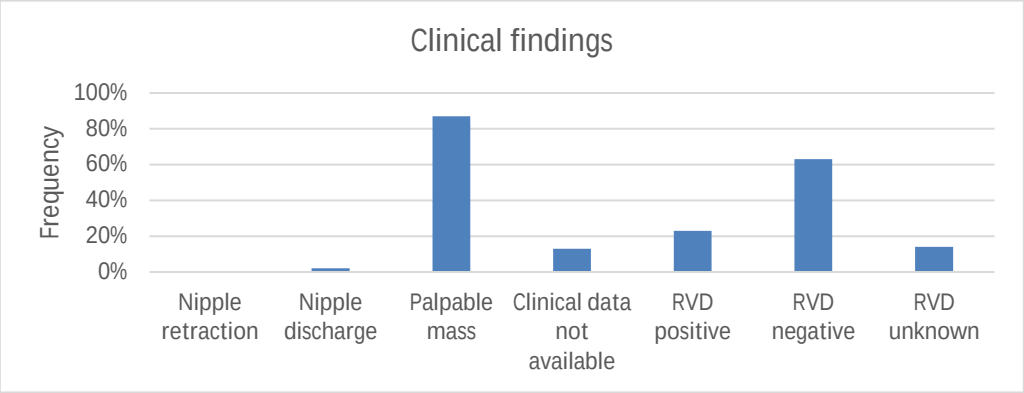

Figure D.4. Background density as seen on mammogram

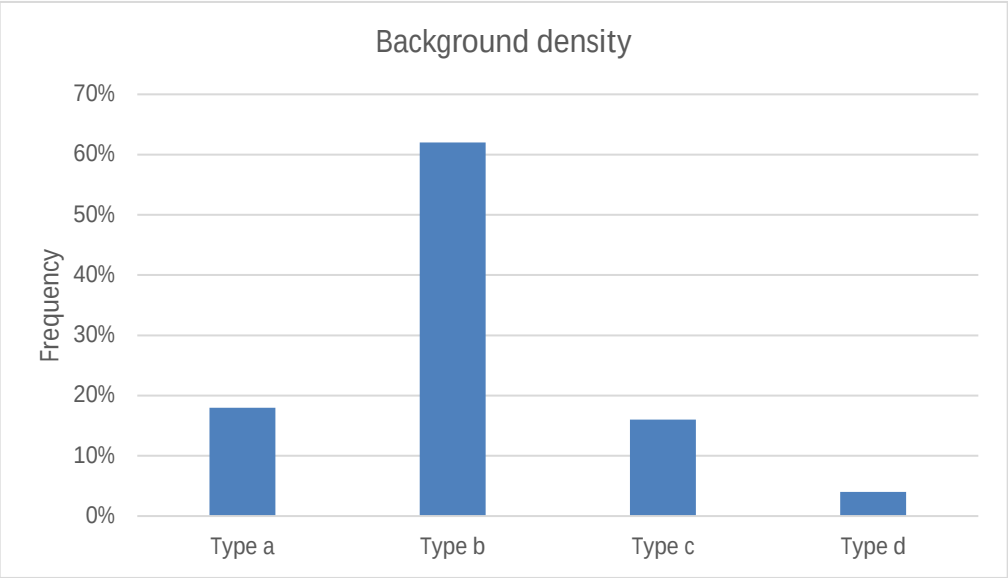

Figure D.5. Site of lesions as demonstrated on mammogram

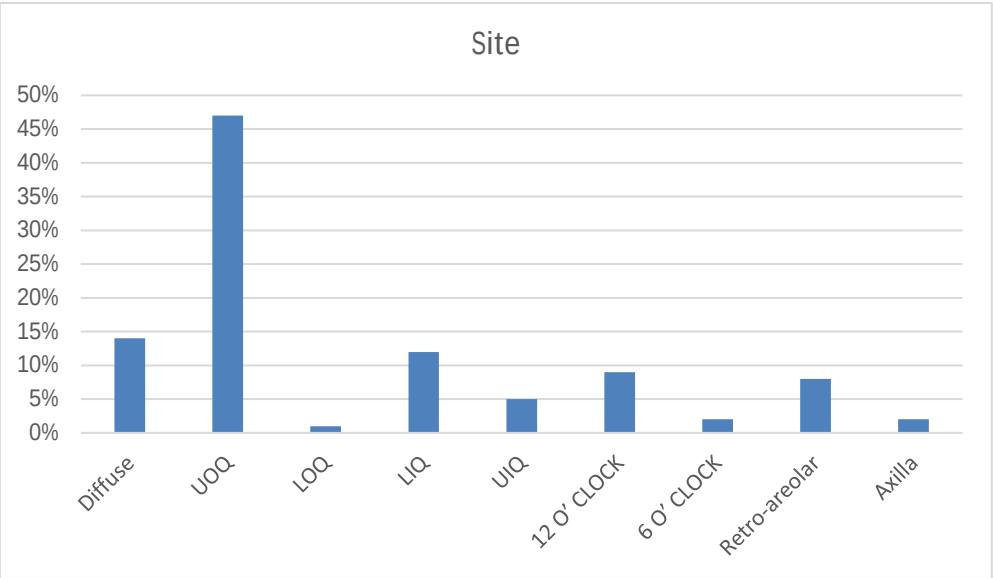

Figure D.6. Mass shape and average age of patients with this finding

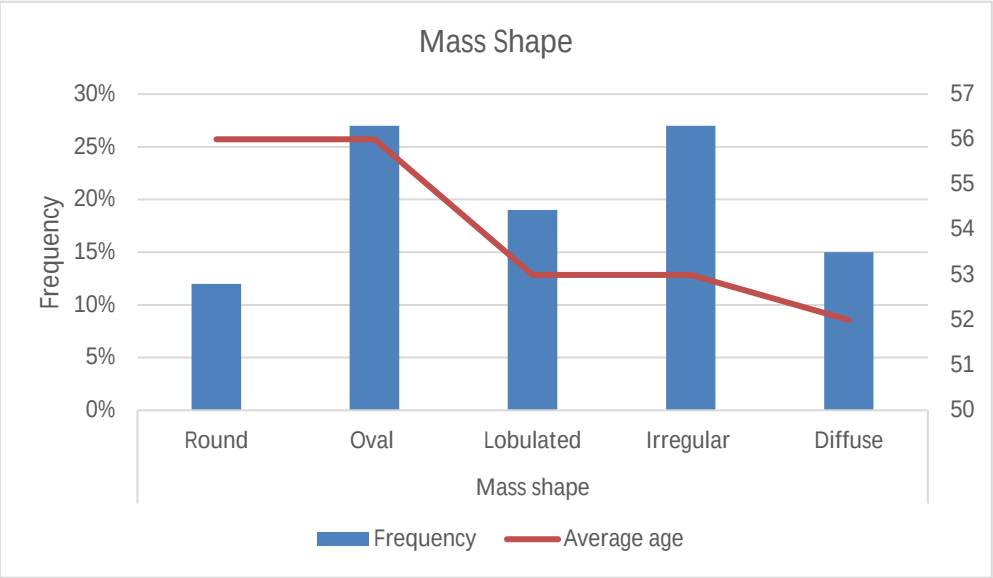

Figure D.7. Mass margins and average age of patients with this finding

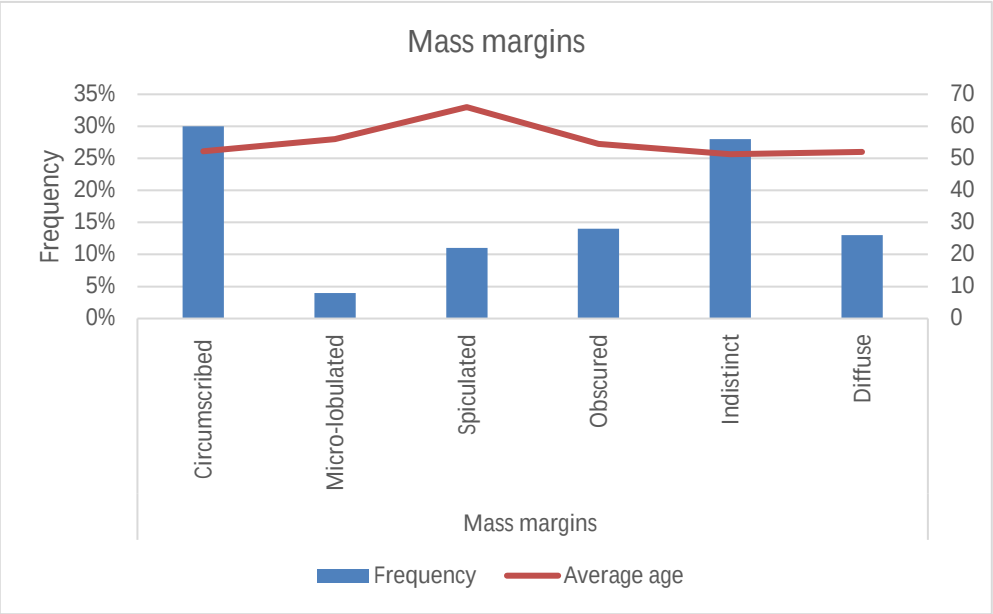

Figure D.8. Asymmetry as seen on mammogram

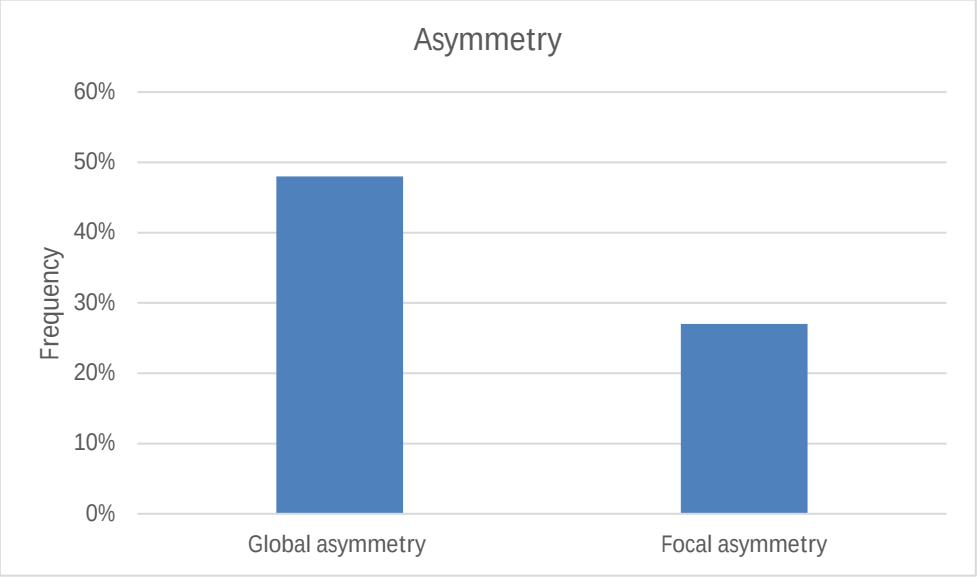

Figure D.9. Additional features seen on mammogram

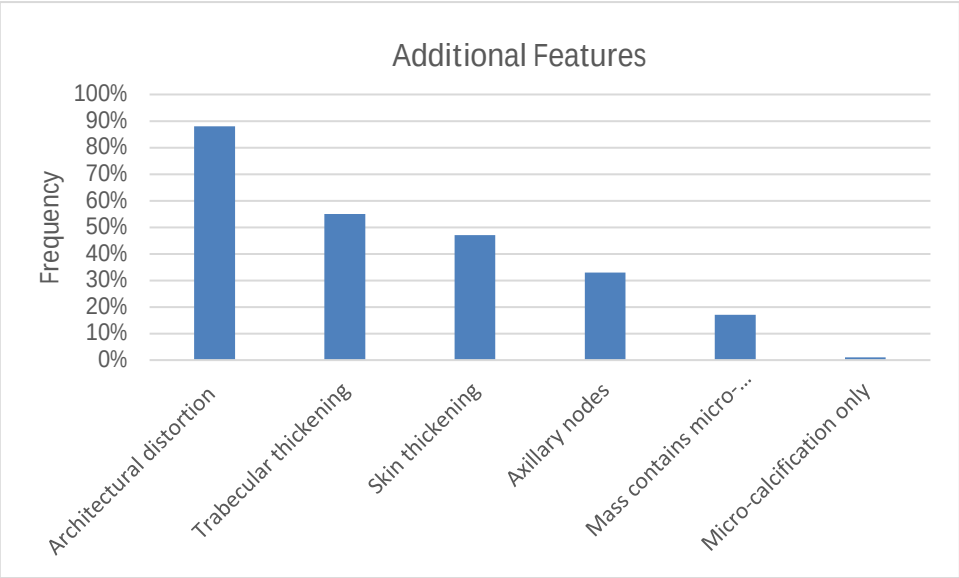

Figure D.10. Shape of the lesions on ultrasound

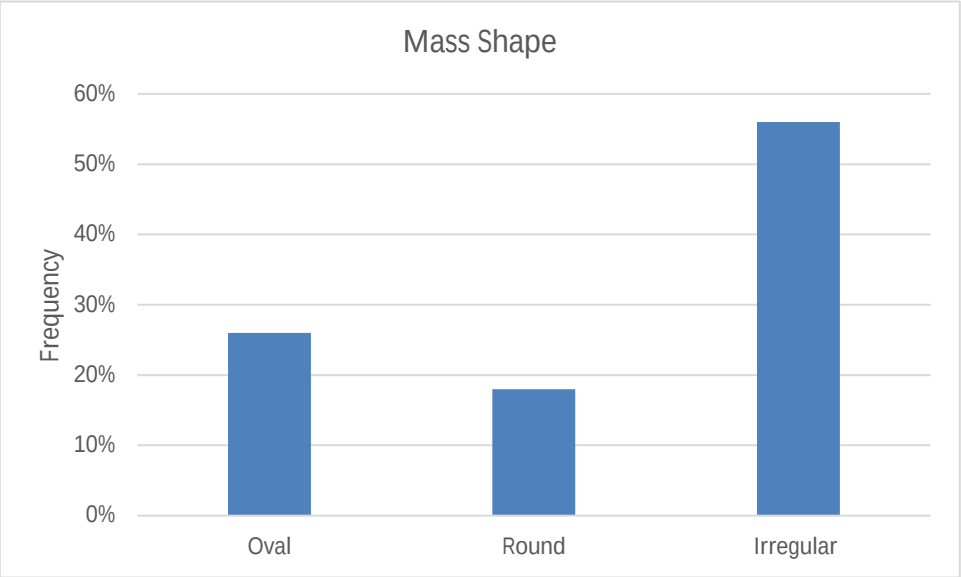

Figure D.11. Lesion borders on ultrasound

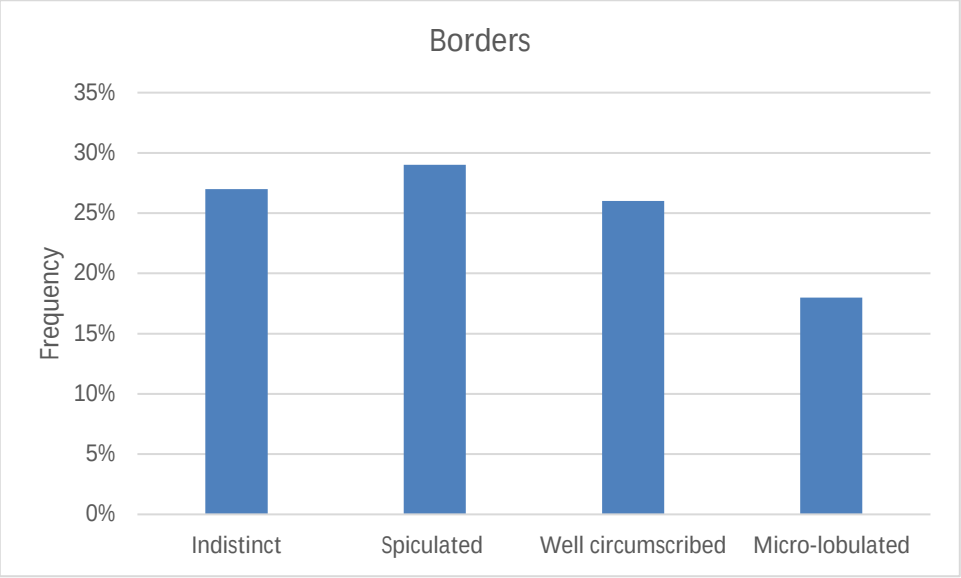

Figure D.12. Internal echogenicity of the mass on ultrasound

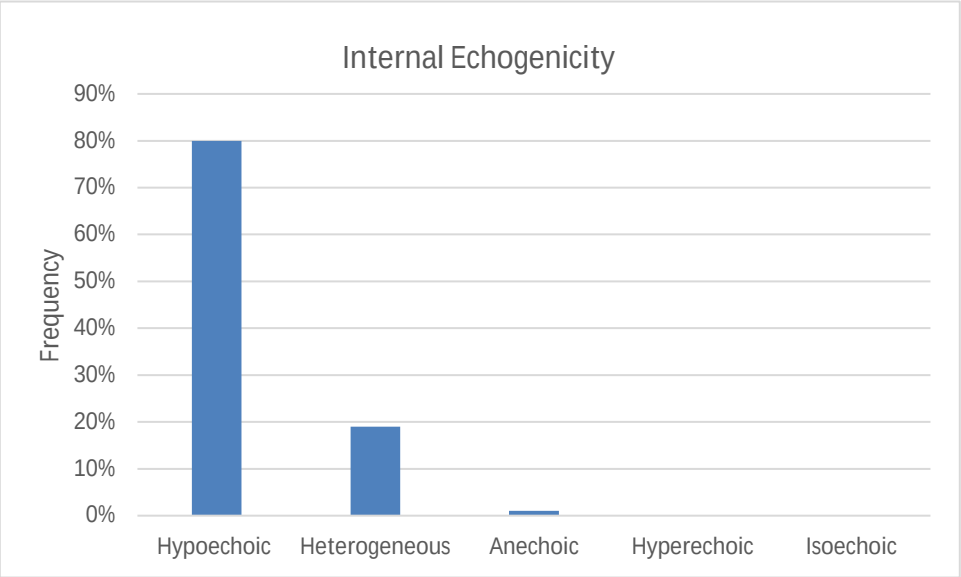

Figure D.13. Additional findings seen on ultrasound

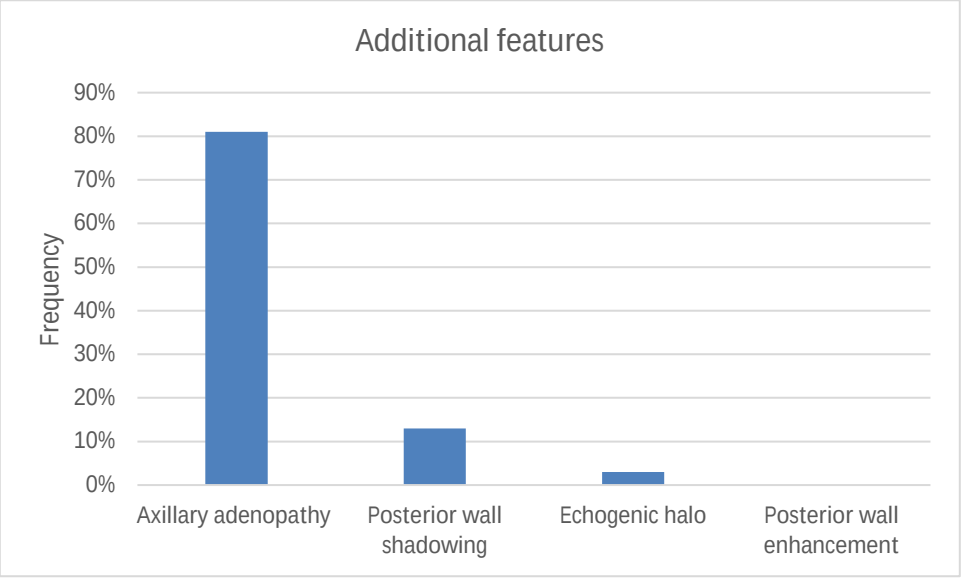

Figure D.14. Final BI-RADS classification

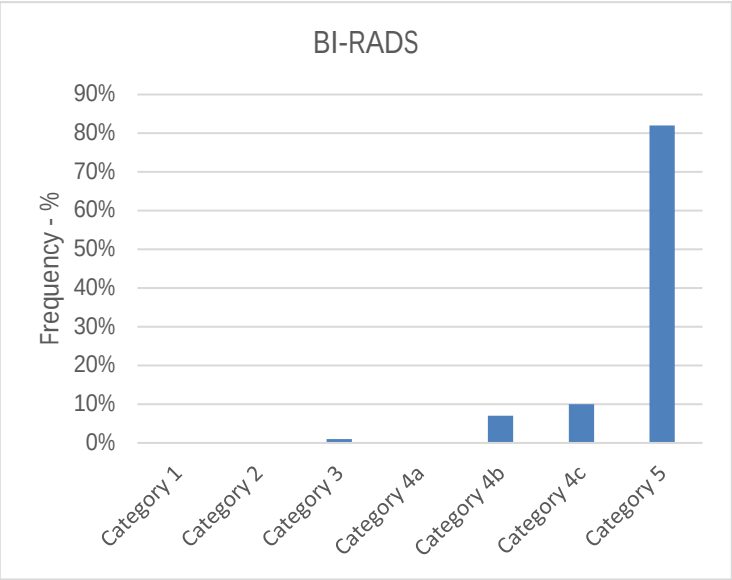

Figure D.15. Common histology type encountered

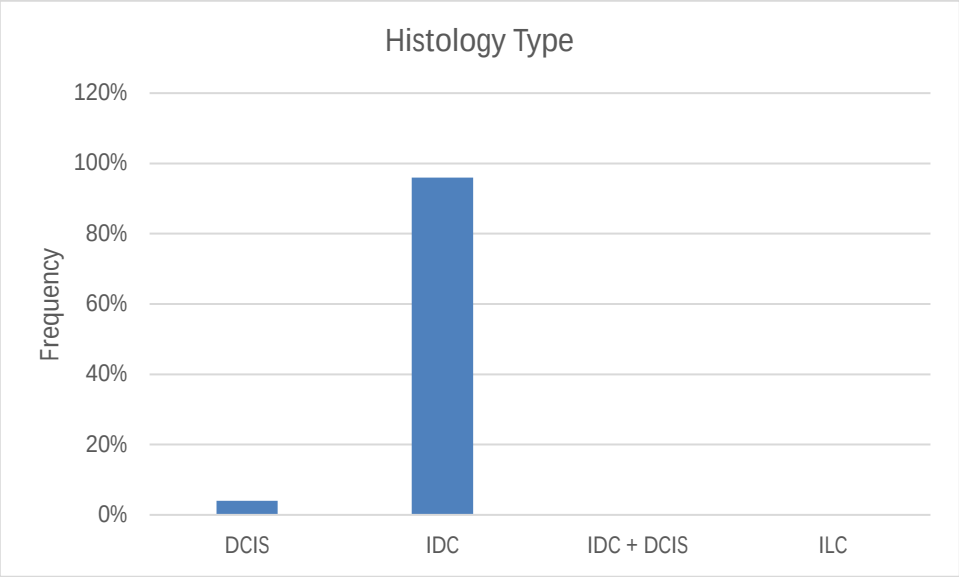
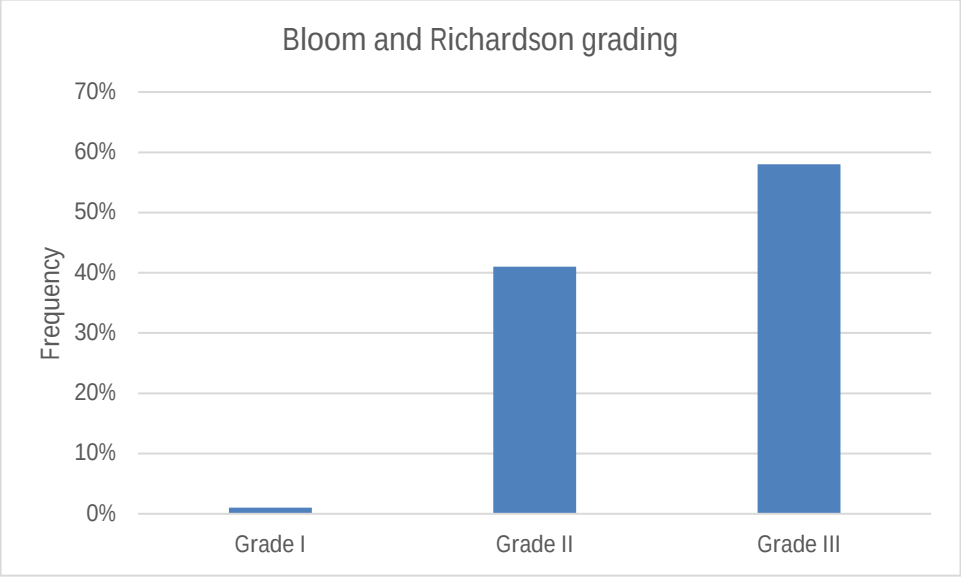
Figure D.16. Tumour grading according to the Bloom and Richardson grading system