DSPACE

https://dspace.org/

Epidemiology and susceptibility of Nakaseomyces formerly Candida glabrata bloodstream isolates from hospitalised adults in South Africa

S Naicker; L Shuping; T Zulu; R Mpembe; E et al ...

INFORMA HEALTHCARE
https://hdl.handle.net/10539/39303
WOS

Downloaded from a DSpace repository. https://dspace.org/

Clinical Radiology 78 (2023) 576–583

Contents lists available at ScienceDirect

Clinical Radiology

journal homepage: www.clinicalradiologyonline.net

Comparison of single coronal thick-slab minimum intensity projection with flexible bronchoscopy for airway compression in children with lymphobronchial tuberculosis

S.S.B. Venkatakrishna [a,*], A.O.A. Krim [b], J. Calle-Toro [c], S. Lucas [d], D. Bester [d], P. Goussard [e], S. Andronikou [a,f]

[a] *Department of Radiology, Children's Hospital of Philadelphia, Philadelphia, PA, USA*
[b] *Waikato District Health Board, Waikato Hospital, 183 Pembroke Street, Hamilton 3204, New Zealand*
[c] *Department of Radiology, University of Texas Health Science Center at San Antonio - UT Health San Antonio, 7703 Floyd Curl Dr, San Antonio, TX 78229, USA*
[d] *Department of Diagnostic Radiology, School of Clinical Medicine, Faculty of Health Sciences, University of the Witwatersrand, Johannesburg, South Africa*
[e] *Department of Pediatrics and Child Health, Faculty of Medicine and Health Sciences, Tygerberg Hospital, Stellenbosch University, Cape Town, South Africa*
[f] *Department of Radiology, Perelman School of Medicine, University of Pennsylvania, Philadelphia, PA, USA*

ARTICLE INFORMATION

Article history:
Received 15 August 2022
Received in revised form
1 March 2023
Accepted 27 March 2023

AIM: To generate standardised coronal minimum intensity projection (MinIP) computed tomography (CT) reconstructions, and compare these with flexible bronchoscopy in children with lymphobronchial tuberculosis (LBTB).

MATERIALS AND METHODS: Standardised coronal MinIP reconstructions were performed from CT images in children with LBTB and the findings of three readers were compared with the reference standard, flexible bronchoscopy (FB), regarding airway narrowing. Intraluminal lesions, the site of the stenosis, and the degree of stenosis were also evaluated. The length of stenosis was evaluated by CT MinIP only.

RESULTS: Sixty-five children (38 males; 58.5% and 27 females; 41.5%), with ages ranging from 2.5 to 144 months were evaluated. Coronal CT MinIP demonstrated a sensitivity of 96% and specificity of 89% against FB. The most common site of stenosis was the bronchus intermedius (91%), followed by the left main bronchus (85%), the right upper lobe bronchus RUL (66%), and the trachea (60%).

CONCLUSION: Coronal CT MinIP reconstruction is useful in demonstrating airway stenosis in children with lymphobronchial TB, with high sensitivity and specificity. CT MinIP had additional advantages over FB in that it allowed objective measurement of the diameter of stenosis,

* Guarantor and correspondent: S.S.B. Venkatakrishna, Department of Radiology, Children's Hospital of Philadelphia, 3401 Civic Center Blvd, Philadelphia, PA 19104, USA.
E-mail address: venkatakrs@chop.edu (S.S.B. Venkatakrishna).

https://doi.org/10.1016/j.crad.2023.03.021
0009-9260/© 2023 Published by Elsevier Ltd on behalf of The Royal College of Radiologists.

measurement of the length of stenosis, and evaluation of post-stenotic segments of the airways and lung parenchymal abnormalities.

© 2023 Published by Elsevier Ltd on behalf of The Royal College of Radiologists.

Introduction

Lymphobronchial tuberculosis (LBTB) is diagnosed when tuberculous lymphadenopathy affects the airways either by compression, erosion, or inflammation.[1–3] The current World Health Organization (WHO) guideline classifies children as having severe TB disease when there is airway compression, which precludes them from the new short-course treatment options.[4] Children have "soft" airways, which are easily compressible, making them susceptible to compression by lymphadenopathy. The diagnosis of LBTB and its management hinges on identifying the airway compression and the implicated compressing tuberculous lymph nodes.

Chest radiography and computed tomography (CT) can both be used to detect airway narrowing, but direct visualisation through flexible bronchoscopy (FB) is considered the reference standard.[5] In LBTB, FB is used to identify the site and degree of airway narrowing/obstruction and can also confirm the TB diagnosis by bronchial lavage or transbronchial biopsy of lymph nodes.[6,7] It has the advantage that it can also be used to treat the condition in that transbronchial enucleation and aspiration of endobronchial material can be achieved at the time of the bronchoscopy[2]; however, paediatric FB is invasive, requires additional training and experience, carries significant costs, and usually requires general anaesthesia. This mandates pre-procedural preparation and post-procedural monitoring because of the many well-described associated complications including major complications, such as apnoea, bradycardia, respiratory depression, and oxygen desaturation (more frequent in young children).[8,9] In addition, FB has difficulty in assessing the distal airways and measuring the length of stenosis when a severe stenosis more proximally prevents passage of the bronchoscope. It has a further limitation in that it is unable to determine the cause of any external compression and any transbronchial biopsy is usually planned in advance using cross-sectional imaging.[5]

Multidetector CT (MDCT) of the chest can play a significant role in children with airway obstruction.[3] MDCT can be performed prior to FB where it can demonstrate the areas of airway compression as well as the presence of lymphadenopathy causing compression, lung parenchymal changes occurring distal to the airway compression and any tuberculous pleural disease. A variety of algorithms and reconstruction techniques can enhance these evaluations.[1,10] Minimum intensity projection (MinIP) is one such post-processing method and is an illustration data method that uses detection of low-density structures (lowest radiodensity value),[11,12] projecting these in a two-dimensional (2D) reconstruction of a desired slab of tissue. It is a simple reconstruction technique[13] that is reported useful for the detection of concentric bronchial stenosis or post-operative extra-bronchial air collection.[12] MinIP is useful in that it allows the measurement of the length of stenosis that is too tight for a bronchoscopy to pass through[13] and can demonstrate the airways distal to tight stenosis. A coronal MinIP view provides images that are easily correlated with frontal chest radiographs, and can demonstrate a large portion of the central bronchial tree in continuity, for better communication of the disease location and severity to clinicians and parents alike.[13] A standardised MinIP reconstruction of the airways can be provided routinely alongside the source imaging and can serve as a roadmap or communication tool that does not require further user manipulation. The accuracy of MinIP CT reconstructions in determining presence, site and degree of stenosis has not been evaluated scientifically in paediatric LBTB. LBTB presents a unique scenario of multifocal extra-luminal airway compressions in children, where an accurate roadmap of the airways is required for decision-making, communication between colleagues and with parents, and can be used in bronchoscopy theatres during bronchoscopic therapeutic procedures.

The aim of the present study was to generate and compare standardised coronal CT MinIP reconstructions of the paediatric central airways with FB, in children with LBTB.

Materials and methods

This study was a retrospective, descriptive, cross-sectional study, using an existing CT database of children with LBTB, imaged over a 10-year period. The most recent sequential 100 children who had undergone helical CT on a 16-section MDCT system were reviewed and included if they had undergone FB with available results, were <13 years of age, and had a final diagnosis of LBTB. Patients were excluded when CT files contained corrupt data, when there were significant motion artefacts in the source CT data, bronchoscopic data were incomplete, and when they were significantly malpositioned and reconstruction was not possible.

The original volumetric high-resolution helical MDCT data acquisition was used to create the coronal MinIP reconstruction using an OsiriX DICOM Viewer, 32-bit (version 5.6) software. The reconstruction was performed as standardised technique on all patients by opening the source CT images in the multiplanar reconstruction (MPR) application of the OsiriX program. The cross-hair was positioned along the length of the trachea in the coronal and sagittal views and along the horizontal axis of the main

bronchi at the carina on the axial view, as shown in (Fig 1). A slab thickness for MinIP reconstruction ranging between 5 and 20 mm (depending on the patient size) was selected to include the full anteroposterior thickness of tracheobronchial tree on the single coronal oblique slab. Image viewing was selected as "lung window". The single coronal image was saved as a DICOM-format file in the OsiriX program, and labelled appropriately. For the purposes of the study, the single standard anonymised image from OsiriX platform was exported for readers to interpret on individual computers without any accompanying source images. Three different radiologist readers read the MinIP reconstructions, blinded to each other and to the bronchoscopy findings. They evaluated the presence and degree of obstruction at 10 predetermined sites along the tracheobronchial tree (Fig 2): trachea, carina, right main bronchus (RMB), bronchus intermedius (BI), right upper lobe bronchus (RUL), right middle lobe bronchus (RML), right lower lobe bronchus (RLL), left main bronchus (LMB), left upper lobe bronchus (LUL), and left lower lobe bronchus (LLL).

Interpretation and reading of the coronal MinIP slabs was performed by the primary investigator (a senior registrar in radiology the time, "A.O.A.K"), one other senior registrar in radiology, and the supervisor (consultant paediatric radiologist with over 15-years of experience interpreting paediatric TB radiographs and CT). Readers were blinded to each other and to the bronchoscopy findings, and a final decision on the presence and category of degree of airway stenosis, was made by determining agreement of at least two of the three readers.

Airway measurements were taken from the most severely narrowed region of each involved airway segment and were expressed as a percentage, based on a ratio derived in relation to "normal airway" immediately proximal to the obstruction. The final stenosed airway measurement was calculated as the average of the readers' measurements.

A standardised report form was used to report bronchoscopy findings in children with TB. This was previously published by Goussard *et al.*[7] The specific airways or combination of airways involved, as well as the severity of the involvement is reported. This included both external compression as well as where the lymph nodes herniated into the airways. Both the large airways (trachea, LMB, RMB, BI) and the different lobes were evaluated and recorded.

The grading below for the MinIP interpretation was used, based on that used during bronchoscopy, to facilitate comparison between the two investigations: Grade 0, no obstruction 0%; Grade 1, mild obstruction 1–50%; Grade 2, moderate obstruction 51–75%; Grade 3(a), severe obstruction 76–99%; Grade 3(b), complete obstruction 100%. The length of stenosis measured using the coronal CT MinIP was also recorded and averaged in the same way.

Ethics clearance for this work was obtained from the local university research ethics committee, but there was no informed consent required as the work was performed

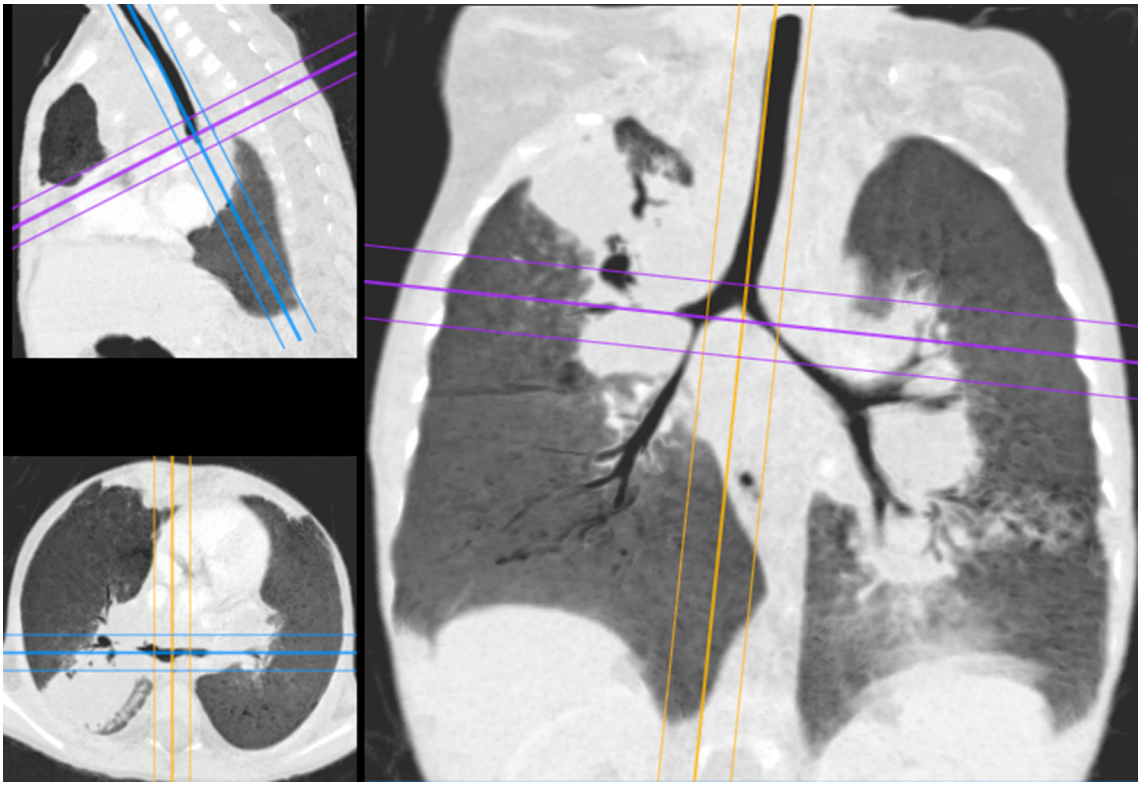

Figure 1 The planning MPR image demonstrates the axes that have been corrected on the sagittal and axial planes along the trachea and bronchial origins to produce a single coronal image of the whole proximal (central) airway. The outer lines of the cross hairs indicate the outer limits of the slab of tissue, representing the selected thickness for including the whole airway.

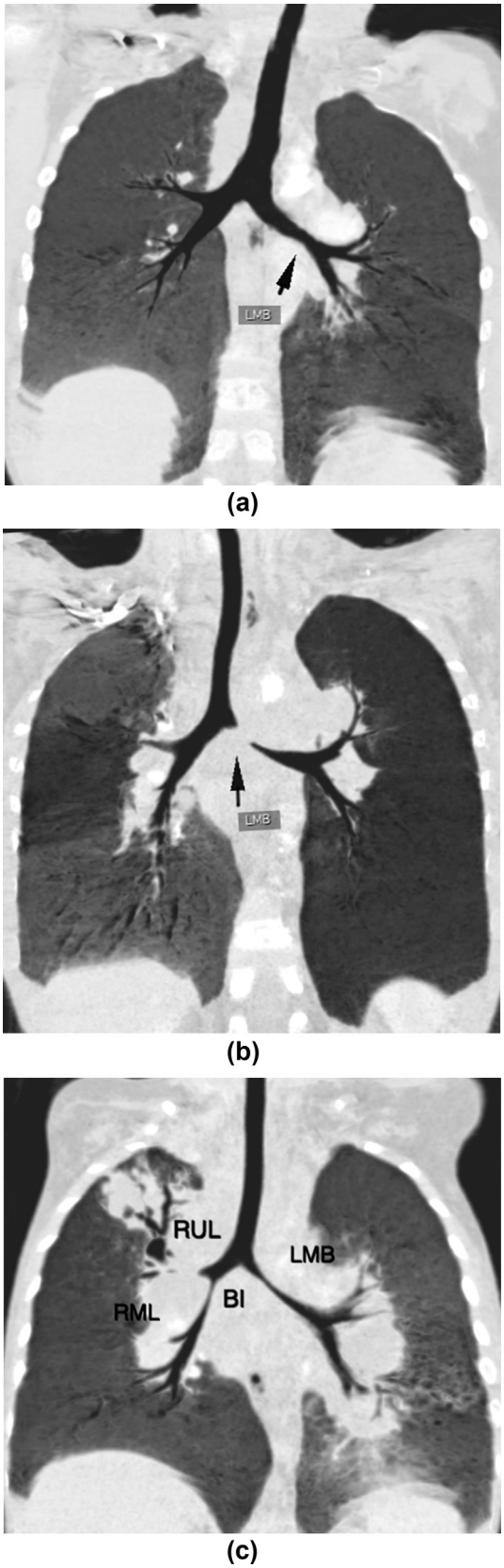

Figure 2 Three examples of varying numbers of airway stenoses on coronal CT MinIP reconstructions. (a) A 10.5-year-old male patient with LBTB demonstrates a single Grade 1 stenosis of the LMB on CT MinIP. (b) A 9-year-old male patient with LBTB demonstrates complete obstruction of the LMB with air-trapping of the left lung on CT MinIP. (c) A 2-year-old male patient with LBTB demonstrates multiple sites of stenosis on CT MinIP.

retrospectively on existing CT images performed for clinical reasons, in an anonymised fashion.

The findings of the coronal CT MinIP were compared to the FB findings. Sensitivity and specificity were calculated with the FB as the reference standard. Comparative statistics of agreement were calculated, both concerning the presence of stenosis at each site, and concerning the degree of stenosis. The chi-square test was used in the evaluation by using the STATA data analysis software application.

Results

A total of 65 children with LBTB made up the final study population (after inclusion and exclusion criteria were applied). This comprised 38 male (58.5%) and 27 female (41.5%) patients, with ages ranging from 2.5 to 144 months, (mean age 23.85 months; median age 14 months). Of these, 55 patients (84.6%) were <40 months of age, and only five patients (7.7%) were above 80 months.

The slab thickness of the coronal MinIP selected for visualising all 10 relevant airway sites on a single coronal image, ranged from 5.95 to 20 mm (mean 12.82 mm; standard deviation 3.34 mm). Only three MinIP images had a thickness <10 mm (4.6%), while 44 images (67.7%) ranged from 10 to 15 mm, and 18 images (27.7%) had a thickness >15 mm.

Airway stenosis was detected in all 65 patients (as expected from the clinical inclusion criteria) with a variable number of sites and varying degrees of stenosis along the bronchial tree. Only one patient had a single site affected (LMB), and only one patient had two sites affected (trachea and BI). Most of the patients had multiple sites of stenosis, including two patients with stenosis at all 10 sites evaluated.

With CT MinIP, there were 352 sites of airway stenosis out of a total of 650 (54%) possible sites (10 possible sites × 65 children). The commonest site of airway stenosis on the coronal MinIP CT reconstruction was the BI, followed by LMB, RUL, and the trachea. The total number of airways with stenosis determined by FB was 266 (41%) with the commonest airway affected being the carina. The comparison of the diagnostic methods according to the site and sensitivity/specificity of MinIP (using the FB as the reference standard), are summarised in Tables 1 and 2, respectively.

There were 23 intraluminal lesions found using the coronal CT MinIP, and only 17 intraluminal lesions were detected using FB; the commonest sites by CT MinIP were the BI (eight patients), LMB, and LUL (four patients each site). The ability of CT MinIP to demonstrate the length of stenosis is demonstrated in Fig 3, which presents three examples of different patients with measurement of the length of stenosis. There was no comparison to FB because measuring the length of the stenosis is not readily achieved using with FB and these results were not provided in the reports.

Table 1
Comparison of coronal minimum intensity projection (MinIP) reconstructions to flexible bronchoscopy (FB) by the number of airway stenoses per site.

Method	Trachea	Carina	RMB	RUL	BI	RML	RLL	LMB	LUL	LLL	Total stenosis
MinIP (n=65)	39 (60%)	26 (40%)	26 (40%)	43 (66%)	59 (91%)	23 (35%)	11 (17%)	55 (85%)	32 (49%)	38 (58.5%)	352 (54%)
FB (n=65)	42 (65%)	57 (88%)	9 (14%)	24 (37%)	49 (75%)	19 (29%)	7 (11%)	46 (71%)	7 (11%)	6 (9%)	266 (41%)

Right main bronchus (RMB), bronchus intermedius (BI), right upper lobe bronchus (RUL), right middle lobe bronchus (RML), right lower lobe bronchus (RLL), left main bronchus (LMB), left upper lobe bronchus (LUL), left lower lobe bronchus (LLL).

There were more stenoses detected using coronal MinIP in small airways bilaterally compared to FB, 10–29% on right side, and 38–50% on left side. MinIP also detected more cases of stenosis in second-order airways, and FB detected more stenoses in proximal airways such as at the carina (Tables 1 and 2).

The severity of the stenosis was classified into four grades from Grade 1 to Grade 3b representing an increasing severity/degree of stenosis of the affected airways. Comparison of CT MinIP and FB regarding severity is summarised in Fig 4. The commonest grade of the airway stenosis detected by the coronal CT Min IP reconstruction was Grade 2 (17.4%) followed by Grade 1 (16.6%), while the commonest grade found on FB was Grade 1 (27.55%) followed by Grade 2 (5.45%).

Discussion

In the present study, standardised coronal CT MinIP slab images enabled measurement of the length and the diameter of the airways at any detected airway stenosis, and additionally, distal to the stenotic sites, highlighting the important advantages of CT MinIP when compared to FB. The coronal CT MinIP also provided information about distal lung complications and the cause of the stenosis in cases where there was an intraluminal lesion. Despite aiming to prove the accuracy of the CT MinIP by comparing it to the current reference standard, this technique is not intended to replace evaluation of source imaging or be used independently of the source axial CT, which is already validated in practice. Instead, the present study aims to prove that coronal CT MinIP can provide an accurate single-image overview representation of the central airways including any stenosis of these. This will hopefully simplify communication; provide a single image for planning intervention and for reference in the bronchoscopy theatre.

Table 2
Sensitivity and specificity of coronal minimum intensity projection (MinIP) reconstruction and comparison of computed tomography (CT) MinIP against flexible bronchoscopy (FB) by site.

Site	Sensitivity	Specificity	p-Value
Trachea	64%	43%	0.5996
Carina	37%	38%	0.2497
Right main bronchus	78%	66%	0.0239
Right upper lobe bronchus	83%	44%	0.0314
Bronchus intermedius	96%	25%	0.0286
Right middle lobe bronchus	32%	63%	0.780
Right lower lobe bronchus	57%	89%	0.0127
Left main bronchus	89%	26%	0.1413
Left upper lobe bronchus	71%	53%	0.2576
Left lower lobe bronchus	67%	42%	1

The present results in evaluating CT MinIP for 65 children with LBTB showed that 54% of evaluated airways demonstrated stenosis on CT MinIP compared to only 41% demonstrated by FB. CT MinIP demonstrated a sensitivity of up to 96% and specificity up to 89% in detecting airway stenosis when the FB was considered the reference standard. There was good agreement between the techniques at the RLL, BI, LMB, and RMB. The CT MinIP was as good as FB in detecting small airway stenosis, demonstrating additional distal areas of airway narrowing.

FB showed superiority in detecting stenosis in the trachea and especially at the carina (88%), compared to the coronal CT MinIP. This is presumably due to the anteroposterior direction of compression of the carina likely making compression more appropriate on axial MDCT or sagittal MPR.[14,15] Therefore, use of axial-source CT is recommended for evaluating and communicating carinal compression.

The performance of the coronal MinIP reconstructions in detecting airway compression compared well with previous studies reporting airway stenosis in children with LBTB on axial CT images, three-dimensional (3D) volume rendering and chest radiography.[3,5,16,17] The most common sites of airway stenosis observed using coronal CT MinIP in the present study were the BI (91%), followed by the LMB (85%). In two studies by Maydell *et al.*, 2010 and Lucas *et al.*, 2012, using CT and chest radiography, the BI was also the most commonly involved, followed by the LMB and the trachea.[3,5,16,17] Du Plessis *et al.* found the LMB was the most common site stenosed by LBTB (92%) followed by the BI 80% and trachea 73%.

The CT MinIP reconstruction may overestimate the degree of the stenosis compared to FB.[15,18] For example, in the present study, Grade 2 was the most common category of airway stenosis severity detected by the coronal CT MinIP (17.5%), followed by Grade 1 (16.6%); while Grade 1 (27.55%) was the most common category of airway stenosis severity on FB, followed by Grade 2 (5.38%). Du Plessis *et al.* also reported the Grade 1 (0–50%) as the most common degree of stenosis using 3D volume rendering[5]; however, it should be noted that measurement of severity on CT MinIP in the present study used objective measures that represent an improvement on the purely subjective assessment using FB (a technique that is not readily evaluated for reliability). The thickness of the slab in the single CT MinIP plays an important role in detecting and grading the stenosis.[15] The slab thickness in this study ranged from 10 to 20 mm for 95% of studies for covering the full anteroposterior

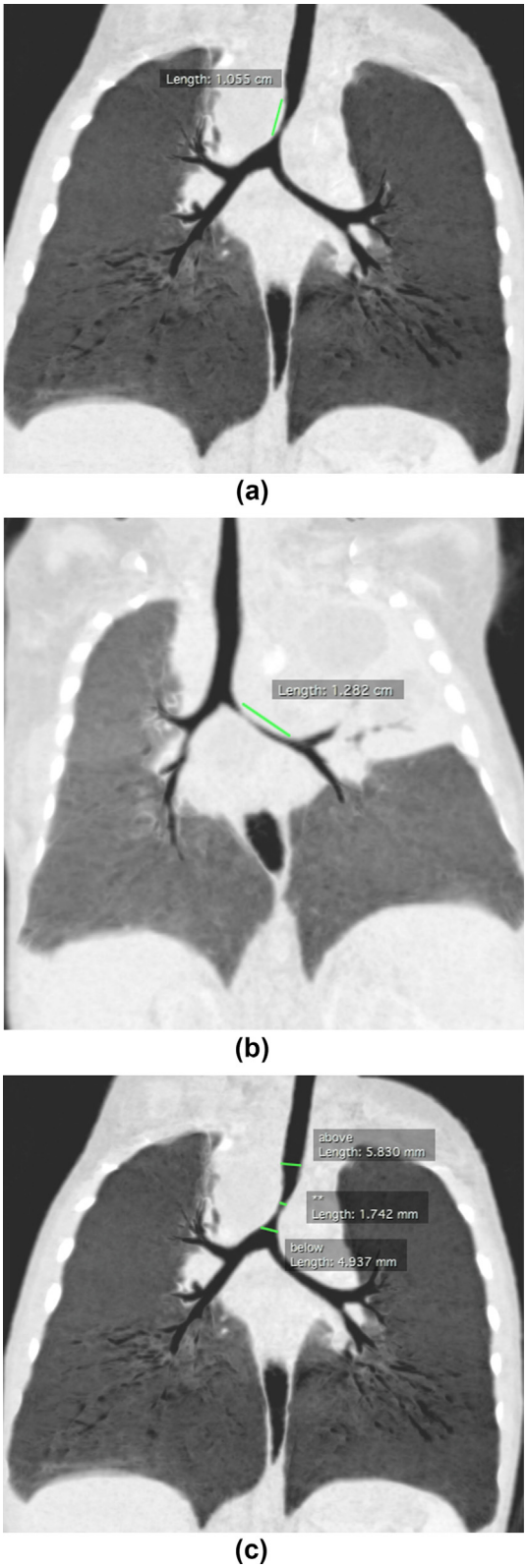

Figure 3 Three examples of airway stenosis demonstrating length and thickness measurements on CT Min IP. (a) A 19-month-old female patient with LBTB demonstrating the measurement of the length of the tracheal narrowing. (b) A 19.5-month-old male patient with LBTB demonstrating measuring the length of the LMB narrowing. (c) An 18-month-old female patient with LBTB demonstrating measuring the diameter of the trachea at the level of the stenosis (**), as well as above and below the stenosis.

thickness of the central airways and a slab thickness <10 mm was only used in 5% of scans in smaller patients.

FB has an important function in addition to diagnosis, in that it can be used for treatment in LBTB, especially for clearing endobronchial material[7,19]; however, FB remains an invasive procedure that requires general anaesthesia,[7] it carries significant costs, it has well-described associated complications,[8] and it can cause massive post-biopsy haemoptysis.[20] CT should precede any FB procedure to make a final decision on performing the FB and for planning the procedure. There are multiple advantages of coronal CT MinIP, which were highlighted in this study. It is a post-processing tool from non-invasive CT source data, which demonstrates the presence and grade of airway stenosis in a single slab image, providing an overview picture of the major airways and proximal bronchial tree. It does this with acceptable detail for measuring the diameter and craniocaudal length of airway stenosis.[21,22] It can evaluate the small airways distal to the region of severe or complete stenosis and provides information on endobronchial lesions. In addition, it provides additional information on any lung parenchymal complications[22] that accompany LBTBT.[2,3,22,23] Examples of these lung changes in the form of consolidation, air-trapping, and cavitation are shown in Fig 5 and Electronic Supplementary Material Fig. S1. Coronal CT MinIP has some limitations for detecting airway compression or stenosis involving the carina, and therefore, it is recommended that it should always be used in combination with source CT images.[21,22]

In the present study, a standardised protocol using a slab thickness between 10 and 20 mm was developed for producing a coronal CT MinIP reconstruction image for airway evaluation in children. In addition to its use for LBTB, this protocol may add value during the communication of the diagnosis of other paediatric airway pathologies such as congenital abnormalities, foreign body inhalation, and vascular compressions. The standardised image is also useful for demonstration and communication of anatomy and the pathology to the bronchoscopist and any surgeons involved in the management.

In conclusion, this study has proven that a standardised coronal CT MinIP reconstruction is accurate in demonstrating the site of airway stenosis in children with lymphobronchial TB, with sensitivity of up to 96% and specificity up to 89%. Compared to FB, coronal CT MinIP detection rate for total and distal airway stenosis was greater than FB at the RMB, RUL bronchus, BI and RLL bronchus.

Coronal CT MinIP has additional advantages over FB in that it allows objective measurement of the diameter of the stenosis, measurement of the length of the stenosis as well as visualisation of the post-stenotic segments of the airways. CT MinIP was also able to provide information about lung parenchymal abnormalities.

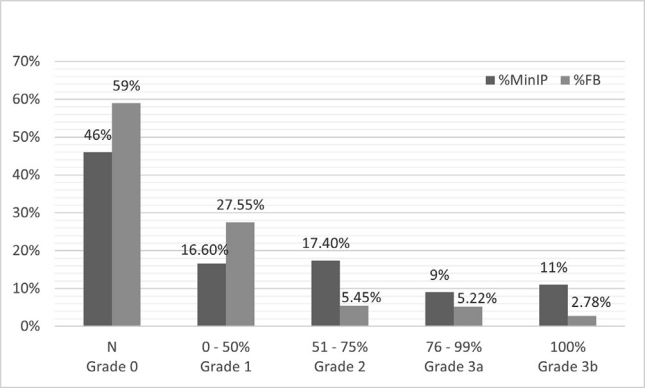

Figure 4 Bar graph comparing the degree of the airway stenosis on CT MinIP with FB.

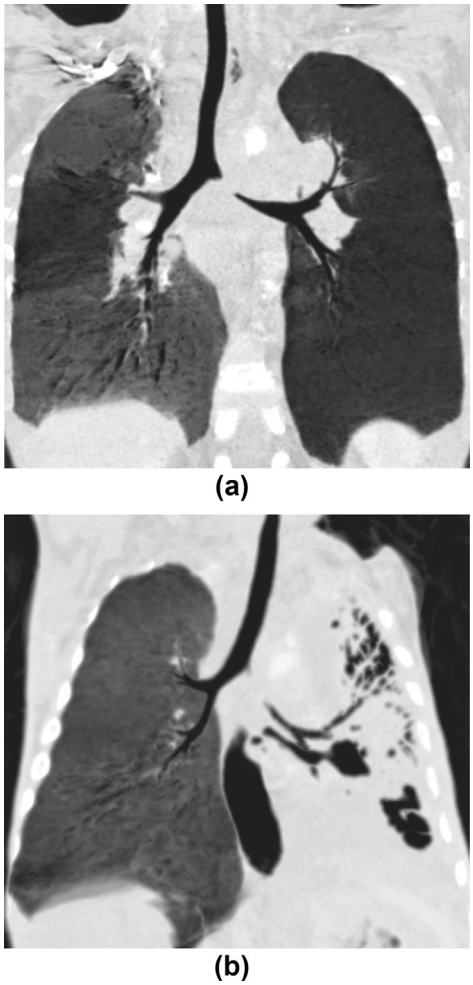

Figure 5 Parenchymal changes distal to bronchial narrowing in two different children with LBTB. (a) A 9-year-old male patient with left lung air-trapping due to obstruction of the LMB as well as RUL segmental air-trapping associated with an endo-bronchial lesion in the RUL bronchus. (b) A 11-month-old female patient with left lung consolidation with volume loss and cavitary lesions predominating in the lower lobe resulting from LMB obstruction.

Standardised coronal MinIP reconstructions are easily performed and can be provided additionally by the CT technologists with each set of cross-sectional MDCT images in children with LBTB. The proposed single coronal MinIP slab image can provide easily appreciable and accurate airway information and additional information not available from FB and for communication with colleagues and parents, planning interventions and for reference in the bronchoscopy theatre.

Conflict of interest

The authors declare no conflict of interest.

Appendix A. Supplementary data

Supplementary data to this article can be found online at https://doi.org/10.1016/j.crad.2023.03.021.

References

1. Perez-Velez CM, Marais BJ. Tuberculosis in children. *N Engl J Med* 2012;**367**:348–61. https://doi.org/10.1056/NEJMRA1008049.
2. Goussard P, Gie R. Airway involvement in pulmonary tuberculosis. *Paediatr Respir Rev* 2007;**8**:118–23. https://doi.org/10.1016/j.prrv.2007.04.007.
3. Lucas S, Andronikou S, Goussard P, *et al*. CT features of lymphobronchial tuberculosis in children, including complications and associated abnormalities. *Pediatr Radiol* 2012;**42**:923–31. https://doi.org/10.1007/s00247-012-2399-x.
4. WHO. WHO consolidated guidelines on tuberculosis. Module 4: treatment. Drug-resistant tuberculosis treatment. https://apps.who.int/iris/rest/bitstreams/1280998/retrieve (accessed 18 May 2022).
5. Du Plessis J, Goussard P, Andronikou S, *et al*. Comparing three-dimensional volume-rendered CT images with fibreoptic tracheobronchoscopy in the evaluation of airway compression caused by tuberculous lymphadenopathy in children. *Pediatr Radiol* 2009;**39**:694–702. https://doi.org/10.1007/s00247-009-1262-1.
6. Campanella SG, Innes Asher M. Pediatric bronchoscopy. *Pediatr Pulmonol* 2001;**31**:150–64. https://doi.org/10.1002/1099-0496(200102)31:2<150::AID-PPUL1024>3.0.CO;2-164.
7. Goussard P, Gie RP, Kling S, *et al*. Bronchoscopic assessment of airway involvement in children presenting with clinically significant airway obstruction due to tuberculosis. *Pediatr Pulmonol* 2013;**48**:1000–7. https://doi.org/10.1002/ppul.22747.
8. Midulla F, de Blic J, Barbato A, *et al*. Flexible endoscopy of paediatric airways. *Eur Respir J* 2003;**22**:698–708. https://doi.org/10.1183/09031936.02.00113202.
9. Arlaud K, Gorincour G, Bouvenot J, *et al*. Could CT scan avoid unnecessary flexible bronchoscopy in children with active pulmonary tuberculosis? A retrospective study. *Arch Dis Child* 2010;**95**:125–9. https://doi.org/10.1136/adc.2009.151639.
10. Garrido JB, Alías Hernández I, Bonillo Perales A, *et al*. Usefulness of thoracic CT to diagnose tuberculosis disease in patients younger than 4 years of age. *Pediatr Pulmonol* 2012;**47**:895–902. https://doi.org/10.1002/ppul.22562.
11. Perandini S, Faccioli N, Zaccarella A, *et al*. The diagnostic contribution of CT volumetric rendering techniques in routine practice. *Indian J Radiol Imaging* 2010;**20**:92–7. https://doi.org/10.4103/0971-3026.63043.
12. Kirchgeorg MA, Prokop M. Increasing spiral CT benefits with post-processing applications. *Eur J Radiol* 1998;**28**:39–54. https://doi.org/10.1016/S0720-048X(98)00011-4.

13. Andronikou S, Irving B, Hlabangana LT, *et al*. Technical developments in postprocessing of paediatric airway imaging. *Pediatr Radiol* 2013;**43**:269–84. https://doi.org/10.1007/s00247-012-2468-1.
14. Andronikou S, Van der Merwe DJ, Goussard P, *et al*. Usefulness of lateral radiographs for detecting tuberculous lymphadenopathy in children—confirmation using sagittal CT reconstruction with multiplanar cross-referencing. *S Afr J Radiol* 2012;**16**:87–92. https://doi.org/10.4102/sajr.v16i3.288.
15. Sundarakumar DK, Bhalla AS, Sharma R, *et al*. Multidetector CT evaluation of central airways stenoses: comparison of virtual bronchoscopy, minimal-intensity projection, and multiplanar reformatted images. *Indian J Radiol Imaging* 2011;**21**:191–4. https://doi.org/10.4103/0971-3026.85366.
16. Andronikou S, Joseph E, Lucas S, *et al*. CT scanning for the detection of tuberculous mediastinal and hilar lymphadenopathy in children. *Pediatr Radiol* 2004;**34**:232–6. https://doi.org/10.1007/s00247-003-1117-0.
17. Maydell A, Goussard P, Andronikou S, *et al*. Radiological changes post-lymph node enucleation for airway obstruction in children with pulmonary tuberculosis. *Eur J Cardio-Thoracic Surg* 2010;**38**:478–83. https://doi.org/10.1016/j.ejcts.2010.02.008.
18. Wang R-P, Deng Q-P, Liang C-H, *et al*. Multidetector CT diagnosis of tracheobronchial stenosis associated with congenital heart diseases in paediatric patients. *J Med Imaging Radiat Oncol* 2012;**56**:220.
19. Cakir E, Uyan ZS, Oktem S, *et al*. Flexible bronchoscopy for diagnosis and follow up of childhood endobronchial tuberculosis. *Pediatr Infect Dis J* 2008;**27**:783–7. https://doi.org/10.1097/INF.0b013e318170fccc.
20. Kang ES, Choi YR, Lee KM, *et al*. Massive hemoptysis after a bronchoscopic biopsy in patients with endobronchial tuberculosis. *Chin Med J (Engl)* 2014;**127**:3837–8. https://doi.org/10.3760/cma.j.issn.0366-6999.20141353.
21. Boiselle PM, Reynolds KF, Ernst A. Multiplanar and three-dimensional imaging of the central airways with multidetector CT. *AJR Am J Roentgenol* 2002;**179**:301–8. https://doi.org/10.2214/ajr.179.2.1790301.
22. Lee KS, Boiselle PM. Update on multidetector computed tomography imaging of the airways. *J Thorac Imaging* 2010;**25**:112–24. https://doi.org/10.1097/RTI.0b013e3181d7e721.
23. Lee EY, Zucker EJ, Restrepo R, *et al*. Advanced large airway CT imaging in children: evolution from axial to 4-D assessment. *Pediatr Radiol* 2013;**43**:285–97. https://doi.org/10.1007/s00247-012-2470-7.