

https://dspace.org/

The value of lateral chest X-rays for the diagnosis of lymphadenopathy in children with pulmonary tuberculosis

Poyiadji, Thalia Leto

2018

https://hdl.handle.net/10539/25329

Downloaded from a DSpace repository. https://dspace.org/

The value of lateral chest X-rays for the diagnosis of lymphadenopathy in children with pulmonary tuberculosis.

Thalia Leto Poyiadji

A research report submitted to the Faculty of Health Sciences, University of Witwatersrand, Johannesburg, in fulfilment of the requirements for the degree of Master of Medicine in the branch of Diagnostic Radiology

Johannesburg 2018

Declaration

I, Thalia Leto Poyiadji, declare that this research report is my own work. It is being submitted for the degree of Masters of Medicine (Diagnostic Radiology) at the University of Witwatersrand. It has not been submitted before for any degree or examination at this or any other University.

Signature of Candidate

Date:

PUBLICATIONS AND PRESENTATIONS ARISING FROM THIS STUDY

This study was presented at the 53rd Annual General Meeting & 39th Post Graduate Course of the European Society of Paediatric Radiology in Davos, Switzerland in May 2017.

ABSTRACT

INTRODUCTION:

Tuberculosis (TB) is an important public health issue, but diagnosis in children can be challenging. The radiological hallmark of pulmonary TB (PTB) in children is mediastinal lymphadenopathy, however there is inter-observer variability in detecting this. The value of the lateral CXR in addition to the frontal view to detect lymphadenopathy has not been well studied.

OBJECTIVES:

To investigate the prevalence of lymphadenopathy in children with confirmed PTB detected on frontal compared to frontal-lateral CXRs.

METHODS:

This was a secondary analysis of a study from Red Cross Children's Hospital in Cape Town. Children with definite TB and a control group (Lower respiratory tract infection other than TB) who had frontal and lateral CXRs were included in this study. Three radiologists independently read the CXRs in 2 separate sittings (frontal CXR and 'combination frontal-lateral' CXR). A 3 reader consensus reading was used during data analysis. Odds ratios and 95% confidence intervals were calculated to determine the presence of lymphadenopathy. Kappa statistics were calculated to determine inter reader agreement.

RESULTS:

Of 172 children (88 confirmed TB and 84 control children), with a median age of 29 months, lymphadenopathy was reported in 86 (50%) patients on the frontal CXR alone and in 143 (83%) on the frontal-lateral CXR combination, p= 0.00. Amongst confirmed PTB cases, 52 (60%) had lymphadenopathy on the frontal CXR alone while 72 (82%) had lymphadenopathy on the frontal-lateral CXR combination, p= 0.00. Amongst the control group, 34 (40%) had lymphadenopathy on the frontal CXR alone while 71 (85%) had lymphadenopathy on the frontal-lateral CXR combination, p= 0.00.

The consensus reading using a frontal-lateral CXR combination resulted in a 5 fold increase (OR 4,9; 95% CI 2,9-8,4) in diagnosis of lymphadenopathy compared to a frontal CXR only.

Overall inter reader agreement for all 3 readers was fair on both the frontal CXR (Kappa= 0,21) and the frontal-lateral CXR (Kappa= 0,23) combination.

CONCLUSION:

The addition of a lateral view to the frontal CXR increased detection of lymphadenopathy, however, the prevalence of lymphadenopathy was similar in children with PTB and those in the control group, with fair inter reader agreement.

ACKNOWLEDGEMENTS:

I would like to acknowledge

-My supervisors Dr Nasreen Mahomed and Prof Savvas Andonikou for their support, enthusiasm and commitment to this MMed.

-The readers Dr Nasreen Mahomed, Dr Tanyia Pillay and Dr Ronel Swarts for their time and expertise in reading the Xrays with no compensation for their time.

-Professor Zar and her team for allowing access to their database and providing invaluable patient information.

Table of contents

Declaration……2
Publications and presentations arising from this study……3
Abstract……4
Acknowledgements……6
Table of contents……7
List of tables……9
List of figures……10
List of abbreviations……11
1. Rationale……12
2. Introduction 12
2.1. TB and South Africa 12
2.2. Diagnosis of TB in children. 13
2.2.1. CXR and TB 13
3. Aim 17
4. Study Objectives 17
5. Methods 17
5.1. Research paradigm 17
5.2. Study population 17
5.2.1. Inclusion criteria 17
5.2.2. Exclusion criteria 18
5.3. Study Period 18
5.4. Materials and Methods 18
5.5. Data collection and collation 20
5.6. Reliability and validity 20
5.7. Bias 20
6. Data analysis and statistics 20
7. Ethics 21
7.1. Consent forms 21
7.2. Data safety 21
8. Results 22
8.1 Demographics and baseline characteristics……22

8.2 Detection of lymphadenopathy using a frontal and frontal-lateral CXR combination for all patients, with and without proven PTB……22
8.3 Detection of lymphadenopathy using a frontal and frontal-lateral CXR combination for HIV infected and HIV negative children……23
8.4 Detection of lymphadenopathy using a frontal and frontal-lateral CXR combination according to final TB diagnosis and stratified by HIV status……24
8.5 CXR findings of lymphadenopathy using frontal vs frontal-lateral CXR combination with odds ratios……25
8.6 Inter reader agreement in detecting lymphadenopathy on frontal and frontal-lateral CXR combinations, in all patients and stratified by TB diagnosis and HIV status……26
8.7 Detection of lymphadenopathy per lymph node region using a frontal and frontal- lateral CXR combination……27
9. Discussion 29
9.1. Value of the addition of a lateral CXR to the standard frontal CXR for diagnosing lymphadenopathy……29
9.2. Interpretation of the presence of lymphadenopathy per location……31
9.3 Interreader agreement in evaluating lymphadenopathy with the addition of a lateral CXR to the standard frontal lateral combination……31
9.4 Evaluation of lymphadenopathy according to HIV status……38
9.5 Limitations of the study……39
9.6 Areas of future research identified by the current study……39
10.Conclusion……40
11. References……42
12. Appendices ……46
12.1 Appendix 1: …… 47
12.2 Appendix 2: ……48
12.3 Appendix 3: ……49
12.4 Appendix 4:……50

List of Tables

Table Number	Table Heading	Table Page
Table 1	Summary of studies comparing findings on lateral and frontal chest X-rays in suspected PTB	16
Table 2	Interpretation of kappa values by Landis and Koch (29)	21
Table 3.1	Presence of lymphadenopathy using a consensus reading on a frontal CXR only and frontal-lateral CXR combination according to final diagnosis of TB	23
Table 3.2	Presence of lymphadenopathy using a consensus reading on a frontal CXR only and frontal-lateral CXR combination according to HIV status	24
Table 3.3	Presence of lymphadenopathy using a consensus reading on a frontal CXR only and frontal-lateral CXR combination according to TB diagnosis and stratified by HIV status	25
Table 3.4	Presence of lymphadenopathy using frontal vs frontal-lateral CXR combination with odds ratios	26
Table 3.5	Inter reader agreement using kappa values (K) for lymphadenopathy for the frontal vs the frontal-lateral CXR combination	27
Table 3.6	Commonest reported sites of lymphadenopathy using a consensus reading on frontal and frontal-lateral CXR combination.	28
Table 4.1	Summary of relevant studies comparing findings on frontal and lateral CXRs	30
Table 4.2	Summary of relevant studies comparing inter reader agreement in reading CXRs	38

List of Figures:

Figure Number	Label of Figure	Figure Page
Figure 1	Flow diagram illustrating study population and demographics	22
Figure 2.1a	Frontal CXR of a child with HIV and positive TB gene expert where all 3 readers reported lymphadenopathy	33
Figure 2.1b	Lateral CXR of a child with HIV and positive TB gene Expert where all 3 readers reported lymphadenopathy	34
Figure 2.2a	Frontal CXR of an HIV negative child with positive TB gene Expert where there was poor inter reader agreement on the presence of lymphadenopathy	36
Figure 2.2b	Lateral CXR of an HIV negative child with positive TB Gene Expert where there was poor inter reader agreement on the presence of lymphadenopathy	37

List of Abbreviations

CXR	Chest X Ray
HIV	Human Immunodeficiency Virus.
AIDS	Acquired Immunodeficiency Virus
TB	Tuberculosis
CT Scan	Computed Tomography Scan
WHO	World Health Organisation
CRF	Customized Reporting Form
K	Kappa
IQR	Interquartile Range
mSV	Millisevert
UCT	University of Cape Town
RCCH	Red Cross Children's Hospital

1. Rationale

In South Africa frontal and lateral chest X-rays (CXR) are often requested as baseline investigations in children with symptoms of lower respiratory tract infection (1, 2). Lateral CXRs are generally not recommended in addition to the frontal radiograph, as they do not substantially alter diagnosis or management of the patient, but increase radiation dose exposure (3-5). In South Africa, the burden of HIV and TB in children may result in a spectrum of CXR findings requiring reconsideration of the value of the lateral CXR (1, 2, 6-8, 32). However lymphadenopathy, the cardinal sign of pulmonary TB (PTB) in children, may be more accurately diagnosed on lateral CXR. Lateral CXRs are therefore frequently done in clinical practise when a diagnosis of PTB is suspected, to detect lymphadenopathy. The value of lateral CXR in addition to the frontal view for detection of lymphadenopathy for suspected PTB in children has not been well studied (12,20,21).

2. Introduction

Tuberculosis (TB) remains an important public health issue and causes serious morbidity and mortality. The Human Immunodeficiency Virus (HIV) epidemic has exacerbated the prevalence of TB and its complications (9, 10, 32). The risks of TB infection are more serious in children, especially those in the under 5-year age group, where there is a higher risk of spread and complications such as miliary TB or TB meningitis. Emphasis is therefore on early diagnosis and treatment (9).

2.1. TB and South Africa

South Africa has one of the highest prevalence rates of paediatric TB globally, with the childhood prevalence estimated to be more than 400 per 100 000 population per annum, (1, 8, 11, 12).The commonest form of TB disease in children is pulmonary TB (PTB). More severe disseminated disease such as TB meningitis may also occur in very young children or immunocompromised states, such as HIV or malnutrition, (1, 8).

2.2. Diagnosis of TB in children.

The diagnosis of PTB in children may be challenging as children present with non-specific symptoms and microbiologic confirmation may be difficult (11). This diagnostic challenge is increased in resource poor settings, such as sub Saharan Africa, as well as in settings of high HIV prevalence (8, 13, 14). In adults the gold standard for TB diagnosis is bacteriological confirmation, however microbiologic confirmation is not often performed in children due to the paucibacilliary nature of disease and lower bacteriological yields (6, 8).

The diagnosis of PTB in children is therefore often made based on the clinical presenting features, TB contacts, the CXR findings as well as the tuberculin skin test with or without microbiologic confirmation. Children with associated HIV may have non-specific clinical symptoms and the tuberculin skin test may be falsely negative, making definitive diagnosis of PTB even more challenging (10, 13). Overall a microbiologically confirmed diagnosis of PTB is made in 30-50% of children with suspected PTB (2), even with the availability of rapid PCR testing (Xpert) (14).

2.2.1. CXR and TB

The "radiological hallmark" in the diagnosis of PTB in children is the presence of mediastinal lymphadenopathy seen on CXR or Computed Tomography scan (CT) of the chest (10, 15-17). One of the five World Health Organization's (WHO) diagnostic criteria for pulmonary TB in children includes "a suggestive appearance on chest radiograph" (11).
CXR features in children with TB mimic the pathophysiology of the infection; these include additional radiological signs, such as compression of the airways by lymphadenopathy, a fine nodular pattern (miliary disease) or parenchymal cavitation on the X-ray (18, 19).

Lymphadenopathy features on CXR are described as oval masses in the region of the hila on frontal projections and as a lobulated ring posterior to bronchus intermedius on lateral projections (20). The 'doughnut sign' is formed superoanteriorly by the aortic arch (its posterior aspect) and the right and left main pulmonary arteries, and inferiorly by hilar and subcarinal nodes. The centre of the doughnut sign is bronchus intermedius (19).

A CXR is recommended in the initial workup of children suspected of having PTB (31). While lymphadenopathy is the radiological hallmark of PTB on CXR, an important limitation is the wide inter- and intra observer variability, as reported in several studies (2, 11, 21). Studies by Swingler et al (18) and Lee et al (4) showed poorer inter-observer agreement when reading lateral CXRs compared to frontal films. The American Thoracic Society (ATS)/ Centre for Disease Control (CDC) guidelines, however, still recommend the use of a single frontal radiograph in all patients over the age of 5 years when screening for PTB, while children under this age should receive both a frontal and lateral radiograph (3, 22). Due to the high prevalence of PTB in South Africa most patients receive both a frontal and lateral radiograph as part of routine clinical care. The lateral projection is believed to increase the likelihood of visualizing lymphadenopathy and subsequently diagnosing PTB (2). The radiation risk of obtaining two projections in a child also needs to be considered. The dose received from a frontal CXR is 0,02mSv and from a lateral CXR is 0,04mSv; if a lateral projection is thus eliminated a dose reduction of approximately 67% can be achieved (5).

Five studies were found in an English language literature search, which assessed the value of the lateral CXR compared to the frontal CXR in diagnosing PTB, summarised in Table 1. The study by Smuts et al included only children with signs and symptoms of PTB or those who had a positive TB contact. This study confirmed the usefulness of a lateral radiograph in diagnosing PTB in children, as evidenced by the 11% of cases with mediastinal lymphadenopathy found **on lateral CXR only**. This study had a large cohort of patients, but 34 % of their study population consisted of clinic based patients with a positive TB contact, who had no symptoms of TB which cannot be extrapolated to studies of patients with confirmed TB (23).

However another study (4), found no new abnormality detected on lateral CXR. This study was performed in a **non-endemic** area on **asymptomatic patients**, however, and these findings cannot be applied to patients living in TB endemic areas. None of the remaining 3 studies (3, 5, 17) found any value in performing an additional lateral CXR for the diagnosis of PTB. The study by Swingler et al used CT scan of the chest as the gold standard for assessment of lymphadenopathy (18) and compared CXR interpretation. However, the CXR readers for this study included primary care physicians and paediatricians rather than

qualified radiologists, which may account for the poor inter-observer agreement with regards to interpretation of the lateral projection, compared with the frontal radiograph (5). The inclusion criteria of their patients were also those for suspected TB rather than confirmed TB, and even the CT gold standard quality at the time is questionable, given the poor CT inter-observer agreement (21). The studies by Eisenberg (5) and Meyer (3) were both done on an adult population with positive skin tuberculin tests. These studies were done in adults and therefore may not be comparable with a paediatric population, especially since the CXR features of pulmonary TB in adults are not characterised by lymphadenopathy (24).

Table 1: Summary of studies comparing findings on lateral and frontal chest X-rays in suspected PTB

Study	Demographics	Diagnostic Inclusion	Sample size	Study Findings
Smuts et al 1994	Children <12yrs Age range: 1 month-12 years	Symptoms of TB or a positive TB contact	449	Lymphadenopathy visualized on: Frontal and lateral X-rays in 81 cases (18%) Frontal X-rays only in 29 cases (7%) Lateral X-rays only in 50 cases (11%)
Swingler et al 2005	Children <14yrs Median age: 21,5 months	Suspected TB	100	"Use of AP together with lateral views showed a non-significant trend towards a higher diagnostic odds ratio than the use of the AP view alone or use of the lateral view alone." Poorer inter-observer agreement for lateral views as compared to frontal views
Lee et al 2010	Children ≤ 18yrs Mean age: 10,8 ± 5,2 years	Positive PPD skin test but no TB symptoms.	605	No new abnormalities were noted on the lateral CXR compared to the frontal CXRs. Poorer inter-observer agreement in interpreting the lateral CXR compared to the frontal CXR
Meyer 2003	Adults > 18yrs Mean age: 39 ±15 years	Positive tuberculin skin test	535	A new abnormality was noted on the lateral CXR in only 0,4% of cases. Abnormality did not alter patient management.
Eisenberg et al 2009	Adults > 18yrs Mean age: Males: 38 ±11 years Females: 37 ± 11 years	Positive PPD test	875	No new abnormalities were noted on lateral CXR compared to frontal CXR. No change in management due to additional findings on lateral CXR

3. Aim

To investigate the prevalence of lymphadenopathy in children with proven PTB detected on frontal CXRs alone compared to frontal-lateral combination CXRs.

4. Study Objectives

- To determine and compare the prevalence of lymph nodes on frontal CXRs alone versus 'combination frontal-lateral' set of CXRs in children with TB using patients with confirmed TB and comparing this to controls (children with LRTIs other than TB).
-To compare the prevalence of lymphadenopathy on frontal vs a frontal –lateral CXR combination by HIV status.

5. Methods

5.1. Research paradigm

Secondary analysis of data collected as part of a prospective study on improved diagnostic methods for childhood TB between 1 February 2009 to 31 December 2013.

5.2. Study population

The study population was all children diagnosed with definite TB (either through culture or Gene Xpert) at the Red Cross Children's Hospital (RCCH) in Cape Town, South Africa, from 1 February 2009 until 31 December 2013. A control group of patients included 84 children, who presented to RCCH with a lower respiratory tract infection other than TB

3 (Classified as not TB, with a negative mantoux, no household TB contact and improved at months without TB treatment) from 1 February 2009 until 31 December 2013.

5.2.1. Inclusion criteria

The study group were children, less than 13 years of age, who presented to the RCCH and were diagnosed with PTB (confirmed on culture or Gene Xpert on induced sputum) who had both frontal and lateral CXRs prior to starting TB treatment.

The control group were children (less than 13 years of age) who presented to RCCH with a lower respiratory tract infection other than TB (as defined above) who had both frontal and lateral CXRs.

The CXRs were obtained from an existing database from the parent study, consisting of digital records of all the patient's files (including a complete patient workup and diagnosis) and CXRs.

5.2.2. Exclusion criteria

Patients whose CXRs were of poor quality/unreadable as per customized report form (CRF). Poor quality and unreadable films were excluded through a consensus read determined during the data analysis phase.

5.3 Study period

A period of 5 years spanning from 1 February 2009 to 31 December 2013.

5.4. Materials and Methods

Chest X-rays (frontal and lateral) and patient information (age, HIV status) of all children enrolled in a larger study of TB diagnosis at the RCCH, with confirmed TB (on culture or Gene Xpert), from 1 February 2009 until 31 December 2013, were collected from an existing study database with permission from Professor Zar (Appendix 3), the lead investigator. Eighty-four control patients, who presented to RCCH with a lower respiratory tract infection other than TB (negative microbiological investigations for TB, not clinically diagnosed with TB, and improved at 3 months without TB treatment) were retrieved from the same research database.

Each digital J-PEG CXR pair (frontal and 'combined frontal-lateral' CXR set) was randomly allocated a number from 1-172. Only the study author had a key to the patient details corresponding to the study number.

The digital CXR files were saved onto 2 DVDs - the first DVD contained all the frontal X-rays, the second DVD all the 'combination frontal-lateral' CXR sets- and these were copied to yield 4 sets of two DVD's (one for each reader and one back-up for the primary investigator).

The CXRs were labelled 1- 172 with no other patient information on the radiographs. Three qualified radiologists independently read the CXRs in 2 separate sittings (one the frontal X-ray and one for the 'combination frontal-lateral' CXR set) one month apart, using their own DVD set, blinded to the diagnosis of PTB.

The reading was performed on each reader's personal computer.

The readers were blinded to all clinical information (i.e. the diagnostic category) and to each other's findings.

The readers were required to complete a CRF for each CXR read – when reading the frontal x-rays they completed a single CRF (Appendix 1), when reading the 'combination frontal-lateral' CXR set they were required to complete 2 CRFs (Appendix 1 and 2). The CRFs with potential lymph node enlargement were limited to the following criteria (as per Andronikou et al)(2, 20).

The criteria for lymphadenopathy on frontal films:

- The mediastinal outline appears multilobulated with or without mediastinal shift.
- Filling of the hilar point: may manifest as obliteration of the hilar "V", a convex margin of the hilar point, hilar elevation or a hilar mass.
- Airway compression: caused by enlarged lymph nodes may result in complete or partial airway obstruction. Partial obstruction manifests as hyperinflation of a lobe distal to the obstruction as opposed to complete obstruction, which results in collapse (24).

The criteria for lymphadenopathy on lateral films (20, 21):

- The doughnut sign: a soft tissue lobulated density noted posterior and inferior to bronchus intermedius. The doughnut ring is completed by the main pulmonary arteries and the aortic arch.
- The incomplete doughnut sign: A lobulated soft tissue mass anterior, inferior or posterior to bronchus intermedius.

Readers underwent standardized training prior to reading. The principal investigator explained the CRF form to the readers who were then given 2 papers, describing the above lymphadenopathy features (19, 20), to read, in their own time, prior to beginning reading

the X-rays. They were also instructed to only record presence of lymphadenopathy when they had confidence in the feature of a sufficient degree to be able to demonstrate the lymphadenopathy on the image to an imaginary student. If any queries arose regarding the CRF or the two articles the principal investigator was available to clarify any questions.

5.5. Data collection and collation

Once the CRF forms were completed by all 3 readers, the principal investigator captured the results onto a Microsoft Excel spreadsheet. The principal investigator was responsible for quality assurance, and data collation.

5.6. Reliability and validity

Three readers were used to read the X-rays in an attempt to increase reliability.
Our study aimed to measure the diagnostic accuracy of CXRs for detecting lymphadenopathy in children to diagnose PTB. However the readers were not required to detect TB but rather the surrogate marker of this, which is lymphadenopathy. Therefore the detection of lymphadenopathy was evaluated against gene Xpert or culture positive TB. A control group of patients, with a LRTI other than TB, were used to increase validity.

5.7. Bias

An element of omission bias was present due to the omission of poor quality CXRs, i.e. CXRs were excluded using the 3 readers consensus decision during the data analysis phase.

6. Data analysis and statistics

Data was analysed using Epi Info software, version 6.04d (Centers for Disease Control and Prevention, Atlanta, Georgia).
Two by two tables were generated with Chi-squared test or Fisher's exact tests as appropriate using the TB culture / Xpert as the "gold standard" and the frontal and 'combination frontal-lateral' CXR consensus reading as the test (of lymphadenopathy). From these, prevalence rates for lymphadenopathy in each group were calculated. Odds ratios and 95% confidence intervals were derived where significant associations were observed. Statistical significance was set as a P-value of <0.05 as per standard practice. Kappa values

for inter reader agreement were calculated according to a study by Landis and Koch (29) in 1977 and interpreted as follows:

Table 2: Interpretation of kappa values by Landis and Koch (29)

Kappa	Interpretation
<0	Less than chance agreement
0.01-0.2	Slight
021-0.4	Fair
0.41-0.6	Moderate
0.61-0.8	Substantial
0.81-0.99	Almost perfect
1	Perfect agreement

7. Ethics

Ethics approval for the overall parent study was from the Faculty of Health Sciences Research Ethics Committee, University of Cape Town (UCT.) Letters of permission were obtained from the head of RCCH paediatric unit (Appendix 3).

Ethics approval for this study was granted by the University of Witwatersrand Human Research Ethics committee (certificate #: M140422- Appendix 4)

No additional imaging was performed for the purposes of this study and CXRs already performed for clinical purposes were used.

7.1. Consent forms

Consent for use of the data was obtained from the principal investigator at RCCH.

No consent forms were required for the study, as all patient personal information was kept confidential and this study was retrospective in nature, nested in the larger study. Consent for participation in the larger study, in which this one is nested, was obtained.

7.2. Data safety

The patient data was stored on the primary investigator's computer with backup files saved onto an external hard drive. Data was collected anonymously by allocating a random number code to each patient. The key to this code was only available to the primary investigator and supervisor.

8. Results:

8.1 Demographics and baseline characteristics

One hundred and seventy two children were included (Figure 1 below), with a median age of 29 months, range of 2 months- 155 months, with an interquartile range (IQR) of 66.0 months.

Of the 172 children enrolled in the study, 88 (51%) were microbiologically confirmed to have TB (median age 30 months, IQR= 62.25 months) while 84 (49%) were in the control group (median age 29 months, IQR = 70.5 months), p=0.50.

Of the 88 patients with microbiologically confirmed TB, 15 (17%) were HIV positive and 73 (83%) were HIV negative, p= 0.00.

Of the 84 control cases 18 (21%) were HIV positive and 66 (79%) were HIV negative, p= 0.00.

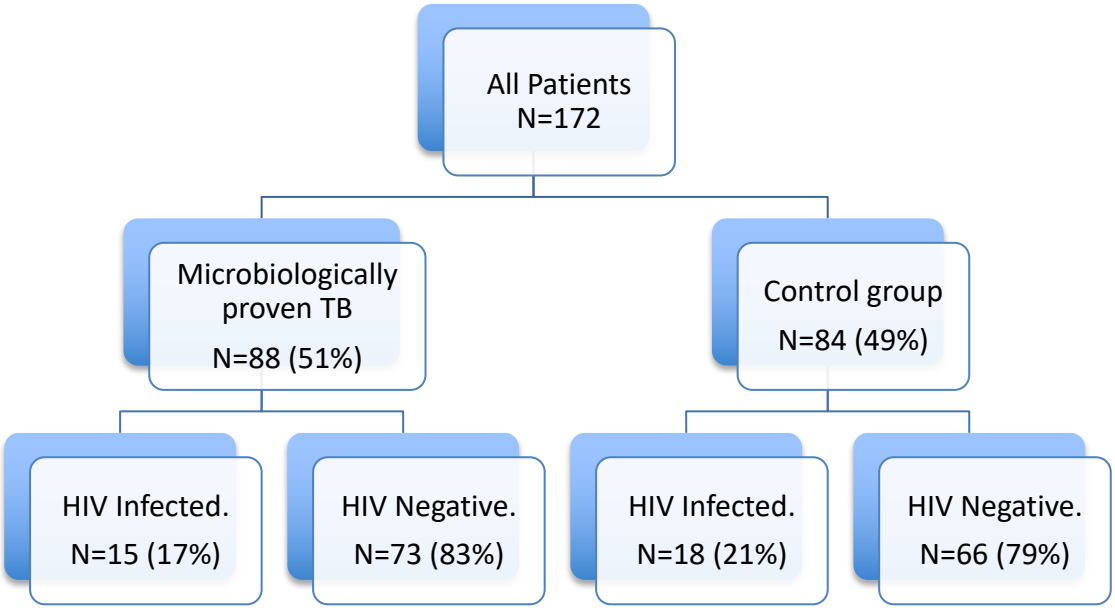

Figure 1. Flow diagram illustrating study population and demographics

8.2 Detection of lymphadenopathy using a frontal and frontal-lateral CXR combination for all patients, with and without proven PTB.

The prevalence of lymphadenopathy on frontal CXR and the frontal-lateral CXR combination are described in table 3.1 below.

For all children (N=172), frontal CXR lymphadenopathy was reported in 86 (50%) patients - of these, 52 (60%) had microbiologically proven TB and 34 (40%) were from the control group, p = 0.00.

Of the 86 (50%) patients with no lymphadenopathy 36 (42%) were TB proven and 50 (58%) were from the control group, p = 0.00.

For all children (N=172), frontal-lateral CXR combination lymphadenopathy was reported in 143 (83%) patients - of these 72 (50%) were microbiologically positive for TB and 71 (50%) were from the control group, P= 0.40. Of the 29 (17%) patients with no lymphadenopathy 16 (55%) were microbiologically positive for TB and 13 (45%) were from the control group, P=0.34.

Table 3.1: Presence of lymphadenopathy using a consensus reading on a frontal CXR only and frontal-lateral CXR combination according to final diagnosis of TB

	Frontal CXR Lymphadenopathy	Frontal-lateral CXR Lymphadenopathy
All patients. N=172	86 (50%)	143 (83%)
Microbiologically proven TB N=88 (51%)	52 (59%)	72 (82%)
Control group N=84 (49%)	34 (40%)	71 (85%)

8.3 Detection of lymphadenopathy using a frontal and frontal-lateral CXR combination for HIV infected and HIV negative children.

The prevalence of lymphadenopathy on frontal CXR and the frontal-lateral CXR combination in patients who were HIV infected and HIV negative are described in table 3.2 below.

For the HIV infected children (N=33), frontal CXR lymphadenopathy was reported in 21 (64%) patients, and in 28 (85%) of patients on the frontal-lateral CXR combination, p = 0.02.

For the HIV negative children (N=139), frontal CXR lymphadenopathy was reported in 65 (47%) patients, and in 115 (83%) patients on the frontal-lateral CXR combination, p = 0.00.

Table 3.2: Presence of lymphadenopathy using a consensus reading on a frontal CXR only and frontal-lateral CXR combination according to HIV status

	Frontal CXR lymphadenopathy	Frontal-lateral CXR combination Lymphadenopathy
All patients N=172	86 (50%)	143 (83%)
HIV Infected N=33 (19%)	21 (64%)	28 (85%)
HIV Negative N=139 (81%)	65 (47%)	115 (83%)

8.4 Detection of lymphadenopathy using a frontal and frontal-lateral CXR combination according to final TB diagnosis and stratified by HIV status.

For all children with microbiologically proven TB (N=88), 15 (17%) were HIV infected, of these lymphadenopathy was found in 13 (87%) patients on either the frontal or on the frontal-lateral CXR combination. In contrast of 73 (83%) HIV negative children, lymphadenopathy was found in 39 (53%) patients on the frontal CXR alone and in 59 (81%) patients on the frontal-lateral CXR combination, p = 0.00.

For all children in the control group (N=84), 18 (21%) were HIV infected; of these lymphadenopathy was found in 8 (44%) patients on the frontal CXR alone and in 15 (83%) patients on the frontal-lateral CXR combination, p = 0.01.

For all children in the control group (N=84), 66 (79%) were HIV negative; of these lymphadenopathy was found in 26 (39%) patients on the frontal CXR alone and in 56 (85%) patients on the frontal-lateral CXR combination, p = 0.00.

These results are summarised in table 3.3 below.

Table 3.3 Presence of lymphadenopathy using a consensus reading on a frontal CXR only and frontal-lateral CXR combination according to TB diagnosis and stratified by HIV status

TB diagnosis	HIV status	Frontal CXR lymphadenopathy	Frontal-lateral CXR lymphadenopathy
Microbiologically proven TB (N=88)	**HIV infected N=15 (17%)**	13 (87%)	13 (87%)
	HIV negative N=73 (83%)	39 (53%)	59 (81%)
Control group (N=84)	**HIV infected N=18 (21%)**	8 (44%)	15 (83%)
	HIV negative N=66 (79%)	26 (39%)	56 (85%)

8.5 CXR findings of lymphadenopathy using frontal vs frontal-lateral CXR combination with odds ratios.

The odds ratios for the presence of lymphadenopathy on frontal CXR and the frontal-lateral CXR combination are described in table 3.4 below.

Evaluating all children, N=172, the consensus reading using a frontal-lateral CXR combination resulted in a 5-fold increase (OR 4,9; 95% CI 2,9-8,4) in calling lymphadenopathy compared to the readers' consensus reading using a frontal CXR only.

In the microbiologically proven TB group, N=88, the consensus reading using a frontal and lateral CXR combination resulted in a 3-fold increase (OR 3,1; 95% CI 1,5-6,6) in calling lymphadenopathy compared to the readers' consensus reading using a frontal CXR only.

In the control group, N=84, using a frontal and lateral CXR combination the consensus reading resulted in an 8-fold increase (OR 8; 95% CI 3,7-18,1) in calling lymphadenopathy compared to a readers' consensus reading using a frontal CXR only.

In the HIV negative group, N=139, the consensus reading using a frontal and lateral CXR combination resulted in a 5-fold increase (OR 5,4; 95% CI 3-9,9) in calling lymphadenopathy compared to a readers' consensus reading using a frontal CXR only.

In the HIV infected group, N=33, the consensus reading using a frontal and lateral CXR combination trended towards an increase in calling lymphadenopathy compared to a

readers' consensus reading using a frontal CXR only however this increase was not statistically significant (OR 3,2; 95% CI 0,86-13,2).

Table 3.4. Presence of lymphadenopathy using frontal vs frontal-lateral CXR combination with odds ratios

	Frontal and Lateral CXR (2nd read)	Frontal CXR (1st read)	Odds Ratios
Overall N=172 (%N)	143 (83%)	86 (50%)	OR 4,9; (95% CI 2,9-8,4)
HIV Infected N=33 (%N)	28 (85%)	21 (64%)	OR 3,2 (95% CI 0,86-13,2)
HIV Negative N=139 (%N)	115 (83%)	65 (47%)	OR 5,4 (95% CI 3,0-9,9)
Microbiologically proven TB N=88 (%N)	72 (82%)	52 (59%)	OR 3,1 (95% CI 1,5-6,6)
Control group N=84 (%N)	71 (85%)	34 (40%)	OR 8 (95% CI 3,7-18,1)

8.6 Inter reader agreement in detecting lymphadenopathy on frontal and frontal-lateral CXR combinations, in all patients and stratified by TB diagnosis and HIV status.

Overall inter reader agreement for all 3 readers when evaluating for lymphadenopathy was fair on both the frontal CXR (Kappa=0,21) and the frontal-lateral CXR combination (Kappa= 0,23). Table 3.5 further demonstrates inter reader agreement for patients with and without confirmed TB and HIV infected and HIV negative patients. Inter reader agreement in patients with microbiologically proven TB was fair on the frontal and frontal-lateral CXR combination (Kappa= 0,25 and Kappa=0,4 respectively) and slight in the control group on the frontal and frontal-lateral CXR combination (Kappa= 0,14 and Kappa= 0,09 respectively). Inter reader agreement in HIV infected patients was slight on both the frontal and frontal-lateral CXR combination (Kappa= 0,14 and Kappa= 0,11 respectively) and fair in HIV negative patients (Kappa =0,22 and Kappa=0,25 respectively).

Table 3.5 Inter reader agreement using kappa values (K) for lymphadenopathy for the frontal vs the frontal-lateral CXR combination.

	3 reader inter reader agreement kappa values on the frontal CXR alone	3 reader inter reader agreement kappa values on the frontal-lateral CXR combination.
All patients	0,21	0,23
Microbiologically proven TB	0,25	0,4
Control group	0,14	0,09
HIV infected	0,14	0,11
HIV negative	0,22	0,25

8.7 Detection of lymphadenopathy per lymph node region using a frontal and frontal-lateral CXR combination.

When further evaluating the data we found that the commonest site for reported lymphadenopathy (summarised in table 3.6) was the left hilum on the frontal CXR, first read. In contrast the right hilum was the commonest site on the frontal CXR, second read. On the lateral CXR the commonest reported site of lymphadenopathy was anterior to bronchus intermedius.

The inter reader agreement for all children on reading the frontal CXRs was fair (Kappa=0,26) for first read where the left hilum was commonest, and (Kappa=0,24) for the second read where the commonest site was the right hilum. The inter-reader agreement for the commonest lymph node site reported on the lateral CXR, anterior to bronchus intermedius, was slight (Kappa=0,19).

Table 3.6: Commonest reported sites of lymphadenopathy using a consensus reading on frontal and frontal-lateral CXR combination.

	Frontal CXR 1st read- commonest site for all demographics= left hilar	Frontal CXR 2nd read Commonest site for all demographics= right hilar	Lateral CXR Commonest site for all demographics= anterior to bronchus intermedius.
All children N=172 (%)	69 (40%)	95 (55%)	133 (77%)
HIV Infected N=33 (%)	17 (51%)	24 (73%)	27 (82%)
HIV Negative N=139 (%)	52 (37%)	71 (51%)	106 (76%)
Microbiologically proven TB N=88 (%)	40 (45%)	46 (52%)	67 (76%)
Control group N=84 (%)	29 (35%)	49 (58%)	66 (79%)

9. Discussion:

9.1. Value of the addition of a lateral CXR to the standard frontal CXR for diagnosing lymphadenopathy.

This study aimed to determine the value of lateral radiographs for the diagnosis of lymphadenopathy in children with pulmonary TB. Lymphadenopathy is the hallmark of pulmonary TB in children (10, 15-17). A CXR is frequently used to confirm the diagnosis of TB and thus guide appropriate management of the child.

This study found that the addition of a lateral view to the standard frontal CXR increased the rate of diagnosis of lymphadenopathy, however the prevalence of lymphadenopathy was similar in children with PTB and those in the control group, with fair inter reader agreement.

Overall, the frontal-lateral CXR combination resulted in an almost 5- fold (OR 4,9 CI: 2,9-8,4) increase in reporting lymphadenopathy than did the frontal CXR alone; with an increase of 33% with the addition of the lateral CXR (50% of patients had lymphadenopathy on frontal CXR and 83% had lymphadenopathy on the frontal-lateral CXR combination).

Table 4.1 below summarises and compares the findings of our study with the findings of other prior similar studies. Our findings are comparable to a study by Smuts et al (24) from 1994 which advocates the use of a combination frontal-lateral CXR to diagnose lymphadenopathy in children with TB. In their study the presence of reported lymphadenopathy more than doubled with the addition of a lateral CXR, from 7% to 18%. This increase in reporting lymphadenopathy was most prominently reported in cases of confirmed TB, with no new cases of lymphadenopathy seen in patients with no TB. In our study a 3-fold increase (59% to 82%) was observed with the addition of the lateral CXR in patients with confirmed TB. In contrast to the study by Smuts et al the most significant increase in reporting lymphadenopathy with the addition of the lateral CXR was seen in patients who did not have TB (40% to 85%).
A study by Swingler et al (18) however reported that the addition of a lateral CXR shows a ‘non significant trend towards an increased OR than the use of the AP X-ray alone’.

Table 4.1: Summary of relevant studies comparing findings on lateral and frontal CXRs

Study	Patients	Frontal CXR lymphadenopathy	Frontal and lateral CXR combination lymphadenopathy.	Conclusions:	Differences to our study:
Our Study 2017	Confirmed TB N=88	52 (59%)	72 (82%)	The addition of a lateral view to the standard frontal CXR increased the rate of calling lymphadenopathy.	However this increase also occurred in the TB negative group
	Control group N=84	34 (40%)	71 (85%)		
Smuts et al 1994	Confirmed TB N=176	19 (11%)	40 (23%)	The lateral CXR is needed in conjunction with the frontal CXR to diagnose LAD in children with PTB.	The X-rays were read by 1 paediatric pulmonologist and multiple paediatricians.
	No TB N=133	2 (1,5%)	2 (1,5%)		
Swingler et al (2005)	Suspected TB N=100	Diagnostic OR 3,1	Diagnostic OR 3,7		Reference standard for LAD was spiral CT. XRs read by primary care physicians and paediatricians

9.2. Interpretation of the presence of lymphadenopathy per location.

Further evaluation of our data found that the commonest lymphadenopathy sites reported by the readers were the hilar nodes on the frontal CXR (left hilar on the first read and right hilar on the second read) and anterior to bronchus intermedius on the lateral CXR. As described in the literature, anatomically there are more lymph nodes (in number) in the paratracheal regions, however hilar lymphadenopathy is more commonly visualised on frontal CXR (24). This is mirrored in our study where hilar lymphadenopathy were the commonest sites reported as being present.

9.3 Inter-reader agreement in evaluating lymphadenopathy with the addition of a lateral CXR to the standard frontal lateral combination.

Overall agreement remained fair when evaluating for lymphadenopathy in all patients on the frontal CXR (Kappa=0,2088) and the frontal-lateral CXR combination (Kappa= 0,233), and in the HIV negative patients (Kappa =0,219 on the frontal CXR and Kappa=0,252 on the frontal-lateral CXR combination)

In the HIV infected group agreement remained slight on both the frontal (Kappa=0,1403) and frontal- lateral CXR combination (Kappa=0,113).

This raises 3 questions:

1) Was the training received by the 3 readers adequate?

All 3 readers received the same training through 2 thorough articles which adequately addressed the radiological evaluation of lymphadenopathy on paediatric CXRs- however no test cases were provided to the readers to confirm they understood the directions given. Two of the three readers were qualified (One was fellowship trained and the other is head of a children's hospital radiology department) paediatric radiologists practising in South Africa - where there is sufficient experience diagnosing primary TB - and thus level of expertise should not have played a role in the poor inter reader agreement.

2) Why was the prevalence of lymphadenopathy similar in children with PTB and those in the control group?

There are two possible explanations for this:

A) All children in our study population had LRTIs and over and above this some were HIV infected- therefore the prevalence of these patient's having lymphadenopathy maybe higher than the general population even if they do not have PTB.

This finding is consistent with our suboptimal inter reader agreement, which was overall 'fair' between readers and only slightly better when using a frontal-lateral combination (Kappa=0,23) compared to the frontal CXR alone (Kappa=0,21). These findings are consistent with similar studies by Swingler et al (18) and du Toit et al (12) (see table 4.2) which both demonstrated only fair inter reader agreement, with Kappa of 0,36 and 0,33 respectively, when assessing for lymphadenopathy on CXR. The study by Swingler et al (18) further confirmed that the inter reader agreement was similar for the frontal CXR alone and the frontal-lateral CXR combination but decreased when the lateral CXR was read in isolation. Despite CT being the gold standard in diagnosing mediastinal and hilar lymphadenopathy, only moderate inter reader agreement was found in a study by Andronikou et al (22). This was however performed on older CT technology and did not specify any size or characteristic criteria for distinguishing lymphadenopathy from 'normal' lymph glands in the mediastinum (22).

The poor inter reader agreement demonstrated by our study is likely due to the lack of criteria for defining lymphadenopathy and the intrinsic limitations of CXR. Radiographs are a 2 tone (either black or white) summation image of a 3 dimensional body with multiple anatomical overlying shadows which may obscure underlying lymphadenopathy. Furthermore, parenchymal pathology and lymphadenopathy both appear radiopaque on radiography and thus lymphadenopathy may be obscured by underlying parenchymal disease (28).

Figure 2.1a and 2.1b below are examples of a frontal and frontal-lateral CXR combination from this study which demonstrated good inter-reader agreement; all three readers agreed that lymphadenopathy was present on the frontal CXR and the frontal and lateral CXR combination. This patient was microbiologically proven to have TB and was HIV infected. All 3 readers agreed that there was bilateral hilar lymphadenopathy, however they did not agree on whether there was mediastinal lymphadenopathy or not. All 3 readers agreed that there was lymphadenopathy on the lateral CXR with only 2 reporting the full donut sign.

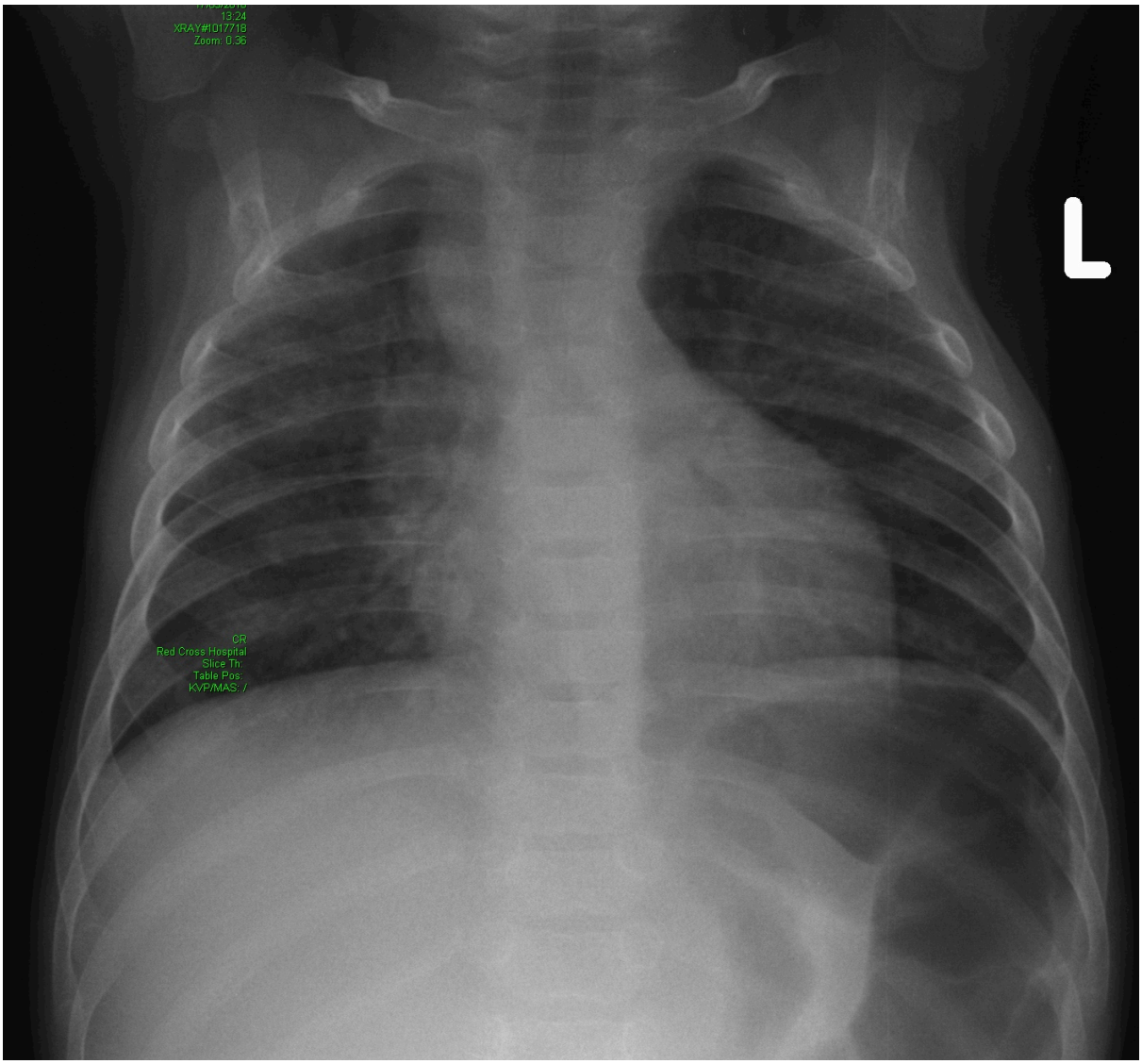

Figure 2.1a: Frontal CXR of a child with microbiologically confirmed TB and HIV infected where all 3 readers reported lymphadenopathy

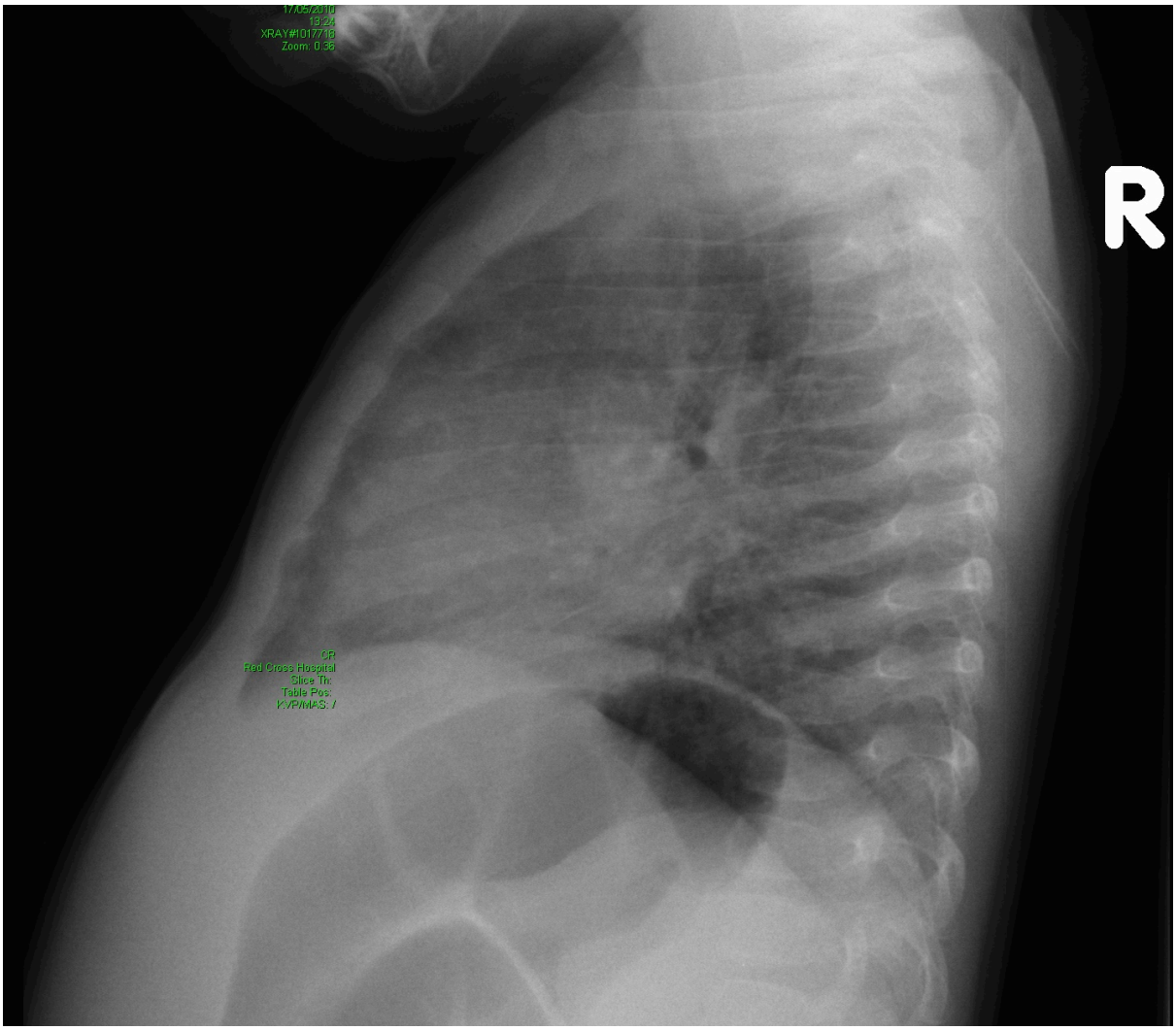

Figure 2.1b: Lateral CXR of a child with microbiologically confirmed TB and HIV infected where all 3 readers reported lymphadenopathy

Figures 2.2a and 2.2b below are examples of a frontal and frontal-lateral CXR combination from this study that demonstrated poor inter-reader agreement. Reader 1 reported lymphadenopathy in all stations on both frontal and lateral CXRs on both reads. Reader 2 reported lymphadenopathy on the frontal-lateral CXR combination but not on the frontal CXR when read alone. Reader 3 reported lymphadenopathy on the frontal CXR on the first read but no lymphadenopathy when reading the frontal-lateral CXR combination. Readers 2 and 3 described the left mediastinal region as 'area obscured by parenchymal disease' whereas reader one described the opacity as lymphadenopathy. This further confirms the limitation of the 2 tone nature (i.e. either black or white) of plain film radiography; lymphadenopathy, vascular structures and parenchymal pathology all appear radiopaque on CXRs and thus accurate delineation of these structures can be difficult even for the experienced radiologist. This patient was HIV negative but had microbiologically proven TB.

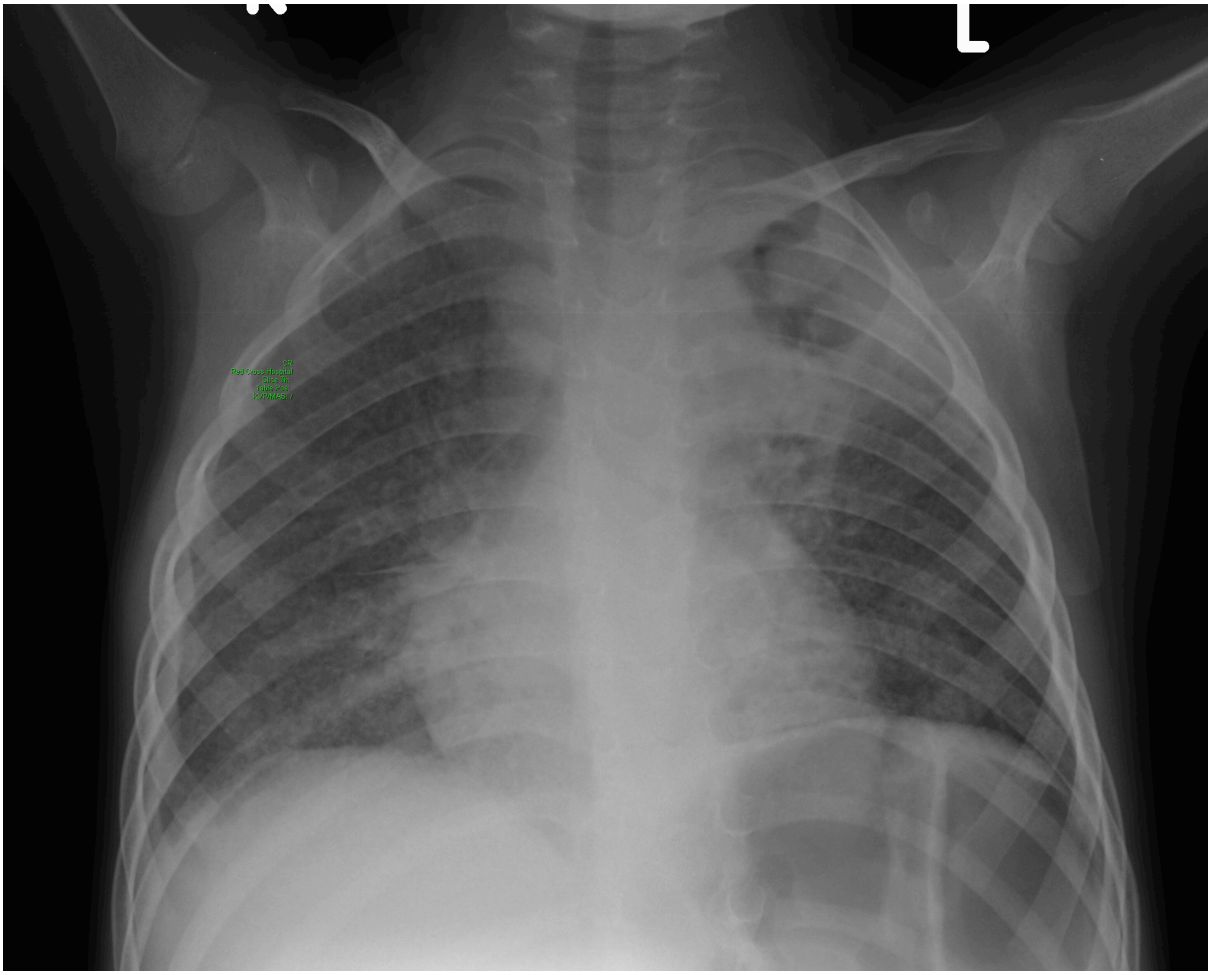

Figure 2.2a: Frontal CXR of an HIV negative child with microbiologically proven TB where there was poor inter reader agreement on the presence of lymphadenopathy. The left hilum is obscured by adjacent air-space disease but the left main bronchus compressions suggests that there is indeed left hilar lymphadenopathy present. There is also a diffuse nodular pattern in keeping with miliary TB as well as a right-sided lamellar effusion.

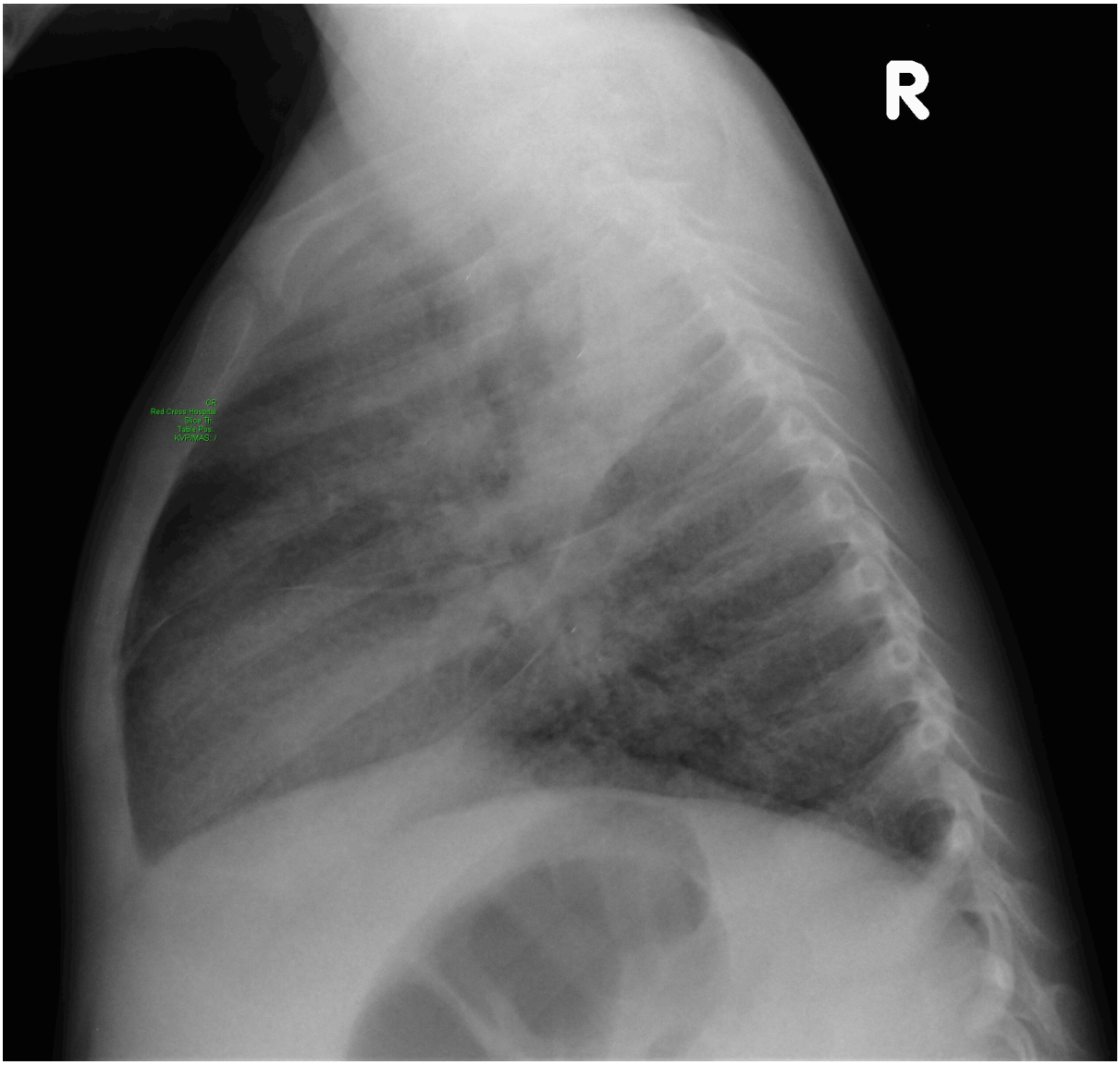

Figure 2.2b: Lateral CXR of an HIV negative child with microbiologically proven TB, where there was poor inter reader agreement on the presence of lymphadenopathy.

Table 4.2: Summary of relevant studies comparing inter reader agreement in reading CXRs

Study:	Objective relative to our study	Inter reader agreement	Other:
Du Toit et al 2002	Assess inter reader agreement in detecting lymphadenopathy in children at risk for TB	Average weighted kappa=0,33	CXRs read by paediatric pulmonologists Caution is necessary when basing clinical decisions on presence of lymphadenopathy on CXR
Swingler et al 2005	Diagnostic accuracy of CXR in detection of chest lymphadenopathy in kids with suspected pulmonary TB	Inter reader agreement kappa=0,36.	Agreement was similar for AP views alone and AP and lateral views together but less good for lateral views alone.
Andronikou et al 2004	Inter reader variability for detecting hilar and mediastinal lymphadenopathy on CT	Overall kappa=0,6	R hilar>Subcarinal>R paratracheal

3) What is the correct reference standard for diagnosing lymphadenopathy?

The reference standard for lymphadenopathy should not be microbiological confirmation Xpert, but rather contrast enhanced CT of the chest (25)- this is emphasised by the results of a study by Delacourt et al (27) in 1993 which detected lymphadenopathy on CT scan in 60% of their study patients who had normal CXRs. However even CT scan is lacking in that there is no predefined size criteria for distinguishing lymphadenopathy from non-pathological lymph glands in the chest in children (22).

9.4 Evaluation of lymphadenopathy according to HIV status.

To the best of our knowledge our study is unique in that we further evaluated for the presence of lymphadenopathy according to the patients HIV status.

In both the HIV infected and HIV negative groups there was an increase in diagnosis of lymphadenopathy with the addition of a lateral CXR.

Surprisingly the increase was more in the HIV negative group which reported a 5 fold increase in lymphadenopathy versus a 3 fold increase in the HIV positive group.

9.5 Limitations of the study.

Despite the readers being given 2 articles describing the interpretation of CXRs with regards to lymphadenopathy, no clearly defined criteria for the diagnosis of lymphadenopathy were provided. Furthermore no test cases were provided to the readers to confirm if they understood the directions given.
This is reflected in our results which demonstrate the presence of lymphadenopathy in 83% of patients, with almost 50% of patients being in TB negative groups.

The images used in this study were JPEG, rather than DICOM, which are of inferior quality making interpretation more difficult.

In our study the reference standard for lymphadenopathy was a positive microbiological result and no correlation was made with the gold standard of diagnosing lymphadenopathy (CT scan) to actually confirm presence of nodes. However radiation dose concerns precludes performing CT scans as the gold standard for lymphadenopathy in children.

Our study did not fully explore the role of HIV in the manifestations of thoracic TB or other lower respiratory tract infections. No correlation with patient's CD4 count or antiretroviral therapy was done which may result in lymphadenopathy being reported which is not due to TB. Other opportunistic LRTIs manifest with mediastinal nodes but are much smaller than nodes caused by TB and are thus not appreciated on CXRs. In current clinical practice patients are suspected to have TB, diagnosed on CXRs, whether they have PTB or pneumonia, irrespective of their HIV status.

9.6 Areas of future research identified by the current study.

A future research project can be proposed as a consequence of this study to correlate the presence of lymphadenopathy on CXR not only with the microbiological results but with a CT scan. This will allow further understanding of the different spectrum of TB changes in HIV infected and negative children. Confirmation of lymphadenopathy on CT scan can

furthermore be used to assess the interpretation of the CXR and thus recommend better criteria for diagnosing lymphadenopathy on CXR. Additionally with CT scan confirmation of lymphadenopathy the cause for the poor inter reader agreement can be evaluated.
A pilot study done by Moseme et al (30) evaluated ultrasound as a means for assessing anterior mediastinal lymphadenopathy; they found that ultrasound through the suprasternal notch is reliable in diagnosing mediastinal lymphadenopathy in children with supposed TB. This was a pilot study however with only 30 children in the study population. Further studies evaluating the usefulness of mediastinal ultrasound in diagnosing lymphadenopathy in children with TB may present an accessible, no radiation, means for diagnosis and follow up in these patients. Thus a study comparing CXRs, CT and ultrasound to assess for lymphadenopathy as a marker for TB in children is an area for future research.

10. Conclusion:

The addition of a lateral view to the standard frontal CXR increased detection of lymphadenopathy, however, the prevalence of lymphadenopathy was similar in children with PTB and those in the control group, with fair inter reader agreement.
Our findings are in keeping with other studies that highlight the weakness of CXR for diagnosing primary PTB in children and we recommend that future research aim at comparing radiographs with CT cross sectional imaging to determine the true accuracy of this imaging technique for detecting lymphadenopathy. If these also demonstrate poor accuracy, then the widespread use of X-ray for diagnosing primary in TB needs to be challenged and novel diagnostic imaging tests such as mediastinal ultrasound, low dose chest CT or MRI need to be introduced depending on the available resources.

11. References

(1) De Villiers RV, Andronikou S, Van de Westhuizen S. Specificity and sensitivity of chest radiographs in the diagnosis of paediatric pulmonary tuberculosis and the value of additional high-kilovolt radiographs. Australasian radiology. 2004 Jun;48(2):148-53.

(2) Andronikou S, Wieselthaler N. Modern imaging of tuberculosis in children: thoracic, central nervous system and abdominal tuberculosis. Pediatric radiology. 2004 Nov;34(11):861-75.

(3) Meyer M, Clarke P, O'Regan AW. Utility of the lateral chest radiograph in the evaluation of patients with a positive tuberculin skin test result. Chest. 2003 Nov;124(5):1824-7.

(4) Lee EY, Tracy DA, Eisenberg RL, et al. Screening of asymptomatic children for tuberculosis is a lateral chest radiograph routinely indicated? Academic radiology. 2011 Feb;18(2):184-90.

(5) Eisenberg RL, Romero J, Litmanovich D, et al. Tuberculosis: value of lateral chest radiography in pre-employment screening of patients with positive purified protein derivative skin test results. Radiology. 2009 Sep;252(3):882-7.

(6) Marais BJ, Gie RP, Schaaf HS, et al. A proposed radiological classification of childhood intra-thoracic tuberculosis. Pediatric radiology. 2004 Nov;34(11):886-94.

(7) Goussard P, Gie RP, Kling S, et al. Bronchoscopic assessment of airway involvement in children presenting with clinically significant airway obstruction due to tuberculosis. Pediatric pulmonology. 2013 Oct;48(10):1000-7.

(8) Marais BJ, Gie RP, Schaaf HS, et al. Childhood pulmonary tuberculosis: old wisdom and new challenges. American journal of respiratory and critical care medicine. 2006 May;173(10):1078-90.

(9) Kim WS, Choi JI, Cheon JE, et al. Pulmonary tuberculosis in infants: radiographic and CT findings. AJR American journal of roentgenology. 2006 Oct;187(4):1024-33.

(10) Bosch-Marcet J, Serres-Creixams X, Zuasnabar-Cotro A, et al. Comparison of ultrasound with plain radiography and CT for the detection of mediastinal lymphadenopathy in children with tuberculosis. Pediatric radiology. 2004 Nov;34(11):895-900.

(11) Cohen J. Reversal of Misfortunes. Science. 2013 Feb;22(2):898-903.

(12) Du Toit G, Swingler G, Iloni K. Observer variation in detecting lymphadenopathy on chest radiography. The international journal of tuberculosis and lung disease : the official journal of the International Union against Tuberculosis and Lung Disease. 2002 Sep;6(9):814-7.

(13) Marais BJ, Hesseling AC, Gie RP, et al. The burden of childhood tuberculosis and the accuracy of community-based surveillance data. The international journal of tuberculosis and lung disease : the official journal of the International Union against Tuberculosis and Lung Disease. 2006 Mar;10(3):259-63.

(14) Weismuller MM, Graham SM, Claessens NJ, et al. Diagnosis of childhood tuberculosis in Malawi: an audit of hospital practice. The international journal of tuberculosis and lung disease : the official journal of the International Union against Tuberculosis and Lung Disease. 2002 May;6(5):432-8.

(15) Zar HJ, Workman L, Isaacs W, et al. Rapid diagnosis of pulmonary tuberculosis in African children in a primary care setting by use of Xpert MTB/RIF on respiratory specimens: a prospective study. The Lancet Global Health. 2013 Aug;2013;1(2):8.

(16) Bosch-Marcet J, Serres-Creixams X, Borras-Perez V, et al. Value of sonography for follow-up of mediastinal lymphadenopathy in children with tuberculosis. Journal of clinical ultrasound : JCU. 2007 Mar-Apr;35(3):118-24.

(17) Goussard P, Gie RP, Kling S, et al. The outcome of infants younger than 6 months requiring ventilation for pneumonia caused by Mycobacterium tuberculosis. Pediatric pulmonology. 2008 May;43(5):505-10.

(18) Swingler GH, du Toit G, Andronikou S, et al. Diagnostic accuracy of chest radiography in detecting mediastinal lymphadenopathy in suspected pulmonary tuberculosis. Archives of disease in childhood. 2005 Nov;90(11):1153-6.

(19) Lucas S, Andronikou S, Goussard P, et al. CT features of lymphobronchial tuberculosis in children, including complications and associated abnormalities. Pediatric radiology. 2012 Aug;42(8):923-31.

(20) Andronikou S, Wieselthaler N. Imaging for Tuberculosis in Children. In: Zumla S, editor. Tuberculosis: a comprehensive reference (eds): Saunders; 24 March 2009. p. 261-95.

(21) Mahomed H, Hleza B, Andronikou S. The Doughnut Sign. SA Journal of Child Health. 2011 Dec;5(4):126-27.

(22) Andronikou S, Brauer B, Galpin J, et al. Interobserver variability in the detection of mediastinal and hilar lymph nodes on CT in children with suspected pulmonary tuberculosis. Pediatric radiology. 2005 Apr;35(4):425-8.

(23) de Charnace G, Delacourt C. Diagnostic techniques in paediatric tuberculosis. Paediatric respiratory reviews. 2001 Jun;2(2):120-6.

(24) Smuts NA, Beyers N, Gie RP, et al. Value of the lateral chest radiograph in tuberculosis in children. Pediatric radiology. 1994 Dec;24(7):478-80.

(25) Marais BJ, Gie RP, Schaaf HS, et al. The natural history of childhood intra-thoracic tuberculosis: a critical review of literature from the pre-chemotherapy era. The international journal of tuberculosis and lung disease : the official journal of the International Union against Tuberculosis and Lung Disease. 2004 Apr;8(4):392-402.

(26) Andronikou S, Joseph E, Lucas S, et al. CT scanning for the detection of tuberculous mediastinal and hilar lymphadenopathy in children. Pediatric radiology. 2004 Mar;34(3):232-6.

(27) Delacourt C, Mani TM, Bonnerot V, et al. Computed tomography with normal chest radiograph in tuberculous infection. Archives of disease in childhood. 1993 Oct;69(4):430-2.

(28) de Groot PM, Carter BW, Abbott GF, et al. Pitfalls in chest radiographic interpretation: blind spots. Seminars in roentgenology. 2015 Jul;50(3):197-209.

(29) Landis JR, Koch GG. The measurement of observer agreement for categorical data. Biometrics. 1977 Mar;33(1):159-74.

(30) Moseme T, Andronikou S. Through the eye of the suprasternal notch: point-of-care sonography for tuberculous mediastinal lymphadenopathy in children. Pediatric radiology. 2014 Jun;44(6):681-84.

(31) Roya-Pabon CL, Perez-Velez CM. Tuberculosis exposure, infection and disease in children: a systematic diagnostic approach. Pneumonia (Nathan). 2016 Nov;8:23.

(32) Naidoo J, Mahomed N, Moodley H. A systematic review of tuberculosis with HIV coinfection in children. Pediatric radiology. 2017 Sep;47(10):1267-76.

12. Appendices

12.1 Appendix 1

Customised Report Form (CRF) for the frontal CXRs

Study Number

Reader 1 ☐ 2 ☐ 3 ☐

Technical quality	Good	Rotated	Movement	Under inspired
	☐	☐	☐	☐

Nodal Station	Yes	Possibly yes	No	Area obscured by parenchymal disease
Right mediastinal	☐	☐	☐	☐
Left mediastinal	☐	☐	☐	☐
Right hilar	☐	☐	☐	☐
Left hilar	☐	☐	☐	☐

Overall is there lymphadenopathy ☐ Y ☐ N

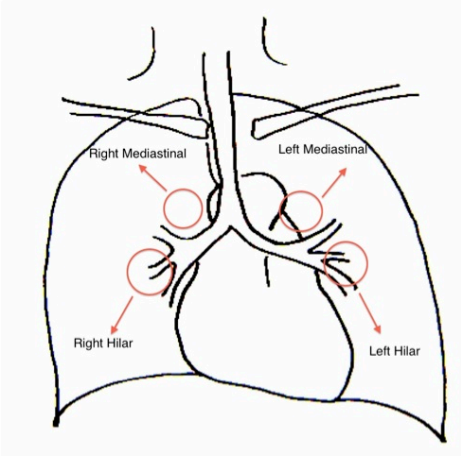

1

12.2 Appendix 2

Customised Report Form (CRF) for the lateral CXR.

Study Number

Reader 1 ☐ 2 ☐ 3 ☐

Nodal Station	Yes	Possibly yes	No	Area obscured by parenchymal disease
Complete doughnut sign	☐	☐	☐	☐
Anterior to bronchus intermedius	☐	☐	☐	☐
Inferior to bronchus intermedius	☐	☐	☐	☐
Posterior to bronchus intermedius	☐	☐	☐	☐

Overall is there lymphadenopathy ☐ Y ☐ N

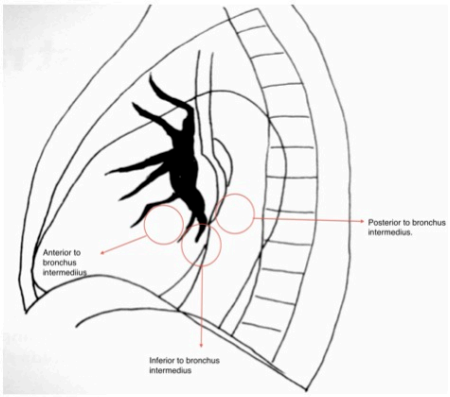

1

12.3 Appendix 3

Letter of Permission from Professor Zar to conduct the study.

UNIVERSITY OF CAPE TOWN

DEPARTMENT OF PAEDIATRICS AND CHILD HEALTH

RED CROSS WAR MEMORIAL CHILDREN'S HOSPITAL
KLIPFONTEIN ROAD
RONDEBOSCH
7700

TEL: +27 21 658 5319/5324
FAX: +27 21 689 1287

29 March 2014

Dear Dr TL Poyiadji.

Re: "The value of lateral chest X-rays for the diagnosis of lymphadenopathy in children with pulmonary tuberculosis."

Permission is granted for you to conduct the above study as indicated in your request.

1. The Red Cross Children's Hospital will not in any way incur or inherit costs as a result of the said study.
2. Strict confidentiality shall be observed at all times.
3. I will have input into any publication/s to be produced and will be a co-author
4. The research staff at Red Cross Children's Hospital will be acknowledged in any publication.

I, Dr TL Poyiadji accept the terms and conditions set in this document.

Sign: _____ **Date:** _____

Yours sincerely

Professor Heather Zar
Head of Department of Paediatrics and Child Health
Director: School of Child and Adolescent Health

12.4 Appendix 4

Ethics approval certificate granted by the University of the Witwatersrand Human Research Ethics Committee

M140422

HUMAN RESEARCH ETHICS COMMITTEE (MEDICAL)

CLEARANCE CERTIFICATE NO. M140422

NAME: (Principal Investigator)	Dr Thalia Leto Poyiadji
DEPARTMENT:	Radiology University of the Witwatersrand
PROJECT TITLE:	The Value of Lateral Chest X-Rays for the Diagnosis of Lymphadenopathy in Children with Pulmonary Tuberculosis
DATE CONSIDERED:	25/04/2014
DECISION:	Approved unconditionally
CONDITIONS:	
SUPERVISOR:	Dr Nasreem Mahomed and Prof Savvas Andronikou
APPROVED BY:	Professor PE Cleaton-Jones, Chairperson, HREC (Medical)

DATE OF APPROVAL: 06/06/2014

This clearance certificate is valid for 5 years from date of approval. Extension may be applied for.

DECLARATION OF INVESTIGATORS

To be completed in duplicate and **ONE COPY** returned to the Secretary in Room 10004, 10th floor, Senate Hous University.

I/we fully understand the conditions under which I am/we are authorized to carry out the above-mentioned resear and I/we undertake to ensure compliance with these conditions. Should any departure be contemplated, from t research protocol as approved, I/we undertake to resubmit the application to the Committee. **I agree to submit yearly progress report**.

Principal Investigator Signature M140422Date

PLEASE QUOTE THE PROTOCOL NUMBER IN ALL ENQUIRIES