

https://dspace.org/

A comparison of chest radiographic findings in human immunodeficiency viruspositive and negative children with pulmonary tuberculosis

Thandi Buthelezi; S.S.B Venkatakrishna; Susanna Lucas; L Workman; K Dheda ...

https://hdl.handle.net/10539/40781
WOS

Downloaded from a DSpace repository. https://dspace.org/

Clinical Radiology 79 (2024) e317–e324

Contents lists available at ScienceDirect

Clinical Radiology

journal homepage: www.clinicalradiologyonline.net

A comparison of chest radiographic findings in human immunodeficiency virus-positive and -negative children with pulmonary tuberculosis

T.E. Buthelezi [a], S.S.B. Venkatakrishna [b], S. Lucas [a], L. Workman [c], K. Dheda [d], M.P. Nicol [e,f], H.J. Zar [c], S. Andronikou [b,g,*]

[a] *Department of Diagnostic Radiology, Chris Hani Baragwanath Academic Hospital, University of Witwatersrand, South Africa*
[b] *Department of Radiology, Children's Hospital of Philadelphia, 3401 Civic Center Blvd, Philadelphia, PA 19104, USA*
[c] *Department of Paediatrics & Child Health, Red Cross Children's Hospital, SA-MRC Unit on Child & Adolescent Health, University of Cape Town, South Africa*
[d] *Lung Infection and Immunity Unit, Division of Pulmonology and University of Cape Town Lung Institute, Department of Medicine, University of Cape Town, South Africa*
[e] *Division of Infection and Immunity, School of Biomedical Sciences, University of Western Australia, Perth, Australia*
[f] *Division of Medical Microbiology, University of Cape Town and National Health Laboratory Services, South Africa*
[g] *Department of Radiology, Perelman School of Medicine, University of Pennsylvania, Philadelphia, PA, USA*

ARTICLE INFORMATION

Article history:
Received 12 January 2023
Received in revised form
18 October 2023
Accepted 26 October 2023

AIM: To compare chest radiography (CXR) findings in human immunodeficiency virus (HIV)-positive and HIV-negative children who had microbiologically confirmed pulmonary tuberculosis (PTB).

MATERIALS AND METHODS: Retrospective analysis of CXRs from children with known HIV status and microbiologically confirmed PTB (culture or GeneXpert Xpert MTB/RIF positive), who were hospitalised or seen at a primary healthcare centre over a 5-year period. Radiological findings were compared according to HIV and nutritional status.

RESULTS: CXRs of 130 children were analysed from 35 (27%) HIV- positive and 95 (73%) HIV-negative children with confirmed PTB, median age 45.7 months (interquartile range [IQR] 18–81.3 months). CXR changes consistent with PTB were reported in 21/35 (60%) of HIV-positive and 59/95 (62%) of HIV-negative patients, (p=0.81). Normal CXR was identified in 3/35 (8.6%) of HIV-positive and 5/95 (5.3%) of HIV-negative patients (p=0.81). Airway compression was present in 3/35 (8.6%) of HIV-positive and 7/95 (7.4%) of HIV-negative patients (p>0.99). Overall, lymphadenopathy was identified in 42/130 (32.3%) of patients, 11/35 (31.4 %) were HIV-positive compared with 31/95 (32.6%) HIV-negative patients. Airspace consolidation was present in 60% of both HIV-positive (21/35) and HIV-negative patients (57/95). Pleural effusion was present in 2/35 (5.7 %) of HIV-negative and 9/95 (9.5 %) of HIV-negative patients. There were no statistically significant radiological differences by HIV group.

* Guarantor and correspondent: S. Andronikou, Department of Radiology, Children's Hospital of Philadelphia, 3401 Civic Center Blvd, Philadelphia, PA 19104, USA.
E-mail address: doctor.andronikou@gmail.com (S. Andronikou).

https://doi.org/10.1016/j.crad.2023.10.036
0009-9260/© 2023 Published by Elsevier Ltd on behalf of The Royal College of Radiologists.

CONCLUSION: There were no significant differences in the CXR findings between the HIV-positive and HIV-negative children with confirmed PTB.
© 2023 Published by Elsevier Ltd on behalf of The Royal College of Radiologists.

Introduction

The impact of human immunodeficiency virus (HIV) and co-infection, including tuberculosis (TB), continues to place a major burden on healthcare in sub-Saharan Africa. In children, vertical transmission is still the predominant mechanism of HIV infection.[1–3] HIV-infected children have a threefold higher risk of contracting respiratory infections, especially TB, not only because of their immature immune systems[4] and HIV-related immune suppression, but also from poor maternal immunity and lack of protective maternal antibodies with vertical transmission.[5,6] TB also commonly co-exists with malnutrition, contributing to high TB-associated mortality.[5,7] TB may be difficult to diagnose in children as the signs and symptoms are non-specific and definitive confirmation may be difficult, especially in young children and HIV-infected children.[8–11] Culture or positive polymerase chain reaction (PCR) (GeneXpert® Xpert® MTB/RIF) of *Mycobacterium tuberculosis* are the reference standard for the diagnosis of definite PTB; however, children are frequently culture-negative. As timely initiation of therapy is important to prevent disease progression in children, therapy is often started based on clinical and radiological features.[12] Diagnosing TB can also be challenging in the presence of malnutrition as the clinical presentation, disease spectrum, and/or diagnostic yield may be altered.[13]

According to the World Health Organization (WHO) Global Tuberculosis Report 2013, HIV-positive TB patients have worse treatment outcomes than HIV-negative TB cases.[14] Treatment of TB disease in HIV-infected children can be complex due to drug interactions, the need to adjust antiretroviral drug doses, and adherence to multiple drugs.[15,16] Chest radiography (CXR) plays a vital role in the diagnosis of PTB especially in children.[13] There is now a new practical value in the use of CXR in diagnosis of PTB based on the 2022 WHO consolidated TB guidelines with classification of disease into severe and non-severe TB categories for decisions on length of treatment.[17] CXR features that are suggestive of TB include: enlarged hilar lymph nodes, lung opacification, miliary pattern opacification and persistent opacification not responding to treatment.[15] HIV-infected children may present with atypical findings and a normal CXR.[18,19] Some studies have compared CXR findings between HIV- infected and HIV- uninfected TB patients,[8,11,20–24] but these were not in children with confirmed PTB. This study aimed to compare the chest X-ray findings in HIV-positive and HIV-negative children with microbiologically confirmed PTB.

Material and methods

This was a retrospective analysis of CXRs from children with known HIV status (PCR or enzyme-linked immunosorbent essay [ELISA]) and proven PTB (culture and/or GeneXpert Xpert MTB/RIF positive), whose drug antiretroviral treatment (ART) profile was unknown. These children were hospitalised at a tertiary referral children's hospital or seen at a primary healthcare centre in South Africa over a 5-year period.

Secondary analysis was undertaken of CXR data collected as part of an institutional review board-approved parent prospective study conducted in the Western Cape province of South Africa. Ethics approval was obtained from the HREC of Faculty of Health Sciences, University of Cape Town, for the parent study (ethics clearance number ref no: 045/2008) and ethics clearance for the current study (certificate no: M140128) was obtained from the University of the Witwatersrand.

Children underwent anteroposterior (AP) and lateral CXR as part of a routine initial assessment and no follow-up radiographs were included. These CXRs were interpreted for this study by two paediatricians, who were independent expert primary readers, each with >20 years of clinical experience. A third independent reader (with >10 years of experience as a paediatric radiologist at the time of the study) was used as a tiebreaker when there was no consensus. A standardised reporting form was used, and all readers were blinded to HIV-status, clinical data, and other laboratory results of all the patients. Radiological findings were subsequently compared according to HIV and nutritional status.

Data available from the parent study included demographic information, clinical information (e.g., nutritional status), and laboratory results (e.g., TB diagnosis and HIV status for each patient). Data on the CXR findings was documented on a standardised reporting form, and readers were blinded to HIV status, clinical data, and other laboratory results of all the patients. This form had six defined reporting categories: lung parenchyma, airway, nodes, pleura, heart, and technical quality.

The chi-squared test was used to assess the relationships between categorical variables. Fisher's exact test was used for 2×2 tables or where the requirements for the chi-squared test could not be met. The strength of the associations was measured by Cramer's V and the phi coefficient, respectively. The relationship between continuous and categorical variables was assessed using the *t*-test. Where the data did not meet the assumptions of these tests, a non-

parametric alternative and the Wilcoxon rank sum test was used. The strength of the associations was measured by the Cohen's d for parametric tests and the *r*-value for the non-parametric tests. For the between group testing for underweight-for-age, HIV status was included as a covariate. For categorical variables, this was accomplished by using the Cochran–Mantel–Haenszel test, while for continuous variables, a general linear model with HIV status and nutritional status as fixed effects was used.

A 5% significance level was used throughout. Results were expressed as frequencies and percentages for categorical variables. Data analysis was carried out using SAS software (version 9.3 for Windows, SAS Institute, Cary, NC, USA).

Results

The CXRs of 130 children were included in the study; 110 (84.6%) were hospitalised at a tertiary referral children's hospital while 20 (15.4%) were ambulatory patients from the primary healthcare centre (NG). Fifty-four patients (41.5%) were female; median age was 45.7 months (3.8 years; interquartile range [IQR] 18–81.3 months or 1.5–6.8 years). There were 35 (26.9%) HIV-positive and 95 (73.1%) HIV-negative children.

HIV-positive and HIV-negative children were compared with regards to healthcare site, sex, and age (Table 1). HIV-positive children were older, median age of 64.7 (IQR 44.2–91.3) months, than those who were HIV-negative, median age 27.3 (IQR 16.6–62.4) months (p=0.005).

A total of 122 (93.8%) CXRs were found to be abnormal, while eight (6.2%) were normal. Eighty (61.5%) CXRs were classified as consistent with PTB, while 42 (32.3%) were considered to be inconclusive. None of these outcomes were significantly associated with HIV status or nutritional status (Table 2). Airway compression was present in 3/35 (8.6%) of HIV-positive and 7/95 (7.4%) of HIV-negative patients. Airspace consolidation (Figs 1 and 2) was present in 60% of both HIV-positive (21/35) and HIV-negative patients (57/95). Only 1/35 (3%) of the HIV-positive cases compared with 12/95 (13%) of the HIV-uninfected cases had lung cavities; similarly, 1/35 (3%) of HIV-positive and 11/95 (11.6%) of HIV-uninfected patients had interstitial nodular infiltrates. Pleural effusion (Fig 3) was present in 2/35 (5.7 %) of HIV-positive and 9/95 (9.5 %) of HIV-negative children (Table 3).

Overall lymphadenopathy was identified in 42/130 (32.3%) patients, with a similar proportion in HIV-positive and negative children (11/35 [31.4 %] versus 31/95 [32.6%]). Hilar lymphadenopathy (Fig 4) was present in 8/35 (23%) of HIV-positive and 25/95 (26%) of HIV-negative patients, while mediastinal lymphadenopathy occurred in 8/35 (23%) of HIV-positive and 20/95 (21.1%) of HIV-negative children (Table 4). None of these differences were statistically significant. Thirty-nine (30.0%) children were underweight-for-age, 74 (56.9%) adequately nourished, and 17 (13.1%) had unknown nutritional status. Most underweight-for-age patients (38/39 patients, 97.4%) were hospitalised (p=0.004) and were male (28/39 patients, 72%; p=0.046). Underweight-for-age occurred more commonly in HIV-positive patients (17/31, 48.6%) than HIV-negative patients (22/95, 23.3%; p=0.008; Table 5). Pleural effusion was present in 9/74 (12.2%) of the adequately nourished patients, while none of the malnourished patients had this feature (p=0.025; Table 3). A proportion of adequately nourished patients with lymphadenopathy was 29/74 (39.2 %) and 12/39 (30.8 %) in underweight-for-age group.

Discussion

In the present study, most children (94%) with microbiologically confirmed PTB had an abnormal CXR, with only 6% of children having a normal CXR; however, there were no significant differences in radiological findings between HIV-positive and HIV-negative children with PTB. A possible reason for this finding could be that the HIV-infected children may have been well-controlled on antiretroviral drugs, with consequently higher CD4 counts and undetectable viral loads. The present findings are consistent with a prior South African study of HIV-infected children, which reported a high prevalence of CXR abnormalities, with the

Table 1
Comparison of human immunodeficiency virus (HIV)-positive and HIV-negative children by healthcare site, sex, age and nutritional status.

Variable	Category	Overall	HIV-positive	HIV-negative	*p*-Value (effect size)
		No. of patients (%) n=130	No. of patients (%) n=35	No. of patients (%) n=95	
Healthcare site	Primary healthcare centre	20 (15.4)	4 (11.4)	16 (16.8)	0.59
	Hospital	110 (84.6)	31 (88.6)	79 (83.2)	
Sex	F	54 (41.5)	17 (48.6)	37 (38.9)	0.42
	M	76 (58.5)	18 (51.4)	58 (61.1)	
Age (months)	Median	45.7	64.7	27.3	0.005[a] (r=0.25[b])
	IQR	18 to 81.3	44.2 to 91.3	16.6 to 62.4	
Age (years)	Median (IQR)	3.8 (1.5–6.8)	5.4 (3.7–7.6)	2.3 (1.4–5.2)	
Underweight	No	74 (65.5)	14 (45.2)	60 (73.2)	0.008[c] (phi = 0.26[b])
For age (n=113)	Yes	39 (34.5)	17 (54.8)	22 (26.8)	

[a] Wilcoxon rank sum test.
[b] Weak association.
[c] Fisher's exact test.

Table 2
Final assessment of chest radiographs (CXRs) including radiological diagnosis of tuberculosis according to human immunodeficiency virus (HIV) and nutritional status categories in children.

Diagnosis on CXR	Overall *n* (%) *n*=130	HIV status (*n*=130)			Nutritional status (*n*=113)		
		Positive *n* (%) *n*=35	Negative *n* (%) *n*=95	*p*-Value	Adequately nourished No. (%) *n*=74	Underweight for age No. (%) *n*=39	*p*-Value
Normal CXR	8 (6.2)	3 (8.6)	5 (5.3)	0.81	6 (8.1)	2 (5.1)	0.91
TB on CXR	80 (61.5)	21 (60)	59 (62.1)		46 (62.2)	28 (71.8)	
Inconclusive CXR	42 (32.3)	11 (31.4)	31 (32.6)		22 (29.7)	9 (23.1)	

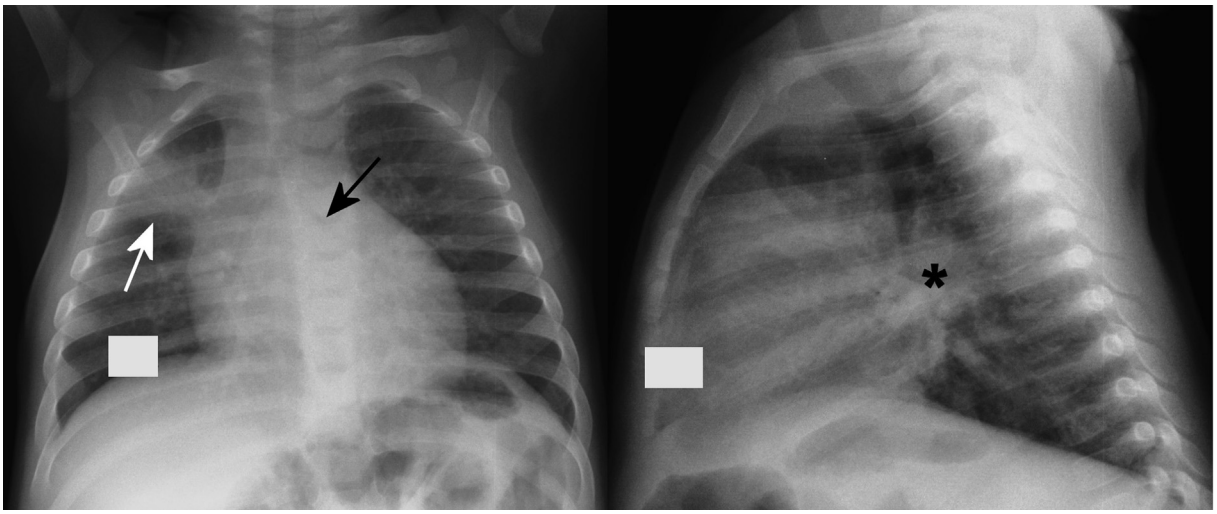

Figure 1 Frontal and lateral chest radiographs of an 8-month-old malnourished female patient with confirmed TB, who was HIV-negative, demonstrating right upper lobe airspace consolidation (white arrow) and perihilar lymphadenopathy (asterisk) causing left main bronchus compression (black arrow).
Key: *Grey box anonymization of hospital identifiers.*

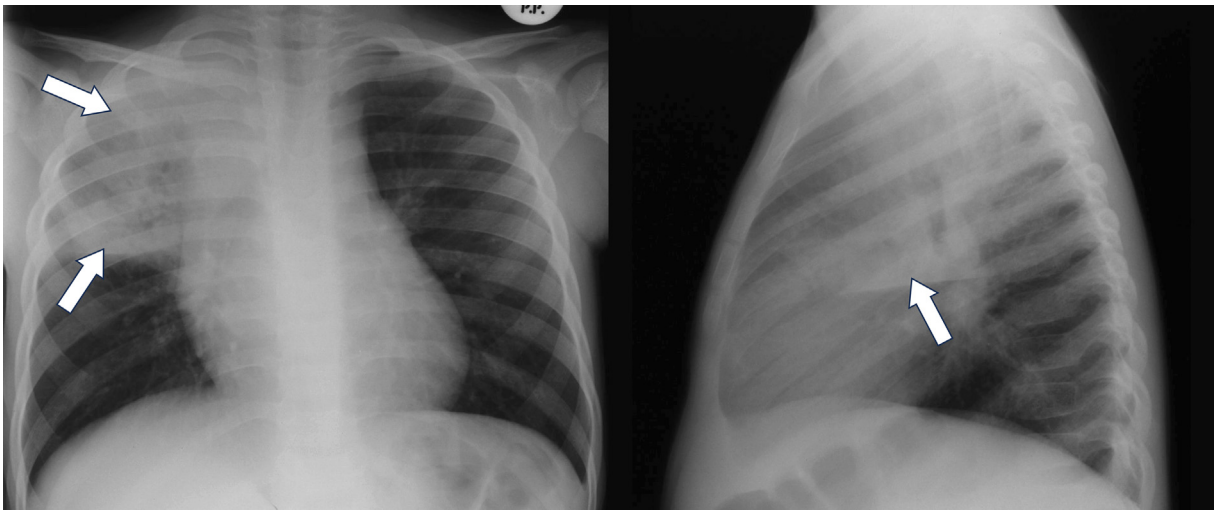

Figure 2 Frontal and lateral chest radiographs of an 8-year-old malnourished male patient with confirmed TB, who was HIV-positive, demonstrating right upper lobe airspace consolidation (arrows) with air bronchograms.

extent of chest radiological abnormality associated with clinical and immunological severity of HIV disease.[18]

The inclusion of children with microbiologically confirmed PTB (GeneXpert Xpert MTB/RIF or culture positive) in the present study and confirmed HIV status of all participants makes these findings important and novel. Other studies, summarised in Table 6, used a combination of radiological, clinical, or culture characteristics to diagnose PTB,[8,11,20–24] and the HIV status of some patients was unknown.[20] Table 6 compares the current study with seven

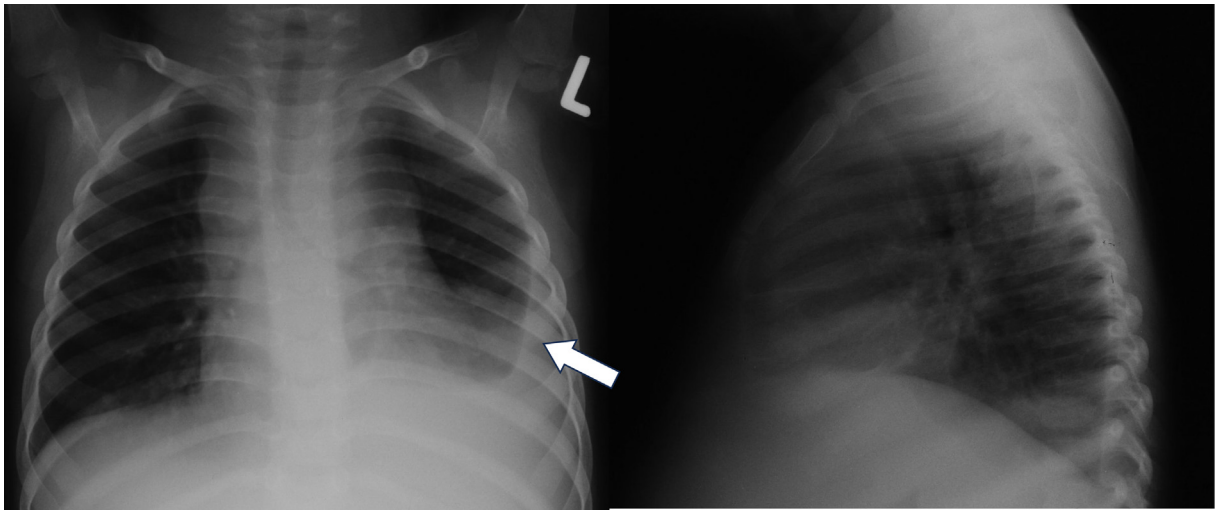

Figure 3 Frontal and lateral chest radiographs of an 18-month-old well-nourished HIV-negative infant with confirmed TB demonstrating left-sided pleural effusion (arrow).

Table 3
Chest radiography (CXR) parenchymal and pleural findings according to human immunodeficiency virus (HIV) and nutritional status categories.

Finding	Category	Overall *n* (%) *n*=130	HIV status (*n*=130)			Nutritional status (*n*=113)		
			Positive *n* (%) *n*=35	Negative *n* (%) *n*=95	*p*-Value	Adequately nourished *n* (%) *n*=74	Underweight for age *n* (%) *n*=39	*p*-Value
Airspace consolidation	No	50 (38.5)	13 (37.1)	37 (38.9)	>0.99	29 (39.2)	15 (38.5)	0.81
	Yes	78 (60)	21 (60)	57 (60)		45 (60.8)	22 (56.4)	
	Inconclusive	2 (1.5)	1 (2.9)	1 (1.1)	-	0 (0)	2 (5.1)	-
Hyperinflation	Yes	3 (2.3)	1 (2.9)	2 (2.1)	>0.99	3 (4.1)	0 (0)	0.17
Cavitation	Yes	13 (10)	1 (2.9)	12 (12.6)	0.18	7 (9.5)	1 (2.6)	0.34
Nodular infiltration	Yes	8 (6.2)	1 (2.9)	7 (7.4)	0.68	4 (5.4)	3 (7.7)	0.47
Miliary infiltration	Yes	4 (3.1)	0 (0)	4 (4.2)	0.57	2 (2.7)	2 (5.1)	0.29
Volume loss	Yes	4 (3.1)	0 (0)	4 (4.2)	0.57	3 (4.1)	0 (0)	0.29
Air trapping	Yes	1 (0.8)	0 (0)	1 (1.1)	>0.99	0 (0)	1 (2.6)	0.1
Pleural effusion	Yes	11 (8.5)	2 (5.7)	9 (9.5)	0.73	9 (12.2)	0 (0)	0.025[a]

[a] Cochran–Mantel–Haenszel test.

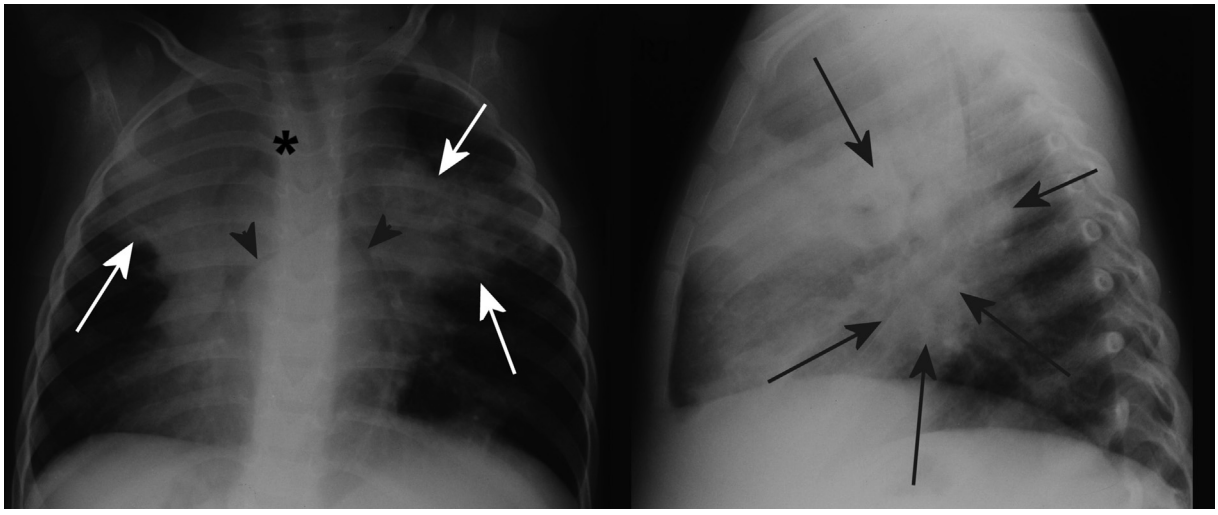

Figure 4 Frontal and lateral chest radiographs of a 2.5-year-old well-nourished girl with confirmed TB, who was HIV-negative, demonstrating paratracheal lymphadenopathy (asterisk) as seen by tracheal displacement to the left, compression of the bronchus intermedius as well as left main bronchus (arrow heads) and multi-lobar air space consolidation (white arrows). The doughnut sign (black arrows) on the lateral view indicates peri-hilar lymphadenopathy.

Table 4
Presence and location of lymphadenopathy on chest radiography (CXR) according to human immunodeficiency virus (HIV) and nutritional status categories.

Variable	Overall	HIV status (n=130)			Nutritional status (n=113)		
		Positive	Negative	p-Value	Adequately nourished	Underweight for age	p-Value
Total	N (%) n=130	n (%) n=35	n (%) n=95		n (%) n=74	n (%) n=39	
Overall lymph adenopathy	42 (32.3)	11 (31.4)	31 (32.6)	>0.99	29 (39.2)	12 (30.8)	0.38
Perihilar lymphadenopathy	33 (25.4)	8 (22.9)	25 (26.3)	0.82	23 (31.1)	9 (23.1)	0.41
Subcarinal lymphadenopathy	6 (4.6)	1 (2.9)	5 (5.3)	>0.99	5 (6.8)	1 (2.6)	0.41
Paratracheal lymphadenopathy	22 (16.9)	7 (20)	15 (15.8)	0.60	16 (21.6)	6 (15.4)	0.34

Table 5
Underweight for age children with pulmonary tuberculosis by healthcare site, sex and human immunodeficiency virus (HIV) status.

Variable	Category	Underweight for age	Adequately nourished	p-Value (effect size)
		No. of patients, n=39 (%)	No. of patients, n=74 (%)	
Healthcare site	Primary healthcare centre	1 (2.6)	18 (24.3)	0.004[a]
	Hospital	38 (97.4)	56 (75.7)	
Sex	F	11 (28.2)	32 (43.2)	0.046[a]
	M	28 (71.8)	42 (56.8)	
HIV status	Positive	17 (43.6)	14 (18.9)	0.008[b] (phi = 0.26[c])
	Negative	22 (56.4)	60 (81.1)	

[a] Cochran–Mantel–Haenszel test.
[b] Fisher's exact test.
[c] Weak association.

other studies of CXR findings of PTB in HIV-positive and HIV-negative children. As shown on this table, the current study is the most comprehensive of these, where comparative studies are missing radiology data or microbiological confirmation.

Most children in the present study (84.6%) were hospitalised, implying that they had severe illness. This may have contributed to the most common CXR finding in both HIV-positive (60%) and HIV-negative (60%) children being airspace consolidation. This is also consistent with prior studies that have reported this in 26%[25] to 61%[26] of patients; however, another South African study reported that bronchial wall thickening was the commonest CXR finding in HIV-infected children,[18] but this study had a younger population (median age 23.4 months, IQR 11.1–47.4) and only 13.9 % of patients had confirmed PTB.

The current study showed that miliary and nodular infiltration, cavitation, hyperinflation, volume loss, or perihilar streakiness were uncommon CXR findings regardless of HIV or nutritional status. In a study from Thailand of 93 children with PTB and known HIV status, 2% of patients in the HIV infected group demonstrated miliary infiltration and none had evidence of cavitation. In the HIV-uninfected group, only 2.4% showed cavitation. There was also no statistically significant difference in radiological findings by HIV status.[8] These findings confirm that cavitation is not a common feature of primary TB but is usually seen in teenagers and adults as part of the post-primary spectrum, which includes re-infection and re-activation.[27] The present patient population was young with a median age of 46 months. The frequency of cavitation on CXR in children with PTB, varies greatly in the literature, from as low as 2.5%–22%,[24,26] consistent with the current study, which found cavitation in only 10% (13 patients) and mostly in an older age group.

Lymphadenopathy is a common finding in children with PTB. The current study showed no statistically significant associations between HIV status or nutritional status and the presence of lymphadenopathy on radiographs. Lymphadenopathy was more likely to be located in the perihilar region. Other studies support this finding that hilar and mediastinal lymphadenopathy is common in PTB patients with prior studies reporting a frequency as high as 70–80% for perihilar adenopathy.[25,26] All patients in those studies comprised hospitalised children with proven TB but unknown HIV status and nutritional status. To the authors' knowledge, no study has shown a difference in the prevalence of lymphadenopathy by HIV status, consistent with the present study.

Pleural effusion was the only CXR finding found as a differentiating feature between the adequately nourished and the underweight-for-age group, present in 12% of adequately nourished and none of poorly nourished children. Pleural effusion often is a hypersensitivity reaction, so poorly nourished children may have immune impairment that limits this immune response, as occurs with a falsely negative tuberculin skin test. The current study confirmed the co-existence of PTB, HIV, and malnutrition. Out of all TB patients who were underweight-for-age (n=39) and those who were HIV-positive (n=35), a proportion of TB patients with both HIV and underweight-for-age was 17/74 (23%). The co-existence of TB, HIV, and malnutrition has been well described by prior studies[11,21,23,24] and is associated with a worse outcome.

Table 6
Comparison of this study with other studies comparing chest radiographs (CXRs) of human immunodeficiency virus (HIV)-infected and HIV-uninfected children with pulmonary tuberculosis (PTB).

	Current study South Africa	Srinakarin, J. *et al.* 2012 (8) Thailand	Soeters, M. *et al.* 2005 (24) South Africa	Schaaf, HS 2007 (20) South Africa	Madhi, S. *et al.* 2000 (11) South Africa	Iriso, R. 2005 (21) Uganda	Kiwanuka 2002 (22) Uganda	Palme, I.B. 2002 (23) Ethiopia
Age (months)	2–156	4–144	<180	<156	2–144	2–60	≤168	0–168
Mean/median (months)	52.8/45.6	86.4 (mean)	25.2 (median)	31 (median)	12.5 (HIV+) and 20 (HIV−) (median)	25.5 (mean)	36 (median)	Not stated
Patients:	130	93: Mostly outpatients	238	596	98[a]	126	88[a]	517 (234[a] with PTB)
Inpatient (HIV+/HIV −/unknown)	110		All	All	All in-patients	All in-patients	All in-patients	72 (Not specified)
Outpatient (HIV+/ HIV−)	20 (4/16)		None	None				445 (Not specified)
TB diagnosis	All confirmed TB by culture and PCR	Mainly clinically and radiologically proven TB	Biochemically proven (52%) Clinically suspected (48%)	Culture Proven TB	Clinical, radiological and Microbiological	Clinical, radiological and microbiological Culture-proven=36 (28.6%)	Clinical, radiological and microbiological	Mainly clinically. (190 culture-positive)
HIV status:								
HIV+	35 (27%)	52 (56%)	43 (18%)	133 (22%)	39[a] (39.8%)	62 (49%)	43[a] (49%)	28[a] (48%) with PTB
HIV−	95 (73%)	41 (44%)	95 (40%)	281 (47.1%)	59[a] (60.2%)	64 (51%)	45[a] (51%)	206[a] (45%) with PTB
Not tested	0	0	100 (42%)	182 (30.5%)	0	0	0	0
Normal CXR:					Not stated	None	None	
HIV+	4 (11.4%)	None	3[a] (7%)	5 (4%)				3%
HIV	6 (6.3%)		14[a] (15%)	32 (11.7%)				18%
Lymphadenopathy (overall)	42[b] (32.3%)	Hilar/ mediastinal[b]	Mediastinal[b]	51.9%	Hilar adenopathy 46[a] (46.9%)	81/126 (64%)	Hilar adenopathy 53[a](60.2)	Hilar adenopathy
HIV+	11[b] (31.4%)	17[b] (32.6%)	18[ab] (42%)	56.3%	17[a] (43.6 %)	44 (35%)	24[a] (56%)	10 (17%)
HIV	31[b] (32.6%)	13[b] (31.7%)	38[ab] (40%)	51.8%	29[a] (49.2%)	37 (29.4%)	29[a] (64%)	115 (25%)
Commonest site (HIV+/HIV-)	Perihilar 25% (23%/26%)	Not specified	Not specified	Perihilar 14.1% (36.5%/33.2%)	Not specified	Perihilar 35% (39%/ 31%)	Not specified	Not specified
Parenchymal changes	Airspace	Interstitial	Airspace consolidation	Airspace	Airspace consolidation	Airspace consolidation	Airspace consolidation	Not specified.
Total	78/130 (60%)	69/93 (74%)	56/138[a] (40.6%)	285 (51.4%)	54[a] (55.1%)	72 (57.1%)	47[a] (53.4%)	
HIV+	21/35 (60%)	39/52 (75%)	18/43[a] (41.9%)	128 (66.7%)	26[a] (66.7%)	37 (60%)	28[a] (65.1)	
HIV	57/95 (60%)	30/41 (73.1%)	38/95[a] (40%)	84 (46.7%)	28[a] (47.5%)	35 (55%)	19[a] (42.2)	
Airway compression (commonest site) n/%	Left main bronchus: 8 (6.2%)	Not stated	Not stated	Not stated	Not stated	Not stated	Not stated	Not stated.
HIV+	3 (8.6%)			17 (13.5 %)				
HIV	5 (5.3%)			54 (19.7%)				

PCR, polymerase chain reaction.
[a] Only patients with known HIV status, TB status and read CXR are tabulated here. Those with unknown HIV, TB status and CXR findings are not included in these calculations.
[b] Overall finding.

The study indicates that CXR abnormalities are very common in children with PTB irrespective of whether they are infected with HIV or not. This supports the use of CXR as a first-line investigation in all children with suspected PTB, and recent revised WHO recommendations that include the extent of chest radiological changes to define severity of TB and guide treatment (4 months for non-severe disease). Further research is needed to investigate longitudinal changes in chest radiology and time to resolution in children with PTB, given the increasing recognition of post-TB chronic lung disease.

Some of the limitations of the present include the study population being mainly hospitalised patients and that follow-up CXRs were not included in the assessment.

In conclusion, this study showed that radiological features in children with microbiologically confirmed PTB are similar in HIV-positive and HIV-negative children, with CXR abnormalities being common, occurring in >90% of children in both groups. More than 60% of patients demonstrated CXR features compatible with PTB. The commonest radiological abnormalities were airspace consolidation followed by hilar or mediastinal lymphadenopathy. Pleural effusion occurred only in adequately nourished patients.

Conflict of interest

The authors declare no conflict of interest.

Acknowledgements

The authors thank Petra Gaylard for her statistical input and feedback. Funding for the parent TB study was from the National Institutes of Health, USA (1R01HD058971-01), the Medical Research Council of South Africa, the National Research Foundation (NRF) South Africa and the EDCTP (TB-NEAT; IP.2009.32040.009). For the current study, no financial support was received for the research, authorship and/or publication.

References

1. Moodley P, Parboosing R, Moodley D. Reduction in perinatal HIV infections in KwaZulu-Natal, South Africa, in the era of more effective prevention of mother to child transmission interventions (2004-2012). *J Acquir Immune Defic Syndr* 2013;**63**(3):410–5. https://doi.org/10.1097/QAI.0b013e3182926931.
2. Tudor Car L, Van Velthoven MHMMT, Brusamento S, *et al.* Integrating prevention of mother-to-child HIV transmission programs to improve uptake: a systematic review. *PLoS One* 2012;**7**(4):e35268, https://doi.org/10.1371/journal.pone.0035268.
3. WHO. *Updated recommendations on HIV prevention, infant diagnosis, antiretroviral initiation and monitoring: March 2021.* Geneva: World Health Organization; 2021.
4. Simon AK, Hollander GA, McMichael A. Evolution of the immune system in humans from infancy to old age. *Proc Biol Sci* 2015;**282**(1821):20143085, https://doi.org/10.1098/rspb.2014.3085.
5. Cohen C, Walaza S, Moyes J, *et al.* Epidemiology of viral-associated acute lower respiratory tract infection among children <5 years of age in a high HIV prevalence setting, South Africa, 2009–2012. *Pediatr Infect Dis J* 2015;**34**(1):66–72. https://doi.org/10.1097/INF.0000000000000478.
6. WHO. Global tuberculosis report 2022. https://www-who-int.proxy.library.upenn.edu/teams/global-tuberculosis-programme/tb-reports/global-tuberculosis-report-2022. [Accessed 3 November 2022].
7. Zar HJ, Connell TG, Nicol M. Diagnosis of pulmonary tuberculosis in children: new advances. *Expert Rev Anti Infect Ther* 2010;**8**(3):277–88. https://doi.org/10.1586/eri.10.9.
8. Srinakarin J, Roongpittayanon N, Teeratakulpisarn J, *et al.* Comparison between the radiographic findings in pulmonary tuberculosis of children with or without HIV infection. *J Med Assoc Thai* 2012;**95**(6):802–8.
9. Connell TG, Zar HJ, Nicol MP. Advances in the diagnosis of pulmonary tuberculosis in HIV-infected and HIV-uninfected children. *J Infect Dis* 2011;**204**(Suppl 4):S1151–8. https://doi.org/10.1093/infdis/jir413.
10. Zar HJ, Workman L, Isaacs W, *et al.* Rapid molecular diagnosis of pulmonary tuberculosis in children using nasopharyngeal specimens. *Clin Infect Dis* 2012;**55**(8):1088–95. https://doi.org/10.1093/cid/cis598.
11. Madhi SA, Huebner RE, Doedens L, *et al.* HIV-1 co-infection in children hospitalised with tuberculosis in South Africa. *Int J Tuberc Lung Dis* 2000;**4**(5):448–54.
12. Nicol MP, Workman L, Isaacs W, *et al.* Accuracy of the Xpert MTB/RIF test for the diagnosis of pulmonary tuberculosis in children admitted to hospital in Cape Town, South Africa: a descriptive study. *Lancet Infect Dis* 2011;**11**(11):819–24. https://doi.org/10.1016/S1473-3099(11)70167-0.
13. Graham SM, Ahmed T, Amanullah F, *et al.* Evaluation of tuberculosis diagnostics in children: 1. Proposed clinical case definitions for classification of intrathoracic tuberculosis disease. Consensus from an expert panel. *J Infect Dis* 2012;**205**(Suppl 2):S199–208. https://doi.org/10.1093/infdis/jis008.
14. WHO. Global tuberculosis report 2013. https://www.who.int/publications-detail-redirect/9789241564656. [Accessed 12 December 2020].
15. WHO. Guidance for national tuberculosis programmes on the management of tuberculosis in children, 2nd edn. Availablt at: https://www-who-int.proxy.library.upenn.edu/publications/i/item/9789241548748. [Accessed 29 September 2022].
16. Sharma SK, Mohan A, Kadhiravan T. HIV-TB co-infection: epidemiology, diagnosis & management. *Indian J Med Res* 2005;**121**(4):550–67.
17. WHO. *WHO consolidated guidelines on tuberculosis: module 5: management of tuberculosis in children and adolescents*. Geneva: World Health Organization; 2022.
18. Pitcher RD, Lombard C, Cotton MF, *et al.* Clinical and immunological correlates of chest X-ray abnormalities in HIV-infected South African children with limited access to anti-retroviral therapy. *Pediatr Pulmonol* 2014;**49**(6):581–8. https://doi.org/10.1002/ppul.22840.
19. Du Plessis V, Andronikou S, Struck G, *et al.* Baseline chest radiographic features of HIV-infected children eligible for antiretroviral therapy. *S Afr Med J* 2011;**101**(11):829–34.
20. Schaaf HS, Marais BJ, Whitelaw A, *et al.* Culture-confirmed childhood tuberculosis in Cape Town, South Africa: a review of 596 cases. *BMC Infect Dis* 2007;**7**:140. https://doi.org/10.1186/1471-2334-7-140.
21. Iriso R, Mudido PM, Karamagi C, *et al.* The diagnosis of childhood tuberculosis in an HIV-endemic setting and the use of induced sputum. *Int J Tuberc Lung Dis* 2005;**9**(7):716–26.
22. Kiwanuka JP. Tuberculosis in children at Mbarara University teaching hospital, Uganda: diagnosis and outcome of treatment. *Afr Health Sci* 2002;**2**(3):82–8.
23. Palme IB, Gudetta B, Bruchfeld J, *et al.* Impact of human immunodeficiency virus 1 infection on clinical presentation, treatment outcome and survival in a cohort of Ethiopian children with tuberculosis. *Pediatr Infect Dis J* 2002;**21**(11):1053–61. https://doi.org/10.1097/00006454-200211000-00016.
24. Soeters M, de Vries AM, Kimpen JLL, *et al.* Clinical features and outcome in children admitted to a TB hospital in the Western Cape—the influence of HIV infection and drug resistance. *S Afr Med J* 2005;**95**(8):602–6.
25. Boloursaz MR, Khalilzadeh S, Baghaie N, *et al.* Radiologic manifestation of pulmonary tuberculosis in children admitted in pediatric ward-Massih Daneshvari Hospital: a 5-year retrospective study. *Acta Med Iran* 2010;**48**(4):244–9.
26. Milković D, Richter D, Zoricić-Letoja I, *et al.* Chest radiography findings in primary pulmonary tuberculosis in children. *Coll Antropol* 2005;**29**(1):271–6.
27. Burrill J, Williams CJ, Bain G, *et al.* Tuberculosis: a radiologic review. *RadioGraphics* 2007;**27**(5):1255–73. https://doi.org/10.1148/rg.275065176.