

https://dspace.org/

Recurrent testicular torsion post orchidopexy: an occult emergency - a systematic review

van Welie, Mikayla

2022

https://hdl.handle.net/10539/34477

Downloaded from a DSpace repository. https://dspace.org/

RECURRENT TESTICULAR TORSION POST ORCHIDOPEXY: AN OCCULT EMERGENCY – A SYSTEMATIC REVIEW

Mikayla van Welie

Student Number: 722387

A Research Report submitted to the Faculty of Health of the University of the Witwatersrand, Johannesburg, in partial fulfilment of the requirements for the degree of Master of Science in Medicine

Johannesburg, 7 April 2022

DECLARATION

I, Mikayla van Welie, hereby declare that this research report is my own work and has not been submitted or presented for any other degree or professional qualification at this or any other institute. This research was undertaken in the Division of Emergency Medicine, University of the Witwatersrand, Johannesburg.

Signature of Student:  Date: 7 April 2022

Name of Supervisor 1: Prof A Laher

Signature of Supervisor 1:  Date: 7 April 2022

Name of Supervisor 2: Prof A Adam

Signature of Supervisor 2:  Date: 7 April 2022

Name of Supervisor 3: Dr L Qu

Signature of Supervisor 3:  Date: 7 April 2022

ACKNOWLEDGMENTS

I would like to express my sincere gratitude to:

My family and friends for their ongoing support, guidance, and encouragement.

My supervisors, Prof Abdullah Laher, Prof Ahmed Adam and Dr Liang Qu for their continual support, guidance, time, patience, dedication, and endless motivation.

SUBMISSION FORMAT OF THIS RESEARCH REPORT

As per the University of Witwatersrand Faculty of Health Sciences guidelines, this research report is being submitted in the following format: submission for publication ready format.

TABLE OF CONTENTS

DECLARATION…… i

ACKNOWLEDGMENTS…….. ii

SUBMISSION FORMAT OF THIS RESEARCH REPORT……. iii

MAUSCRIPT…….. 6

ABSTRACT……..... 11

INTRODUCTION…….. 13

METHODOLOGY……. 14

RESULTS……... 16

DISCUSSION……. 21

CONCLUSION……... 24

REFERENCES…… 24

FIGURES/TABLE LEGEND……. 29

FIGURES……...……. 30

TABLES……. 33

RESEACH PROTOCOL……. 45

ETHICS WAIVER ……. 62

TURN-IT-IN REPORT …….. 63

MANUSCRIPT

TITLE OF MANUSCRIPT

Recurrent testicular torsion post orchidopexy: an occult emergency – a systematic review

RUNNING TITLE

Recurrent testicular torsion – a systematic review

TYPE OF ARTICLE

Systematic review

AUTHORS AND AFFILIATIONS

Mikayla van Welie[1]; BHSc (EMC); mik.van.welie@gmail.com

Liang G Qu[2]**,** MBBS (Hons), BMedSc (Hons); liang.qu@austin.org.au

Ahmed Adam[3]**,** MBBCh, MMed, FCUrol, DipLapSurg, DipPEC; aadam81@gmail.com

Nathan Lawrentschuk[4]**,** MBBS, PhD, FRACS; lawrentschuk@gmail.com

Abdullah E Laher[1]; MBBCh, MMed, PhD, FCEM, Cert Critical Care, EDIC, DipPEC, DCH, DipAllerg, DipHIVMan; abdullahlaher@msn.com

[1] Department of Emergency Medicine, Faculty of Health Sciences, University of the Witwatersrand, Johannesburg, South Africa

[2]Department of Urology, Olivia Newton John Cancer Research Institute, Austin Health, Heidelberg, Victoria, Australia

[3] Division of Urology, Faculty of Health Sciences, University of the Witwatersrand, Johannesburg, South Africa

[4]Department of Urology, Royal Melbourne Hospital, Melbourne, Victoria, Australia

CORRESPONDING AUTHOR

Mikayla van Welie, Department of Emergency Medicine, Faculty of Health Sciences, University of the Witwatersrand, 7 Jubilee Road, Parktown, Johannesburg, 2193, South Africa; e mail: mik.van.welie@gmail.com

WORD COUNTS, FIGURES AND TABLES

Abstract: 250

Manuscript: 2904

Figures: 2

Tables: 4

AUTHOR CONTRIBUTIONS

MVW: Guarantor of the manuscript, contributed to the study concept and design, data collection, drafting, writing and review of the manuscript, incorporating co-author feedback, revision and final approval of the manuscript.

AA, LQ, NL & AL: Contributed to the study concept and design, responsible for the integrity, interpretation of the data, drafting, writing, and review of the manuscript and approval of the submission.

CONFLICTS OF INTEREST

The authors hereby certify that this submission is not under publication consideration elsewhere and is free from any conflict of interest.

FUNDING

None

COVER LETTER

Dear Editor – ANZ J Surg

Thank you for considering our systematic review manuscript entitled: "**Recurrent testicular torsion post orchidopexy: an occult emergency – a systematic review**"

Recurrent testicular torsion (RTT) following previous surgical exploration and management of TT is a rarely reported event. Patients may present to the ED with acute testicular pain, nausea, vomiting, a history of prior TT and a history of prior scrotal surgery. Previous testicular surgery does not guarantee permanent fixation of the testis, even after bilateral orchidopexy. Failure to consider the rare possibility of RTT may delay diagnosis and result in testicular loss.

There is a paucity of data pertaining to the presentation, diagnosis, risk factors, management, and outcomes of RTT post orchidopexy. To determine this, a comprehensive literature review was performed using the current body of literature.

We are certain that this review will appeal to the readership of "**ANZ J Surg**" Journal. Furthermore, it carries a high citation potential, as it is applicable to those in the fields of Urology, Emergency Medicine and family Medicine.

CORRESPONDING AUTHOR

Mikayla van Welie

Department of Emergency Medicine, Faculty of Health Sciences, University of the Witwatersrand, 7 Jubilee Road, Parktown, Johannesburg, 2193, South Africa

e mail: mik.van.welie@gmail.com

Recurrent testicular torsion post orchidopexy: an occult emergency – a systematic review

ABSTRACT

Background: Recurrent Testicular Torsion (RTT) is a rarely reported event after previous testicular torsion (TT) repair. Both conditions have similar signs and symptoms. Various techniques have been attempted to reduce the incidence of retorsion. This review assesses the presentation, diagnosis, risk factors, management and outcomes associated with RTT.

Methods: After PROSPERO Registration (CRD42021258997), a systematic search of PubMed, Google Scholar, Embase, Scopus, Web of Science, Cochrane Database of Systematic Reviews, Global Index Medicus and Cumulative Index to Nursing and Allied Health Literature (CIANHL) was performed using specific search terms. Study metadata including patient demographics, orchidopexy techniques, RTT rates and RTT timing were extracted.

Results: Twenty-six articles, comprising 12 case series and 14 case reports, with a total of 46 patients were included. Overall, the median (IQR) age of the pooled cohort was 18 (15-26) years, the median (IQR) time to presentation was 6 (3-36) hours from the onset of testicular pain. The most common presenting features were testicular pain (100%), testicular swelling (60.9%) and a high riding testicle (34.8%). The left testicle was most commonly affected (63.0%), RTT was on the ipsilateral side in relation to the primary episode of TT in 52.2% of cases, the median (IQR) interval between torsion and retorsion events was 4 (1.3-10.0) years, non-absorbable sutures were the most common suture material used during orchidopexy after RTT (88.9%).

Conclusion: RTT is a rare presentation to the Emergency Department. Recurrent testicular torsion should be considered in patients presenting with classic symptoms, even with a prior history of TT.

PROSPERO Registration: CRD42021258997

Keywords: recurrent testicular torsion; RTT; testicular torsion; TT; spermatic cord torsion; recurrence; testis torsion; acute scrotum

INTRODUCTION

Testicular torsion (TT) is a urological emergency that commonly presents to the emergency department (ED). It occurs as a result of rotation of the testis around the spermatic cord, thereby compromising testicular blood flow and resulting in irreversible ischemic testicular damage.[1,2] Timeous surgical exploration is required to untwist the ischemic testicle and thereafter fixate it (orchidopexy) to prevent retorsion. Since the contralateral testis is also predisposed to torsion, it is generally also fixated during the same procedure.[3]

Recurrent testicular torsion (RTT) following previous surgical exploration and management of TT is a rarely reported event.[4] Patients may present to the ED with acute testicular pain, nausea, vomiting, a high riding testicle, a history of prior TT and a history of prior scrotal surgery.[5] When the diagnosis of RTT is suspected, urgent surgical re-exploration should be considered to prevent potential testicular loss.[3] Hence, a history of previous testicular exploration should not exclude RTT as a diagnosis.

Various techniques have been described to reduce the incidence of testicular retorsion.[5] The surgical technique used during the initial exploration as well as the suture type used have been linked to the cause of orchidopexy failure.[4] Various studies have reported that RTT is more common when absorbable sutures were used during initial orchidopexy, leaving the affected testis to lose its attachments to the scrotal wall.[3] Moreover, complications following a second orchidopexy, such as testicular atrophy, infertility, and chronic pain have not been explored in the literature.

Overall, there is a paucity of data pertaining to the presentation, diagnosis, risk factors, management, and outcomes of RTT post orchidopexy for TT. Therefore, a comprehensive literature review was performed using the current body of literature.

METHODS

Search strategy

This systematic review was registered on the PROSPERO database (CRD42021258997) prior to commencement of the search. A search strategy was conducted in October 2021 using the following databases: PubMed, Google Scholar, Embase, Scopus, Web of Science, Cochrane Database of Systematic Reviews, Global Index Medicus and Cumulative Index to Nursing and Allied Health Literature (CIANHL). The following search terms were used: ‘recurrent testicular torsion’ OR ‘spermatic cord torsion’ AND (‘torsion’ OR ‘failure’ OR ‘recurrent’ OR ‘re-operation’ OR ‘treatment’). All citations retrieved from the various papers were analysed for additional relevant resources. The search was restricted to publications within the medical literature. No language restrictions were applied.

Study selection

Studies included in the review met the following criteria: i) the studies were clinical publications, ii) limited to human studies and iii) included full study text. All publications relating to the topic, including correspondence and letters to the editors were eligible for inclusion. Exclusion criteria included: i) studies that were found as a result of keyword matching or tags but are obviously irrelevant to the study topic, ii) full text articles not available and iii) articles pertaining to the first occurrence of TT, rather than RTT.

Review study definition of recurrent testicular torsion

For the purpose of this systematic review, recurrent testicular torsion was defined as a representation of testicular torsion following previous orchidopexy.

Data extraction and methodological evaluation

The Preferred Reporting Items for Systematic Reviews and Meta-analyses (PRISMA) guidelines were applied to guide the electronic search.[6] Articles fitting the eligibility criteria were screened by two independent reviewers (MVW & LQ), based on the inclusion criteria described above, a descriptive narrative of each study was compiled by the reviewers. Conflicting entries, disagreements and differences were resolved by seeking opinions from a third reviewers (AA). The points of interest in each study were tabulated. These included the study origin, age range of the study population, sample size, time from symptom onset to presentation, duration between episodes of torsion, signs and symptoms of RTT, tool used to diagnose RTT, degree of torsion rotation, surgical techniques used, suture materials and number of sutures used, comments on previous orchidopexy, complications, and recommendations.

Data synthesis

The outcomes reported from this systematic review were summary data pertaining to the clinical features of RTT, the diagnostic pathway of RTT, the common surgical techniques used for surgical exploration of RTT, and an overview of complications. Given the anticipated heterogeneity in reported data across studies, a narrative synthesis was primarily utilised outlining the range of techniques described. Descriptive summary statistics included the median and interquartile range (IQR) of the reported values for baseline variables such as age, time to presentation, interval between torsion and retorsion, degree of torsion and number of sutures. Other data including surgical techniques were tabulated and described.

Assessment of methodological quality of included articles

All studies that met the inclusion criteria were either case reports or case series. The methodological quality of the included articles were assessed using the tool proposed by Murad et al.[7] The tool comprises four domains with a total of eight questions (figure 1). Since questions 5 and 6 were not relevant to our study as they predominantly relate to drug reactions, these were removed. The overall methodological quality of each of the included articles was described as either low quality, intermediate quality, or high quality. High quality was defined as a "yes" answer to 4 or more of the included questions, while intermediate quality was defined as a "yes" answer to 3 of the included questions and low quality was defined as a "yes" answer to fewer than 3 of the included questions (table 1).

RESULTS

Search

The electronic database search yielded 930 titles with the following breakdown: PubMed (662), Google Scholar (125), Embase (90), Scopus (26), Web of Science (eight), Cochrane Database of Systematic Reviews (eight), Global Index Medicus (six) and CIANHL (five). Of these, 865 titles were excluded (305 duplicates and 560 irrelevant to the topic). A further 12 were removed after abstract review. The remaining 53 articles were fully reviewed, of which 26 articles were selected for inclusion in this systematic review. Details of the above are described in figure 2.

Study metadata

The 26 included articles[8–33] comprised 12 case series[8–11,20,27–33] and 14 case reports,[12–19,21–26] with a total of 46 patients with RTT. The largest of the case series included five subjects.[28]

The methodological quality of each of the included articles is described in table 1. A total of 11 (42.3%) studies were ranked as high quality,[9–11,18,20,24,27–29,32,33] seven (26.9%) as intermediate quality[8,13,17,19,21–23] and 8 (30.1%) as low quality.[12,14–16,25,26,30,31] Details of the included articles are described in tables 2, 3 and 4.

Definition of RTT among the included studies

In general, the included articles all alluded to the definition of RTT as a recurrence of testicular torsion following previous orchidopexy.

Region of publication of included articles

Among the included articles, 10 (38.5%) emanated from the USA,[8,9,13–20] five (19.2%) from the UK,[21,22,27–29] two (7.7%) each from Ireland,[23,33] Denmark,[31,32] and Germany[26,30] and one (3.8%) each from New Zealand,[24] Israel,[11] the Netherlands,[10] France[25] and Qatar,[12]

Age range of study subjects

The age range of all included subjects ranged from 5-35 years. The median (IQR) age of the pooled cohort was 18 (15-26) years. Approximately three-quarter of the pooled subjects (n=34, 73.9%) were younger than 25 years of age.[8–11,13–17,19–24,26–30]

Time to ED presentation from presumed onset of RTT

Among the 36 (78.3%) cases in whom time to ED presentation from the presumed onset of RTT was reported, the median (IQR) time was 6 (3-36) hours after the onset of testicular pain.[8–12,14–33]

Presenting features of RTT

The most common signs and symptoms on RTT were testicular pain (n=46, 100%),[8–33] testicular swelling (n=28, 60.9%),[8,10,12,14,16,18,20–23,27–30,33] a riding high testicle (n=16, 34.8%),[9,13,16–19,21,23,28,29,31–33] testicular redness (n=8, 17.4%),[8,10,14,16,21,27,28,30] nausea and/ or vomiting (n=7, 15.2%)[13,15,19,26–28,31] and abdominal pain (n=2, 4.4%).[19,28]

Affected side of TT and RTT

At the initial presentation of TT, the right testicle was more commonly affected (n=26, 56.5%),[8–11,14,15,17,20,22,25,26,28,30] whereas at the recurrent presentation, the left testicle was more commonly affected (n=29, 63.0%).[8–15,17,19,20,22–26,28–32] Overall, RTT was on the ipsilateral side in 24 (52.2%) cases [8–10,12,13,19,21,23,24,27–31,33] and on the contralateral side in 22 (47.8%) cases.[8–10,14–18,20,22,25,26,28,30,32,33]

Interval between initial TT and RTT episodes

Among the 45 (97.8%) cases[8–33] in whom the interval between torsion and retorsion episodes was reported, the median (IQR) interval was 4 (1.3-10.0) years, with the shortest duration being 6 months[11] and the longest 27 years.[29]

Degree of torsion at RTT episode

Among the 26 (56.5%) cases[8,10,11,14–21,25,26,28–33] in whom the rotational degree of RTT was reported, the median (IQR) degree of rotation of the testis was 360 (360-720) degrees, with the largest degree of torsion being 1080 degrees (i.e. a twist torsion of three rotations).[30]

Diagnostic modality utilised to diagnose RTT

Physical examination was most frequently relied upon as the sole means of diagnosing RTT in 32 (69.5%)[8–11,13–16,20,21,23,24,27–33] cases. Doppler ultrasound was performed in 13 (28%)

cases,[9,10,12,17–20,22,25,26,30,32] while a testicular nuclear scan was performed in five (10.8%) cases.[9,13,17,20] Eleven (23.9%) cases were misdiagnosed, of which seven (15.2%) were misdiagnosed as epididymitis[8,12,15,16,25,30,31] and one (2.2%) as spermatic cord neuralgia.[30]

Surgical technique utilised for TT and RTT

The surgical techniques used during the index episode of TT was only described in 24 (52.8%) cases. Of these, in eight (17.4%) cases, the authors simply reported that the testes were fixed bilaterally,[9–11,17,28] while a dartos pouch fixation (either to the tunica albuginea or tunica vaginalis) was described in nine (19.6%) cases,[16,18,20,28,30,33] and the tunica albuginea was described to be fixed either to the parietal tunica vaginalis (n=2, 4.4%),[31] visceral tunica vaginalis (n=1, 2.2%)[10] or to the scrotum itself (n=2, 4.4%) in another five cases.[8,24] Two other authors describe unusual techniques for fixation as fixed to the thigh (n=1, 2.2%)[28] and pexed transeptally (n=1, 2.2%).[17]

The surgical techniques used during RTT was only described in 26 cases (56.5%). In seven (15.2%) cases, the authors simply reported that the testes were fixed bilaterally.[9,29,33] In another seven cases it was described as fixation of the testes to the dartos (n=5, 10.9%),[31,32] scrotal wall (n=1, 2.2%)[12] and tunica vaginalis (n=1, 2.2%),[28] in four cases it was described as fixation of the tunica albuginea to the scrotal wall (n=2, 4.4%),[8,24] the septum (n=1, 2.2%)[18] and the tunica vaginalis (n=1, 2.2%),[33] while in eight (17.4%) cases,[10,27,28] Jaboulay's technique (external eversion of the tunica vaginalis with suturing of the free edges posterior to the spermatic cord)[34] was used.

Type and number of sutures used

Of the 25 cases in which the suture type for initial presentation of TT was reported, absorbable sutures were used in 21 (84.0%) cases, with a median (IQR) of 2 (1-3) sutures used per case.[8–10,14,16,20–22,24,27,28,31,33] Of the 18 cases in which the suture type for RTT was reported, non-absorbable sutures were used in 16 (88.9%) cases with a median (IQR) of 3 (2-3) sutures used per case.[9,11,17–21,24,26,28] Overall, the most widely used absorbable suture was chromic catgut (n=11, 23.9%).[8,9,14,16,20,24,28,33] None of the studies specified the suture type for non-absorbable sutures.

Complications post RTT

In 20 (43.5%) cases, no mention was made as to the presence or absence of any complications.[9,10,29–33,11,13,14,18,19,21,23,28] In a further 12 (26.1%) cases, the authors reported that there were no complications.[8,17,22,24,27,28] Among the 14 (30.4%) cases where complications were reported, 10 (21.8%) underwent orchidectomy,[8,10,12,16,20,25,26,28] three (6.5%) developed testicular atrophy[15,27,30] and one (2.2%) had prolonged testicular swelling.[28] Only one (2.2%) study reported low sperm count in a patient that underwent orchidectomy post RTT.[28]

Recommendations

Twenty-four of the twenty-six (92.3%) authors included in this review concurred that the preferred method of treatment was to concurrently fixate both testes on initial presentation of TT.[8–25,27–29,31–33] The use of non-absorbable sutures for fixation of initial TT was recommended by 14 (53.8%) authors,[9,11,12,14,16,18–21,24,25,28,29,31] while four (8.7%) authors recommended the use of three sutures sites[16,19,22,28] and six (23.1%) authors recommended Jaboulay's procedure.[8,10,11,18,28,29]

DISCUSSION

The incidence of RTT is probably higher than the literature would indicate.[35] Previous testicular surgery does not guarantee permanent fixation of the testis, even after bilateral orchidopexy.[31] Failure to consider the rare possibility of RTT may delay the diagnosis and result in testicular loss.[18]

The clinical diagnosis of RTT can be difficult due to the presence of non-specific clinical signs and symptoms. Common symptoms, as shown in this review, include testicular pain, swelling, redness, nausea, vomiting and a high-riding testicle. These symptoms are almost identical to TT.[36] Patients who present with these symptoms were mostly younger than 25 years of age. This systematic review indicates that right testicle was more commonly involved during the initial presentation (56.5%), while the left testicle was more commonly involved in the recurrent episode (63.0%) and all patients had bilateral fixation at initial presentation of TT as well as at the recurrent episode. The bell-clapper deformity is often found in patients who present with RTT. It is thought that patients who have the bell-clapper deformity are at higher risk of torsion as there is increased mobility of the testicle within the tunica vaginalis.[37]

RTT presents with similar symptoms to TT, which can confuse and delay the diagnosis. If symptoms are equivocal, colour Doppler Ultrasound (US) has been shown to assist with confirming the diagnosis.[38] The use of Doppler US is the favoured diagnostic modality to assess testicular blood flow, as it provides a non-invasive view of the testes, is generally available at the bedside and can be performed rapidly.[39] The use of US has a diagnostic accuracy of 95% in testicular torsion, similar to that achieved with radionuclear testicular scanning.[40] When considering the diagnosis of RTT, physical exam findings are just as

important to assess as they effectively guide diagnosis.[41] The most definitive way to diagnose RTT is through surgical exploration. Surgical exploration should not be delayed, as this may lead to worsening ischemia and potential testicular loss.[1,35]

Techniques to fixate the testes after torsion has shifted over the years. Suture types have changed and gained and lost favour amongst physicians. It was initially thought that absorbable sutures would be better, as it was assumed that a dense inflammatory response would limit rotational movement of the testis once the sutures had dissolved.[4] However, various studies note that only fine adhesions form at the suture site, allowing potential retorsion to occur.[8,9,14,24,27,28] The widespread use of absorbable sutures in initial TT may also be related to standard recommendations in urological educational resources.[3] It was only in 1992 that the recommended suture type was changed to non-absorbable sutures. Within this review, only one case was reported using absorbable sutures after 1992.[10] Many authors have advocated for the use of non-absorbable sutures in the fixation of the testes. Among the reported cases, 89% used non-absorbable sutures.[9,11,17–21,24,26,28] The shift in suture type used, however, did not prevent retorsion. Despite the use of non-absorbable sutures at the initial presentation of TT, the occurrence of RTT was still reported.[17–19,30] The mechanism for torsion is therefore unclear, with little consensus among authors.

Surgical fixation techniques have also changed over the years. The tunica albuginea can be fixed to the scrotal wall, septum or tunica vaginalis. [8,18,24,33] A recent systematic review looked at different surgical techniques for orchidopexy.[35] In this study, the authors attempted to find consensus amongst the various proposed techniques based on the available literature. There were several techniques presented, and it was reported that regardless of the technique used, there was no report of retortion in follow-up at 6-31 weeks. This may suggest that all

techniques were effective in the short term. It was noted, however, that there was a large degree of heterogeneity, high risk of bias and poor reporting of outcomes in the included studies. Moore et al advise the need for an interim consensus until a randomised control trial can be conducted to determine the safest technique.[35]

Most authors agreed that both testes should be fixed,[8–25,27–29,31–33] regardless of the previous diagnosis. The use of non-absorbable sutures, at three sites is recommended.[16,19,22,28] The fixation of the tunica albuginea to the dartos muscle, as well as eversion of the tunica albuginea, has been shown, at least in the current available literature, to prevent retorsion.[42] It must be noted, however, that there is currently no available literature on the third occurrence of torsion, which may be a consequence not yet reported. Current surgical technique recommendations include orchidopexy of both testes with non-absorbable sutures with fixing of the testes via the dartos pouch or directly to the dartos pouch.[5] Based on animal data, it is recommended to perform a dartos pouch placement to preserve fertility.[5]

The reporting of complications may be challenging with few included studies having looked at long term outcomes. The link between delayed diagnosis and poor testicular outcome has been briefly commented upon. Often, patients are misdiagnosed as having epididymitis with physicians dismissing the possibility of recurrent torsion due to previous orchidopexy, which may lead to potential delays in diagnosis, testicular loss and subsequent litigation.[43] Anderson et al. found that 89% of testes that underwent surgical intervention within 7-12 hours were salvaged and that these rates rapidly declined over time.[44] Less than 10% of testes were salvaged if the duration of torsion was greater than 24 hours. None of the case studies in this review that reported testicular pain of longer than 24 hours duration had testicular salvage.

The quality of the included studies was overall rated as low. This is due to all the included studies being case reports and case studies. This it in itself is a limitation as no multi-centre studies exist to determine accurate information regarding RTT. This is probably due to the fact that the incidence of RTT is incredibly rare, and the earliest description of this event takes place in the 1970s.[12] There is a need for larger studies to be done to further describe this condition.

CONCLUSION

The diagnosis of RTT is complicated by the rarity of the condition and undifferentiated presentation. A high index of suspicion is required in the detection of this surgical emergency, as cases have been reported to occur even as late as two decades after the primary TT repair. There is little consensus regarding the optimal fixation technique. Absolute predictors for RTT were not identified within this review. Future research is required to further characterise this uncommon emergency.

REFERENCES

1. Laher A, Ragavan S, Mehta P, Adam A. Testicular torsion in the emergency room: A review of detection and management strategies. Open Access Emerg Med. 2020;12:237–46.
2. Fujita N, Tambo M, Okegawa T, Higashihara E, Nutahara K. Distinguishing testicular torsion from torsion of the appendix testis by clinical features and signs in patients with acute scrotum. Res Reports Urol. 2017 Aug 28;9:169–74.
3. Mor Y, Pinthus JH, Nadu A, Raviv G, Golomb J, Winkler H, et al. Testicular fixation following torsion of the spermatic cord - Does it guarantee prevention of recurrent torsion events? J Urol. 2006;175(1):171–3.

4. Sells H, Moretti KL, Burfield GD. Recurrent torsion after previous testicular fixation. ANZ J Surg. 2002;72(1):46–8.
5. Hawksworth D, Khera M, Herati S. Surgery of the Scrotum and Seminal Vesicles. In: Partin AW, Dmochowski RR, Kavoussi LR, Peters CA, editors. Campbell-Walsh-Wein Urology. 12th ed. Elsevier; 2020. p. 8551–630.
6. Page MJ, McKenzie JE, Bossuyt PM, Boutron I, Hoffmann TC, Mulrow CD, et al. The PRISMA 2020 statement: An updated guideline for reporting systematic reviews. BMJ. 2021;372:n71.
7. Murad MH, Sultan S, Haffar S, Bazerbachi F. Methodological quality and synthesis of case series and case reports. Evid Based Med. 2018;23(2):60–3.
8. Johenning PW. Torsion of the previously operated testicle. J Urol. 1973;110(2):221–2.
9. McNellis DR, Rabinovitch HH. Repeat torsion of "fixed" testis. Urology. 1980 Nov;16(5):476–7.
10. de Vylder AMA, Breeuwsma AJ, van Driel MF, Fonteyne E, Nijman JM. Torsion of the spermatic cord after orchiopexy. J Pediatr Urol. 2006;2(5):497–9.
11. Gillon G, Livne P, Servadio C. Torsion of the testis following previous "fixation." Surg Infancy Child. 1986 Aug 25;41(04):246–7.
12. Alnadhari I, Abdulmuhsin A, Ali O, Shamsodini A, Salah M, Abdeljaleel O. Recurrent Testicular Torsion of a Fixed Testis. Case Rep Urol. 2019 Jul 15;1–3.
13. Morgan JA, Mellick LB. Testicular torsion following orchiopexy. Pediatr Emerg Care. 1986;2(4):244–6.
14. Redman JF, Walt Stallings J. Torsion of testicle following orchiopexy. Urology. 1980;16(5):502–3.
15. Kossow AS. Torsion following orchiopexy. N Y State J Med. 1980;June:1136.
16. Tawil EA, Gregory JG. Torsion of the contralateral testis 5 years after orchiopexy. J

Urol. 1984;132(4):766–7.

17. Hulecki SJ, Crawford JP, Broecker B. Testicular torsion after orchiopexy with nonabsorbable sutures. Urology. 1986;28(2):131–2.
18. Koochakzadeh S, Johnson K, Rich MA, Swana HS. Testicular torsion after previous surgical fixation. J Pediatr Surg Case Reports. 2019;47(April):101225.
19. Wang M, Bukavina L, Mishra K, Woo L, Ross J, Gnessin E. Testicular Torsion Postorchiopexy: A Case of Twisted Hammock. Urology. 2019;125:202–4.
20. Kuntze JR, Lowe P, Ahlering TE. Testicular torsion after orchiopexy. J Urol. 1985;134(6):1209–10.
21. Phillips JH. Torsion of testis following orchiopexy. Br J Urol. 1987;59(6):596.
22. Chinegwundoh F. Acute testicular torsion following testicular fixation. Br J Urol. 1995;76(2):268.
23. Naughton P, Kelly D. Torsion after previous orchiopexy. Br J Urol. 1983;55(5):578.
24. Vorstman B, Rothwell D. Spermatic cord torsion following previous surgical fixation. J Urol. 1982;128(4):823–4.
25. Van Glabeke E, Ferhi K, Maloum C. Torsion du cordon spermatique: Faut-il faire confiance à un antécédent d'orchidopexie ? À proposd'un cas ayant entraîné la perte d'un testicule unique avec conséquences médicolégales. Prog en Urol. 2010;20(9):657–9.
26. Blaut S, Steinbach F, Tittel B, Dürig E. Hodentorsion nach prophylaktischer orchidopexie. Aktuelle Urol. 2008;39(2):147–9.
27. May RE, Thomas WEG. Recurrent torsion of the testis following previous surgical fixation. Br J Surg. 1980;67(2):129–30.
28. Thurston A, Whitaker R. Torsion of testis after previous testicular surgery. Br J Surg. 1983;70(4):217.

29. Hurren JS, Corder AP. Acute testicular torsion following orchidopexy for undescended testis. Br J Surg. 1992;79(12):1292.

30. Von Zastrow C, Sotelino JA. Wiederauftretende hodentorsionen: Kann ein pexierter hoden torquieren? Urol - Ausgabe A. 2005;44(11):1337–40.

31. Steinbrüchel DA, Hansen MK. Testicular torsion after previous orchidopexy. Br J Surg. 1988 Dec 6;75(1):47.

32. Rasmussen JS. Contralateral testicular torsion after previous unilateral orchiopexy for undescended testis. Scand J Urol Nephrol. 1996;30(6):513–4.

33. O'Shaughnessy M, Walsh TN, Given HF. Testicular torsion following orchidopexy for undescended testis. Br J Surg. 1990;77(April):583.

34. Rowe NE, Martin P, Luke PP. The Western snip, stitch, and tug hydrocelectomy: How I do it. Can Urol Assoc J. 2016;10(9–10):E328–30.

35. Moore SL, Chebbout R, Cumberbatch M, Bondad J, Forster L, Hendry J, et al. Orchidopexy for testicular torsion: A systematic review of surgical technique. Eur Urol Focus. 2020;1–11.

36. Boettcher M, Krebs T, Bergholz R, Wenke K, Aronson D, Reinshagen K. Clinical and sonographic features predict testicular torsion in children: A prospective study. BJU Int. 2013;112(8):1201–6.

37. Sharp VJ, Kieran K, Arlen AM. Testicular torsion: diagnosis, evaluation, and management. Am Fam Physician. 2013;88(12):835–40.

38. Pearce I, Islam S, McIntyre IG, O'Flynn KJ. Suspected testicular torsion: a survey of clinical practice in North West England. J R Soc Med. 2002;95(5):247.

39. McDowall J, Adam A, Gerber L, Enyuma COA, Aigbodion SJ, Buchanan S, et al. The ultrasonographic "whirlpool sign" in testicular torsion: valuable tool or waste of valuable time? A systematic review and meta-analysis. Emerg Radiol.

2018;25(3):281–92.

40. Pepe P, Panella P, Pennisi M, Aragona F. Does color Doppler sonography improve the clinical assessment of patients with acute scrotum? Eur J Radiol. 2006;60(1):120–4.

41. Hyun GS. Testicular Torsion. Rev Urol. 2018;20(2):104–6.

42. Lent V, Viegas H. Die umwendungsorchidopexie zur rezidivprophylaxe einer hodentorsion. Urol - Ausgabe A. 2013;52(3):391–5.

43. Matteson JR, Stock JA, Hanna MK, Arnold T V, Nagler HM. Medicolegal aspects of testicular torsion. Urology. 2001 Apr;57(4):783–6.

44. Anderson JB, Williamson RCN. Testicular torsion in Bristol: A 25-year review. Br J Surg. 1988;75(10):988–92.

FIGURE LEGENDS

Figure 1: Tool for evaluating the methodological quality of case reports and case series (Figure obtained from Murad MH, Sultan S, Haffar S, Bazerbachi F. Methodological quality and synthesis of case series and case reports. Evid Based Med. 2018;23(2):60–3. doi: 10.1136/bmjebm-2017-110853.[7] Distributed under the terms of the Creative Commons Attributions 4.0 International License (http://creativecommons.org/licenses/by-nc/4.0/). No changes have been made to the figure or the figure description).

Figure 2: Study flow diagram

Figure 3: Black, torsed left testis attached with old stitch from lower pole to the side wall of scrotum (Image obtained from Alnadhari I, Abdulmuhsin A, Ali O, Shamsodini A, Salah M, Abdeljaleel O. Recurrent Testicular Torsion of a Fixed Testis. Case Rep Urol. 2019 Jul 15;1–3. doi: 10.1155/2019/8735842.[12] Distributed under the terms of the Creative Commons Attributions 4.0 International License (http://creativecommons.org/licenses/by-nc/4.0/). No changes have been made to the image or the image description).

TABLE LEGENDS

Table 1: Methodological quality of included articles

Table 2: Summary of literature included in the review

Table 3: Summary of clinical features of cases included in the review

Table 4: Summary of surgical techniques for TT and RTT reported in the included articles

Domains	Leading explanatory questions
Selection	1. Does the patient(s) represent(s) the whole experience of the investigator (centre) or is the selection method unclear to the extent that other patients with similar presentation may not have been reported?
Ascertainment	2. Was the exposure adequately ascertained? 3. Was the outcome adequately ascertained?
Causality	4. Were other alternative causes that may explain the observation ruled out? 5. Was there a challenge/rechallenge phenomenon? 6. Was there a dose–response effect? 7. Was follow-up long enough for outcomes to occur?
Reporting	8. Is the case(s) described with sufficient details to allow other investigators to replicate the research or to allow practitioners make inferences related to their own practice?

Figure 1: Tool for evaluating the methodological quality of case reports and case series

(Figure obtained from Murad MH, Sultan S, Haffar S, Bazerbachi F. Methodological quality and synthesis of case series and case reports. Evid Based Med. 2018;23(2):60–3. doi: 10.1136/bmjebm-2017-110853.[7] Distributed under the terms of the Creative Commons Attributions 4.0 International License (http://creativecommons.org/licenses/by-nc/4.0/). No changes have been made to the figure or the figure description).

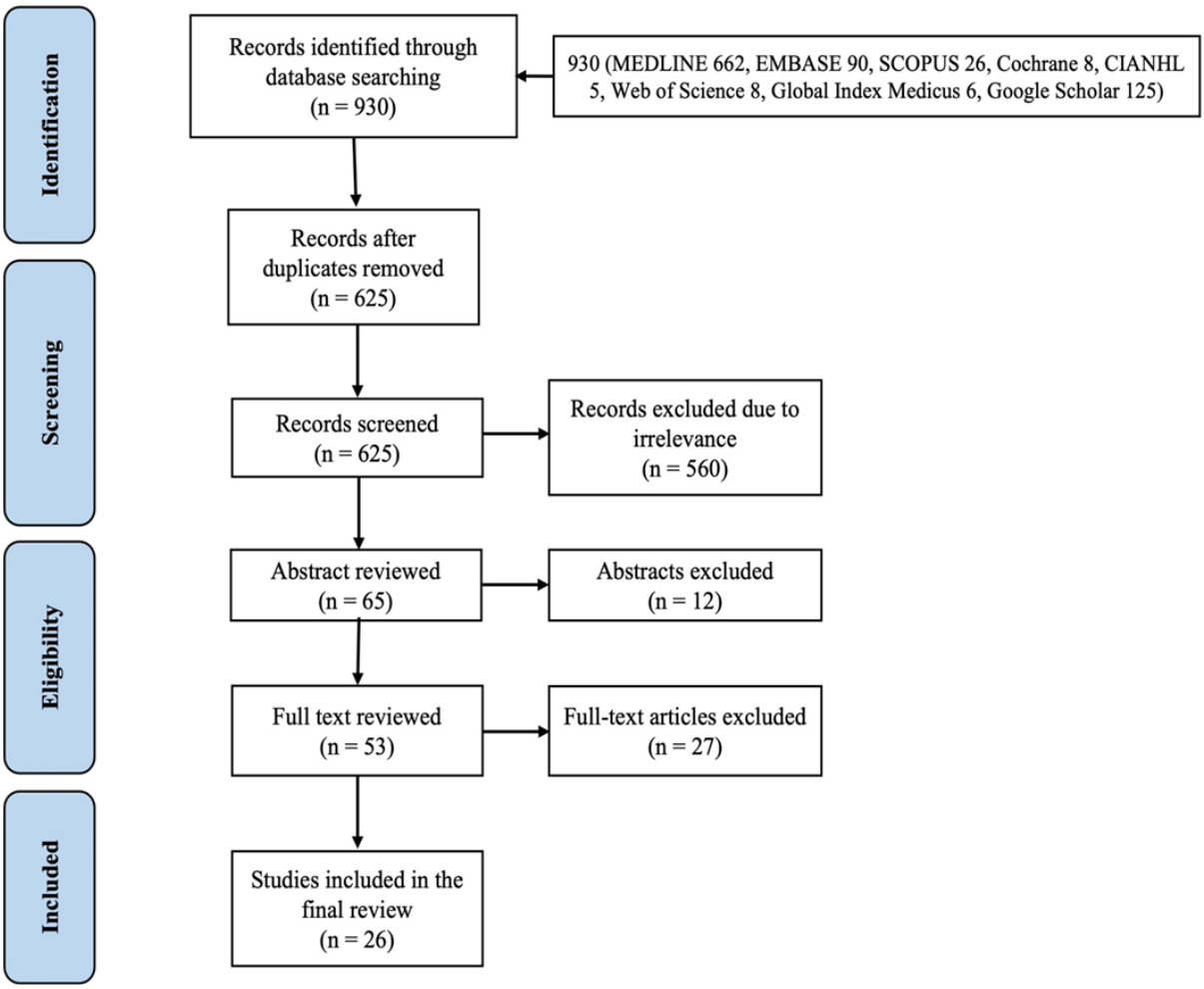

Figure 2: Study flow diagram



Figure 3: Black, torsed left testis attached with old stitch from lower pole to the side wall of scrotum (Image obtained from Alnadhari I, Abdulmuhsin A, Ali O, Shamsodini A, Salah M, Abdeljaleel O. Recurrent Testicular Torsion of a Fixed Testis. Case Rep Urol. 2019

Jul 15;1–3. doi: 10.1155/2019/8735842.[12] Distributed under the terms of the Creative Commons Attributions 4.0 International License (http://creativecommons.org/licenses/by-nc/4.0/). No changes have been made to the image or the image description).

Table 1: Methodological quality of included articles

First author	No. of cases	Q1	Q2	Q3	Q4	Q5	Q6	Overall Quality
Johenning[8]	2	Yes	No	Yes	No	Unclear	Yes	Intermediate
Kossow[15]	1	Unclear	No	No	No	Unclear	Yes	Low
May[27]	2	Yes	Yes	Yes	Yes	Unclear	Yes	High
McNellis[9]	4	Yes	Yes	Yes	Yes	Unclear	Yes	High
Redman[14]	1	Unclear	No	No	No	Unclear	Yes	Low
Vorstman[24]	1	Unclear	Yes	Yes	Yes	Unclear	Yes	High
Naughton[23]	1	Unclear	Yes	No	Yes	Unclear	Yes	Intermediate
Thurston[28]	5	Yes	No	Yes	No	Yes	Yes	High
Tawil[16]	1	Unclear	No	No	No	Unclear	Yes	Low
Kuntze[20]	2	Yes	Yes	Yes	Yes	Unclear	Yes	High
Gillion[11]	2	Yes	Yes	Yes	Yes	Unclear	Yes	High
Hulecki[17]	1	Unclear	Yes	No	Yes	Unclear	Yes	Intermediate
Morgan[13]	1	Unclear	Yes	No	Yes	Unclear	Yes	Intermediate
Phillips[21]	1	Unclear	Yes	No	Yes	Unclear	Yes	Intermediate
Steinbruchel[31]	2	Yes	No	No	No	Unclear	Yes	Low
O'Shaughnessy[33]	2	Yes	Yes	Yes	Yes	Unclear	Yes	High
Hurren[29]	2	Yes	Yes	No	Yes	Unclear	Yes	High
Chinegwundoh[22]	1	Unclear	Yes	No	Yes	Unclear	Yes	Intermediate
Rasmussen[32]	2	Yes	No	No	No	Unclear	No	Low
Von Zastrow[30]	4	Yes	Yes	No	Yes	Unclear	Yes	High
De Vylder[10]	3	Yes	Yes	No	Yes	Unclear	Yes	High

Blaut[26]	2	Yes	No	No	No	Unclear	No	Low
Van Glabeke[25]	1	Unclear	No	No	No	Unclear	Yes	Low
Alnadhari[12]	1	Unclear	No	No	No	Unclear	Yes	Low
Koochakzadeh[18]	1	Unclear	Yes	Yes	Yes	Unclear	Yes	High
Wang[19]	1	Unclear	Yes	No	Yes	Unclear	Yes	Intermediate

Q – question

*Questions 1-6 comprise the tool for assessing the methodological quality of each of the included articles:

1. Does the patient(s) represent(s) the whole experience of the investigator or is the selection method unclear to the extent that other patients with similar presentation may not have been reported?
2. Was the condition adequately ascertained?
3. Was the outcome adequately ascertained?
4. Were other alternative causes that may explain the observation ruled out?
5. Was follow-up long enough for outcomes to occur?
6. Is the case(s) described with sufficient details to allow other investigators to replicate the research or to allow practitioners to make inferences related to their own practice?

Table 2: Summary of literature included in the review

	First author	Location of study	Year published	Sample size	Age (years)	Time from symptom onset to ED presentation (hours)	Time from initial surgical intervention to representation (years)
1	Johenning[8]	Ohio, USA	1973	2	17	36	14
					16	-	1
2	Kossow[15]	Florida, USA	1980	1	21	96	6
3	May[27]	Bristol, UK	1980	2	10	Few	2
					15	2	1
4	McNellis[9]	Pennsylvania, USA	1980	4	24	-	4
					16	-	0.58
					29	5	2
					16	-	0.75
5	Redman[14]	Arkansas, USA	1980	1	16	36	1.5
6	Vorstman[24]	Auckland, New Zealand	1982	1	15	several	0.92
7	Naughton[23]	Dublin, Ireland	1983	1	16	8	4
8	Thurston[28]	Cambridge, UK	1983	5	26	48	11
					12	12	5
					28	120	16
					12	3	7

					15	3	0.83
9	Tawil[16]	Mussouri, USA	1984	1	23	48	5
10	Kuntze[20]	California, USA	1985	2	15	48	0.83
					17	16	4
11	Gillion[11]	Tel Aviv, Israel	1986	2	15	3	2
					12	Several	0.5
12	Hulecki[17]	Virginia, USA	1986	1	15	2	3
13	Morgan[13]	Texas, USA	1986	1	19	-	1
14	Phillips[21]	Leicester, UK	1987	1	12	4	8
15	Steinbruchel[31]	Kolding, Denmark	1988	2	26	24	15
					34	4	17
16	O'Shaughnessy[33]	Dublin, Ireland	1990	2	18	3	2
					20	6	6
17	Hurren[29]	Southhampton, UK	1992	2	20	Sudden	4
					33	6	27
18	Chinegwundoh[22]	Stoke-on-Trent	1995	1	20	4	6
19	Rasmussen[32]	Randers, Denmark	1996	4	20	6	11
					12	12	2
					26	4	7
					5	2	3.5
20	Von Zastrow[30]	Germany	2005	2	29	-	10
					16	-	1.17
21	De Vylder[10]	Netherlands	2006	3	22	-	4
					30	168	15

					35	-	-
22	Blaut[26]	Germany	2008	1	13	30	2
23	Van Glabeke[25]	France	2010	1	27	-	10
24	Alnadhari[12]	Doha, Qatar	2019	1	31	120	25
25	Koochakzadeh[18]	Florida, USA	2019	1	13	Sudden	1
26	Wang[19]	Ohio, USA	2019	1	22	3	14

Table 3: Summary of clinical features of cases included in the review

	First author	Abdominal pain	Nausea & vomiting	Testicular pain	Redness	Swelling	High riding testicle	Degree of rotation	Side of initial torsion	Side of recurrent torsion	How was diagnosis made?
1	Johenning[8]	-	-	X	X	X	-	360	R	R	PE
		-	-	X	-	X	-	180	R	L	PE
2	Kossow[15]	-	X	X	-	X	-	180	R	L	PE
3	May[27]	-	-	X	-	X	-	-	-	-	PE
		-	X	X	X	X	-	-	R	R	Observations of Angell
4	McNellis[9]	-	-	X	-	-	X	-	L	R	PE
		-	-	X	-	-	-	-	R	R	Doppler & TS
		-	-	X	-	-	-	-	L	L	Doppler
		-	-	X	-	-	-	-	R	L	Surgery
5	Redman[14]	-	-	X	X	X	-	360	R	L	PE
6	Vorstman[24]	-	-	X	-	X	-	-	L	L	PE
7	Naughton[23]	-	-	X	-	X	X	-	L	L	PE
8	Thurston[28]	X	X	X	-	-	-	-	UD	L	PE
		-	-	X	-	X	X	-	RUD	R	PE
		-	-	X	X	X	X	540	LUD	R	PE
		-	-	X	-	X	-	-	R	L	PE
		-	-	X	-	-	-	-	L	L	PE

9	Tawil[16]	-	-	X	X	-	X	360	L	R	PE
10	Kuntze[20]	-	-	X	-	X	-	360	L	R	PE, Doppler, TS
		-	-	X	-	X	-	360	R	L	TS
11	Gillion[11]	-	-	X	-	-	-	-	R	L	PE
		-	-	X	-	-	-	180	R	L	PE
12	Hulecki[17]	-	-	X	-	-	X	720	R	L	Doppler & TS
13	Morgan[13]	-	X	X	-	-	X	-	L	L	PE & TS
14	Phillips[21]	-	-	X	X	X	X	720	RUD	R	PE
15	Steinbruchel[31]	-	X	X	-	X	-	-	LUD	L	PE
		-	-	X	-	X	X	720	RUD	R	PE
16	O'Shaughnessy[33]	-	-	X	-	-	-	540	RUD	L	PE
		-	-	X	-	X	X	360	LUD	R	PE
17	Hurren[29]	-	-	X	-	X	X	-	LUD	L	PE
		-	-	X	-	-	X	180	LUD	L	PE
18	Chinegwundoh[22]	-	-	X	-	X	-	-	R	L	Doppler
19	Rasmussen[32]	-	-	X	-	X	-	-	RUD	L	PE
		-	-	X	-	X	-	-	LUD	R	PE
		-	-	X	-	X	X	-	RUD	L	PE & Doppler
		-	-	X	-	X	X	360	RUD	L	PE
20	Von Zastrow[30]	-	-	X	-	-	-	-	R	R	Doppler
		-	-	X	X	X	-	1080	R	L	PE & Doppler
21	De Vylder[10]	-	-	X	-	-	-	720	L	L	PE
		-	-	X	X	-	-	-	R	R	PE

		-	-	X	-	X	-	-	R	L	Doppler
22	Blaut[26]	-	X	X	-	-	-	360	R	L	Doppler
23	Van Glabeke[25]	-	-	X	-	X	-	720	R	L	Doppler
24	Alnadhari[12]	-	-	X	-	X	-	-	L	L	Doppler
25	Koochakzadeh[18]	-	-	X	-	X	X	360	L	R	Doppler
26	Wang[19]	X	X	X	-	-	X	360	L	L	Doppler

R – right, L – left, UD – undescended, RUD – right undescended, LUD – left undescended,

PE – physical exam, TS – testicular scan

Table 4: Summary of surgical techniques for TT and RTT reported in the included articles

		First Incidence of Torsion					Second Incidence of Torsion				
	First author	**Technique**	**Suture type**	**No. of sutures**	**Site of sutures**	**Complications**	**Technique**	**Suture type**	**No. of sutures**	**Site of sutures**	**Complications**
1	Johenning[8]	-	-	-	-	None	TA to SW	-	2	-	R Orchiectomy
		TA to scrotum	3/0 chromic catgut	2	-	-	-	-	-	-	None
2	Kossow[15]	-	-	-	-	R Orchiectomy	Fixation	-	3	-	L Atrophy
3	May[27]	TA to PTV	Catgut	Several	-	None	PTV excised	-	-	-	None
		TA to PV	Catgut	3	-	None	PTV excised	-	-	-	R Atrophy
4	McNellis[9]	Fixed bilaterally	3/0 chromic catgut	-	-	None	Fixed bilaterally	-	-	-	None
		Fixed bilaterally	3/0 vicryl	-	-	-	Fixed bilaterally	-	-	-	-
		Fixed bilaterally	3/0 chromic catgut	-	-	-	Fixed bilaterally	-	-	-	-
		-	Absorbable	-	-	-	Fixed bilaterally	Non-absorbable	-	-	-
5	Redman[14]	PTV to VTV	3/0 chromic catgut	3	-	-	-	-	-	-	-

6	Vorstman[24]	TA to SS	3/0 chromic catgut	2	-	None	TA to SW	Silk	2	-	None
7	Naughton[23]	-	-	-	-	-	-	-	-	-	-
8	Thurston[28]	Fixed to thigh	Chromic catgut	1	-	-	Evag. TV to SW	Non-absorbable	2	Bipolar	L Orchiectomy
		Dartos Pouch	-	-	-	None	Evagination PTV	Non-absorbable	3	-	None
		-	-	-	Lower	L Orchiectomy	Plication of TV	-	-	-	-
		-	2/0 chromic catgut	-	Bipolar	R Orchiectomy	-	Non-absorbable -	3	-	Swelling
		Fixed bilaterally	Absorbable	-	Bipolar	None	-	-	-	-	None
9	Tawil[16]	VTV to TA & PTV	3/0 chromic catgut	2	-	-	-	-	-	-	R+L Orchiectomy
10	Kuntze[20]	Fixed to DF	2/0 chromic	-	-	L Orchiectomy	-	3/0 silk	-	-	R Orchiectomy
		TA to DF	3/0 chromic	-	-	R Orchiectomy	Remove window TV	3/0 silk	-	-	L Orchiectomy
11	Gillion[11]	Fixed bilaterally	-	-	-	-	-	Non-absorbable	-	-	-
		Fixed bilaterally	-	-	-	-	Fixation to TV	Non-absorbable	-	-	-
12	Hulecki[17]	Transeptally	2/0 proline	-	-	None	-	3/0 proline	4	-	None

13	Morgan[13]	-	-	1	-	-	-	2/0 vicryl	2	-	-
14	Phillips[21]	-	Catgut	2	Bipolar	-	-	Silk	3	-	-
15	Steinbruchel[31]	-	-	1	SW&TE	-	-	-	-	-	-
		-	Catgut	2	Lower	-	Fixed to DF	-	-	-	-
16	O'Shaughnessy[33]	DP to DF	-	-	-	-	TA to TV	2/0 polyglycolic acid	2	-	-
		DP fixation	Chromic catgut	1	-	-	-	2/0 polyglycolic acid	-	-	-
17	Hurren[29]	-	-	-	-	-	Fixed bilaterally	-	-	-	-
		-	-	-	-	-	Fixed bilaterally	-	-	-	-
18	Chinegwundoh[22]	-	Catgut	-	-	None	-	-	-	-	None
19	Rasmussen[32]	-	-	-	-	-	Fixed to DF	-	-	-	-
		-	-	-	-	-	Fixed to DF	-	-	-	-
		-	-	-	-	-	Fixed to DF	-	-	-	-
		-	-	-	-	-	Fixed to DF	Dexon	-	-	-
20	Von Zastrow[30]	DF to TA	Non-absorbable	3	-	-	-	-	-	-	-
		-	-	-	-	-	R Orchiectomy	-	-	-	L Atrophy
21	De Vylder[10]	-	Absorbable	2	-	-	Jaboulay's bottle neck	-	-	-	-

		Fixed bilaterally	Absorbable	-	-	-	-	-	-	-	R Orchiectomy
		Fixed to TA	-	-	-	R Orchiectomy	-	-	-	-	-
22	Blaut[26]	-	-	-	-	-	R Orchiectomy	4/0 polypropylene	3	SW	L Orchiectomy
23	Van Glabeke[25]	-	-	-	-	-	R Orchiectomy	-	-	-	L Orchiectomy
24	Alnadhari[12]	-	-	-	Lower	-	Fixed to SW	-	3	-	L Orchiectomy
25	Koochakzadeh[18]	Fixation to DP	4/0 prolene	4	-	L Orchiectomy	TA to SS	4/0 non-absorbable	4	-	-
26	Wang[19]	-	5/0 prolene	3	Lower pole	-	-	4/0 prolene	3	-	-

SW – scrotal wall, TE – tail of epididymis, TA – tunica albuiginea, PTV – parietal tunica vaginalis, VTV – visceral tunica vaginalis, SS – scrotal septum, DF – dartos fascia, DP - dartos pouch

RESEARCH PROTOCOL

Recurrent testicular torsion post orchidopexy: an occult emergency – a systematic review

Mikayla van Welie

Student no.: 722387

Supervisors: Prof Abdullah Laher

Prof Ahmed Adam

Dr Liang Qu

INTRODUCTION

Testicular torsion (TT) is a urological emergency that commonly presents to the emergency department (ED). It occurs as a result of rotation of the testes around the spermatic cord thereby compromising testicular blood flow and resulting in irreversible ischemic testicular damage [1,2].

Testicular torsion can occur at any age, but most commonly presents soon after birth and during puberty. It affects approximately 1 in 4000 males younger than 25 years of age [1,3]. The bell-clapper deformity is a predisposing factor to TT. This occurs when there is an abnormally high attachment of the tunica vaginalis parietal lamina to the spermatic cord. Hence, the tunica vaginalis completely encircles the epididymis, the distal unattached spermatic cord and the testes rather than only attaching to the posterolateral aspect of the testes [4]. This deformity is seen in approximately 12% of males and 78% of cases of TT

[4]. It has also been documented that lower temperatures are associated with an increase in the incidence of TT [2,5].

Testicular torsion can present with a variety of clinical signs and symptoms and therefore the diagnosis can be challenging. Additionally, it commonly mimics other conditions such as epididymitis, orchitis, inguinal hernia, cancer, torsion of the appendix testicle, testicular rupture and varicocele [2,3]. It is important to obtain a thorough history in a patient presenting with possible testicular pain. Significant features that may assist with identification of TT include age younger than 25 years, a sudden onset of severe testicular pain, swelling, redness, nausea and vomiting. Patients may also sometimes report a history of recent trauma or recent strenuous physical activity. Other signs include a 'high riding' testes (Brenzel Sign) and retraction of the scrotal skin (Ger's sign) [1,3,5].

While the diagnosis of TT is predominantly a clinical diagnosis, the use of various imagining tools such as ultrasonography (including colour doppler sonography), magnetic resonance imaging, computed tomography and nuclear imaging may be useful to assist in confirming the diagnosis [1,2,6].

Testicular torsion is a time critical diagnosis, hence identification and management should ideally be performed within 4-6 hours of symptoms onset to prevent testicular infarction [7]. Once identified, management of TT usually requires early surgical intervention [6]. It is imperative that surgical intervention is not delayed. Anderson et al. found that 89% of testes operated on within 7-12 hours were salvaged [8]. Salvage rates decline rapidly with time with less than 10% salvageability when the duration of torsion is greater than 24 hours [3].

The goals of surgical exploration include detorsion, assessment of testicular viability, removal (orchidectomy) or fixation (orchidopexy) of the affected testis and fixation of the contralateral testis [9]. Current literature shows rates of orchidectomy ranging from 39%-71% [3].

Recurrent TT after previous surgical exploration is a rare complication and often occurs on the testicle that was not previously fixated [10]. Patients that have previously undergone testicular fixation may present to the ED with acute testicular pain, nausea and vomiting. The severity of swelling, erythema and firmness of the affected testis is variable and dependent on the duration of torsion [11].

The surgical technique used during the initial exploration as well as the suture type used have been linked to the cause of orchidopexy failure [12]. Various studies have reported that recurrent TT is more common when absorbable sutures were used with the affected testicle losing its attachment to the scrotal wall [7,10]. Complications following a second orchidopexy, such as infertility, chronic pain and orchidectomy have not been explored in depth.

Over the years, various techniques have been attempted to reduce the incidence of retorsion [13]. In the 12th Edition of Campbell's Urology, it is recommend that both the affected and contralateral teste be fixed either via dartos pouch or directly to the dartos fascia with nonabsorbable sutures fixed at three points to reduce the risk of retorsion [12,13]. However, even when the above-mentioned fixation technique is used, recurrent torsion may still occur. It must be noted, however, that this might be due to a higher number of these

orchidopexies being performed with absorbable sutures [14]. Absorbable sutures have historically been used on the assumption that a dense inflammatory response will occur to fix the testis once the sutures have dissolved. However, Sell et.al reported that only fine adhesions form at the site fixation with the use of absorbable sutures [15].

Since recurrent TT is rare, there is a paucity of data pertaining to the presentation, diagnosis, risk factors, management, and outcomes of recurrent TT post orchidopexy. Hence, this systematic review will aim to address this.

STUDY AIM

To conduct a systematic review of the literature that will explore recurrent TT post orchidopexy

STUDY OBJECTIVES

1. To describe the presentation of recurrent TT
2. To describe the diagnosis recurrent TT
3. To determine the risk factors associated with recurrent TT
4. To describe the management and outcomes associated with recurrent TT

METHODOLOGY

Study design

The study will be a systematic review carried out in accordance with the PRISMA statement. The PRISMA statement provides a framework of components that should be included in a systematic review to ensure transparency and reproducibility (see Appendix A). This study will

be conducted systematically using the aforementioned guidelines but will not undergo a meta-analysis. The study has been registered with PROSPERO (ID CRD42021258997) (Appendix B). A scoping review was done and approximately 1000 articles were found relevant to the topic.

Search strategy

The following electronic databases will be searched: Pubmed, EMBASE, CIANHL, SCOPUS, Web of Science, Google Scholar, Global Index Medicus and the Cochrane Database of Systematic Reviews. The search terms “spermatic cord”, “torsion”, “treatment”, “failure”, “re-operation”, “recurrence”, “retorsion” will be used. The following inclusion criteria will be applied as limits during each search:

1. Studies relating only to the human species
2. Studies published in any language
3. Original studies only

A backward citation search will be carried out in those databases that index citations to locate studies that were not found during the original search. The final pool of included studies will include all studies that are relevant to this research. A reference manager will be used to collect studies and eliminate duplicates.

Study population

Males of all ages from all countries with previous orchidopexies performed for suspected or confirmed testicular torsion.

Intervention

Diagnosis of recurrent testicular torsion after previous orchidopexy and the management thereof.

Comparison

None, as no comparisons are being measured.

Study selection

Once duplicate studies have been removed from the pool, titles and abstracts will be scrutinised, and the below criteria applied to screen for eligible studies.

The following will be excluded:

1. Studies that were found as a result of keyword matching or tags but are obviously irrelevant to the study topic.
2. Full text articles not available.
3. Articles pertaining to the first occurrence of TT, rather than recurrent TT.

Every attempt will be made to locate full-text articles, including contacting the corresponding authors where possible. The final search strategy will be represented in a flow diagram in accordance with the PRISMA statement (Appendix C). For articles in languages other than English, an online free document translator will be used to assess the article.

Risk of bias

Each study will be independently assessed for selection bias, measurement bias, as well as the potential for confounders as per the requirements of the Cochrane handbook. The

overall quality will be assessed for each study and categorized on a three-point scoring system, with high quality, intermediate quality and low quality categories. The quality assessment tool used for this review will be adapted from the tool proposed by Murad et al. [16], comprising of four domains with a total of eight questions.

Data extraction

Data will be extracted from the pool of eligible studies using full-text articles. Data will be collated using Microsoft Excel. The following categories of data will be collected: Study details, number of patients and demographics, clinical characteristics of patients, surgical technique used, type of suture used, time since initial operation, contralateral torsion rates, follow-up duration, patient outcomes and complications. The full list of data variables to be extracted is included in Appendix D. Studies will be initially rated by the primary and one of the study supervisors. If any disagreement exists, other supervisors will be approached.

DATA ANALYSIS

Univariate analysis will be performed by reporting descriptive statistics for each of the following variables: age (years), time to presentation (hours) and time to diagnosis (hours). If data is parametric and normally distributed, then the mean and standard deviation will be reported. If the data is either parametric and not normally distributed or non-parametric, then the median and range will be calculated.

The remaining data (clinical characteristics, associated factors, and diagnostic-related data) are categorical descriptive data which will be reported as percentages or proportions.

ETHICAL CONSIDERATIONS

As this study will be a retrospective review of documents already in the public domain, an application for waiver of ethics clearance will be submitted to the University of Witwatersrand Human Research Ethics Committee (Medical). There will be no active human participation in this study.

TIMING

Proposal wrote up and submission:	May – June 2021
Protocol Assessment:	July 2021
Collection of Articles for review:	August 2021
Quality check of relevant articles:	September 2021
Write Up:	October – November 2021

FUNDING

The primary researcher will cover all expenses relating to the study. This will include the cost of printing and data for internet usage. There are no further foreseen costs. The total amount is expected to be approximately R500.

LIMITATIONS

As the basis for any systematic review is existing literature, the quality and availability of relevant documents will present the biggest challenge. Case reports were not previously appraised to the same degree as other forms of studies, so data can be inconsistent and incomplete in some cases. If certain sought-after data is not included in the report, it can lead to difficulty in incorporating the study in the review. Similarly, as with all descriptive

studies, it is often left to the author to draw conclusion about possible associations and make inferences based on their personal experience, leading to a certain level of bias in some cases. Using a checklist to appraise studies can help reduce the impact of this potential limitation and offer some standardisation.

Despite best efforts, there may ultimately be several studies where the full text cannot be located, particularly for older publication dates. These studies will then have to be excluded from the review.

REFERENCES

[1] Laher A, Ragavan S, Mehta P, Adam A. Testicular Torsion in the Emergency Room: A Review of Detection and Management Strategies. Open Access Emerg Med 2020;Volume 12:237–46. https://doi.org/10.2147/OAEM.S236767.

[2] Fujita N, Tambo M, Okegawa T, Higashihara E, Nutahara K. Distinguishing testicular torsion from torsion of the appendix testis by clinical features and signs in patients with acute scrotum. Res Reports Urol 2017;9:169–74. https://doi.org/10.2147/RRU.S140361.

[3] Sharp VJ, Kieran K, Arlen AM. Testicular Torsion: Diagnosis, Evaluation, vand Management. Am Fam Physician 2013;88:835–40.

[4] Bandarkar AN, Blask AR. Testicular torsion with preserved flow: key sonographic features and value-added approach to diagnosis. Pediatr Radiol 2018;48:735–44. https://doi.org/10.1007/s00247-018-4093-0.

[5] Korkes F, Cabral PR dos A, Alves CDM, Savioli ML, Pompeo ACL. Testicular torsion and weather conditions: analysis of 21,289 cases in Brazil. Int Braz j Urol 2012;38:222–9. https://doi.org/10.1590/S1677-55382012000200010.

[6] McDowall J, Adam A, Gerber L, Enyuma COA, Aigbodion SJ, Buchanan S, et al. The ultrasonographic “whirlpool sign” in testicular torsion: valuable tool or waste of valuable time? A systematic review and meta-analysis. Emerg Radiol 2018:1–12. https://doi.org/10.1007/s10140-018-1579-x.

[7] Alnadhari I, Abdulmuhsin A, Ali O, Shamsodini A, Salah M, Abdeljaleel O. Recurrent Testicular Torsion of a Fixed Testis. Case Rep Urol 2019:1–3. https://doi.org/10.1155/2019/8735842.

[8] Anderson JB, Williamson RCN. Testicular torsion in Bristol: A 25-year review. Br J Surg 1988;75:988–92. https://doi.org/10.1002/bjs.1800751015.

[9] Singh S, Bedi S. Intermittent testicular torsion in an adult: A case report and review of the literature. Saudi J Heal Sci 2013;2:61. https://doi.org/10.4103/2278-0521.112634.

[10] Morgan JA, Mellick LB. Testicular Torsion following orchiopexy. Pediatr Emerg Care 1986;2:244–6.

[11] Hyun GS. Testicular Torsion. Rev Urol 2018;20:104–6. https://doi.org/10.3909/riu0800.

[12] Palmer LS, Palmer JS. Campbell-Walsh-Wein Urology. 12th ed. Elsevier; 2020.

[13] Mor Y, Pinthus JH, Nadu A, Raviv G, Golomb J, Winkler H, et al. Testicular fixation following torsion of the spermatic cord - Does it guarantee prevention of recurrent torsion events? J Urol 2006;175:171–3. https://doi.org/10.1016/S0022-5347(05)00060-1.

[14] Moore SL, Chebbout R, Cumberbatch M, Bondad J, Forster L, Hendry J, et al. Orchidopexy for Testicular Torsion: A Systematic Review of Surgical Technique. Eur Urol Focus 2020:1–11. https://doi.org/10.1016/j.euf.2020.07.006.

[15] Sells H, Moretti KL, Burfield GD. Recurrent torsion after previous testicular fixation. ANZ J Surg 2002;72:46–8. https://doi.org/10.1046/j.1445-2197.2002.02295.x.

[16] Murad MH, Sultan S, Haffar S, Bazerbachi F. Methodological quality and synthesis of

case series and case reports. Evid Based Med. 2018;23(2):60–3.

PRISMA 2020 Checklist

Section and Topic	Item #	Checklist item	Location where item is reported
TITLE			
Title	1	Identify the report as a systematic review.	
ABSTRACT			
Abstract	2	See the PRISMA 2020 for Abstracts checklist.	
INTRODUCTION			
Rationale	3	Describe the rationale for the review in the context of existing knowledge.	
Objectives	4	Provide an explicit statement of the objective(s) or question(s) the review addresses.	
METHODS			
Eligibility criteria	5	Specify the inclusion and exclusion criteria for the review and how studies were grouped for the syntheses.	
Information sources	6	Specify all databases, registers, websites, organisations, reference lists and other sources searched or consulted to identify studies. Specify the date when each source was last searched or consulted.	
Search strategy	7	Present the full search strategies for all databases, registers and websites, including any filters and limits used.	
Selection process	8	Specify the methods used to decide whether a study met the inclusion criteria of the review, including how many reviewers screened each record and each report retrieved, whether they worked independently, and if applicable, details of automation tools used in the process.	
Data collection process	9	Specify the methods used to collect data from reports, including how many reviewers collected data from each report, whether they worked independently, any processes for obtaining or confirming data from study investigators, and if applicable, details of automation tools used in the process.	
Data items	10a	List and define all outcomes for which data were sought. Specify whether all results that were compatible with each outcome domain in each study were sought (e.g. for all measures, time points, analyses), and if not, the methods used to decide which results to collect.	
	10b	List and define all other variables for which data were sought (e.g. participant and intervention characteristics, funding sources). Describe any assumptions made about any missing or unclear information.	
Study risk of bias assessment	11	Specify the methods used to assess risk of bias in the included studies, including details of the tool(s) used, how many reviewers assessed each study and whether they worked independently, and if applicable, details of automation tools used in the process.	
Effect measures	12	Specify for each outcome the effect measure(s) (e.g. risk ratio, mean difference) used in the synthesis or presentation of results.	
Synthesis methods	13a	Describe the processes used to decide which studies were eligible for each synthesis (e.g. tabulating the study intervention characteristics and comparing against the planned groups for each synthesis (item #5)).	
	13b	Describe any methods required to prepare the data for presentation or synthesis, such as handling of missing summary statistics, or data conversions.	
	13c	Describe any methods used to tabulate or visually display results of individual studies and syntheses.	
	13d	Describe any methods used to synthesize results and provide a rationale for the choice(s). If meta-analysis was performed, describe the model(s), method(s) to identify the presence and extent of statistical heterogeneity, and software package(s) used.	
	13e	Describe any methods used to explore possible causes of heterogeneity among study results (e.g. subgroup analysis, meta-regression).	
	13f	Describe any sensitivity analyses conducted to assess robustness of the synthesized results.	
Reporting bias assessment	14	Describe any methods used to assess risk of bias due to missing results in a synthesis (arising from reporting biases).	
Certainty assessment	15	Describe any methods used to assess certainty (or confidence) in the body of evidence for an outcome.	

PRISMA 2020 Checklist

Section and Topic	Item #	Checklist item	Location where item is reported
RESULTS			
Study selection	16a	Describe the results of the search and selection process, from the number of records identified in the search to the number of studies included in the review, ideally using a flow diagram.	
	16b	Cite studies that might appear to meet the inclusion criteria, but which were excluded, and explain why they were excluded.	
Study characteristics	17	Cite each included study and present its characteristics.	
Risk of bias in studies	18	Present assessments of risk of bias for each included study.	
Results of individual studies	19	For all outcomes, present, for each study: (a) summary statistics for each group (where appropriate) and (b) an effect estimate and its precision (e.g. confidence/credible interval), ideally using structured tables or plots.	
Results of syntheses	20a	For each synthesis, briefly summarise the characteristics and risk of bias among contributing studies.	
	20b	Present results of all statistical syntheses conducted. If meta-analysis was done, present for each the summary estimate and its precision (e.g. confidence/credible interval) and measures of statistical heterogeneity. If comparing groups, describe the direction of the effect.	
	20c	Present results of all investigations of possible causes of heterogeneity among study results.	
	20d	Present results of all sensitivity analyses conducted to assess the robustness of the synthesized results.	
Reporting biases	21	Present assessments of risk of bias due to missing results (arising from reporting biases) for each synthesis assessed.	
Certainty of evidence	22	Present assessments of certainty (or confidence) in the body of evidence for each outcome assessed.	
DISCUSSION			
Discussion	23a	Provide a general interpretation of the results in the context of other evidence.	
	23b	Discuss any limitations of the evidence included in the review.	
	23c	Discuss any limitations of the review processes used.	
	23d	Discuss implications of the results for practice, policy, and future research.	
OTHER INFORMATION			
Registration and protocol	24a	Provide registration information for the review, including register name and registration number, or state that the review was not registered.	
	24b	Indicate where the review protocol can be accessed, or state that a protocol was not prepared.	
	24c	Describe and explain any amendments to information provided at registration or in the protocol.	
Support	25	Describe sources of financial or non-financial support for the review, and the role of the funders or sponsors in the review.	
Competing interests	26	Declare any competing interests of review authors.	
Availability of data, code and other materials	27	Report which of the following are publicly available and where they can be found: template data collection forms; data extracted from included studies; data used for all analyses; analytic code; any other materials used in the review.	

From: Page MJ, McKenzie JE, Bossuyt PM, Boutron I, Hoffmann TC, Mulrow CD, et al. The PRISMA 2020 statement: an updated guideline for reporting systematic reviews. BMJ 2021;372:n71. doi: 10.1136/bmj.n71

For more information, visit: http://www.prisma-statement.org/

Appendix B – PROSPERO RECORD as attached

Appendix C – PRISMA Flow Diagram

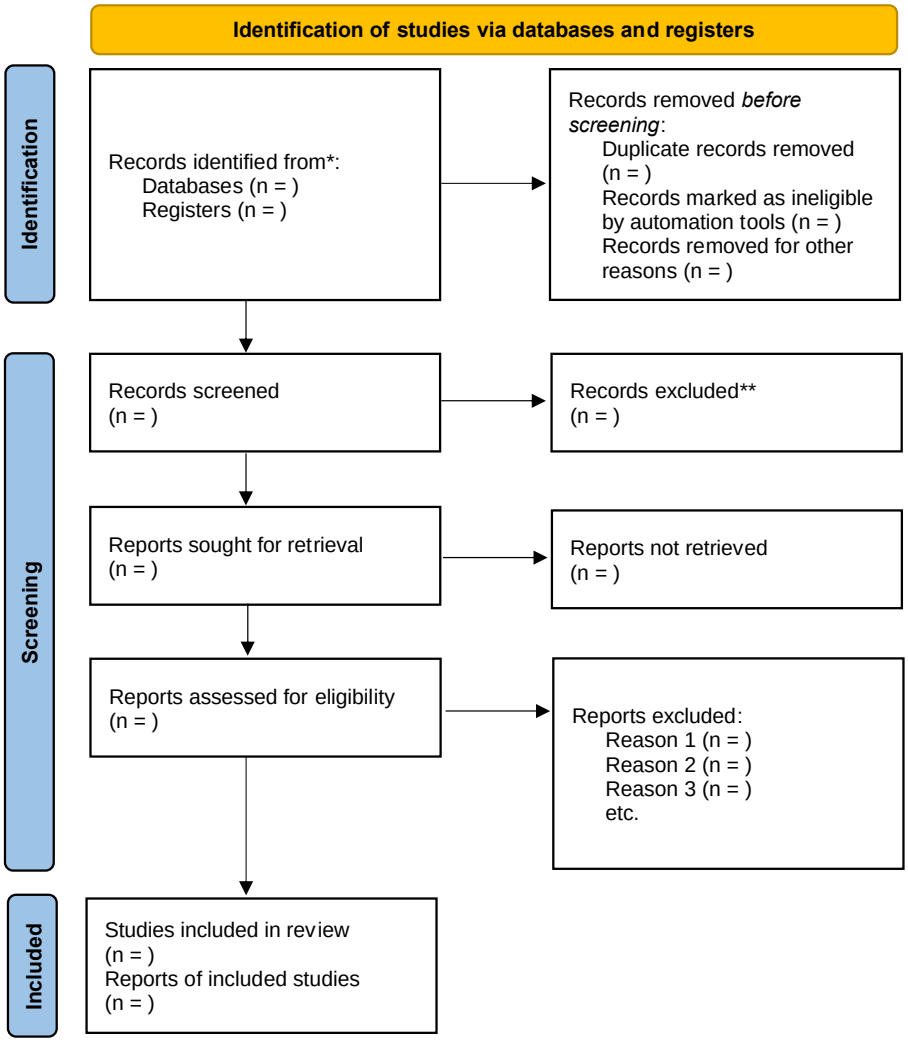

*Consider, if feasible to do so, reporting the number of records identified from each database or register searched (rather than the total number across all databases/registers).

**If automation tools were used, indicate how many records wer e excluded by a human and how many were excluded by automation tools.

Appendix D – Data variables to be extracted

Data Collection Sheet Paper no: ___

1. Location of Study: _____
2. Name of First Author:_____
3. Year Published: _____
4. Sample Size: _____
5. Age of Patients (mean (SD)): _____ years
6. First Torsion:
    a. Left / Right side
    b. Clinical Characteristics
        i. Abdominal Pain Y/N
        ii. Nausea & vomiting Y/N
        iii. Testicular pain Y/N
        iv. Redness Y/N
        v. Swelling Y/N
        vi. Testis riding high in scrotum Y/N
        vii. Degree of rotation: _____
        viii. Other: _____
    c. Diagnosis confirmation
        i. Doppler Ultrasound
        ii. Physical Exam
        iii. Testicular Scan
        iv. Other: _____
    d. Surgical Technique
        i. Technique used: _____

ii. Type of suture: _____

iii. No of sutures: _____

iv. Location of sutures: _____

e. No of testes fixated at first torsion? One / Both

f. Complications due to torsion:

i. Atrophy

ii. Orchiectomy: R / L

iii. None

iv. Other: _____

7. Second Torsion:

a. Left / Right

b. Time

i. Hours from symptoms onset to presentation: _____

ii. Year from initial surgical intervention to recurrence: _____

c. Clinical Characteristics

i. Abdominal Pain Y/N

ii. Nausea & vomiting Y/N

iii. Testicular pain Y/N

iv. Redness Y/N

v. Swelling Y/N

vi. Testis riding high in scrotum Y/N

vii. Degree of rotation: _____

viii. Other: _____

d. Diagnosis confirmation

i. Doppler Ultrasound

ii. Physical Exam

iii. Testicular Scan

iv. Other: _____

e. Surgical Technique

i. Technique used: _____

ii. Type of suture: _____

iii. No of sutures: _____

iv. Location of sutures: _____

v. Evidence of adhesions/sutures from previous fixation: Y/N

f. Complications due to torsion:

i. Atrophy

ii. Orchiectomy: R / L

iii. None

iv. Other: _____

8. Author recommendations:

a. Preferred technique: _____

b. Number of Sutures: _____

c. Suture type: _____

d. Location of sutures: _____

e. Other: _____

ETHICS WAIVER CERTIFICATE