

https://dspace.org/

A review of the management of impacted oesophageal coins in children presenting at Dr George Mukhari Hospital

Kasakanga, Marie-Josee Kasongo

2016-03-14
http://hdl.handle.net/10539/20077

Downloaded from a DSpace repository. https://dspace.org/

A REVIEW OF THE MANAGEMENT OF IMPACTED OESOPHAGEAL COINS IN CHILDREN PRESENTING AT DR GEORGE MUKHARI HOSPITAL

By

MARIE-JOSEE KASONGO KASAKANGA

347377

RESEARCH REPORT

Submitted in partial fulfilment of the requirements for the degree

MASTER OF SCIENCES IN MEDICINE (EMERGENCY MEDICINE)

In the

FACULTY OF HEALTH SCIENCES

UNIVERSITY OF THE WITWATERSRAND

Supervisor: Dr Anita Groenewald

Co-supervisor: Prof. Efraim Kramer

2015

DECLARATION

I, Marie-Josee Kasongo Kasakanga, declare that this research report is my own work. It is submitted for the degree of Master of Science in Medicine (Emergency Medicine) to the University of the Witwatersrand, Johannesburg. It has not been submitted before for any degree or examination at this or any other university.

M-J. K. Kasakanga

Signature: Date: 20/11/2015

DEDICATION

To Almighty God, the Father of all, who is above all, and through all and in you all (Eph. 4:6, KJV);

To my Saviour and Lord Jesus Christ, through all eternity I will have the privilege of thanking you for the wonderful salvation you gave so much for me to receive;

To my late father, Celestin Kasongo Mutambayi, and my mother, Celestine Ndaya Kanyinda, my sister Mukundi Kasongo and brother Mbikay Tshianda, Biaya Kasongo, may their souls rest in peace;

To my husband, Janvier Baleke Mabunga, and our two sons, David Muyayu Mabunga, Isaac Baleke Mabunga and our daughter, Laurena Mukuna Ndaya, for your love and having always been there for me;

To my brothers, Jeef Kasongo and Thierry Kanyinda, for all your love and support;
To my sisters, Mulanga Mpinda, Regine Mujinga, Sidonie Ndaya, Martine Goya, Kathy Masengo, Gody Ntumba and Dally Mitonga, for your help and support, spiritually and financially.

ABSTRACT

Introduction: Ingestion of coins is a common presentation at the emergency departments of hospitals globally. Children are most often the victims of ingesting coins. It requires prompt management of this emergency to prevent complications, as there could be adverse outcomes for the child.

Aims of the study: This study was designed to review the management of paediatric patients that presented to the Emergency Department (ED) at Dr George Mukhari Academic Hospital (DGMAH) with impacted oesophageal coins from 01 January 2009 to 31 December 2013.

Objectives: To describe the clinical features of paediatric patients who presented to the DGMAH ED with an impacted oesophageal coin and to compare their clinical outcomes based on the method used to extract the foreign body, namely, Foley catheter versus oesophagoscopic technique.

Methodology: This was a retrospective transverse descriptive study. Data was collected from the medical records of paediatric patients aged ≤12 years, treated at DGMAH for coin ingestion with oesophageal impaction during the five years from 01 January 2009 to 31 December 2013. A data collection sheet was used to extract relevant data from the medical records.

Results: A total of 95 patients (51 females and 44 males) were included in the analysis. The age ranged from 0.70 to 10 years with a median age of 3.0 years. The

majority of patients (81.1%) resided in informal settlements. Coins were mostly located in the upper oesophagus (71.6% of cases). The most commonly-impacted coin was a fifty-cent coin (50c); 22mm, which occurred in 23 patients (27.4%).

Thirty-five children (42.7%) presented before 8 hours after the ingestion of the coin had elapsed and 47 children (57.3%) presented 8 hours after the coin was ingested.

From the 95 patients in the study, 82 patients (86.3%), were asymptomatic.

The most commonly-observed signs of oesophageal coin lodgement in the present study were hypersalivation in 17 patients (17.9%) and vomiting in 8 patients (8.4%). The Foley catheter was solely used in 48 patients (77.4%). In this study, the rigid oesophagoscopy was used in 33 patients as first procedure (34.7%). Rigid oesophagoscopy was used in 14 (22.6%) patients following the failure to use Foley's catheter. The overall success for rigid oesophagoscopy was 100% (44 patients).

Conclusion: Coin ingestion is more common in children aged 0–5 years, raised in informal settlements. This study also demonstrated that the Foley catheter seems to offer a safer and effective method in comparison to rigid oesophagoscopy.

ACKNOWLEDGEMENTS

Firstly, I would like to thank Professor Efraim Kramer, for his academic co-supervision, Dr Anita Groenewald, my supervisor for help, encouragement, suggestions, patience, motivational talks and friendship. Her support made this work come to a fruitful completion.

I am grateful for the time and assistance given by the following people:

- Professor Malangu for his input and assistance in statistical analysis
- Professor HS Schoeman for his advice with statistical analysis
- Professor Craig Mackenzie, for language editing this dissertation
- Kelly for language editing this dissertation
- Dr Jane Murray for language editing this dissertation
- Dr Paul Chelule for language editing this dissertation
- Nomsa for language editing this dissertation and her spiritual support
- Dr Katumba Nyunyi for his advice and encouragement
- Dr Paul Mbaya
- Dr Tshitenge wa Tshitenge
- Dr George Mukhari Academic Hospital staff.

TABLE OF CONTENTS

DECLARATION i

DEDICATION ii

ABSTRACT iii

ACKNOWLEDGEMENTS v

TABLE OF CONTENTS vi

LIST OF TABLES viii

LIST OF FIGURES viii

LIST OF ABBREVIATIONS ix

CHAPTER 1: INTRODUCTION 1

1.1 BACKGROUND AND SIGNIFICANCE OF THE STUDY 1

1.2 PROBLEM STATEMENT 3

1.3 AIMS AND OBJECTIVES OF THE STUDY 5

1.3.1 Aim of study 5

1.3.2 Study objectives 5

1.4 RATIONALE FOR THE STUDY 5

CHAPTER 2: LITERATURE REVIEW 7

2.1 INTRODUCTION 7

2.2 EPIDEMIOLOGY 7

2.3 RISK FACTORS OF RETAINED COINS 9

2.4 DIAGNOSTIC APPROACH 9

2.4.1 History 9

2.4.2 Clinical presentation 10

2.4.3 Investigations 12

2.5 MANAGEMENT 14

2.5.1 Medical management 14

2.5.2 Standard procedures 15

2.6 COMPLICATIONS FROM PROCEDURES USED 24

CHAPTER 3: METHODOLOGY 26

3.1 INTRODUCTION 26

3.2 STUDY DESIGN 26

3.3 STUDY POPULATION 26

3.4 INCLUSION CRITERIA 26

3.5 EXCLUSION CRITERIA 27

3.6 SAMPLE SIZE 27

3.7 DATA COLLECTION 27

3.8 DATA ANALYSIS 28

CHAPTER 4: RESULTS 30

4.1 INTRODUCTION 30

4.2 SOCIO-DEMOGRAPHIC VARIABLES 30
4.2.1 Age 30
4.2.2 Gender 31
4.2.3 Residence 31
4.3 CLINICAL VARIABLES 32
4.3.1 Site of coin 32
4.3.2 Size of coin 33
4.3.3 Elapsed time since ingestion of coin 34
4.3.4 History of symptoms reported 35
4.3.5 Clinical signs on examination 36
4.3.6 Stable condition 36
4.3.7 Complications 37
4.3.8 Length of stay in hospital 38
4.4 EXTRACTION METHODS 38
4.4.1 Foley catheter 38
4.4.2 Foley catheter outcome 39
4.4.3 Rigid oesophagoscopy procedure 40
4.4.4 Rigid oesophagoscopy procedure outcome 40
CHAPTER 5: DISCUSSION OF RESULTS 41
5.1 INTRODUCTION 41
5.2 SOCIO-DEMOGRAPHIC CHARACTERISTICS 41
5.2.1 Age 41
5.2.2 Gender 42
5.2.3 Residence 43
5.3 CLINICAL FEATURES 44
5.3.1 Location of coin or anatomic site involved 44
5.3.2 Size of coin 45
5.3.3 Elapsed time since ingestion of coin 46
5.3.4 Symptoms 46
5.3.5 Clinical signs on examination 46
5.3.6 Stable conditions 47
5.3.7 Complications 48
5.3.8 Length of hospital stay 48
5.4 EXTRACTION METHODS 48
5.4.1 Foley catheter 48
5.4.3 Rigid oesophagoscopy procedure and outcome 51
CHAPTER 6: CONCLUSIONS AND RECOMMENDATIONS 53
6.1 CONCLUSIONS 53
6.2 STUDY LIMITATIONS 54
6.3 RECOMMENDATIONS 54
7. REFERENCES 56
8. APPENDICES 61

LIST OF TABLES

Table 4.1: Age distribution (N= 95).....31
Table 4.2: Descriptive summary of time since ingestion.....35
Table 4.3: History of symptoms reported.....35
Table 4.4: Clinical signs on examination 36
Table 4.5: Stable condition observed on examination 37
Table 4.6: Upper airway obstruction.....37
Table 4.7: Length of stay in hospital.....38
Table 4.8: Foley catheter outcome 39
Table 4.9: Rigid oesophagoscopy 40

LIST OF FIGURES

Figure 4.1: Patients' residence type 32
Figure 4.2: Site of coin 33
Figure 4.3: Size of coin.....34
Figure 4.4: Extraction method 39

LIST OF ABBREVIATIONS

CXR: Chest X-ray

DGMAH: Dr George Mukhari Academic Hospital

ED: Emergency Department

ER: Emergency Room

FB: Foreign body

FC: Foley catheter

SA: South Africa

USA: United States of America

CHAPTER 1: INTRODUCTION

1.1 BACKGROUND AND SIGNIFICANCE OF THE STUDY

Foreign body ingestion is a surgical emergency condition that requires urgent attention as it can be life-threatening. Oesophageal ingestion of foreign bodies occurs most frequently in children, as reported in a retrospective study by Baral, Joshi and Bhattarai in Nepal (2010)[1]. These findings are also similar to those reported by Watson et al. (2003), in the American Poison Control Center Annual Report, where 119.323 cases of foreign body ingestion were recorded.[2] Children represent approximately 75 to 80% of the total number of patients.[2]

Children ingest all kinds of foreign bodies, such as “buttons, food, bone pieces, chocolate and toffees”. Among these, coins are reported as the most commonly-ingested foreign bodies. This observation made by Baral et al. (2010) also showed that children, more often than adults, ingested coins. These coins were often lodged in the cricopharynx.[1] Foreign body ingestion is usually an accidental event in the child population and this explains why it is so frequently encountered, as reported by Pfau (2014) at Wisconsin Medical School in Wisconsin, USA,[3] in his review on management of oesophageal foreign bodies.

The authors of several studies have reported many complications following coin ingestion, from mucosal ulceration to acute respiratory distress syndrome, especially if the child was not attended to on time and the condition was not managed

appropriately.[1-3,4,5] The list of complications, besides ulceration and respiratory distress, include certain acute complications, e.g. oesophageal obstruction, perforation, pneumomediastinum, as well as sub-acute or chronic complications such as infections and fistulas.[1-3,4,5] Death is the worst outcome condition, as reported by Baral et al.(2010) which most often occurs in an acute setting.[1]

The above facts on ingestion outcomes justify why patients with oesophageal coin ingestion require prompt diagnosis and therapy. Despite the frequency and seriousness of coin ingestion with oesophageal lodgement and several published records of such incidents, there is no consensus in the literature on the appropriate management of such patients.[1,3] The clinical history is a key element for early medical attention and assessment, given that the lack of reporting by parents has been associated with a high complication rate, as demonstrated by Lea et al. (2005) in a 2-year prospective study conducted in Haifa, Israel, done with a cohort of 98 children.[4] Long-standing respiratory manifestations with chronic cough, intermittent wheezing without a past medical history of asthma, and repeated chest infections all have a very high index of suspicion for foreign body ingestion. Notwithstanding the absence of parental reports, physicians strive to find evidence of foreign body ingestion from radiological examinations. Therefore, the delay in diagnosing patients with retained oesophageal coins, whether symptomatic or asymptomatic, has been associated with an increased risk for complications.

The next chapter will address the different management options, weighting their value on the best outcome for the patient. The readiness of the nursing staff on receiving such patients at Emergency Room (ER), the availability of the necessary emergency equipment, the diligent making of an accurate clinical assessment by the physician all these factors play an important role for an adequate management. When the diagnosis is reached, one of the management modalities are then the removal of the impacted coin with a Foley catheter. Hence its use for removal of the foreign body versus the oesophagoscopic method will be discussed in light of the existing literature.

1.2 PROBLEM STATEMENT

The ingestion of foreign bodies is among the most common presentations in a paediatric emergency department. A study conducted at the Red Cross War Memorial Children's Hospital at the University of Cape Town, South Africa, found that swallowed foreign bodies were the fifth most common cause of admission into healthcare facilities.[5] Ingested coins were the most common foreign bodies.[5] The natural anatomical configuration of the oesophagus explains why the younger the child, the more he or she is exposed to impaction after ingestion of a foreign body. As described by Waltzam[6] (2006), **"**the main anatomic locations for oesophageal coin retention are as follows:

a) Level of the crico-pharangeous; this is where foreign bodies are most frequently found and where iatrogenic perforations often occur[1,3];

b) Thoracic inlet;

c) Aortic arch; and

d) Lower oesophageal sphincter.

These anatomic areas correlate radiographically with the proximal third or crico-pharyngeal segment and the aortic thoracic inlet, the middle third or aortic arch and the distal third or lower oesophageal sphincter of the oesophagus".[6] Two methods are commonly used for the removal of oesophageal coins in children presenting at the emergency department (ED) of the paediatric department at Dr George Mukhari Academic Hospital (DGMAH), namely the Foley catheter method and the rigid oesophagoscopy. The paediatric surgical department has been using the Foley catheter method of coin extraction without fluoroscopy, even though its success rate has not been as high as the 96% reported by Harned et al. (1997) in Birmingham, Alabama, in the USA.[7] The oesophagoscopic technique is indicated as an alternative method in cases where the Foley catheter has failed.

The Foley catheter, as a method of coin extraction, is considered the best choice in patients presenting to the ED within 24 hours from the time of ingestion (as per unit protocol). However, until now, no study has been undertaken to evaluate the outcomes of those procedures at DGMAH. This study therefore aims at reviewing the clinical presentation, management and outcomes of the paediatric population that presented to DGMAH in Pretoria, South Africa, with impacted oesophageal coin, from 01 January 2009 to 31 December 2013.

1.3 AIMS AND OBJECTIVES OF THE STUDY

1.3.1 Aim of study

The study aimed to review the management of paediatric patients presenting to the DGMAH ED (also known as Emergency Centre) with impacted oesophageal coins from 01 January 2009 to 31 December 2013.

1.3.2 Study objectives

- To describe the demographics of paediatric patients that presented at the DGMAH ED with an impacted oesophageal coin;
- To describe the clinical features of paediatric patients that presented at the DGMAH ED with an impacted oesophageal coin; and
- To compare the clinical outcomes of paediatric patients that presented at the DGMAH ED with an impacted oesophageal coin and from whom a coin was extracted with the Foley catheter versus the oesophagoscopic technique.

1.4 RATIONALE FOR THE STUDY

Oesophageal coin impaction occurs frequently in children and can be a life-threatening condition. It is therefore important to make an accurate clinical assessment and to reach an exact diagnosis, so that the appropriate modality of treatment can be executed. A correct technique for the management of an impacted oesophageal coin can be performed only when these steps have been correctly observed.

The present study will determine the indications of oesophageal coin extraction in children presenting at the ED of DGMAH and to evaluate the outcome of the procedures used to treat these patients.

The Foley catheter method of removal is safe and effective and can be used by the emergency physician when a patient is seen within 24 hours of ingestion(as per unit protocol), because delay decreases the likelihood of successful removal and increases the risk of complications including risk of perforation [7]. The procedure does not require anaesthesia and is performed without fluoroscopy. Endoscopic removal of the coin is used as a second choice or if the impaction of the coin is more than 24 hours old. The endoscopic removal of the impacted coin from the oesophagus is successful in 95%–100% of cases and presents no major complications when it is performed according to a protocol.

CHAPTER 2: LITERATURE REVIEW

2.1 INTRODUCTION

A literature review was done on studies reporting on the management of oesophageal coins in children. The scope of review was limited to the last two decades (1995–2015). The literature study was done using PubMED, EMBASE, Cochrane Database of Systemic Reviews and MEDLINE. Medical theses were the major data sources. Only articles in English were evaluated.

2.2 EPIDEMIOLOGY

In a one-year retrospective study done on 21 patients in a tertiary care hospital, at BP Koirala Institute of Health Sciences in Dharan, (Nepal), it was reported that the ingestion of foreign bodies is a common problem among children who are under twelve years of age Baral[1] et al.(2010) . It is also considered to be the most common presenting case in their paediatric emergency department.[1] In spite of its small size, this study illustrates the seriousness of the problem. Similarly, a study conducted in the United States reported that the foreign bodies most frequently swallowed by children included coins and metallic foreign bodies (Watson[2] et al. 2003).

This was one of the findings in this multicentric annual report based on 64 poison centres in the USA and Puerto Rico, covering a population of 294.7 million inhabitants.[2] Likewise, in South Africa, the trauma related to foreign body ingestion was reported as one of the life-threatening conditions in children by Van As[5] et al. (2003). This study was conducted at the Red Cross War Memorial Children's Hospital at the University of Cape Town. It was also the main reported pathological condition in children under three

years. The aforementioned authors showed that ingestion of a foreign body represented 4% (n=3677) of their patients. The most commonly-ingested objects were coins (30%). The male to female ratio was 1:1, with a peak incidence at three years of age.[5]

Little et al. (2006), however, reported in an American retrospective study on 555 children in Kansas City, that boys were more prone to ingest foreign bodies than girls were and that coins were the most commonly found objects besides “round batteries, rings, keys, fish bones, tacks, nuts, washers and pins”.[8] The same study also found that the upper oesophagus segment was the most common anatomic site of impaction as it represents the narrowest segment of the alimentary tract in children.[8-10]. This observation was also reported in a retrospective study on 113 children in North Carolina McNeil et al.,(2012).[9] Moreover, this later study reported that coin ingestion affected young children most often, and mostly boys.[9] Although there is evidence indicating the seriousness of this problem, the number of reports emerging from the developing world, particularly from South Africa, is limited.

The oesophagus is the alimentary tract through which food progresses by ante-grade peristaltic contractions. Regurgitations and vomiting continuously occur as preventive physiologic mechanisms against gastric content reflux, provided that both the upper and the lower portions act synergistically. Some medical pathological conditions, e.g. dysphagia and gastro oesophageal reflux, are described when this anti-reflux mechanism is impaired.[6]

Four oesophageal narrowings are described by Waltzman (2006), namely, the proximal oesophagus at the cricopharynx, the mid-oesophagus at the level of the carina and

aortic arch, the left main bronchus compression and the distal oesophagus, slightly proximal to the gastro-oesophageal junction.[6]

2.3 RISK FACTORS OF RETAINED COINS

According to Smith and Wong (2006), factors that increase the risk of oesophageal foreign body impaction include: "male gender in older children[11], underlying oesophageal stricture[7-9], neuromuscular disease like myasthenia gravis[11], lack of molars before age 4 years[10], seizure disorders, immature laryngeal sphincter control, an unsafe environment, mental retardation, psychiatric illness, while oral curiosity is the major cause of foreign body ingestion in the paediatric population".[1, 3,10]

Patients with retained oesophageal coins, whether symptomatic or asymptomatic, are at risk of complications. These include mucosal ulceration, inflammation, oesophageal perforation, oesophageal aortic fistula formation, tracheo-oesophageal fistula, respiratory distress with or without associated cyanosis, and the potential progression to death.[1, 6, 7]

2.4 DIAGNOSTIC APPROACH

Any life-threatening medical or surgical condition prompts a rapid assessment and subsequently appropriate management.

2.4.1 History

The first assessment of patients with oesophageal foreign body obstruction typically takes place in the ED where the physician will prioritise and guide further

management.[12] Patients' presentations may be grouped according to the history of early or late foreign body ingestion whenever such information is available.

2.4.2 Clinical presentation

In medicine, it is common knowledge that sound management is always preceded by recording a thorough medical history that subsequently leads to a diagnosis based on physical examination findings and confirmatory investigations. Foreign bodies have various clinical presentations. Asymptomatic patients account for approximately 40 to 50%, as reported by Chauvin et al. (2013) in a retrospective multidisciplinary study conducted in Paris, France.[13] These authors conceded in their literature review that the prevalence of foreign body ingestion did not include all the cases of patients with communication disorders or those suffering from psychiatric disorders, even though mental illnesses are not as common in children as in adults.[13]

2.4.2.1 Symptoms and signs

Medical history and clinical examination can assist in making a diagnosis, as indicated by Miller et al. (2003) in a retrospective study done at Cincinnati Children's Hospital Medical Center (CCHMC), USA[14] and in London a prospective study that included 388 patients (Jones et al., 1991).[15] Triadafilopoulos et al. (2013) from Stanford University in the USA, in a multivariate analysis with 90 patients titled "Update on foreign bodies in the oesophagus: diagnosis and management", reported that the dysphagia and odynophagia were the most frequently-observed symptoms.[12] In the same study, symptoms like chest pain and the pooling of saliva that manifest in minutes to hours

following foreign body ingestion, and certain foreign bodies, were observed in younger children; only years later, on account of recurrent chest infections. Other symptoms reported were regurgitation and hiccups.[12] This study also found that partial obstruction was associated with cases of dysphagia whereas complete obstruction was found in the presence of the inability to swallow. Oesophageal laceration or perforation was suspected in the presence of odynophagia, while tracheal compression was the most likely cause in the presence of wheezing, stridor or choking. These symptoms and signs were associated with a foreign body entrapment in the hypopharynx, the trachea, the pyriform sinus or Zenker's diverticulum.[12]

Miller et al. (2004) in a clinical review on 522 children in Cincinnati, Ohio, USA, reported that patients can be classified into two distinct groups: the respiratory and the gastrointestinal.[14] In the respiratory group of patients, the most commonly-recorded symptoms were coughing and short and laborious breathing. On assessment, upper respiratory infections and/or asthma were the main findings. In patients with digestive complaints, nausea, vomiting, dysphagia and/or odynophagia were the most common symptoms. On examination, an abdominal distension, painful palpation and reduced bowel sounds were more prominent.

It is challenging for both emergency and family physicians to establish the diagnosis of an impacted oesophageal coin, given that patients often present with respiratory symptoms and signs suggesting a respiratory distress syndrome, including, severe upper respiratory tract infection or an acute asthmatic attack (Lea et al., 2005).[4] In a

predominantly digestive context, the differential diagnosis is equally difficult because one can assume a paralytic ileus or an acute abdomen due to a perforation. However, Lea et al. (2005) have reported choking and intermittent cough as the main respiratory symptoms. Patients' clinical manifestations can be correlated with neither the socioeconomic conditions nor the educational level of the parents.[4] Studies have also indicated that foreign body ingestion is commonly accidental in younger children and occurs most often at home.[4, 9]

2.4.3 Investigations

Investigations help in confirming the diagnosis. Baral et al. (2010) described their way of conducting diagnostic investigations in the case of foreign body ingestion.[1] These researchers start first by using a simple tool like a tongue depressor with or without a laryngeal mirror. When this preliminary check fails, they then proceed to the use of a flexible endoscope and pharyngo-laryngoscope in order to visualise the entrapped foreign body. Patients under such investigations are assessed in theatre.[1]

A series of radiological investigations is always performed in the case of foreign body ingestion. These include, chest and abdomen x-rays, endoscopic manipulations for diagnostic purposes, chest computerised tomography scan and barium studies. A chest X-ray is always recommended in case of ingestion together with a biplane cervical X-ray. They show the localisation, especially when the foreign body is radiopaque, such as in coin ingestion. In a study by Chauvin et al. (2013), patients seen at Lariboisiere Hospital, Paris University, France, systematically receive a chest, abdomen (antero-

posterior and lateral) and cervical X-ray as first investigative methods.[13] Chauvin et al.(2013) emphasised the need to recognise the radiographic airway landmarks on posterior-anterior and lateral chest radiographs.[13] This is helpful in making the differential diagnosis between the trachea-bronchial and the oesophageal foreign bodies.[8] Another key element is the establishment of the difference between the coins and the batteries by using the border aspect of the coin, that is either smooth or irregular, while in batteries there are two concentric circles.[11,14]

When fluoroscopy was performed, the same authors diagnosed “mediastinal shift more often than paradoxical movements of the diaphragm”.[4] These clinical findings tend to be exacerbated in late presentation, recorded in patients seen beyond 24 hours following the event.[4] This investigation has been favoured by some authors,[13,14] although it has a low specificity as reported by Lea et al (2005).[4]

Endoscopic exploration can be performed under general anaesthesia on a patient with an empty stomach. The endoscope helps in visualising the foreign body and this allows the surgeon to make the diagnosis.[4] Endoscopic utilisation relies on varies sizes of endoscopes. In children aged one year or less, a smaller endoscope with an external diameter inferior to 6 mm is the preferred size[11] as is also demonstrated by Chauvin et al. (2013) in Paris, France.[13] Anatomical constitution – although not explicitly stated – of these children younger than one year old would logically be the rationale behind this indication of an endoscope with a diameter of less than 6 mm. In the review of management of impacted objects and food, these authors have focused on endoscopic

procedures, indicating the guidelines related to different age groups in the child population and, for that matter, also in adults.[11]

As for the computerised tomography scan, it is rarely indicated as radiographic investigation, and endoscopic investigations usually confirm the diagnosis of an opaque foreign body.[11] Chauvin et al. (2013) advised against performing barium studies in the presence of perforation. They also refuted the use of hypertonic contrast agents, and warned about the risk of acute pulmonary oedema if aspiration occurs.[13] In any case, endoscopic exploration should always be done prior to contrast studies otherwise they may impair endoscopic views.[9]

2.5 MANAGEMENT

Foreign body ingestion, as in any condition, should be managed to ensure the patient's full recovery.

2.5.1 Medical management

Medical options are available for the removal of a foreign body, from observation to pharmacological therapy using glucagon, as indicated by both Smith and Wong (2006) in their study[11] as well as Khan (2006), from Karachi in Pakistan, in his review of articles on foreign bodies in the oesophagus.[16]

From these authors' perspective, no patient needs treatment when the foreign body is radiolucent because it is assumed that it has already passed the oesophagus.[11,16] To

further confirm these retrospective conclusions, a prospective randomised control study from the Children's Hospital in Boston, Massachusetts, by Waltzman et al. (2006) confirmed the importance of coin localisation.[6] This is the factor that determines the passage out of the oesophagus, rather than the size of the coin. This passage happens within 6–10 hours in 75% of cases and can be far longer, up to 19 hours, in the remaining cases. Smith and Wong (2006) demonstrated the use of glucagon in food oesophageal impaction. These authors have indicated the complications seen in their study without specifying the failure or success rate.[11] Pharmacological usage of glucagon is justified by the myorelaxant effect of the glucagon on the lower oesophageal sphincter, inducing an easy downwards progression of the foreign body. Most commonly these are solid foreign bodies, such as food particles. When a coin is concerned, a standard dose for intravenous administration of glucagon of 1–2 mg is used, to be repeated 5–10 minutes later if necessary. The side effects are dose dependent with nausea, vomiting and hyperglycaemia indicated in rapid drug injection. The authors, having used this medication, confirmed that there is no drug interaction but they cautioned on the contraindications such as known hypersensitivity, insulinoma, pheochromocytoma and Zollinger-Ellison syndrome.[11]

2.5.2 Standard procedures

There are various methods for the management of both symptomatic, as well as asymptomatic ingested oesophageal coins, both surgical and non-surgical. These include: extraction utilising a Foley catheter; oesophageal bougienage; use of Magill forceps; and endoscopy. Endoscopes may be flexible or rigid but the latter is more often

used, especially in complicated cases and for sharp objects. All these techniques have advantages as well as real and potential complications.[5, 16]

Baral et al. (2010) suggested seven sequential steps in the management of oesophageal coin obstruction. They recommended the following:[1]

> "Immediate evaluation of the airway;
>
> Assessment of the urgency of removal;
>
> Radiological evaluation to localise the object;
>
> Medical management, Foley catheter removal;
>
> Endoscopic retrieval when using retrieval instruments, like basket devices;
>
> Monitoring for complications; and
>
> Endoscopic therapy (rigid or flexible oesophagoscopy) and/or surgery".

2.5.2.1 Foley catheter technique and indications

Two methods are commonly used for the removal of oesophageal coins in children presenting at the DGMAH paediatric surgical department: the Foley catheter and the rigid oesophagoscope. From an historical perspective, the first removal of an oesophageal foreign body hails from the seventh century, where a string attached to a sponge was used. It was ingenuously performed by a Greek physician in 690 AD. Indeed, Paulus Aegineta, the Greek physician, would request a patient to swallow a string attached to a dry sponge, slide it as far into the stomach as possible, and slowly withdraw it, sometimes together with the ingested foreign body. There is no specific

reference attached to this procedure even though it was used for impacted fish bones, for example.[17]

Thereafter, the management was to use a rigid oesophagoscope until 1966 when Bigler, cited by Mariani (1986), reported a new technique.[17] He is accredited with the first use of the Foley catheter and the technique became popular in the late 1970s, with its indication initially limited to large radiopaque objects, found in adults. Bigler reported on only two cases of successful removal of an ingested coin, indicating that the balloon had to be inflated beyond the impacted foreign body for it to dilate enough in the oesophagus and permit a safe extraction.[17]

The technique for extraction of coins using the Foley catheter is simple, provided that it is performed on an immobilised child, as recommended by Little et al.[8] Under that prerequisite, it does not require anaesthetic and the size of the catheter is determined by the patient‘s age and his or her physical structure. A 10F or 12F catheter is inserted orally or nasally just behind the coin and gently pushed into the stomach, then the balloon is inflated with 5 ml water. The patient is placed in the lateral decubitus, or prone oblique steep Trendelenburg position.[7, 8] The catheter is then gently pulled, applying a steady traction. The balloon is used to push the coin ahead. The coin is expectorated, or removed from the mouth, using forceps or a tongue depressor or even a finger sweep.[8,17]

In the Foley catheter technique with fluoroscopy, diluted barium is used instead of water.[10,17] The catheter is advanced past the coin and the balloon is filled with barium. Under fluoroscopy, it is then advanced under visual control and ideally in a fluoroscopy room; the physician can then manually remove the foreign body wearing a protected bite block on his or her finger. At the end of the procedure, the catheter is removed, bringing the coin with it. Care must be taken to ensure the patient does not aspirate the coin during its removal, irrespective of what is used to fill the balloon.

Hence, when it is in good hands, the Foley catheter is successfully used and does not require anaesthetic. Moreover, it is less costly than other methods. As with any technique, it has its limitations, including lack of direct visualisation of the oesophagus and a lack of direct protection of the airway. The use is contraindicated in the presence of repaired peptic structure, a vascular ring and esophagitis.[8,17] Besides the above contraindications, many authors recognise that it is generally not recommended to use the Foley catheter for impacted coins that were ingested more than 24 hours earlier(as per protocol) or in the presence of oesophageal abnormality, such asoesophageal atresia, even after it is repaired.[8,17] The use of the Foley catheter after 24 hours have passed has been responsible for aggravating the already existing oesophageal oedema formed owing to the duration of the impaction.[7,17-19]

Many studies have reported fairly good results with the Foley catheter as device for the dislodgement of an impacted oesophageal foreign body. Under fluoroscopy, the success rate has been more than 90%.[3,7,8, 17] According to Harned, Strain, Hay et al.

(1997) in their retrospective study over 10 years, the use of the Foley catheter fluoroscopically guided was successful in 322 (96%) cases of 337 patients.[7]

The technique used in manipulating the Foley catheter in the centre at DGMA where this study was conducted does not differ from the above description. Little et al. (2006) stressed the fact that two attempts must be allowed and the procedure be abandoned in case of failure. In that instance, a rigid oesophagoscope must be used in theatre under general anaesthesia.[8] Their study had an overall success rate of 88%. The 12% failure was due to the smaller calibre of the oesophagus in children between one and two years of age, as well as the delayed diagnosis in non-verbal infants. The latter may result in increased oesophageal oedema from the impacted foreign body.[17]

2.5.2.2 Endoscopy

Lin et al. (2007) reported a 100% success rate for removing the coin from the oesophagus by endoscopy (not specified if flexible or rigid) at the China Medical University Hospital in Taiwan.[18] Chauvin et al. (2013) at the University of Paris, France, found that a flexible oesophagoscope yields better results than a rigid one and therefore they recommended it in cases of a soft impacted foreign body.[13] This method was not used in impacted coins. These researchers further indicated that the complication rate was higher with the rigid oesophagoscope (10%) than with the flexible one, as reported in other studies (5%).[8,17-24]

From Pfau's (2014) experience in Wisconsin, USA, the flexible endoscopy has become the diagnostic and the treatment method of choice for oesophageal foreign body extraction because of the high success rates and low complication rates.[3] A comparison of rigid versus flexible endoscopy in the treatment of oesophageal foreign bodies found significantly fewer perforations with a flexible endoscopy.[3] The complication rate of endoscopic treatment of gastrointestinal foreign bodies ranges from no complication reports in most studies to 1,8%.[3] The most serious complication associated with endoscopic (rigid) removal of foreign bodies is oesophageal perforation. Other complications reported are gastrointestinal bleeding, aspiration and cardio-pulmonary complications secondary to sedation.[3] Flexible endoscopy remains the standard of care for patients with blunt foreign objects in the oesophagus[10] but the rigid endoscope is the method of choice for sharp objects, according to Morrow et al. (1998).[19]

2.5.2.3 Flexible versus rigid oesophagoscopy

There is no consensus on the use of either flexible or rigid oesophagoscope. The rigid oesophagoscope was the first one used by Bigler.[17] It has, however, a risk of perforation even though it has the advantage of protecting the airway at the same time. The flexible oesophagoscope is easy to manipulate, cost effective and is indicated for small objects of less than 2 cm long and with a diameter less than 3 cm .[25] It can even be used in the physician's room, without need of anaesthesia.[23] Hence, the choice of rigid oesophagoscopy versus flexible depends on only a few criteria: the surgeon's preference, the size of the foreign body and the cost.[24,25-27]

2.5.2.4 Retrieval devices

As indicated in their study in 2006, Smith and Wong also mentioned rat-tooth or alligator forceps and the retrieval net as the best tools for coin removal. Round objects, such as discs or button batteries, are best captured using the retrieval net. [11] In this report, the success or failure rate is not mentioned. The cost of retrieval graspers and basket devices is 3-fold compared to the retrieval net and retrieval forceps.[13]

2.5.2.5 Bougienage

The bougienage technique consists of using a dilator so that the impacted coin can be pushed into the stomach. A study by Smith and Wong (2006) reported a remarkable success rate (100%) in 46 patients who presented within 24 hours of the ingestion of the coin.[11] A study in the USA by Arms, Bowen et al. (2008) on a larger sample of 372 children in a 12-year period revealed a 95% success rate using the bougienage technique.[26] It is a safe technique when performed under supervision, so any medical staff from the physician to the nurse can do it.[24,26] It has clear criteria, e.g. witnessed single-coin ingestion, no previous coin ingestion and no prior surgery.

An X-ray is taken at the beginning and the end of the procedure as proof that the coin was localised and that it has been safely removed. A lubricated Hurst oesophageal dilator is used after measurement of the correct length from the mouth to the oesophagus. The application of topical anaesthesia to the posterior pharynx is optional.

The dilator is then passed to the measured depth and removed rapidly. No general anaesthesia is required in a child wrapped in a sheet and held in bear-bag fashion. Either a parent or a nurse can hold the child. A bougienage is indicated in the following circumstances: witnessed single-coin ingestion; duration of less than 24 hours ingestion before medical assessment; a confirmatory X-ray indicating localisation of the coin; no previous history of surgery or previous ingestion of foreign bodies. Its limitations are absence of data on pain control or satisfaction at discharge.[11]

2.5.2.6 Penny pincher

Coins can also be removed by the penny pincher, which is a new device described by Smith and Wong (2006). The method involves “placing an endoscopic grasping forceps through a soft rubber catheter from which the end has been cut off. The device is passed orally through a bite block without sedation, using fluoroscopic observation”. In their series of 19 patients, they had a 100% success rate without any complications.[11]

The limitation of these two techniques – the bougienage and the penny pincher – is the combination of limited expertise and material resources in many centres, besides the fact that neither the bougienage nor the penny pincher allows for the inspection of the mucosa.[10,11]

2.5.2.7 Magill forceps

The Magill forceps technique has previously been used to extract coins from the upper oesophageal tract of child patients by paediatric surgeons (Janik, 2010) and ortholaryngologist (Mahafaz, 2010), cited by Baral (2010), under endotracheal intubation with propofol.[1] No complications were reported in these two series. Baral et al. (2010) suggested that coins impacted at the cricopharyngeal area and the upper oesophagus would be easily and safely dealt with by using Magill forceps or Foley catheter following one of the techniques described above.[1] Furthermore**,** there were no immediate or late complications observed following this procedure. The results were remarkably good as there was no mortality or morbidity even though the main limitation was its small size. In their centre in Nepal, the team was composed of an endoscopist, an ENT surgeon and a thoracic or paediatric surgeon. Conversely, in the settings where this present study was conducted, there was no technician specifically trained as an endoscopist. In this case, the task was in the hands of either the ENT surgeon or the paediatric surgeon.

Magill forceps is a familiar tool in the anaesthetist's hands. It is a safe and efficient alternative to flexible and rigid oesophagoscopy for the removal of impacted upper oesophageal coins. It has been the most-used tool in some health facilities, e.g. in rural hospitals in Nepal, where resources are scarce.[1]

2.5.2.8 Surgical interventions

Surgery is the last resort when dealing with impacted foreign bodies. It is indicated principally for sharp foreign bodies. Prior to surgical intervention, one must document a failed endoscopic removal, an arrested progression of the object through the intestinal tract and the presence of perforation, obstruction or bleeding.[1]

2.6 COMPLICATIONS FROM PROCEDURES USED

Reported complications following the use of rigid oesophagoscopy include: neck swelling, cervical crepitation, and pneumomediastinum. These complications arise due to oesophageal perforation during the extraction process.[13] In addition, bronchospasm and mucosal abrasion have also been reported by McNeil et al. (2012)[9] from the University of Carolina, USA. However, these were documented in less than 3% of their cases.[25] Studies made in France and the USA have also reported rigid oesophagoscopy complications that include ulcers (21%), lacerations (14.9%), erosions (12.0%) and perforation (1.9%).[12,13]

The use of the Foley catheter can also lead to serious complications. Aspiration is one of these complications, especially when the child is uncooperative. Hypoxia is an even a more alarming medical condition and is secondary to the inflated balloon that obstructs the trachea. However, these complications are more closely related to the manipulation of the catheter itself. Authors have then recommended that the procedure be performed by more expert hands to avoid the above complications.[8, 13] In other words, the more

experienced and accustomed to the technique the physician is, the fewer complications will be experienced.

Finally, some pre-existing complications have been seen only during surgical removal of foreign bodies, such as “the presence of granulation tissue, mucosal erosion, perforation and tracheo-oesophageal inflammation”.[12,13] Nevertheless, irrespective of patients’ complaints, either respiratory or gastrointestinal, mucosal inflammation and tracheal narrowing were the most common complications in the group of patients with respiratory complaints.[27-30] In patients with gastrointestinal complaints, mucosal inflammation and technical oesophageal perforation were the complications most often encountered.[5,8,12,24] Respiratory failure and upper airway obstruction have also been reported as post–operative complications; they are managed through intubation ventilation support, leading to pneumonia and lung atelectasis.[14]

Rarely reported in many studies, fistulas such as aorto-oesophageal and bronchoesophageal, as well as, oesophageal diverticulum, mediastinitis, pulmonary oedema and lobar atelectasis are also possible complications.[13,18]

CHAPTER 3: METHODOLOGY

3.1 INTRODUCTION

This chapter discusses the material and methods used to achieve the objectives of the study. Thus the following sections are discussed: study design; setting; data collection tools; data analysis; and data presentation approach.

3.2 STUDY DESIGN

This study is a retrospective transverse descriptive study using the medical records of paediatric patients who were treated at DGMAH for coin ingestion with oesophageal impaction for the five years ranging from 01 January 2009 to 31 December 2013.

3.3 STUDY POPULATION

The study population comprised of paediatric patients that presented at the DGMAH ED with an impacted oesophageal coin. This being a record review study, the information was accessed in the patients' records for a period of five years from 01 January 2009 to 31 December 2013.

3.4 INCLUSION CRITERIA

All patients aged 12 years or less who presented with a diagnosis of oesophageal coin and who underwent an attempted extraction of the foreign body were included.

3.5 EXCLUSION CRITERIA

The following patients were excluded:

- Patients with coins that passed to the stomach;
- Patients aged >12 years;
- Patients with oesophageal foreign body other than a coin; and
- Patients without accessible medical records

3.6 SAMPLE SIZE

There was no sampling; instead a review of all cases was done retrospectively based on the information in the medical records. An estimated 95 paediatric patients who presented to the DGMAH ED over a period of five years constituted the study population.

3.7 DATA COLLECTION

A designed data collection form was used (Appendix 1). The following data was collected from the patients' files by the investigator using a data extraction sheet;

1. Socio-demographic variables such as age, sex and home circumstances.

2. Clinical variables that include:

    - Location of coin or anatomic site;
    - Type of coin;

- Time elapsed since ingestion of the coin;
- History and related symptoms: vomiting, fever, coughing, respiratory distress, drooling saliva, dysphagia, refusal to eat, agitation, chest pain;
- Physical signs as noted by the clinician, and associated morbidity; and
- Complications before and after removal of coin: respiratory distress, gastrointestinal perforation, pneumothorax, pneumonia, and tracheo-oesophageal fistula.

3. Eventual outcomes: Outcomes were assessed for their usefulness. If there was a complication, its nature and the number of days of hospitalisation were recorded, as follows:

- With Foley catheter; and
- With rigid oesophagoscopy.

3.8 DATA ANALYSIS

The data collected in the study was captured in a Microsoft® Excel® spreadsheet. Data capturing was verified and edit checks were performed. Data was typically presented in the form of tables or figures.

Statistical analyses were performed on SAS® (SAS Institute Inc, Carey, NC), Release 9.3, running under Microsoft® Windows® for a personal computer. The following

procedures were used: PROC FREQ for frequency calculations; PROC MEANS for calculation of mean, standard deviation, minimum and maximum values. The normal approximation of the z test was used for significance testing involving percentages. P values ≤ 0.05 were considered significant. Graphs were done on Microsoft® Excel®.

CHAPTER 4: RESULTS

4.1 INTRODUCTION

In this chapter, the findings are presented in details, based on the objectives for the study. The present study population comprised of 95 children from DGMAH in Pretoria. The study reviewed the management strategies of oesophageal coin ingestion based on the records of patients admitted to the paediatric emergency department with a history of coin ingestion. This chapter presents the analysis and interpretation of data.

4.2 SOCIO-DEMOGRAPHIC VARIABLES

In this section the socio-demographic variables of the patients presenting with oesophageal coin lodgement from 01 January 2009 to 31 December 2013 are discussed.

4.2.1 Age

The age of the patients ranges from 7 months to 10 years, with a median age of 3.0 years. Of the 95 patients treated for oesophageal coin ingestion, 69 patients (72.6%) were younger than 5 years compared to 26 patients (27.4%) that were older than 5 years (table 4.1). The peak age in this study was 3 years.

Table 4.1: Age distribution of patients (N= 95)

Years	Number (%) patients
<5	69 (72.6)
≥5	26 (27.4)
Total	95 (100)
Median	3.0
Interquartile range	2 – 5
Min / Max	0.70 / 10.00

4.2.2 Gender

Of the 95 patients, 51 (53.7%) were female and 44 (46.3%) were male.

4.2.3 Residence

Most of the patients (77; 81.1%) resided in informal settlements (squatters), while 18 patients (18.9%) lived in formal middle-class residential areas, as represented by Figure 4.1.

Figure 4.1: Patients' residence type

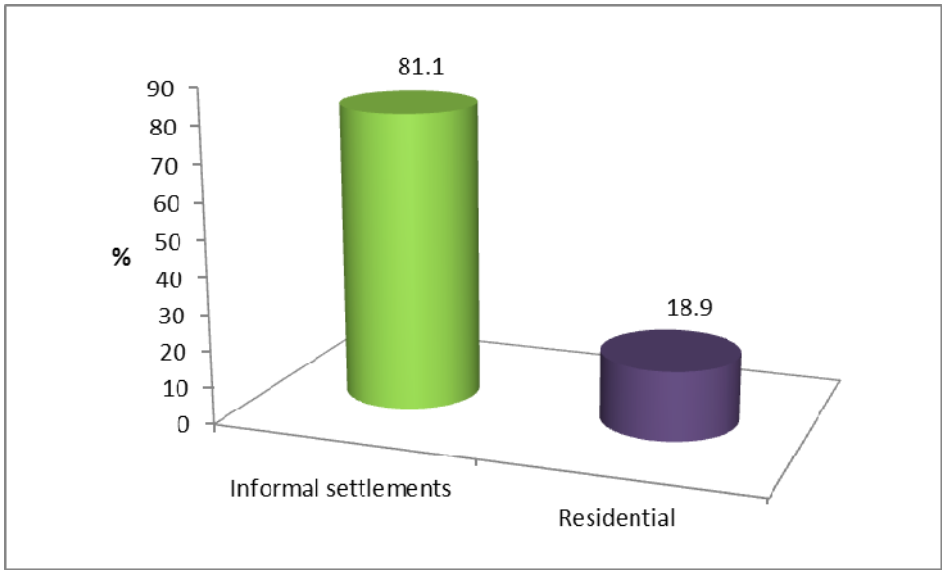

4.3 CLINICAL VARIABLES

4.3.1 Site of coin

Coins lodged in the oesophagus were mostly located in the upper oesophagus (71.6% of cases), with 20%, and 8.4% presenting with coins lodged in the middle and lower oesophagus respectively, as illustrated in Figure 4.2.

Figure 4.2: Site of coin

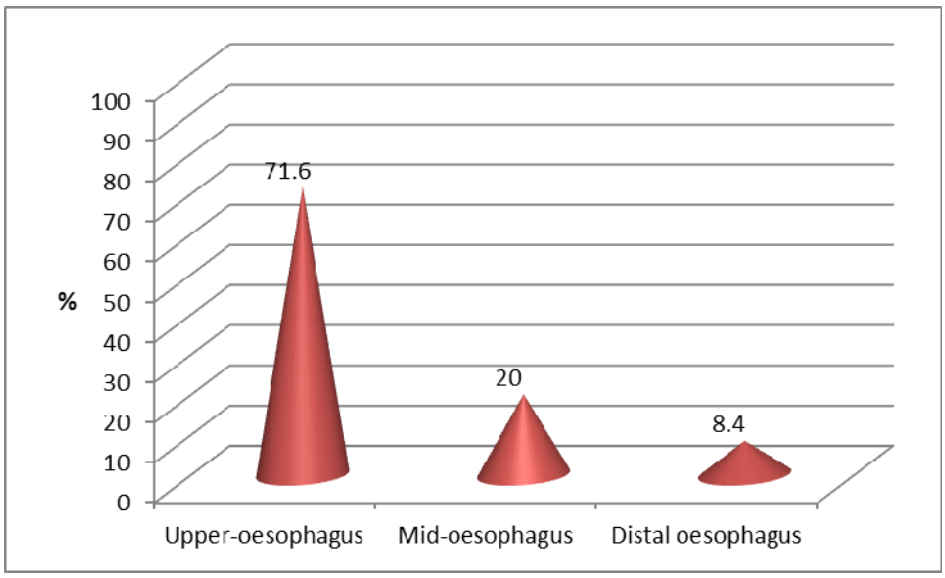

4.3.2 Size of coin

The most commonly-impacted coin was a 22mm (50c) coin, which occurred in 23 patients (27.4%), followed by a 21mm (5c) coin, occurring in 21 patients (25%) and, finally, a 23mm (R2) coin in 17 patients (20.2%), as illustrated in Figure 4.3.

Figure 4.3 Size of coin

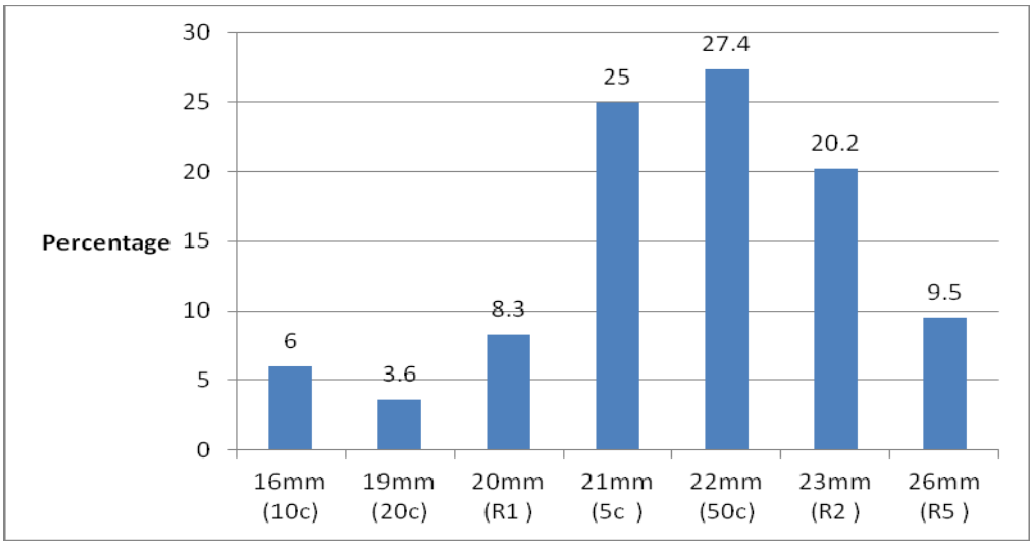

4.3.3 Elapsed time since ingestion of coin

Thirty-five children (42.7%) presented before 8 hours after the ingestion of the coin had elapsed. Among the sample size, 47 (57.3%) presented 8 hours after the coin was ingested.

In 82 patients, the time of ingestion was accurate. The median time was 8 hours, with the minimum time of 1 hour and the maximum time of 120 hours. The results are presented in table 4.2.

Table 4.2: Descriptive summary of time since ingestion

Time since ingestion, in hours	
N	82
Median	8
Interquartile range	5 – 15
Min / Max	1 / 120

4.3.4 History of symptoms reported

Vomiting, chest pain, refusing to eat and dysphagia were among the presenting symptoms in a minority (13.7%) of patients, with the majority (86.3%) being asymptomatic. These results are represented in table 4.3.

Table 4.3: History of symptoms reported

Symptom reported	Number (%) patients*
None	82 (86.3)
Vomiting	4 (4.2)
Pain in chest	3 (3.2)
Refuse to eat	2 (2.1)
Stomach ache	3 (3.2)
Dizziness	1 (1.0)
Total	95 (100)

*None reported more than 1 symptom

4.3.5 Clinical signs on examination

The most commonly-observed signs of oesophageal coin lodgement were hypersalivation (17 patients, i.e. 17.9%) and vomiting (8 patients, i.e. 8.4%). In 66 patients (69.5%) no signs were observed and they were comfortable. Four patients were not comfortable. These signs are presented in table 4.4.

Table 4.4: Patient's Clinical signs on examination

Signs observed	Number (%) patients
None	66 (69.5)*
Agitated patient	1 (1.0)
Symptoms of stridor	3 (3.2)
Vomiting	8 (8.4)
Drooling saliva	17 (17.9)
Total	95 (100)

*None reported more than 1 symptom

4.3.6 Stable condition

Eighty-seven patients were stable (95.6%), compared to four (4.4%) not stable (unstable condition implies patients with airway compromise), as illustrated in table 4.5.

Table 4.5: Stable condition observed on examination

Stable condition observed*	Number (%) patients
Yes	87 (95.6)
No	4 (4.4)
Total	91 (100)

*Unstable condition implies patients with airway compromise.

4.3.7 Complications

Among the 87 patients, no complications were observed before removal. Four patients experienced discomfort owing to airway obstruction before removal, which was released after the removal of the coin. Reports do not specify whether or not there were complications in four patients. There were no major complications, such as perforation. Instances of upper airway obstruction before and after the removal of the coin are shown in table 4.6.

Table 4.6: Upper airway obstruction

Condition	Number (%) patients	
	Before removal	After removal
None	87 (95.6)	89 (100)
Upper airway obstruction (partial)	4 (4.4)	-
Total	91 (100)	89 (100)

4.3.8 Length of stay in hospital

A total of 37 patients (39%) were hospitalised for one day for further observation. The range of the length of hospitalisation was between less than 24 hours to six days, as illustrated in Table 4.7.

Table 4.7: Length of stay in hospital

Length of stay in hospital	Number (%) patients
< 24 Hours	20 (21.1)
1 Day	37 (39.0)
2 Days	25 (26.3)
3 Days	8 (8.4)
4 Days	2 (2.1)
5 Days	1 (1.0)
6 Days	2 (2.1)
Total	95 (100)

4.4 EXTRACTION METHODS

4.4.1 Foley catheter

The Foley catheter was solely used in 48 patients (50.5%) and the rigid oesophagoscopy was first used in 33 patients (34.7%). In 14 patients (14.8%), both Foley catheter and rigid oesophagoscopy were used, as shown in figure 4.4.

Figure 4.4: Extraction method

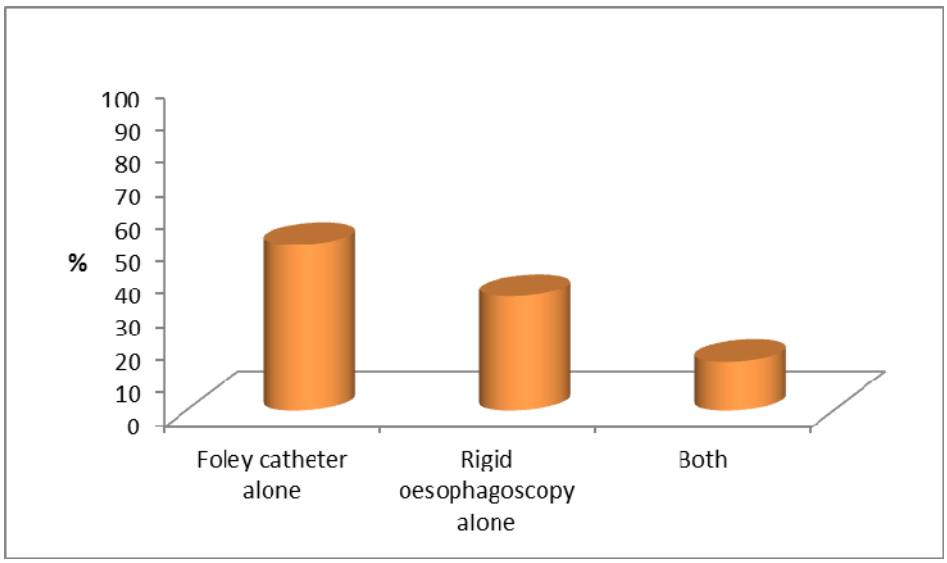

4.4.2 Foley catheter outcome

The Foley catheter was used in 62 patients in total and was successfully used to remove the coin in 48 patients (77.4%), but was not successful in 14 (22.3%) of patients, as shown in table 4.8.

Table 4.8: Foley catheter outcome

Foley catheter outcome	Number (%) patients
Successful	48 (77.4)
Not successful	14 (22.6)
Total	62 (100)

4.4.3 Rigid oesophagoscopy procedure

Rigid oesophagoscopy was used in 47 patients (49.5%), as shown in table 4.9.

Table 4.9: Rigid oesophagoscopy

Rigid oesophagoscopy	Number (%) patients
Yes	47 (49.5)
No	48 (50.5)
Total	95 (100)

4.4.4 Rigid oesophagoscopy procedure outcome

Rigid oesophagoscopy was applied to 47 patients but removal of the coin was not necessary in 3 patients as it was found during oesophagoscopy that the coin had already moved into the stomach. Rigid oesophagoscopy was successful in the remaining 44 patients (100%) to whom it was applied.

CHAPTER 5: DISCUSSION OF RESULTS

5.1 INTRODUCTION

This was a retrospective, transverse, descriptive hospital-based study on the review of the management of oesophageal coin ingestion in paediatric patients who were treated at DGMAH during a period of five years from 01 January 2009 to 31 December 2013.

A total of 95 patients constituted the study sample. The medical records of all paediatric patients that presented to DGMAH and underwent an attempted extraction of coin impacted in the oesophagus were included. Patients with a coin that had passed to the stomach, patients aged > 12 years, and patients with any object other than a coin were excluded from the study.

5.2 SOCIO-DEMOGRAPHIC CHARACTERISTICS

5.2.1 Age

This study has shown that coin ingestion was more common in patients between 0 to 5 years of age. The median age was 3.0 years , which was comparable to the mean age reported in a study conducted at the Red Cross War Memorial Hospital in Cape Town by Van As et al. (2003).[5]

The results of the present study were also comparable to those of Baral et al. (2010) on removal of coins from the upper oesophageal tract in children with a Magill's forceps under propofol sedation.[1] In the study done at DGMAH, the age ranged from 7 months to 10 years. Lin et al. (2006) reported similar findings (6 months to 13 years) with a

mean age of 3.4 years in a study on the endoscopic removal of foreign bodies in children, conducted in a tertiary hospital in Taiwan.[18]

The reason for the ingestion of foreign bodies in children is mostly related to a child's behaviour. In their curiosity, children tend to explore everything with the mouth and coin ingestion is therefore predominantly a problem of the paediatric age group as described by Baral et al. (2010) in Nepal.[1] This curiosity ultimately exposes children to easy ingestion of foreign bodies, explaining why there are more children less than 5 years in our sample study. Children are often seen walking and playing while eating and this tendency puts them at risk for oesophageal ingestion,or tracheobronchial aspiration.[1, 3, 10, 19-28]

The age distribution found in this study is consistent with a worldwide trend and preventive measures should thus include children of all ages from 7 months up to at least 10 years. Holcomb[10] et al. (2010) found that 22% of children with oesophageal foreign bodies and older than 5 years, had anatomical abnormalities. In the present study anatomical abnormalities were unspecified in the patients' records and it cannot be confirmed that there was any previous oesophageal pathology in any patient that could have constituted a real risk factor to impaction of a foreign body.

5.2.2 Gender

In the present study, coin ingestion was found in 51 female children (53.7%) and in 44 male children (46.3%) with boy to girl ratio of 1:1 equal. Research conducted by Van As

et al. (2003) at Red Cross War Memorial Children's Hospital of the University of Cape Town on oesophageal coin ingestion showed that both sexes were equally affected (boys 49%).[5]

Al-alawneh et al. (2014) at Taibah University in Pakistan reported in a study on 34 cases of foreign body ingestion between December 2012 and May 2013, 52,9% females and 47,1% males.[27] These findings are in line with the findings of this present study. Pokharel et al. (2008) in a retrospective research report of 122 cases conducted from April 2004 to July 2008, at TU Teaching Hospital Kathmandu in Nepal, reported a male predominance of 67% but no explanation for the high incidence of a foreign body in male children was given.[20] It is also thought that boys are prone by their temperament to be more playful and curious to explore the universe around them than girls are (Baral et al., 2010).[1] One of the ways to do so is with their mouths.[1,20] From the findings of this study, it seems that age rather than gender predisposes the child to ingestion. As a result, prevention should target the age of a child, and not only the gender.

5.2.3 Residence

The present study showed that 77 patients (81.1%) originated from informal settlements, also known as squatter camps, which comprise the lowest socioeconomic class; 18 patients were in the middle class (18, 9%). The high incidence among the lowest socioeconomic patients may be explained by the lack of toys which prompt children to play with coins, as reported by Van As et al. (2003) in a study conducted in Cape Town[5] and by Al-alawneh et al. (2014) in a Pakistani study.[27] Van As et al.[5]

observed that it appears that children in a rural environment have minimal access to toys in comparison with their counterparts in urban areas. They should therefore be under greater surveillance in order to prevent them from ingesting coins.[5, 28] The researcher agrees with this observation even though this aspect was not specifically considered in this study.

The findings of Al-alawneh et al. (2014) in Pakistan also concur with the results of our study where most of their cases were from the lower socioeconomic strata of society[27] because of the catchment area of the institution and perhaps because of less awareness of the consequences. [27]

The DGMAH hospital has a large catchment area, covering urban, peri-urban and rural areas with relatively low-to-middle income. Although it seems that foreign body lodgement is more common in patients from the lower socioeconomic conditions when one considers the location of the patients included in this study, one should not lose sight of the fact that the results could be distorted. Some children from middle-income families might have been taken to private institutions for medical treatment.

5.3 CLINICAL FEATURES

5.3.1 Location of coin or anatomic site involved

In this retrospective study from DGMH, coins were more often lodged in the oesophagus, and mostly located in the upper oesophagus (71.6%). This is in contrast with the study by Chinski et al. (2010) in which it was found that the middle part of the

oesophagus was the most frequent area of impaction.[23] The most frequent lodgement site in this study was the crico-pharyngeous muscle which is consistent with the literature[1-20] including the study by Waltzam et al. (2006) on the anatomical configuration of the tracheo-oesophageal tree at the Children's Hospital at Harvard Medical School in Boston.[6] The high incidence of foreign body impaction in crico-pharyngeous muscle may be explained by the fact that it is the narrowest segment compared to the remaining oesophageal tree.[1,3-20,25-29]

5.3.2 Size of coin

The most common impacted coins found were the five-cent (5c); 21mm, and the fifty-cent (50c); 22mm coin, which are middle-sized coins compared to the ten-cent (10c); 16mm and twenty-cent (20c); 19mm coins which are the smallest sizes (figure 4.3). A small coin may be unrecognised and asymptomatic, passing without difficulty through the gut. This may explain the low incidence of 6% and 3% for small coins: ten-cent and twenty-cent respectively in this study.

Chen et al. (2006) in the USA have reported that "infants and children have poor oral control capability and narrower airways and, it may be difficult for them to shift a coin like a quarter to the back of their oral cavity and subsequently ingest it. However, such an incident might prove to be fatal if it does occur".[28] This may also be the explanation for the low incidence (9.5%) of the ingestion of a five-rand coin, the largest coin in South Africa, in this study.

5.3.3 Elapsed time since ingestion of coin

The management of an ingested foreign body is in most instances time-dependent. The earlier the child is brought to the emergency room the better, especially if he/she is symptomatic. In this study, approximately half the patients arrived within 8 hours after ingestion of the coin. The median time of arrival was 8 hours. In this study population, the early arrival could be explained by proximity to the hospital and also the fact that the population knows that coin ingestion can have potentially major complications. Forty-seven patients (57.3%) were brought to the ED within 8 hours following the ingestion of the coin in this study.

5.3.4 Symptoms

The majority of patients (86.3%) were asymptomatic on presentation in this study . Symptoms generally found in the literature may vary from vomiting or refractory wheezing to generalized irritability in swallowing or even breathing.[10] Predominant symptoms found were vomiting (4.2%), followed by chest pains (3.2%) without respiratory distress, as well as abdominal pain (3.2%) in the present study.

Uyemura (2005) in Salt Lake City in the USA reported only 50% asymptomatic patients.[25] The low incidence of symptoms reported in the present study can be attributed to a few factors, such as poor recordkeeping, language barriers, time constraints and early presentation.

5.3.5 Clinical signs on examination

Most patients (69.5%) presented with no signs on physical examination. The most commonly-observed signs of oesophageal coin lodgement in the present study were hypersalivation in 17 patients (17.9%) and vomiting in 8 patients (8.4%). This was in contrast with respiratory signs (dyspnoea, stridor, asthma, cough) and digestive signs (hypersalivation, regurgitation, dysphagia), also reported by Triadafilopoulos[12] et al. (2013) and Lea[4] et al. (2003). No signs were observed in 66 patients (69.5%) and they were comfortable. Four patients were not comfortable but were stable. There were no respiratory discomfort or distress syndrome signs recorded in the files. Sixty-six patients (69.5%) were brought to the ED within 8 hours following the ingestion of the coin in our study and this can be one explanation for the high number of asymptomatic patients. As for the physical signs, drooling of saliva was the most frequent sign in seventeen patients (17.9%).

5.3.6 Stable conditions

Almost all the study patients (95.6%) were stable on presentation, as illustrated in table 4.5. A stable condition in this study refers to patients without airway compromise. The fear of complications in the study population is probably the reason for early consultation and therefore the low incidence of airway compromise. The absence of signs in at least 50% of patients with an impacted oesophageal foreign body is not uncommon. A study from Lariboisiere Hospital in Paris on the management and endoscopic techniques for digestive foreign body and food impaction has also reported the same finding (up to 50% in paediatric series).[13]

5.3.7 Complications

In the present study the majority of the patients (90%) had no complications. Four of them presented with respiratory discomfort due to partial upper airway obstruction but all symptoms and signs subsided after the removal of the coin. There were no major complications, such as a perforation before or after a procedure. Patients in the present study received attention within 8 hours following ingestion of a coin which may explain the absence of major complications. This is similar to less than one per cent reported by Uyemura.[25]

5.3.8 Length of hospital stay

A total of 37 patients (39%) were hospitalised for one day for further observation. The range of the length of hospitalisation was between less than 24 hours to 6 days.The prolonged length of stay in this study may be attributed to administrative reasons, such as transport-related problems as the patients did not have any medical complications. Arms (2008)[26], in a 12-year retrospective observational case series of 620 patients, reported that when compared with endoscopy the average length of stay and hospital charges were significantly less for the bougienage procedure. From the review of the literature related to this study, the length of stay was determined by the management option. The length of stay was shorter for bougienage compared to the endoscopic interventions (2.2 hours versus 6.1 hours) respectively.[26]

5.4 EXTRACTION METHODS

5.4.1 Foley catheter

The Foley catheter was solely used for half of the patients (50.5%). The indication for the Foley catheter is admission within 24 hours after ingestion of the coin (as per unit protocol), because delay decreases the likelihood of successful removal and increases the risk of complications including risk of perforation [7]. The procedure does not require anaesthesia and is done without fluoroscopy. This is because staff has not been trained in fluoroscopy manipulation. Agaruela [30]et al. (1995) from the Indian Institute of Medical Sciences, report that the Foley catheter method was used in 93.7% of children with impacted coin in the oesophagus. This is higher than the finding reported in this study.

Waltzman (2006) and Khan (2006) found that in the asymptomatic group, careful medical observation for at least 12 hours is recommended for the spontaneous passage of a coin into the stomach[6, 16]. In the present study, the paediatric surgical team did not take the same approach in any radiographically-confirmed case of an ingested oesophageal coin. Instead, the coin was removed promptly without observing the spontaneous passage into the stomach. The DGMAH surgical team believes that the duration that a foreign body is retained in the oesophagus is an unreliable variable because the time of ingestion is frequently unknown or inaccurate in their population.

5.4.2 Foley catheter outcome

The Foley catheter was used in 62 patients and successfully used to remove the coin in 48 patients (77.4%) without fluoroscopy. There was a failure rate of 22% with the Foley catheter for reasons not recorded in the patients' files. Nonetheless, this rate is not too high compared to the score achieved by Little et al. (2008) who report a 25% failure

rate.[8] These investigators in Kansas could not accomplish a 100% success rate because of the small size of the oesophagus in children below one year. van As et al.(2003) in Cape Town attributed their failure rate to the late presentation by patients which caused oesophageal oedema secondary to impaction.[5]

However, many studies have reported fairly good results with the Foley catheter as device for dislodgement of an impacted oesophageal foreign body. These authors recognise that it is generally not recommended to use the Foley catheter for impacted coins for later than 24 hours after ingestion in addition to the presence of oesophageal abnormality as well as a previous history of oesophageal surgery[7, 8].

Manning et al. in the USA at University of Michigan Medical School showed in their series of oesophageal and tracheobronchial foreign bodies in infants and children at Mott Children's Hospital that 59.2% of their patients received early treatment following admission within 24 hours compared to 16.3% who were attended to only a week later.[29] Out of this group, the delay in 75% of the cases was not due to a long waiting period but rather to late presentation from patients seeking medical attention; 31% received their treatment after a week. These authors further state that the delay did not have a negative impact on the outcome. In the group who received delayed treatment, the confounding factor was the fact that these children had oesophageal surgery for an unspecified reason and that distorted the clinical presentation following the recent foreign body ingestion.[29] This was not a finding in the study population at DGMAH. One of the factors could be that no anatomical abnormality was recorded in any of the files evaluated in this research.

In their retrospective study reviewed over 10 years of experience, Harned et al. (1997) reported that the Foley catheter used for coin extraction under fluoroscopy was successful in 322 (96%) of 337 patients. In their opinion, the Foley catheter method of oesophageal coin extraction is safe and effective.[7]

In the researcher's opinion, the failure rate of 22% in this record review of 95 patients could be attributed to factors such as the inexperience of the registrar who first attended to the patients in this study. The experience of the specific registrar performing the procedure was never evaluated in the study. Current practice in the department is that the young and inexperienced registrars will, from day one, perform all procedures on completion of training if the registrar feels comfortable with the procedure. The other reason for the relatively high failure rate could be that rapid airway oedema developed, as reported in other studies[5,7], although no reason for the failure was recorded in any of the patients' files. As indicated under paragraph 5.2.7, no complications were experienced after this procedure was performed on any of the 62 patients. Consequently, the researcher still considers that even with a failure rate of 22%, the procedure is safe and possibly cost effective if one takes into consideration theatre time for oesophagoscopy.

5.4.3 Rigid oesophagoscopy procedure and outcome

The rigid oesophagoscope was used in this study in case of failure with the Foley catheter extraction and as first procedure, according to the surgeon's preference. It is

also recommended when a patient presents at the emergency room more than 24 hours after ingestion of a coin. In the present study, rigid oesophagoscopy was used in 33 patients first (34.7%). In 14 patients (14.8%), both the Foley catheter and rigid oesophagoscopy were used (due to the failure of Foley's method) and the coin was successfully removed in all 44 patients (100%). In three cases the coin had passed spontaneously into the stomach, therefore there was no need for oesophagoscopy. The results in this record review in DGMAH correlate well with the one retrospective study by Lin et al. (2006) who reported a 100% success rate for removing the coin from the oesophagus by endoscopy at the China Medical University Hospital, Taiwan.[18] However, the authors do not specify if the endoscope was rigid or flexible. Nevertheless, the researcher assumes that it was a rigid endoscope because the procedure in all their cases was performed under general anaesthesia. The 100% success rate observed in the study done at the DGMAH paediatric surgery department over the five years indicates that the method used is safe and effective because no complications are indicated in any of the files.

CHAPTER 6: CONCLUSIONS AND RECOMMENDATIONS

6.1 CONCLUSIONS

This study was a retrospective transverse descriptive study on the management of oesophageal coin ingestion in paediatric patients who were treated at DGMAH for the period 01 January 2009 to 31 December 2013. The author reached the following conclusions after the record review and these will be discussed in this chapter.

- This study has shown that coin ingestion is more common in children aged 0–5 years of age (72.6%).
- This research shows that coin ingestion in this study was not specific to the gender of the child.
- The results indicate that children from informal settlements are more prone to coin ingestion (81.1%) in the population evaluated.
- In this record review the majority of patients presented with no symptoms (83.6%).
- The symptomatic patients in this study presented with respiratory or digestive problems.
- The Foley catheter extrication in this department seems to offer a safe and effective method of extricating impacted coins from the oesophagus.
- The rigid oesophagoscopy, as used in this study, is a safe and effective method used as a second choice or if the impaction is > 24 hours old.

6.2 STUDY LIMITATIONS

The study does have a few potential limitations. As a retrospective analysis, this study is subject to known limitations regarding spurious findings, missing data.

- The research was limited to only 95 cases of impacted oesophageal coins in children admitted to DGMAH from January 2009 to December 2013. The study was also limited to children aged ≤ 12 years old.
- This study was a record review where data was extracted from the patients' data files.

This study reported findings based on only two methods of extraction utilised in the specific department. There are many other methods for the removal of impacted foreign bodies reviewed earlier in this study, e.g. endoscopic manipulations, bougienage, Magill forceps, retrieval device or surgery. They are available and may be safe as well as cost effective. None of these methods was used in this study because the Foley catheter and the rigid oesophagoscope were efficient in removing the coins with a very low complication rate.

6.3 RECOMMENDATIONS

For the effective management of oesophageal coin impaction in an emergency situation patients should attend as soon as possible after ingestion. Care and surveillance of

small children needs to be strengthened because this is the most vulnerable age at which they might suffer coin ingestion problems.

The Foley catheter could be recommended for use in healthcare institutions in South Africa as the first method to extricate an impacted coin in the oesophagus unless contraindicated, e.g. a duration exceeding 24 hours after ingestion. Rigid oesophagoscopy is a very effective second alternative if the Foley catheter fails or if impaction exceeds 24 hours. However, further studies are recommended that would investigate the safety and efficacy of other methods available on the market. Prospective studies would also be effective as a comparison to the current records review study.

7. REFERENCES

1. Baral BK, Joshi RR, Bhattarai BK, Sewal RB. Removal of coin from upper oesophageal tract in children with Magill's forceps under propofol sedation. Nepal Med Coll J. 2010;12(1):38–41.

2. Watson WA,Litovitz TL, Schwartz WK, Roger GC, Youniss J, Reid N, Rouse W. G, Rember RS. Annual Report of the American Association of Poison Control Center: Toxic Exposure Surveillance System. American Journal of Emergency Medicine. 2003; 21:353–421.

3. Pfau P. Removal and management of esophageal foreign bodies. Techniques in Gastrointestinal Endoscopy. 2014;16:32–39.

4 Lea E, Nawaf H, Yoav T, Elvin S, Ze'ev Z, Amir K. Diagnostic evaluation of foreign body aspiration in children: a prospective study. Journal of Paediatric Surgery. 2005;40:1123–1127.

5 Van As AB, Du Toit N, Wallis L, Stool D, Chen X, Rode H. The South African experience with ingestion injury in children. International Journal of Paediatric Otorhinolaryngology. 2003; 6751, S175–S178.

6. Mark L, Waltzman ML. Management of esophageal coin. Current Options in Paediatrics. 2006; 18(1):571–74.

7. Harned II RK, Strain JD, Hay TC, Douglas MR. Oesophageal foreign bodies: safety and efficacy of Foley catheter extraction of coins. AJR. 1997; 168:443–446.

8. Little DC, Shah SR, St Peter D, Calkins CM, Morrow SE, Murphy JP et al. Esophageal foreign bodies in the pediatric population: our first 500 cases. Journal of Pediatric Surgery. 2006; 41:914–918.

9. McNeil MB, Sperry SLW, Crockett SD, Brock Miller C, Shaheen NJ, Dllon ES. Epidemiology and management of oesophageal coin impaction in children. Digestive and Liver Disease. 2012; 44:482–486.

10. Holcomb III GW, Murphy JP, Ostlie DJ. Ashgraft's pediatric surgery. 5th ed. Philadelphia: Saunders; 2010:135-143.

11. Smith MT, Wong RKH. Oesophageal foreign bodies: types and techniques for removal current treatment option. Gastroenterology. 2006;9:75–84.

12. Triadafilopoulos G. Roorda A. Akiyama J. Update on foreign bodies in the oesophagus: diagnosis and management. Curr Gastroenterol Rep. 2013 ;(15):317, 1–6.

13. Chauvin A, Viala J, Marteau P, Hermann P, Dray X. Management and endoscopic techniques for digestive foreign body and food bolus impaction. Digestive and Liver Disease. 2013; 45:529–542.

14. Miller RS. Willging JP, Rutter MJ. Rookkapan K. Chronic oesophageal foreign bodies in paediatric patients: a retrospective review intern. Journal of Pediatric Otorhinolaryngology. 2004; 68:265–272.

15. Jones NS, Lannigan FJ. Salama NY. Foreign bodies in the throat: a prospective study of 388 cases. Journal of Laryngology and Otology. 1991; 105:104–108.

16. Khan A. Foreign body in the esophageal: a review. Sao Paulo Medical Journal. 2006; 124(6):346–9.

17. Mariani PJ., Wagner DK. Foley catheter extraction of blunt oesophageal foreign bodies. JEmerg Med. 1986 ;(4):301–306.

18. Lin CH, Chen AC, Tsai JD, Wei SH, Hsueh KC, and Lin WC. Endoscopic removal of foreign bodies in children. Kaohsiung J Med Sci. 2007; 23:447–52.

19. Marrow SE, Bickeler SW, Kennedy AP, Snyder CL, Sharp RJ, Ashcraft KW. Balloon extraction of oesophageal foreign bodies in children. Journal of Pediatric Surgery. 1998 ;(33):266–27.

20. Pokharel R, Adhikari P, Bhusal CL, Guragain RPS. Oesophageal foreign bodies in children. J Nepal Med Assoc. 2008; 47(172):186–8.

21. Waltzman ML, Baskin M, Wypij D, Mooney D, Jones D, Fleisher G. A randomized clinical trial of the management of esophageal coins in children. Pediatrics. 2005; 116:614–619.

22. Weissberg D, Refaely Y. Foreign bodies in the esophagus. Ann Thorac Surg. 2007; 84:1854–7.

23. Chinski A, Foltran F, Gregori D, Ballali S. Foreign bodies in the oesophagus: the experience of the Buenos Aires Paediatric ORL Clinic. International Journal of Pediatrics. 2010; 1–6.

24. Athanassiadi K, Gerazounis M, Metaxas E, Kalantzi N. Management of oesophageal foreign bodies: a retrospective review of 400 cases. European Journal of Cardio-thoracic Surgery. 2002 ;(21):653–656.

25. Uyemura MC. Foreign body ingestion in children. American Family Physician. 2005;15(72) 2:287-291.

26. Arms JL, Mohn MD, Bowen MV, Chamberlain CM, Skrypek TM, Madhok M et al. Safety and efficacy of a protocol using bougienage or endoscopy for the management of coin acutely lodged in the esophagus. A large case series:Ann Emerg Med. 2008;51(4):367–372.

27. Al-alawneh MT, Khan MA, Sheikh MS, Madni AB. Management of oesophageal foreign bodies. Journal of Taibah University Medical Sciences. 2014;9(3):206–208.

28. Chen X, Milkovich S, Stool D, van As AB, Reilly J, Rider G. Pediatric coin ingestion and aspiration. International Journal of Pediatric Ortorhindaryngology. 2006; 70:325–329.

29. Manning P. Esophageal and tracheobronchial foreign bodies in infants and children. Pediatric Surgery International. 1989; 2:346–351.

30. Agarwala S, Bhatnagar V, Mitra DK. Coins can be safely removed from the esophagus by Foley's catheter without fluoroscopic control. Indian Pediatrics. 1996; 33.

8. APPENDICES

Appendix 1: Ethics clearance certificate

UNIVERSITY OF THE WITWATERSRAND, JOHANNESBURG
Division of the Deputy Registrar (Research)

HUMAN RESEARCH ETHICS COMMITTEE (MEDICAL)
R14/49 Dr KMJ Kasakanga

CLEARANCE CERTIFICATE	**M120459**
PROJECT	A Review of Foley Catherter Extraction of Oesophageal Coins in Children, Presenting at Dr George Mukhari Hospital (DGMH), Ga-Rankuwa
INVESTIGATORS	Dr KMJ Kasakanga.
DEPARTMENT	Department of Family Medicine
DATE CONSIDERED	04/05/2012
+DECISION OF THE COMMITTEE*	Approved unconditionally

Unless otherwise specified this ethical clearance is valid for 5 years and may be renewed upon application.

DATE 04/05/2012 **CHAIRPERSON** .....
(Professor PE Cleaton-Jones)

*Guidelines for written 'informed consent' attached where applicable
cc: Supervisor : Dr Anita Groenewald

DECLARATION OF INVESTIGATOR(S)
To be completed in duplicate and **ONE COPY** returned to the Secretary at Room 10004, 10th Floor, Senate House, University.
I/We fully understand the conditions under which I am/we are authorized to carry out the abovementioned research and I/we guarantee to ensure compliance with these conditions. Should any departure to be contemplated from the research procedure as approved I/we undertake to resubmit the protocol to the Committee. **I agree to a completion of a yearly progress report.**

PLEASE QUOTE THE PROTOCOL NUMBER IN ALL ENQUIRIES...

Appendix 2: Data extraction sheet

Data collection

A. Child Socio-demographic variables:

1. Age:_____(years) 2. Sex: 1. Female 2. Male

4. Home circumstances: 1. Informal settlements (tin houses) 2. Residential (normal houses)

B. Clinical variables:

1. Location of FB or anatomic site involved ***(circle appropriate)***
    1. Upper third of oesophagus (cervical oesophagus)
    2. Middle third of oesophagus (mid-oesophagus)
    3. Lower third of oesophagus (distal oesophagus)
    4. Abdominal cavity
2. Size of coin: ***(Record Yes/No)***

Coin type	Yes/No
One cent	
Two cents	
Ten cents	
Twenty cents	
Fifty cents	
One Rand	
Two Rands	
Five Rands	

3. Elapsed time since the ingestion of coin_____(number in days)

4. History, reported symptoms:_____

Symptoms Observed	Yes/No
Vomiting	
Coughing	
Fever	
Drooling saliva	
Respiratory distress	
Dysphagia	
Refusal to eat	
Agitation (that can lead to air way compromise)	
Chest pain	

5. Clinical signs and symptoms on examination.

Conditions Observed		Yes/No
Stable	no respiratory distress no dysphagia	
Not Stable	Agitated patient Difficulty breathing, Respiratory symptoms of stridor Cough Chocking Vomiting Fever Drooling saliva Dysphagia Chest pain	

6. Complications before and after removal of coin:

	Ye/No	
Complications	Before Removal	After Removal
Respiratory distress		
Gastro-intestinal perforation		
Pneumothorax		
Pneumonia		
Trachea oesophageal fistula		
Epistaxis		
Oesophageal oedema		
Oesophageal stricture		
Mediastinitis		
Aspiration		
Upper air way obstruction		

C. Eventual outcomes:

C 1. Extraction methods.

1. Extraction methods	Foley catheter		Rigid oesophagascopy		Both	
2. Out Come	Successful	Unsuccessful	Successful	Unsuccessful	Successful	Unsuccessful

Any other comments during removal_____

If hospitalised, how many days?:_____(number of days)

Appendix 3: Institutional Permission to conduct a study

health and
social development
Department: Health and Social Development
GAUTENG PROVINCE

Enquiries: Dr. P. Shembe
Tel no: 012 529 3880
Fax no: 012 5600099

To : Dr Marie-Josee Kasonga Kasakanga
28 Michael Street
Linmeyer
2190 JOHANNESBURG

Date : 03 APRIL 2012

PERMISSION TO CONDUCT RESEARCH

The Dr. George Mukhari Hospital hereby grants you permission to conduct research on "A review of Foley catheter extraction of oesophageal coins in children presenting at Dr George Mukhari Hospital".

This permission is granted subject to the following conditions:

☐ That you obtain Ethical Clearance from the Human Research Ethics Committee of the relevant University

☐ That the Hospital incurs no cost in the course of your research

☐ That access to the staff and patients at the Dr George Mukhari Hospital will not interrupt the daily provision of services.

☐ That prior to conducting the research you will liaise with the supervisors of the relevant sections to introduce yourself (with this letter) and to make arrangements with them in a manner that is convenient to the sections.

Yours sincerely

DR. P SHEMBE
DIRECTOR: CLINICAL SERVICES

Dr George Mukhari Hospital
Private Bag X623
PRETORIA

Appendix 4: Approval letter to conduct the study

Faculty of Health Sciences
Medical School, 7 York Road, Parktown, 2193
Fax: (011) 717-2119
Tel: (011)717-2075/6

Reference: Ms Mathoto Senamela
E-mail: mathoto.senamela@wits.ac.za
27 November 2012
Person No: 347377
PAG

Dr MK Kasakanga
MBE 177
P?Bag X21
Kempton Park
1920
South Africa

Dear Dr Kasakanga

Master of Science in Medicine (Emergency Medicine): Approval of Title

We have pleasure in advising that your proposal entitled "*A review of management of oesophageal coins in children presenting at Dr George Mukhari Hospital*" has been approved. Please note that any amendments to this title have to be endorsed by the Faculty's higher degrees committee and formally approved.

Yours sincerely

Mrs Sandra Benn
Faculty Registrar
Faculty of Health Sciences