

https://dspace.org/

Suricata tetradactyla

Eiselen, G. T. S.

2015-03-11
http://hdl.handle.net/10539/17228

Downloaded from a DSpace repository. https://dspace.org/

SURICATA TETRADACTYLA.

BY

G. T. S. EISELEN B.A. (Cape)

DEPARTMENT OF ZOOLOGY, UNIVERSITY OF THE WITWATERSRAND.

WITH PLATES I — XXX.

DISSERTATION PRESENTED FOR THE DEGREE OF MASTER OF SCIENCE IN THE UNIVERSITY OF THE WITWATERSRAND, JOHANNESBURG.

DECEMBER 1923.

SURICATA TETRADACTYLA.

CONTENTS.

	Page.
Historical survey and introductory remarks.	1
Habitat and habits.	4
The morphology of Suricata tetradactyla.	9
The skeleton.	
The skull.	13
The vertebral column.	17
The pectoral girdle and limbs.	19
The sternum and ribs	18
The pelvic girdle and limbs.	23
The muscular system.	28
The muscles of the head.	28
The muscles of the trunk.	30
The muscles of the fore limb.	31
The muscles of the hind limb.	34
The respiratory system.	36
The circulatory system.	38
The alimentary system.	44
The endocrine organs.	47
The nervous system.	48
The sense organs.	56
The urinogenital organs.	57
Classification.	61
Geographical distribution.	61
Parasites of the meerkat.	62
Affinities.	64
The meerkat in South African folk lore.	66
Acknowledgements.	67
References.	68
Classification of plates.	68a.
Appendix with plate XXXI.	98

SURICATA TETRADACTYLA

HISTORICAL SURVEY AND INTRODUCTORY REMARKS.

Since 1777, when this suricate was first described by Erxleben, it has often been renamed. It is interesting to note that the name "suricate" was wrongly applied to this animal by Buffon, who was the first to describe its habits. Buffon erroneously named it a suricate as he believed that the example he purchased in Holland, had come from Surinam in South America. This error was corrected by Schreber, who saw an example in the menagerie of the Staatholder of Holland. He showed that the name suricate wrongly applied by Buffon, really belonged to a lemur from Madagascar.

Erxleben in 1777 named this suricate Viverra suricatta, but it was renamed by Schreber, who objected to Buffon's nomenclature of suricata, in 1778 as Viverra tetradactyla. This was confirmed by Thurnberg in 1811. Scopoli in 1786 renamed the animal Mus zenick. Desmarest in 1804 returned to Buffon's nomenclature and renamed it Suricata capensis, but changed the specific name and spelling of the generic name, so that the animal was known as Surikata viverrina. In 1836 A.Smith renamed it Ryzaena surakatta, but Smuts six years later, in 1832, called it Ryzaena capensis. In 1834 A.Smith changed the specific name into Ryzaena typicus. Layard in 1861 returned to Buffon's nomenclature and adopted Scopoli's specific name and called it Suricata zenick. In 1882 O.Thomas renamed the animal Suricata tetradactyla. This was confirmed by Nozak in 1885, and Lydekker in 1895. Since then this name has been generally adopted.

Oldfield Thomas and Harold Schwann* state that Suricata suricatta fall naturally into four distinct groups or local races. They thus distinguish subspecies and make them trinomial They classify them as follows:-

(1) Central (typical) found in the Cape (Karroo) and Paelfontein, and termed Suricata suricatta suricatta or S.s.tetradactyla.

---

* Proc.Zool.Soc. London- 1905. Vol.1. pp.133-134.

SURICATA TETRADACTYLA

HISTORICAL SURVEY AND INTRODUCTORY REMARKS.

Since 1777, when this suricate was first described by Erxleben, it has often been renamed. It is interesting to note that the name "suricate" was wrongly applied to this animal by Buffon, who was the first to describe its habits. Buffon erroneously named it a suricate as he believed that the example he purchased in Holland, had come from Surinam in South America. This error was corrected by Schreber, who saw an example in the menagerie of the Staatholder of Holland. He showed that the name suricate wrongly applied by Buffon, really belonged to a lemur from Madagascar.

Erxleben in 1777 named this suricate Viverra suricatta, but it was renamed by Schreber, who objected to Buffon's nomenclature of suricata, in 1778 as Viverra tetradactyla. This was confirmed by Thurnberg in 1811. Scopoli in 1786 renamed the animal Mus zenick. Desmarest in 1804 returned to Buffon's nomenclature and renamed it Suricata capensis, but changed the specific name and spelling of the generic name, so that the animal was known as Surikata viverrina. In 1836 A.Smith renamed it Ryzaena surikatta, but Smuts six years later, in 1832, called it Ryzaena capensis. In 1834 A.Smith changed the specific name into Ryzaena typicus. Layard in 1861 returned to Buffon's nomenclature and adopted Scopoli's specific name and called it Suricata zenick. In 1882 O.Thomas renamed the animal Suricata tetradactyla. This was confirmed by Nowak in 1889, and Lydekker in 1895. Since then this name has been generally adopted.

Oldfield Thomas and Harold Schwann* state that Suricata suricatta fall naturally into four distinct groups or local races. They thus distinguish subspecies and make them trinomial They classify them as follows:-

(1) Central (typical) found in the Cape (Karroo) and Deelfontein, and termed Suricata suricatta suricatta or S.s.tetradactyla.

---

* Proc.Zool.Soc. London- 1905. Vol.1. pp.133-134.

(2) South-easterly round Grahamstown:- S.s.lophurus.

(3) North-easterly in the Orange Free State and Transvaal :- S.s.hamiltoni.

(4) North-westerly in little Namaqualand (Klipfontein) :- S.s.namaquensis

It is interesting to note the following characteristics on which their classification is based.

The Neelfontein specimen is looked upon, by them, as the typical animal, namely S.s.tetradactyla, and it is "characterised by having head and shoulder ,drab-grey' and the cheeks and under parts of the neck dirty white. The tail appears to be rather more fulvous than in the other forms".

S.s.lophurus is a specimen of the South-eastern race (Grahamstown) and of a large size. It is drab-grey on head and shoulder and dirty white or grey on cheeks and throat. The tail is distinctly bushy and of the same general colour as the body, not showing the yellow of the fulvous suffusion toward the tip so generally present in other groups.

S.s.hamiltoni is distinguished by a general lighter colour above and below and a stronger fulvous suffusion is present on the back. One of its best characters is a strongly marked white patch extending from the eye to the neck and it entirely surrounds the ear. The throat is also strongly suffused with white.

S.s.namaquensis is characterised by a silvery tone of the forehead, lips, cheeks and shoulders. The throat is grey. The suffusion on the tail is more yellow than fulvous, the black tip is rather less strongly pronounced than in other races.

A key for classifying the different subspecies has also been compiled by Oldfield Thomas and Harold Schwann which is as follows :-

A/ Greatest length of skull 68mms. at most, hind foot less than 65mms.; tail less bushy.

a) Forehead and nape uniformly coloured, white cheek patch not passing over ears.

b) Forehead, cheeks and shoulders with distinctly silvery tone :- S.s.namaquensis.

b^2) For head and shoulders drab-grey, cheeks dirty white :- S.s.tetradactyla (suricatta).

b) White cheek patch extending above ears :- S.s.hamiltoni.

B/ Skull 60mms. or more; hind foot more than 67mms. tail very bushy :- S.s.lophurus.

No other accounts published on suricates nor specimens in the Transvaal Museum - which I was able to examine carefully, through the kindness of Mr. Austin Roberts - seem to verify this classification of Thomas and Schwann. It seems to be very doubtful, whether such a classification is justified, and whether there is any valid reason for these four subspecies. Thomas and Schwann declare that their classification was mostly based on skins, some of which were rather dilapidated, so that a classification was often very difficult. Besides that, this classification was often based on one or two specimens only.

My chief objection to a classification on the basis of colour variations of various specimens is founded on an example of a young specimen, I was able to examine carefully in the Transvaal Museum. The colour of this specimen was an ochre red, while the colour of the adult was a yellowish, grizzled-grey. It could be easily discerned that this colour was not due to pigment in the hair, but consisted of very fine dust particles of earth. This red colour was only restricted to the distal ⅔ of the individual hairs, the portion near the skin was white or had a light brown colour. It may thus, and I think rightly, be assumed that the soil, in which these animals burrow, imparts a colour to their fur, especially if the soil is of a fatty consistency. This soil colouration is especially evident in the young, which are more confined to their "nests" than the adults, which by roaming about and an occasional shower of rain, lose most, if not all, of these minute particles of soil clinging to their hair. In natural surroundings it will be noticed, that the young always have a darker colour than their parent.

On the ground of this evidence,furnished by the colour variation between young and adult,due to soil particles,I consider it a rather bold assumption to form four subspecies on colour variations,which are but slight. Besid s,it is more than probable, that the soil in the different localities,in which these animals live,does to a certain extent,according to the consistency of the soil and its composition,modify the colour.

On the whole it seems to me advisable to leave this classification into four subspecies an open question and to confine ourselves to the one species Suricata tetradactyla,as generally recognised.

HABITAT AND HABITS.

The meerkats* live on the open veld in burrows. These burrows are in the form of a rough semi-circle with four openings or holes. The underground tunnels are very ingeniously constructed,providing ample protection and refuge.(Plate I,Figs.1-3.)It is difficult to say which opening forms the main entrance,but in those I have investigated,I take it to be the one marked (a) in the 1st.figure as it lies closest to the nests. Commencing from hole (a),which is 6inches in di meter,the tunnel slants downwards at an angle of about 45° for the length of 3feet 6 inches,and to the depth of about 1 foot 8inches. It then turns fairly sharply to the left ascending at an angle of about 30° for a length of 3feet. Here the tunnel forks. One arm descends at an angle of 25° for the length of 3feet. The other arm forms "nests",which lie fairly horizontal and end in a cul de sac 3feet from the point of divergence. The first nest lies 8inches below the surface and is 10inches in di meter and 7inches high,the second nest lies 13 inches below the surface,is 13inches long 8i ches broad and is continued into a cul de sac.

---

* The vernacular Dutch name "mierkat" is phonetically best represented by adopting the English version "meerkat",though some writers use "mierkat". As no English vernacular name exists,and the above mentioned nomenclature is used by all South Africans, I am using the name "meerkat" throughout,as a literal translation of the Dutch mierkat -ant-cat - would be inappropiate.

When the first arm has descended for the distance of 3feet a blind alley or tunnel is given off having a length of 1foot 9 inches. From here the tunnel runs along fairly horizontally at a depth of 2feet 8inches. Three feet from this point a tunnel arises vertically at right angles to it, and ends blindly about 8inches from the surface. It is not clear what the significance of this upright tunnel is. As the meercats have few enemies it is not very likely that this upright tunnel should serve as an emergency outlet. It seems more probable that it has been excavated by a field mouse.being cornered in the tunnel,and then has been enlarged by the meercat so as to capture the mouse. From this upright canal the horizontal tunnel is continued for the length of a foot and then suddenly ascends at an angle of 60° for the distance of 2feet. From here a side branch at right angles to the tunnel commences and opens into a nest 13inches long 13 inches broad,7inches high and 6inches below the surface. The connecting channel from it to the main tunnel has a length of 13 inches. After having given off this side channel,the main tunnel again slopes downwards for a distance of 3feet 7inches at an angleof 55°,until the depth of 2feet 8inches below the surface is again reached. At this point there are openings of three passages,which may be numbered 1,2,and3. No.1 forms an angle of about 60° with the main tunnel and slopes upwards for a length of 3feet 10inches at an angle of about 15°. Thence it turns a little to the right,forming a kind of curve,for the distance of 3feet 8inches at an angle of 45°,to end in an opening to the outer world. From this opening a blind tunnel 1foot 9inches long emerges at right angles to it and descends at an inclination of about 30°.

Opening no.2 is situated above no.1, and opens into a semi-circular passage,which, after a distance of about 8inches,opens again into the tunnel arising from no. 1. What the use of this small passage is can hardly be conjectured,unless it be used as a kind of ambush. Opening no.3 arises where the passage from no. 2 opens into that from no.1. This opening leads into a tunnel which runs along straight for the distance of 2feet 8inches,in

fact,it seems to be a continuation of the tunnel arising from hole (b)-(see Fig. 1 .)-. This passage then bends sharply to the right,runs along for the length of 1foot 1inch and then bends sharply to the left again. From here it describes a curve for the length of 6feet to open into a cave 2feet below the surface and 8inches in diameter and 7inches high. It lies opposite to the upright tunnel emanating from the main tunnel. This little cave is separated from the main tunnel by a wall 2inches thick.

About 1foot distant from hole (b) lies hole (c),from which runs down,in the form of a curve at an angle of 25° for the length of 3feet 4inches,a tunnel to the depth of 1foot 3inches. Here it is met by a tunnel from hole (b),which more or less slopes at the same angle for the length of 2feet 2inches. Where these two meet arises a sausage-shaped blind alley 2feet long,which slopes slightly upwards. The two tunnels,having joined,then form a sharp bend and slope downwards for a distance of 1foot 8inches until a depth of 1foot 5inches is reached. From here it continues at an angle of 30° for another 1foot 8inches,sloping slightly upwards. It then bends again nearly at right angles to its former course and,sloping at an angle of 30°,it runs along for a length of 3feet to open into hole (d). The average diameter of the four holes is 6inches,while the average diameter of the tunnels is 4 inches.

The distance from hole (a) to hole (d) is 18feet 6inches;from (a) to (b) 16feet;from (b) to (d) 8feet. At a distance of 6feet from hole (d) is the depository for the excrements of the animals No faeces,or refuse of any kind were found in the burrow. The tunnels were scrupulously clean except for a few locusts,which had probably been left in a hurry. The largest nest,arising from the main tunnel and only 6inches below the surface,appears to be the place where the young are thrown. It is placed most centrally and is least exposed,while escape from it is possible in two directions. It lies higher than the main tunnel and is thus,in case the burrow should be flooded,out of danger. The danger retreat seems to be the cave 2feet below the surface and only separated by a 2inches thick wall from the main tunnel. The two

nests or dives near hole (a) probably serve as a sleeping place and perhaps too as an ambush. It is not at all clear what the significance of the four cul de sacs is. Probably they are used to corner a mouse,or rat,which may have strayed into the burrow, on the other hand it may be suggested that the blind alleys are beginnings of new tunnels.A look at the plan (see Fig. 1. favours this view,as quite interesting ramifications could be brought about by a continuation of these blind alleys.

The meercats generally live in colonies,a number of burrows generally lie in close proximity,though not communicating with each other,and one burrow seems to be inhabited by one pair only. Mr. Austin Roberts states that he has,on more occasions than one, found Suricata tetradactyla, Cynictis penicillata, and Geosciurus capensis living cheek by jowl. This contradicts Mr. FitzSimons' statement that Cynictis preys on the ground squirrel. Mr,Roberts also states that Cynictis and Suricata,though living with each other,do not interbreed.

Meercats live on small mammals,e.g. field mice,birds and their eggs,if they can get them,reptiles (snakes),but particularly on insects and their grubs. Insects,for example,locusts are preferr- to any other diet.They are also stated to feed on bulbs of veld plants. In captivity the meercat thrives well on finely chopped raw meat,fish,raw eggs and milk;in lieu of anything better it will be content with an occasional diet of monkey-nuts. The meer- cat requires a ration of two and two-third ounces of meat per day. Water is also necessary for its maintenance,which it laps up after the fashion of a cat. The meercat is,in certain,sense, the farmer's friend as it keeps down the smaller vermin.

Dr. Annie Porter informed me that,a pet meercat, in her posses- ion, was fed on raw meat,milk and raw eggs - boiled eggs it would not touch -. When given the heads of fowls,it would crunch the skulls and eat the brains only,nor would it suck the blood,when a whole fowl was given,nor eat any other part of the fowl but the brain. It cleared the plants of the surroundings of stink- bugs. This meercat also occasionally helped itself to cabbage leaves from a rabbit's cage.

One of the characteristic attitudes of the meercat,when on the

alert,is with the right fore-limb raised and the paw bent. It often sits on its haunches after the fashion of a marmot or rabbit. It seldom trots but generally gallops. It is exceedingly quick and nimble and can twist its body into practically any form,when trying to get loose. This animal stalks its prey after the fashion of a cat;finally pouncing upon it. When feeding it does so after the fashion of a dog not of a cat,as it uses its paws for holding and tearing its food.

When alarmed the animal emits a series of short,sharp barks, which cause all meercats in the vicinity to scuttle into their holes. When in the least uncomfortable or annoyed it keeps up an incessant,unpleasant,half-chattering,half- barking noise. When annoyed it barks somewhat like a young terrier,when pleased it makes a sort of crooning noise resembling,as Buffon describes it a"policeman's rattle", or a modern child's wooden rattle. When irritated or attacking a foe, it emits a hissing,spitting sound closely resembling that of a fighting cat.

The meercat is a strictly diurnal animal, which loves basking in the sun, where it lies stretched out after the fashion of a dog.

In the Natural History* edited by Rev.J.G. Wood mention of the animal is made as Suricata zenick, and the following statement is made :-"it is offended by brilliant light and is best pleased when it can abide in comparative darkness." In the Standard Natural History† a similar statement is made :-"In habits it is largely nocturnal residing mostly in mountain caves,not relishing bright light."

It must also be clearly understood that the meercat lives in burrows on the veld and not in "cave and rock cavities."‡It seems,in this respect,to have been confused with Cynictis,which often lives in rock cavities.

---

* Rev.J.G.Wood:- Natural History p.348.

† Standard Natural History,edited by J.S.Kingsley, p. 445.

‡ Cambridge Natural History Vol. X. Mammals. p. 411

alert,is with the right fore-limb raised and the paw bent. It often sits on its haunches after the fashion of a marmot or rabbit. It seldom trots but generally gallops. It is exceedingly quick and nimble and can twist its body into practically any form,when trying to get loose. This animal stalks its prey after the fashion of a cat;finally pouncing upon it. When feeding it does so after the fashion of a dog not of a cat, as it uses its paws for holding and tearing its food.

When alarmed the animal emits a series of short,sharp barks, which cause all meercats in the vicinity to scuttle into their holes. When in the least uncomfortable or annoyed it keeps up an incessant,unpleasant,half-chattering,half- barking noise. When annoyed it barks somewhat like a young terrier,when pleased it makes a sort of crooning noise resembling,as Buffon describes it a"policeman's rattle", or a modern child's wooden rattle. When irritated or attacking a foe, it emits a hissing,spitting sound closely resembling that of a fighting cat.

The meercat is a strictly diurnal animal, which loves basking in the sun, where it lies stretched out after the fashion of a dog.

In the Natural History* edited by Rev.J.G. Wood mention of the animal is made as Suricata zenick, and the following statement is made :-"it is offended by brilliant light and is best pleased when it can abide in comparative darkness." In the Standard Natural History† a similar statement is made :-"In habits it is largely nocturnal residing mostly in mountain caves,not relishing bright light."

It must also be clearly understood that the meercat lives in burrows on the veld and not in "cave and rock cavities."‡It seems,in this respect,to have been confused with Cynictis,which often lives in rock cavities.

---

* Rev.J.G.Wood:- Natural History p.342.

† Standard Natural History,edited by J.S.Kingsley, p. 445.

‡ Cambridge Natural History Vol. X. Mammals. p. 411

The meercat has very few natural enemies, the chief of which are eagles and the honey badger (Mellivora ratel).

This meercat is very often tamed and makes a very confiding, intelligent and docile pet. It is distrustful towards strangers, whom it bites on the slightest provocation. One of its characteristic habits is inquisitiveness; it is also very fearless, when domesticated, attacking any strange animal, even a dog. Dr. Porter's pet, kept in a laboratory, went up to the electric radiator, as soon as it was switched on, sat down on its haunches in front of the radiator, rubbing its abdomen with its fore-paws and emitting all the time a crooning sound of apparent delight. As soon as the radiator was switched off, it became annoyed and gave vent to its feelings by making a half barking noise.

THE MORPHOLOGY OF SURICATA TETRADACTYLA.

(Plate II, Fig.4.)

The meercat is small and slender; its general colour is grizzled grey. The under fur is woolly and pale brown. The whole back is irregularly, transversely marked with alternate black and greyish-white bands; these are caused by the regular arrangement of black and white rings on the longer hairs. The exact colouration of one of these longer hairs is, beginning from the root, white,- black,- white,- brown,- black. These hair markings on the back vary from black,- white,- brown,- black, to white,- black,- white,- brown,- black. The maximum length of the individual hair is 23 mms. The hair of the under fur is pale brown and 35mms. long; while the hair of the fore limb is pale brown and that of the hind limb reddish brown, intermingled with occasional black, but becomes reddish brown towards the foot.

The fur on the head is of a grizzled grey colour with a black patch around each eye. The whole appearance of the head is more canine than feline. There is no naked line from the nose to the upper lip. The snout is slender and projects considerably beyond the lips and is surrounded by hair. The ears are placed very low but are conspicuous by the deep black of the skin and hairs on their anterior surface. The ears somewhat resemble those of

monkeys. On the head are found five patches from which vibrissae originate. There are seven long,stiff hairs each side of the upper jaw,situated just above the canine tooth. The hairs are all black and three of them are rather long. Half an inch in front of the ear are found,on either side, five black hairs,three of which are long. Just below the abovementioned patch is found, on either side,a patch with six greyish-black hairs. Above each eye a patch of ten hairs is found,one of these hairs is especially long measuring 35mms. On the lower jaw,in the region of the tongue,is a single patch from which five hairs spring; two are black and three grey.

The eyes are placed in the side of the head. The orbit is slit-like and upper and lower eye-lids are provided with palpebrae. The lids are immovable. Their function is performed by a very well developed nictitating membrane,strengthened by cartilage. The eyes are very bright, the iris is dark-brown and the pupil is large. The iris is only to a very slight extent capable of dilatation and contraction,and is not influenced by different intensities of light in such a marked way as is the case in cats. This again proves that the animal is diurnal.

The external nares are black on top and on the sides,but reddish brown below and towards the inside. Here slight variations may be met with; the nares may be quite black.

The tail is slender -never bushy -- and measures a bit more than half the length of the head and trunk together. It is reddish yellow and shows, anteriorly, a few transverse markings , similar to those on the back of the animal. The extreme 2½inches of the tip are quite black. The hair on the tip of the tail measures 23mms. in length ,on the tail itself 37mms., and its markings are white,- black,- brown,- black rings.

The animal stands about 6½inches high. There are four toes on both fore and hind paws -- giving the animal its specific name. Each toe is provided with a long,curved,non-retractile claw. The claws of the fore paws are twice as long as the hind ones; the maximum length being 10mms. The tarsus is naked and the carpus partially so. Both tarsus and carpus are provided with pads,which

absorb the shock when the animal jumps.(Plate III Fig.5.) When galloping, the pads are also very useful in forming an elastic cushion, preventing a jerking of the body. The claws, besides being primarily used for digging, assist the animal in climbing trees for example. The meerkat is, like the dog, semi-digitigrade.

There are three pairs of teats placed latero-ventrally. In one specimen there were found four teats, placed latero-ventrally on the right side and three on the left. Unless this occurrence be looked upon as a "sport", it might point to an ancestral number of four pairs of abdominal teats. Teats are also conspicuous in male specimens.

There are openings of a pair of perineal glands on either side of the anus in both male and female specimens. As a matter of fact, the anus is very large and capable of extension, protrusion and retraction, and the openings of the perineal glands are really placed within the anal aperture. Beneath the anus is situated the slit like vulva or, as the case may be, the scrotum with the penis. The scrotum resembles in appearance and position that of a cat, in being closely applied to the body and non-pendent, but differs from the cat's in being naked and having a few sparse hairs only.

DIMENSIONS. The following measurements have been taken from both male and female living specimens :-

	MALE	FEMALE	
		No.I	No.II.
Length, from snout to tip of tail	605mms.	480mms.	485mms.
Length of head and trunk	370mms.	285mms.	285mms.
Length of head	89 mms.	76 mms.	76mms.
Length of tail	235mms.	204mms.	210mms.
Ratioof tail to body	1:3.5	1:3.4	1:3.4
Length of fore limb	178mms.	140mms.	153mms.
Length of upper arm	51mms.	38mms.	33mms.
Length of lower arm	114mms.	113mms.	114mms.
Length of hind limb	190mms.	185mms.	178mms.
Length of thigh	64mms.	54mms.	61mms.
Length of leg	127mms.	119mms.	116mms.
Ratio of fore limb to body (without tail)	1:3.1	1:3	1:3

	MALE	FEMALE No.I	FEMALE No.II
Ratio of hind limb to body (without tail)	1:1.96	1:2	1:1.87
Ratio of fore limb to hind limb	1:1.71	1:1.2	1:1.2
Length of fore paw	56mms.	51mms.	51mms.
Length of hind paw	76mms.	67mms.	73mms.
Length of digits, in order, of Manus -- in mms.:-	II - III - IV - V;; 35 - 35 - 32 -22.5;	II -III - IV - V 29- 29- 28.5-22	
Length of digits, in order, of Pes -- in mms.:-	II - III - IV - V;; 25.5- 29 - 29 -18;;	II -III - IV -V 18 - 22 - 22-16	
Ratio of digits to fore limb:-	1:5-1:5- 1:5.3-1:7;	1:5-1:5-1:5- 1:6.6	
Ratio of digits to hind limb:-	1:7.5-1:6.6-1:6.6-1:9;	1:9-1:7-1:7- 1.	
Measurement of ear in mms.:-	21.5X18X22	19 X 16 X 20.5	
Distance from ear to ear	64mms.	57mms.	
Length from ear opening to tip of nose	73mms.	67mms.	
Breadth of head from ear to ear	64mms.	60mms.	
Length of upper jaw	38mms.	35mms.	
Length of lower jaw	25.5mms.	22mms.	
Distance from orbit to tip of nose	29mms.	25.5mms.	
Distance from orbit to ear	41mms.	38mms.	
Distance from eye to eye (behind)	41mms.	38mms..	
Distance from eye to eye(anteriorly	19mms.	16mms.	
Mouth gape	38mms.	38mms.	

The following dimensions are given by Sclater* as taken from a mounted specimen :- Length of head and body 14.5 inches(369mms.) Length of tail 7inches (178mms.);Length of hind foot 2.35inches (60mms.); Ear opening to tip of nose 2.6inches (66.5mms.) Haagner† gives the following :- Length of head and body 12 - 14 inches (305 - 356mms.);Length of tail 6 - 8inches (152.5 - 204 millimetres), and Mr. A.Roberts - personal information - gives the length of head and body as 300 - 354mms., the length of the tail as 177 - 190mms..

---

*Sclater; Mammals of South Africa. Vol. I. pp. 76 - 78.

†A.Haagner; South African Mammals.pp. 64 - 65.

THE SKELETON.

THE SKULL.(Plates IV-VI Figs.6-11.) The skull is somewhat elongate and more canine than feline in appearance. It shows a fair compression in the interorbital region. The zygomatic arches are complete and diverge widely from in front outwards.The post-frontal and the postorbital process of the jugal join and fuse, thus cutting the orbit off completely. The auditory bulla is large and flattened,the bony auditory meatus is somewhat prolong - ed with a fissure or a line of fine holes (in the young only) marking its course. (Plate IVFig.7.) There is a distinct alisphe_ noid canal. The pterygoid has well marked hamular processes. The occipital and sagittal crests are very well developed and serve for the attachment of muscles.(Plate IV,Fig.6.) The nasals are well developed and the nasal processes of the premaxillae reach the frontals. The junction of the parietals is well developed and produced into the sagittal crest. The paroccipital processes are weakly developed and closely apposed to the bullae. An inter— parietal is distinctly present. The glenoid fossa is deep and in the form of a transverse groove. The post glenoid process is well developed. The orbit is cut off from the temporal fossa. The postorbital bar developed on frontal and jugal is well marked strong and complete. The greater part of the palate is formed by the palatines,and the maxillary part of the palate is pierced by the anterior palatine foramina. The large,rounded auditory bulla consists of two portions separated by a nearly complete septum, much as in the cat,except that the chamber, corresponding with the inner chamber of the cat's bulla,is posterior in position. Lachrymal bone and foramen are present. There are three tubercu- lar teeth in the upper jaw,two molars and one premolar.

The mandible (Plate V , Figs.8-9)has a well developed coronary process which curves backwards. The articular process is small and slightly swung outwards. The condylar surface is very well developed and placed transversely.

The incisors are $\frac{3}{3}$,of which the two inner ones are small and blade like,the third and outer one is comparatively large and bl de like. The canines are long,conical and projecting. There are three

premolars and two molars in the upper as well as the lower jaw. There is no carnassial tooth. The first two premolars are conical and compressed. The third premolar,the largest tooth,is triconodont and tritubercular. The first molar,also large,is tritubercular and in the young adult somewhat approaches the triconodont type,having a third cusp just inside to the first. This cusp, however,is soon worn away, and is no longer visible in a fully developed skull.The second molar is tritubercular. The last molar of the upper jaw is small and not in line with the preceding. The third premolar and the two molars,though provided with sharp cusps, are not sectorial but have broadened crowns pointing to an occasional plant diet. The lower canines and premolars bite in front of the upper ones. The dental formula is :- $\frac{3,1,3,3.}{3\ 1\ 3\ 2}$.

The skull of a young adult varies considerably from that of an older specimen. In the younger specimen the occipital and sagittal crests have not yet been developed. In fact they seem to appear late in life. The sutures still discernible in younger specimens disappear. The postorbital processes of the frontal and jugal ossify more and become much more pronounced. The whole interorbital region of the frontal becomes denser and more strongly pronounced and widens. As a whole the skull tends to broaden the older the animal becomes. The post glenoid process also becomes pronounced in an advanced stage. There is a bony symphysis of the mandible. In younger adults the line of fusion of the two mandibular halves can still be discerned,but it disappears in advanced age. In young adults the course of the bony auditory meatus is marked by a line of fine holes,which becomes a fissure in advanced age. In younger adults the dental formula is :- $\frac{3,1,3,3}{3,1,3,3}$ The innermost incisors appear at a more advanced age,their place is indicated by a gap between the two inner incisors. In fact the occipital and sagittal crests have reached a fair development before the innermost incisors are formed.

THE FORAMINA IN THE SKULL (Plates IV-V Figs.7and 8.)are twenty five in number and are best enumerated in tabulated form,giving the name ,position and function of each foramen.

FORAMINA IN THE SKULL.

NAME	POSITION	FUNCTION
1/Pores of cribriform plate	In the mesethmoid boundary of the cranial cavity.	Transmits the first nerve.
2/Optic foramen	In the orbitosphenoid	Transmits optic nerve.
3/Foramen lacerum anterius	Between orbito- and alisphenoids	Transmits 3rd,4th,6th and ophthalmic of 5th nerve
4/Foramen rotundum	In alisphenoid	Transmits 2nd. branch of 5th. nerve.
5/Foramen ovale	In alisphenoid	Transmits 3rd branch of 5th.nerve.
6/Alisphenoid canal	In alisphenoid at root of pterygoid process.Begins in front of foramen ovale and opens at foramen rotundum.	Transmits the external carotid artery.
7/Foramen lacerum medium	Between alisphenoid and periotic,just internal to opening of Eustachian canal	Transmits the internal carotid artery.
8/Eustachian canal	Internal to foramen lacerum medium and arched over by projecting bone of bulla.	
9/Internal auditory meatus	Large,in periotic its course marked by a fissure.	Transmits the 7th.and 8th. nerves.
10/Carotid foramen	Between bulla and basioccipital	Transmits a branch of internal carotid artery
11/Foramen lacerum posterius	Between periotic and exoccipitals	Transmits 9th,10th.11th nerves and internal jugular vein.
12/Stylomastoid foramen	On bulla,between the paroccipital and mastoid portion of the periotic.	Through it the 7th.nerve leaves the skull.
13/Condylar foramen	In exoccipital just behind foramen lacerum posterius	Transmits the 12th.nerve.
14/Postglenoid foramen	Very small, at commencement of glenoid surface of squamosal	Transmits a vein.
15/External auditory meatus	On outer side of bulla	Opens into external ear.

(Foramina in the skull cont.)

NAME	POSITION	FUNCTION
16/Infra-orbital foramen	In middle of maxilla,at side of face	Part of 2nd.branch of 5th.nerve passes to side of face.
17/Lachrymal foramen	In lachrymal bone	Opens into lachrymal duct
18/Internal orbital foramina	In palatines,within the orbit below the lachrymal foramen and above the last molar.	Transmit the 5th.nerve passing into the nasal cavity.
19/Anterior palatine foramina	Between premaxillae and maxillae in the anterior part of the palate,in front of the canines.	Transmit a part of the 5th.nerve.
20/Posterior palatine foramina	All along the palate about five pairs	Transmit branches of the 5th.nerve and blood vessels.
21/Posterior nares	Bounded chiefly by the palatines.	
22/Anterior nares	Bounded by nasals and premaxillae.	
23/Foramen magnum	Bounded by supra- and exoccipitals and occipital condyles.	
24/Inferior dental foramen	On inner surface of each mandibular ramus below the coronoid process.	Transmits an artery and a branch of the 5th,nerve to the teeth.
25/Mental foramen	On outer side of mandibular ramus near anterior end.	A branch of the 5th.nerve passes out.

SKULL MEASUREMENTS taken of the largest skull.Greatest length of the skull 70mms.; basilar length 58mms.; zygomatic breadth 45mms.; breadth from bulla to bulla 36.5mms.; greatest breadth 30mms.; intertemporal breadth 18mms. and 35.3mms.; interorbital breadth 14.1mms.; bulla 16.5mms.; palatal length 35.75mms.; palatal breadth 21mms.; brain case 30.75mms..

These measurements may be compared to those taken by Mr,A.

Roberts,of the Transvaal Museum,of the skull of an old Bothaville (O.F.S.) male:-greatest length of skull 70.5mms.; basilar length 58.5mms.; zygomatic breadth 47mms.; breadth from bulla to bulla 35.2mms.; greatest breadth 31mms.; intertemporal breadth 18.5ms.and 36.7mms.; interorbital breadth 14.1mms.; bulla 16.8mms. ; palatal length 35.2mms.; palatal breadth 21.8mms.; brain case 31.2mms..

THE AXES OF THE SKULL (PlateVI Fig.10) are five in number namely the basicranial axis - a line drawn from the foramen magnum to the front end of the middle part of the upper surface of thepresphenoid -; the basifacial axis - a line drawn from the same point of the presphenoid to the front part of the alveolar margin of the premaxilla. The cranial axis is a line drawn from the front end of the basicranial axis to the summit of the attachment of the tentorium. The plane of the cribriform plate is a line extending from the front end of the basifacial axis tothe summit of the mesethmoid. The plane of the foramen magnum is a line drawn from the occipital condyle to the supraoccipital. The basicranial axis forms with the plane of the foramen magnum an angle of 97^{0},and with the cranial axis an angle of 48^{0},with the plane of the cribriform plate an angle of 178^{0},and with the basifacial axis an angle of 138^{0}.The basifacial axis forms with the plane of the cribriform plate an angle of 45^{0},and with the cranial axis an angle of 176^{0}.

THE VERTEBRAL COLUMN. The c e r v i c a l v e r t e b r a e are seven in number.(Plate VIIFigs.18-22)The a t l a s (Figs.12 - 15) has very deep cups for the articulation with the occipital condyles. The wings are well developed. The a x i s has a long conical odontoid peg; the neural spine is high,compressed and elongate from before backwards,and is especially produced forwards. (Plate VII Figs.16-20. and Plate VII Figs.21 & 22)

The 3rd. cervical vertebra has no distinct neural spine,it is only indicated by a slight ridge; the 4th. has a small compressed spine. The neural spines of the remaining three vertebrae gradually lengthen until the maximum in the 7th. is reached. Their transverse processes are large.The inferior lamellae are

very slightly indicated. The base of the7th. vertebra is imperforate. Metapophyses are more or less developed.

The t h o r a c i c vertebrae (Plate VII Figs. 23-25) are fourteen in number,not fifteen as stated by F.E.Beddard. The 11th. vertebra is anticlinial. In front of this vertebra the vertebrae are provided with long,slender,backwardly directed spines,behind this the spines are shorter,thicker and directed forwards,and the metapophyses and anapophyses become distinctly developed.

The l u m b a r vertebrae are six in number with fairly long transverse processes directed forwards and downwards and the spines are short,stout and compressed. The maximum length of both the transverse processes and spines is reached in the 6th. vertebra.(Plate VII Figs.26-28 and Figs.29-31.)

The s a c r a l vertebrae consist of two fused vertebrae, their transverse processes form the wings,which articulate with the ilia. Rudiments of spines and zygapophyses are discernible.

The c a u d a l vertebrae vary from twenty-one to twenty-four in number.The first eight still have distinct prezygapophyses and postzygapophyses as well as indications of metapophyses and anapophyses.The remaining vertebrae become more and more subcylindrical; the last one being a pointed bone. Chevron bones are present on the 7th. to 14th. caudal vertebrae.

All the vertebrae are amphiplatyan and provided with bony inter vertebral discs.

THE STERNUM (Plate VIII Fig. 32) is composed of six mesosternebrae,a presternum and a xiphisternum.Mesosternebrae 1 to 6 are all nearly of the same size. The presternum or manubrium is long narrow and expanded in front for the articulation of the first pair of ribs. It ends anteriorly in a laterally compressed,pointed process. The xiphisternum is long,narrow,rounded and ends in an ensiform cartilage. The mesosternebrae,distinctly separated from each other,are elongate,four-sided and each is somewhat contracted in the middle. The first sternebra has an articulating surface for the 2nd. sternal rib. The notches for the 3rd.,4th., 5th.,6th.,and 7th. sternal ribs are situated at the lines of junction of the sternebrae. The notches for the 8th.and 9th.

sternal ribs are placed close together at the hinder end of the mesosternecra.

THE RIBS. There are fourteen pairs of ribs. The vertebral ribs are comparatively slender,subcylindrical and little curved. The sternal ribs are not segmented off from the vertebral ribs. The last five pairs are false ribs,the last two form floating ribs. The last two ribs have no tuberculum.(PlateVIII,Figs.33-35)

THE PECTORAL GIRDLE AND LIMBS. The s c a p u l a is more or less triangular in shape,very slightly curved backwards. (Plate IX,Figs.36-37) The scapula is very thin,being in fact translucent. The spine is placed more towards the anterior border so that the post-scapular fossa is slightly the larger. The a-cromion is well developed and recurved. The metacromion is also well developed. The coracoid is very small. Clavicles are absent.

THE FORE LIMB. The h u m e r u s (Plate IX,Figs. 38-42) is provided with an entepicondylar foramen and a supratrochlear foramen. It is imperfectly cylindrical,being flattened from side to side above,and from before backwards below. The shaft has its inner surface marked above by a wide longitudinal depression,the bicipital groove,where the biceps muscle is lodged. External to this is a slightly roughened and elevated tract,the deltoid ridge which serves for the attachment of the deltoid muscle.

On the lower part of the shaft the anterior surface is separated from the posterior by two ridges,one on each side,which become more pronounced on nearing the distal portion of the bone. The outer ridge is the supinator the inner the pronator ridge. Within these ridges lies the entepicondylar foramen,which transmits the median nerve and the brachial artery.

On the hinder surface of the somewhat convex shaft is a very slightly marked,oblique groove,the musculo-spiral,passing from above downwards and outwards.

The proximal end of the humerus (Plate IX Fig. 41) shows a large,rounded,convex head,covered in the living animal with cartilage and articulated to the glenoid cavity of the scapula. The head is placed in such a way that its axis does not coincide with that of the shaft. On the outer and inner sides of the head

are two blunt prominences. The one lying on the outer side of the summit of the bicipital groove is the greater tuberosity, which has at its hinder end a depressed surface for the insertion of the infraspinatus muscle. The smaller prominence, the lesser tuberosity, is placed on the inner side of the bicipital groove. Both tuberosities serve for the attachment of muscles.

The distal part of the humerus (Plate IX Fig. 42) expands considerably and forms prominences-condyles- on each side. The internal condyle projects further inwards than does the external outwards. Between the condyles lies the concave and convex articular surface for the radius and ulna. At its outer part it forms a rounded prominence, the capitellum, which articulates with the radius. Internal to this is a transversely concave surface, the trochlea, which articulates with the ulna. Immediately above the trochlea lies the coronoid fossa, a shallow cavity which receives the coronoid process of the ulna. Above it lies the supratrochlear fossa, which is pierced by the supratrochlear foramen. It receives the olecranon. In young specimens this foramen is closed by a thin tissue. In older specimens this tissue ossifies to some extent leaving, however, a fair sized foramen.

The r a d i u s (Plate X, Figs. 43&44) slightly shorter than the humerus, is long, cylindrical and expanded at either end and flattened on one side. The long middle part of the bone is a little curved, with the convexity forwards and outwards. At the proximal part of its inner margin is a tuberosity to which the tendon of the biceps is attached. Just above this tuberosity the bone is narrowed into a neck from which rises the head. The head is oval with a smooth margin and concave above for articulation with the capitellum of the humerus. At its distal end the radius broadens out and its anterior surface is grooved for the passage of tendons. Its outer side is prolonged into a styloid process. The distal end of the radius articulates with the carpus by a large concave surface. Its outer distal end also has internally a small articular surface for the ulna.

The u l n a (Plate X Figs. 45 - 47) is longer than the humerus and much longer than the radius. It is flattened both in front

are two blunt prominences. The one lying on the outer side of the summit of the bicipital groove is the greater tuberosity, which has at its hinder end a depressed surface for the insertion of the infraspinatus muscle. The smaller prominence, the lesser tuberosity, is placed on the inner side of the bicipital groove. Both tuberosities serve for the attachment of muscles.

The distal part of the humerus (Plate IX Fig. 42) expands considerably and forms prominences-condyles- on each side. The internal condyle projects further inwards than does the external outwards. Between the condyles lies the concave and convex articular surface for the radius and ulna. At its outer part it forms a rounded prominence, the capitellum, which articulates with the radius. Internal to this is a transversely concave surface, the trochlea, which articulates with the ulna. Immediately above the trochlea lies the coronoid fossa, a shallow cavity which receives the coronoid process of the ulna. Above it lies the supratrochlear fossa, which is pierced by the supratrochlear foramen. It receives the olecranon. In young specimens this foramen is closed by a thin tissue. In older specimens this tissue ossifies to some extent leaving, however, a fair sized foramen.

The r a d i u s (Plate X Figs. 43&44) slightly shorter than the humerus, is long, cylindrical and expanded at either end and flattened on one side. The long middle part of the bone is a little curved, with the convexity forwards and outwards. At the proximal part of its inner margin is a tuberosity to which the tendon of the biceps is attached. Just above this tuberosity the bone is narrowed into a neck from which rises the head. The head is oval with a smooth margin and concave above for articulation with the capitellum of the humerus. At its distal end the radius broadens out and its anterior surface is grooved for the passage of tendons. Its outer side is prolonged into a styloid process. The distal end of the radius articulates with the carpus by a large concave surface. Its outer distal end also has internally a small articular surface for the ulna.

The u l n a (Plate X Figs. 45 - 47) is longer than the humerus and much longer than the radius. It is flattened both in front

and behind with a rather sharp radial margin to which an interosseus membrane is attached,which connects the ulna with the radius. The proximal end has a deep sigmoid fossa for articulation with the trochlea of the humerus. The fossa is unequally divided by an ill-defined vertical prominence,which extends between the two processes which bound the fossa above and below respectively (Plate X Fig. 47) The lower process is the coronoid,which fits into the coronoid fossa of the humerus. The higher and larger process is the olecranon,which passes into the supratrochlear or olecranal foramen or fossa of the humerus. The olecranon ends in a rough surface to which the triceps muscle is attached. On the outer side of the coroncid process is a small,elongated,concave, articular surface,the lesser sigmoid cavity,upon which the head of the radius turns. The distal end of the ulna is a small,rounded,convex head which articulates with the adjacent surface of the radius. On its opposite side is developed a large,laterally compressed,styloid process,which directly articulates with the carpus.

The c a r p u s is composed of seven bones,arranged in two transvers rows. Those of the proximal row are :- the scapho-lunar, the cuneiform and the pisiform. Those of the distal row are :- the trapezium,the trapezoid,the os magnum and the unciform.(Plate XI Figs. 48 & 49).

The carpus has a convex dorsal surface,while its palmar surface is concave from side to side. The scapho-lunar and the cuneiform together form a convex surface,which fits into the articular surface of the radius.

The scapho-lunar,formed by the fusion of the scaphoid and lunar,is the largest carpal bone. Is long axis is transverse;it is smooth and convex above,joining the radius; below it fits into a depression formed by the four distal carpals. From the hinder part of the outer side of the bone a tubercle projects outwards and backwards.

The cuneiform is wedge-shaped and articulates with the innermost carpal. The pisiform projects freely backwards and downwards from the palmar surface. It is supported by the cuneiform,but

also articulates with the unciform.

The trapezium is the smallest and most radial carpal bone. It is convex from without inwards and convex from before backwards.

The trapezoid is also small, and articulates distally by a slight convexity with the second metacarpal. It is hardly visible on the palmar surface.

The os magnum is much larger than the last two. It is convex above and articulates mainly with the third metacarpal.

The unciform lies on the ulnar side. It articulates slightly with the fourth mainly with the fifth metacarpal. Its upper surface is narrow and convex. Its palmar surface develops a small palmar process.

The metacarpus is composed of four elongated bones and the mere vestige of a fifth, each of the four supports a digit at the distal end. The proximal end of each metacarpal is formed so as to fit the carpal bones exactly; while the distal end of each has the form of a rounded head. The metacarpals are curved and thus slightly concave from above downwards. The dorsal surface of each is a little flattened, more so than the ventral side. The first metacarpal is represented by a vestigial bone only and joins the trapezium, The four metacarpals decrease in length outwards from the third, so that the second is slightly shorter than the fourth but longer than the fifth. The articular surfaces of the heads of the metacarpals extend further on the palmar than on the dorsal surface. Each has on its palmar surface a median ridge, on each side of which a small, rounded sesamoid bone is attached.

There are four digits. The pollex is absent. Each digit consists of three elongated phalanges. (Plate XI, Fig. 50) The phalanges become successively shorter and smaller, the third phalanx, a little shorter than the second, is vertically expanded to support the claw. The first phalanges are somewhat curved like the metacarpals. They are smooth and transversely convex dorsally but somewhat concave ventrally. At their proximal end each is concave, but distally each has two condyles divided by a shallow groove. The middle row of the phalanges is like the proximal row but the phalanges are smaller and each has proximally a median

elevation with a concavity on each side,which fits the condyles of the first phalanx. The penultimate phalanx of each digit is hollowed out on the ulnar side and the ultimate phalanx generally lies bent back,reposing in the cavity thus prepared.

Each third phalanx has its proximal end produced backwards ventrally,so that,when it is placed with its long axis horizontal its articular surface is exposed dorsally. The phalanx is much compressed laterally,ending distally in a sharp,vertically curved process and greatly flattened from side to side. A thin lamella of bone projects forward above and on each side of the base of this curved process,enclosing a deep groove for the reception of the claw.

THE PELVIC GIRDLE AND LIMBS. (Plates XII - XIV Figs.53 - 68).

The p e l v i s (Plate XII Figs.53 - 55) consists of an os innominatum on either side,connected one to the other by the pubic symphysis. Each os innominatum (Figs.54 & 55) consists of an ilium,ischium and pubis. The ilium forms the elongated upper portion of the os innominatum,and is joined to the sacrum. Its outer surface is somewhat concave and its upper border forms a crest and is somewhat convex and arched. To this surface the gluteal muscles are attached. From the front end of the crest the anterior border descends sharply to the pubis; a blunt prominence,the iliopectineal,marks the point of junction. From the hinder end of the crest descends the posterior border,the summit of which is marked by the posterior spinous process,separated by a wide notch from a small marked prominence,the spine of the ischium. The inner surface of the ilium is slightly concave forming the iliac fossa; and at its anterior and upper part is a rough,irregular, auricular surface for the articulation with the sacrum. The ilium forms about the upper third of the acetabulum.

The pubis forms the inner part of the acetabulum and of the os innominatum. It joins the ilium at the iliopectineal eminence, to the formation of which it contributes. From here it descends inwards as the flattened horizontal ramus,till it meets with its fellow of the opposite side,when it turns backwards and downwards

to form a short pubic symphysis. From this pubic symphysis the pubis runs outwards and backwards till it meets the ischium.

The ischium forms the outer and posterior part of the acetabulum as well as of the os innominatum. The body of the ischium forms about two-fifth of the acetabulum,which is situated on its anterior and outer side. The body is broad and sends from its posterior upper margin the ischial spine. Behind this and the acetabulum the ischium slightly contracts and then expands again The expansion has a rough,outwardly projecting tuberosity. On the tuberosities of the ischia the animal sits. Just below the tuberosity the ischium sends off a flat band of bone,which curves forwards and downwards and meets the pubis. Between the spine and the tuberosity the upper posterior margin of the ischium is somewhat concave.

The acetabulum has a prominent rim except at the inner and lower part,where the rim is interrupted by the cotyloid notch. There is no perforation in the acetabulum,but its surface within the cotyloid notch is depressed; this depression serves for the attachment of the ligamentum teres to the head of the femur. Enclosed by the ischium and pubis is the oval and somewhat triangular obturator foramen. The concavity in the posterior border,between the posterior spinous process of the ilium and the spine of the ischium is the greater ischiatic notch,the other concavity between the spine of the ischium and the ischial tuberosity is the lesser ischiatic notch.

The width from side to side of the pelvis is about equal to its depth from the brim of the pubis to midway between the tuberosities of the ischia. Either of these dimensions is much less than half the greatest extent of the ossa innominata.

The f e m u r (Plate XIII Figs. 56 - 61) is somewhat shorter than the ulna and is more or less cylindrical,with a rounded head proximally,fitting into the acetabulum and with an expansion distally with two articular surfaces. The shaft,which is nearly straight,is smooth anteriorly,but has an oblique ridge,the linea aspera,posteriorly,which is most marked about half way up the bone. At the proximal end of the shaft,projecting from the

outer margin of the bone,which it continues upwards,is the greater trochanter. From the inner and hinder side of the bone stands out the much smaller and more conical lesser trochanter. There is no third trochanter. A posterior intertrochanteric ridge extend on the posterior side of the femur between the two trochanters, while a slightly marked anterior intertrochanteric ridge connects the two trochanters on the anterior surface of the femur. On the inner and hinder side of the greater trochanter lies the trochanteric fossa. From between the intertrochanteric ridges the neck of the femur,a narrower bone,compressed antero-posteriorly,arises It projects inwards and forms a slightly obtuse angle with the shaft and ends in the rounded head. On the posterior part of the inner side of the head is a pit,which serves to attach the ligamentum teres. On the outer side of the posterior part of the femur,a little below the greater trochanter,is a vertical ridge which serves for the insertion of the gluteus maximus muscle.

On the distal end of the femur (Fig.59) are the two rounded condyles elongated from before backwards and of nearly equal size separated behind by a median depression. The external condyle has on its outer surface a depression for the tendon of the popliteus muscle. Immediately above this lies the slight external tuberosity,above which again is a pit for the tendon of the gastrocnemius muscle. The internal condyle is a little longer,and descends a little lower down than the external one. On its inner side is the internal tuberosity. The articular surfaces of the condyles meet in front and form an elongated,transversely concave ascending,articular surface for the patella. Posteriorly they diverge leaving between them the inter-condyloid fossa. The femur does not articulate with the fibula,only with the tibia.

The p a t e l l a (Plate XIII Fig.63) is small,elongate and oval,and convex in both directions externally,while internally it is convex transversely,but concave from above downwards.

The t i b i a (Plate XIV Figs.63,64,66,67 & 68) has more or less the same length as the ulna. The proximal end is wide with two condyles,which are each convex from before backwards,and slightly concave from side to side. They receive the condyles of

the femur. Between the two condyles lies a depression giving inser-tion to the one end of the crucial ligaments. The two condyles are supported by external and internal tuberosities respectively. Beneath the external one is a very small articular surface for the proximal part of the fibula. The shaft of the tibia is more or less triangular and is produced into a sharp crest anteriorly on the internal side of the crest the bone is more or less flatten-ed while strongly concave on the outer side. In front, on the proximal end, is a median tuberosity or tubercle with a flattened surface for the attachment of the patella.

On the posterior surface, just below the external condyle, lies a wide, vertical groove, extending about one-third the length of the shaft, for the tendon of the flexor muscle. The distal end of the tibia is much smaller than the proximal. Its outer surface is somewhat flattened for reception of the fibula; its inner margin is produced downwards into a strongly marked, triangular internal malleolus, which articulates with the inner side of the tarsus.

The posterior part of the non-articulating surface of the in-ternal malleolus shows two small vertical grooves for the attach-ment of muscles. The lower end of the tibia presents an irregular and undulating, articular surface. This corresponds to the surface of the tarsus, which it joins. This surface has a median ridge, running obliquely backwards and inwards from its front margin and fitting into the groove on the upper surface of the astragalus On the outer side of the ridge is a fairly wide articular surface which slopes upwards and outwards; on its inner surface is a more concave, but less inclined surface which becomes continuous with the articular surface, borne by the internal malleolus. The hinder margin of this articular surface descends slightly below its front border, which has a descending process corresponding with the front end of the median ridge.

The f i b u l a (Plate XIV Figs. 63 & 65) is the most slender bone of the limb. It extends on the outer side of the leg from close to the knee down to the ankle. Its proximal part is slight-ly enlarged into a head, which articulates with the outer side of

the head of the tibia. Its outer surface is concave.The shaft of this bone is irregularly triangular. Its distal end is expanded into an external malleolus,which articulates with the outer side of the tarsus. The external malleolus does not extend as far down as the internal one. It also has a deep groove for the attachment of muscles.

The t a r s u s (Plate XI Figs. 51 & 52) is composed of seven bones,namely the astragalus,the calcaneum,the cuboid,the navicular,the ectocuneiform,the mesocuneiform,and the entocuneiform.

The astragalus is short and irregular and divisible into a body,neck and head. The upper surface possesses an articular surface for the tibia. Two other articular surfaces almost at right angles to the former,join the two malleoli respectively. The posterior surface of the bone is grooved for the tendon of a muscle. The anterior part of this bone is prolonged forward as a neck ending in a rounded head,which fits into the posterior surface of the navicular. This anterior part also has a concavity from which a muscle springs.

The calcaneum is more than twice as long as it is broad and is somewhat expanded at its posterior extremity,which is vertically grooved for a muscle. It articulates with the astragalus above and with the cuboid in front. It has a process on its inner side to support part of the cuboid,and another smaller process on its outer side just before joining the cuboid.

The navicular is dorsally wider than long.Posteriorly it is deeply concave,receiving the head of the astragalus. Anteriorly it has three surfaces for the articulation with the three cuneiforms. Its inner margin gives off a tuberosity,which passes below the head of the astragalus to support it.

The cuboid,situated on the outer side of the tarsus,articulates with the calcaneum posteriorly and with both the fourth and fifth metatarsals anteriorly. Its inferior surface is traversed by a groove for the tendon of a muscle.

The three cuneiform bones are small,the mesocuneiform is the smallest and not visible on the plantar surface. They articulate

with the navicular.

There are four digits. The first metatarsus is a very small conical bone, representing the vestige of a hallux. The third metatarsus is the thickest of the four. The proximal ends of all the metatarsals are enlarged, each with an articular surface. That of the second is small and triangular, that of the third large and crescentic; that of the fourth is medium in size and quadrangular; that of the fifth is very small and oval, with a tuberosity extending backwards on its outer side. The shafts of the four are flattened dorsally and on their plantar surface, and where they come in contact with each other at their proximal ends. The second metatarsus is the shortest; the third the longest and stoutest; the fifth the most slender. Each of the four has distally a rounded head, which articulates with the proximal end of the respective phalanx. As in the corresponding part of the metacarpals, there is a median, ventral ridge with a sesamoid bone on either side. Each digit has three phalanges; there is no hallux. In form and arrangement they essentially resemble those of the fore paw.

THE MUSCULAR SYSTEM.

The muscular system is of the typical mammalian type. Examinations of the superficial muscles of the head, trunk and limbs were made, as well as the deeper lying muscles of the latter. Only those muscles shewn in the plates are described. (Plates XV - XVII, Figs. 69 - 75).

MUSCLES OF THE HEAD AND TRUNK. (Plate XV, Fig. 69) The o r b i c u l a r i s o r i s is a sphincter muscle, the fibres of which extend round the mouth in the lips. The fibres of the upper and lower lips meet at each angle of the mouth.

The o r b i c u l a r i s p a l p e b r a r u m is the thin sphincter muscle of the eye-lids. Its fibres are arranged concentrically and are attached to the inner margin of the orbit.

The l e v a t o r a n g u l o r i s , a small, fleshy mass, arises below the infraorbital foramen and descends to the outer portion of the nose and upper lip.

The p y r a m i d a l i s passes downwards from the frontal

bone to the dorsal surface of the nose.

The zygomaticus is small and extends downwards from the jugal bone, near the maxillary bone, to the orbicularis oris.

The myrtiformis is triangular and stretches from the upper lip to the side of the nose.

The fronto-auricular is large and stretches over the parietal and frontal bones to the orbit and ear.

The retrahentes auriculam come from the occipital and cervical regions to the pinna of the ear. They are not very well developed.

The buccinator is thin and extends between the alveolar margins of the jaws on each side of the mouth.

The masseter, a short and very thick muscle, arises from the jugal bone and the ventral surface of the zygoma. Its fibres pas obliquely backwards to be inserted in the ascending ramus of the lower jaw.

The temporal lies between the orbit, ear, masseter and fronto-auricular muscles. It fills up the temporal fossa within the zygomatic arch.

The digastric, arising behind the external auditory meatus, is attached to the inside of the anterior half of the lower jaw.

The stylo-hyoid is long and descends from behind the external auditory meatus to the neck.

The stylo-glossus arises below the ear and descends to the tongue.

The sterno-hyoid extends from the inner surface of the sternum to the basihyal.

The sterno-thyroid arises close to the above and ends in the thyroid cartilage of the larynx.

The sternomastoid springs from the periotic bone and passes to the border of the glenoid cavity.

The scalenus secundus lies deeply at the side of the neck and arises from the transverse processes of the last four cervical vertebrae to be inserted into the first rib.

The s c a l e n u s p r i m u s, closely connected with the above, is long and arises by strong tendons from the 4th. and 5th. cervical vertebrae and is inserted near the sternum into the 4th 5th. and 6th. ribs.

MUSCLES OF THE TRUNK. (Plate XV Fig. 69 & Plate XVI Fig. 70).

The p a n n i c u l u s c a r n o s u s, one of the largest muscles of the body, is intimately connected with the skin. Beneath it lies the t r a p e z i u s, divided into two parts, which are closely connected inferiorly. The anterior portion arises in the middle of the neck, immediately behind the cephalo-humeral, with which it is connected, and is inserted into the spine of the scapula. The hinder portion arise from the neural spines of the second to the thirteenth thoracic vertebrae, and goes to the scapula.

The l a t i s s i m u s d o r s i, a very large muscular sheet, springs from the neural spines of the sixth thoracic to the fourth lumbar vertebrae. Its anterior portion is covered by the posterior portion of the trapezius. It ends in the axilla.

The external d o r s o - e p i t r o c h l e a r is slender and arises outside the spine of the scapula and descends to the olecranon. The internal dorso-epitrochlear has a similar course.

The c l e i d o - m a s t o i d arises with the sternomastoid and has a similar course.

The abdominal region is invested by three great sheets of muscle, supporting and enclosing the viscera. In contracting they expel the excrements and indirectly aid the respiration.

The e x t e r n a l o b l i q u e extends from the nine last ribs to the pelvis.

The i n t e r n a l o b l i q u e arises from the ventral margin of the ilium and pubis. It is inserted inside the cartilages of the ribs and joins with its fellow from the opposite side behind the thorax.

The r e c t u s a b d o m i n i s is long and arises from the pubic symphysis to end in the fourth rib. It is separated from its fellow of the opposite side by a narrow, tendinous linea alba.

The s t e r n a l i s is small and arises from the anterior end of the rectus abdominis close to the sternum. It passes forwards and outwards and ends in the first rib, ventrally to the insertion of the scalenus primus. A small second sternalis extends from the outer margin of the rectus to the fifth and sixth digitations of the serratus magnus, immediately behind the scalenus primus.

THE MUSCLES OF THE FORE-LIMB. (Plates XV & XVI Figs. 69 & 71).

The s e r r a t u s m a g n u s, a large muscular sheet, arises by ten digitations from the sternal surface of the first ten ribs. It is inserted into the vertebral border of the scapula.

The l e v a t o r a n g u l i s c a p u l a e is closely connected with and ends like the former. It originates from the transverse processes of the last five cervical vertebrae.

The r h o m b o i d e u s m a i o r is a squarish muscle, arising from the neural spines of the six last cervical and first five thoracic vertebrae. It ends in the vertebral border of the scapula.

The p e c t o r a l i s is very large and consists of five portions :-

a) The most superficial part is long, narrow and originates beneath the manubrium, and partly joins the cephalo-humoral.

b) The second and largest part extends from the manubrium and sternum, as far back as the fourth costal cartilage, to the deltoid ridge of the humerus, which it passes down for some distance.

c) The third part arises from the sternum between the second and seventh costal cartilages and ends in the head of the humerus, between the tuberosities and closely connected with the infraspinatus muscle.

d) The fourth part is the most posterior in position. It arises between the sixth costal cartilage and the xiphisternum. It is inserted into the inner side of the deltoid ridge of the humerus.

e) The fifth and smallest part is the most anterior. It arises from the side of the manubrium, partly covered by and

more or less blended with the second part. It ends in the humerus just above the insertion of the second part.

The c e p h a l o h u m e r a l is large and arises conterminously with and partly blended with the anterior part of the trapezius. Its main part arises from the back of the skull and the occipital crest, and from the middle of the neck, and passes down the anterior end of the upper arm.

The d e l t o i d consists of three portions. One part arises from the scapula, the acromion and metacromion processes; another part from the posterior side of the scapular spine. These two parts end, externally to the bicipital groove, on the deltoid surface of the humerus. The third part arises from the border of the glenoid cavity and fuses with the adjacent part of the cephalohumeral.

The b i c e p s is spindle shaped and originates from the anterior edge of the glenoid cavity and ends on the proximal end of the radius.

The b r a c h i a l i s a n t i c u s is flat and placed on the outer side of the anterior surface of the humerus. It ends in the coronoid process of the ulna.

The t r i c e p s is very large and consists of five parts.

a) The first originates from the summit of the outer, posterior part of the humerus. It passes downwards and blends with the second part just above the elbow.

b) The second and largest part arises from the lower half of the axillary border of the scapula, and ends in the olecranon, after receiving the first part.

c) The third branch arises from the upper and inner side of the shaft of the humerus. It passes downwards and blends with the fourth branch.

d) The fourth branch originates from the whole upper surface of the humerus below the head. It passes downwards, receives the third branch, and ends in the olecranon.

e) The fifth branch is the smallest. It arises from the inner condyle of the humerus and is inserted in the olecranon.

The muscles of the fore arm consist of pronators, supinators,

flexors and extensors.

The p r o n a t o r t e r e s extends from the inner condyle obliquely downwards to the middle of the anterior surface of the radius.

The f l e x o r c a r p i r a d i a l i s is long and narrow. It arises from the internal condyle of the humerus and ends on the proximal end of the palmar surface of the second metacarpal.

The p a l m a r i s l o n g u s arises from the internal condyle of the humerus and,passing down, becomes tendinous at the carpus,where it ends in a palmar fascia,which ends in the bases of the digits.

The f l e x o r p r o f u n d u s d i g i t o r u m has five roots of origin,namely,from the internal condyle,the outer surface of the ulna,the internal condyle,the external condyle and from the radius. The muscle, after having formed a common tendon at the carpus,divides into four small tendons,which supply the distal phalanges of the four digits.

The s u p i n a t o r l o n g u s is long and slender.It arises above the external condyle of the humerus,and ends in the outer side of the distal part of the radius.

The e x t e n s o r c a r p i r a d i a l i s l o n g i o r is long and narrow. It originates from the supinator ridge and ends on the dorsal surface of the second metacarpal.

The e x t e n s o r c a r p i r a d i a l i s b r e v i o r arises close beside and closely connected with the above;it is long and narrow and ends on the dorsal surface of the third metacarpal.

The e x t e n s o r c o m m u n i s d i g i t o r u m arises from the external condyle of the humerus and divides into two parts. The one part sends tendons to the second &third digits. the other a tendon to the fifth digit.

The e x t e n s o r m i n i m i d i g i t i has about the same size as the last mentioned muscle,arising in common with it and running down beside it.It divides into three tendons at the

wrist,which supply the second,third and fourth digits respectively.

The e x t e n s o r o s s i s m e t a c a r p i p o l l i c i s is large and,arising from the surface of the ulna and radius,ends in the second metacarpal.

The e x t e n s o r c a r p i u l n a r i s originates from the external condyle of the humerus and ends in the fifth metacarpal.

THE MUSCLES OF THE HIND LIMB.(Plate XVII Figs.72 & 73) The g l u t e u s m a x i m u s is a great sheet of muscle and more or less divisible into two parts. The one part arises from the membrane,covering the sacral region dorsally,and from the sacrum itself. The other arises from the first two caudal vertebrae.The first is inserted into the great trochanter,the other into the femur below the greater trochanter,by means of a sheet,the fascia lata,which invests thefemur.

The t e n s o r v a g i n a e f e m o r a l i s is large and thick and arises from the anterior end of the ventral margin of the ilium. It ends in the fascia lata.

The g l u t e u s m e d i u s ,large and fleshy,arises from the whole outer surface of the ilium and ends in the greater trochanter.

The q u a d r a t u s f e m o r i s proceeds from the ischial tuberosities and the margin of the ischium below it to the intertrochanteric fossa and the posterior surface of the femur at the lower end of the greater trochanter.

The p s o a s is large and originates from the transverse processesof all the lumbar vertebrae and ends in the lesser trochanter.

The a d d u c t o r is very large and takes its origin from the pubic symphysis and from the ischium and pubis at each end of the symphysis. It is attached to the whole length of the linea aspera of the femur.

The s a r t o r i u s originates from the ventral margin of the ilium,anteriorly. It expands into a sheet investing the anterior and the antero-internal surface of the femur,and finally

ends in the ligament of the patella and internal tuberosity of the tibia.

The s e m i - t e n d i n o s u s is long and subcylindrical, arising from the ischiatic tuberosity, and goes to the tibia.

The s e m i - m e m b r a n o s u s ,thick and fleshy,arises from the ischiatic tuberosity and the ramus of the ischium below the tuberosity down to the pubic symphysis. It is intimately united with the adductor along its course. It is inserted into the internal condyle of the femur,and also by a strong tendon into the internal tuberosity of the tibia.

The b i c e p s f e m o r i s is an elongated muscular sheet, the fibres of which expand in a fan like manner. It arises from the ischiatic tuberosity between the origin of the semi-tendinosus and semi-membranosus muscles. It is inserted into the outer side of the tibia.

The q u a d r i c e p s e x t e n s o r is a very large muscle,which forms the anterior part of the thigh.It is divisible into several parts,namely :-

a) The r e c t u s f e m o r i s originates from the posterior ventral margin of the ilium and by a tendon from the antero-superior edge of the acetabulum.It runs into the tendon of the patella.

b) The v a s t u s e x t e r n u s envelops the rectus femoris anteriorly and is large.It arises from the whole outer surface of the femur and ends as the above mentioned muscle.

The t i b i a l i s a n t i c u s arises from the outer tuberosity and cremial crest of the tibia and from the adjacent part of the fibula.It goes to the rudimentary first metatarsal and also to the second; and surrounds the upper portion of the extensor longus digitorum.

The e x t e n s o r l o n g u s d i g i t o r u m arises by a strong tendon from the pit of the femur,situated just outside the outer margin of the groove for the patella. At the tarsus it passes through a strong tendinous loop,which is attached on to the upper surface of the calcaneum anterior to the astraga-

lus. Before passing through the loop it divides into four tendons which supply the four digits.

The peroneus longus arises from the proximal end of the fibula. It ends in a tendon,passing down in a special groove in front of the external malleolus,which is inserted into the cuboid.

The peroneus brevis originates from the anterior and outer side of the fibula. it ends as a tendon on the proximal end of the fifth metatarsal.

The peroneus quinti dizitii arises from the proximal and outer end of the fibula,and ends on the dorsal surface of the proximal phalanx of the fifth digit.

The gastrocnemius is large and two headed,forming the posterior surface of the shank. Its inner head arises from the internal condyle its outer from the external condyle of the femur. The two heads unite with each other and together with the soleus form a large strong tendon,the tendo Achillis,which ends in the calcaneal tuberosity.

The soleus arises from the summit of the posterior part of the fibula,and ends in the tuberosity of the calcaneum.

The flexor longus digitorum pedis is small and originates on the posterior surface of the tibia and on the summit of the fibula. It ends in a tendon,which passes down a groove behind the internal malleolus. It thendivides into four tendons,which are inserted into the distal phalanges of the digits.

THE RESPIRATORY SYSTEM.

The thoracic cavity is 8inches long,and contains on either side a lung;.The lungs together with the heart,which lies between them, fill the greater portion of the thorax. Each lung is enclosed by a pleura. The pleurae line the left and right halves of the thorax respectively,being reflected over their lungs at their roots. The pleurae are medially separated from above downwards by an anterior mediastinum,containing the heart in its pericardium,and a posterior mediastinum,containing the oesophagus,the

aorta and the two pneumogastric nerves.

The left lung is divided by a deep fissure into two large lobes which are unequal in size. The upper lobe of the two is divided by a transverse fissure. The right lung is divided into four unequal lobes by three deep fissures. The uppermost of these is large and triangular;the next narrow and elongated but much smaller the third lobe is the largest and has the fourth lobe lying on its inner side. The latter is in-completely divided by a fissure into two small,narrow,pointed parts,which are traversed by the inferior vena cava.(Plate XVIII. Fig. 74.)

The floor of the mouth opens into the cartilaginous larynx. From the latter the trachea,which is 8cmms. long,passes backwards and downwards ventrally to the oesophagus along the neck and the thorax. The trachea is permanently hollow,its cavity being supported by fourty-five incomplete cartilaginous rings,which surround it in front remaining incomplete dorsally,where the soft wall adjoins the oesophagus closely. The lower end of the trachea lies above the sternum and the aortic arch. It divides into two bronchi above the pulmonary artery. The right bronchus is short and passes horizontally into the root of the right lung.The left bronchus is a little longer and enters the left lung behind the aortic arch Within the lungs the bronchi divide and subdivide into bronchioles.

The larynx (Plate XVIII.Fig.75) is composed of five cartilages three of which are median and two are laterally placed. The uppermost median cartilage is the epiglottis,which has the form of a triangle its apex ending in a conical point. Its base is attached to the second median cartilage,the thyroid,by means of a ligament. Its posterior surface is concave from side to side.Its anterior surface is,vertically,concave above and convex below. The ventral end of its anterior surface is attached to the tongue and the hyoid bone,its remaining portion is invested by mucous membrane

The thyroid is a large plate,consisting of right and left alae united to each other ventrally at an acute angle. Each ala,somewhat quadrilateral,has a short anterior border,while the posterior one is prolonged upwards and a little downwards into two blunt cornua. The two posterior edges are somewhat oblique,with an un-

dulating margin,and are widely separated from each other. The inferior margin of each ala is concave and slightly convex more anteriorly. The superior margin of each ala is likewise concave and convex more anteriorly. Each ala is smooth and concave within.Each cornu articulates with the epiglottis above and the third median cartilage below.

The third median cartilage,the cricoid,is annular and best developed posteriorly. Its ventral border slightly undulates. Its upper,convex and posterior border has a very slight median notch on each side of which is an oval,convex,articular facet.

The two laterally placed arytenoid cartilages rest each on one of the two articular facets,mentioned above. Each cartilage is triangular in shape,the base of each triangle resting on the cricoid.

THE CIRCULATORY SYSTEM.

The heart, a dark red,conical body enclosed within a pericardium,is distinctly four-chambered. It lies on the ventral side of the body,within the anterior mediastinum, and on the inner surface of the sternum. Its broad base is directed forwards;its blunt apex backwards and slightly to the left,touching the anterior surface of the diaphragm. (Plate XIX,Figs.76 & 77.)

The right auricle communicates with the right ventricle by means of the auriculo-ventricular aperture,which is guarded by the tricuspid valve,consisting of three segments. The left auricle also communicates with the left ventricle by means of an auriculo-ventricular aperture,which is guarded by a bicuspid or mitral valve,consisting of two segments,but is much thicker and stronger than the tricuspid. The lobes of these valves are attached by means of delicate chordae to the columnae carneae,the papillary prolongations inwards of the muscular ventricular walls. The right ventricle gives off anteriorly at its left anterior angle the pulmonary artery,the entrance to which is guarded by three pouch like, semi-lunar valves. Into the left auricle open the right and left pulmonary veins. At the basal,left,anterior end of the left ventricle is the opening of the aorta,guarded by

three semi-lunar valves,similar to those at the entrance of the pulmonary artery. The right auricle receives the superior and inferior venae cavae respectively.

The right auricle is placed on the ventral side of the base of the heart and is smooth. The superior vena cava opens into the anterior,the inferior vena cava by a larger opening into the posterior part of the cavity. Between the two is the opening of the coronary vein. At the posterior part of the septum,which separates the right from the left auricle,is the fossa ovalis,an oval depression and vestige of a former opening connecting the two auricles in the foetus. In front of the fossa ovalis is a transverse prominence,the tubercle of Lower.

The left auricle lies to the left on the dorsal surface of the base of the heart. There are three openings of the pulmonary veins which enter it,two from the left and one from the right side,because the two veins of the right side meet together close to the auricle,so that a single opening into the auricle is formed.

The right ventricle is conically prolonged forwards,forming a conus arteriosus. The left ventricle is the thickest walled part of the whole heart.

The coronary arteries originate from the aorta,one opening on each side immediately anterior to the attachment of its semi-lunar valves.

The pulmonary artery,arising from the conus arteriosus,passes dorsally and to the left. It then bifurcates;one branch passes to the right,dorsal to the aortic arch,and divides and subdivides within the left lung. The other branch passes ventral to the aortic arch to the left lung,where it divides and subdivides. Each pulmonary artery,as it enters the lung ,lies dorsal to the pulmonary veins but ventral to the bronchus. A little to the left of its bifurcation,the pulmonary artery is connected by a fibrous band with the concavity of the aorta. This band is a relic of the foetal ductus arteriosus.

The aorta,soon after its origin,arches to the left,over the left branch of the pulmonary artery and the root of the left lung till it reaches the ventral side of the vertebral column. Thence

it passes backwards through the posterior margin of the diaphragm and ends by dividing into the two iliac arteries. Almost from the origin of the aorta spring the two coronary arteries. Where the aortic arch reaches its height there is given off somewhat to the right,the large innominate artery. The latter runs forward for some distance and then gives off the right subclavian artery from here the innominate artery continues its upward and forward course,till it reaches a point just below the presternum,where it bifurcates into the right and left carotid arteries respectively. The left subclavian artery is the second and much smaller branch given off from the aorta more to the left,where the arch begins to ascend. Thence the aorta passes upwards as the thoracic part of the dorsal aorta.

The two carotids pass forwards along the neck on either side of the trachea and oesophagus,respectively, onwards to the head. Each gives off in succession the following branches :-(1)a rather large artery to the muscles of the neck;(2)opposite to this a small branch to the lymphatic gland lying on the middle of the trachea;(3)a thyroid artery to the thyroid gland and thyroid cartilage;(4)opposite to this another branch to the muscles of the neck,and almost(5)opposite to this again a lingual artery to the tongue.Each carotid then divides into a very small internal carotid artery,which enters the cranial cavity;and a larger external carotid artery,which gives off successively (a)a facial artery to the cheek and lips;(b)a branch to the submaxillary and parotid glands. It then breaks up into a plexus of capillary branches.

The subclavian artery arches over the first rib and enters the axilla. The first branch given off from it is the vertebral artery ,which passes upwards to run through the intervertebrarterial foramina of the first six cervical vertebrae. The next branch is the thyroid axis,arising on the same side as the vertebral artery,it arches over the scapula and sends a branch to the thyroid gland. Some distance further on from the thyroid axis a suprascapular artery ,arching forwards and upwards over the scapula,is given off.

Opposite to the vertebral artery arises the internal mammary

artery. It passes backwards along the dorsal surface of the costal ribs and supplies the mammary glands of the female and the muscles of the ribs in the male. Directly opposite to the thyroid axis a - rises the mammary artery, from which a slender superior phrenic artery branches off to the diaphragm. A superior intercostal artery arises opposite to the suprascapular and supplies the intercostal muscles.

As the subclavian artery passes into the axilla, it becomes the axillary artery, giving off a superior thoracic to the pectoral muscle; an acromial thoracic to the pectoralis, deltoid and serratus magnus muscles; a long thoracic and ular thoracic to the lymph glands and muscles and an anterior and posterior circumflex to the humerus. Below the axilla the artery becomes the brachial artery, which gives off two branches to the muscles and divides below the elbow, into an ulnar and a radial artery. The ulnar artery ends on the palmar surface, after having given off a branch. The radial artery also finally ends on the palmar surface.

The thoracic aorta passes backwards to the left and ventral side of the vertebral column. It perforates the diaphragm and runs on backwards as the abdominal aorta. It gives off numerous small arteries, namely the bronchial, oesophageal and intercostal arteries. Immediately behind the diaphragm the abdominal aorta gives off a very small inferior phrenic artery to the diaphragm and a number of lumbar arteries, which continue backwards the intercostal series.

A little distance behind the diaphragm the large coeliac axis arises, which almost immediately divides into three branches :-

1) The coronary artery of the stomach, extending along the greater curvature of the stomach. (Plate XX Fig. 7a)
2) The hepatic artery, which passes upwards to the transverse fissure of the liver, where it divides and ramifies within the substance of the liver.
3) The splenic artery which supplies the pancreas and spleen.

Some distance behind the coeliac axis arises the fairly large anterior or superior mesenteric artery, which supplies the ileum chiefly. Then comes on either side the small capsular or supra-

renal artery,which passes obliquely outwards to the suprarenal capsules. (Plate XXI Fig.81) On this follow the large but short renal arteries,one on either side, The left renal is a little more posterior in position. Each artery ends in the hilus of the corresponding kidney. Quite a distance from the renal arteries arise the two ovarian or spermatic arteries,one on each side, They are long and slender and supply the ovaries or testes,as the case may be.

Near to the point where the abdominal aorta divides into the iliac arteries,arises a very slender posterior or inferior mesenteric artery,which supplies the rectum. The abdominal aorta divides into two external iliac arteries. Each external iliac artery passes backwards,downwards and outwards giving off an obturator and an epigastric artery. In the thigh the iliac becomes the femoral artery,where it sends off a branch. It then divides into the anterior and posterior tibial arteries,which,after giving off branches,end in the foot.

Behind the external iliac arteries the abdominal aorta gives origin,in the female,to two uterine arteries,which supply the uterus. In the male it gives rise to the inferior vesical artery,which goes to the prostate gland. Close behind these come the fairly large two internal iliac or hypogastric arteries,which ramify in the pelvis.

The abdominal aorta ends in the caudal artery.

The veins from the face and cranium converge to form the external jugular vein on either side. The two veins are connected at the mandibular angle by an undulating branch,receiving the two thyroid veins. (Plates XIX & XXI,Figs.78 & 81) The jugular veins then descend and merge into the subclavian vein. The internal jugular veins are formed by the confluence of the veins of the brain and interior of the cranium. These jugular veins, one on each side,run downwards and parallel and outside to the common carotid arteries, and join the subclavian vein where it is entered by the external jugulars. The common vein thus formed is the right or left innominate or brachiocephalic vein - as the case may be. The internal jugulars both receive a branch from

the thyroid vein. All the veins of the fore limb such as the ulnar,radial and brachial unite ,forming the single axillary vein, which having passed the first rib becomes the great subclavian vein.

The left innominate vein receives an internal mammary vein. Half way along its length it receives an inferior thyroid vein, coming from the left thyroid gland;this is typical of Suricata. Opposite to this vein the innominate receives a superior intercostal vein. After that,close to its junction with its fellow of the opposite side,it receives the vertebral vein,which runs close to the vertebral artery. The two innominate veins join and form the large superior vena cava or precaval vein,which runs backwards along and to the right of the innominate artery,to end in the right auricle. It receives,just after its commencement,the right internal mammary vein.

From the hind limb the veins converge to form the femoral vein,which becomes the external iliac vein on either side. The external iliac together with the caudal,internal iliac and uterine veins,join and fo m the vena cava inferior or the postcaval vein. This is a very la- long vessel,which runs forward on the right side of the a- l aorta. It then bends down perforates the diaphragm,and e- right auricle. In its course it receives the ovarian or spermatic,the renal,capsular,lumbar and phrenic veins. All these veins lie immediately posterior to the corresponding arteries. The renal artery midway from the kidney receives an ovarian vein and from the opposite side a very much undulating and branching dorso-lumbar vein. From the liver,blood enters the vena cava by hepatic veins.

A hepatic portal system is present and consists of a series of veins from the various parts of the alimentary tract,which unite to form a single portal vein. This is formed by the lienogastric,duodenal,anterior and posterior mesenteric veins.

There is a pair of azygos veins,one on each side. They are formed by the union of the intercostal veins. The right azygos vein passes through the diaphragm and opens into the vena cava superior,very near the right auricle. The left azygos opens in-

to the left innominate vein.

THE ALIMENTARY SYSTEM.

The mouth is externally bounded by lips,which form a single fold around the lower and two folds around the upper jaw. Inside, the lips are bound to the gums . frenae. The mucous membrane of the palate is raised into ten curved,transverse rugae. The tongue is long and flat,with nearly parallel sides,tapering slightly anteriorly and to a marked degree posteriorly. On the ventral surface of the tongue is a spindle shaped so-called "worm"or lytta. The dorsal surface of the tongue is flat with a depressed area bounded,posteriorly by the epiglottis. The ventral surface of the tongue is smooth,but the dorsal has four kinds of papillae,namely a)Circumvallate papillae,placed posteriorly;b)fungiform papillae,placed antero-laterally; (c) conical,very closely set and horny papillae,which are placed over nearly the whole surface making it rasp like;(d) flattened papillae,placed behind the circumvallate ones.

The tongue is supported by a hyoid bone,situated at the root of the tongue and anterior to the larynx.(Plate XXII, Figs.83 & 85) It consists of a stout basihyal,to which is attached,posteriorly a pair of long backwardly directed cornua,the thyrohyals. Placed anteriorly and somewhat obliquely on the basihyal,is a pair of small ceratohyals. On these follows a pair of epihyals,forming a knee with the former. On the latter abuts a pair of slender epihyals,which bear,at their ends,the cartilage of the tympanohyal.

There are five pairs of salivary glands,five glands on each side of the head. (Plate XXII Fig.84). The parotid gland lies at the root of the external ear. It is more or less crescentic in shape. Its concavity is applied to the cartilage of the ear. Its inferior border is prolonged downwards and forwards. Its duct, known as Steno's or Stenson's duct,runs forwards,across the masseter muscle,and,perforating the buccinator muscle,opens inside the cheek opposite to the last premolar. Two accessory parotids lie opposite each other,one on the anterior the other on

the posterior margin of the parotid gland. A rounded facial gland lies on the middle of the masseter muscle beside Steno's duct,into which it opens. The submaxillary gland is smaller than the parotid and oval in shape. It lies behind the angle of the mandible and is in contact with the downward prolongation of the parotid. Its duct- Wharton's duct - runs forwards beneath the facial vein and opens on a salivary papilla below and beside the tongue. There are two accessory submaxillary glands,lying side by side and separated from each other by the facial vein, and close to the lower and anterior end of the submaxillary gland.

A large zygomatic gland lies beneath the globe of the eye. It opens into the mouth behind the first molar. The buccal glands are small and open directly by means of small openings into the mouth.

The pharynx lies behind the mouth and posterior nares and is bounded posteriorly by the base of the skull. Into it open the larynx,oesophagus and Eustachian tubes.

The oesophagus is 127mms.long,narrow and cylindrical. It extends backwards and downwards and,piercing the diaphragm,ends immediately behind it in the stomach. The stomach lies somewhat to the left. In shape it somewhat resembles a pear and is a little bent. Its left and more globular portion is the cardiac;the narrower and less dilated end is the pyloric portion,which after forming a constriction,opens into the duodenum. Its concave surface,between the oesophagus and the commencement of the duodenum is the lesser curvature,while the convex side of the stomach is the greater curvature. (Plate XX Fig. 80)

The duodenum begins at the pyloric end of the stomach,ascends for a little distance then bends transversely and descends again. The anterior 88mms. form the duodenum proper,the posterior 38mms form the jejunum. The duodenum encloses the pancreas,the duct of which,as well as the bile duct,enters it. The duodenum lies towards the right side of the stomach. The jejunum is continued into the narrow and much coiled ileum,which is 928mms. long. It is surrounded by adipose tissue and occupies the larger portion of the abdominal cavity. There are about seven Peyer's patches in

the wall of the ileum.

The ileum opens into a rather wide and quite straight rectum, which is 152mms. long. At the junction of the ileum and rectum there is a caecum,somewhat tapering, 28mms. long,bent towards the ileum. The ileum opens into the caecum by an ileo-caecal valve. Towards the posterior end the rectum widens somewhat. There are no anal glands. The anus,viewed externally, is large,measuring 17mms. by 17mms.,and is 26mms. deep,where the end of the rectum, surrounded by a sphincter muscle ,opens into it. Towards the outer margin of the anus,on either side, are the openings of a pair of perineal glands.

The pancreas is large and racemose and is invested by the peritoneum. (Plate XX Fig.80) It consists of lobes and lobules of different size,connected together. The pancreas is elongate and narrow and distinctly divisible into two parts. The one portion, the body lies posterior to and above the posterior border of the stomach on the right,the other part,the head,passes backwards along the duodenum. There are two ducts,one enters the common bile duct before passing into the duodenum, the other enters the duodenum about 26mms. further backwards.

The liver is very large and lies mainly on the right side, immediately behind the diaphragm,between it and the stomach,protected by the cartilages of the ribs. It is thick dorsally and thinning out below,solid,reddish brown in colour,smooth and convex towards the diaphragm,but concave and uneven on its opposite surface. It is divisible into lobes,partly by grooves and notches in its substance,and partly by ligaments and blood vessels connected with it. It is divided into two lateral,unequal halves by the falciform ligament,which passes to it from the adjacent surface of the diaphragm. The ligament makes the part on the right the larger. On the right,as viewed from the ventral surface,there is the large right central lobe in which the gall bladder is embedded. (Plate XXIII Fig.85) The right central lobe is separated from a smaller ridge like right lateral lobe by a right lateral fissure. More or less medially the right central lobe has a portion cut off from it by the cystic fissure. The right lateral lobe

adjoins it,and abuts on the triangular caudate lobe below. The somewhat pyramidal small Spigelian lobe,partly covered by the portal vein,is bounded on the right by the deep fissure of the vena cava inferior and ventrally by the portal fissure. The right central lobe is separated from a small left central lobe by an umbilical fissure; the latter again from the very large and compact left lateral lobe by a left lateral fissure.

The bile ducts come from the lobes of the liver and join the cystic duct from the gall bladder.The common duct,thus formed, opens as the ductus communis choledughus into the duodenum,about 38mms. from the pyloric end,after being joined by one of the pancreatic ducts.

The chief mesentery is that which binds the ileum to the abdominal wall;two small mesenteries the mesocolon and the mesorectum are also present.

There are three omenta,namely the gastro-colic omentum which extends from the stomach anteriorly,to the dorsal surface of the abdominal wall posteriorly; the gastro-hepatic omentum which connects the posterior surface of the liver to the pyloric end of the stomach; the gastro-splenic omentum which stretches from the cardiac portion of the stomach to the spleen.

THE ENDOCRINE ORGANS.

The s u p r a r e n a l c a p s u l e s are small,flat, triangular bodies and are placed one in front of the kidney and nearer towards the abdominal aorta. (Plate XXI,Fig.81) Each of the two capsules is attached to the kidney of the same side by areolar tissue. Each is supplied with an artery and a vein as well as nerves.

The t h y r o i d g l a n d s are two in number,lying on each side of the trachea just below the larynx.(Plate XIX,Fig.78) They are somewhat oval in shape,are reddish brown in colour and well supplied with blood vessels. The gland of the left side has an extra inferior thyroid vein.

The t h y m u s is very small in the adult and lies just above the heart,where the main blood vessels originate.

The s p l e e n is 100mms. long and 14mms. broad.It is elongate in shape having the form of a band. It is concave and smooth on its inner surface by which it is attached to the stomach,occupying most of the greater curvature.(Plate XXIII Fig.86

THE NERVOUS SYSTEM.

The brain is typical and enveloped by the dura mater,the pia mater and the arachnoidea. Each cerebral hemisphere consists of two lobes,a frontal and a temporal lobe. The former occupies the anterior half of each hemisphere,while the latter occupies the rest,except for the posterior,inner and upper portion,which can be regarded as a posterior lobe. The hemispheres are separated from each other by a median longitudinal fissure. Each hemisphere is well provided with sulci and gyri. On the dorsal surface three more or less parallel gyri extend antero-posteriorly on each side of the median longitudinal fissure.They are disposed as follows:- (Plate XXIV,Figs.87 & 89)

1/The s u p e r i o r e x t e r n a l g y r u s runs straight from behind forwards till it reaches a transverse sulcus,the crucial sulcus,round which it bends running inwards again,finally turning outwards and downwards round the supraorbital sulcus.

2/The middle e x t e r n a l g y r u s runs in the median line and curves outwards and downwards at each end.

3/The i n f e r i o r e x t e r n a l g y r u s runs along below the above mentioned and is somewhat divided at each end by ascending sulci.

4/The h i p p o c a m p a l g y r u s lies chiefly ventrally,but is laterally visible when the brain is seen from above. The hippocampal gyrus is also seen incompletely separated by a deep calloso-marginal sulcus from the superior external gyrus,on making a vertical bisection.

Of all the sulci the Sylvian fissure is the most important.It forms a sort of axis round which all these convolutions are disposed.

Between the two cerebral hemispheres lies the corpus callosum connecting the two hemispheres. Immediately in front of the cerebellum lie the four corpora quadrigemina,the more posterior pair the testes,and the smaller anterior nates. In front of the nates lies the pineal gland. In front and external to the corpora quadrigemina lies,on each side,a corpus geniculatum.(Plate XXIV,Fig.1)

The cerebellum is somewhat darker in colour than the cerebrum. Its greatest diameter is transverse and it consists of two lateral lobes and a median vermiform process. The cerebellum is connected to the rest of the brain by three pairs of crura. The anterior connect it with the testes,thus bounding the valve of Viaussens laterally; the median crura are continuous on each side with the pons Varolii,and the posterior crura or restiform bodies connect it to the dorsal surface of the medulla oblongata.

The medulla oblongata forms the hindmost portion of the brain, which gradually merges into the spinal cord. It is,ventrally, marked by a median groove,on each side of which is an anterior pyramid,a prominence going to the pons Varolii.

The olfactory bulbs are very well developed.

The brain,on being viewed from the ventral surface,shows the following structures :- (Plate XXIV,Fig.8)

a/The two c o r p o r a t r a p e z o i d e a lie,one corpus on each side,as a band of transverse fibres in front of the pyramids.

b/The two crura cerebri,which emerge as two white bodies,with longitudinal striations,from the pons Varolii. They diverge as they advance and are traversed by two, anteriorly converging,round optic tracts,thus enclosing a lozenge shaped space.

c/The c o r p u s a l b i c a n s lies in the posterior part of the above mentioned space as a small,round body,which is divided medially into two lateral halves,the c o r p o r a m a m m i l l a r i a.

d/The t u b e r c i n e r u m lies in front of the last and from its middle projects a hollow,conical i n f u n d i b u l u m .

e/The p i t u i t a r y b o d y lies at the end of the in-

fundibulum.

f/The l o c u s p e r f o r a t u s p o s t e r i o r lies between the crura and corpus albicans as a depressed surface with numerous small vascular openings.

g/The l o c u s p e r f o r a t u s a n t e r i o r is placed on each side and just in front of the optic tracts.

h/The median longitudinal fissure and the Sylvian fissure separating the frontal from the temporal lobe.

On bisecting the brain in the line of the median longitudinal fissure the following structures are seen :-(Plate XXIV, Fig.90)

1/The convoluted inner surface of the cerebral hemispheres, the olfactory bulb, the cerebellum and the medulla oblongata.

2/The corpus callosum lies just below the middle of the cerebrum. Its front part bends sharply backwards and downwards forming a genu.

3/The fornix lies below the corpus callosum; it extends upwards and forwards, then curving backwards it reaches to the posterior portion of the corpus callosum. The parts of the fornix enclose the lateral ventricles.

4/The cut surface of the anterior commissure lies below the fornix, anteriorly.

5/Between the corpus callosum and the fornix lies the septum lucidum enclosing the fifth ventricle.

6/Beneath the fornix lies the third ventricle.

7/The foramen of Munro lies beneath the fornix anteriorly.

8/The cut surface of the soft commissure is visible a little behind the foramen of Munro.

9/A little in front and below the third ventricle is the cut surface of the optic chiasma.

10/The pituitary body lies below and behind the above mentioned

11/A little above and behind the last lies the corpus albicans thereon follows the pons Varolii and, behind that the medulla oblongata.

12/The velum interpositum lies above the third ventricle. It thickens behind and forms the pineal gland.

13/On the pituitary body abut the corpora quadrigemina, below

which lies the fourth ventricle, communicating with the third

14/The arbor vitae is shown by the cerebellum in section.

On making a horizontal section of the cerebrum down to the corpus callosum, the following structures are visible:-(Plate XXIV, Fig. 93)

a/The fibres of the corpus callosum pass outwards and near the median line are the striae longitudinales.

b/The lateral ventricles with a body and an anterior cornu.

c/The hippocampus maior, forming the floor of the lateral ventricle, extends outwards and backwards and internally into the lyra, by which it is united with its fellow of the opposite side.

d/The septum lucidum, a triangular body, lies beneath the anterior end of the corpus callosum and in front of the anterior end of the hippocampus and forms the inner wall of the anterior cornu of the lateral ventricle.

e/The choroid plexus lies anterior to the hippocampus and passes, beneath the corpus callosum, through the foramen of Munro, to join its fellow of the opposite side, thus bringing about a communication between the third and the lateral ventricles.

f/The corpus striatum forms the floor of the anterior cornu.

There are twelve pairs of cranial nerves, namely:- the olfactory, optic, oculomotor, pathetic or trochlear, trigeminal, abducent, facial, auditory, glossopharyngeal, pneumogastric or vagus, spinal accessory, and hypo-glossal nerves. Their functions and distribution are typically mammalian.

THE NERVES OF THE NECK.(Plate XXV Fig.93) are chiefly the spinal accessory, the pneumogastric and the glossopharyngeal nerves, with their branches.

The spinal accessory, having left the skull along with the pneumogastric and glossopharyngeal nerves, runs down the neck for about 4cms. and divides into branches to the sterno-mastoid and other muscles. The hypoglossal also runs downwards and, having

traversed the carotid artery near the point of bifurcation into the external and internal branches, runs forwards and inwards to the tongue. Just before traversing the carotid artery, the hypoglossal gives off a ramus descendens, which runs backwards external to and alongside of the carotid artery for the length of 15 mms. It crosses the carotid artery and ends in the muscles of the hyoid and thyroid regions.

Soon after having emerged from the skull, the pneumogastric or vagus forms a ganglionic swelling. It thenruns back-wards along the neck, lying outside of and slightly dorsal to the carotid artery. It enters the thorax and having crossed the subclavian ar - tery, runs alongside the oesophagus and ends in the stomach. The pneumogastric gives origin to several branches, chief of which are (a) the anterior laryngeal, which arises immediately below the pneumogastric ganglion, and runs inwards to the laryngeal and thy - roid muscles. Close to its origin it sends off a slender depressor nerve, which runs backward along the neck, dorsal to the carotid artery and internal to the pneumogastric, to end in the heart. (b) The right posterior or recurrent laryngeal nerve arises from the pneumogastric in the vicinity of the aortic arch. On the left side it loops round the aortic arch and runs forwards alongside the trachea to the larynx. On the right side it loops round the subclavian artery and then runs forwards alongside the trachea to the larynx. (c) The pneumogastric gives off, in the thorax, small branches to the heart, lungs and oesophagus.

A cervical sympathetic nerve lies between the depressor and main stem of the pneumogastric nerve. It forms an anterior cervical ganglion in close proximity to that of the pneumogastric, and just above the aortic arch, more or less at the level of the origin of the left subclavian artery, a posterior cervical ganglion is formed.

From the fourth cervical nerve arises the phrenic nerve, which runs alongside the vertebral column, and enters the thorax. It continues its course backwards and, passing in between the heart and lungs, ends in the diaphragm.

THE SPINAL NERVES arise in pairs from the sides of the spinal

cord. There are eight cervical nerves,as one pair emerges in front of the atlas; fourteen thoracic; six lumbar; two sacral and from twenty-one to twenty-four caudal nerves. Each spinal nerve arises from two roots and divides into three branches. The roots are,a dorsal and ganglionated one and a ventral one. The nerve,so formed passes out by the intervertebral foramen.

THE SYMPATHETIC NERVE CHAIN is formed by the first two branches of the spinal nerves. The sympathetic nerve runs along either side of the trunk as a longitudinal ganglionated cord,supplying the blood vessels and viscera as well as the skin and muscles. Each sympathetic ganglion is connected to the spinal nerve by a ramus communicans.This ramus communicans is the third branch of the spinal nerve.

The ventral roots of the spinal nerves form,with their branches the solar,brachial and lumbo-sacral plexus.

THE SOLAR OR EPIGASTRIC PLEXUS is of the typical mammalian type It is large and lies in the anterior portion of the abdomen, between the stomach,aorta,diaphragm and the suprarenal capsules. It receives the splanchnic nerves and some branches of the pneumogastric. From the last four sympathetic thoracic ganglia arise the greater and lesser splanchnic nerves. From each of the four ganglia there arises a nerve. The nerves of the two anterior converge in front of the diaphragm to form the greater splanchnic nerve; those of the two posterior ganglia unite similarly to form the lesser splanchnic nerve. These two nerves pass through the diaphragm and extend upwards,crossing the coeliac axis,and end in the large coeliac ganglion,a soft,pinkish white mass of irregular form,situated just anterior to the origin of the anterior mesenteric artery. From it branches are given off which accompany the arteries to the different abdominal viscera. Branches connect it to the anterior mesenteric ganglion,which lies immediately posterior to the artery. This ganglion also gives off branches to the viscera and is connected to the renal ganglion,which lies in close proximity to and above the suprarenal artery. The renal ganglion also supplies the suprarenal capsules with nerves besides the kidneys. From the renal ganglion a nerve passes alongside and

ventral to the aorta to the posterior mesenteric artery,where it ends in a posterior mesenteric ganglion,which gives off branches to the rectum. (Plate XXVI,Fig. 94)

From the thoracic ganglia there continues the sympathetic ganglionated chain,which passes backwards parallel and dorsal to the dorsal aorta.

THE BRACHIAL PLEXUS is formed by the union of the sixth to eighth cervical and first thoracic nerves. (Plate XXVI,Fig.95)

The sixth cervical nerve divides soon after emerging from the intervertebral foramen into three main branches. The most anterior of these receives a branch from the fifth cervical,and,immediately below the entrance of this branch,it gives off a slender subclavian nerve,and then passes on straight as the suprascapular nerve. The middle branch gives off a slender connection to the third branch then passes downwards as the circumflex nerve,which soon curves upwards assuming an undulating form.

Just above the place where the third branch of the sixth cervical branches off,and close to the origin of the nerve,two slender nerves,one below the other are given off. The uppermost is the nervus longus colli et scaleni ,the lower forms,together with a slender side branch from the fifth cervical,the respiratory nerve of Bell. The third branch gives off a branch to the seventh cervical,just above and to the left of the entrance into it of the branchlet from the middle branch. It then divides into three branches. Of these one immediately curves backwards and enters the seventh cervical at the same point,where the branchlet from the main branch enters it. The other two branches curve somewhat and extend inwards as the subscapular nerves,after having given off a connective to the musculo-cutaneous nerve.

The seventh cervical gives off,close to its origin,a nervus longus colli et scaleni ,and is crossed by the respiratory nerve of Bell ,just where it receives the two connectives from the sixth It then bifurcates,the one branch passing obliquely downwards as the musculo-cutaneous nerve,which splits into three branches. Where it receives the connective from one branch of the subscapular,it gives off somewhat below that point and on the opposite

side a thoraco-dorsal nerve, which crosses the anterior branch of the musculo-spiral and passes below the posterior branch of the musculo-spiral. The second branch of the seventh cervical extends backwards and obliquely downwards and, half way between the seventh and eighth cervicals, it bifurcates; the one branch runs alongside the musculo-cutaneous and passes beneath the thoraco-dorsal as the anterior musculo-spiral. The other branch runs obliquely onwards as the medial anterior thoracic nerve, and ends in the median nerve, after crossing the seventh cervical.

The seventh cervical also gives off, close to its origin, a nervus longus colli et scaleni. It then passes downwards giving off a connective to the first thoracic; this connective crosses the connective from the first thoracic to the seventh cervical, entering it where the medial anterior thoracic crosses it. It finally bifurcates into the musculo-spiral nerves.

The first thoracic gives off a connective to the seventh cervical and, a little below that point, receives a connective from the seventh. On the opposite side and below the point of entrance of the connective from the seventh cervical, a cutaneous nerve is given off, which branches profusely, and receives a connective from the second thoracic. The main nerve then bifurcates. The anterior branch runs downwards as the median nerve, after having received the medial anterior thoracic. The other branch also runs downwards as the ulnar nerve.

THE LUMBO-SACRAL PLEXUS is formed by the union of the third to sixth lumbar and the two sacral nerves. (Plate XXVI, Fig.8C) The third lumbar nerve bifurcates into an iliac and genito-crural branch. The iliac nerve receives, near its origin, a connective from the second lumbar, and lower down one from the fourth lumbar It runs backwards for some distance and divides into an ilio-hypogastric and an ilio-inguinal nerve. Midway between the iliac and genito-crural branch, the connective from the fourth lumbar to the iliac gives off a slender external cutaneous nerve.

The fourth lumbar, close to its origin, gives off the above mentioned connective to the iliac, and, a little below that, a connective to the genito-crural, which enters the latter at a point

a little below the place where it is crossed by the connective to the iliac .It then curves backwards,giving off a slender psoas nerve,which passes downwards. Thence it extends further backwards and fuses with the fifth lumbar nerve. The two together form the lumbo-sacral cord,which is very thick and extends backwards for a short distance to divide into the pudic and great sciatic nerves. Midway the length of the lumbo-sacral cord,the anterior crural nerve originates,which soon bifurcates.

The sixth lumbar passes obliquely backwards to meet the great sciatic;just before entering it, it gives off on the right a small very slender connective,which also enters the great sciatic On about the same level,where this connective arises but on the opposite side,the sixth lumbar receives a connective from the first sacral.

The first sacral also passes obliquely backwards into the great sciatic. Half way along its length it gives off the connective to the sixth lumbar,and receives,a little below that point,on the opposite side,a connective from the second sacral. From this connective arises a caudal nerve. and,below the point where it enters the first sacral,there also arises a caudal nerve which soon bifurcates. Below that again a small sciatic nerve arises,passing backwards. It receives a branch from the great sciatic,which arises where the first sacral enters it.

THE ORGANS OF SENSE.

a) The tongue is the main organ of taste,especially its posterior region.

b) The organ of smell is very well developed and is contained within the nasal bones and is of the typically mammalian structure. The nasal cartilages extend for quite a distance beyond the nasal bones,forming the snout projecting beyond the lower jaw and bearing at their extremity the external nares. The organ of Jacobson is present.

c) The eye is of the typical mammalian structure and is globular in shape. Its iris is dark brown. The iris is incapable of the contraction so typical of the cat. Lachrymal

and Harderian glands are both present. Typical is the membrana nictitans, which, strengthened by cartilage, exercises the functions of the palpebrae, which in a waking condition are hardly moved. Six eye muscles are present, namely two oblique and four recti.

d) The organ of hearing consists, as in all mammals, of an external, middle and internal ear. The external ear is the cartilaginous, membranous and muscular pinna, which is shell shaped and closely applied to the side of the head. It has a semi-circular form and does not project above the head, but stands behind the opening of the ear. The pinna is concave on the surface directed outwards and convex on its posterior surface. It is hairy within and without; the hairs are short and black. The inner surface has prominences and fossae.

The external auditory meatus extends from the pinna to the tympanic membrane. Its outer part is composed of cartilage its inner of bone. The middle ear is typical. The internal ear is also typical and consists of the vestibule, cochlea and semicircular canals, enclosed in the bony labyrinth.

e) Organs of touch are the vibrissae and the hairs covering the body.

THE URINOGENITAL ORGANS.

The two kidneys are rounded, somewhat bean shaped bodies, smooth externally showing an arborescent network of veins. Each kidney is convex, with the exception of a concave inner side, from the middle of which the ureter arises. The kidneys are placed on either side of the vertebral column, a little behind the diaphragm. The anterior end of the right kidney adjoins the liver posteriorly, while the left lies lower down near the spleen. The kidney has the typical mammalian structure. The ureter as well as the renal vein arise from the hilus, while the artery and nerve enter it dorsal to the vein.

The ureters lie on the dorsal side of the peritoneum and proceed inwards and backwards to the bladder, which they enter obliquely, opening within it by a narrow slit like aperture. The

bladder is hollow and rounded and receives the ureters near the origin of the urethra. (Plates XXVII & XXVIII Figs.98 & 100)

THE MALE GENERATIVE ORGANS.(Plate XXVII Figs.97 - 99) The scrotum,not very large,lies immediately below the perinaeum. It is divided into two halves by a distinct raphe,and the scrotum shows many rugae. (Plate XXVII Fig.97) Its colour is black with hair only placed around it,a few stray hairs occur on it too. Below the scrotum is the aperture for the penis.

Each testis is oval and suspended in the scrotum by the spermatic cord. A conical,more or less separable epididymis lies dorsally and posteriorly upon the testis. Both testis and epididymis are invested by a tunica vaginalis,and the testis alone by an inner coat, the tunica albuginea,thus separating it from the epididymis. From the anterior surface of the testis arises the gubernaculum Hunteri,by means of which the testis can be retracted into the inguinal canal.

The vas deferens is the continuation of the canal of the epididymis. At first much convoluted it becomes straight and extends up the inner side of the epididymis,and thence upwards with the spermatic artery and vein. These,together with the vas deferens and the tissues binding them together,form the spermatic cord. The two vasa deferentia open into the urethra in front of the openings of the ureters.

As it leaves the bladder,the urethra - now a muscular tube - enters the prostate gland. In the floor of the prostatic portion of the urethra is a small,ridge like prominence,the verum montanum,in the midst of which is a narrow,slit like depression,the utricle,within the margins of which the vasa deferentia open into the urethra. The prostate gland is large and prominent. Its greater part lies ventral to the urethra. Here it assumes a roughly triangular form with a groove running through the middle so that,viewed dorsally,only two portions are seen lying alongside the urethra. The gland opens by numerous apertures at the sides of the verum montanum into the urethra.

From the prostate gland the urethra extends as the membranous urethra until it reaches the accelerator urinae muscles and the

crurae ischio-cavernosae. On the ventral surface below these muscles lie Cowper's glands,two large structures of a firm consistency and enveloped by a thick muscular coat. They meet in the median line of the urethra. Each gland opens into the urethra at the root of the penis. The urethra then traverses the penis to open as a small slit like aperture on the distal end of the glans penis.

The penis is conical and composed of a median,ventral and terminal corpus spongiosum,immediately investing the urethra,and two laterally and dorsally placed corpora cavernosa,which are placed side by side and form the bulk of the penis. The penis is attached,by its root,to the pubes and ischia,near the pubic symphysis,by the ischio-cavernosus muscles. The distal end of the penis is the glans,an expansion of the corpus spongiosum. It is conical and pointed,bearing at its extremity the urethral orifice A fold of skin,the prepuce,which is inserted around the glans attaches the penis to the abdominal wall. The penis is retromingent when the animal is sexu lly inactive. A small os penis 7 mms. long,and pyramidal in shape is embedded in the middle part of the distal portion of the penis,reaching almost to the extremity of the glans. (Plate XXVII,Fig.oo) Its pointed end lies within the glans;its base in the penis. The surface of the glans is smooth.

THE FEMALE GENERATIVE ORGANS. (Plate XXVIII,Fig.100) There are two ovaries,placed on either side of the abdomen alittle above and lateral to the posterior end of each kidney. They are ovoidal bodies,about 9mms. by 6mms.in size,situated just external to the fimbriated extremity of the Fallopian tubes. They are whitish in colour and studded with small,round Graafian follicles

The Fallopian tube ends anteriorly in a wide,membranous, funnel shaped extremity with a fimbriated margin. Each tube is very narrow and much convoluted and 1omms. long. It opens into a cornu of the uterus.

The uterus is bicornuate. The two cornua extend obliquely forwards in the abdominal cavity. The uterus proper is a short muscular sac;its commencement,the os tincae,projects prominently

into the posterior part of the vagina. The vagina,into which the uterus opens posteriorly,opens anteriorly into the vestibule.Its mucous membrane has numerous papillae and follicles. Towards the vestibule its muscular fibres arrange themselves as a sphincter. A few rugae extend along its inner surface and terminate at a transverse,circular prominence,the hymen,which marks off the vagina from the vestibule.

The vestibule or urinogenital chamber is short and wide,and opens on the surface of the body,a little below the anus,by a slit like aperture,the vulva,guarded by two labia maiora and surrounded by hair. At the anterior part of the vestibule is the opening of the urethra,which is a short tube and leads directly from the bladder to the vesticule. At the anterior portion of the vulva,within the labia maiora,is the small rod like clitoris and below the labia lie two glands of Bertholini.

Copulation takes place in spring,that is from the end of September to the beginning of November. The mode of coitus is that the female lies down on her abdomen,while the male stands astride over her. The period of gestation is about six weeks. Three to six young ones are usually born. The placentation is zonary and deciduate. The young ones,when born,are blind and half naked;therefore the complicated structure of the burrow to ensure their full protection. Cases are cited when only two young are born in captivity.* In natural surroundings,as already stated,the number of the offspring varies from three to six. It is quite usual to see a female prowling about with her litter of six. This seems to confirm the view that certain wild animals degenerate in captivity with regard to their reproductive capability,as the highest number of young thrown is cited as three,the usual number being two;while in nature the maximum is twice or thrice the number.

---

* A.Haagner, "SOUTH AFRICAN MAMMALS." p. 65.

CLASSIFICATION.

WALLACE gives the following classification :-

ORDER :- Carnivora.

FAMILY:- Viverridae.

SUB-FAMILY:- Rhinogalidae

GENUS :- Suricata.

F.E.BEDDARD gives the following :-

ORDER :- Carnivora.

SUB-ORDER :- Fissipedia.

FAMILY :-Viverridae.

SUB-FAMILY :- Herpestinae.

GENUS :- Suricata.

SPECIES :- Suricata tetradactyla.

The following seems to be the fullest and most justifiable classification :-

ORDER :-Carnivora.

SUB-ORDER :-Fissipedia.

SECTION :-Aeluroidea

FAMILY :-Viverridae.

SUB-FAMILY :-Herpestinae.

GENUS :-Suricata.

SPECIES :-Suricata tetradactyla.

As pointed out in the introductory remarks,it does not,as yet seem advisable - before more proof is to hand - to adopt the classification of O.Thomas and H.Schwann into four sub-species.

GEOGRAPHICAL DISTRIBUTION.

Suricata is a typically South African mammal and is met with in all the upland divisions of the Cape Colony,from Namaqualand to Ceres in the West,and as far as Griqualand East in the East. Northwards it is found throughout the Orange Free State,Great Namaqualand,and the southern and western Transvaal.

PARASITES OF SURICATA TETRADACTYLA.

The first specimen examined was killed,but apparently showed no ectoparasites or endoparasites. The second specimen died and was examined a few hours after death. The intestinal blood vessels were found to be slightly engorged. In the intestinal tract parasites were found,as enumerated below.

The duodenal contents,rather thick and mucoid,were rubbed with water on a slide,and examined fresh as follows :-

a)Near the pyloric constriction a very good infection of living Giardia was seen. Giardia is a so-called diplozoic Protozoon with four pairs of flagella. The parasites were actively moving about and assuming the different shapes depicted on Plate XXIX, Figs.101 - 106,namely sickle-shaped,oval,pear-shaped and the so-quarter moon-shaped. Vibrating flagella and an axostyle together with two clear spots - nuclei - were clearly discernible. The flagella caused a slowly spinning movement of the organism. Some flagella Giardia were seen to be attached to epithelial cells by their peristome or "sucking discs."

b)about ½ inch from the constriction,a good infection,essentially similar to the above,was found.

c)about 1 inch from the constriction,similar to (a) and (b).

d)about 1½ inch from the constriction,a good infection similar to the above.

e)about 2½ inches from the constriction,a good infection.

f)about 3½ inches from the constriction,a good infection.

g)from the duodenal bend,a good infection.

h)from the ascending portion of the duodenum 1 inch from the bend,a good infection similar to the above.

i)from the ascending portion of the duodenum 2 inches from the bend,a fair infection.

j)from the ileum about 3 inches from its commencement,good infection. (Plate XXIX,Figs.107 - 108)

k)from the ileum half way its length,a good infection some of the organisms were beginning to round up (Plate XXIX Fig.109).

l)from the ileum about 2½inches from the caecum,good infection

and some organisms were rounding up. In the mucous membrane of the ileum were found young coccidian trophozoites,causing a bulging out of the submucosal cells containing them. There were also found coccidian microgame ocytes.(Plate XXIX Figs.110 - 111).

Stained preparations of Giardia were made of the ileac and duodenal contents and were examined fromthese areas.

m)from the caecum,good infection of flagellate Giardia,as well as coccidian oocysts.(Plate XXIX Fig.112)

n)from the rectum,which contained no faecal material,so scrapings were taken from the mucoid rectal wall,about half way from the anus. A good infection of moving,flagellate Giardia was found. (Plate XXIX Fig.113)

o)A preparation was made of faecal material,found on the fur outside the anus,and was found to contain coccidian oocysts. Plate XXIX Fig.114).

In the ileum 5 - 6 inches from its commencement,near the first Peyer's patch,and about 10 inches from the caecum, Nematode worms,in groups of four each,and appearing darkish through the intestinal wall,were found. They caused a haemorrhage. These Nematodes are Ascarids. The worm is 67 - 97 mms. long,of a yellowish white colour. The body is striated and the head is distinct with three distinct lips,enlarged at their base. The posterior extremity is terminated by a kind of conical point. There is a distinct lateral line. (Plate XXX,Fig.117) It is a species of Belascaris.

On a third specimen,examined a few hours after its death,no ectoparasites were apparently present.White,slender,much coiled, thread like worms were found lying loosely in the adipose tissue surrounding the intestine. See appendix p.98.

AFFINITIES.

Suricata tetradactyla is a Viverrid Carnivore closely allied to the dog and cat. A comparison of Suricata with these animals may be tabulated as follows :-

Suricata.	Felis.	Canis.
The animal is semidigitigrade.	The cat is digitigrade	The dog is semidigitigrade.
Manus tetradactylate.	Manus pentadactylate.	Manus pentadactylate.
Pes tetradactylate with small rudiment of first metatarsal.	Pes tetradactylate with rudiment of first metatarsal.	Pes tetradactylate with hallux represented by a vestigial metatarsal.
External ear small, closely applied to head.	External ear large projects beyond head.	External ear large projects beyond head.
Head rather elongate	Head rather rounded	Head elongate.
No naked line from nose to upper lip.	Naked line present.	Naked line present.
Perineal glands present.	No perineal glands.	No perineal glands.
Claws non-retractile	Claws retractile.	Claws non-retractile.
Claws of manus very long, twice the length of those of pes.	Claws equal in length.	Claws of manus slightly longer than of pes.
Tongue with horny papillae.	Tongue with horny papillae.	Tongue smooth.
Intestine four times length of head and trunk.	Intestine three and a half times length of head and trunk.	Intestine four and a half times length of head and trunk.
Colon not divisible three parts, but forms a straight tube with the rectum.	Colon divisible into ascending, transverse and descending parts.	Colon as in Suricata.
Occipital and sagittal crests very well developed.	Occipital crest well developed, sagittal weaker in development.	Occipital crest well developed, sagittal weaker in development.

Suricata.	Felis.	Canis.
Sutures of skull disappear as age increases.	Sutures remain distinct through life.	Sutures remain distinct through life.
Postorbital processes of frontal and jugal meet, cutting off orbit.	Postorbital processes incomplete.	Postorbital processes incomplete
Bullallarge, smooth, separated by septum into two chambers.	Bulla inflated, separated by septum, but chambers not placed quite behind one another, inner chamber corresponds with posterior one of Suricata.	Bulla large, smooth, separated by incomplete septum.
Bulla with a fissure.	Bulla without fissure	Bulla without fissure.
Bony auditory meatus short, with small lower lip.	Bony auditory meatus very short, and very short lower lip.	Bony auditory meatus longer, with longer lower lip.
Paroccipital process closely applied to bulla.	Paroccipital process closely applied to bulla.	Paroccipital process applied to back of bulla its end being free.
Mastoid inconspicuous	Mastoid inconspicuous	Mastoid conspicuous.
Aliasphenoid canal present.	Aliasphenoid canal absent.	Aliasphenoid canal present.
Condylar foramen distinct from foramen lacerum posterius.	Condylar foramen opens within margin of foramen lacerum posterius.	Condylar foramen distinct from foramen lacerum posterius.

Opening of carotid canal looks into foramen lacerum posterius. The canal has a groove on the side of the bulla.

Postglenoid foramen very small.	Postglenoid foramen absent.	Postglenoid foramen well developed.
Dentition $\frac{3.1.3.2}{3\ 1\ 3\ 2}$.	Dentition $\frac{3.1.3.1}{3\ 1\ 3\ 1}$.	Dentition $\frac{3.1.4.2}{3\ 1\ 4\ 2}$.
Bony symphysis of mandible.	No bony symphysis	No bony symphysis.

Seven cervical vertebrae in all three genera.

Suricata	Felis.	Canis.
14 thoracic vertebrae.	13 thoracic vertebrae	13 thoracic vertebrae
6 lumbar vertebrae	7 lumbar vertebrae	7 lumbar vertebrae.
2 sacral vertebrae	3 sacral vertebrae	3 sacral vertebrae.
Scapula triangular, very thin with fairly straight borders.	Scapula curved triangular	Scapula curved triangular.
Humerus with supratrochlear and entepicondylar foramen.	Only entepicondylar foramen present.	No foramina.

Scaphoid and lunar fused, no os centrale.

Cowper's glands present	Cowper's glands present	Cowper's glands absent.

There are no vesiculae seminales.

Triangular os penis	Os penis an irregular bone.	Os penis is grooved.
Glans penis smooth.	Glans with recurved hooks in cat and dog.	

The placentation is zonary and deciduate.

THE MEERCAT IN SOUTH AFRICAN FOLK LORE.

The meercat is looked upon by the Basotho tribe as a sacred animal, the skins of which may only be used for the chief's kaross. Heavy fines are imposed on those contravening this law. A native proceeding somewhere, will, when a meercat crosses his path, return at once, as the continuation of his journey would meet with ill-fortune. The meercat, in Basotho folk lore, replaces our hare in the well-known fable of the race between the hare and the tortoise, which, in Basotho folk lore, is replaced by the snail.

It is interesting to note, that the fresh faeces, rubbed up in a little water, are used by the natives in cases of ophthalmia; and - strange to say - this more than crude remedy is reported to give relief and even bring about a healing. It might be suggested, that the secretions of the perineal glands on the faeces together with the vegetable matter, present in the faeces - as the animal eats veld bulbs - , cause this healing effect.

The natives of South Africa do not,in their nomenclature,distiguish between Suricata and Cynictis. Either of the two is known,by the Zulus,as "cagiti",by the Xosas,as "ekute",and,by the Basotho,as "rumodye". Even the Boers make no very definite distinction; Cynictis being termed the "Rooi Mierkat" and Suricata the "Stokstert Mierkat". A more appropiate name for the latter seems to be "Kommetjiesgat Mierkat",whereby hangs a tale. Some Boers seem to have observed,that the anus of the meercat is very dilatable and capable of a marked expansion and contraction. It is related that the animal goes to an ant heap,lies down near it opens out its anus,and when the latter is swarming with ants, closes it again. It thence proceeds to a farmstead,lies down in the vicinity of fowls,and opens its anus. The ants swarming about attract the attention of a fowl,which,when picking them,is caught by the meercat enclosing the fowl's head within its anus, The meercat then turns round and kills the fowl. This tale,however interesting,is not based on any truth and must have been propounded by some wit.

ACKNOWLEDGEMENTS.

In conclusion I wish to express my sincere appreciation of the kind assistance and valuable information received from Prof. H.B.Fantham,of the University of the Witwatersrand,from Dr. Annie Porter,of the South African Institute for Medical Research, and from Mr. Austin Roberts,of the Transvaal Museum.

I am also indebted to Master Glover for feeding and tending the animals.

REFERENCES.

Sclater , "Mammals of South Africa ". Vol.I.pp.76 - 78.

A.Haagner, "South African Mammals ". pp.64 - 65.

Rev. J.G.Wood, "Natural History", p.342.

J.S.Kingsley, "Standard Natural History". p.445.

The Cambridge Natural History,Vol.X "Mammals." p.410-_411.

Proc.Zool.Soc.Lond.,1905.Vol.I. pp.133 - 134.

Marshall and Hurst, "Practical Zoology." pp.370 - 375.

St.G.Mivart, "The Cat."

T.J. Parker,"Zootomy". pp.339 -365.

Wallace,"Geographical Distribution of Animals".Vol.II.p.195.

PLATE I.

Fig.1. Ground plan of the burrow of Suriogata tetradactyla, drawn to the scale of 1cm. = to 1foot.

Fig.2. Diagrammatic vertical section of the burrow along the line A - B in Fig.1.

Fig.3. Diagrammatic vertical section along the line C - D in Fig.1.

N.B. In both Figs.2and 3 the plain black line represents the tunnel as seen in vertical section, while the posterior portion of the tunnel is represented by a dotted line, and the more anterior portion by a red line.



FIG. 1

of Surigata

ale of 1cm.=

tion of the
B in Fig.1.

tion along the

ain black line
in vertical section,
the tunnel is re-
d the more anterior

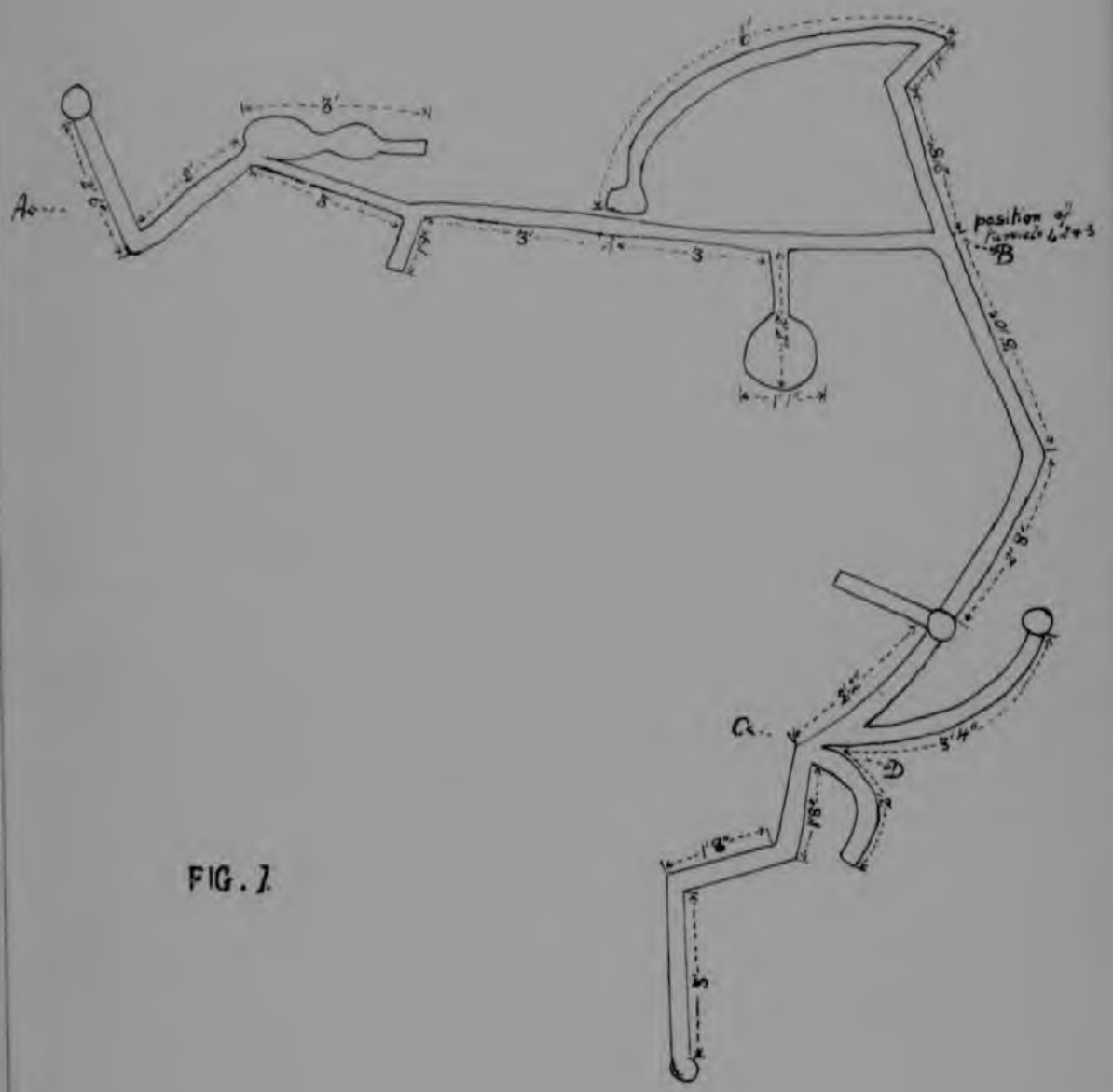

FIG. 1



FIG. 2



FIG. 3.

GTSE

PLATE I.

(69)

PLATE II.

Fig.4. Gurigata tetradactyla, entire animal. X ¾.



PLATE II.

FIG. 4.

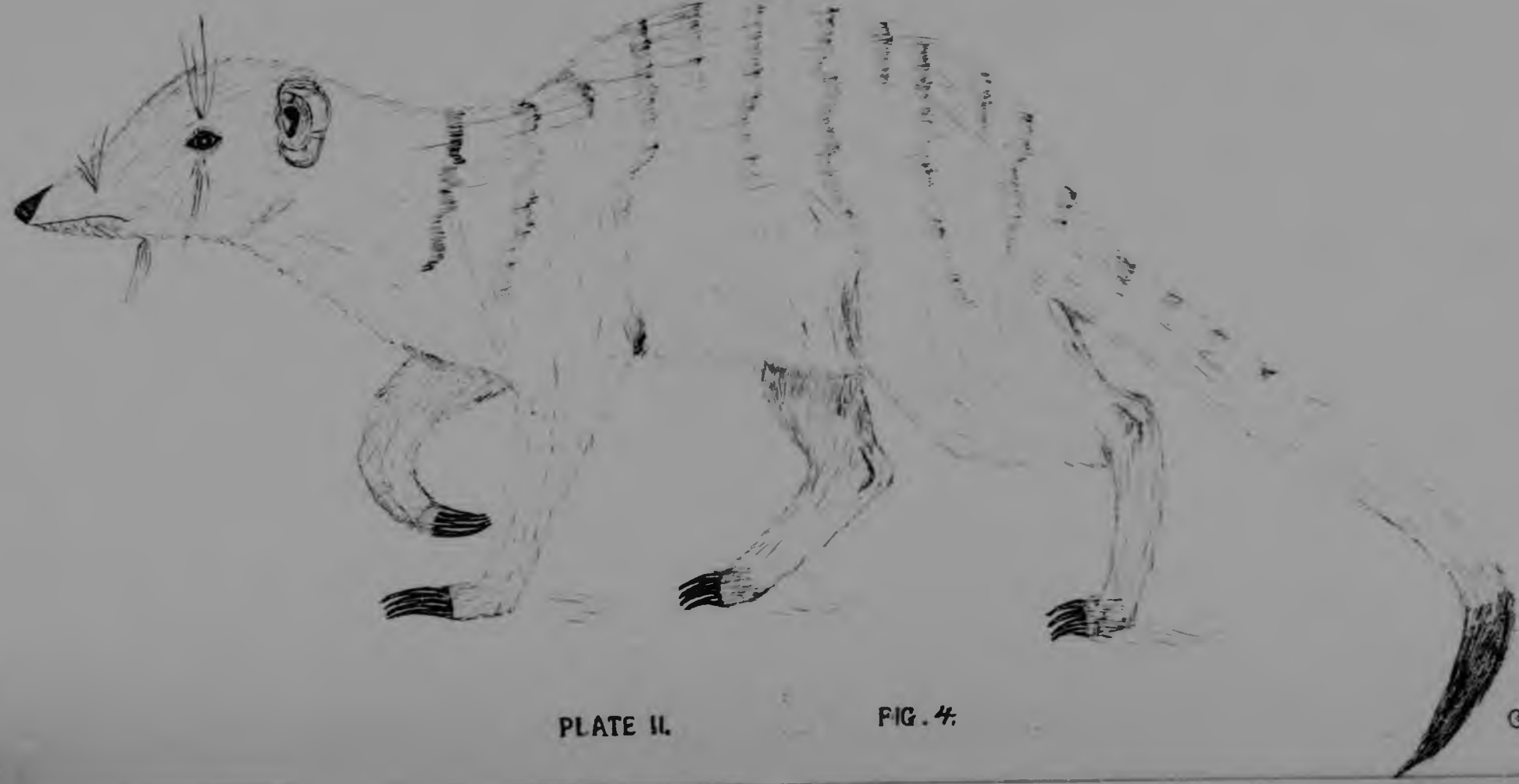

PLATE II. FIG. 4.

unimal. x ¼.

(70)

PLATE III.

Fig.5.A. Fore-paw of Suricata tetradactyla, seen from the palmar surface to show the pads.

x 3/2

Fig.5.B. Hind paw of Suricata tetradactyla, seen from the plantar surface to show the pads.

x 3/2

radactyla, seen
to show the pads.

tradactyla, seen
to show the pads.

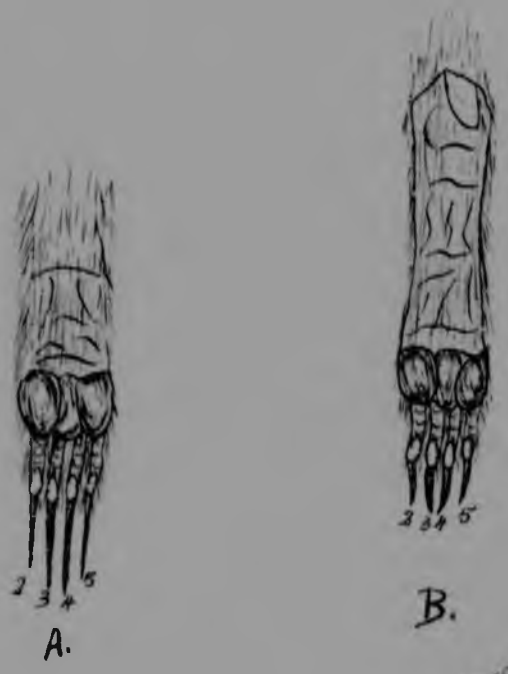

A. B.

FIG 5.

PLATE III.

(71)

PLATE IV.

Fig.6. Skull of Euriocta tetradactyla.

Dorsal view X1½.



Fig 6.

Fig.7. Skull of Euriocta tetradactyla.

Ventral view X 1½.



Fig 7

IV.

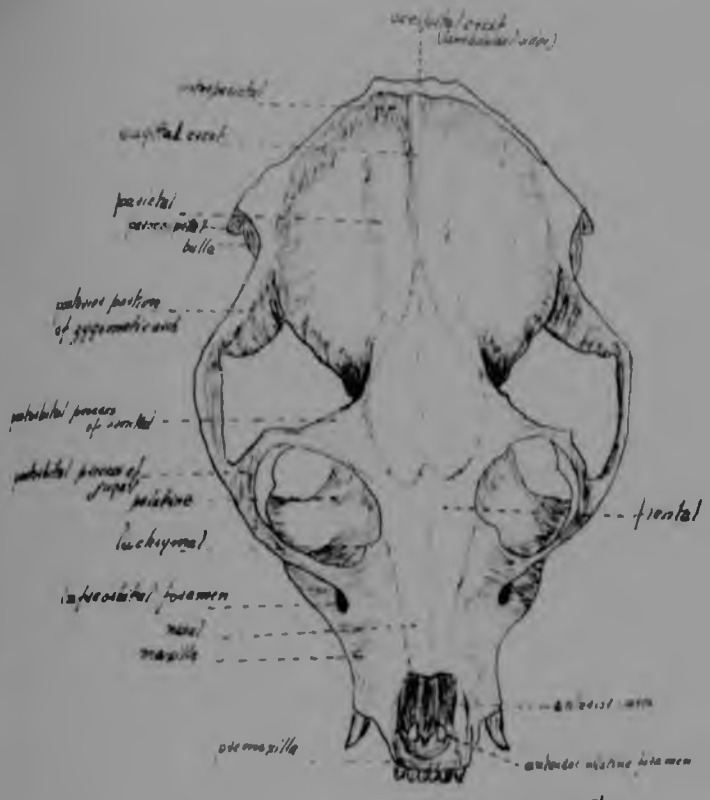

Fig. 6. **Skull** – dorsal view × 3/4

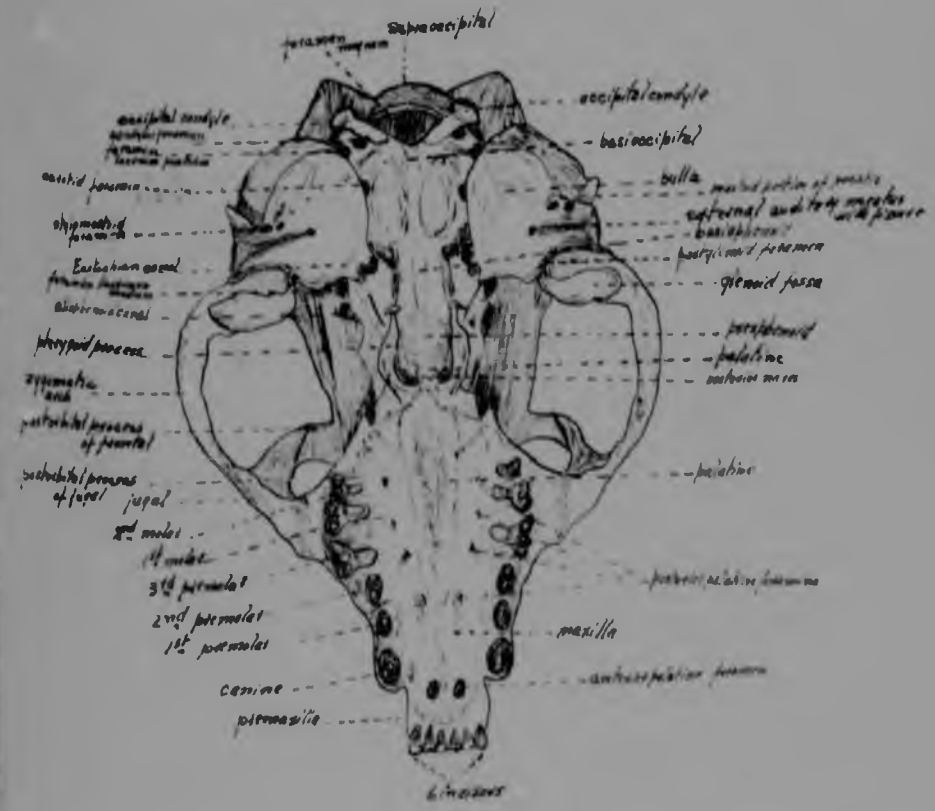

Fig. 7. **Skull** – ventral view × 3/4

GTSE.

Plate IV.

(73)

PLATE .V.



Fig.8. Skull and lower jaw of Suricata tetradactyla.

Lateral view. X 1½.



Fig.9. Skull and lower jaw of Suricata tetradactyla.

In vertical longitudinal section.

X 1½.

n tetradactyla.

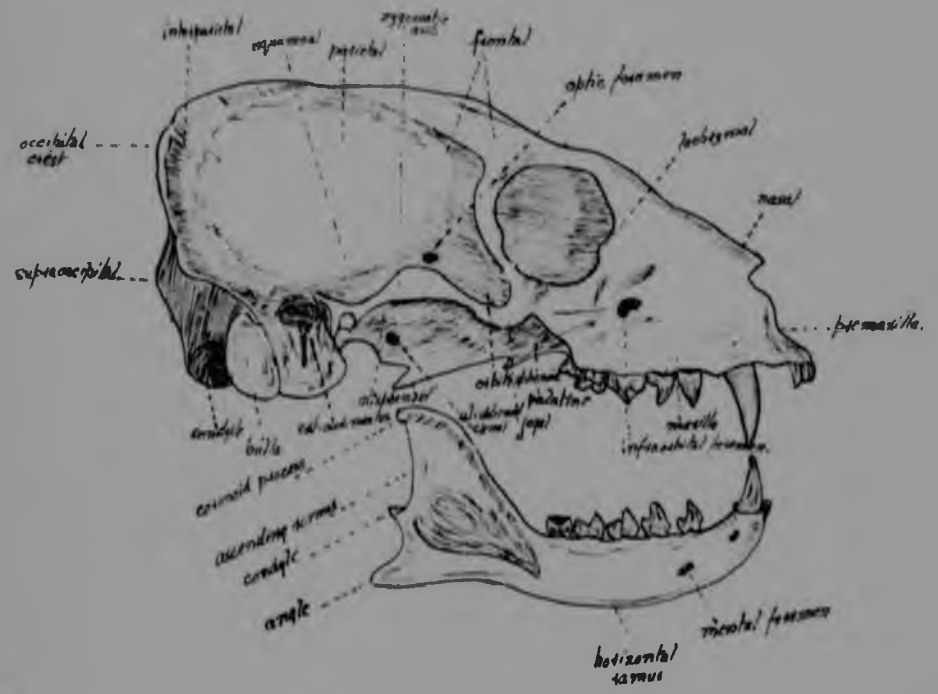

FIG. 8

ta tetradactyla.

section.

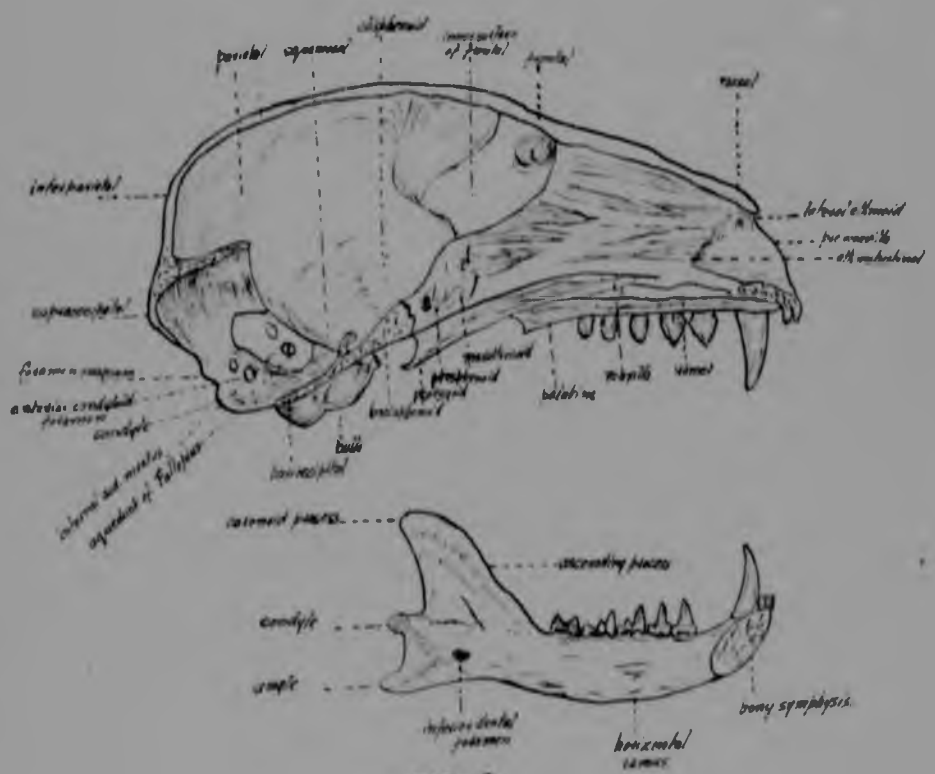

FIG. 9.

G.T.S.E.

PLATE V.

PLATE VI.

Fig. 10. Skull of Suricata tetradactyla,
in vertical longitudinal section,
to show the axes of the skull.
a)cranial axis;(b.c.)basicranial axis
b.f.)basifacial axis;(c.p)plane of
cribriform plate;(f.m)plane of foramen
magnum.
X 1½.

Fig. 11. Skull and lower jaw of Suricata tetradactyla.
Viewed from behind. X 1½.



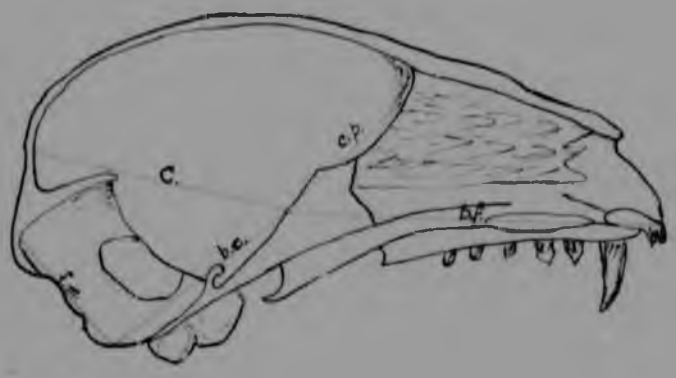

FIG. 10.

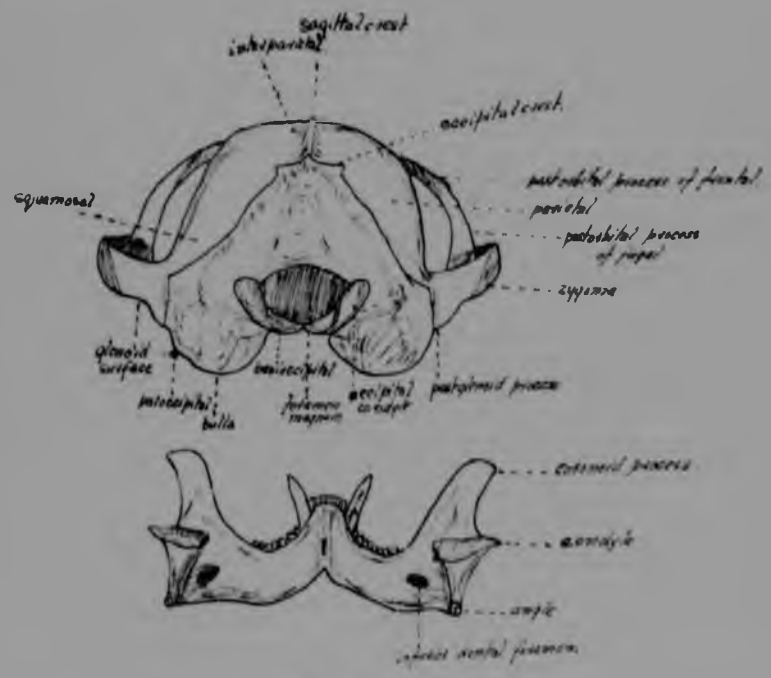

FIG. 11.

PLATE VI.

PLATE VII.

SURICATA TETRADACTYLA.

Fig.12. Atlas. Front view. X 1½.

Fig.13. Atlas. Back view. X 1½.

Fig. 14. Atlas. Dorsal surface. X 1½.

Fig.15 . Atlas. Ventral surface.X 1½.

Fig. 16. Axis. Front view. X 1½.

Fig. 17. Axis. Lateral view. X 1½.

Fig. 18. Axis. Back view. X 1½.

Fig. 19. Axis. Dorsal surface. X 1½.

Fig. 20. Axis. Ventral surface. X 1½.

Fig. 21. Fifth cervical vertebra.Anterior surface. X 1½.

Fig. 22. Fifth cervical vertebra.Posterior surface. X 1½.

Fig. 23. 6th. thoracic vertebra.Anterior view.X 1½.

Fig. 24. 6th. thoracic vertebra.Lateral view. X 1½.

Fig. 25. 6th. thoracic vertebra.Posterior view.X 1½.

Fig. 26. 6th. lumbar vertebra.Anterior view. X 1½.

Fig. 27. 6th. lumbar vertebra.Posterior view. X 1½.

Fig. 28. 6th. lumbar vertebra.Lateral view. X1½.

Fig. 29. Sacrum.Anterior view. X 1½.

Fig. 30. Sacrum. Posterior view.X 1½.

Fig. 31. Sacrum.Ventral view. X 1½.



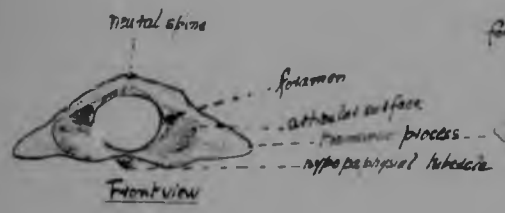

Front view

FIG. 12.



Back view

FIG. 13.



Dorsal surface.

FIG. 14.



Ventral surface.

FIG. 15.

Atlas. x 3/2.



FIG. 16.

Front view



FIG. 17.

Lateral view.



FIG. 18

Back view.



FIG. 19

Dorsal surface

FIG. 20

Ventral surface.

Axis. x 3/2.



FIG. 21.

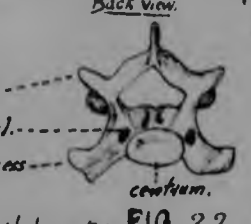

FIG. 22.

5th Cervical Vertebra. x 3/2

Posterior surface.



FIG. 23. Anterior view.

FIG. 24 Lateral view.

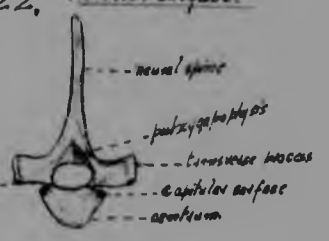

FIG. 25.

Posterior view.

6th Thoracic Vertebra. x 3/2.

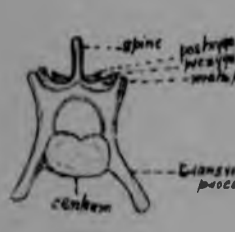

FIG. 26.

Front view.

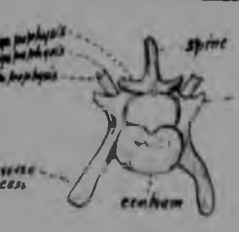

FIG. 27.

Back view.



FIG. 28.

Lateral view.

6th Lumbar Vertebra x 3/2.



FIG. 29.



FIG. 30.



FIG. 31.

Sacrum x 3/2.

GTSE

PLATE VII.



Front view

FIG. 12.

Back view

FIG. 13.



Dorsal surface.

FIG. 14.

Ventral surface.

FIG. 15.

Atlas. x 3/2.

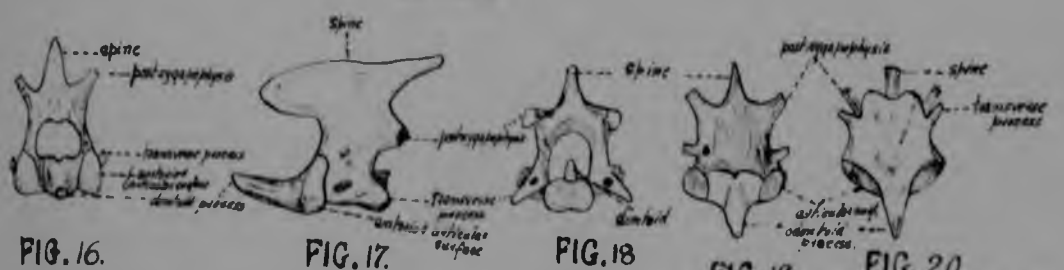

FIG. 16. Front view

FIG. 17. Lateral view.

FIG. 18 Back view.

FIG. 19 Dorsal surface

FIG. 20 Ventral surface.

Axis. x 3/2.



Anterior surface

FIG. 21.

5th Cervical Vertebra. x 3/2

FIG. 22.

Posterior surface.



FIG. 23. Anterior view.

FIG. 24 Lateral view.

FIG. 25.

Posterior view.

6th Thoracic Vertebra. x 3/2

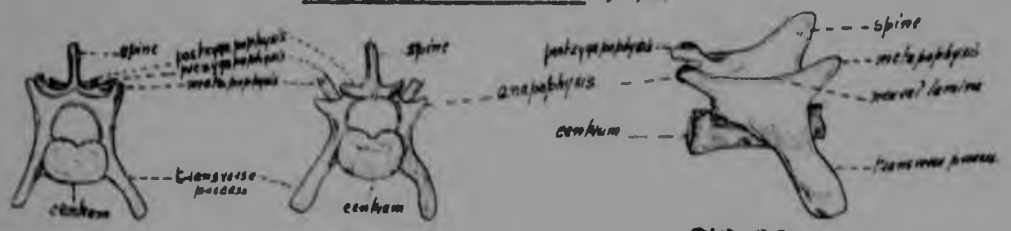

FIG. 26. Front view.

FIG. 27. Back view.

FIG. 28. Lateral view.

6th Lumbar Vertebra. x 3/2.

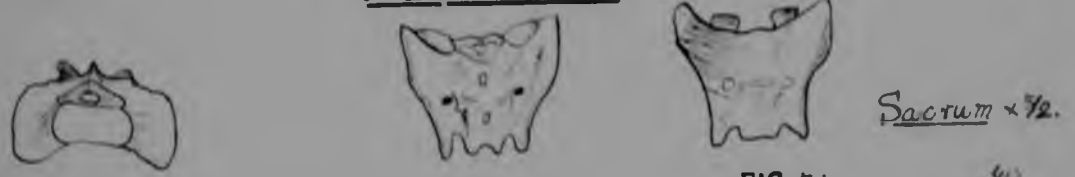

FIG. 29.

FIG. 30.

FIG. 31.

Sacrum x 3/2.

GISE

PLATE VII.

PLATE VIII.

SUBICATA TETRADACTYLA.

Fig. 32. Sternum. Ventral view. X 1½.

Fig. 33. First rib. Lateral view. X 1½.

Fig. 34. Sixth rib. Lateral view. X 1½.

Fig. 35. Thirteenth rib. Lateral view. X 1½.



FIG. 32.

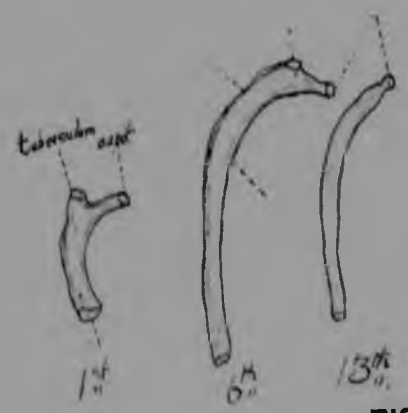

FIG. 33. FIG. 34. FIG. 35.

PLATE VIII.

PLATE IX.

SURICATA TETRADACTYLA

Fig. 36. Right scapula. Dorsal surface. X 1½.

Fig. 37. Right scapula. Ventral surface. X 1½.

Fig. 38. Right humerus. Anterior surface. X 1½.

Fig. 39. Right humerus. Posterior surface. X1½.

Fig. 40. Right humerus. Inner aspect. X 1½.

Fig. 41. Summit of humerus, seen from above. X 1½.

Fig. 42. Lower end of humerus, seen from below. X 1½.

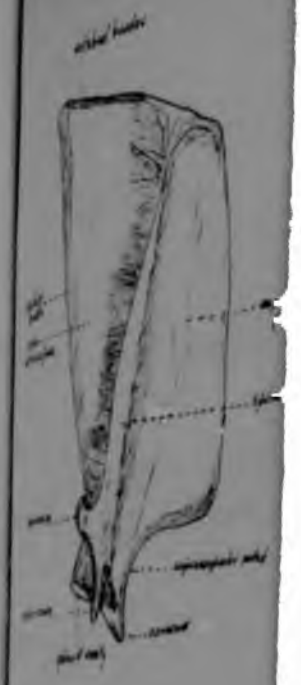

FIG. 36.



FIG. 38.

FIG. 3

PLATE

...L.

...l surface. X 1½.

...al surface. X 1½.

...ior surface. X 1½.

...rior surface. X1½.

... aspect. X 1½.

...en from above. X 1½.

..., seen from below. X 1½.

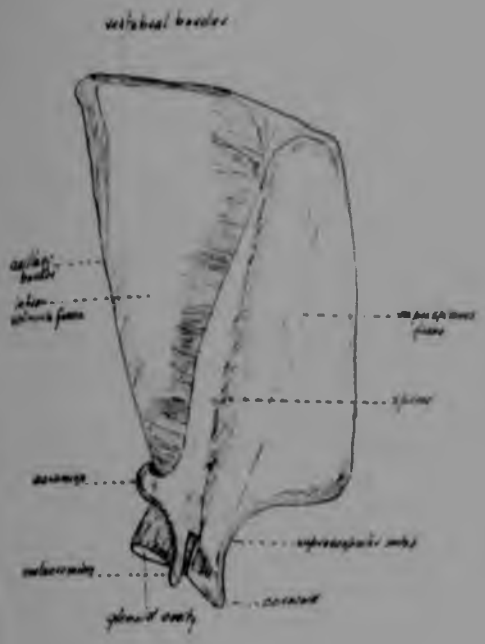

FIG. 36.

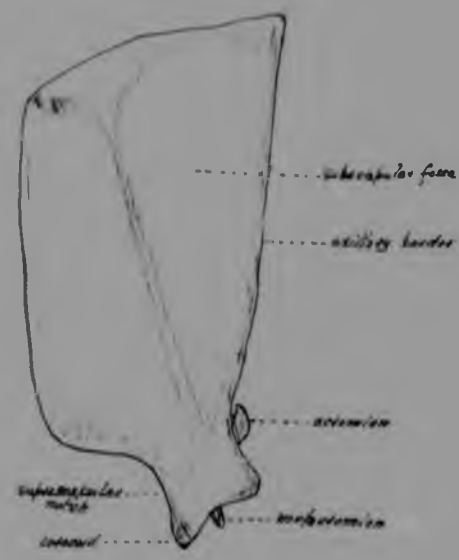

FIG. 37.



FIG. 38.



FIG. 39.



FIG. 40

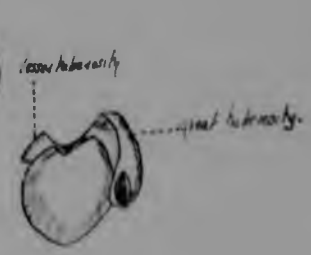

FIG. 41.



FIG. 42.

G.T.S.E.

PLATE IX.

PLATE X.

SURICATA TETRADACTYLA.

Fig. 43. Right radius. X 1½.
Anterior and outer surface.

Fig. 44. Right radius. X 1½.
Posterior and inner surface.



Fig. 45. Right ulna. X 1½.
Anterior and outer surface.

Fig. 46. Right ulna. X 1½.
Posterior and inner surface.

Fig. 47. Right ulna. X 1½.
Surface of sigmoid fossa.



CTYLA.

1½.

surface.

1½.

surface.

1½.

surface.

1½.

fossa.

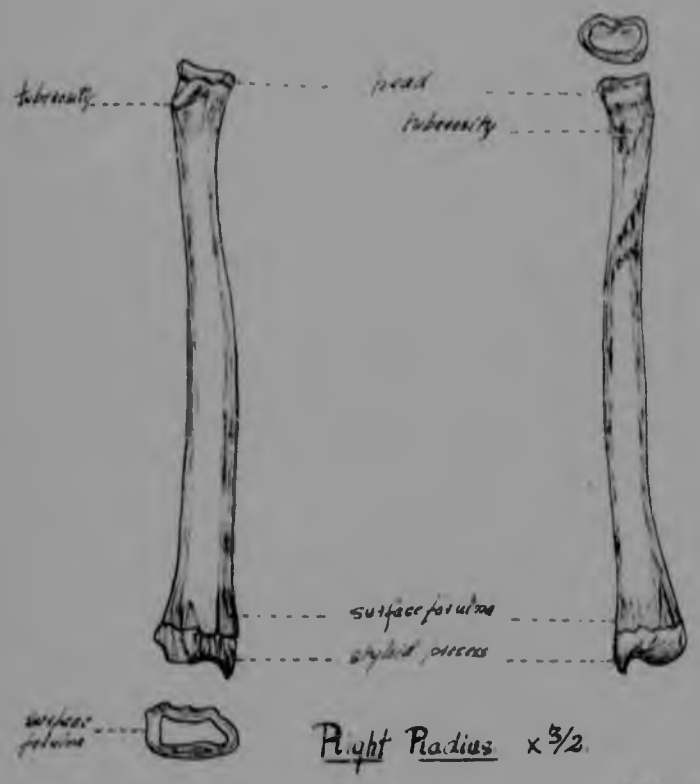

Right Radius x 3/2.

Anterior and outer surface
FIG. 43.

Posterior and inner surface.
FIG. 44.

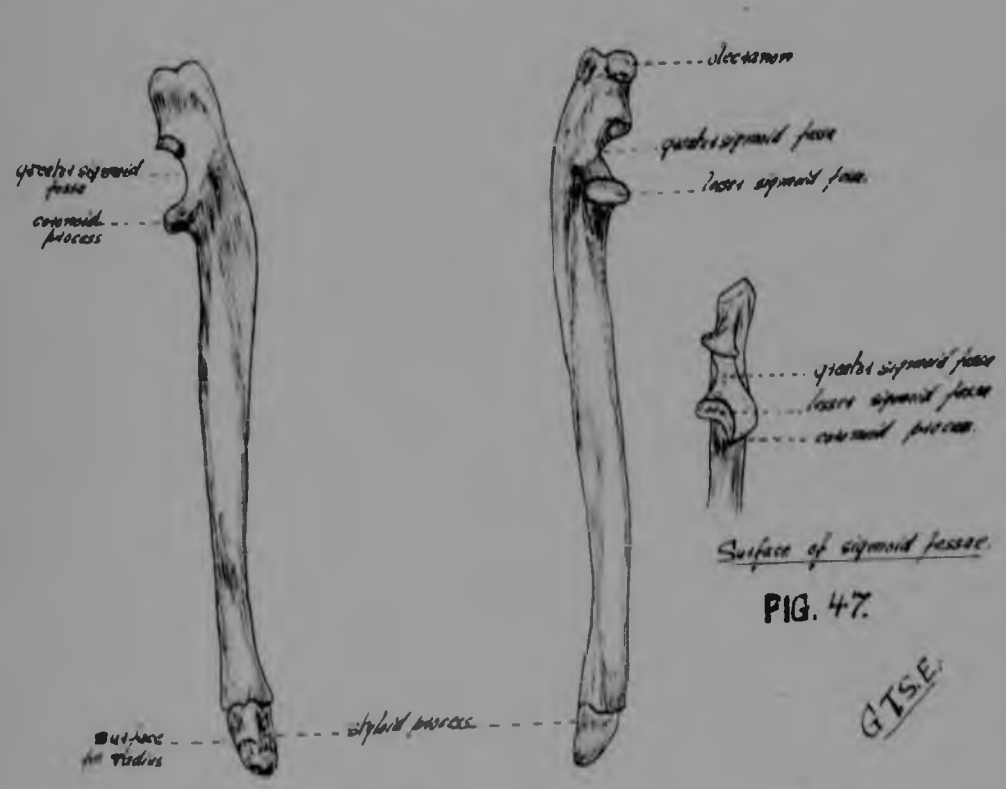

Anterior and outer surface.
FIG. 45.

Posterior and inner surface.
FIG. 46.

Surface of sigmoid fossae.
FIG. 47.

Right Ulna. x 3/2.

PLATE X.

GISE

PLATE XI.

SURICATA TETRADACTYLA

Fig. 48. Right fore - paw. X 1½.
Dorsal surface.

Fig. 49. Right fore - paw. X 1½.
Palmar surface.

Fig. 50. Bones of third digit.
Lateral view. X 1½.

Fig. 51. Right hind paw. X 1½.
Dorsal surface.

Fig. 52. Right hind paw. X 1½.
Plantar surface.





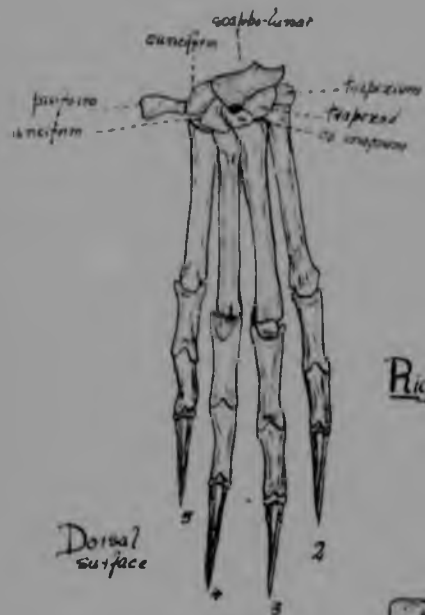

Dorsal surface

FIG. 48.

Right Fore-paw
× 3/2



Palmar surface

FIG. 49.

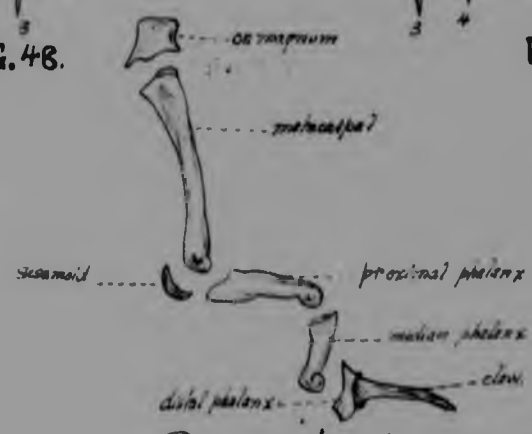

Bones of 3rd digit. Lateral view. × 3/2

FIG. 50.

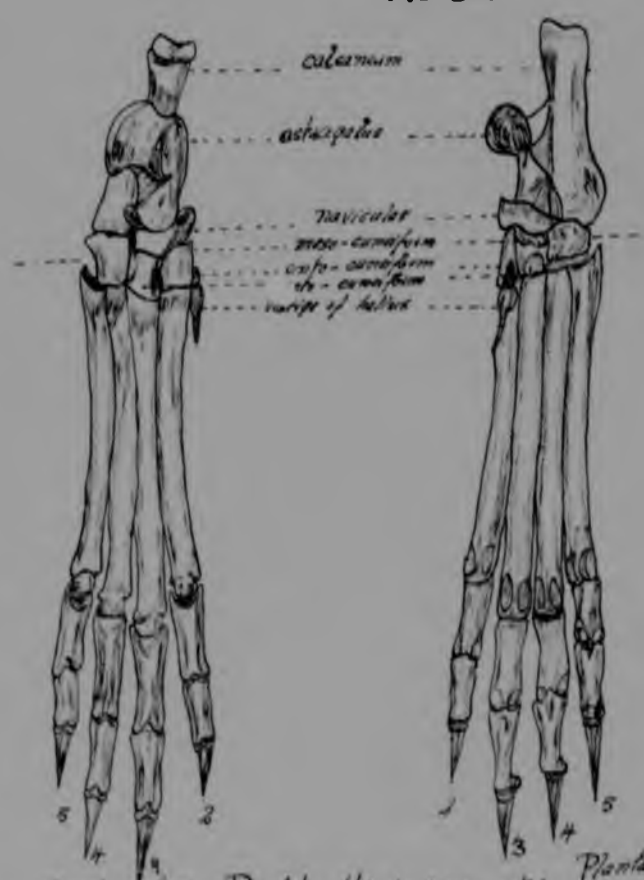

Dorsal surface

Right Hind-paw. × 3/2

Plantar surface.

FIG. 51.

FIG. 52.

G.T.S.E.

PLATE XI.

PLATE XII.

SURICATA TETRADACTYLA.

Fig. 53. Pelvis. X 1½.
Ventral view.

Fig. 54. Right os innominatum. X 1½.
External aspect.

Fig. 55. Right os innominatum. X 1½.
Internal aspect.



LA.

tum. X 1½.

tum. X 1½.

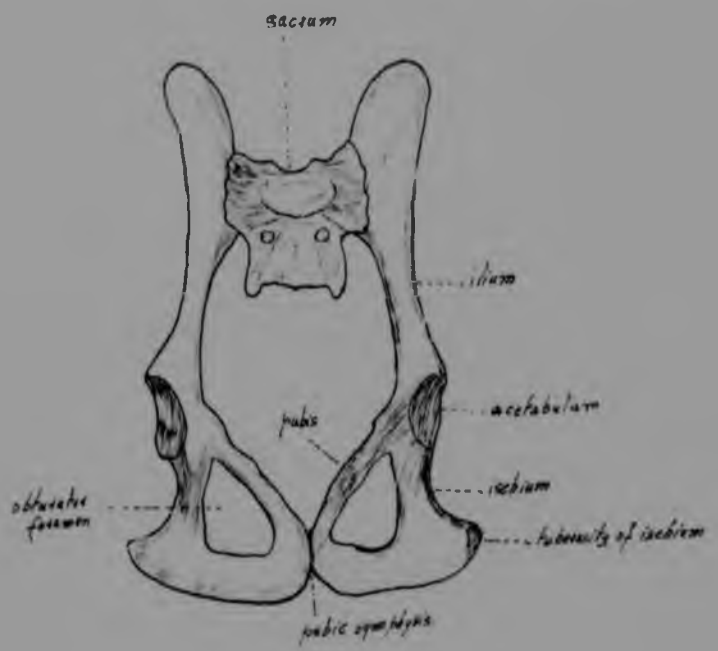

FIG. 53.

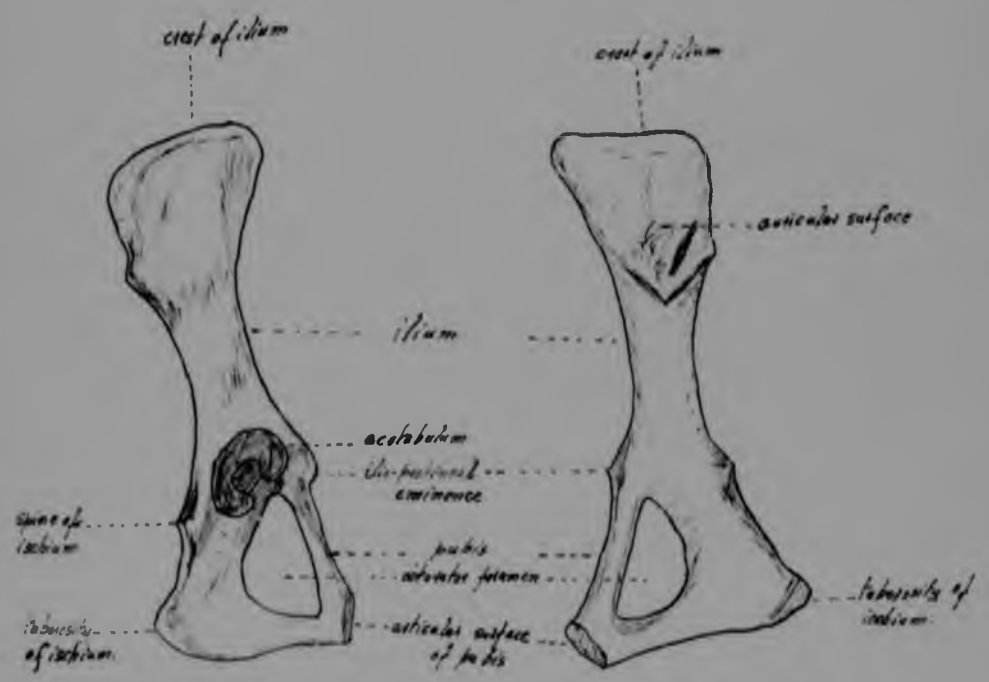

FIG. 54

FIG. 55.

GTSE

PLATE XII.

PLATE XIII.

SURICATA TETRADACTYLA.

Fig. 56. Right femur. X 1½.
Anterior surface.

Fig. 57. Right femur. X 1½.
Posterior surface.

Fig. 58. Right femur. X 1½.
Lateral view of head.

Fig. 59. Distal end of femur. X 1½.
Anterior and ventral view.

Fig. 60. Right femur. X 1½.
Internal aspect.

Fig. 61. Right femur. X 1½.
External aspect.

Fig. 62. Patella. X 1½.
Dorsal surface.





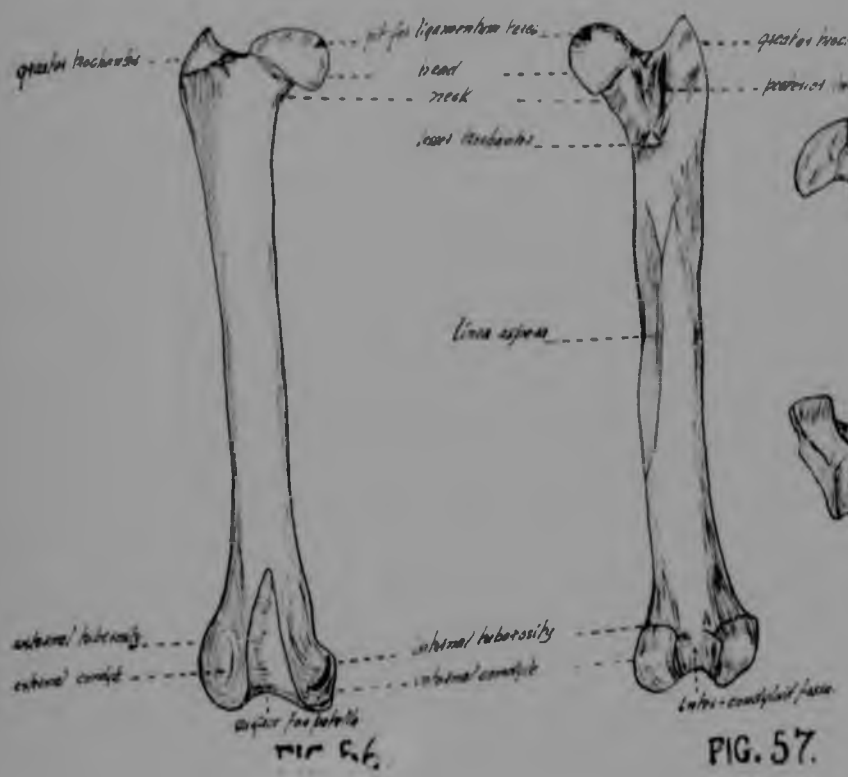

FIG. 58.

FIG. 59.

FIG. 57.

X 1/4.

view.

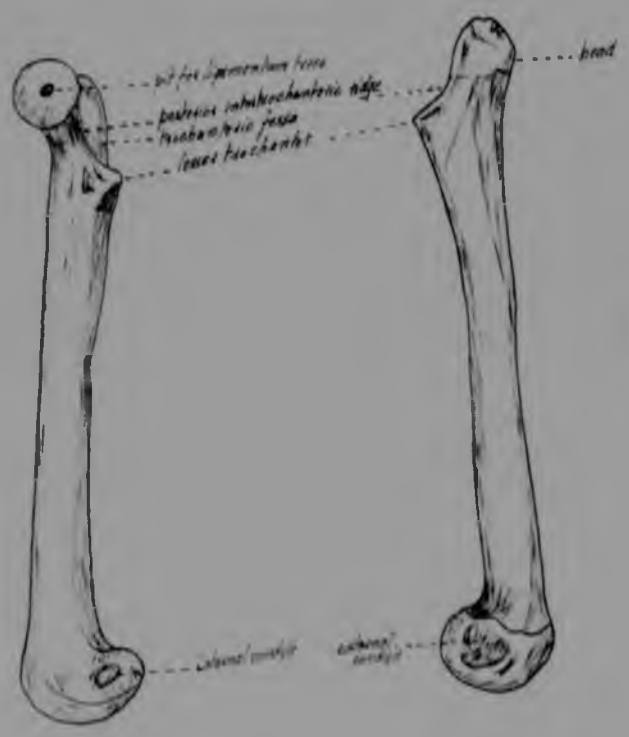

FIG. 62.

FIG. 60

FIG. 61.

PLATE XIII.

PLATE XIV.

SURICATA TETRADACTYLA.

Fig. 62. Right fibula. X 1½.
Anterior aspect.

Fig. 63. Right tibia. X 1½.
Anterior aspect.

Fig. 64. Right tibia. X 1½.
Posterior aspect.

Fig. 65. Right fibula. X 1½.
Posterior aspect.

Fig. 66. Right tibia. X 1½.
Lateral view.

Fig. 67. Summit of tibia. X 1½.
Dorsal aspect.

Fig. 68. Lower end of tibia. X 1½.
Ventral aspect.



FIG. 62

CTYLA.

1½.

1½.

1½.

1½.

1½.

1½.

n. X 1½.



FIG. 62

FIG. 63.

FIG. 64.

FIG. 65.

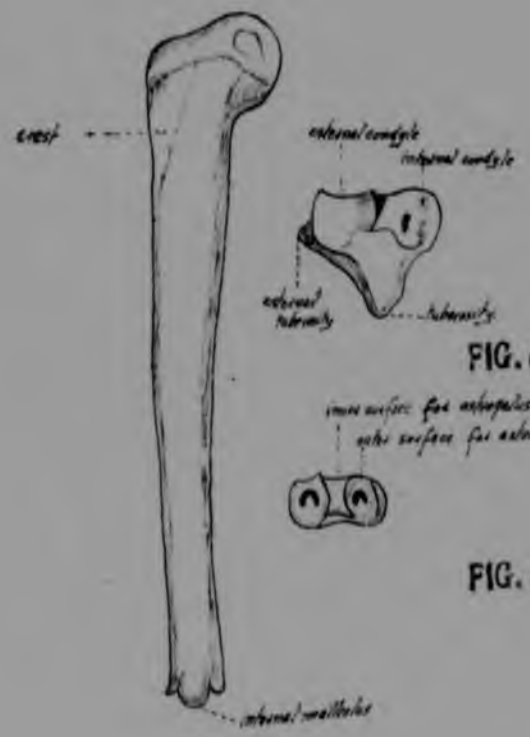

FIG. 66

FIG. 67.

FIG. 68.

BTSE

PLATE XIV.

PLATE XV.

SURICATA TETRADACTYLA.

Fig. 68. Muscles of the left side of the head and fore quarter.

X ¾.

A rect-angular cut is made in the cephalo-humeral to show the muscle underneath.

MUSCLES OF HEAD & FORE QUARTER.
PLATE XV
FIG. 69.

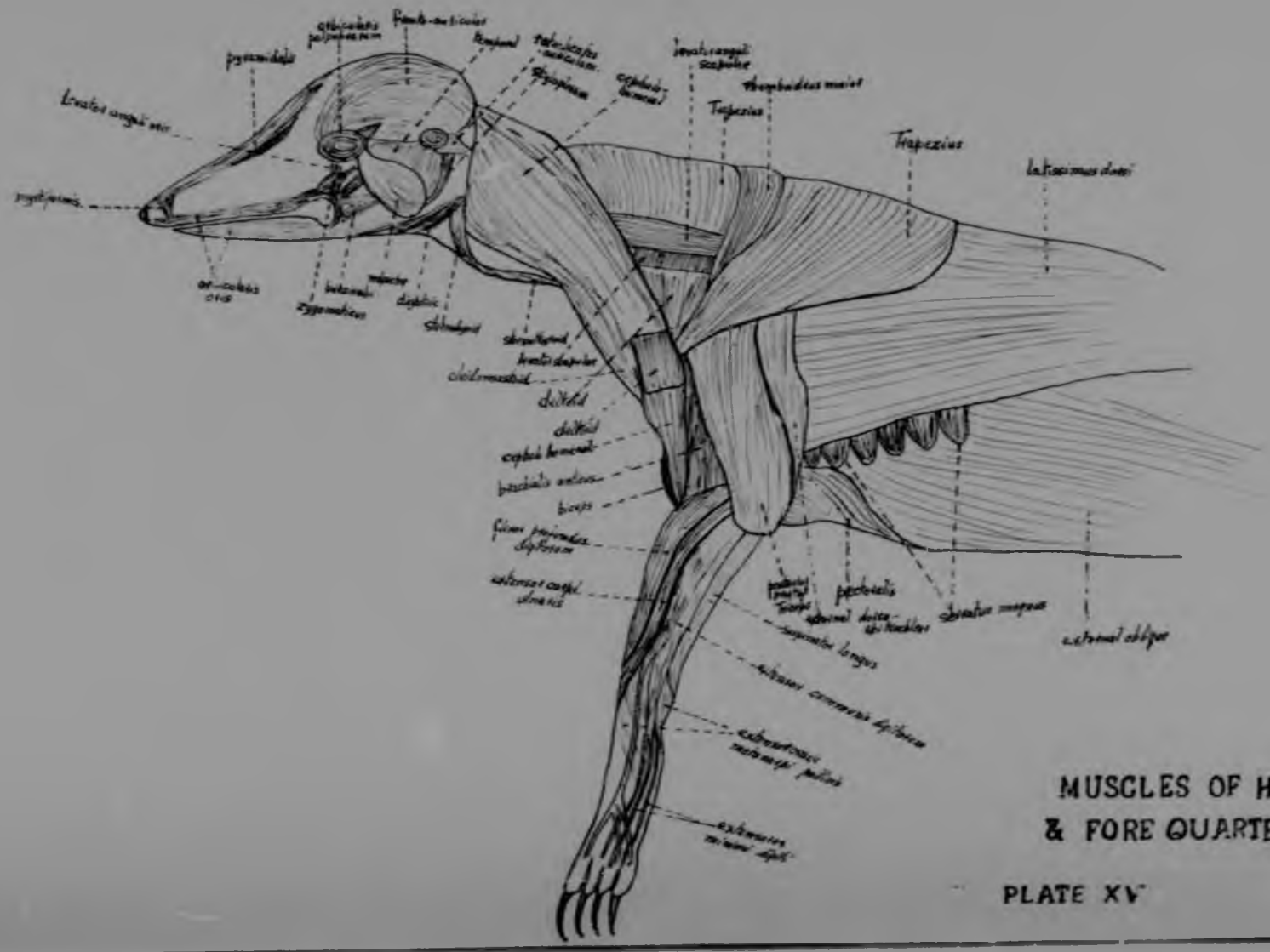

MUSCLES OF HEAD
& FORE QUARTER.

PLATE XV FIG. 69.

GTSE

PLATE XVI.

SURICATA TETRADACTYLA.

Fig. 70. Muscles of the ventral surface of the trunk. The left fore limb and the left pectoral muscle have been removed.

x ¾.

Fig. 71. Deeper layer of muscles of the fore limb.

x ¾.

FIG. 70. MUSCLES OF TRUNK. PLATE XVI.

FIG. 71. MUSCLES OF FORE LIMB.

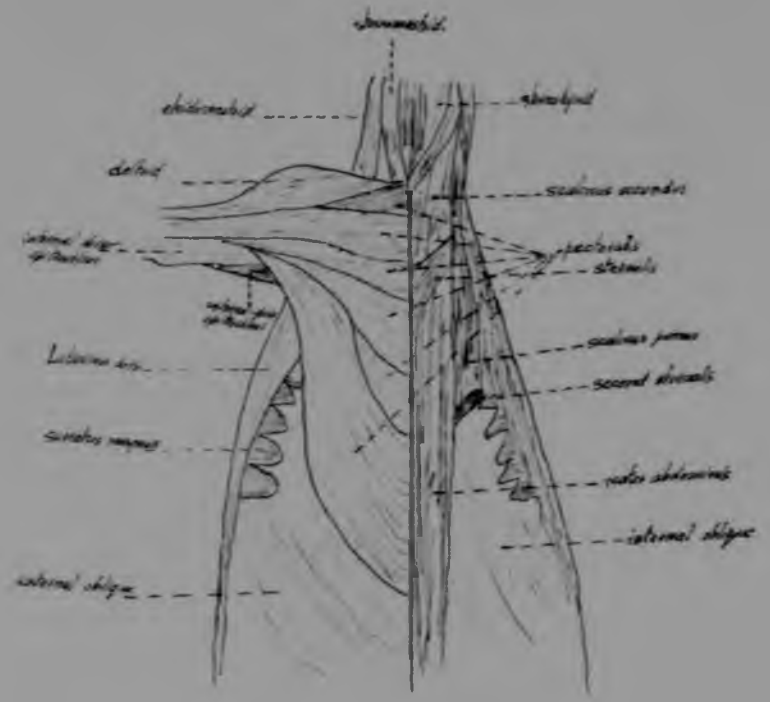

FIG. 70.

MUSCLES OF TRUNK.

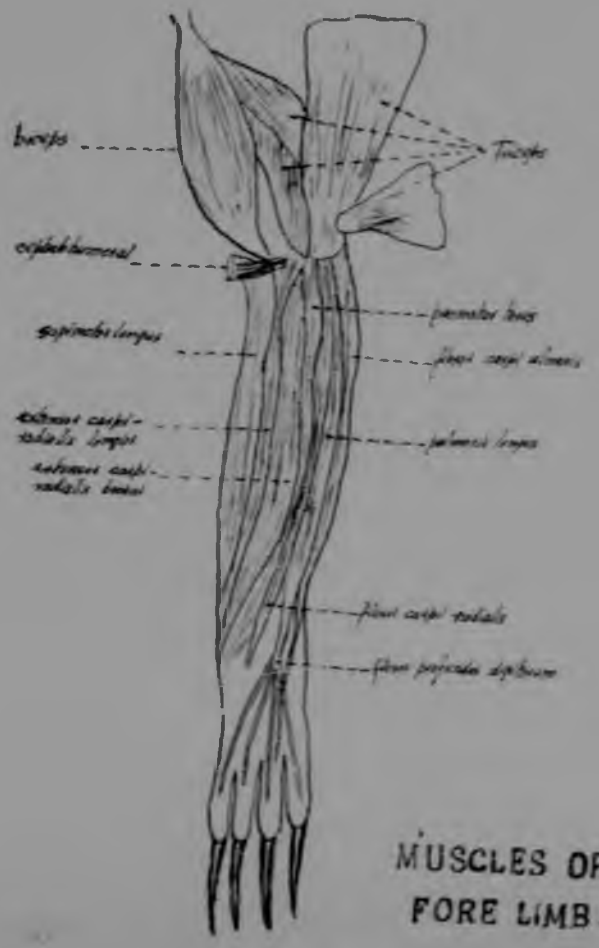

MUSCLES OF FORE LIMB.

FIG. 71.

PLATE XVI.

PLATE XVII.

SURICATA TETRADACTYLA.

Fig. 72. Superficial muscles of the thigh.
Natural size.

Fig. 73. Deep muscles of the thigh, the biceps and fascia lata are cut and reflected.
Natural size.

PLATE XVII

FIG. 72. MUSCLES OF THIGH.

FIG. 73. MUSCLES OF THIGH.

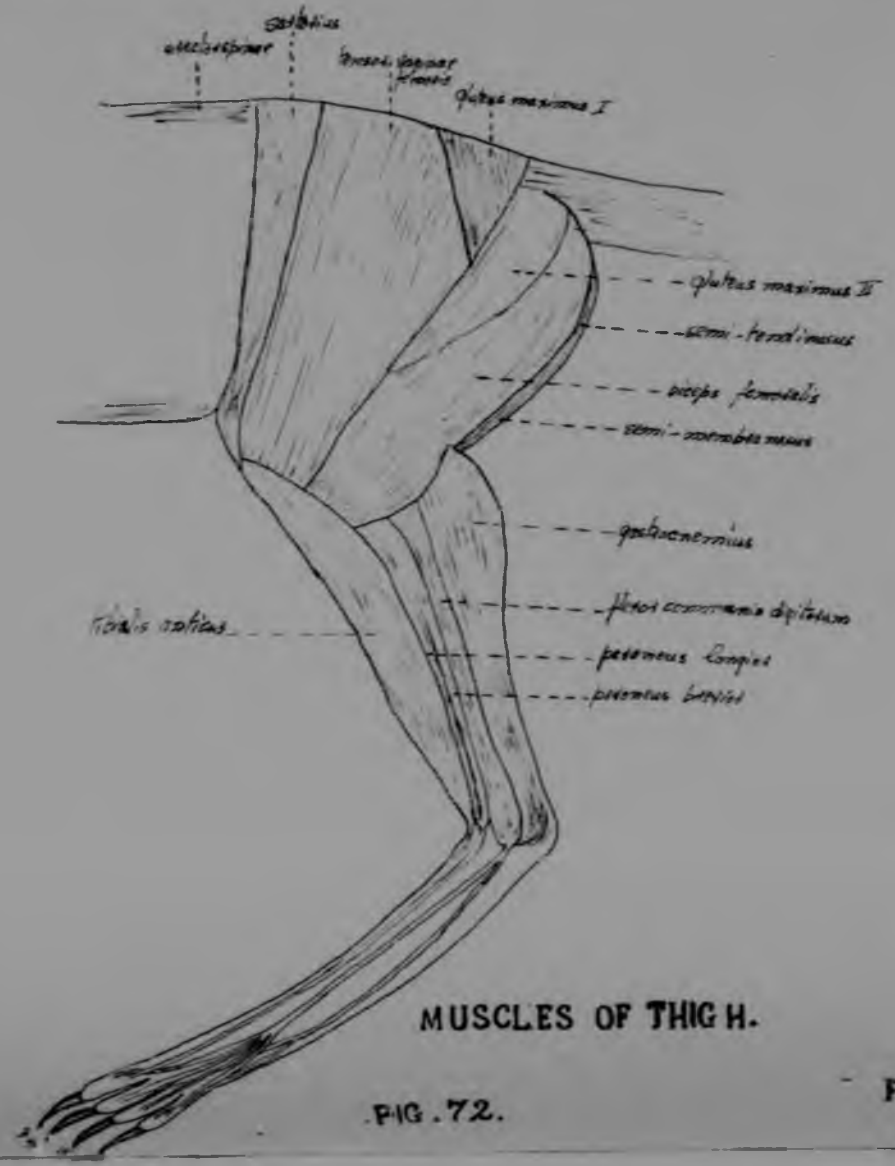

MUSCLES OF THIGH.

FIG. 72.

PLATE XVII



FIG. 73.

MUSCLES OF THIGH.

G.T.S.E.

PLATE XVIII.

SURICATA TETRADACTYLA.

Fig. 74. The lung.Ventral view.
Natural size.

Fig. 75. The larynx;lateral view.
The cartilages are dis-
articulated.
Natural size.

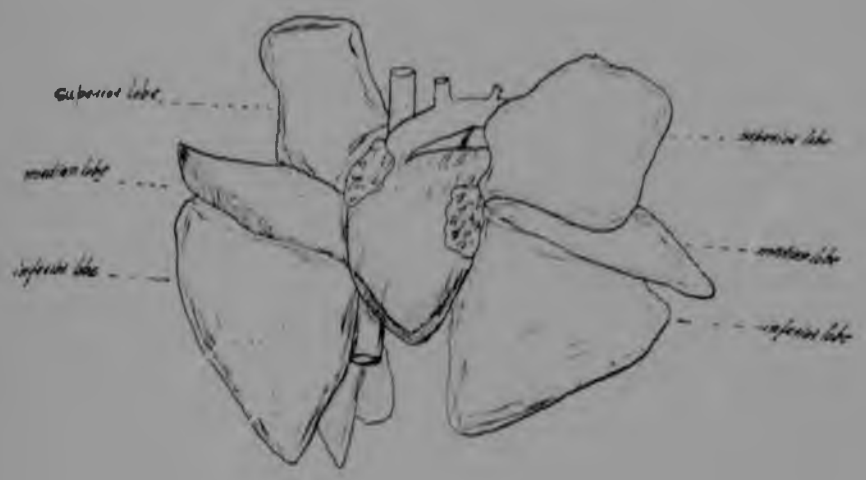

FIG. 74.

vion.



l view,

e dis-

FIG. 75.

G.T.S.E.

PLATE XVIII.

PLATE XIX.

SURICATA TETRADACTYLA.

Fig. 76. The heart;median longitudinal section through the left side.
X 1½.

Fig. 77. The heart;median longitudinal section through the right side.
X 1½.

Fig. 78. The main blood vessels.

Main Blood Vessels

inal

side.

inal

side.

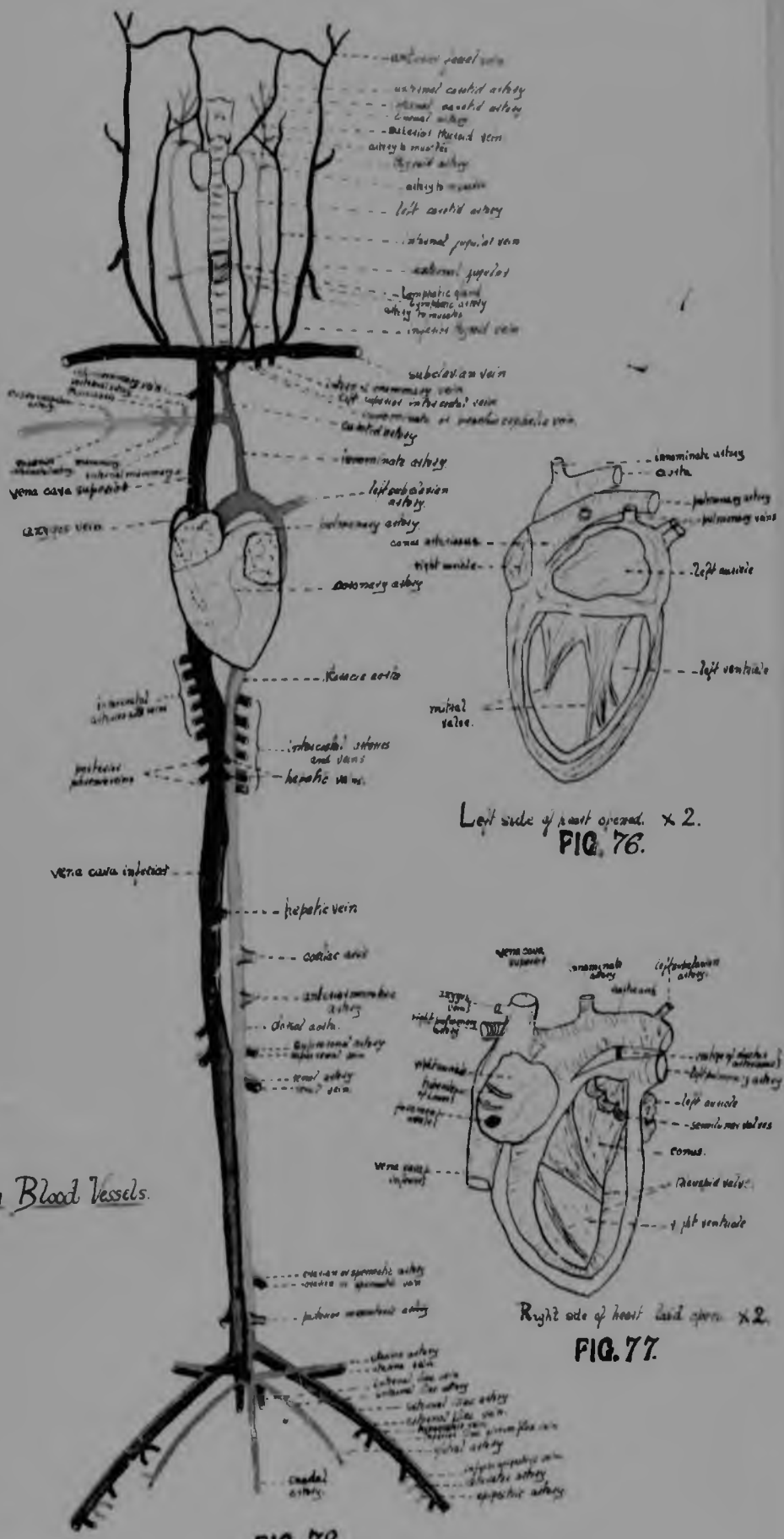

Left side of heart opened. × 2.

FIG. 76.

Main Blood Vessels.

Right side of heart laid open. ×2.

FIG. 77.

FIG. 78.

PLATE XIX.

PLATE XX.

BURITATA TETRADACTYLA.

Fig. 79. The coeliac axis. X 1½.

Fig. 80. The alimentary tract with associated blood vessels.

Slightly reduced.

PLATE XX.

BURISATA TETRADACTYLA.

Fig. 79. The coeliac axis. X 1½.

Fig. 80. The alimentary tract with associated blood vessels.

Slightly reduced.

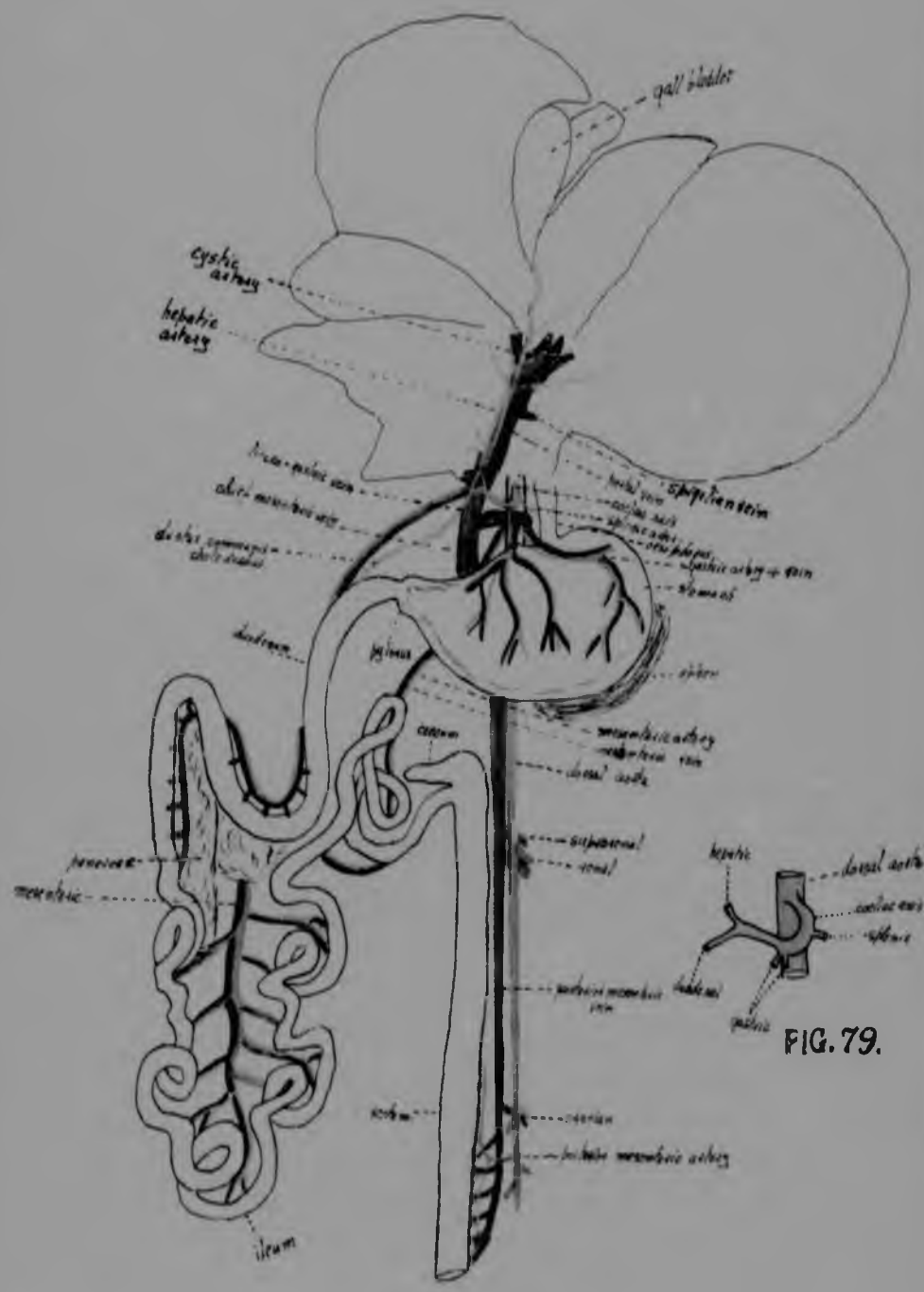

G.T.S.E.

PLATE XX.

PLATE XXI.

SURICATA TETRADACTYLA.

Fig. 31. Posterior portion of the vascular system.

X 1½.



FIG. 81.

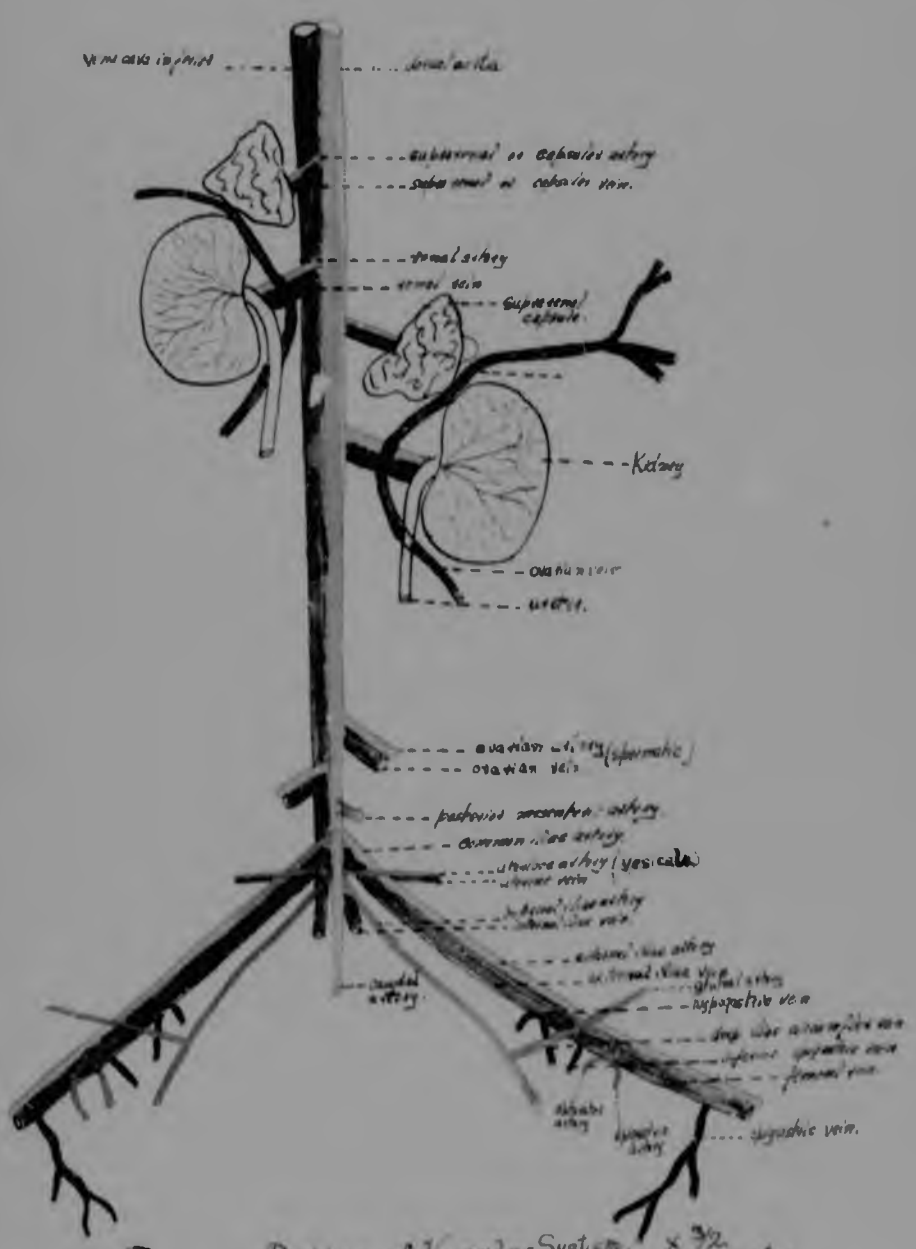

PLATE XXI

PLATE XXII.

MURICATA TETRADACTYLA.

Fig. 82. The hyoid bone. X 1½.
Posterior aspect.

Fig. 83. The hyoid bone. X 1½.
Lateral aspect.

Fig. 84. The head with the skin
partly removed to show
the salivary glands.
Natural size.



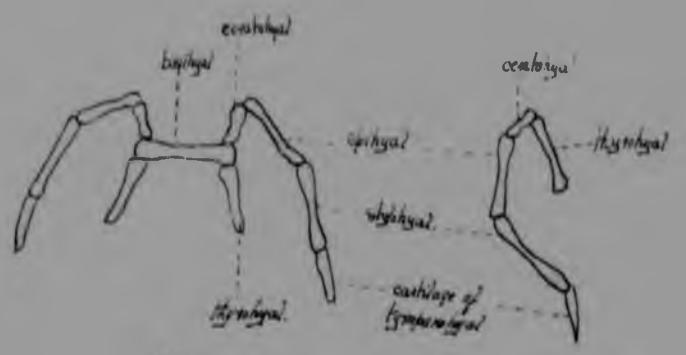

Posterior view
Fig. 82

Lateral view
Fig. 83.

Hyoid bone. x 3/2.

PIGS. 82 and 83.

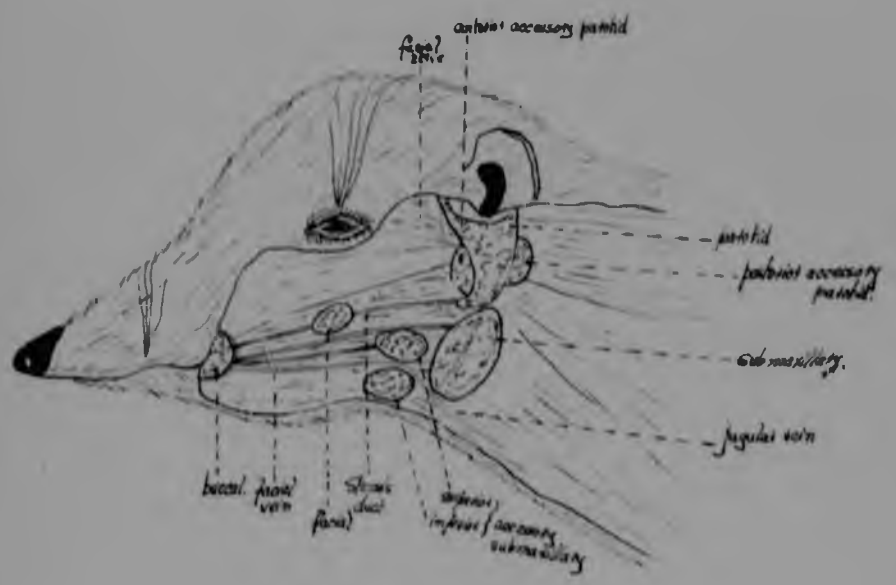

Salivary glands. FIG. 84.

PLATE XXII.

QTSE

PLATE XXIII.

SUBICATA TETHALACTYLA.

Fig. 35. The liver. Ventral surface.
Natural size.

Fig. 36. The spleen. Posterior aspect.
Natural size.

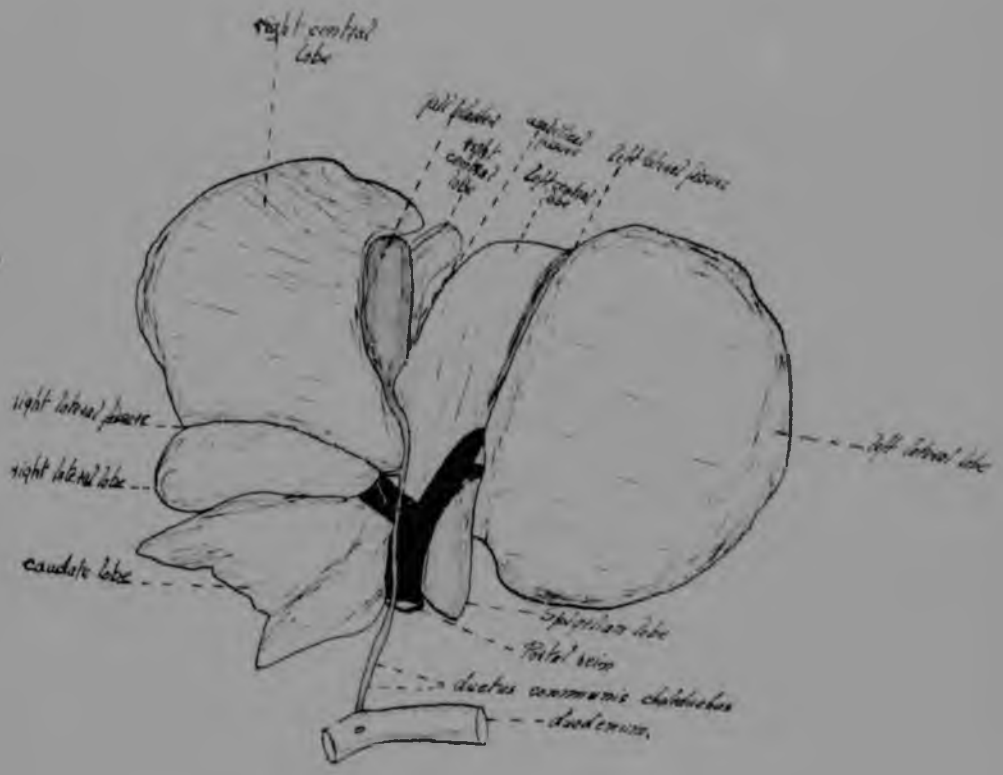

LIVER. Ventral surface.

PIG. 85.



Spleen. dorsal surface.

PIG. 86.

G.T.S.E.

PLATE XXIII.

PLATE XXIV.

DURICATA TETRADACTYLA.

THE BRAIN.

Fig. 87. Dorsal view;natural size.

Fig. 88. Ventral view;natural size.

Fig. 89. Lateral view;natural size.

Fig. 90. Vertical longitudinal section through the middle.
Natural size.

Fig. 91. Upper surface;natural size.
The cerebral hemispheres are widely divaricated to show the parts naturally covered.

Fig. 92. Dorsal view of left cerebral hemisphere dissected down to the corpus callosum, and of the right dissected still lower to expose the lateral ventricle.
Natural size.



Dorsal view
Fig. 87.



Lateral view
Fig. 89.



Upper surface.
Fig. 91.

BRAIN.

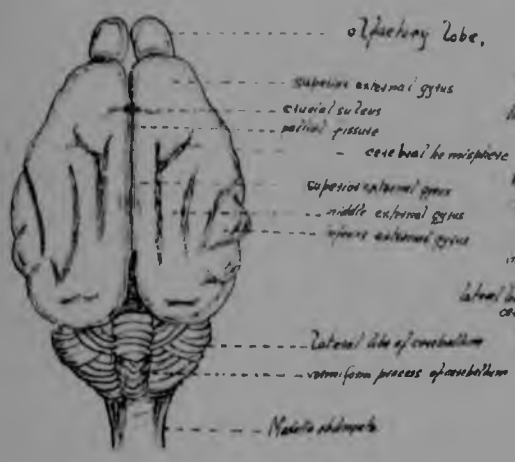

Dorsal view
Fig. 87.

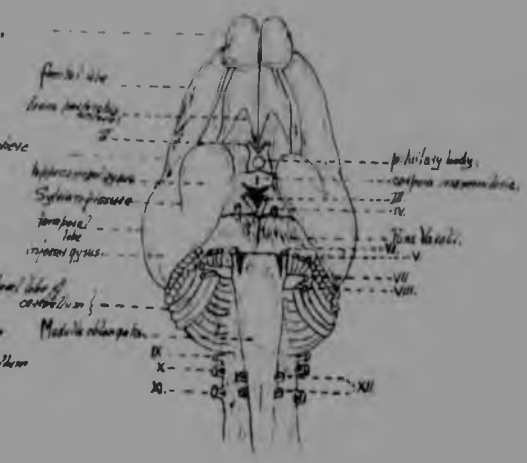

Ventral view.
Fig. 88.

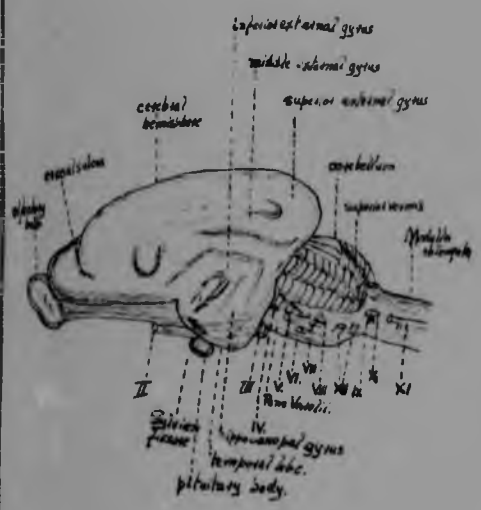

Lateral view.
Fig. 89.

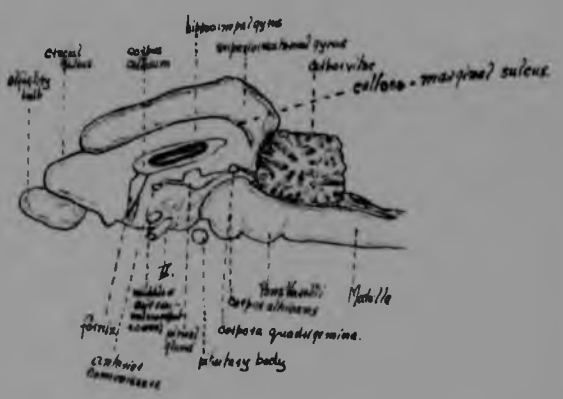

Vertical longitudinal section
through the middle.
Fig. 90.

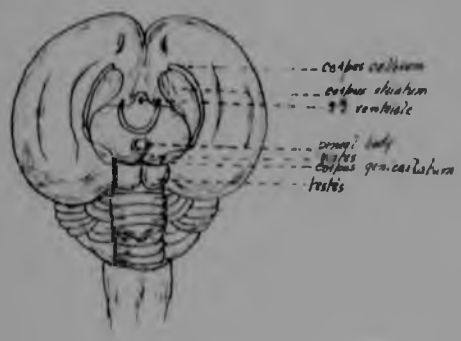

Upper surface.
the cerebral hemispheres are widely diverticated to show parts usually covered.
Fig. 91.

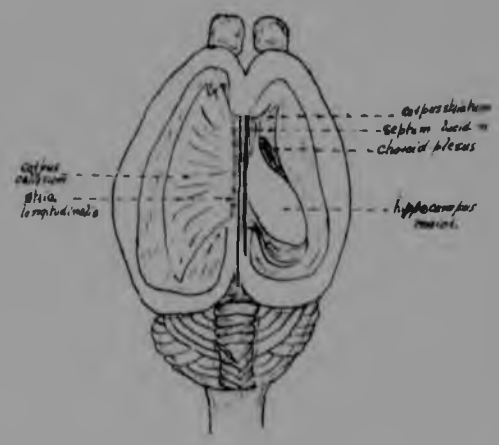

Left cerebral hemisphere dissected down to corpus callosum; on right lateral ventricle is exposed.
Fig. 92.

G.T.S.E.

PLATE XXIV.

PLATE XXV.

SUBICATA TETRADACTYLA.

Fig. 93. The nerves of the neck.

Natural size.

neck.

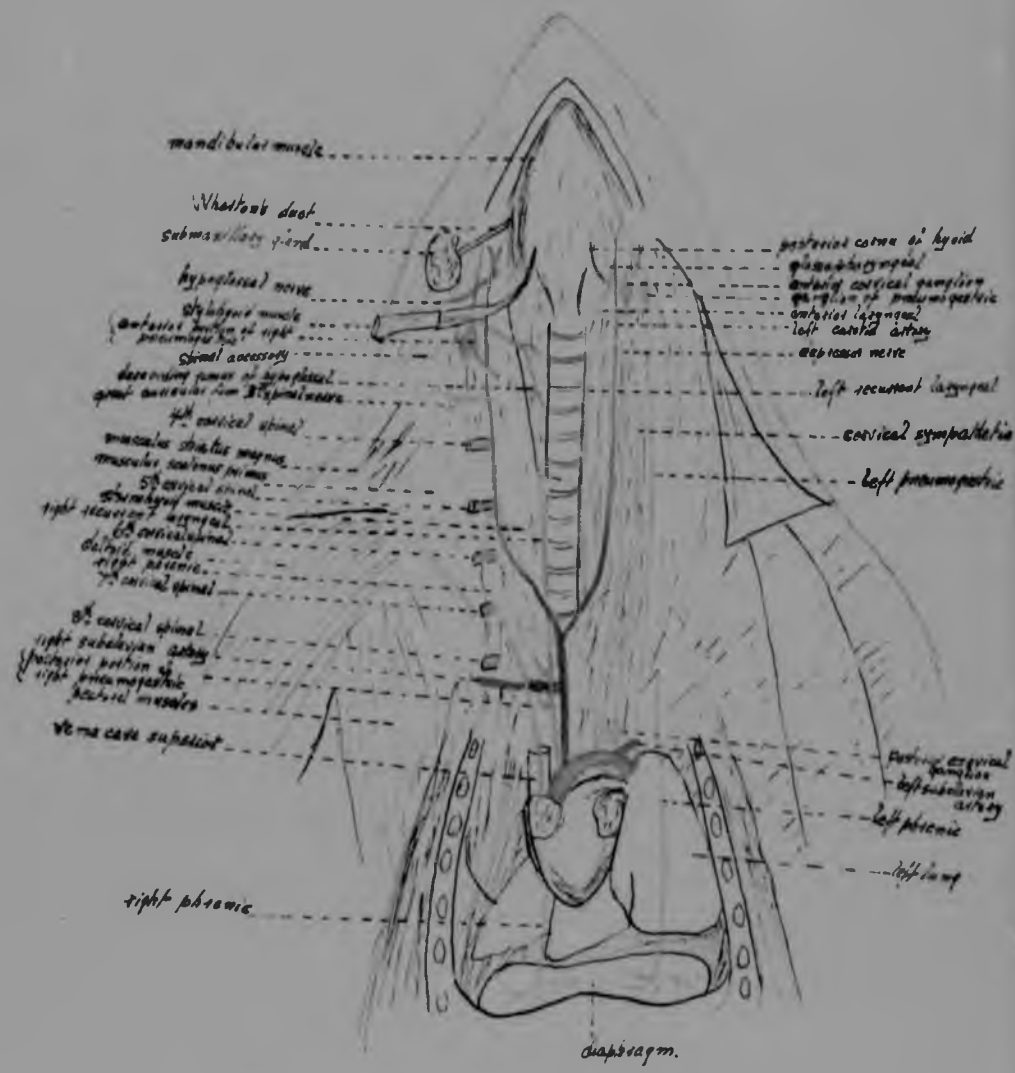

FIG. 93.

PLATE XXV.

GTSE

PLATE XXVI.

SURICATA TETRADACTYLA.

Fig. 94. Diagram of the solar plexus.

Natural size.

Fig. 95. Diagram of the brachial plexus.

Natural size.

Fig. 96. Diagram of the lumbo-sacral plexus.

Natural size.

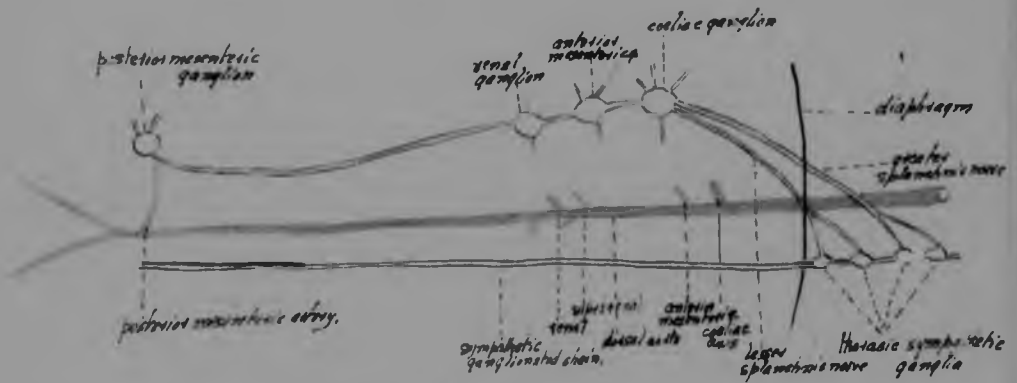

Solar Plexus. (Diagram.)

FIG. 94.

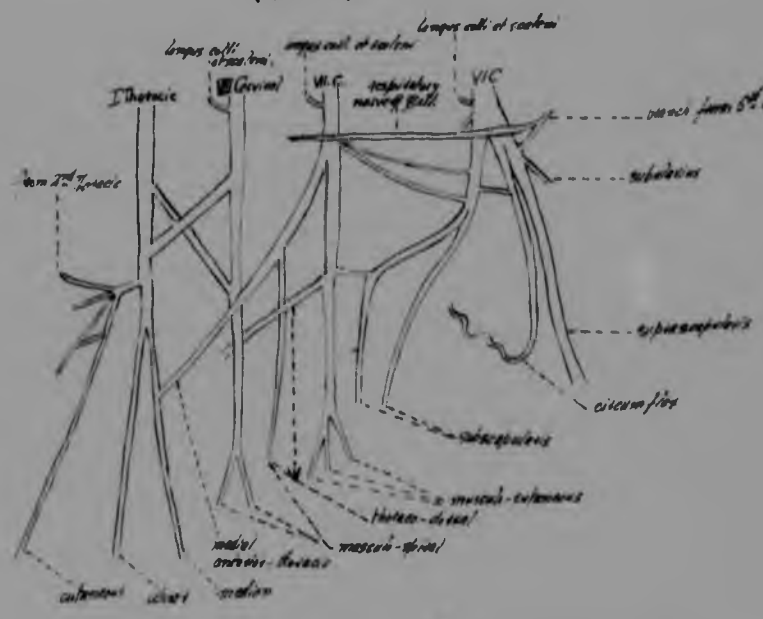

Diagram of Left Brachial Plexus.

FIG. 95.

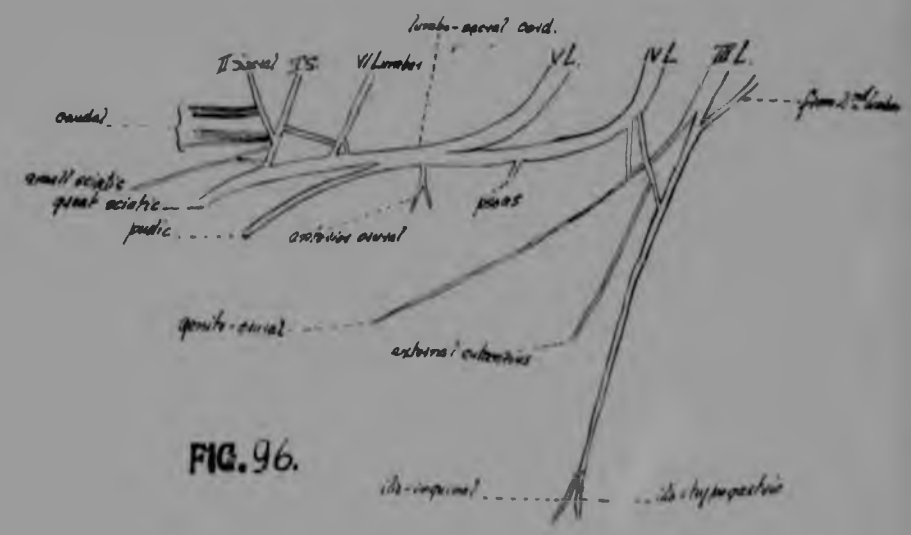

FIG. 96.

Diagram of Left Lumbo-sacral Plexus.

PLATE XXVI

G.T.S.F.

PLATE XXVII.

SURICATA TETRADACTYLA.

Fig. 97. Anus and scrotum, seen from above.
Natural size.

Fig. 98. Male urinogenital organs.
Natural size.
Dorsal aspect.

Fig. 99. Os penis. X 1½.
Dorsal aspect.

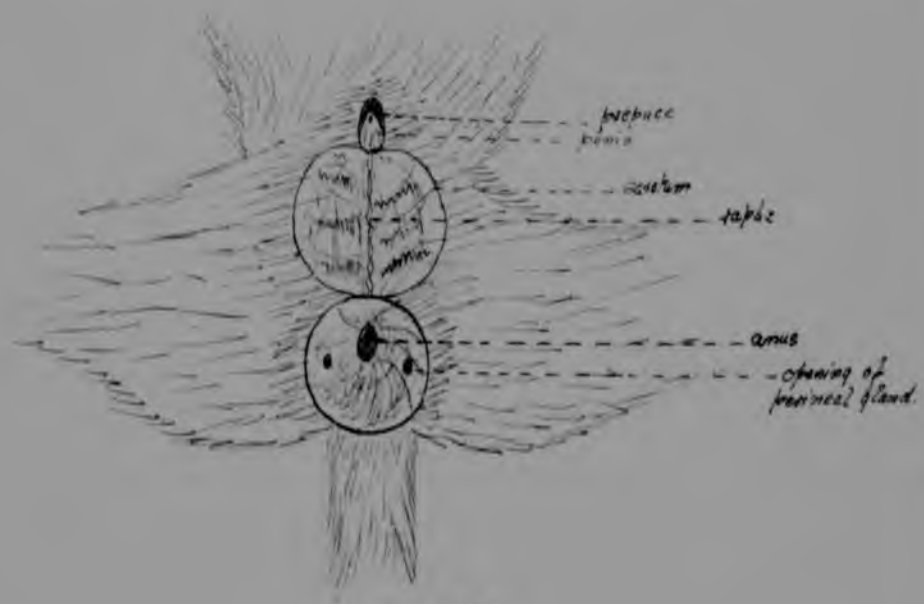

FIG. 97.

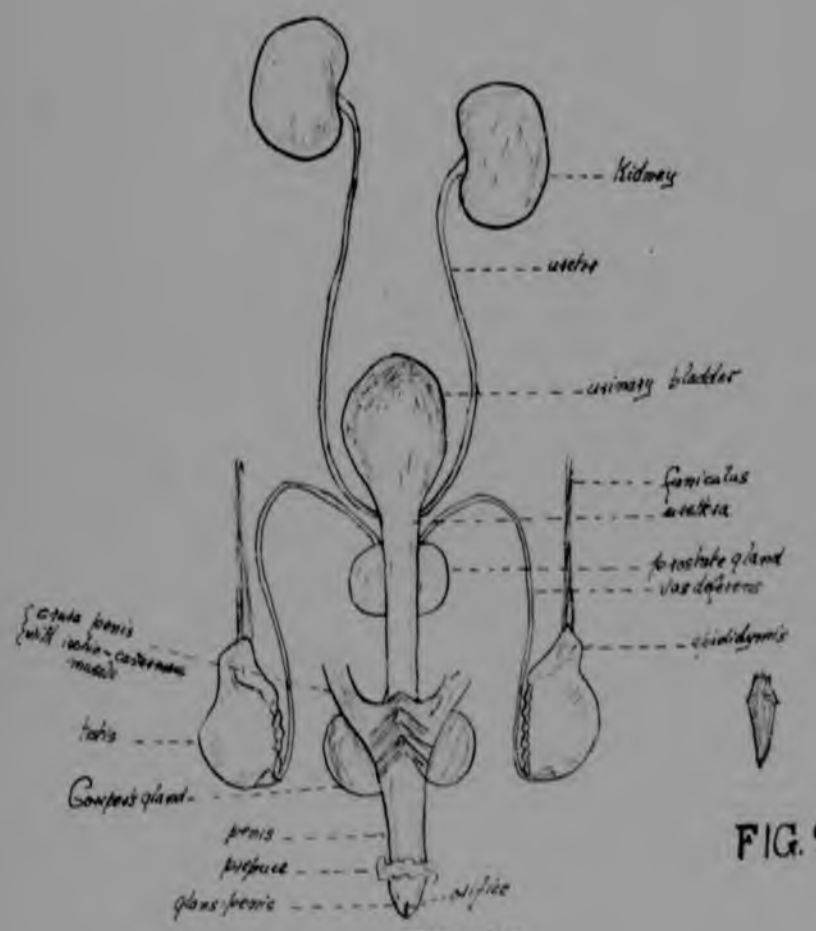

FIG. 98

FIG. 99.

PLATE XXVII.

GTSE

PLATE XXVIII.

SUBICATA TETRADACTYLA.

Fig. 100. Female urirogenital organs.

Natural size.

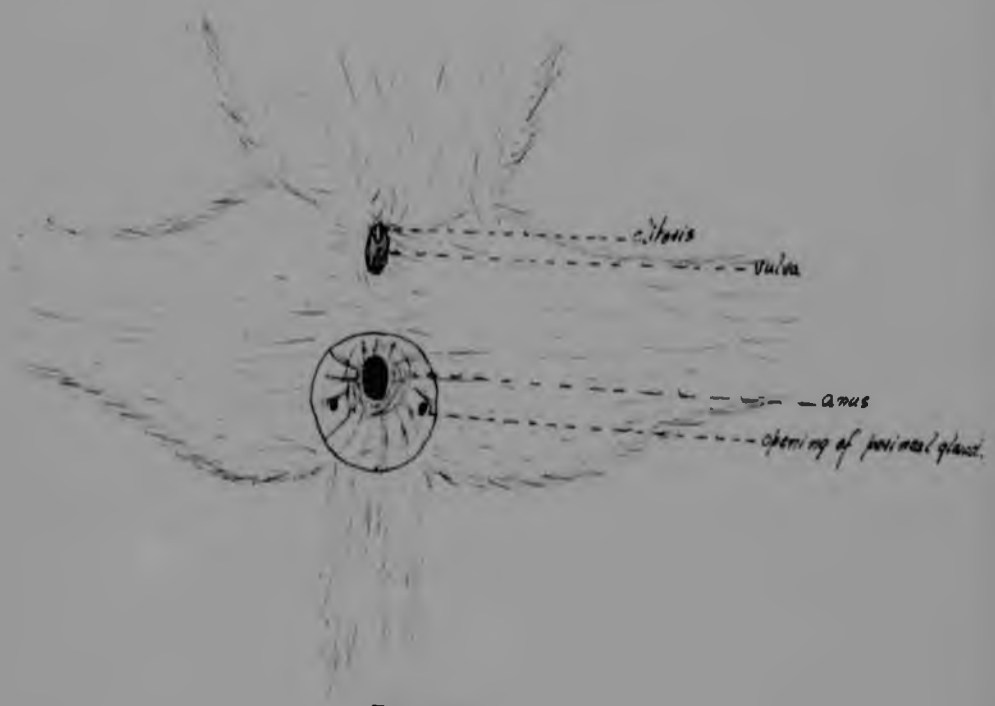

FIG. 100 a.

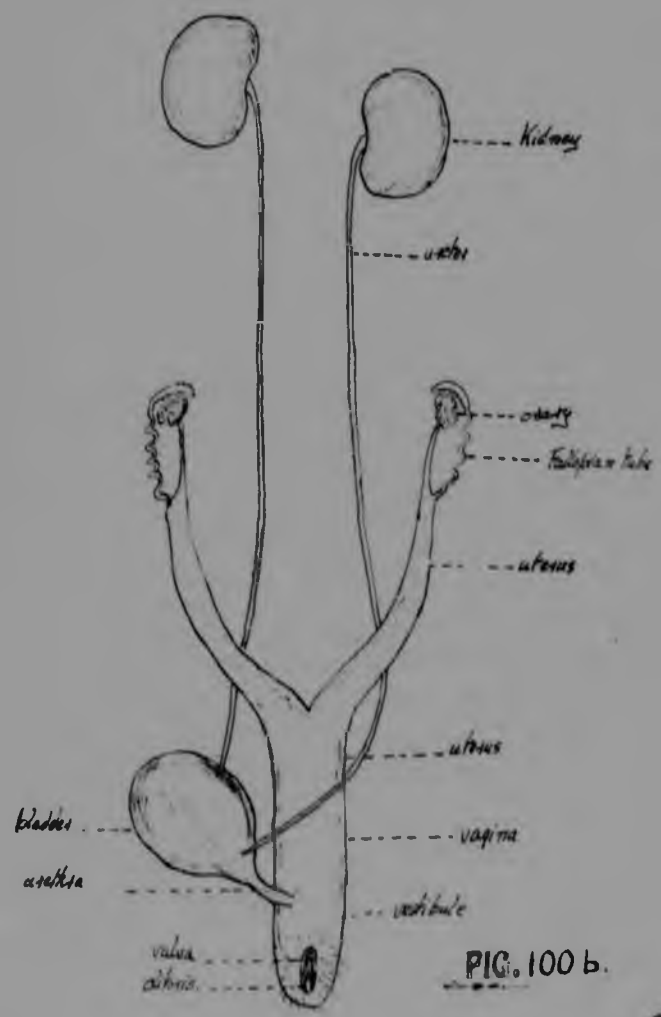

FIG. 100 b.

PLATE XXVIII.

PLATE XXIX.

Figs. 101 - 109. Giardia, depicting the various shapes as seen under the microscope.
Highly magnified.

Fig. 110. Young coccidian trophozoites in submucosal cells of the ileum.
Highly magnified.

Fig. 111. Microgametocyte of a Coccidium.
Highly magnified.

Fig. 112. Coccidian oocyst.
and 113. Highly magnified.

Fig. 114. Giardia from ileum.
Highly magnified.

Figs. 115 & 116. Giardia.
Drawn from stained preparations.
Highly magnified.













Fig. 101.



Fig. 102.



Fig. 103



Fig. 104.



Fig. 105.



Fig. 106.



Fig. 107.



Fig. 108.



Fig. 109.



Fig. 111.



Fig. 110



Fig. 112.



Fig. 113.



Fig. 114.

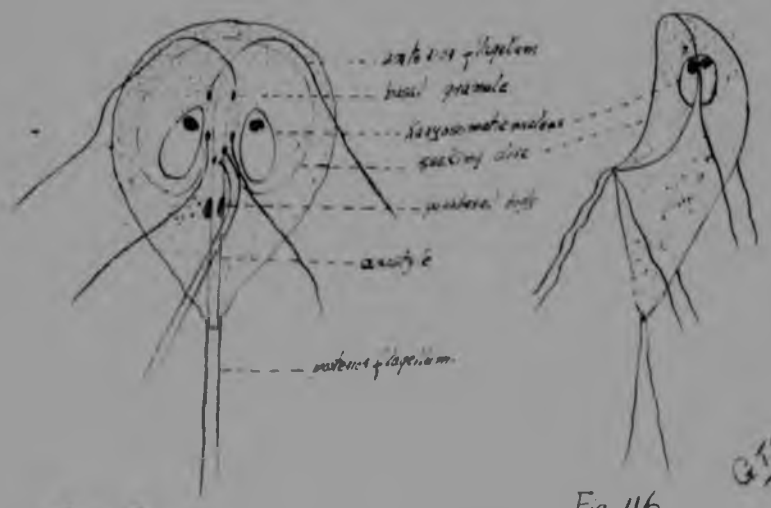

Fig. 115.

Fig. 116.

G.T.S.E

PLATE XXIX.



Fig. 101.



Fig. 102.



Fig. 103



Fig. 104.



Fig. 105.



Fig. 106.



Fig. 107.



Fig. 108.



Fig 109.



Fig. 111.



Fig. 110



Fig. 112.



Fig. 113.



Fig. 114.

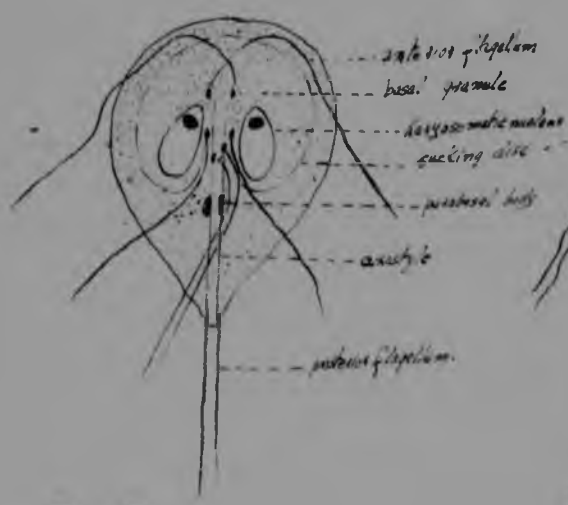

Fig. 115.



Fig. 116.

GTSE

PLATE XXIX.

PLATE XXX.

Fig. 117. Ascarid Nematode.



Head region



Caudal region.

Fig. 117.

G.T.S.E.

Plate XXX.

Filaria setariosa



Anterior portion.

Fig. 118.



Oral region

Fig 119

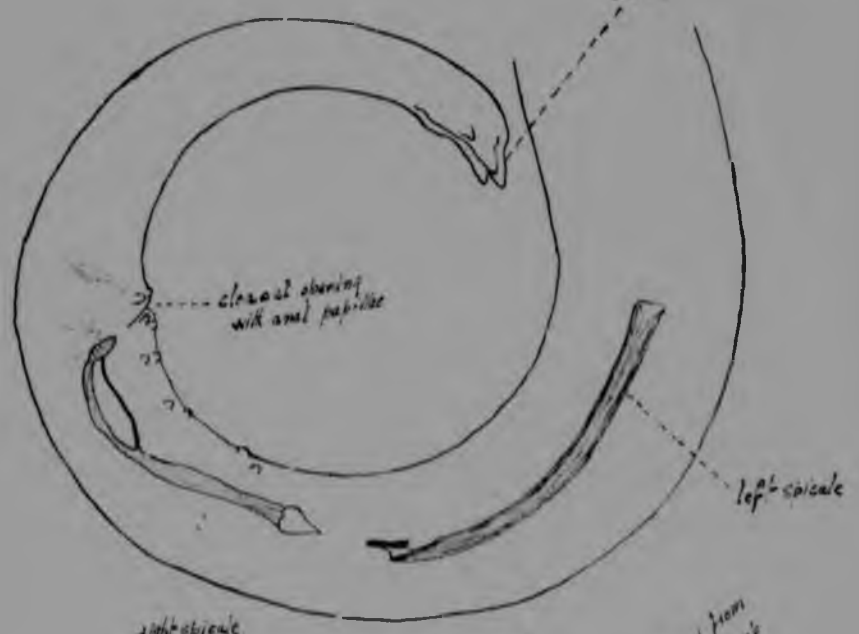

Posterior portion of Male (magnified)

Reproduced from Dr. H.O. Morning's drawings.

Fig 120.

Plate XXXI.

APPENDIX

The threadworms (Filariidae) mentioned on page 63 were submitted to Dr. H.O. Mönnig, Onderstepoort, who was kind enough to identify the same and to furnish me with the following particulars and drawings. He proposes naming it Filaria setariosa, and considers it a new species.

FILARIA SETARIOSA n.sp.
(Plate XXXI. Figs. 118-120.)

"Body very slightly tapering anteriorly, but markedly posteriorly. Mouth seems to be surrounded by ten papillae, an outer ring of two, dorsal and ventral, and four submedian, and an inner ring of four submedian, but they are very indistinct and only the outer four submedian could be made out definitely. Cuticle not striated.

Male. 38mm.X 30μ. Posterior extremity coiled in a spiral of four to five turns and strengthened by transverse cuticular thickenings on the ventral side, 12 μ apart, for several millimetres. There are four pairs of preanal papillae and a single pair of postanals situated on the posterior border of the cloacal opening. The left spicule is 157 μ long, with a distal pointed end to which is attached a small chitinous rod, lying next to the end of the spicule. The right spicule is 134 μ long, somewhat irregularly curved; the distal portion is split into a thicker and a thinner limb, which diverge and again meet at the end; the latter is slightly thickened and corrugated. The tail is 302 μ long and bears near the end a pair of ventral thickenings followed by a pair of small lateral processes and ends in three larger terminal processes.

Female. 81.5mm.X 182 μ. The oesophagus is 3.03 mms. long, its anterior muscular portion being ¼ of the whole. The nerve ring is situated at about the middle of the muscular oesophagus. The vulva is situated shortly behind the end of the oesophagus, 3.2 mms. from the anterior extremity. The tail is 558 μ long, ending bluntly with three conical terminal projections. The eggs measure 31 μ X 27 μ, they are thin-shelled and contain fully developed embryos.

HOST:- Suricata tetradactyla.

LOCATION:- Peritoneum and peri-intestinal adipose tissue

LOCALITY:- South Africa.

This worm corresponds in some respects to Filaria diacantha, Molin 1858, also a parasite in the abdominal cavity of rodents, but according to the description of the latter, the two cannot be regarded as identical. The location of the parasite in the abdominal cavity, the presence of appendices on the tail and more especially the structure of the spicules would tend to suggest affinities with SETARIA rather than with FILARIA. However, the structure of the mouth is typically Filarian, the caudal appendices of Setaria are a pair of lateral ones and the worm conforms to the diagnosis of Filaria."

(The above account is a verbal reproduction of Dr. Mönnig's description.)

LOCATION:- Peritoneum and peri-intestinal adipose tissue

LOCALITY:- South Africa.

This worm corresponds in some respects to Filaria diacantha, Molin 1858, also a parasite in the abdominal cavity of rodents, but according to the description of the latter, the two cannot be regarded as identical. The location of the parasite in the abdominal cavity, the presence of appendices on the tail and more especially the structure of the spicules would tend to suggest affinities with SETARIA rather than with FILARIA. However, the structure of the mouth is typically Filarian, the caudal appendices of Setaria are a pair of lateral ones and the worm conforms to the diagnosis of Filaria."

(The above account is a verbal reproduction of Dr. Monnig's description.)

Author Eiselen G T S
Name of thesis Suricata Tetradactyla 1923

PUBLISHER:
University of the Witwatersrand, Johannesburg
©2013

LEGAL NOTICES:

Copyright Notice: All materials on the University of the Witwatersrand, Johannesburg Library website are protected by South African copyright law and may not be distributed, transmitted, displayed, or otherwise published in any format, without the prior written permission of the copyright owner.

Disclaimer and Terms of Use: Provided that you maintain all copyright and other notices contained therein, you may download material (one machine readable copy and one print copy per page) for your personal and/or educational non-commercial use only.

The University of the Witwatersrand, Johannesburg, is not responsible for any errors or omissions and excludes any and all liability for any errors in or omissions from the information on the Library website.