

https://dspace.org/

The safety of the superomedial pedicle for gigantomastia

Chetty, Vaneshri

2016
http://hdl.handle.net/10539/22464

Downloaded from a DSpace repository. https://dspace.org/

TABLE OF CONTENTS

i. DECLARATION
ii. DEDICATION
iii. ABSTRACT
iv. ACKNOWLEDGEMENTS
v. TABLE OF CONTENTS
vi. LIST OF TABLES
vii. LIST OF FIGURES
viii. LIST OF ABBREVIATIONS

CHAPTER 1 - INTRODUCTION AND LITERATURE REVIEW 28

1.1 INTRODUCTION 28

1.1.1 Aetiology of Breast hypertrophy 31

1.1.2 Incidence 33

1.1.3 Indications for Choosing a pedicled BBR for Macromastia/Gigantomastia 34

1.1.4 Objective 34

1.1.5 Background 35

CHAPTER 2 - PATIENTS & METHODS 39

2.1 PATIENT SELECTION 39

2.2 SURGICAL APPROACH 39

2.2.1 Skin Markings (figure 1) 40

2.2.2 Operative technique 40

CHAPTER 3 - RESULTS 44

3.1 TABLE 1: PATIENT DATA 44

3.2 TABLE 2: COMPLICATIONS 46

3.3 TABLE 3: QUADRANT DIVISION OF NAC LIGHT TOUCH SENSATION CHANGE AT 1 YEAR47

3.4 TABLE 4: BREAST AESTHETICS AFTER 1 YEAR 47

3.5 RESULTS ANALYSIS 48

CHAPTER 4 - DISCUSSION 50

4.1 NAC PLACING 50

4.2 SKIN RESECTION PATTERN 50

4.3 SMP PATTERN DESIGN 51

4.4 THE BREAST PEDICLE 51

4.5 DRAINS AND ANTIBIOTICS 52

4.6 TAPE, BANDAGES, AND COMPRESSION 52

4.7 EXPLORING CONCEPTS 52

4.7.1 Tissue Parenchymal Pattern Versus Skin Resection Pattern 52

4.7.2 Parenchymal Shaping Versus Skin Brassiere 52

4.7.3 What role does the parenchymal resection play? 53

4.7.4 Do Breast Sutures to pectoralis fascia work? 53

4.7.5 Liposuction for fine contouring 53

4.8 ANTICIPATION OF COMPLICATIONS 53

4.8.1 Nipple-areola malposition 54

4.8.2 Breast shape improvement using the medial pedicle, with the wise pattern skin resection 55

4.8.3 Nipple retraction 56

4.8.4 Hematoma 56

4.8.5 Nipple-areola necrosis 56

4.8.6 Fat necrosis 57

4.9 NIPPLE SENSATION 57

4.9.1 Shape and Projection and Scarring 58

4.9.2 Hypertrophied and symptomatic scars 59

4.9.3 Secondary breast deformity 59

4.9.4 Minor breast asymmetry 59

4.9.5 Nipple-areola malposition 59

CHAPTER 5 - CONCLUSION 62

5.1 OUTCOME AND PROGNOSIS 62

5.2 LIMITATIONS 62

APPENDIX F: ETHICAL APPROVAL FOR CONDUCTING THIS STUDY

APPENDIX G: SIGNED DECLARATION OF NON-PLAGERISM, TURNITIN

TITLE:The Safety of the Superomedial pedicle for Gigantomastia.

Dr. Vaneshri Chetty

A research submitted to the Faculty of Health Sciences, University of Witwatersrand, Johannesburg, in partial fulfillment of the requirements for the degree of Master of Medicine in Plastic and Reconstructive Surgery

18 July 2016

Johannesburg



i. DECLARATION

I, Chetty, Vaneshri, declare that this research report is my own work. It is being submitted for the degree of Master of Medicine in Plastic and Reconstructive Surgery at the University of the Witwatersrand, Johannesburg. It has not been submitted before for any degree or examination at this or any other University.

Chetty, Vaneshri



.....

Full Name & Surname

18 July 2016

DEDICATION

To all the staff at both Chris Hani Baragwaneth and Rand Clinic Hospitals without whichthis work would not have been so fruitful and unencumbered.

ABSTRACT

Introduction

Breast reduction surgery in women with gigantomastia and macromastia can present as a major challenge to the plastic and reconstructive surgeon. The superomedial pedicle (SMP) technique of breast reduction has been shown to be a safe and efficacious procedure to decrease a moderate size hypertrophy of the mammary glands. A myriad of techniques has been demonstrated to decrease the size of extremely large and hyperplastic breasts, they can, however, potentially result in complications, amongst the most dreaded being damage to the nipple-areola complex (NAC), especially necrosis and loss of sensibility.

Excessive breast hypertrophy is termed macromastia or gigantomastia. Macromastia is defined as an excess or hypertrophy of breast tissue over 1.0 kg per breast but less than 2.0 kg. Gigantomastia is defined as hypertrophied breast tissue equal to and greater than 2.0 kg per breast. [1]

McKissock recommended breast amputation mammoplasty and free nipple grafts for those reductions that required removal of more than one kilogram of parenchyma, or if the length of vertical distance is greater than 35 cm. [2]

Numerous pedicled techniques of breast reduction exist and pedicles can be based in any of the four quadrants as well as centrally. While the 2 main skin excision patterns include the Wise pattern (inverted T-shape closure) and the Vertical pattern. (Diagram.1 & 2)

Objective

The objective of this study was to determine exactly how efficiently the superomedial pedicle (SMP) technique performs breast reduction surgery, particularly in candidates with extremely large breasts, viz. macromastia and gigantomastia.

To evaluate the efficacy and complication rate of the SMP reduction mammoplasty technique, with wise pattern skin closure, for macromastia and gigantomastic breasts, at two different hospitals in Johannesburg, as performed by 2 surgeons, Chetty, V. and Ndobe, E.

Methods

Retrospective review of patient records with macromastia and gigantomastia who had undergone the SMP technique reduction mammoplasty, over a 4-year period. Complications were assessed at 1 week, 3 weeks, 6 months and a mean of one-year post operatively. Photo records were taken at each stage.

Results

There were a total of 31 patients, 62 breasts, with macromastia and gigantomastia that had an SMP pattern of reduction. The mean age was 30.1 years, mean BMI was 28.1 and average resection weight from each breast was 1835 g. The mean N-N was 44.13 cm. The majority, 90 % of patients had a good aesthetic outcome with less than 20% having any long-term complications, which were all relatively minor.

Conclusion

The SMP reduction mammoplasty efficiently reduces extremely large breasts while preserving the integrity of the NAC, sensation and simultaneously provides a well-shaped, projecting breast in macromastia and gigantomastia patients.

AKNOWLEDGEMENTS

To my family for theirinspiration always.

iv.**LIST OF TABLES**

Table 1: Patient data

Table 2: Complications

Table 3: Sensation 1 week to 1year post BBR

Table 4: Sensation at 1 year: per Quadrant

Table 5: Breast Aesthetics after 1 year

LIST OF DIAGRAMS

Diagram 1: Vertical skin resection pattern with variation of pedicle designs

Diagram 2: Wise key hole pattern skin resection pattern with variation of pedicle designs

Diagram 3: Skin resection pattern: Wise keyhole pattern

Diagram 4: Vertical movement of the NAC and Wise Keyhole pattern.

Diagram 5: Post-operative breast scars. 3: peri-areolar, vertical and horizontal

Diagram6: Post Operative Niple Areola Complex Viability:Right breast

Diagram7: Post Operative Niple Areola Complex Viability:Left breast

Diagram 8:Postoperative Preservation of Sensation Right Breast

Diagram 9:Postoperative Preservation of Sensation Right Breast

LIST OF FIGURES

Figure 1: Patient 1- Pre Operative Marking on Breasts

Figure 2: Patient 2 - Gigantomastia: yellow shading: Superomedial pedicle pre-operative planning

Figure 3: Patient 3 - Pre and Post-operative Superomedial Pedicle Reduction Mammoplasty

Figure 4: Patient 4 - Right Breast Superomedial Pedicle Dissection ofMacromastia breast

DIAGRAMS

Vertical skin resection pattern with variation of pedicle designs

Pedicle designed in each of the 4 breast quadrants:

a. Superior pedicle

b. Lateral pedicle

c. Medial pedicle

d. Inferior pedicle

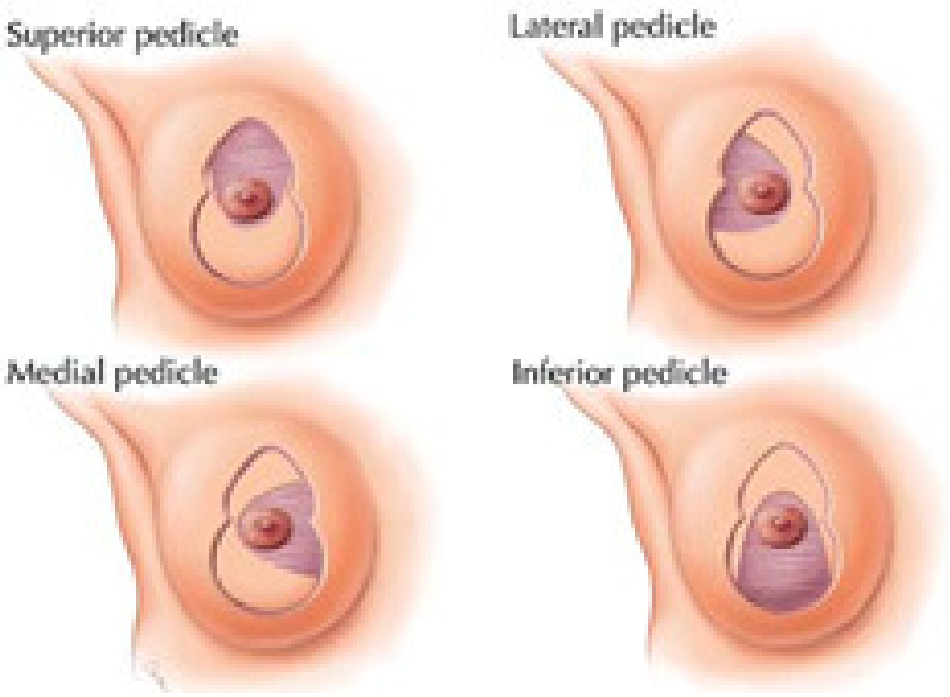

Diagram 1

Wise key hole pattern skin resection pattern with variation of pedicle designs

In each quadrant:

a. Central pedicle

b. Superomedial pedicle

c. Inferior pedicle

d. Superior pedicle

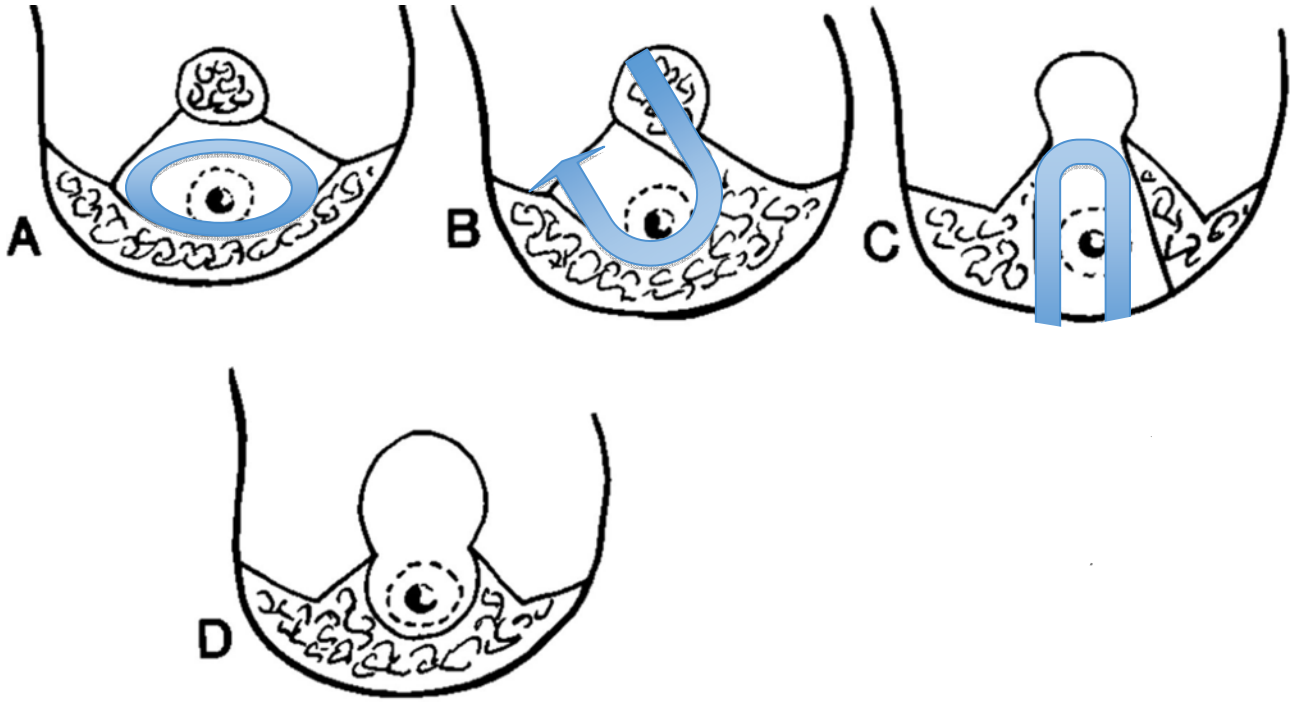

Diagram 2

Skin Markings

Preoperative

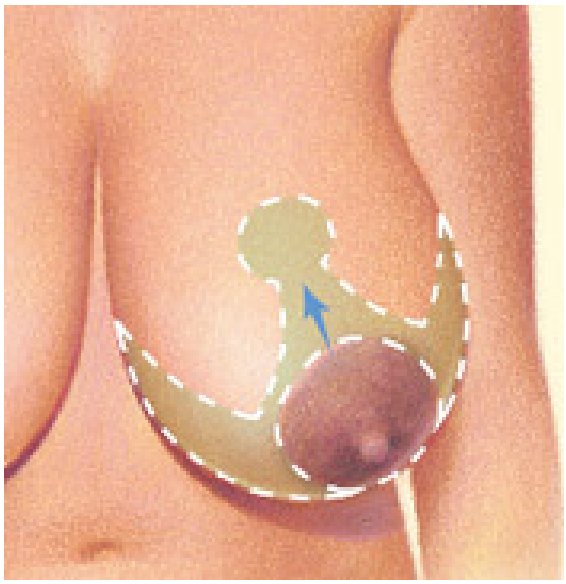

Diagram 4

1)White dash line:a)Wise 'Keyhole' pattern with peri-aereolar opening at the top of the 'keyhole'

b)White circular dash line: New areola marking

2)Blue arrow: planned vertical movement of the new NAC into the top of the keyhole

Post-Operative

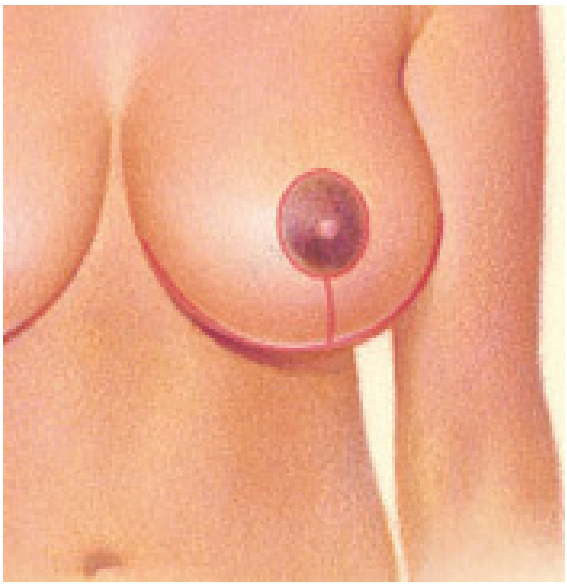

Diagram 5

1) 3 Red lines:Scars- peri-areola, vertical, horizontal

Post Operative Niple Areola Complex Viability

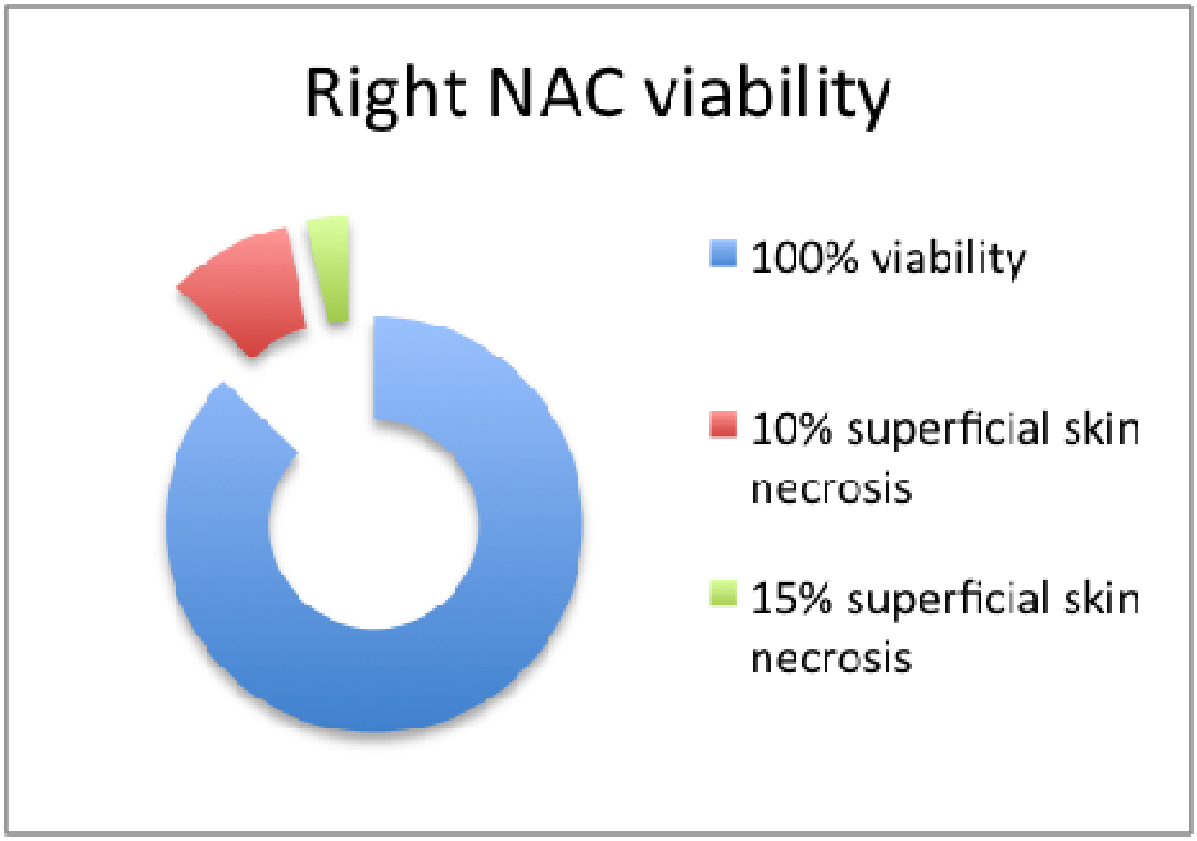

Diagram 6

NAC viability was well maintained, except minor superficial necrosis in 3 left breasts and 4 right breasts which experienced up to 10% and 15% minor surface necrosis respectively.

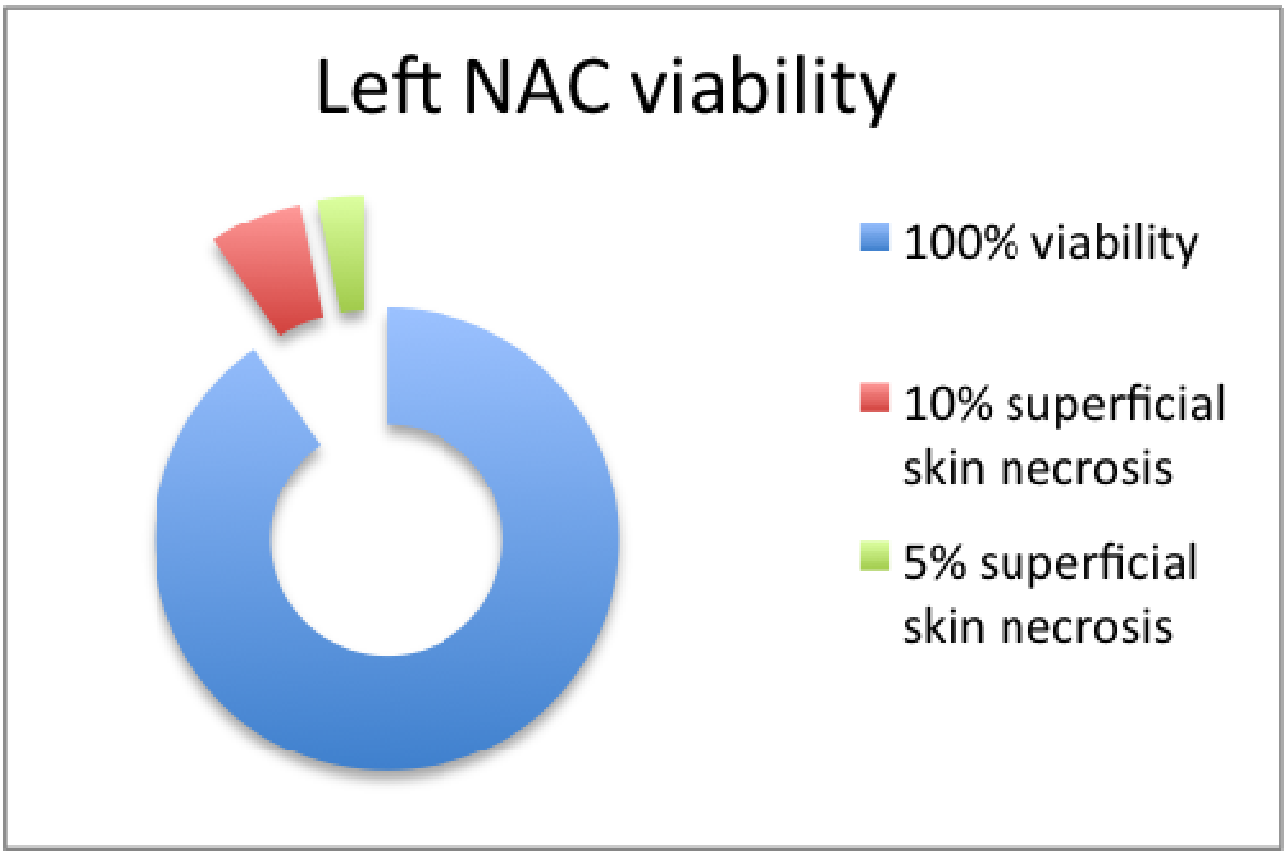
Left NAC viability
100% viability
10% superficial skin necrosis
5% superficial skin necrosis

Diagram 7

Postoperative Preservation of Sensation

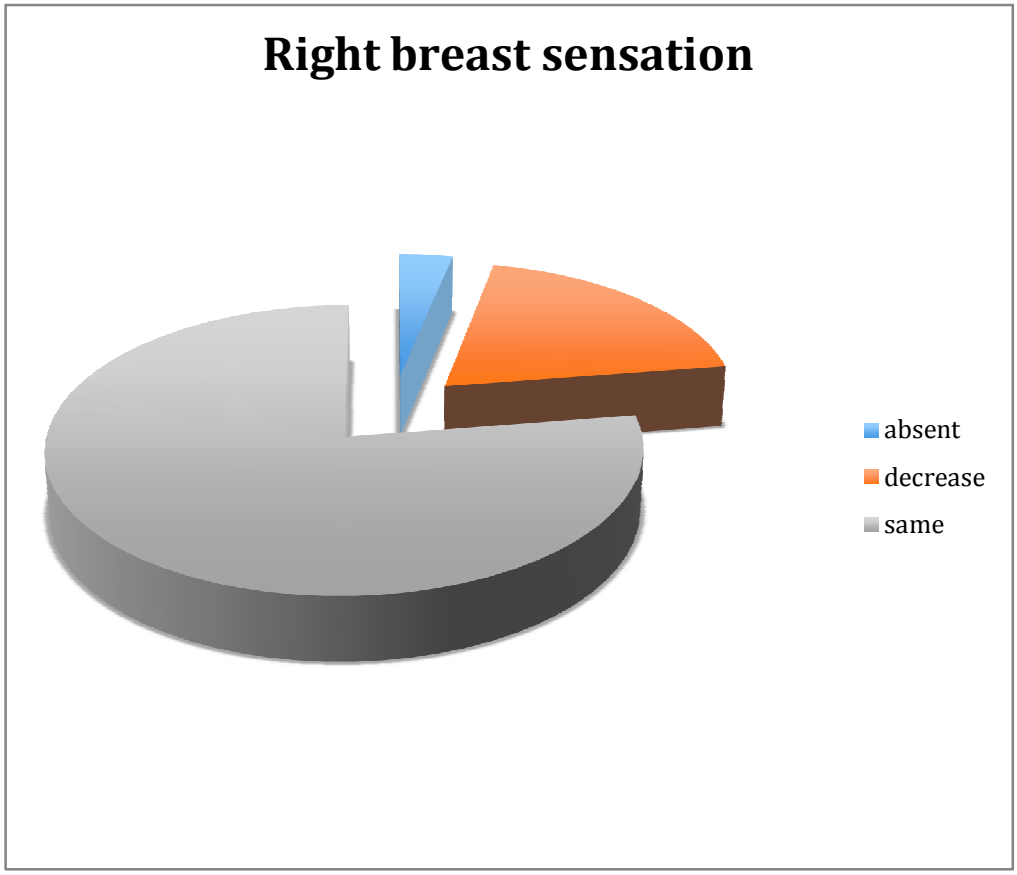

Diagram 8

Normal pre-operative sensation was preserved in over 80% on the left and 77% on the right. 16.1% experienced decreased, but not absent sensation, on the right and 12,9% on the left. One left and two right breasts still had absent sensation at 1 year.

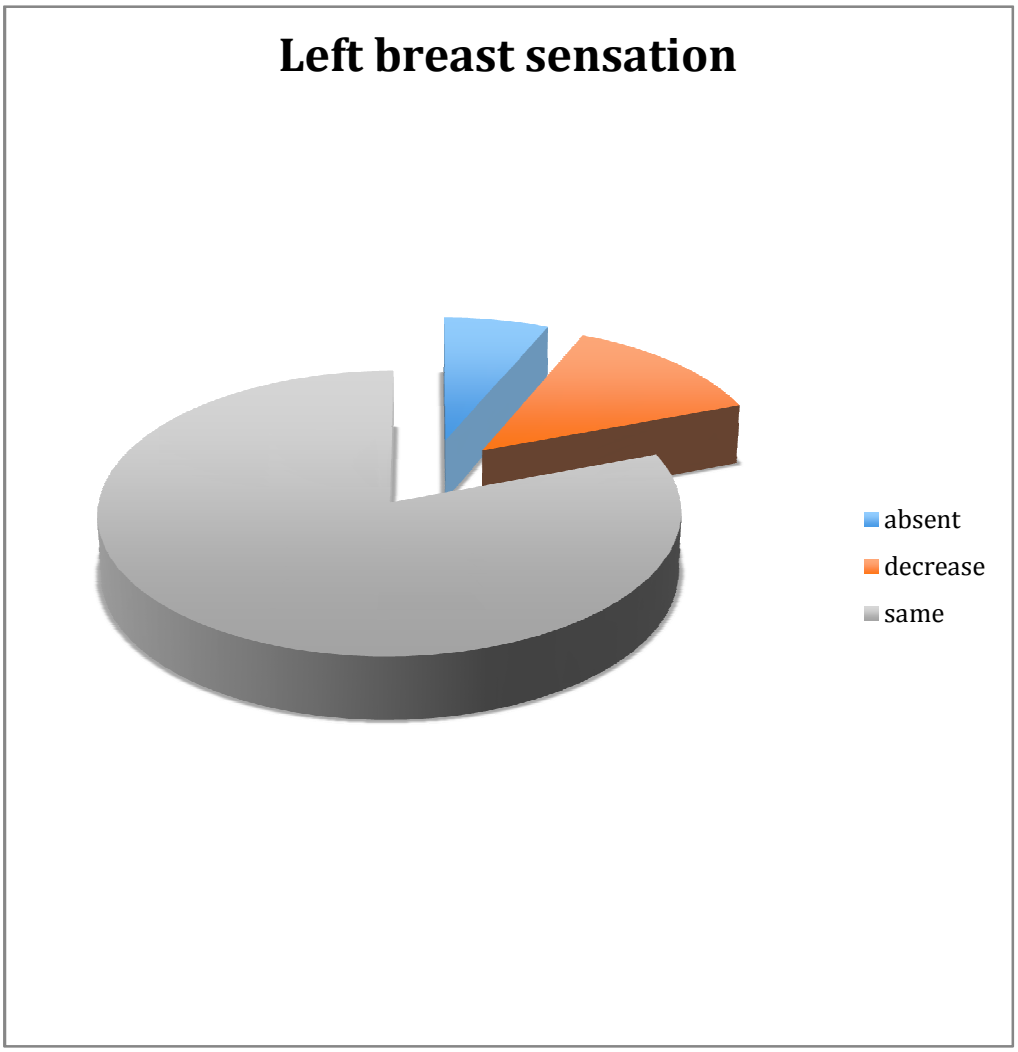

Diagram 9

Testing Light touch in 5 Quadrants

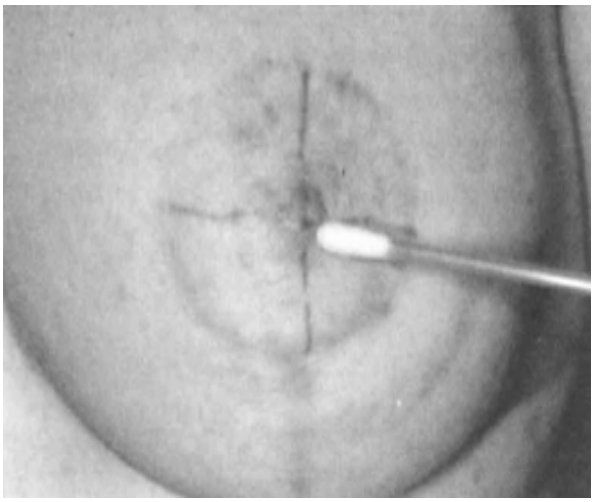

1 Central quadrant: Nipple

2 Right: Upper and Lower quadrants

2 Left: Upper and Lower quadrants

Diagram 10

Breast Amputation Skin Markings

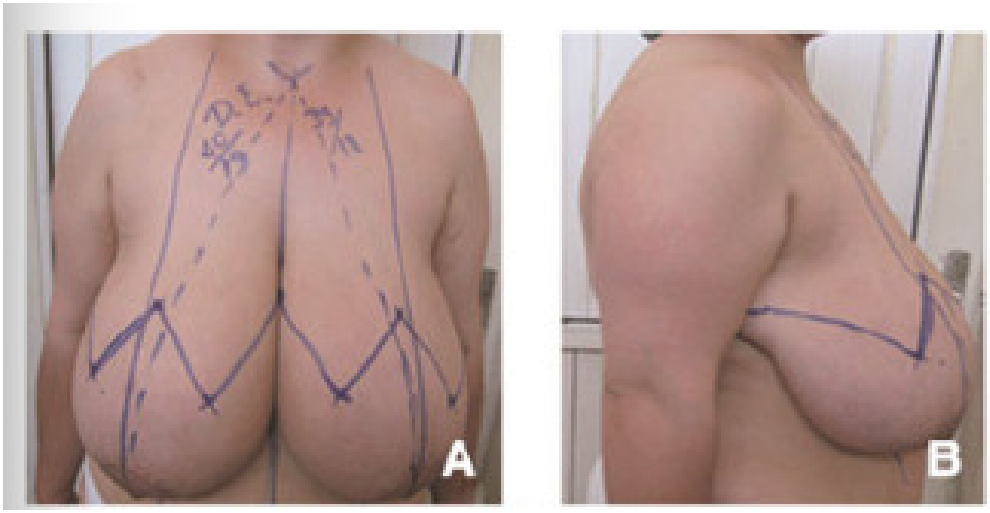

Diagram 11

A: Anterior View

B: Right Lateral View

FIGURES

Patient1: Pre-Operative Marking on Breasts

- Gigantomastic breasts
- Preoperative Markings:done in standing position
- Breast meridian: Central, vertical marking
- Skin resection pattern: Wise keyhole pattern (Fig.1 and diag. 3)
- Midline: N-N to Umbilicus

Anterior View



Figure 1a

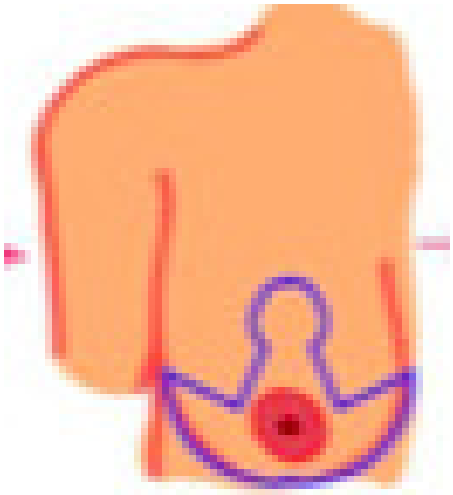

Diagram 3: Wise Keyhole Skin Pattern

Lateral View



Figure 1b

Patient 2: Gigantomastia: Pre-operative planning yellow shading: Superomedial pedicle, left.

Post-operative views, right.



Figure 2a

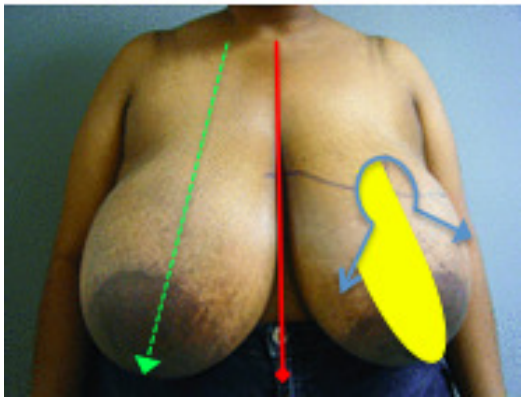

Figure 2b



Figure 2c



Figure 2d



Figure 2e



Figure 2f

Patient 2

2a:Gigantomastia Breast-large pendulous breasts. Note shoulder ‘bra strap grooving’

2b: Yellow shading: Superomedial pedicle pre-operative planning

2c: Post reduction mammoplasty: Anterior view

2d: Left semi-lateral view pre-operative

2e: Left semi-lateral view post-operative

2f: Right lateral view post-operative

Patient 3: Pre and Post-operative Superomedial Pedicle Reduction Mammoplasty

Anterior View

Pre-Operative

Markings

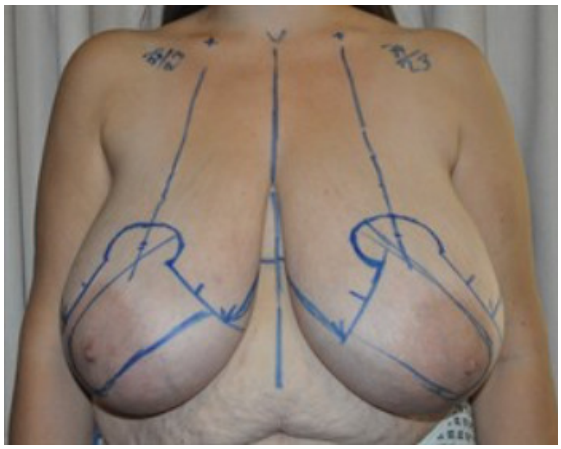

Figure 3a

Post-Operative: 1 month

Note: Vertical Scars



Figure 3b

Lateral View

Pre-Operative



Figure 3c

Post-operative

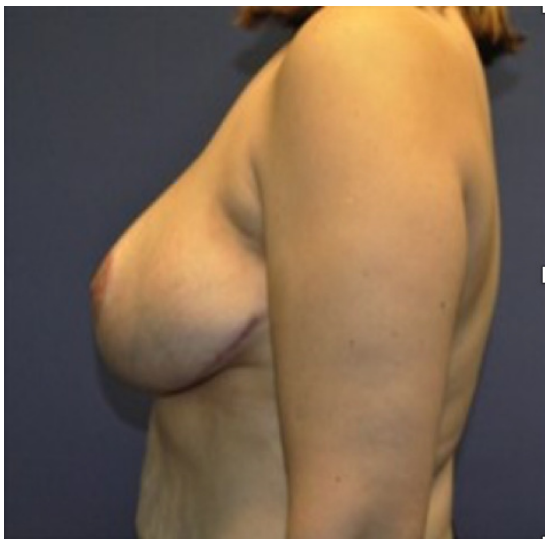

Figure 3d

Patient 4: Right Breast Superomedial Pedicle DissectionMacromastia

Anterior view: Preoperative Marking

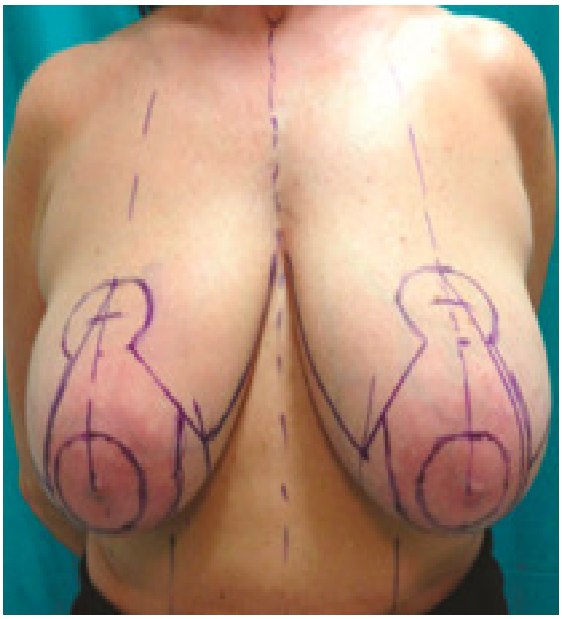

Figure 4a

- Pedicle de-epithelialized
- New NAC reduced to 4.5-5.5cm diameter
- Vertical pillar height: 6-8cm



Figure 4b

Rotation of Pedicle outward and upward into the keyhole of the Wise Keyhole

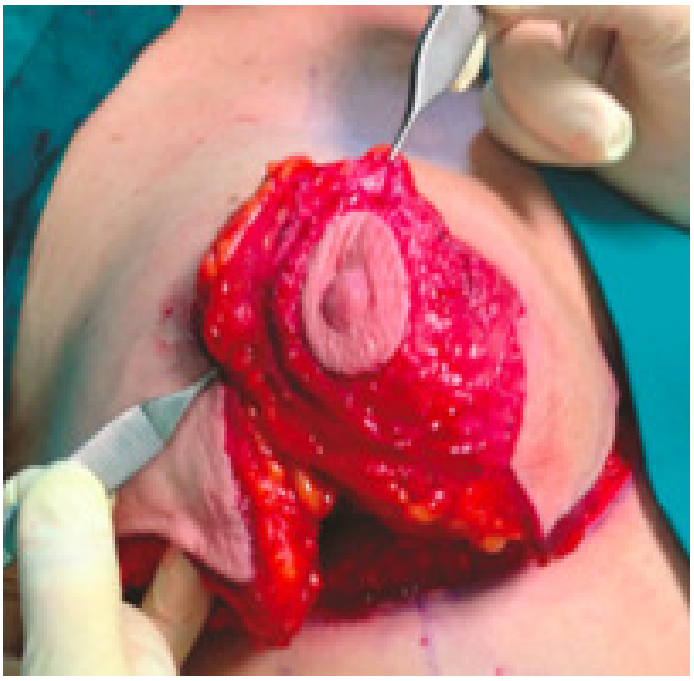

Figure 4c

LIST OF ABBREVIATIONS

BBR:Bilateral breast reduction

SMP:Superomedial pedicle

NAC:Nipple areola complex

IMF:Inferior mammary fold

N-N: Nipple to suprasternal notch distance

N-IMF: Nipple to inframammary fold distance

PI: Protease inhibitors

HIV: Human Immunodeficiency Virus

HAART: Highly Active Anti-Retroviral Therapy

s.c.:subcutaneous

ICN:Intercostal nerves

1.1 Introduction

Historically, moderately large breasts have reflected a sign of womanliness and femininity,and displayedboth their sexuality and a woman's ability to nurture. Though a woman with breasts that are significantly larger than the aesthetic norm of her era, may be seen as unusual or deformed.

Breast amputation with free-nipple graft and numerous unilateral pedicled and bi-pedicledsurgical reduction techniques are amongst the many current options for reducing large breasts. Some of the more severe complications of these reductionprocedures include NAC and or skin flap necrosis,hypopigmentationchange in sensitivity of the NAC.

Reduction mammoplasty improves body posture and decreases the perception of pain. [3]

Excessively large breasts, such as in gigantomastia is a disabling and unusualcondition marked by extreme mammarygland enlargement.[4]Extremely large and pendulous breastscan be troublesome to a woman. They cause abroad spectrum of physical as well as psychological repercussions. Macromastic and gigantimastic breasts are usually pendulous and heavy with nipples and areolas pointing downward.[5][6]Clinically they have averagely biggerthan normal, ptotic, descended,mammary glands, where most of the breast tissue hangs beneath the inframammary fold (IMF), additionally resulting in breast discomfort, ulceration and'bra-shoulder grooving'.

The candidate usually has a high BMI with a wider chest and pannus folds in the abdominal region.

Excessive breast hypertrophy results inan uncomfortable mastalgia,neck, back and shoulder pain, postural distortion,can lead to skeletalproblems in the IMF[5][6]and nerve paresthesia's. Additionally, clothing may never fit well.

Large breasts place restrictionson participation in exercise and sport.[7][8]

They are often associated social stigmas which leads to loss of confidence, social discomfort, embarrassment and feelings of sexual inadequacy. In more severe cases the chest weight can cause breathing discomfort and difficulty, especially during supine lying.

The large breast size can dominate a woman's appearance and contribute to a poor quality of life.[9][10]The cosmetic, physical defect potentially causes psychological and

emotional disturbances such as social awkwardness and depression. The hypertrophicbreast size can dominate a woman's appearance and contribute to a poor life quality.[9][10]

Bilateral breast reduction (BBR) offers advantageous physical benefits.Potential psychological advantages are immense and contribute to improved body self-image, quality of life, sexual function, as well as improving related symptoms of anxiety and depression.[Error! Bookmark not defined.][11]

Hall-Findlay [12]outlined why gigantomastia breasts, warrant a careful understanding when considering choice ofsurgical reduction procedure. This requires a plan,individualized to the patient, pre-empting of physical changes which occur when reducing thevolume and weight, and careful manipulation of the NAC.[12]

Theapproach to bilateral breast hyperplasia has traditionally been a surgical one, the first more primitive methods made their debut over 100 years ago.[13]

Thorek, in 1921[14] described the earlydepartureinto this realm, and endeavored to excise large amounts of the breast tissue surgically and transplant the NAC, for purely cosmetic reasons.

Someadditional historic indications for breast amputation[15] and free grafting of the NAC, included gigantomastia and macromastia,older age group, poor wound-healing ability e.g., diabetes, chronic steroids systemic disease with poor microcirculation, and previous breast scarring which could compromise skin flap or pedicle tissue viability.

Attention to patient selection will limit the possible functional and cosmetic liabilities of the amputation and free nipple graft technique.It was not offered as an optimal choice for younger candidates who may want to breast-feed infants in the future, or if they don’t want to risk loss of nipple-areola sensation.

Courtis et al[16]looked at patients undergoing different plastic surgical procedures on their breasts and assessed them before and after operations with respect to sensation from crude touch, light pressure, and pain. Those with extensive operations on the breast (the more skin and breast tissue removed) had greater postoperative decrease in sensation. Reduction mammoplasty and subcutaneous mastectomy were associated with decreased sensation in a significant number of patients. At two years, 15 percent of the patients still had impaired sensory perception, although crude touch and light pressure appreciation had returned. Many of these patients had normal erectility with normal, and even enhanced, sensuality.[16]

Robbins[17]in 1987,suggested the breast amputation procedure only for excisions greater than 1500 mg per breast, extreme skin laxity or nipple excessively far from the

desired new position. In theory, breast amputation can remove a considerable amount of the mammary ducts and thus could also be beneficial in helping diminish the risk of subsequent breast cancer.

However, some valid reservations about breastreduction by amputation are as aforementioned for BBR, and including, diminishednipple sensibility, actual NAC loss and erectile response. Additionally, the possibility of flattening of the breastand patchy loss of pigmentation of the NAC are a concern. Often a suboptimal breast shape is an additional downside with amputation.

Medical hormonal manipulations to attempt to reduce massive breast hypertrophyare ineffective. Medical regimens have included Tamoxifen, progesterone, Bromocriptine, and testosterone.

Loss of weight alone, correlates with reduction in breast size, but does not alter body proportions or breast position and has not been shown to definitively relieve the symptoms of breast hyperplasia.[12]

Breast pedicle reconstructive reduction procedures has been shown to give relief to both functional and aesthetic problems associated with hyperplastic breasts.

Reduction mammoplasty with a pedicled technique aims to create proportionate, projecting breast mounds with minimal scars, whilst retaining normal sensation, erectile function and ideally the ability to breast feed.

The many methods for reduction mammoplasty have evolved in response to a wide spectrum of challenges. Reduction mammaplasty has both a reconstructive, aesthetic as well as a psychologicalcomponent. The main indication for intervention is relief of pain and discomfort in the neck, back, and shoulder. Preoperative patient planning will reveal the most optimal pedicle choice, aiming at the best functional and cosmetic outcome for an individual. Patient satisfaction is usually immense, and most cases show early and favorable improvement. Numerous pedicled techniques exist. (Diagram 1and 2).

Two choices need to be made: a. what skin incision pattern is to be selected? and b. what pedicle to choose to preserve the NAC on?

Usually quadrants other than that of the preserved pedicle, are surgically removed, the breast is shaped and redundant skin is excised. An entire array of approaches and surgical methods have been described to achieve the above-mentioned goals. Out of these, the Wise pattern[18]skin access with inferior pedicle breast reduction has been the most popular choice for reduction mammoplasty in recent years.[19](Diagram 3)

However, the vertical pattern mammoplasty has its advantages and proponents too, due to the works of Lassus[20] Lejour[21] and Hall-Findlay[22] amongst others. Benelli[23]has advocated the circum-areolar access for the operation.

In cases of mild hypertrophy liposuction of the breast achieves significant and adequate size reduction.

The superior pedicles as techniques of BBR, including specifically the SMP, are recognized by many as being technically easier, and capable of resulting in a longer lasting cosmetic effect.[22]Though, traditionally the recommendation held truemainly for relatively small and moderate size BBRs.

Medium and long-term functional and aesthetic results post reduction mammoplasty reflect important parameters for assessing the efficacy of the different surgical techniques. The SMP techniques are reported to be reproducible, easy, and are able to produce a more appealing breast projection in moderate volume breast hypertrophy.[41]They also show reduced pseudoptosisof the inferior mammary pole compared to techniques using inferior pedicles. [24]

Results have not been previously published for the use of the SMP procedure in reduction of large or gigantomastia breasts with elongated NAC to suprasternal notch distances (N-N).

The objective of this study, therefore, was to ascertainthe SMP reduction pattern efficacy in candidates with extremely large breasts, macromastia and gigantomastia and very long N-N distances, above 40cm.

1.1.1 Aetiology of Breast hypertrophy

Hyperplasia or hypertrophy of breast tissue due to the action of estrogen effect on breast tissue and also due to increased receptor sensitivity in breast tissue. The receptors are contained predominantly in the ductal epithelium, collagen and stroma of the breasts may have increased sensitivity to minimal concentrations of the estrogens and progesterone's that regulate breast growth and development. [25]

1.1.1.1 Neonatal hypertrophy

It is a common finding in both male and female sex, characterized by a firm sub-areolar mass palpable in full term infants. It is etiologically related to circulating maternal hormones and also possible increased receptor sensitivity in target tissue of breast. A relationship exists between the presence of subcutaneous breast nodules and the level of gestational maturity. [25]

1.1.1.2 Genetic

The size of women's breasts is determined by several factors, including inherited genes. Some females may be genetically destined to have large breasts. And genetic predisposition may be worsened by an individual's weight gain and or pregnancy.

1.1.1.3 Virginal/ Juvenile mammary hypertrophy

The etiology unknown, a rare condition.

An alarmingly rapid breast enlargement during adolescence. These patients often have a high rate of recurrence rate following any type of surgical mammoplasty procedure to reduce the breasts.

1.1.1.4 Adolescence

Macromastia occurring in puberty is often idiopathic and usually multifactorial, or associated with obesity and hormonal imbalances. Breast cancer in adolescents is very rare and even less frequent in children.

1.1.1.5 Pregnancy and hormonal influences

Gigantomastia and macromastia have been described during pregnancy or weight gain periods, postpartum and middle age, following menopause or with commencement of the use of Hormonal replacement therapy (HRT).

1.1.1.6 Obesity

The American Board reports a 76% increase in BBR surgery over the period 2009-2014.[26]

The advent of ‘junk’ food all over the new world, has given rise toa massive and rapidly growing healthcare challenge,increasingly affecting developing countries. This alarming new trend rampant in South Africa, who now boasts twice the mean world obesity rates, and according to the report has evolved into the world’s third most obese population.[24]Almost two-thirds of the South African nation is obese or overweight and, while in first world countries, the obesity affliction alsoaffects more commonly women compared to males. Alarmingly, 69.3% of femaleSouth Africans show unacceptably large levels of central accumulated adipose tissue, and greater than forty percent are show up as clinically obese, according to their BMI charts. The definition of clinical obesity is a BMI greater than 30.[27]

Plastic surgeons have felt the impact in the form of increasing numbers of patient requesting and general body reduction and contouring procedures, particularly for breasts.

1.1.1.7 Side effect of Protease inhibitors (PI) in HIV patients

In South African in 2013, 6,3 million people are reported to be living with HIV (Human Immunodeficiency Virus), with 42% adults on antiretroviral treatment in 2012-2013. [28]

Fat redistribution and lipoatrophy are the potentially damaging side effects of HAART [29] (Highly Active Anti-Retroviral Therapy).

Abnormal lipid deposition or lipodystrophy, namely fat redistribution and its complicationsthereof have become a burden for HIV infected patients taking HAART medication.[27]

HAART and combination therapy, specificallyHIV-1 protease inhibitors (PIs) have drastically altered and prolonged the survival period of patients infected with HIV. The unfortunate side effects are those of an associated lipodystrophy syndrome.The syndrome is often characterized by selective excess fat deposition, more in some areas and loss of subcutaneous (s.c.) fat in other regions of the body. Lipodystrophy classically displays a central fat accumulation pattern including breast, abdomen, dorsal upper back, (dorsal hump), with simultaneous loss of s.c. fat tissue in other areas, specifically face and limbs.

1.1.1.8 Gigantomastia due to Penicillamine-D

The drug is used in the treatment of various diseases, including Scleroderma. One of the adverse, but rare side effects is breast hypertrophy. The breast enlargement is reversible and regresses when treatment stops. It has been proposed that penicillamine breaks down carrier proteins for estrogen and this results in increased circulating estrogen able to exact a local effect on breast tissue.[30]

1.1.1.9 Cowden Syndrome

Breast hypertrophy often occurs in Cowden's syndrome, which multiple is characterized by multiple hamartomas and neoplasia's.

1.1.1.10Iatrogenic Causes

Include asymmetry due to unilateral benign and malignant mastectomy for breast diseases which can result in breast asymmetry.

1.1.2 Incidence

The American Board of Plastic surgeons [31] record breast reduction surgery as the 8th most common cosmetic procedure in 2013. They performed a total of 103 775 breast reductions in 2013.

1.1.3 Indications for Choosing a pedicled BBR for Macromastia/Gigantomastia

Reduction mammoplasty procedures are undertaken in a female who had the above describedmain complaints, and were free of surgical contra-indications, viz. uncontrolled comorbidities, large trauma to the breast, back or neck, or a history of improvement of breast hypertrophy with a simple body weight loss program. Reliefof some of their symptoms, by manually elevating the breast weight off the chest wall, suggests a successful outcome if surgical reduction is undertaken. In addition, a history of breathing more comfortably upon standing from supine lying, support the diagnosis of symptomatic macromastia.

1.1.4 Objective

Surgical approach to Macromastia and Gigantomastia has historically been with breast amputation and free grafting of the NAC. This method, while for many represents an option in cases of excessively large breasts has, as mentioned, many disadvantages. Breast amputationspre-operative skin markings, illustrated in Diag. 10, uses the inverted t-technique, (described in 2.2 below).However instead of the wise-keyhole pattern it uses two diverging arms are drawn from the selected nipple point at an angle of 90 degrees, and vertical limb length is measured and designed to an average of 8cm height.

Indicated for women with gigantomastia, ≥ 2500g per side and or patients with complicating factors like increased age, or co-morbid illness where shorter operating times and low blood loss is required. [32]

Some authors prefer breast amputation with a free nipple transfer when the NAC elevation is > 15cm. [32]

Total breast amputation, markings illustrated in Diag. 10, uses the inverted t-technique, instead of the wise-keyhole pattern shown in Diagram 4. Two diverging arms are drawn from the selected nipple point at an angle of 90 degrees, limb length is measured to an average of 8cm.

A number of surgical methods to reduce large breasts have been successfully used. The optimal choice of operation for excessively large breasts, however, remains controversial amongst surgeons.[10]

The primary objective of BBR surgery are to reduce breast size and volume, while still maintaining viability of the NAC and the breast skin flaps.[5] It is vital to maintain the sensation of the NAC, and maintain its normal pigmentation, and to simultaneously produce a symmetrical, conical breast shape.[6]

The larger the breast dimensions, the more difficult it is to safely achieve these objectives.

Of primary importance in achieving these objectives is the meticulous preservation of the relevant neuro-vascular supply to the NAC and breast skin flaps.

'A constant battle between blood supply and tissue preservation' is how Ralph Gilles described the quest of Plastic surgery.[7]Reducing very large breasts is a fine balance between excision of a large amount ofparenchymal tissue and skin, while still retaining functional viability of the tissue left behind.

The SMP technique was initially described by Orlando & Guthrie in 1975 for small and medium sized breast reductions [11] Reduction sizedefined as mild >300 g resection, to the moderate = 300–800 g to the severe >800 g resection.

This technique was, in this study, applied to Macromastia and Gigantomastia breast, specifically those breasts with large excision weights and very long nipple to notch distances (N-N). Outcomes were measured in terms of post-operative preservation of NAC and breast skin flaps, sensation, shape, symmetry and projection.

1.1.5 Background

1.1.5.1 Concepts in Perforator Anatomy and Blood supply

a) Arterial Perforators

The arterial perforator supply of the female mammary gland is predominantly from the internal mammary artery perforators, 48,8%, 24,4% via the anterior IC perforators, 23.2% via the lateral thoracic perforators, in 2.4% the NAC is supplied by the Axillary artery branches.[33]

Taylor and Corduff[34]found thatthe perforator blood entering the mammary glandsdo so at a superficial level. Main source artery perforators enter the subcutaneous tissue,into the mammary gland and subsequently turn downwards to penetrate into the parenchyma. These originate from theInternal mammary/Internal thoracicnetwork,[34] together with the perforators from the lateral thoracic arteryand the thoraco-acromial network. A single perforator emanating from the internal thoracic artery gives off one branch, consistently from the second or third intercostal space (ICS) and turns inferiorly and obliquelyto approach the NAC. [34]It is most commonly present at the breast meridian just beneath the skin at about 1 cm deep. This vessel supplies directly the superior and superomedial breast pedicles.[34]

The viability of the NAC is maintained by preserving the microvascular integrity of the underlying dermo-glandular layer of the NAC. The surgical preservation of the dominant pedicle perforators from both the 2nd and 3rd interspaces includes a dual

axial supply to the SMP. A full thickness pedicle is maintained and incorporated into the superior and medial quadrants and a limited medial undermining is performed. Meticulous handling of the superficial tissue improves NAC preservation on a long pedicle. The pedicle is rotated laterally and outward, and then upward.

SMP demonstrates its versatility by incorporating a broad base superiorly as well as from the medial quadrant. The dual blood supply of the flap would hence allow the gigantomastic breast to be safely manipulated.

Post-operative NAC survival correlates directly with the patency of the blood supply of the distal most tip of the SMP, viz. the furthest point from the arterial source supply.

b) Venous Drainage

Usually veins accompany arteries and their perforators. However, those supplying the pectoralis muscle, which provide the perforators to the inferior breast pedicle do not all consistently have an accompanying vein.[33]The veins form a superficial, concentrated venous plexus in the the skin surface and the areola. Significant damage to this venous system occurs if deep circumferential incisions are placed in the areola.[35]

Breast pedicle designs,such as an elongated superior pedicle, which may requirefolding of the pedicle risks viabilityof its venous return. Pressure of the arterial inflow may be sufficient to overcome the folded pedicle; however, return of venous flow would suffer from the compression pressure of folding. A good practice may be to preoperatively mark the veins and attempt to incorporate some of themin the pedicle design. This maysecurethe venous drainage of the flap.

1.1.5.2 Preserving Breast Sensation

The primary objective in surgical practice has focused on preservingblood supply and thereby viability of tissue. However, additionally it involves preserving also function and sensation of the breast. The NAC serves as aregion of concentrated nerve supply, the sensory unit of the breast. Its preservation is an important indicator of surgical efficacy.It is a valuable part of women's psychology and body health image, making preservation of nipple sensation of the utmost importance.

Jaspers [36] studied the superficial innervation of the female mammary gland, and demonstrated its medialderivation from the 1st-4th intercostal nerves (ICN), anterior branches, the lateral derivation of the lateral cutaneous portions of the second to the seventh ICN. The NAC is predominantly, and uniformly, supplied via the lateral and anterior branches of the 4th intercostal nerve, which runs cutaneous.The superficial branches of the 3rd and 4th ICNs provide additional cutaneous supply. [36]This study illustrated the consistent and equivalent dual supply of the lateral and anterior

cutaneous portions derived from ICNs. Recommendations thereof, in order to avert disruption to bothlateral and anteriorcutaneous portions of ICNs, 3, 4 and 5, one should pay attention to these during surgical dissection. Specific attention is given to the 4th ICN which is the dominant nerve to the NAC.[36]

Riccio [37] proposed abreast zone where it is 'unsafe' to dissect during reduction mammoplasty and it should to be avoided to preserve nipple sensation.

The major innervation to the NAC is provided by the fourth ICN.[37]Dissection should be avoided in the inferolateral breast quadrant or "unsafe zone", during breast surgical procedures including reduction mammoplasty, toreliably spare nipple sensation and maximize patient outcomes.[37]

Theinitial doubt regarding the lateral cutaneous portion of the 4th ICN,as the predominant sensory supply tothe NAC,has been clarified. Itas the most commonnerve to provide sensation to the NAC. What is however poorly understood, is the detailed anatomical structure of that innervation. [38]A primary branch of the 4th ICN travels superficially, it is demonstratedto be an important nerve which runsinitially on the fascia of the pectoralis muscle, then takes a nearly90-degree rotation at the breast meridian and then runs downward in a vertical fashion from the posterior surface of the breast, to approach the NAC. [38]This considered,it would be prudent to leave a lean fatty layer of tissue above the fascia of the pectoralis muscle when dissecting any full-thickness pedicle, so as to maintain the sensibility to the NAC.

The fourth ICN gives off a lateral cutaneous branch which is additionally supplied by other lesser branches. The branches from the anterior cutaneous nerveinitially runs a superficial course and terminates medially to the NAC border. In this instancein order to maintain the sensibility of the NAC, a pedicle based in the medial quadrant would thus not be required to be a full thickness flap.

A smaller and much less important contribution to sensation is made by small supraclavicular nerves branches.

Gigantomastia and Macromastia patients may experience changes in sensation as the breast size grows and expands.[38] The postulated cause was thought to be aweight traction- pulling force damage to the sensory branches, or the resultant diminished density of nerve fibers, however both these were refuted in a paper by Greuse in 2004. [38]

A dual hypothesiswas considered by Godwin. [39]Firstly, the diminished sensibility could result from sensory nerve fiber neuropraxia, consequential to a traction-pulldue to the heavy, pendulous breast parenchymal weight. Thesecond hypothesis thereafter postulated that the NAC widened by tissue expansion due to the large volume of

mammary tissue resulting in a correlated diminished concentrationof sensory fibers per surface area and thus diminished overall sensation.

The nipple and areola are not similarin their nerve supply. The areola is a, pliable thin structure which lends itself to easy traction as the mammary gland expands and thus experiences a simultaneous reduction in sensory fiber concentration. [39]5[]The nipple isless able to stretch and widen with mammary hyperplasia, it is also a tighter, more compact structure. The nippledemonstrates neither changes of sensory perception nor an alteration of fiber concentration with gland ptosis or an expanding mammary size. They showedthat neither the theory oftraction-pull damage to the fibers of sensation, or thediminished fiber concentration, individually can fully account for the perceived breast loss of sensation noted by individuals with breast hypertrophy. [39]They instead postulated that subjective numbness perceived by patients was multifactorial, and importantly, included dissatisfaction with body habitus and patient interpretation of loss of areola sensation as also affecting the nipple. It is this may affect their overall perception of NAC sensation.

Le Roux [40] used CT analysis to radiographically demonstrated nerves in a superomedial breast specimen that have been defined with fine mapping wires. The nerves supplying the NAC become superficial at a length just greater than 3cm from the NAC and at a depth of 2mm. The nerves arise deep and become superficial to traverse in a plane just below the dermis. The design of the SMP is most likely to capture the anterior intercostal nerves 2 to 5 to the medial breast, branches 4 and 5 supply the NAC. Hence the superficial breast tissue must be preserved to enhance capture of this nerve supply network.

CHAPTER 2 - PATIENTS & METHODS

2.1 Patient Selection

The study was a retrospective record review of patients who had macromastia and gigantomastia, andhad undergone a SMP technique ofbreast reduction surgery, performed at the Rand Clinic and Chris Hani, Baragwaneth hospitals between 2008 and 2012.

Inclusion criteria were healthy females, aged between19 and 59 years, with no previous breast surgery, BMI ≤ 31 kg, and non-smokers. Other inclusion criteria required a breast resection weight of greater than 1500g per breast, and a N-N distance of greater than 40 cm.Women with poorly controlled co-morbid illnesses were excluded. Patients were allocated study numbers, instead of names or hospital numbers, to protect their identity. Photographs were taken without facial view. Procedures were performed at the Rand Clinic and Chris Hani, Baragwaneth hospitals, Johannesburg, over a four-year period, 2008-2012.

2 surgeons performed all procedures. Approval was obtained from the Human Research Ethics committee, Medical University of the Witwatersrand.

(Clearance certificate number: M130236).

According to protocol, data was collected retrospectively, bilateral breast reduction (BBR) patients with Macromastia and Gigantomastia size breasts, who had undergone a superomedial pedicle (SMP) pattern reduction mammoplasty were collected and data collated. The objective was to show the efficacy of the SMP for the safe surgical reduction mammoplasty of excessively large breasts. Patient records were evaluated.

The cohort selected were women presenting with macromastia and gigantomastia, large, pendulous breasts with varying complaints of headache, back, neck, shoulder and upper thoracic pain and discomfort, including inflammatory skin problems, difficulty exercising,psychological manifestations and loss of self-esteem due to their large breast size.

Inclusion criteria were healthy females, with age ranging from 19-59 years. BMI ≤ 31, non-smokers. Specifically, those with breast resection weights > 1500g per breast, and nipple to suprasternal notch distance (N-N) > 40 cm. Exclusion criteria were women with BMI≥32 or greater, smokers and poorly controlled co-morbid illnesses. Major trauma to back, neck or chest were also excluded.

2.2 Surgical Approach

The pre-operative patient assessment followed routine guidelines for standard BBR patient preparation.[5]

2.2.1 Skin Markings (figure 1)

The patient is marked in the standard manner for BBR with SMP and Wise pattern skinclosure.[5]For excessively large breasts special attention is given to mark the candidate in an upright position.

- The patients were marked in the standing position
- The new NACheight is marked on the breast meridian.
- A deliberate decision was taken to err on marking the new NAC site lower, rather than too high. The NAC was marked at a slightly lowaverage height, of 23-24cm.

2.2.2 Operative technique

2.2.2.1 Areolar Opening

A key-hole template design was used. The opening for the areola was designed at the top of a key-hole pattern at the initial preoperative marking stage. First the new NAC level is determined by a combination of placing the top of the NAC at the anterior projection of the IMF and diagonal height from the suprasternal notch The template design results in a circle when it is completed, with a pre-measured circumference of 16 to 18 cm. A 16cm keyhole circumference delivers a 5cm NACdiameter. (see Diagram 4: White circle, 1b).

A circumference greater than 20 cm will result inenlargement of the areolar diameter widening of the scar at the circumference.

The pedicle is, full thickness, based superomedially and reaches the chest wall meridian. The flap base is fashioned in such a way that that fifty percent of the base is in the window opening of the NAC and other fifty percent runs alongside the skin vertical resection line of the inverted T pattern. This assists with ease of inset. It fashions a good superomedial pillar. Keep the base as wide as possible in the superomedial quadrant, so as to capture more blood supply while still making allowance for the pedicle to rotate away from the midline into the top of the keyhole of the Wise pattern. Avoid torsion.It is wise to delineate the superficial veins initially, if possible, such that the design of the pedicle would include superficial venous drainage.

2.2.2.2 The Breast Pedicle

The superomedial pedicle is designed and planned as a full-thickness pedicle.

De-epithelializationis performed while leaving a bordercircumferentiallyaround the areolar edge.

The superomedial based pedicle is dissected, descending to the level of the chest wall bycutting cautery or scalpel. The flap is beveled at its superior margin so as to leave a wide stage ofsupport for the NAC. A larger, fuller pedicle will not assist in delivering a full upper pole, instead, it may make it more difficult to inset. It is however prudent not to excisetoo much of the parenchyma superiorly, except cases where the upper pole isexcessively full.

2.2.2.3 Excision of Excess Breast Parenchyma

The Wise pattern marking guidesthe skin as well as the parenchymal resections. The tissue is undermined from the IMF upward. Parenchymal resections are done inferiorly. The lower, horizontal ellipse of breast tissue is removed by beveling outwards beneath the skin laterally and mediallyand undermining down to the fascia of the pectoralis muscle,extending down to theIMF.

Inferiorly, vertical and horizontal ellipses of parenchymal tissue are removed en-bloc. Of importance to note in this method, is to limit the extent by which the the skin is undermined from the underlying breast parenchyma in both the medial and lateral vertical pillars, keep the pedicle base broad in the superomedial quadrant. It is crucial to leave a thin to moderately thicknessfatty layer of tissue beneath the undersurface of the dermis i.e. approximately 1-2 cm. Breast tissue resection is removed, beveling outward extensively on both the lateral and medial side to a lesser extent. Specifically, the lateral breast pillar is thinned out, while the medial pillar is kept comparatively full. The NAC is preserved and the parenchyma under the dermis is maintained at a minimum of 2 cm thickness.

The lateral and medial pillars should measure 6-7 cm in length, according to the objectively planned final breast shape and volume. Vertical pillar sutures are used to provide additional shaping of the breast.

The IMF usually rises 1-2cm post-operatively, compared to its original position, especially laterally. The parenchymal tissue along the IMF therefore needs to be excised directly intraoperatively, and especially just lateral to the meridian parenchymal tissue must be adequately removed. Leaving too much subcutaneous fat here will contribute to puckering.It must be noted that puckering postoperatively is rather a challenge of too much tissue subcutaneously, rather thantoo much skin.

If the deeper subcutaneous tissue layer is not removed in the inferior pole, a pucker will persist. The superficial tissue is preserved.The skin is excised according tothe Wise keyhole design guideline.

2.2.2.4 TheSuperomedial Breast Pedicle Inset

Pedicle rotation occurs laterally and outwards and hence easily reaches into the top of the keyhole without kinking or compression. The inferior border of the superomedial pedicle rotated upwards and outwards then becomes the medial pillar border.

The new NAC is preserved on a dermo-glandular pedicle based superior and medially.

Closure of the new areolar circumference is performedusing a Monocryl 3/0, which is buried. It is unnecessary to undermine the dermal layer at the base of the pedicle at closure. The flapis timeously turned into a superior position once the areolar circumference is closed inferiorly.Before final in setting of the NAC, the pillars are closed

2.2.2.5 Pillar Closure

Bothvertical pillars are designed at 6-8 cm. From the left and right side of the breast these pillars are pulled towards the center vertical midline of the breast, with pillar sutures. They are so used to provide additional shaping of the breast. Sutures are inserted intermittentlyalong the vertical length of the opening. The pillars are closed with Monocryl3/0, suturewhich is placed into the fibrous subcutaneous part of the breast parenchyma.

Pillar suturing is started from inferior to superior once the vertical pillars are brought together. The new central vertical line will form the perpendicular limb of the final inverted T-scar on the reduced breast.The first suture rotatesthe pedicle into position, by taking it from its inferior position and placing it into the top of the key-hole.It is unnecessary to put the deep tissues under tension, theinitial pillar suture, placed at the base, is fairly superficial.

2.2.2.6 Closure of the Keyhole Incision

The skin envelope will dictate the breast shape. Monocryl 3/0,buried and interrupted, is used to approximate the deep dermis. It permits skin adaptation to the new shape rather than attempt to deal with the pucker by suturing it down to the chest wall. The possibilityof suturing the pucker first time into the right position is low, and hence it will take months to smooth out. Meticulous hemostasis reduces the chances of hematoma, one of the main causes of delayed wound healing. The final, detailed shaping is performed in a curvilinear manner to fashion like a curve on a spherical surface. The skin envelope was closed in the regular inverted T- pattern.

Monocryl 3/0, interrupted, buried sutures are inserted into the deep dermis to ensure that the vertical limb closes in the line of the meridian.

A subcuticular Monocryl 4/0, suture is used to achieve the final skin closure. Suture bites that are too deep will gather the skin too tightly. The surgeon must be aware of delayed skin edge healing when large bites are taken, it can result due to blood vessel constriction.

The skin is closed along the inverted T with a 3–0 Monocryl, subcuticular.

While gathered skin or puckering laterally will stretch out with time to some degree, cheat away dog ears from lateral to medial as they have a tendency to gather laterally. Tension is avoided during closure.

Postoperative dressings to support the breast are essential, with a window facility to inspect the nipple and areola complex, without opening the dressing. Additional post-operative care is as for routine post BBR care. A snugly fitting bra is worn immediately post operatively and the patient is advised to continue to do so for a period of 3 months.

2.2.2.7 Methods of testing of NACs' sensory competence.

The NAC sensation was crudely tested by means of a cotton bud stroked in each of 5 quadrants, Diagram 10.

Patient was asked to close their eyes and then respond by 'yes' or 'no' to being stroked lightly, by the examiner each of the 5 quadrants of the NAC.

The test was performed once pre-operatively, and then at first dressing change on approximately day 5, at 6 weeks, then on average of 1 year later at their last and final consultation

2.2.2.8 Methods of assessing post-operative aesthetic outcome

The aesthetic outcome of the breast was sub-divided into shape, symmetry, projection and scar formation.The allocation of 'poor', 'fair', 'good' and 'excellent' was purely the opinion of 4 specialists involved in breast surgery. They were shown anterior and lateral views photographs, taken at approximately 1 year post-operatively. They were asked to look at symmetry, projection, shape and scar formation and then categorize each patient outcome.

3.1 Table 1: Patient data

Age	BMI	Right Nipple to notch	Left Nipple to notch	Right Nipple to *IMF	Left Nipple to IMF	Right Weight of breast tissue removed	Left Weight of breast tissue removed	UpwardmovementNAC: Right	Upward movement of NAC:Left
36	29	49,0	48,0	23,0	22,0	1750	1720	26,0	23,0
38	27	44,0	43,0	19,0	19,5	1650	1795	21,0	20,0
35	28	42,8	43,8	18,0	18,0	1620	1659	20,8	21,8
25	29	42,5	42,9	20,0	20,5	1800	1890	20,5	20,9
28	30	46,0	45,0	20,0	19,5	1670	1790	23,0	22,0
35	27	39,0	39,0	17,0	18,0	1600	1600	18,0	18,0
31	28	40,5	41,0	17,0	17,5	1800	1800	19,5	20,0
20	27	43,7	43,8	20,5	22,0	1950	1990	20,7	20,8
39	35	41,0	41,5	18,0	18,0	1790	1700	19,0	19,5
32	29	40,8	42,5	23,0	25,0	1600	1700	18,8	20,5
54	26	41,0	42,0	23,0	24,0	1820	1850	19,0	20,0
20	27	47,0	48,0	21,0	21,0	1680	1410	24,0	25,0
42	31	48,0	49,0	27,0	28,0	2670	2720	25,0	26,0
29	30	45,0	46,0	24,0	23,0	2333	2200	22,0	23,0
20	27	43,8	43,0	17,0	18,0	2200	2100	22,8	20,0
32	29	41,0	42,0	21,0	21,0	1900	1800	18,0	19,0
37	25	46,0	46,0	28,0	28,0	1700	1800	24,0	24,0
46	30	38,0	40,0	22,0	23,0	1850	1700	16,0	18,0
26	32	46,0	46,5	25,0	26,0	1700	1700	24,0	24,5
28	29	46,0	47,0	23,0	23,0	1400	1380	23,0	24,0
26	26	49,0	49,0	28,0	28,0	1260	1260	26,0	26,0
24	31	42,0	43,0	24,0	24,0	1310	1330	19,0	20,0
42	29	47,0	47,0	21,0	22,0	1600	1640	24,0	24,0
23	32	49,5	49,0	25,0	25,0	2190	2100	26,5	26,0
19	24	43,0	44,0	23,0	24,0	1750	1650	20,0	21,0
18	25	45,0	44,0	22,0	22,5	1850	1900	22,0	21,0
21	28	46,0	46,5	24,0	25,0	2100	2130	24,0	24,5
20	27	47,0	48,0	28,0	29,0	1990	1800	24,0	25,0
18	26	46,0	44,0	25,0	24,0	2200	2100	23,0	21,0
21	25	47,0	47,5	26,0	27,0	2300	2370	24,0	24,5
49	24	44,0	44,0	23,0	23,5	2095	2100	21,0	21,0

3.2 Table2:Complications

Early and late, experienced by women after SMP breast reduction surgery

	Adverse event	%Right breast (n=31)	%Left breast (n=31)	Mean %	Total number of women affected
Early (Day 0-21)	**Superficial NAC necrosis(≤15%)**	13	10	11,5	11
	Superficial NAC necrosis (>15%)	0	0	0	0
	Complete NAC necrosis	0	0	0	0
	T-Junction wound breakdown	19,4	29	24,2	8
	Fat Necrosis	6,45	6,45	6,45	4
	Decreased/ loss of NAC sensation	29	25,8	27,4	
Late (mean time = 1 year)	**Absent sensation of NAC**	3,2	6,45	4,8	3
	Decreased sensation of NAC	19,4	13,5	16,4	
	Loss of NAC (partial or complete necrosis)	0	0	0	0
	Hypopigmentation	12,9	19,4	16,1	6
	Hyperpigmentation	0	0	0	0

3.3 Table 3: Quadrant division of NAC Light Touch Sensation change at 1 year

5 Quadrants: Upper, lower, central (nipple)

Right	% Absent	% Decr.	% Same
Nipple	3,2	19,4	77,4
Right upper	3,2	19,4	77,4
Right lower	3,2	19,4	77,4
Left lower	3,2	19,4	77,4
Left upper	3,2	19,4	77,4

Left	% Absent	% Decr.	% Same
Nipple	6,45	16,1	77,4
Left upper	6,45	12,9	80,6
Left lower	6,45	12,9	80,6
Right lower	6,45	12,9	80,6
Right upper	6,45	12,9	80,6

*1 patient had increased sensation continued until week 6

3.4 Table 4: Breast Aesthetics after 1 year

(Mean Good=26,75, Poor = 4,25)

	Projection	Symmetry	Shape	Scar formation
Poor	0	0	0	0
Fair	8	2	2	5
Good	23	29	29	26
Excellent	0	0	0	0

*** Independent Panel: shown final photographs of patients taken 1 year post-operative:D. Marchac (2012, Plastic surgeon, Private Practice), Dr. EA.Arnaud, Hospital Necker Enfant Malades, Plastic surgeon), Dr.C. BeckerSurgeon, Hospital Americaine, Dr. L. Lepage, Anesthetist, Clinique Turin,Paris.*

3.5 Results Analysis

There were 31 patients who met the inclusion criteria for macromastia and gigantomastia breasts which had been surgically reduced by the SMP pattern. All procedures went well and all patients were discharged 1-2 days' post operatively.

The mean(SD) age of the cohort was 29.3(9.27) years and a mean(SD) BMI of 28.1(2.5) kg. The mean(SD) weight removed from the right breasts was 1842 (0.31) g and from the left breasts was 1828(0.31) g. There was no significant difference in weight removed between the right and left breasts (p=0.4216, paired t-test).

The mean(SD) nipple to notch length (N-N) was 44.7(19.2)cm for the right breast and 44.8(20.1) cm for the left breasts with no significant difference (p=0.0707 paired t-test) between the right and left breasts The mean(SD) elevation distance of the nipple areola complex, (NAC), was 22.4(3.3) cm for the right breast and 22.8(3.3) cm for the left breast. The elevation distance for the left breasts was significantly longer than the right side (p=0.0023 paired t-test).

Complications were minor and self-limiting (table 2). All patients showed preserved NAC viability post operatively. (Diagram 6 & 7) There were no patients with superficial necrosis greater than 15% of the NAC surface area. In a quarter of patients there were limited areas of wound breakdown occurred over the T-junction during the first weeks. They were managed conservatively with wound dressings and prophylactic antibacterial gel. None required surgical intervention. Fat necrosiswas clinically diagnosed in 4 breasts, during the postoperative periods not associated with skin necrosis. Patients complained of pain and redness of breast, no nipple discharge. Sonar examination confirmed small lumps (<4 cm) in unilateral breast. They were treated conservatively; surgery was not deemed necessary. No infections were recorded. One patient had an allergic reaction to the dressing tape.

Final NAC sensation was tested at a mean time of one year.95,2 % of NAC maintained sensation post operatively. Of these 14,5 % experienced a decrease. 4,8 % lost NAC sensation altogether as a result of surgery, (Table 3). The median extent of NAC hypopigmentation was 20%. No problems of NAC hyperpigmentation were recorded.(Table 2)

There was no significant difference over time in sensation changes for the right breast (p=0.1063) but a significant reduction for the left breast over the same period of time (p=0.0159 both Fishers Exact test)In terms of final outcome of contour and aesthetics,

at 1 year, patients were independently judged[(1)]to have a good outcome, 74.2% good projection, 93,5% had good symmetry and 93,5%, had good shape (93.5%) and 83.8% of patients were judged to have a good scar formation. The rest of the patients had a fair result for these parameters, while no patients were judged as poor. (Table 4)

(1) 2 independent Plastic surgeons, 1 Breast surgeon, 1 Anesthetist.

4.1 NAC Placing

Thenew NAC level on the breast, should be set over the of the chest-wall meridian or thebreast meridian itself. If the lineis drawn through the existing NAC position, the current study found that this can be ambiguous due to fact that the NAC may be placed either too lateralor too medial,and hence it is more accurate to use the meridian.

The chest midline is marked on the IMF line by placing a tape measure beneath the breasts of the patient, in the IMF. The top of the new NAC is positioned at the IMF level,projected anteriorly to the breast surface.Creating a cone shape of the breast as well as sliding the NAC superiorly, is achieved by suturing of thelateral and medial pillars converging centrally.

The IMF may rise postoperatively with this technique; hence the surgeon must avoid designing the patients' new NAC too far up,especially in candidates with an IMFnaturally very inferior. Higher NAC placement maybe appropriate in breasts with a substantial upper pole fullness,however, this is unlikely in the macromastia or gigantomastia breast. The NAC placed on the concave slope of the upper quadrant of the gigantomastic breast will ultimately result in a postoperative NAC position that will ride too high on the breast and or point skyward.

Due to the pull of the various vectors on the NAC, it is more appropriate toposition the new NAC at a slightly lower level on the larger breast and so avoid the possibility of what is commonly referred to as the 'high riding nipple'.

The surgeon should avoid marking the new nipple position lower, rather than too high. The current study marked the new nipple a slightly lower mean height, of 23cm in this cohort.

4.2 Skin Resection Pattern

The skin envelope shapes the breast,though it is prudent not to remove too much skin. The actual design of the pedicle pattern and soft tissue resection is important in the approach to the skin resection. To locate the vertical center of the lower pole, the method of turning the mammary gland upward and inward which allows meridian location on one side,followed by upward and outward to allowmeridian location on the other side, is used.Centrally these vertices make up the perpendicular limb of an 'inverted T' scar. The horizontal limbs of the Inverted-T extend laterally and medially in the IMF.

4.3 SMP pattern design

Designed full thickness in the superomedial quadrant, the pedicle descendsto the meridian of the chest. As described, when the pedicle base is constructed, fifty percent of the vertical width is designed along the the line of vertical resection of the Inverted-T-pattern,while the other fifty percent of the base of the vertical flap lies in the NAC window. This assists with ease of insetting of the pedicle.It creates a fuller superomedial pillar. As the base is kept as wide as possible, it captures more perforator supply. The importance of noting and even marking the superficial veins during the initial marking stage,cannot be understated, as it ensures that the SMP is fashioned to capture some venous drainage superficially.

The decision of the width of the the base of pedicle must be done astutely, about a two: oneratio for pedicle length to pedicle width is recommended, though not always physically possible. The base in the superomedial quadrant is kept as wide as possible, while still making allowance for the pedicle to rotate away from the midline, into the top of the keyhole This will also allow more arterial capture and include more venous drainage. However, too broad a base may make it difficult to rotate the pedicle inward without torsion. The extra tissue from the base forms a round surface platform to support the NAC, and helps prevent it from sinking inwards postoperatively. Though, pushing too much tissue up into the upper quadrant does not necessarily give more upper pole fullness, but may instead may result in a drop down and pseudo ptosis. An excess parenchyma in the upper pole will hamper ease of pedicle insertion into its keyhole.

4.4 The Breast Pedicle

The pectoralis fascia is not incised into despite the resection reaching down to the chest wall, the overlying muscle fascia is unveiled andcareful attention is paid to preserving it.Failure to do so results in unnecessary intraoperative bleeding and postoperative pain, and may results in an increased risk of sensation loss. Gently remove tissue from the deep surface. The NAC is preserved and the parenchyma under the dermis is maintained at a minimum of 2 cm thickness. Preserve the superficial tissue.

The superomedial region provides not only the arterial supply to the SMP, but additionally, the fullness that prevents the NAC, and especially the areola from sinking inward. Tissue excision just lateral to the meridian is performed. With a long pedicle there is less danger of tension but, beware, the superomedial pedicle is floppy due to its length and it can easily be inadvertently undermined.

4.5 Drains and Antibiotics

Intravenous antibiotics are started at anesthetic induction and continued until drain removal. Drains can be taken out on the 1st post-operative day usually. Wound taping is performed for wound support. A snugly fitting bra is worn immediately post operatively as described above. With no scientific merit in prolonged antibiotic treatment, these can be withdrawn after 5-7 days.

4.6 Tape, Bandages, and Compression

Postoperative dressings to support the breast are essential. A window facility can be created to inspect the nipple and areola without opening the entire dressing. 'Steri-strips' are used to dress the incision lines. Firm 'Primapore'and or taping over the inferior area of the breast inferiorly provides light wound compression. Excess compressionhowever, must be avoided.

4.7 Exploring Concepts

4.7.1 Tissue Parenchymal Pattern Versus Skin Resection Pattern

Breast reduction, it is divided into 2 parts, a. the skin resection pattern viz. either wise keyhole (Inverted-T scar), lateral, vertical or circum-areolar skin patterns are used, and b. the pedicle design, viz. superior, inferior, lateral, medial or central. A third option would be breast amputation with free nipple grafts. Many combinations of the first 2 are possible.

4.7.2 Parenchymal Shaping Versus Skin Brassiere

This type of breast reduction technique relies mainly on an envelope formed by the skin,which act as a brassiere to maintain breast shape and support.

There controversy relating to the effectiveness of using the envelope formed by the skinto maintain the postoperative breast contour, is long standing.[41]Genetics and lifestyle dictate how much skin and dermis will stretch over a duration of time.These factors with the addition of gravity almost ensure that the'Inverted-T' tends to fall downwards, to a greater extentversus bottoming out in the 'vertical skin' pattern, over time. Generally, a 5cm rule for the vertical limb length has been recommended to prevent bottoming out. It remains controversial as to whether it is it a valid recommendation or if it comparatively just flattens the mound of the mammary gland and pulls it below the initial IMF height? [41]

The current studyelected to keep the vertical limb pillars at an average of 6-8cm, so as to allow adequate space in the lower pole to accommodate a larger amount of breast tissue.

4.7.3 What role does the parenchymal resection play?

Deciding which pedicle drops out comparatively more is debatable. When fashioning the medial pedicle, the parenchymal tissue in the inferior regions is excised laterally and medially. When the inferior pedicle is used, the surrounding parenchyma is removed, i.e.the superior, tissue in the lateral and medial superior regions of mammary glands parenchyma is removed. [42] Does the inferior pedicle drop out more because its weight and position are more subject to gravity?

4.7.4 Do Breast Sutures to pectoralis fascia work?

Sutures placed from breast to breast parenchymal tissuehold to some degree, but there is no evidence to show long term suture capacity to hold between breast tissue onthe fascia of the pectoralis fascia, these stitchesdon't seem to hold promise.[43]As pectoralis fascia is thin and slippery, it will only provide a temporary increase of fullness in upper pole. Constriction of the tissue should be prevented by taking smaller bites in the fibrous subcutaneous tissue, which is maintained. Fat to fat placement of sutures arealso ineffective.

4.7.5 Liposuction for fine contouring

Liposuction is often recommended for final symmetry of shapeof the breast once the reduction mammoplasty is completed. Common areas of small excess or irregularity, often in the pre-axilla area and along the IMF and the chest wall laterally, are dealt with.It is often effective for the final tailoring. Liposuction was not, however, used as an adjunct in this cohort.

4.8 Anticipation of Complications

The most frequent complication is delayed wound healing.[44]Complications must be anticipated in reduction mammoplasty; percentages are reported to be as high as 53%. [45] (Diagram 10)

The chance of a complication increases as the quantity of resection increases. Of these, hematoma, fat necrosis, nipple necrosis, cellulitis and fungal dermatitis have been reported. Makki reported probably the highestpercentage in a large series of women dissatisfied with their reduction mammoplasty surgery.[46] This study investigated long-term results, morbidity, and patient satisfaction after reduction mammoplasty. A comprehensive questionnaire was sent to 296 patients who underwent reduction mammoplasty The response rate to the questionnaire was 55.4%. An average of 1,037 g of tissue was resected per breast. Seventy-eight percent of respondents listed the relief of physical symptoms of large breasts as their primary motivation for surgery. Ninety-one percent of subjects realized improvement of symptoms and 65% were asymptomatic. The overall

satisfaction rate was 67.6%, whereas 18.4% were dissatisfied and 14% were unsure. Minor complications that did not require further surgery were reported by 29% of subjects. Twenty-seven percent of respondents would have preferred to have more preoperative discussions with the surgeon, and 78% of subjects would recommend breast reduction to others.

Appearance of scars and asymmetry can also be causes for complaints.[47]

Despite the high percentage of complications, [48] most patients accept and recommend the procedure.[49]

Generally, the amount of breast tissue removed correlates directly with increased risk in poor wound healing. However, it is not clearlyestablished,that women having a higher BMI,have a greater chance of complications from breast reduction surgery specifically.[4]

In general, surgical patients with high BMI, undergoing large or more complex procedures, antibiotic coverage is recommended for at least 5 days may be useful to prevent delayed wound healing and dehiscence.[**Error! Bookmark not defined.**][50]

4.8.1 Nipple-areola malposition

Minor asymmetry of position, i.e. a difference of about a centimeter can be managed with a crescent excision on the desired border of the areola. [5]

Major asymmetry requires circumferential release of the NAC. An NAC which is set too high is a complexdefect to reset. Whilst an NAC set too low may be corrected by crescentic excisions superiorly.

Often criticism of BBR has been the long term “bottoming out” and shape loss due to gravity’seffect on the weight of the breast. The genetic and the individual’s exposure to various environmental factors,result in the invariable stretch of the skin envelope, hence splaying of the breast scars.

There is no consensus on pre-emptive methods to prevent pseudoptosis or “bottoming out”, without impairing the cosmetic outcome. The inferior pole envelop enlarges with time, subject to factors already mentioned.

Hall Findley described her discontent with the long-term results of the inferior pedicletechnique ,with a vertical pattern scar breast reduction, due to its difficulty to maintain long term breast shape and projection.[51]

Unlike the inferior pedicle pattern, where the weight of the flaplower down pulls with a greater gravitational force, sinking the breast inferiorly, the location of the SMP allows instead a molding in the upper inner quadrant and is situated more superiorly

in the breast. It gives an improved medial fullness, higher up, which amplifiesthe shapeand projection of the breast.

Wound hypertrophy in the perpendicular limb of the inverted T-scar was common after reduction surgery. Up to 15% of all scars are reported to be thick, itchy or uncomfortable.[3]In this study pressure taping of the scars was used for several weeks and a snug fitting bra worn immediately post operatively for an intermediate period to give improved wound support.

4.8.2 Breast shape improvement using the medial pedicle,with the wise pattern skin resection

A great variety of challenges in breast reduction surgery have resulted in an evolution of techniques for breast reduction.

A range of of anatomic deformities in gigantomastia and macromastia breasts were considered, which influencedatailored andindividualizedsurgical approach.Abramson showed that medial pedicle procedures have been shown to be dependable in extreme mammary hyperplasia.[51]They alsoshowed this in their series of 88 patients undergoing BBR with a medial pedicle. [52]Wise pattern skin resection at one year had less ‘bottoming out’ and a lower complication rate versus inferior pedicle reductions with vertical scars. [53]

A complication rate of up to 20%, in the early post-operative phase and a delayed complication incidence of 20-30%was demonstrated by Beer with the Inverted-T scar breast reductions. [54]

Breast surgery candidates are prone to a similar complications risk profile that accompanies any surgical procedure, viz.bleeding, pulmonary emboli, pain, infection, seroma, thrombophlebitis, allergies to medications and poor scarring.

Specific potentialcomplications include skin flap necrosis, skin or nipple loss, loss of sensation to NAC and or breast flaps, asymmetry, contour irregularities, high-riding nipples and bottoming out, inability to breastfeed, resecting too much or too little breast tissue, incision dehiscence, and less than optimalintermediate and long term scarring.

Additionally, the candidates’requested or preferred volume, shape and appearance, although uncommon, may not be fulfilled with this technique. Dramatic post-operative weight loss may lead to further reduction in breast size, up to where on the rare occasion, a breast augmentation may have to be considered.

4.8.3 Nipple retraction

The current study sometimes noted a minimal nipple retraction seen as a result of tension in suture line or the weight of pedicle on the areola and it usuallyresolves in a few days. A grossly retracted nipple might need correction by releasing the dermal pedicle wherever the tension is more. If it persists for a long time, secondary correction may be advisable after 6 months, by division of the scar contracture.

In the wise pattern if the flaps are thinned excessively or wound closure is too tight, the chances of wound breakdown increases. This is most often found at the junction of vertical and horizontal suture lines, as at the Inverted-T suture junction line.

If the breakdown area is small, it is self-limiting. If larger and or associated with fat necrosis, surgical debridement and dressings are required until healing is complete and scar revision can be planned at a later date. A conservative approach of debridement and dressing until granulation tissue appears, then skin graftas required.

4.8.4 Hematoma

This is a common complication seen with all types of breast reduction. It can be prevented by meticulous hemostasis and although the patient must mobilize out of bed on day 1 post operatively, excessive shoulder movements must be avoided for the patient for first 2-3 days post-operatively.

Meticulous intra-operative hemostasis is imperative.

When in doubt, it is advised perform exploration and hematoma evacuation under anesthesia with closed suction drainage. A hematoma is the number one cause leading to other wound problems. If left untreated, it can result in fat necrosis, skin sloughing, and nipple loss and or skin flap loss.

4.8.5 Nipple-areola necrosis

Potential necrosis of the NAC is a dreaded and unfortunate complication.

Internal mammary perforators provide the most reliable perforatorsupply to the NAC. [55](cf: Arterial Perforators page 31).

A planning and noting of the superficial venous drainage pattern during the initial marking process of the patient, as described in the surgical technique, will avert the potential for venous congestion.

Post operatively, a meticulous observation of the areolar circulation through dressing with a window facility in the first 48 hours would warn about this complication. If persistent cyanosis is noticed, identification of the problem and immediate surgical intervention may salvage the nipple. Sutures are removed as necessary, a hematoma

sought for and vascularity of the nipple reassessed. Some breast surgeons have described early conversion to a free nipple graft. The nipple has to be grafted onto de-epithelialized dermis, [4]not the underlying fat, at an early stage. The use of leeches for NAC had been described to improve venous congestion. [56]

If these immediate salvage methods measure fail, a delayed reconstruction of the nipple-areola is opted for or this can be the chosen first option if suture release and hematoma evacuation doesn't work. The incidence of NAC necrosis varies and is related predominantly to a compromised vascular supply of the breast SMP itself, or the skin flaps which gives direct supply to the NAC distally.

In our cohort the NAC was elevated up to 26 cm with a mean of 21 cm of upward movement without significant loss of the NAC. There were no patients with superficial necrosis greater than 15% of the total NAC surface area. In a quarter of patients there were limited areas of wound breakdown occurred over the T-junction within the first weeks. They were all minor enough to resolve with wound dressings alone, and without surgical intervention.

4.8.6 Fat necrosis

Small areas may not require intervention especially when there is no skin necrosis. This dreaded complication is due to vascular compromise to the parenchyma with hemorrhagic necrosis. If skin and fat necrosis is excessive and associated with infection, surgical debridement, secondary closure is required.[57]

Grafting is done at a later date.

If the skin and nipple-areola complex are involved, discharge may be evident followed by cellulitis and fever. Healing is prolonged.

4.9 Nipple sensation

Dysesthesia over the nipple may persist for a year and then recovery usually occurs. Good sensibility has been reported with the SMP technique.[58]

Sexual sensibility is decreased at least in 50% of the subjects, but can recover.[59]

Though rare, improved sensation has been reported too.[60]

Our cohort recorded 1 patient with hypersensitivity at 6 weeks post operatively but this had resolved atthe 1year consultation time.

Santanelli in 2007, [61] in their study confirmed that some macromastia patients already have a reducedsensation and that the breast reduction surgery does not necessarily further worsen their breast sensibility. Their pedicle choice was however superolateral.With this pedicle technique, NAC sensibility might be slightly reduced.

They showed that breast sensation loss was less obvious in large-breast hyperplasiadue to the comparative decreased sensibility preoperatively.

In a study comparing 39 breasts who had the inferior pedicles and 36 breasts who had a superior pedicle BBR, Hamdi showedat 6 months, in the 2 series of patients, thatthe mean value of NAC pressure sensation was similar.[62]

Our cohort showed thatsensation may was altered in the initial postoperative period in all or some the 5 NAC quadrants, probably due to postoperative swelling and or traction on the nerve. However, sensation recorded one year later reflect a favorable return of sensation to that of its pre-operative status. (Table 4).

Lejour's [63] technique of vertical reduction with a superior pedicle for moderately enlarged breasts regained their preoperative level of sensation, specifically pressure sensitivity, only after 1 year.

Nahabadien [64] retained 98% of NAC sensation with use of medial pedicle pattern in a series of 45 hypertrophic breast reduction patients.

4.9.1 Shape and Projection and Scarring

The breast can be perceived as a cone shape.

Larger breasts with a larger volume require a reproducible dependable safe approach; the surgeons selected the Wise pattern skin resection and inverted T pattern closure. (Diagram 3).

While the superomedial pedicle mammoplasty with vertical-scar closure is growing in popularity, it is an efficientprocedure, though rates of revision have been reported higher with certain skin resection patterns, namely the vertical pattern skin scar.Rinker [65] showed in 2013, that the rates of revision can be improved with the choice of the inverted-T technique resection design in the group of gigantomastia and macromastia candidates who undergo SMP reduction technique. He showed in his review of 127 patients undergoing breast reduction using anSMP, that a reduction in revision rates can mean opting for an inverted-T skin pattern versus vertical scar reduction pattern, particularly in patients with an extended N-IMF distance. Neither the operative time or complication rates were significantly increased. Secondary breast deformity, changes in shape and bottoming out may be due to choice of wrong technique or error in judgment. [66]

Minor but noticeable breast asymmetry can be treated with liposuction with good results. [67] Larger asymmetry entails revision surgery, after a waiting period of at least 6 months. Pseudoptosis can be tackled with a horizontal elliptical excision from the inferior aspect. [68]

4.9.2 Hypertrophied and symptomatic scars

Wound hypertrophy in and along the inverted T-scar, especially of the perpendicular limb is common after reduction surgery. Shermak et al, showed that up to 15% of all scars are reported to be thick, itchy or uncomfortable. [69]

Taping the scar for several weeks is a simple measure to offset the tendency. Scar hypertrophy can also be treated with intra-lesional steroid injections and silicone gel sheet pressure.

4.9.3 Secondary breast deformity

Larger asymmetry entails revision surgery, after at least 6 months. Pseudoptosis can be tackled with a horizontal elliptical excision from the inferior aspect. [70]

4.9.4 Minor breast asymmetry

If the asymmetry is small and minor, it can be treated with liposuction[71]or small excisions of 'dog ears' laterally, if necessary.

4.9.5 Nipple-areola malposition

A nipple set too high is the most challenging to reset.

Minor asymmetry of position, difference of about a centimeter can be managed with a crescentic excision on the desired border of the areola.[5] Major asymmetry requires circumferential surgical release of the NAC and re-setting.

The results of the current study showed that in 62 macromastia and gigantomastia breasts, with elongatedN-N distances and large resection large weights, the SMP reduction mammoplasty was safely and efficaciously used.

A small number of breasts had early superficial necrosis and T-Junction breakdown. These symptoms were short lived and resolved with conservative wound management, without need for surgical revision.

No NACs were lost in this study cohort. Sensation returned to preoperative status in all but 2 patients, (3 breasts). These were not the same patients who had T-junction wound breakdown.

Independent opinion on aesthetic outcome assessed predominantly a 'good' poll in 90% patients. (Table 4). The scoring of the different specialists were not analyzed in terms of their scoring to their specialty or to each other.

In 2007 Davidson et al[72], in a cohort of 216 breast reduction patients showed that the SMP with various skin patterns, was a safe reliable technique for small and moderate size reductions with different skin resection patterns, provided a consistent breast

shape, nipple viability and superomedial fullness. Their overall complication rate was 18%.

Finger[24], showed2 partial losses of the nipple areola complex (< 25%), decreased sensation in 15% in 148 patients (291 breasts) patients undergoing the SMP technique. Other complications were hypertrophic scars, nipple retraction, and dog-ears. Average blood loss was measured at 200 ml.

In 2010 Serra et al[73] reduced severe gigantomastia (defined by their study as >1200 g) with a modified superior pedicle They described an 'extension' to the superior pedicle pattern, i.e. adding a medial component to the Wise pattern BBR. Their mean resection rate was 1450 g, with a low complication rate of 2% of patients requiring revision surgery. They demonstrated that by incorporating the quadrant on the medial side into their superior pedicle, viz. essentially a SMP, larger, and more voluminous reductions can safely be undertaken compared to other techniques. While the author describes a superior pedicle with medial extension, it is not clear exactly how much of the medial quadrant is included in their pedicle. The mean resection weight, 1450 g was smaller than our mean resection weight of 1835 g, and N-N mean distance of 44,75cm with a NAC mean elevation of 22,6 cm, no mean N-N distance is recorded in this report. However, they showed with their 'modified SMP' a low rate of revision surgical of 2%. In this study, there were no cases which required surgical revision.

This study complications rates were comparable with ours, namely partial superficial nipple necrosis in 11,5%. T-junction breakdown occurred in 24,2% of patients, no nipples were lost. A total of 6,4%, 2 patients, had absent sensation at 1 year, 83,8% of patients deemed their sensation to be exactly the same as before surgery after one year. 50% of thosepatients who had minor T-junction breakdown, and 55% of thosepatients who had partial NAC necrosis, also had a high BMI, $\geq$ 30. This is in keeping with Orlando and Guthrie, who supports the fact that candidates with a raised BMI are more likely to have slower wound repair postBBR surgery.[11]

In the current study patients with the longest N-N = 49,5 and 49 cm each side, did well, and showed neither NAC necrosis nor T-junction wound dehiscence. While the patient with the highest resection weight, 2670 g, showed minor T-junction wound breakdown, but no NAC necrosis and also her sensation was preservedAdditionally the small wound breakdown healed with regular wound dressings and did not require surgical revision.

Landau and Hudson[74]reviewed 61 Gigantomastia patients who had the SMP pattern reduction. The mean average resection weights were 1379 g, and the mean N-N lengths of 35cm. They showed complication rates of 6.5% and 18% for partial areola necrosis and T- junction breakdown respectively. Our complication rate was higher, 11,5% and 24,2% respectively, but with larger breast resection volumes and longer N-

N lengths, i.e. mean breast resection weights of 1835 g and mean N-N= 44,12 cm. When comparing the 2 studies, the breast resection weight was larger by 33% and the N-N by 26%. While the complication rate increased by 34% and 76% for T-junction breakdown and NAC necrosis respectively.

When compared it shows that as the breast resection weight and N-N distances increased, the chance of complication rates increased. High BMI also correlated with a higher complication rate.

5.1 Outcome and Prognosis

Patients interviewed postoperatively expressed marked alleviation from their initial symptoms and expressed satisfaction with the outcome.

The majority of patients were advised to initiate or continue weight loss programs pre-operatively, it became easier to participate in such programsdue to their own increased upper body mobility postoperatively. With a good quality, supportive sports bra, full unrestricted activities may be resumed once wounds have healed, usually 1 month after surgery.

There is diminished risk for "bottoming out" following this SMP procedure and better preservation of long-term breast contour.[75]

Beraldo[76] showed in women with breast hypertrophy, breast reduction surgery can improve sexual function and relieve depression. The study included 56 women with breast hypertrophy, 29 of whom underwent breast reduction and the rest of whom did not. Using the Female Sexual Function Index and Beck Depression Inventory, the investigators found that at 3 and 6-month follow-up, the breast reduction patients reported better sexual function, while at 6-month follow-up, they demonstrated better depression scores.

5.2 Limitations

A limitation are the relatively small numbers in this study 62 breasts, other study numbers reviewing breast reduction cohorts, have numbers over 80 breasts and some asses their patients for longer post-operative periods. A prospective study would be able to better look at a broader variety of factors, viz. a younger, pre-breastfeeding cohort of macromastia and gigantomastia breasts that looks at patient’s post-operative breast feeding ability, to study the specific effect of the SMP pattern of reduction on breastfeeding. Also the study design could better incorporate better record keeping at each visit, including polled patient opinion at each stage of the follow up.

The testing for post-operative NAC sensation could be improved in accuracy by expanding the different modalities of NAC sensation tested. This study only tested light touch. To be more comprehensive, deep touch, temperature and pressure should be tested.

Also the use of a grading system like: Female Sexual Function Index and Beck Depression Inventory and similar for example may give a greater insight to the lesser recorded sexualimpact of massive breast hypertrophy and the alleviation of these problems post operatively.

There should ideally be guidelines given to the independent judges in future to improve uniformity of what constitutes the categories of ‘poor’, ‘fair’, ‘good’ and ‘excellent’ in terms of breast aesthetics, and while the currently study chose specialists involved in breast surgery, there was no standardization of each category.

Although the results of this study were favorable at a mean follow up of 1 year. Alonger term follow up would reflect a more accurate and, more in-depth indication as to the longevity of breast shape and projection over time. While patients were unanimously satisfied with their new breasts, a standardized patient written paper poll was not performed and the authors felt that it would give a more committed accurate and standardizedcaptureof their personal opinion It couldalso record other parameters, like the impact surgery has on their breastsspecifically,but also the impact on their overall psychology, lifestyle and postoperative daily functioning.

Reduction mammoplasty surgery generally enjoys excellent patient satisfaction levels. The SMP reduction mammoplasty used for macromastia and gigantomastia patients has shown similar outcomes and satisfaction levels.Knowledge of the anatomy, meticulous pre-operative planning, gentle tissue handling and anticipatory post-operative care will reduce the incidence of complications.Our data on the SMP presents a technique that is safe, efficacious, reliable and reproducible for macromastia and gigantomastia size breasts, specifically with elongated N-N lengths of > 40 cm, and resection weights > 1500 g per breast.

The viability and sensibility of NAC are well preserved, while simultaneously producing a good superomedial breast fullness and hence a good subjective shape. There was also good breast projection and symmetry with fair to good scarring, whilst still retaining nipple viability and sensation. However, complications may occur in patients with higher BMI.[62]Parameters can be more streamlined in future and BMI maybe a factor to warrant individualized patient weight loss prior to BBR surgery. The authors believe that the SMP BBR provides a low complication profile for patients presenting with macromastia and gigantomastia type breast hypertrophy.

References

[1] Hernanz F, Santos R. Treatment of symptomatic macromastia in a breast unit. World J. Surg. Oncol 2010;8(1):93.
DOI: [http://dx.doi.org/10.1186/1477-7819-8-93]

[2] McKissock P. Color Atlas of Mammaplasty. Thieme Medical Publishers. 1991:47-78.]
PMID: 25741497

[3]Remi Goulart, Daniele Detanico, Roberta Pires Vasconcellos, Gustavo Ricardo Schütz, Saray Giovana dos Santos. Can J Plast Surg. 2013 Spring; 21(1): 29–32. PMCID: PMC3891107

[4] Min Jeng Cho, Jung-Hyun Yang, Hyeon-Gon Choi, Wan Seop Kim, Kyoung Sik Park. An idiopathic gigantomastia. Ann. Surg. Treat. Res. 2015 Mar;88(3):166-9.
DOI: [http://dx doi: 10.4174/astr.2015.88.3.166]

[5] Nahai FR. Nahai, Foad. MOC-PSSM CME: Breast Reduction. Plast. Reconstr. Surg. 2008;121(1) suppl:1–13.
DOI: [http://dx.doi.org/10.1097/01.prs0000294705.85848.cf]

[6] Lassus C. Breast reduction: evolution of a technique - a single vertical scar. Aesthetic Plast Surg. 1987; 11:107–112.
DOI: [http://dx.doi.org/10.1007/BF01575495]

[7]Gillies, H. D., and Millard, D. R. The Principles and Art of Plastic Surgery. Boston: Little, Brown, 1957. p(104–110)

[8]Cardenas-Camarena L, Vergara R: Reduction mammaplasty with superolateral dermoglandular pedicle: Another alternative. Plast Reconstr Surg. 2001;107(3):693–699.
DOI: [http://dx.doi.org/10.1097/00006534-200103000-00007]

[9] Chao JD, Redding JF, Egan L, Reduction mammaplasty is a functional operation, improving quality of life in symptomatic women: a prospective, single-center breast reduction outcome study. Plast Reconstr Surg. 2002;110(7):1644-5.
DOI: [http://dx.doi.org/10.1097/00006534-200212000-00003]

[10]Lacerna M, Spears J, Mitra A, et al. Avoiding free nipple grafts during reduction mammaplasty in patients with gigantomastia. Ann Plast Surg. 2005 Jul; 55(1):21-4.
PMID: 15985786

[11]Orlando JC & Guthrie RH. The superomedial dermal pedicle for nipple transposition. Br J Plast Surg. 1975(1); 28:42-45.
DOI: [doi http://dx.doi.org/10.1016/0007-1226(75)90149-6]

[12]Hall-Findlay, J. LongSimplified Vertical Breast Reduction
http://emedicine.medscape.com/article/1818858-overview#a6

[13]The American Society of Plastic and reconstructive Surgeons Clinical Practice Guidelines for Female /Hypertrophy Breast Reconstruction. 1993.
http://www.plasticsurgery.org/for-medical-professionals/quality-and-health-policy/evidence-based-medicine-guidelines.html

[14]Thorek M. Possibilities in the reconstruction of the human form. NY Med J 1922; 116:572. 4.Mastopexy and Breast Reduction.
Chapter: Superior-Medial Pedicle Technique for Large Breast Reduction Jorge I. de la Torre, James N. Long, Luis O. Vásconez, pp 387-394

[15]Richard J. Restifo, Janice F. Lalikos Amputation/free nipple graft reduction mammaplasty: Operative Techniques in Plastic and Reconstructive Surgery: 1996 3(3), p184–188
doi:10.1016/S1071-0949(96)80037-0

[16] Courtis EH, Goldwyn RM. Breast sensation before and after plastic surgery. Plast Reconstr. Surg. 1976 Jul;58(1):1-13.
PMID:6983

[17]Robbins TH. Reduction mammaplasty by the Robbins technique. Plast Reconstr Surg. 1987 Feb. 79(2):308-9
PMID: 3543983

[18]Wise RJ. A preliminary report on a method of planning the mammaplasty.Plast. Reconstr Surg. (1946) 1956; 17:367–75.
PMID: 13335513

[19] Wise RJ, Gannon JP, Hill JR. Further experience with reduction Mammaplasty. Plast Reconstr Surg. 1963; 32:12–20.

PMID: 14045092
[20]Lassus C. A 30-year experience with vertical mammaplasty. Plast Reconstr Surg. 1996; 97:373–80.
PMID: 8559820

[21]Lejour M. Vertical mammaplasty and liposuction of the breast. Plast Reconstr Surg. 1994; 94:100–14.
PMID: 8016222

[22] Hall-Findlay EJ. A simplified vertical reduction mammaplasty: Shortening the learning curve. Plast Reconstr Surg. 1999; 104:748–59. 760.
PMID: 10456528

[23]Benelli L. A new peri-areolar mammaplasty: The "round block" technique.Aesthetic. Plast. Surg. 1990; 14:93–100
PMID: 2185619

[24] Finger RE1, Vasquez B, Drew GS, Given KS Superomedial pedicle technique of reduction mammaplasty. Plast Reconstr Surg. 1989 Mar;83(3):471-80.

[25]Bland KI, Romrell LJ: Congenital and acquired disturbances of breast development and growth. In The Breast, KI Bland, EM Copeland 111 eds. WB Saunders Co. Philadelphia, 1991, p.69

[26] The American Board reports a 76% increase in reduction mammoplasty surgery over the period 2009-2014 American Society of Plastic Surgeons Annual statistic report 2014

[27] McPherson K: Reducing the global prevalence of overweight and obesity
Lancet. Volume 384, No. 9945, p728–730, 30 August 2014
DOI: http://dx.doi.org/10.1016/S0140-6736(14)60767-4

[28]UNAIDS Gap Report 2014
http://www.unaids.org/en/regionscountries/countries/southafrica/

[29] Sunil KN, Shashibhushan, Malappa J, Venugopal K, Huggi V, Menon M. Lipodystrophy in Human Immunodeficiency Virus (HIV) Patients on Highly Active Antiretroviral Therapy (HAART). J Clin. Diagn. Res. 2015 Jul; 9(7): OC05–OC08.
DOI: 10.7860/JCDR/2015/12979.6183

[30] Tchebiner JZ. Breast enlargement induced by D-penicillamine. Ann Pharmacother. 2002 Mar;36(3):444-5.
PMID: 11895058

[31] The American Society of Plastic surgeons. 2014 Plastic Surgery Statistics
DOI:http://plasticsurgery.org/news/plastic-surgery-statistics/2014-statistics.html

[32]Spear Scott, Breast Reduction, Inverted T-Technique' Grabb and Smith, Chapter 59, page 600.

[33] Deventer, van P. The Blood Supply to the Nipple–Areola Complex of the Human Mammary Gland. Aesth. Plast. Surg. 2004 (27):393–398
DOI: [http://dx.doi.org/10.1007/s00266-003-7113-9]

[34] Corduff N, Taylor GI. Subglandular breast reduction: the evolution of a minimal scar approach to breast reduction. Plast Reconstr Surg. 2004 Jan;113(1):175-84.
PMID:14707635

[35]Corduff N, Rozen WM, Taylor GI The superficial venous drainage of the breast: a clinical study and implications for breast reduction surgery.J Plast. Reconstr. Aesthet. Surg. 2010 May;63(5):809-13.
DOI:[http://dx.doi.org/10.1016/j.bjps.2009.02.055.
PMID:19345164

[36] Jaspars JJ, Posma AN, van Immerseel AA, Gittenberger-de Groot AC) (The cutaneous innervation of the female breast and nipple-areola complex: implications for surgery. Br J Plast Surg. 1997 Jun;50(4):249-59.
PMID: 9215081

[37] Riccio CA, Zeiderman MR, Chowdhry, S, Brooks RM, Kelishadi SS, Tutela JP, Choo J, Yonick DV, Wilhelmi BJ.: Keeping the Nipple Sensitive. Plastic Surgery of the Breast Eplasty. 2015 Jul 2;15: e28. eCollection 2015.
PMID: 26171100

[38]Greuse, Muriel M.D.; Hamdi, Moustapha M.D.; DeMey, Albert M.D. Plast. Reconstr. Surg. 107: 970, 2001.pg. 2283-2288
PMID:11121316

[39] Godwin Y1, Valassiadou K, Lewis S, Denley H.
Plast Reconstr Surg. 2004 May;113(6):1598-606. Investigation into the possible cause of subjective decreased sensory perception in the nipple-areola complex of women with macromastia.
PMID: 15114119

[40]Roux le, MC, Kill BJ, Pan WR. Preserving the neurovascular pedicle in the Hall-Findlay superomedial pedicle breast reduction: An anatomical study. 2010, J Plast Reconstr. Aesthe. Surg.April;63(4):655-62

[41] Elizabeth J. Hall-Findlay, Vertical Breast Reduction. Semin. Plast. Surg. Aug 2004; 18(3): 21224.
DOI: 10.1055/s-2004-831908
PMCID: PMC2884717

[42]Selected Reading in Plastic Surgery-Reduction Mammoplasty and Mastopexy. Joshua Lemmon, Vol 10, No 19

[43]Vertical Reduction Mammaplasty Using the Medial Pedicle Elizabeth J. Hall-Findlay/Hall-Findlay EJ (2002) Vertical breast reduction with a medially based pedicle. Oper Strat Aesthetic Surg J 22:2:185

[44]Cunningham BL, Gear AJ, Kerrigan CL, Collins ED. Analysis of breast reduction complications derived from the BRAVO study. Plast Reconstr Surg. 2005;115:1597–604.
PMID: 15861063

[45]Davis GM, Ringler SL, Short K, Sherrick D, Bengtson BP. Reduction mammaplasty: Long-term efficacy, morbidity, and patient satisfaction. Plast Reconstr Surg. 1995; 96:1106–10.
PMID: 7568486

[46]Makki AS, Ghanem AA. Long-term results and patient satisfaction with reduction mammaplasty. Ann Plast Surg. 1998; 41:370–7.
PMID: 9788216

[47] Meshulam-Derazon S, Barnea Y, Zaretski A, Leshem D, Miller U, Meilik B, et al. Large-volume breast reduction: Long-term results. Scand. J Plast. Reconstr. Surg. Hand Surg. 2009; 43:65–70.
PMID: 19308855

[48]Shermak MA, Chang D, Buretta K, Mithani S, Mallalieu J, Manahan M. Increasing age impairs outcomes in breast reduction surgery. Plast. Reconstr. Surg. 2011; 128:1182–7.
PMID: 22094737

[49]Eggert E, Schuss R, Edsander-Nord A. Clinical outcome, quality of life, patients' satisfaction, and aesthetic results, after reduction mammaplasty. Scand.J. Plast. Reconstr. Surg. Hand Surg. 2009; 43:201–6.
PMID: 19688643

[50] Yvonne N. Pierpont,1,2 Trish Phuong Dinh,2 R. Emerick Salas,1,2 Erika L. Johnson,1,2 Terry G. Wright,1,2 Martin C. Robson,2 and Wyatt G. Payne1,
Review Article: Obesity and Surgical Wound Healing: A Current Review ISRN Obesity Volume 2014 (2014), Article ID 638936, page 13
http://dx.doi.org/10.1155/2014/638936

[51]Elizabeth J. Hall-Findlay, Vertical Breast Reduction. Semin. Plast. Surg. Aug 2004; 18(3): 21224.
DOI: [http://dx.doi.org 10.1055/s-2004-831908]
PMCID: PMC2884717

[52] Abramson DL, Pap S, Shifteh S, Glasberg SB. Improving long-term breast shape with the medial pedicle wise pattern breast reduction. Plast. Reconstr. Surg. 2005 Jun;115(7):1937-43.
PMID: 15923840

[53] Kenneth C. Shestak, Edward H. Davidson, MA/ Avoiding Risk and Complications in Breast Reduction/ Clinics in Plastic Surgery.
DOI: http://dx 10.1016/j.cps.2015.12.007

[54] Beer GM1, Spicher I, Cierpka KA, Meyer VE.Benefits and pitfalls of vertical scar breast reduction.Br. J. Plas. Surg. 2004 Jan;57(1):12-9.
PMID: 14672673

[55]van Deventer PV, Graewe FR. Enhancing pedicle safety in mastopexy and breast reduction procedures: The postero-inferomedial pedicle, retaining the medial vertical ligament of Würinger. Plast Reconstr Surg.2010; 126:786–93.
PMID: 20811213

[56] Gross MP, Apesos J. The use of leeches for treatment of venous congestion of the nipple following breast surgery. Aesthetic Plast Surg. 1992 Fall;16(4):343-8.
[57] Dabbah A, Lehman JA, Jr, Parker MG, Tantri D, Wagner DS. Reduction mammaplasty: An outcome analysis. Ann Plast Surg. 1995; 35:337–41.
PMID: 8585673

[58] Serletti, Joseph M. MD; Reading, George MD; Caldwell, Elethea MD; Wray, R Christie MD
Long-term Patient Satisfaction Following Reduction Mammoplasty ANNALS OF PLASTIC SURGERY 28(4):363-5 • MAY 1992

[59] Romeo M1, Cuccia G, Zirilli A, Weiler-Mithoff E, Stagno d'Alcontres F. Reduction mammoplasty and related impact on psychosexual function. J Plast Reconstr Aesthet Surg. 2010 Dec;63(12):2112-6. Epub 2010 Mar 5.
PMID:20207212
DOI: 10.1016/j.bjps.2010.01.001

[60]Swanson E. Prospective outcome study of 106 cases of vertical mastopexy, augmentation/mastopexy, and breast reduction. J Plast Reconstr Aesthet.Surg. 2013;66:937–49.
PMID: 23582506

[61] Santanelli F, Paolini G, Bittarelli D, Nofroni I. Computer-assisted evaluation of nipple-areola complex sensibility in macromastia and following superolateral pedicle reduction mammaplasty: a statistical analysis. Plast. Reconstr. Surg. 2007 May;119(6):1679-83.

[62] Hamdi M, Greuse M, De Mey A, Webster MH. A prospective quantitative comparison of breast. Br. J. Plast. Surg. 2001 Jan;54(1):39-42
PMID: 11121316

[63]Hamdi M1, Greuse M, De Mey A, Webster MH. Breast Sensitivity after Vertical Mammaplasty
Department of Plastic Surgery, C. H. U. Brugmann, Free University of Brussels, Belgium.

Plastic & Reconstructive Surgery (Impact Factor: 2.99). 05/2001; 107(4):970-6.DOI: [http://dx.doi.org/10.1097/00006534-200104010-00011

[64]Nahabedian MY, McGibbon BM, Manson PN.Medial pedicle reduction mammaplasty for severe mammary hypertrophy.Plast. Reconstr. Surg. 2000 Mar;105(3):896-904.
PMID:10724248

[65]Rinker B.Lowering revision rates in medial pedicle breast reduction by the selective addition of "Inverted-T" technique Aesthetic Plast Surg. 2013 Apr;37(2):341-8.
DOI:[http://dx.doi.org 10.1007/s00266-013-0061-0

[66] Hammond DC, Loffredo M. Breast reduction. Plast. Reconstr. Surg. 2003; 111:387–93.
PMID: 22544113

[67] Rohrich RJ, Thornton JF, Sorokin ES. Recurrent mammary hyperplasia: Current concepts. Plast. Reconstr. Surg. 2003; 111:387–93.
PMID: 12496611

[68]Hudson DA, Skoll PJ. Repeat reduction mammaplasty. Plast Reconstr Surg. 1999; 104:401–8.
PMID: 10654683

[69]Shermak MA, Chang D, Buretta K, Mithani S, Mallalieu J, Manahan M Increasing age impairs outcomes in breast reduction surgery. Plast Reconstr Surg. 2011; 128:1182–7.
PMID: 22094737

[70]Hudson DA, Skoll PJ. Repeat reduction mammaplasty. Plast Reconstr Surg. 1999; 104:401–8.
PMID:10654683

[71]Rohrich RJ, Thornton JF, Sorokin ES. Recurrent mammary hyperplasia: Current concepts. Plast Reconstr Surg. 2003; 111:387–93.
PMID: 12496611

[72]Davison SP, Mesbahi AN, Ducic I, Sarcia M, Dayan J, Spear SL.
The versatility of the superomedial pedicle with various skin reduction patterns. Plast. Reconstr. Surg. 2007 Nov;120(6):1466-76.

PMID:18040175

[73]Serra MP, Longhi P. Haubeden. The supero-medial dermal-glandular pedicle mastoplasty with Wise pattern: an easy technique with a shorten learning curve. Is it the gold standard for severe gigantomastia? Ann. Ital. Chir. 2010 Sep-Oct;81(5):369-75
PMID: 21294391

[74]Landau AG, Hudson DA Choosing the Superomedial pedicle for the reduction mammoplasty in gigantomastia. Plastic. Reconstr. Surg.2008 Mar:121(3):91-6
PMID: 18317123

[75]Srinivasaiah N, Iwuchukwu OC, Stanley PR, Hart NB, Platt AJ, Drew PJ: Risk factors for complications following breast reduction: results from a randomized control trial. Breast J. 2014 May-Jun;20(3):274-8.
DOI: [http://dx.doi.org/10.1111/tbj.12256.
PMID: n24750511

[76]Beraldo FN, Veiga DF, Veiga-Filho J, et al. Sexual Function and Depression Outcomes Among Breast Hypertrophy Patients Undergoing Reduction Mammaplasty: A Randomized Controlled Trial. Ann Plast Surg. 2014 Dec 19.
PMID: 25536204