

https://dspace.org/

Audit of maxillectomy at Wits maxillofacial and oral surgery unit

Mogajane, Brampie Mpumpile

2019

https://hdl.handle.net/10539/29139

Downloaded from a DSpace repository. https://dspace.org/

AUDIT OF MAXILLECTOMY AT WITS MAXILLOFACIAL AND ORAL SURGERY UNIT

Brampie Mpumpile Mogajane (571318)

A research report submitted to the Faculty of Health Sciences, University of the Witwatersrand, Johannesburg, in partial fulfilment of the requirements for the degree of Master of Dentistry in the branch of Maxillofacial and Oral Surgery.

Johannesburg, 2019

DECLARATION

I, Brampie Mpumpile Mogajane, hereby declare that this research report is my own work. It is being submitted for the degree of Master of Dentistry in the University of Witwatersrand, Johannesburg. It has not been submitted before for any degree or examination at this or any other University.

…….

…….day of……, 2019

ABSTRACT

Aim: The aim of this study was to retrospectively audit maxillectomy performed at Wits Oral Health Centre (WOHC) over a ten (10) year period from January 2008 to December 2018.

Objectives: To describe the profile of the patients who underwent maxillectomy in the Maxillofacial and Oral Surgery (MFOS) department; to evaluate the patterns of maxillectomies in the MFOS department and to determine the indications for maxillectomy in the MFOS department.

Materials and Methods: This is a cross-sectional retrospective study of the patients who underwent maxillectomy at WOHC, University of Witwatersrand, Johannesburg. The study included patients from both Maxillofacial and Oral surgery units in Charlotte Maxeke Johannesburg Academic Hospital (CMJAH) and Chris Hani Baragwanath Academic Hospital (CHBAH). Records of patients from 2008 to 2018 were obtained from outpatient departments and theatres of both hospitals. Data collected for evaluation included the age of patients; gender; aetiology of maxillectomy; classification of maxillectomy according to Brown's classification (2010); rehabilitation modality and complications associated with the type of rehabilitation modality instituted. Data was analysed and results presented as frequencies and percentages.

RESULTS: Out of the 47 cases of maxillectomy recorded in the department during the study period, 44 cases met the criteria for inclusion, while 3 cases were excluded due to missing records. There were 21(47.7%) males and 23(52.3%) females with a male to female ratio of 1:1,015. The minimum age was 1 and the maximum age was 73 years, with the mean age of 36.1(16.3). Majority of patients were in the age group of 41-60 years. The most indications for maxillectomy were pathological lesions (90.9%), with a nearly equivalent distribution of 19 (47.5%) benign and 21 (52.5%) malignant lesions. Ossifying fibroma (26.32%) was the most common benign lesions and squamous cell carcinoma (33.33%) was the most common malignant lesions. Trauma constituted only 9.1%. Brown's classification type IIB (38.6%) was the most common defect following maxillectomy procedure. The prosthetic obturator was used as a sole rehabilitative modality in most (47.75%) of the patients. Vascularised free tissue transfers were associated with more complications.

CONCLUSION: Prosthetic obturator as a sole rehabilitative modality still plays an important role in the rehabilitation of patients with maxillectomy. The findings of this study should serve as the basis for future treatment algorithm for maxillectomy in the department.

DEDICATION

I dedicate this research report to my loving mother Matlale, for her unwavering support and motivation to help complete this research report.

ACKNOWLEDGEMENTS

I wish to express my gratitude to my supervisor Prof E. Rikhotso for his supervision and selfless support and guidance in the preparation of this research report. I would like to acknowledge Mr Nyathi for his kindness in providing statistical input. I am indebted to everyone's contribution, without which this research report would have not completed.

TABLE OF CONTENTS

Contents

DECLARATION i

ABSTRACT ii

DEDICATION iii

ACKNOWLEDGEMENTS iv

TABLE OF CONTENTS v

LIST OF FIGURES vii

LIST OF TABLES viii

Chapter 1 : Introduction and Literature Review 1

Chapter 2 : Research design 9

2.1 Aim 9

2.2 Objectives 9

2.3 Material and Methods 9

2.3.1. Study design 9

2.3.2. Sample size 9

2.3.3. Inclusion criteria 9

2.3.4. Exclusion criteria 9

2.3.5. Methodology 9

2.4 Data management and analysis 10

2.5 Ethical considerations 10

Chapter 3 : Results 11

3.1 Demographic data 11

3.2 Indications for maxillectomy 12

3.3 Classification of maxillectomy according to brown's classification (2010) 14

3.4 Rehabilitative modalities 15

3.5 Complications associated with rehabilitative modalities 18

Chapter 4 : Discussion 20

Chapter 5 : Conclusion 26

Chapter 6 : References 27

APPENDIX A: Clearance certificate 31
APPENDIX B: Data collection sheet 32

LIST OF FIGURES

Figure 2.1: Classification of Vertical and horizontal maxillectomy and midface. 10

Figure 3.1: Distribution of patients by gender 11

Figure 3.2: Distribution of patients by age.....12

Figure 3.3: Distribution of patients by Brown's classification.....15

Figure 3.4: (**A-I**). (**A**) A 23 years old male patient with maxillary osteosarcoma. (**B**) An intra-oral view showing fungating mass with displaced teeth. (**C**) Coronal bony window of computed tomograpgy (CT) scan showing classic "sunburst" appearance. (**D**) A 3-Dimensional reconstruction of CT scan. (**E**) A tumour exposed via modified Weber-Ferguson approach. (**F**) A tumour resected in its entirety. (**G**) A type IID Brown's maxillectomy defect. (**H**) An obturator secured with miniplates to remaining defect. (**I**) A patient with stent to keep nasal passage patent. 16-17

LIST OF TABLES

Table 3.1: Distribution of malignant lesions by patients. 13

Table 3.2: Distribution of patients by benign lesions 13

Table 3.3: Distribution of rehabilitative modality by patients 18

Table 3.4: Distribution of complications by patients 19

Chapter 1 : Introduction and Literature Review

The maxilla provides a structural support between the skull base and the occlusal plane. It bears the maxillary teeth, transmits masticatory forces, and gives functional support to the orbit and its contents while providing a partition between the oral and nasal cavities and maxillary sinuses. It is also a source of attachment for the muscles of facial expression and mastication (Futran and Mendez, 2006; Akinmoladun *et al*., 2018). The maxilla supports the bony and soft tissue midface and provides a good portion of the facial appearance that is distinctive to each individual. It also provides critical functions such as mastication, speech and deglutition (Futran and Mendez, 2006; Cordeiro and Santamaria, 1999).

The maxilla is composed of the paired right and left maxillae, each of which is defined as a geometrical structure of six walls (hexahedron). When the anatomical palatomaxillary reconstruction is taken into consideration, the maxilla can be conveniently divided into supportive buttresses and processes. The buttresses constitute the foundation required for resisting the forces of mastication; the processes are accountable for the form of the palate and midface. Ideally, the palatomaxillary surgical reconstruction should deal with both units (Cordeiro and Santamaria, 1999; Okay *et al*., 2001).

The anatomic complexity of the maxilla is related to its 3-dimensional construct that is supported by 3 separate vertical buttresses: nasomaxillary; zygomaticomaxillary and pterygomaxillary, which form as an adaptation to the vertical forces of mastication. In order to provide a stable occlusal surface, the integrity of these constructions is critical. In addition, the distribution of forces across the skull base will become even.

The maxillary processes are 4: zygomatic; alveolar; palatine and frontal. Zygomatic and alveolar processes play a major part in the midface shape. A symmetry and projection of malar eminence are provided by the zygomatic process. Reconstruction of the hard palate, alveolus, anterior wall of the maxilla and lateral nasal wall should be included in the maxillary reconstruction. These structures offer cosmetic and functional characteristics of the face. Reconstruction of the buttress systems and processes ensure a stable base for occlusion, which is essential to optimal functional and aesthetic rehabilitation (Okay *et al*., 2001).

The different shapes and sizes of tumours affecting the maxilla and the complex surgical anatomy can result in defects ranging from the small oroantral fistula to large cavity bound by the tongue inferiorly and anterior skull base superiorly (Futran and Mendez, 2006). Because of its close relationship with many critical anatomic structures, the maxillary bone is usually included when resecting tumours that arise from the paranasal sinuses, palate, nasal cavity, orbital contents, overlying skin, or intraoral mucosa (Cordeiro and Santamaria, 1999). Maxillectomy associated morbidity is rarely trivial and potentially involves impairment of deglutition and nutrition; orbital function and vision; speech and communication; self-image and mental health; hygiene maintenance and social acceptability (Futran and Mendez,1999).

Individuals with a diagnosis of orofacial cancer are overwhelmed by the concept of potential functional defects due to surgery, radiation and chemotherapy treatments. Often, functional limitations that restrict eating and talking are obvious and contribute to job loss, social isolation and decreasing quality of life. This may lead to patients being unable to look after their loved ones and taking care of themselves. Lack of employment places a financial strain on society when these individuals depend on social welfare systems (Ruben, 2000). Health-related quality of life should therefore become one of the primary determinants of outcome for treatment of patients with head and neck cancer (Breeze *et al*., 2016).

Reconstruction of the maxillary defect bears a significant challenge because the 3-dimensional midface architecture has both functional and aesthetical functions (Andrades *et al*., 2011). On the basis of these considerations, the overall objective is to replace the native tissue function and form. Ideal reconstruction of maxillary defects particularly requires, in order of importance, the presence of a healed wound; separation of oral and nasal cavities; restoration of maxillary buttresses; restoration of functional dentition; mastication and deglutition; re-establishment of globe position or addressing an exenterated cavity cosmetically; maintenance of a patent nasal airway; support and suspension of adynamic facial soft tissue; including the avoidance of ectropion ; and the restoration of an adequate and symmetrical facial form on the contralateral side and psychological well-being (Andrades *et al*., 2011; Chigurupati *et al*., 2013)

Complex reconstructions had no place in the management of maxillectomy patients until the 1990s. The aim was to produce a clean, skin-grafted cavity to facilitate surveillance and to restore oral competence with a dental obturator when the palate was resected. (Aramany, 1978; Spiro *et al*., 1997). This rehabilitative method had advantages such as immediate restoration of functional and aesthetic dentition; oronasal separation essential for speech and swallowing; lack of donor site morbidity; support of facial profile; improved quality of life and ongoing tumour surveillance (Futran and Mendez, 1999; Chen *et a*l., 2016). However, the obturator was limited by problems such as the discomfort of wearing a prosthesis; the inconvenience of removing and cleaning the prosthesis; the inability to retain a prosthesis successfully when defects are large or dentition is missing; and the frequent need for prosthetic adjustment in cases of adjuvant radiotherapy due to tissue contraction. (Triana *et al*., 2000; Brown and Shaw, 2010).

The theoretical benefit of obturator over the flap in terms of recurrent tumour detection is unproven. This is likely due to the accuracy and availability of modern imaging techniques, which allows a precise evaluation of the resection bed without direct inspection (Futran and Haller, 2005).

Several studies on maxillectomy patients reconstructed with the prosthetic obturator showed a strong relation between the quality of life and the obturator function (Breeze *et al*., 2016; Chen *et al.,* 2016; Irish *et al*., 2009). Clinical impressions indicated that a wide range of factors may influence quality of live in these patients, including tumour type and stage; medical comorbidity; time since surgery; size of ablative defect; post-surgery radiation therapy; the number and state of maxillary teeth left; periodontal health; the root form of teeth; demographic and other social variables (Okay *et al*., 2001).

A pressure-resistant seal of the obturator bulb against the mucous lining and skin graft restores speech and swallowing functions. Coordinating surgical considerations for prosthodontic rehabilitation of maxillary defects enhances prosthetic prognosis and functional outcomes. The remaining palate and dentition are used to improve support, stability, and retention of the obturator bulb by means of a successful prosthetic design for the functional restoration of the maxillectomy defect. Instability of the obturator results in air and fluid leakage through the nasal cavity and thereby compromises function (Okay *et al*.,

2001). Okay *et al.,* (2001) noted that prosthesis effectiveness was impaired as the magnitude of the defect increased, leading to poor obturator function and quality of life.

The distance of the direct retainer to the fulcrum line of the prosthesis can also affect the stability of the obturator. Rogers *et al*., (2003) observed that there are lower scores of activity, physical function, recreation and general quality of life in patients with larger defects. Kornblith *et al.,* (1996) reported that patients who had no more than a third of the soft palate and a fourth of the hard palate resected had better speech scores and overall obturator function. Okay *et al.,* (2001) demonstrated that defects involving greater than half the hard palate or involved the premaxilla and both canines resulted with poor prosthetic stability and retention.

Chen *et al.,* (2016) showed that addition of retentive attachment to obturator prostheses improves oral function. They reported that patients who received enhanced retentive obturator prosthesis with stud attachment demonstrated better speech, chewing and swallowing compared with those who received conventionally retained obturator prosthesis and enhanced retentive obturator prosthesis with magnetic attachment. This finding corroborates the one reported by Murat *et al*., (2012).

Boyes-Varley *et al.,* (2007) developed a protocol for maxillary defect reconstruction using zygomatic implants supported obturator, which they reported to be more stable and circumvent complications associated with biomechanics and decay of remaining dentition, particularly in irradiated patients, thus resulting in improved quality of life. Chigurupati *et al.,* (2007) also reported a similar finding. Costa *et al.,* (2015) however, questioned these findings citing that, an adequate consensus has not been reached, and that long term results are in doubt, the experience is small and the report included only patients with class I and II of Okay's classification.

The use of various autogenous pedicled tissues in reconstruction of maxillary defect dates back to the 19th century. Von Langenbeck described local palatal flaps for small defects in 1862, and Gullane *et al* revisited them in 1977. The use of flaps such as the nasal septum, tongue, cheek, upper lip, pharynx, turbinate, forehead, and cervical flaps was notable in the middle of the 20th century (Chambers *et* al*.,* 1969; Elliot, 1976). These techniques have been mainly substituted by pedicled myocutaneous flaps in the sixties and seventies.

Myocutaneous flaps accommodated large defects through an adequate amount of well-vascularized tissue, however, these flaps are usually bulky and poorly pliable (Baker,1984). This type of reconstruction was not ideal considering the complex anatomy of defects after maxillectomy.

The development of microvascular anastomotic techniques in the 1980s allowed for the transfer of free tissue, which resulted in an incredible breakthrough in the reconstruction of defects in a single stage without limitation of the reach and orientation of regional, myocutenous pedicled flaps.

The emergence of microsurgery also allowed the primary reconstruction of these challenging defects in a single-stage, circumventing the utilization of different combinations of local and regional flaps which produce poor functional and aesthetic outcomes (Disa *et al*., 2001; Rosenthal *et al*., 2004). In retrospective non-randomized studies, several authors have tried to compare functional and aesthetic outcomes in terms of obturation and reconstruction, usually with free flaps. The conclusion was that, reconstruction has advantages that are more assured in larger defects (Brown *et al*., 2000; Cordeiro and Santamaria, 2000; Gomes *et al*., 2013; Rogers *et al*., 2003).

The microsurgical reconstruction allows different types of donor tissue to be used, enabling a surgeon to customize the reconstruction suitable for the defects. The various nuances of soft tissue and osseous shape, bulk, and quality can be included into the reconstructive plan (Futran and Mendez, 2006).

Various donor sites for free-tissue transfer have been described for defects after maxillectomy including iliac crest; fibula; radial forearm; rectus abdominis; scapular system and anterolateral thigh (ALT). The regional flaps include temporalis; sternocleidomastoid and pectoralis major flaps, these flaps however result in some poor aesthetic deficit (Futran *et al*., 2002; Genden *et al*., 2001; Macleod *et al*.,1987; Nakayama *et al*., 1995; Olsen *et al*., 1992). Selection of flaps is determined by different factors including donor site vascular condition, flap surface to volume ratio, tissue pliability, bone thickness, donor site morbidity and pedicle size and length. The amount, location and quality of the midface residual bone and dentition or denture-bearing alveolar arch largely determine if a flap containing a bone is necessary or not (Futran and Mendez, 2006).

When only the soft tissue of the palate is reconstructed, conventional dentures provide functional dentition if adequate teeth and retentive surfaces are available to provide stability. In many cases, soft tissue reconstruction alone lacks bony support, resulting in a flatter surface of the maxillary arch and flap ptosis. Blunted neoalveolar contours are created and the gingival buccal sulcus and palatal arch depth are lost, resulting in a trampoline-like surface so that the reconstructed maxilla is poor at retaining the denture (Futran and Haller, 2005). If sufficient underlying bone is available, osseointegrated implants could overcome this issue. Other techniques to circumvent this problem include suture suspensions and fascial manipulation to prevent prolapse of the intraoral flap (Sullivan *et al.*, 2002).

Although the reconstructive method selected is based on the extent of the bony and soft-tissue defect, there is generally no definite or commonly recognized recommendation. A number of authors proposed the treatment algorithms (Andrades *et al*., 2011; Costa *et al*., 2014; Brown and Shaw, 2010). Reconstruction of bone should be considered in medium to large defects with good oncological prognosis whenever oral rehabilitation, midface contour and orbital support are a priority. While these defects also can be reconstructed with a prosthetic obturator or a vascularised free soft tissue flap, vascularised bone flaps are often essential to reconstruct the midfacial height, width, and projection, as well as to provide adequate bone stock for mastication and osseointegrated implants, which are usually required for dental prosthesis fixation (Andrades *et al.,* 2011).

The fibula, osteocutenous radial forearm, iliac crest and subscapular system of flaps are the most commonly used free tissue flaps for bone, soft tissue palate and maxillary reconstruction. Prior to reconstruction, the surgeon must determine the extent of the skin, soft tissue and bone defects and also consider several prerequisites when planning midface reconstruction. Free flaps should be anastomosed to reliable large vessels, which are often resected with maxillectomy. There is a minimum distance of 10 to 12 cm from the ipsilateral neck to the midface, so the flaps with a long pedicle and good vessel diameter to avoid vein grafting is required. (Andrades *et al.,* 2011).

The osteocutenous radial forearm free flap with a thin bone, a versatile skin paddle and a long pedicle is a reliable flap that can easily be harvested in a two team approach (Chepeha et al, 2005). The bone can be aligned horizontally for alveolar reconstruction, obliquely for

zygomaticomaxillary buttress reconstruction or osteotomized for reconstruction of the inferior orbital rim. (Andrades *et al*., 2008; Chepeha *et al*., 2005). In the paranasal region, the skin paddle can be oriented to restore the mucosal defect, or even advanced superiorly to pad the midface or fill in a cutaneous defect. To avoid the risk of donor site fracture, the surgeon should prophylactically plate the radial bone. Harvesting radial bone thickness of less than 40% and use of keel-shaped osteotomies can also reduce this risk. This flap is suited for patients with inferior maxillectomy defects sparing the infraorbital rim and requiring mucosal lining with small bone defect (Andrades et al., 2011).

The fibula has an excellent bone volume and is regarded by many as a workhorse flap for reconstruction of neck and head. It also has a long pedicle with a good diameter and a soft pliable skin paddle that can be used on the midface defects crossing the palatal midline. The surgeon has the option of placing osseointegrated implants immediately or secondarily (Virgin *et al*., 2010). Reconstruction of the palate, anterior maxilla and infraorbital rim requires multiple osteotomies with severe angles, these, together with skin island orientation can be challenging. Large defects reconstruction often results in flat cheek with poor cosmetic outcome (Futran *et al.,* 2002). The best candidates for this flap are patients with an inferior maxillectomy without involvement of the inferior orbital rim, defect extending through the mid-line and requires the use of osteointegrated dental implants for oral rehabilitation (Andrades et al., 2011).

The iliac crest free flap based on the deep circumflex iliac artery (DCIA) harvested with an internal oblique muscle provides full maxillary reconstruction. One part restores the infraorbital rim, zygomatic prominence, alveolus and the muscle is used for restoration of the sinus lining (Genden *et al*., 2001). This flap has however excessive bulk, limited soft tissue mobility in relation to bone, donor site morbidity and short pedicle length. This flap is suited for patients with total maxillectomy defects with or without sacrifice of infraorbital rim with preservation of orbital contents (Andrades., 2011).

The subscapular system of flaps provides the greatest versatility in maxillectomy reconstruction (Bidros *et al*., 2005). The scapular tip (supplied by the angular branch of the thoracodorsal artery) restores the orbital floor and rim, the lateral part of the scapula (supplied by the circumflex artery) restores the alveolar arch inferiorly. The disadvantage for this flap includes complex harvesting and a short pedicle length.

A combination of microvascular free-tissue transfer, local flaps or maxillofacial prosthesis with or without osseointegrated implants is usually required to meet the goals of maxillary reconstruction, namely functional and aesthetic restoration. The complexity of the technique, patient factors and the size of the defect should all guide the ultimate reconstructive options post maxillectomy.

Maxillectomy is an uncommon procedure in many maxillofacial units, resulting in several authors developing algorithms for treatment of these complex defects in their respective units without a universal consensus. Wits Maxillofacial and Oral surgery unit has performed a significant number of maxillectomies but never reported its experience in these challenging defects. Against this background, this study is undertaken to report our experience on maxillectomies. Data obtained from this study will provide valuable information on the demographics and treatment of maxillectomies, and could serve as the basis for a future treatment algorithm.

Chapter 2 : Research design

2.1 Aim

The aim of the study is to perform an audit of maxillectomies done at Wits Oral Health Centre over a ten-year period (from January 2008 to December 2018).

2.2 Objectives

To describe the profile of the patients who received maxillectomy in the department

To evaluate the pattern of maxillectomy in the department.

To determine the indications for maxillectomy in the department.

2.3 Material and Methods

2.3.1. Study design

This is a retrospective cross-sectional study of the patients who had maxillectomy at Wits Oral Health Centre, Department of Maxillofacial and Oral Surgery, University of Witswatersrand, Chris Hani Baragwanath Academic Hospital (CHBAH) and Charlotte Maxeke Johannesburg Academic Hospital (CMJAH).

2.3.2. Sample size

All patients who had maxillectomy at Wits Oral Health Centre, Department of Maxillofacial and Oral Surgery, from both CHBAH and CMJAH (from January 2008 to December 2018).

2.3.3. Inclusion criteria

All patients who had maxillectomy in the department from 2008 to 2018 will be included in the study.

2.3.4. Exclusion criteria

All patients with missing records will be excluded.

2.3.5. Methodology

Hospital outpatient department and theatre records were used to collect patients' information. The variables recorded on the data collection sheet included the following: patients' age, gender, the aetiology of maxillectomy, classification of maxillectomy according to Brown's classification (Figure 2.1), rehabilitative modality and complications.

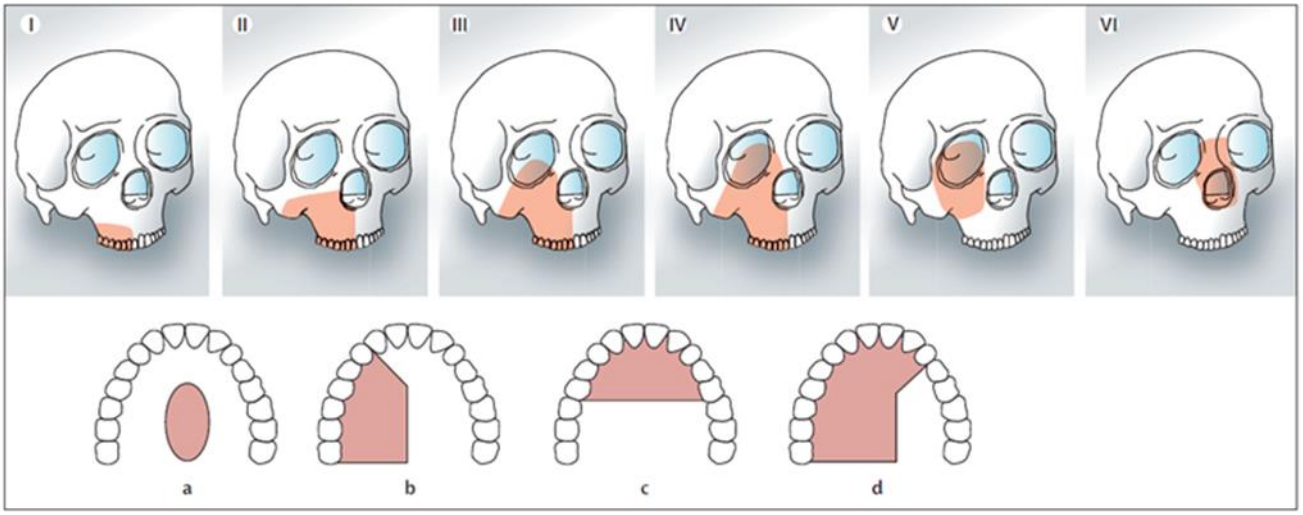

Figure 2.1: Classification of Vertical and horizontal maxillectomy and midface.

Vertical classification: I-maxillectomy not causing an oronasal fistula; II-not involving the orbit; III-involving the orbital adnexae with orbital retention; IV-with orbital enucleation or exenteration; V-orbitomaxillary defect; VI-nasomaxillary defect. Horizontal classification: a-palatal defect only, not involving the dental alveolus; b-less than or equal to ½ unilateral; c-less than or equal to ½ bilateral or transverse anterior; d-greater than ½ maxillectomy (From Brown and Shaw, 2010).

2.4 Data management and analysis

Categorical data was summarised using frequencies and percentages. Associations between categorical variables were assessed using the chi-squared test. Continuous data was assessed for normality and where appropriate summarised as means and standard deviation. All data collected was entered into REDcap and transferred into the latest version of stata (StatCorp, USA) software for analysis. All analyses were performed at the 95% confidence interval.

2.5 Ethical considerations

Ethical clearance (**M190233**) was sought from the Human Research Ethics Committee of the University of the Witwatersrand prior to commencement of the study. Permission to access patients' records was sought from the CEO of WOHC; CMJAH and CHBAH, and the head of Maxillofacial and oral surgery department. Patients' personal information was kept confidential to protect their identity and each patient was allocated unique identity code.

Chapter 3 : Results

3.1 Demographic data

Over the period of ten (10) years from 2008 to 2018, data from 47 patients with maxillectomies carried out from the two units of our department were retrospectively recorded and reviewed. Three (3) patients were excluded from this study owing to insufficient records, hence only 44 patients were analysed. Of the 44 patients, 21(47.7%) were males and 23 (52.3%) were females, with a male to female ratio of 1:1,015. There was no significant difference (P=0.963) in the proportions of patients' gender. Figure 3.1 shows the distribution of patients by gender.

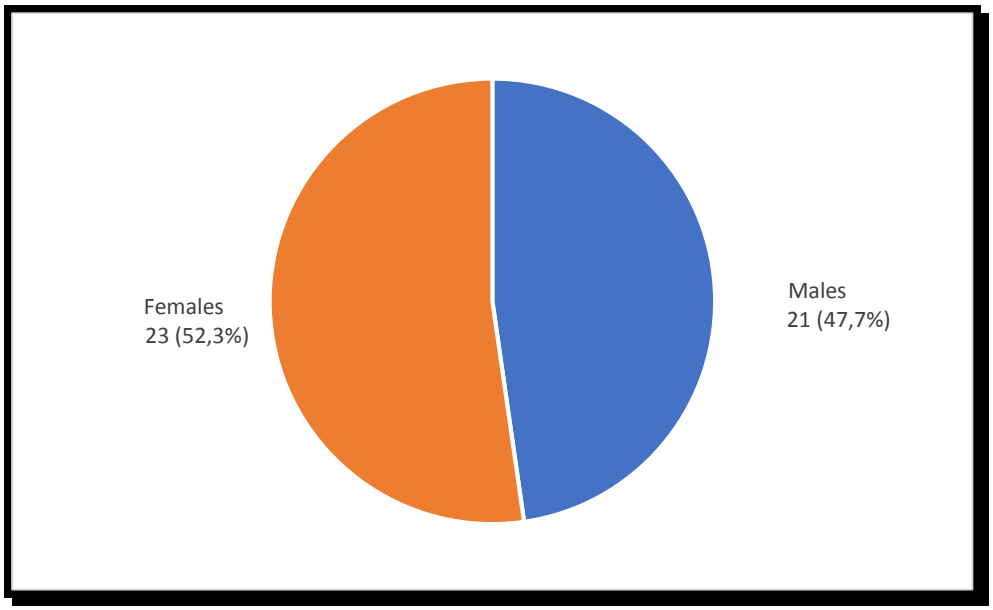

Figure 3.1: Distribution of patients by gender

The minimum age was one (1) and the maximum age was 73 years, with the majority (38.6%) of the patients in the age group of 41-60 years. The mean age for males was 36.2 (15.1) and 36.0 (17.7) for females, with a total mean age of 36.1(16.3). Figure 3.2 shows the distribution of patients by age.

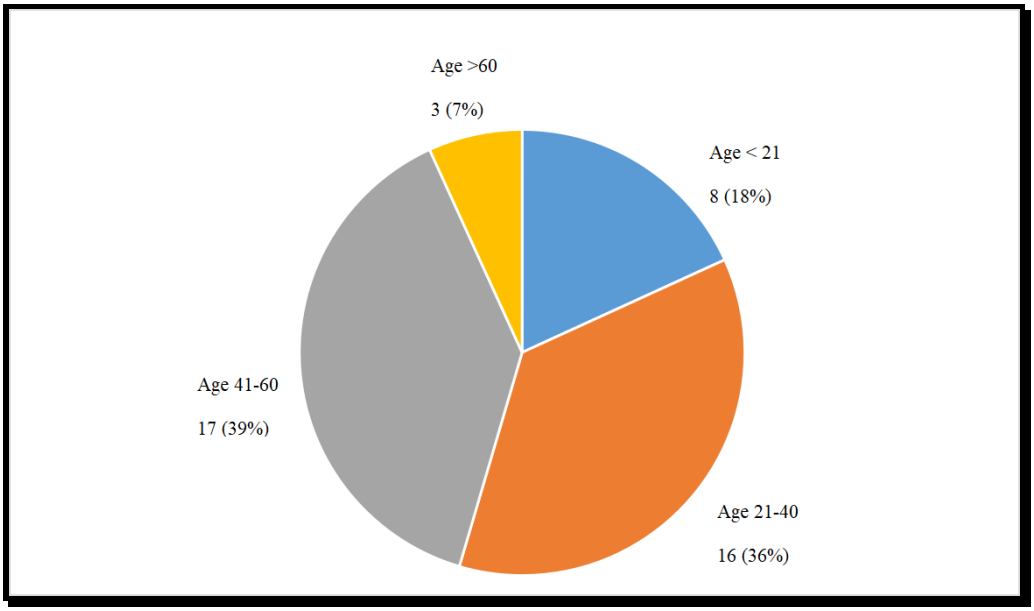

Figure 3.2: Distribution of patients by age

3.2 Indications for maxillectomy

The indications for maxillectomy included pathology (40 patients) and trauma (4 patients). There was a statistically significant difference between pathology and trauma as the reasons for maxillectomy. The most common indication for maxillectomy was pathology (90.9%) with an almost equal distribution between benign ((47.5%) and malignant (52.5%) lesions (Tables 3.1 and 3.2). Amongst the benign lesions, ossifying fibroma (26.32%) was the predominant pathology, followed by conventional ameloblastoma (15.79%). Squamous cell carcinoma (33.33%) was the leading malignant lesion, followed by osteosarcoma (14.29%). Amongst the 40 patients who underwent maxillectomy following pathological lesions, 18(45.0%) patients were males and 22(55.0%) were females. Out of the 19 patients with benign lesions, 10(52.6%) patients were males and 9(47.4%) were females. Of the 21 patients with malignant lesions, 8(38.0%) patients were males and 13(61.9%) were females. Of the 4(9.1%) patients who underwent maxillectomy following trauma, 2(50%) patients sustained gunshot wound (GSW) and 2 (50%) sustained motor vehicle accident (MVA). Three (75.0%) patients were males and one was female.

Table 3.1: Distribution of patients by malignant lesions.

MALIGNANT LESIONS	FREQUENCY	PERCENT
Adenoid cystic carcinoma	1	4.76
Ameloblastic carcinoma	1	4.76
Peripheral nerve sheath tumour	1	4.76
Mucoepidermoid carcinoma	1	4.76
Nasopharyngeal carcinoma	2	9.52
NonHodgkin's lymphoma	1	4.76
Polymorphous low-grade adenocarcinoma	1	4.76
Rhabdomyosarcoma	1	4.76
Spindle cell carcinoma	2	9.52
Osteosarcoma	3	14.29
Squamous cell carcinoma	7	33.33

Table 3.2: Distribution of patients by benign lesions

BENIGN LESIONS	FREQUENCY	PERCENT
Calcifying odontogenic cyst	1	5.26
Fibrous dysplasia	1	5.26
Juvenile aggressive ossifying fibroma	1	5.26
Juvenile ossifying fibroma	1	5.26
Medical-Related Osteonecrosis of the Jaws	1	5.26
Mucormycosis	1	5.26
Myxofibroma	2	10.53
Osteoradionecrosis	1	5.26
Unicystic ameloblastoma type 3	1	5.26
Odontogenic myxoma	1	5.26
Ameloblastoma	3	15.79
Ossifying fibroma	5	26.32

3.3 Classification of maxillectomy according to brown's classification (2010)

Surgical procedures carried out for these patients ranged from type I-IV of Brown's vertical classification and type B-D of Brown's horizontal classification. There were no patients with Brown's type V; VI and A defects (Figure 2.1 and 3.3). There were 33(75.0%) patients with Brown's type II defect following maxillectomy. Of these patients, 16(48.5%) had malignant lesions;14(42.4%) had benign lesions and the other 3(9.1%) patients sustained trauma. Eighteen (54.5%) of the 33 patients were males. Amongst all various defects, Brown's type IIB (38.6%) was the most common surgical procedure, followed by Brown's type IID which was carried out in 27.3% of the patients. Of the 44 patients, 21(47.7%) were rehabilitated with only dentate supported prosthetic obturator, most of whom had type IIB defect following maxillectomy.

Surgical procedures involving orbital adnexae (Brown's type III) defect, were only carried out in 8(18.2%) patients. Six (75.0%) of these patients had type IIID defect and the 2 other patients had type IIIB defect. Of the total 44 patients, 6(13.6%) patients were reconstructed with vascularised free fibula graft and 4 of these patients were females and 4 had malignant lesions. Of these 6 patients, 3(50.0%) patients had type IIID defect. and the other 3 patients had type II defect (2 IID and 1 IIB). The other 2 patients with type III defect were reconstructed with zygomatic implants supported obturator.

Out of the two (4.6%) patients with type IV defect following malignant lesions resection, one patient with adenoid cystic carcinoma was reconstructed with standard and zygomatic implants supported obturator with anterolateral thigh flap obturating the orbital defect, and the other patient had standard and zygomatic implants supported obturator with abdominal rectus flap and prosthetic eye after squamous cell carcinoma resection. These patients were females. The one patient with type IB (2.3%) defect had medication-related osteonecrosis of the jaw (MRONJ) and was one of the patients who received an obturator.

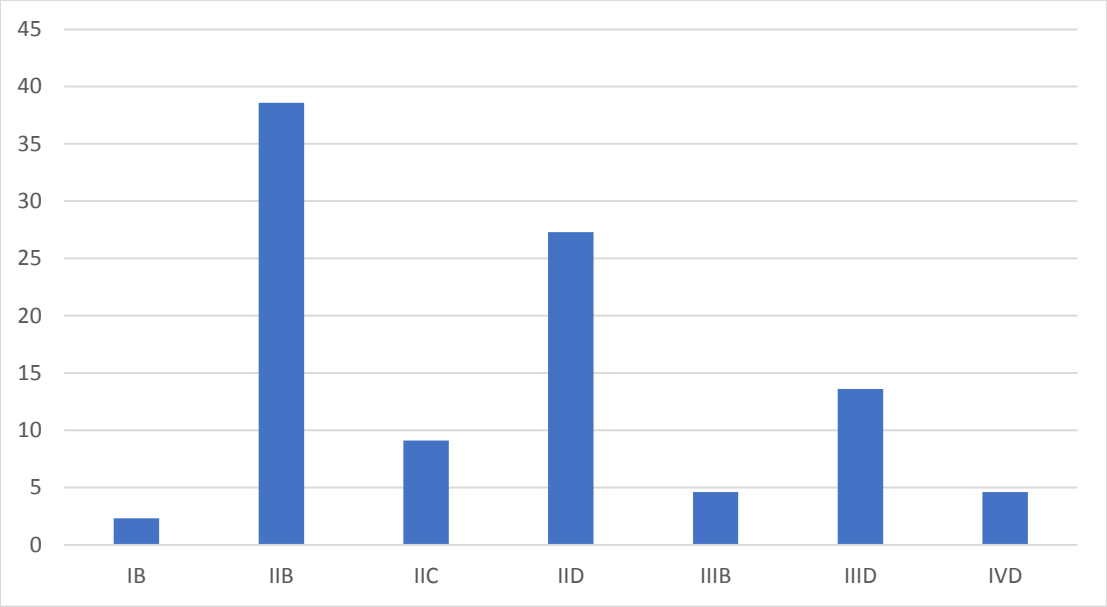

Figure 3.3: Distribution of patients by Brown's classification.

3.4 Rehabilitative modalities

The obturator (47.7%) was the commonly used rehabilitative modality, followed by standard and zygomatic implants supported obturator in 6(13.6%) patients. Four (66.7%) of these patients had type II defect, mainly with type IID defect. Three (6.8%) patients were reconstructed with vascularised free fibula graft and standard implants supported obturator, 2 of these patients had type II (B and D) and 1 had type IIID. Only 2(4.6%) patients with type IID defect were reconstructed with zygomatic implants supported obturator. The remaining patients with different defects were reconstructed with various autogenous and alloplastic grafts (Table 3.3). Figure 3.4 shows a case of a 23 years old male patient with type IID defect rehabilitated with a prosthetic obturator following resection of osteosarcoma.

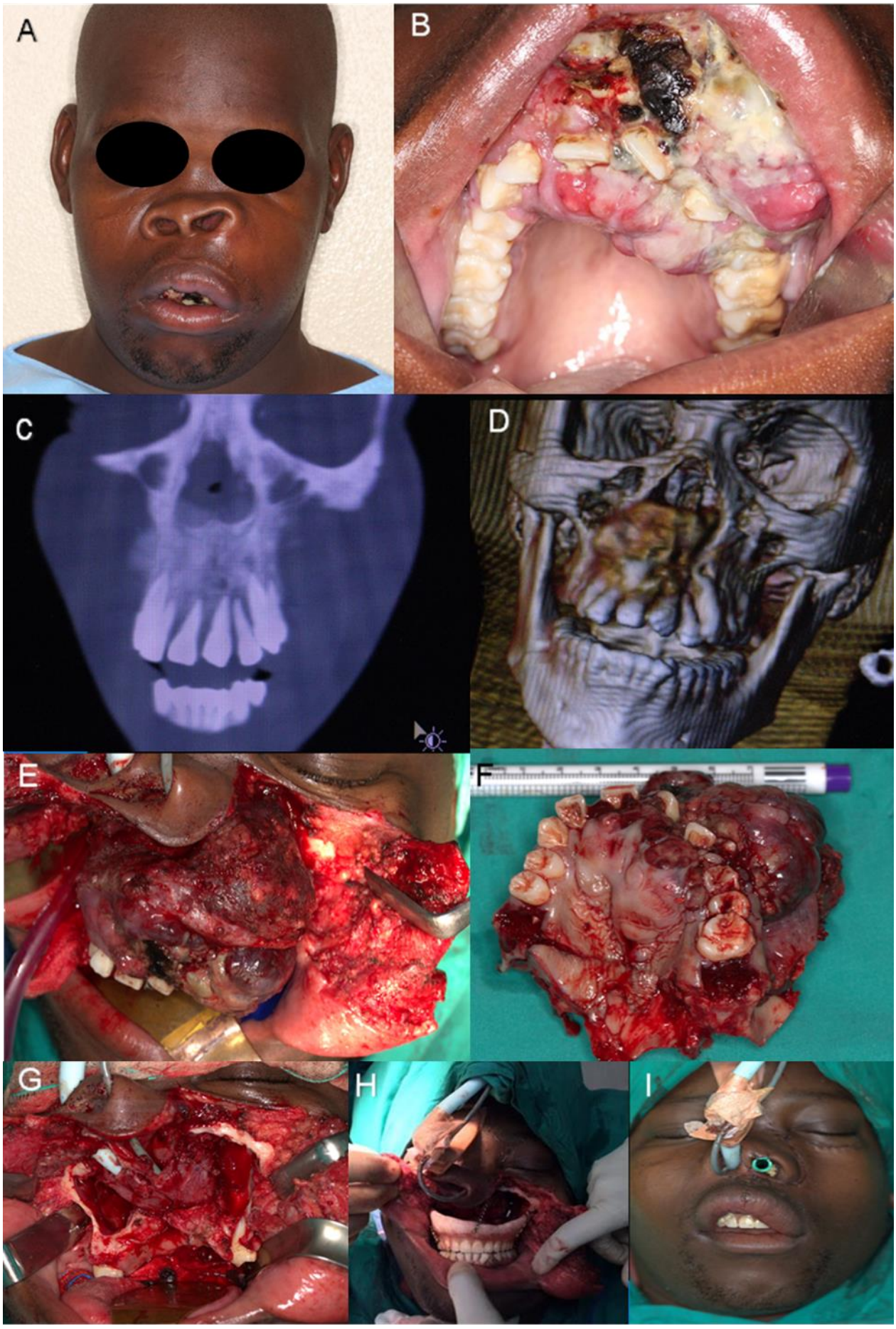
A
B
C
D
E
F
G
H
I

Figure 3.4: (**A-I**). (**A**) A 23 years old male patient with maxillary osteosarcoma. (**B**) An intra-oral view showing fungating mass with displaced teeth. (**C**) Coronal bony window of computed tomography (CT) scan showing classic “sunburst” appearance. (**D**) A 3-Dimensional reconstruction of CT scan. (**E**) A tumour exposed via modified Weber-Ferguson approach. (**F**) A tumour resected in its entirety. (**G**) A type IID Brown’s maxillectomy defect. (**H**) An obturator secured with miniplates to remaining defect. (**I**) A patient with stent to keep nasal passage patent.

Table 3.3: Distribution of rehabilitative modality by patients

REHABILITATIVE MODALITY	FREQUENCY	PERCENT
Abdominal flap Iliac crest flap Rib flap and obturator	1	2.27
Abdominal flap Obturator and titanium orbital mesh	1	2.27
Abdominal rectus flap Standard and zygomatic implants supported obturator Prosthetic eye	1	2.27
Alt flap and obturator	1	2.27
Alt flap Standard and zygomatic implants supported obturator	1	2.27
Obturator Titanium orbital mesh	1	2.27
Orbital titanium mesh Standard implants supported obturator FFF	1	2.27
Orbital titanium mesh Standard and zygomatic implants supported obturator	1	2.27
Orbital titanium mesh Skin flap and zygomatic implants supported obturator	1	2.27
Radial forearm flap Zygomatic implants supported obturator	1	2.27
Radial forearm flap Obturator Titanium orbital mesh FFF	1	2.27
Zygomatic implants supported obturator FFF	1	2.27
Zygomatic implants supported obturator	2	4.55
Standard implants supported obturator FFF	3	6.82
Standard and zygomatic implants supported obturator	6	13.64
Obturator	21	47.73

3.5 Complications associated with rehabilitative modalities

Of the total 44 patients, 25(56.8%) presented with a wide variety of complications associated with rehabilitative modality employed. The most common complications recorded were loss of implants and obturator instability. Nine (9) implants were lost from 6(24.0%) patients (ranging from 1 to 2 implants per patient). Five (83.3%) of these patients had 8 standard implants and 1 patient had 1 zygomatic implant. Five (62.5%) of the 8 lost standard implants were placed in the fibula flap and most (4) of these implants were placed during the reconstruction procedure. All the six patients who lost their implants had

malignant lesions and 5 were females. There was no significant correlation between the instability of the obturator and any of the variables recorded in the 6 patients.

Four (16.0%) patients had complete autogenous graft failure, 2 of these patients had vascularized free fibula flaps (FFF). All these patients were regrafted with different flaps. Three (12.0%) patients with malignancy developed tumour recurrence (2 of these 3 were recurrent salivary gland tumours). Table 3.4 shows various complications associated with rehabilitative modality.

Table 3.4: Distribution of complications by patients

COMPLICATIONS ASSOCIATED WITH REHABILITATIVE MODALITY	FREQUENCY	PERCENT
Tumour recurrence	3	12,0
Obturator instability	6	24,0
Flap failure	4	16,0
Bulky flap One implant loss	1	4,0
Collapsed nasal bridge	1	4,0
Enophthalmic eye Septic titanium mesh	1	4,0
Dehisced fibula One implant loss	1	4,0
Enophthalmic prosthetic eye Two implants loss	1	4,0
Oronasal communication	1	4,0
Oronasal communication Two implants loss	1	4,0
Dehisced FFF Two implants loss	1	4,0
Plate fracture One zygomatic implant loss	1	4,0
Osteomyelitic FFF Ectropion Proptotic eye Diplopia	1	4,0
Fibrous dysplasia regrowth	1	4,0
Oroantral communication and oronasal communicatiom	1	4,0

Chapter 4 : Discussion

This study aimed to retrospectively audit maxillectomy performed in our department in a period of 10 years from 2008 to 2018. A total of 44 patients who met the inclusion criteria were included in the present study.

The gender proportion (male to female ratio of 1:1,015) of this study was almost equal, with 23(52.3%) females, slightly outnumbering the males. This finding was in consonance with reports by Akinmoladun *et al.,* (2018) and Eziyi *et al.,* (2013) but varied from that of Fomete *et al.,* (2017) and Mazlina *et al.,* (2006) who reported more males in their study. The only possible reasons for this small margin in this study could be our small sample size and possibly the fact that females are more health-conscious, presenting early to hospitals. The majority of the patients were in the age of 41-60 years, with a mean age 36.1. This finding is not surprising because malignant tumours were the most common indication for maxillectomy in this study and this age group, together with other factors are reported as the risk factors for cancer development (Walden and Aygun, 2013).

Pathology and trauma were the main indications for maxillectomy, with malignancies constituting more than half (52.5%) of the pathologies. Squamous cell carcinoma was the most common malignancy. This finding concurs with that reported by Ogunlewe *et al*., (2001) and Djae *et al*., (2011) but contrasts with findings by Chen *et al.,* (2015) and Akinmoladun *et al*., (2018), who reported adenoid cystic carcinoma as the more prevalent malignancy. Squamous cell carcinoma was the commonest reported tumour affecting maxillary and ethmoid sinuses (Lewis and Castro., 1972). Due to late presentation, the majority of maxillary antral carcinoma patients present with radiological evidence of bony wall destruction. Lewis and Castro (1972) further reported that plain radiological evidence of bony wall destruction was seen in approximately 69% of maxillary sinus neoplasms. In agreement with the literature regarding gender proportion in this tumour, males in this study constituted 71.4% of patients with squamous cell carcinoma (Walden and Aygun, 2013). Osteosarcoma was the second most malignancy constituting 14.3%.

Ossifying fibroma was the most common benign tumour in the present study constituting 26.32%. This finding varied from reports by Chigurupati *et al*., (2013) and Mazlina *et al*., (2006) who reported ameloblastoma and inverted papilloma as the leading benign tumours respectively. Most studies (Chigurupati *et al*., 2013; Djae *et al.,* 2011 and Mazlina *et al*.,

2006) on maxillectomy reviewed only patients with tumours as indications for these defects. This is possibly because of low trauma prevalence in these developed countries or the studies focused only on tumours as indications for maxillectomy. In this study, 4(9.1%) patients had maxillectomy following trauma, which possibly reflects a high prevalence of trauma in our country.

For the purpose of our study, we chose to use modified Brown's classification (Brown and Shaw, 2010) on the basis of its practicality and clinical applicability. In this classification, vertical and horizontal components are evaluated independently, then combined to provide a 3-dimensional description of the defect. This 2-part classification system provides a simple technique of precisely describing even the most complex maxillary defect using the combined independent horizontal and vertical dimensional evaluations. (Lenox and Kim, 2013). The vertical dimension (I-VI) shows the degree of unilateral involvement and emphasizes the orbital involvement. While the horizontal (a-d) dimension indicate the sacrificed amount of palate and alveolar ridge. This audit included patients with Brown's type I-IV and B-D. There were no patients with type V; VI and A defects (Figure 3.3).

Type I defects include alveolus and palate, with preservation of maxillary antrum. There are a variety of reconstruction methods for this defect including prosthetic obturator; local flaps (temporalis and temporoparietal); soft tissue free flaps (ALT and radial) and composite flap such as radial forearm fasciocutaneous flap (RFFF). Andrades *et al.,* (2011) recommended prosthetic rehabilitation for these defects in patients who have not undergone radiation therapy. In contrary, Brown and Shaw (2010) reported that RFFF produced the best reconstructive solution for type I defect. Our study reports one patient with type IB defect who had MRONJ, this patient was rehabilitated with obturator and we achieved excellent aesthetic and functional results.

Type II defects involve half or less than half of unilateral maxilla. A potential reconstructive option includes obturator; local pedicled tissue flaps and microvascular free tissue flaps. Obturator can achieve acceptable results in patients with type IIB posterior defect with sound ipsilateral canine and incisors. Of the 33(75.0%) patients with type II defect, 19(57.6%) patients were rehabilitated with an obturator (11 IIB; 3 IIC and 5 IID). Only one patient with type IIB had regrowth of fibrous dysplasia and complained of the unstable obturator, giving obturation 95% success rate in these defects. This success rate validates

report by Chigurupati *et al.,* (2013) that, the size of the defect does not correlate with obturator on patients with type II defects. In contrast, although they did not specify the defect types, Okay *et al.,* (2001) concluded that the stability of prosthesis was compromised as the defect size increases.

The remaining 14 patients with type II defects were reconstructed with various microvascular free tissue transfers and standard or zygomatic implants supported obturator (RFFF, ALT, FFF, and Iliac crest). Boyes-Varley *et al.,* (2007) reported good results with zygomatic implants supported obturator in patients with type IID defects, a finding that was validated in this study. Amin *et al*. (2005) and Djae *et al*. (2011) recommended temporal fat pat and buccal flaps to be an ideal local options for select oro-antral and oro-nasal fistulae closure. They reported excellent outcomes with 100% flap survival rate in terms of speech, mastication, swallowing and appearance

For the restoration of type II defects, FFF is favourably recommended; arguing that it provides best results and allows for reliable placement of dental implants. The pedicled flap has a good size and length, the donor and recipient surgical sites allow for an easy and effective two-team approach and the complications on the donor site are acceptable (Yamamoto *et al.,* 2004; Peng *et al*., 2005; Yazar *et al.,* 2006). Shen *et al.,* (2011) reported good aesthetic and functional results when using computer assisted design and computer assisted manufacturing (CAD/CAM) vascularised fibula osteomyocutaneous flap to reconstruct patients with type IID and IA-D defects. Lenox and Kim (2013) recommended the use of strut grafts discarded from the fibula bone segments used in type IIC defects to support paranasal region. Their alternative in these defects was vascularised iliac crest flap. We, however, managed to achieve acceptable results in patients with type IIC defect rehabilitated with an obturator.

Defects of type III designates a moderate to large volume tissue requirement sacrificing all six maxillary walls. As facial soft tissue support is extensively lost and the orbital rim is destructed, type III defects are challenging to reconstruct. The goals for reconstructing these defects include orbital and facial soft tissue support; provide enough bone to guarantee alveolar residue and zygomatic buttress union; close the oronasal communication and oroantral communication and restore sufficient dental alveolus for implant placement. Two patients with type IIIB defects were rehabilitated with obturator and

titanium orbital mesh with good results. Again, confirming a finding by Chugurupati *et al* (2013). Three patients with type IIID defects were reconstructed with zygomatic implants supported obturator and titanium orbital mesh. Two patients had complications, one had collapsed nasal bridge which was corrected with rhinoplasty and the other one had enophthalmia which was corrected by replacement of mesh. The other three patients with type IIID defects were reconstructed with vascularized free fibula flap, all these presented with complications (i.e ectropion; lost implant; failed graft; recurrent tumour; ONC and exophthalmia). This finding shows that complications increase with the complexity of defect and reconstruction.

Brown and Shaw (2010) indicated that 58% of the cases reported in the literature used soft tissue flaps to reconstruct defects of type III. In addition to providing a bony reconstruction of the orbital rim; orbital floor and anterior maxillary wall, the non-vascularized bone may be used, however, the risk of graft failure need to be considered, particularly when postoperative radiation therapy will be required. The DCIA is recommended for reconstruction of large defects (i.e. type IIID). The block of iliac crest can be shaped according to the defect and contoured to reconstruct the orbital rim; facial form; support the missing zygomaticomaxillary and nasomaxillary buttresses and provide sufficient bone for implants placement. The attached internal oblique muscle is used to close the dead space; fistulae and allows for functional mucosal lining of nasal and oral cavity. (Brown and Shaw., 2010; Brown *et al*., 2002).

The subscapular system of flaps is another option for midface reconstruction. The missing alveolar arch is replaced with the lateral border of scapular (supplied by circumflex scapular artery) and the orbital floor and rim replaced by scapular tip (supplied by the thoracodorsal artery) (Andrades *et al*., 2011). Patients at risk of prolonged bed rest and postoperative gait disturbance are suitable candidates for scapula flap. The primary constraints of scapula flap include its poor bone volume; short pedicle length; inability to perform two-team approach and a need for intra-operative repositioning. Surgical technique by raising the flap on a thoracodorsal artery instead of the circumflex scapular artery improve the pedicle length (Lenox and Kim, 2013; Miles and Gilbert., 2011). No patient was reconstructed using this option in the present study.

Type IV defects mainly involve patients with poor prognosis (i.e stage IV disease) and this should be considered when selecting the most suitable reconstructive option. The focus is usually on disease eradication and life preservation; some functional and aesthetic objectives may be compromised to achieve the overall results. Reconstructive attempts should be aimed at eliminating dead space; creating a separation between the exposed dura and contaminated aerodigestive tract and preparing a mucosalised cavity to fabricate prosthetic eye.

This study included only two patients with type IVD defects following resection of malignant lesions. One patient who had adenoid cystic carcinoma was reconstructed with anterolateral thigh and standard and zygomatic implants supported obturator; this patient underwent debulking for flap ptosis and also lost one standard implant. The patient uses dark glasses to mask aesthetic deformity because prosthetic eye was not provided. The other patient who had squamous cell carcinoma was reconstructed with abdominal rectus flap and standard and zygomatic implants supported obturator; this patient developed enophthalmic prosthetic eye which was corrected, one implant was also lost in this patient.

The Latissimus dorsi; abdorminal rectus; DCIA and ALT flaps provide good results for reconstruction of type IV defects depending on the surgeons' preference. The abdominal rectus has the lowest incidence of vascular thrombosis and overall flap failure due to its large calibre vessels and low risk for atherosclerosis. Flap ptosis following radiation therapy will typically need flap revision. This problem can be prevented with the use of miniplates; titanium mesh; fascial sling sutures and other implantable devices (Lenox and Kim, 2013; Andrades *et al*., 2011).

Some authors have substantiated the claim that the free fibula flap is less than optimal to reconstruct type III/IV defects due to problems with several osteotomies and skin paddle alignment (Futran *et al*., 2005; Peng *et al*., 2005). However, Shen *et al.,* (2011) demonstrated the success of fibula flaps in these defects using CAD/CAM model and predictive surgical design software circumventing these technical drawbacks. The use of this software enabled a more effective layout of osteotomy intraoperatively, reduced operating time and produced overall predictable reconstructive outcomes.

The most common complications noted in the present study were implant loss and obturator instability. Most of the lost implants placed in the fibula flap during reconstruction procedure were in patients who had squamous cell carcinoma. This finding suggests the type of tumour may have an influence on the failure of the implant. De Ceulaer *et al*., (2010) and Pinchasov *et al*., (2017) reported a strong correlation between implants placed primarily and tumour recurrence at implant sites. Seeding of the implant placement bed may be the cause of tumour recurrence at implant sites. Although radiation therapy was not a variable in this study, radiation dosage interference due to the presence of metallic material could also result in recurrence. Chronic irritation of oral mucosa from long-term use of alcohol and/or smoking in these patients could also be a factor.

Rhoner *et al*., (2002) reconstructed a severely atrophied maxilla using a two-staged prefabricated free vascularized fibula flap. The first surgical stage includes prefabrication where implants are placed on donor fibula using drilling template; split skin graft placed over the periosteum for future gingiva and fabrication of the prosthesis. The second stage follows after 6 weeks where the prefabricated fibula with implant-supported provisional prosthesis is transferred to the recipient site. The authors reported a 100% flap and implant survival in 12 months mean observation period using this technique.

Although it was not a variable in this study, radiation therapy could be the main reason for unstable obturator owing to soft tissue contraction. These patients received either adjusted or new obturator.

Chapter 5 : Conclusion

This study evaluated maxillectomies performed at Wits Oral Health Centre over a ten-year period. Malignancy was the most common indication for maxillectomy, with squamous cell carcinoma being the most common pathology. The majority of patients were in the age group of 41 to 60 years.

Most patients in this study had Brown's type II defect, and the majority of these patients were rehabilitated with prosthetic obturator as the sole rehabilitative modality. This modality achieved acceptable functional and aesthetic outcomes in most patients despite the size of the defect, validating that prosthetic obturator has still a role in the reconstruction of maxillectomy. Most complications were reported in patients who were reconstructed with vascularised free tissue transfers, exposing these patients to multiple general anaesthesia. Most implants (4) were lost in patients who had implants placed in the fibula at the time of reconstruction. Based on this, it is recommended that the placement of implants be delayed by about 4-6 months after successful reconstruction.

Proper training for general dentists in diagnosing squamous cell carcinoma at primary health care level may assist in managing these lesions at an early stage, thus avoiding complex resection with challenging reconstruction. This approach will result in relief of health care system costs in this country.

The retrospective nature and the small sample size may have affected the outcome of the present study. A similar but prospective study with a larger sample size will help validate the findings in our study.

Notwithstanding its limitation, this study has provided valuable data that could be used as the basis for future treatment algorithm following maxillectomy.

Chapter 6 : References

Akinmoladun, VI., Akinyamoju, CA., Olaniran, FO., Olaopa OL. (2018). Maxillectomy and quality of life: Experience from a Nigerian tertiary institution. *Nigerian Journal of surgery,* 24:125-130.

Andrades, P., Militsakh, O., Matthew, MH., Rieger, J., Rosenthal, EL. (2011). Current strategies in reconstruction of maxillectomy defects. *Arch Otolaryngol Head Neck Surg*, 137(8): 806-812.

Andrades, P., Rosenthal, EL., Carrol, WR., Baranano, CF., Peters, GE. (2008). Zygomatic – maxillary buttress reconstruction of midface defects with the osteocutaneous radial forearm free flap. *Head Neck*, 30(10): 1295-1302.

Amin, MA., Bailey, BM., Swinson, B., *et al*. (2005). Use of the buccal fat pat in reconstruction and prosthetic rehabilitation of oncological maxillary defects. *Br J Oral Maxillofac Surg*, 43:148-154.

Aramany, MA. (1978). Basic principles of obturator design for partially edentulous patients. Part 1. *J Prosthet Dent*, 40:554-557.

Bidros, RS., Metzinger, SE., Guerra, AB. (2005). The thoracodorsal artery perforator-scapular osteocutaneous flap for reconstruction of palatal and maxillary defects. *Ann Plast Surg,* 54(1): 59-65.

Breeze, J., Rennie, A., Morrison, A., Dawson, D., Tipper, J., Rehman K., Grew, N., Snee, D., Pigadas, N. (2016). Health related quality of life after maxillectomy: obturator rehabilitation compared with flap reconstruction. *British Journal of oral and maxillofacial surgery*, 54: 857-862.

Brown, JS., Jones, DC., Summerwill, A. (2002). Vascularized iliac crest with internal oblique muscle for immediate reconstruction after Maxillectomy. *Br J Oral Maxillofac Surg*, 40:183-190.

Brown, JS., Rogers, SN., McNally, D., Boyle, M. (2000). A modified classification for the maxillectomy defect*. Head Neck*, 17-26.

Brown, JS., Shaw, RJ. (2010). Reconstruction of the maxilla and midface: Introducing a new classification. Personal View. *Lancet Oncol*, 11:1001-1008.

Boyes-Varley, JG., Howes, DG., Davidge-Pitts KD., McAlpine JA. (2007). A protocol for maxillary reconstruction following oncology resection using zygomatic implants. *Int J Prosthodont*, 20(5): 521-531.

Chambers, RG., Jaques, DA., Mahoney, WD. (1969). Tongue flaps for intra oral reconstruction. *Am J surg*, 118: 783-786.

Chen, C., Ren, W., Gao, L., Cheng, Z., Zhang, L., Li, S., Zhi, PK. (2016). Function of obturator prosthesis after maxillectomy and prosthetic obturator rehabilitation. *Braz J Otolaryngol*, 82(2): 177-183.

Chepeha, DB., Moyer, JS., Bradford, CR., Prince, ME., Marentette, L., Teknos, TN. (2005). Osseocutaneous radial forearm free tissue transfer for repair of complex midface defects. *Arch Otolaryngol Head Neck Surg*, 131(6): 513-517.

Chigurupati, R., Aloor, N., Salas, R., Schmidt, BL. (2013). Quality of life after maxillectomy and prosthetic obturator rehabilitation. *J oral Maxillfac Surg*, 71:1471-1478.

Cordeiro, PG., Chen, CM. (2012). A 15 year review of midface reconstruction after total and subtotal maxillectomy: Part 1. Algorithm and outcomes. *Plast Reconstr Surg,* 129: 124-136.

Cordeiro, PG., Santamaria, E. (2000). A classification system and algorithm for reconstruction of maxillectomy and midfacial defects. *Plast Reconstr Surg*, 105: 2331.

Costa, H., Zenha, H., Sequeira, H., Coelho, G., Gomes, N., Pinto, C., Martins, J., Santos, D., Andresen, C. (2014). Microsurgical reconstruction of the maxilla: Algorithm and concepts. *Journal of Plastic, Reconstructive and Aesthetic Surgery*, 68: e89-e104.

De Ceulaer, J., Magremanne, M., Van Veen, A., *et al*. (2010). Squamous cell carcinoma recurrence around dental implants. *J Oral Maxillofac Surg,* 68(10): 2507-2512.

Disa, JJ., Liew, S., Cordeiro, PG. (2001). Soft tissue reconstruction of the face using the folded/multipiece skin island radial forearm free flap. *Ann Plast Surg*, 47(6): 612-619.

Djae, AK., Li, Z., Li, ZB. (2011). Temporalis muscle flap for immediate reconstruction of maxillary defects: review of 39 cases. *Int J Oral Maxillofac Surg*, 40:715-721.

Eziyi, JA., Amusa, YB., Fatusi, O., Otoghile, B. (2013). Challenges of surgical management of maxillary tumours in a developing country. *J Med Med Sci*, 5:162-168.

Fomete, B., Agbara, R., Osunde, OD., Ogbeifun, JO. (2017). Maxillectomy and its surgical indications in a tertiary health care centre in North-West Nigeria. *J Oral Maxiloofac Surg Med Pathol*, 29:198-202.

Futran, ND., Mendez E. (2006). Developments in reconstruction of midface and maxilla. *Lancet Oncol*, 7:249-258.

Futran, ND., Wadsworth, JT., Farwell, DG. (2002). Midface reconstruction with the fibula free flap. *Arch Otolaryngol Head Neck Surg*, 128: 161-166.

Genden, EM., Wallace, D., Buchbinder, D., *et al*. (2001). Iliac crest internal oblique osteomusculocutaneous free flap reconstruction of the postablative palatomaxillary defect. *Arch Otolaryngol Head Neck Surg*, 18: 854-861.

Gomes, N., Zenha, H., Azevedo, L. (2013). Microsurgical reconstruction of maxillectomy defects. *Head Neck*, 32:860-868.

Irish, J., Sandhu, N., Simpson, C., et al. (2009). Quality of life in patients with maxillectomy prostheses. *Head Neck*, 31: 813.

Kornblith, AB., Zlotolow, IM., Gooen, J., *et al*. (1996). Quality of life of maxillectomy patients using an obturator prosthesis*. Head Neck*, 18: 325-334.

Lenox, ND., Kim, DD. (2013). *Maxillary reconstruction. Oral Maxillofacial Surg Clin N Am,* 25:215-222.

Lewis, JS., Castro, EB. (1972). Cancer of the nasal cavity and paranasal sinuses. *J. Laryngol Otol*, 86:255-262.

MacLeod, A.M., Morrison, W.A., McCann, J.J., et al. (1987). The free radial forearm flap with and without bone for closure of large palatal fistulae. *Br J Plast Surg*, 40: 391-395.

Mazlina, S., Primuharsa Putra, SHA., Megat Shiraz, MAR., Hazim, MYS., Roszalina, R., Roslan, AR. (2006). Maxillary sinus tumours- A review of twenty-nine patients treated by Maxillectomy approach. *Med J Malaysia*, 61(3):284-287.

Miles, BA., Gilbert, RW. (2011). Maxillary reconstruction with the scapular angle osteomyogenous free flap*. Arch Otolaryngol Head Neck Surg,* 137:1130-1135.

Murat, S., Gurbuz, A., Isayev, A., Dokmez, B., Cetin, U. (2012). Enhanced retention of a maxillofacial prosthetic obturator using precision attachments: two case reports. *Eur J Dent*, 6: 212-217

Nakayama, B., Matsuura, H., Ishihara, O., *et al*. (!995). Functional reconstruction of a bilateral maxillectomy defect using a fibula osteocutaneous flap with osseointegrated implants. *Plast Reconstr Surg*, 96:1201-1204.

Ogunlewe, MO., Somefun, AO., Nwawolo, CC. (2001). Maxillary antral carcinoma. A five year study at the Lagos University teaching hospital (Luth) Nigeria. *Nigerian Journal of Clinical Practice,* 4(2):80-83.

Okay, DJ., Genden, E., Buchbinder, D., Urken, M. (2001). Prosthodontic guidelines for surgical reconstruction of the maxilla: A classification system of defects. *J Prosthet Dent*, 86: 352-363.

Peng, X., Mao, C., Yu, GY. (2005). Maxillary reconstruction with the free fibula flap. Plast Reconstr Surg, 115:1562-1569.

Pinchasov, G., Haimov, H., Druseikaite., M., *et al*. (2017). Oral cancer around dental implants appearing in patients with or without a history of oral or systemic malignancy: a systematic review. *J Oral Maxillofac Res,* 8(3): 1-10.

Rhoner, D., Bucher, P., Kunz, C., Hammer, B., Schenk, RK., Prein, J. (2002). Treatment of severe atrophy of the maxilla with a prefabricated free vascularised fibula flap. *Clin. Oral Impl. Res,* 13: 44-52

Rogers, SN., Lowe, D., McNally, D., Brown JS., Vaughn, ED. (2003). Health-related quality of life after maxillectomy: a comparison between prosthetic obturation and free flap. *J Oral Maxillofac Surg*, 61: 174-181.

Rosenthal, E., Carrol, W., Dobbs, M., Scott Magnuson, J., Wax, M., Peters, G. (2004). Simplifying head and neck microvascular reconstruction. *Head Neck*, 26(11): 930-936.

Ruben, RJ. (2000). Redefining the survival of the fittest: communication disorders in the 12th century. *Laryngoscope,* 110(2 pt 1): 241-245.

Shen, YI., Sun, J., Li, J., Li, M., Huang, W., Qw, A. (2011). Special considerations in virtual surgical planning for secondary accurate maxillary reconstruction with vascularised fibula osteomyocutaneous flap. *Journal of Plastic, Reconstructive & Aethetic Surgery*, 65: 893-902.

Spiro, RH., Strong, EW., Shah, JP. (1997). Maxillectomy and its classification. *Head Neck,* 309-314.

Sullivan, M., Gaebler, C., Beukelman, D., et al. (2002). Impact of palatal prosthodontic intervention on communication performance of patients' maxillectomy defects: a multilevel outcome study. *Head Neck*, 24(6): 530-538.

Triana, RJ, Jr., Uglesic, V., Virag, M., *et al.* (2000). Microvascular free flap reconstructive options in patients with partial and total maxillectomy defects. *Arch Facial Plast Surg*, 2(2): 91-101.

Virgin, FW., Iseli, TA., Iseli, CE., *et al.* (2010). Functional outcomes of fibula and osteocutaneous forearm free flap reconstruction for segmental mandibular defects. *Laryngoscope*, 120(4): 663-667.

Walden, MJ., Aygun, N. (2012). Head and Neck Cancer. Seminars in Roentgenology, 48:75-86

Yamamoto, Y., Kawashima, K., Sugihara, T., Nohira, K., Furuta, Y., Fukuda, S. (2004). Surgical management of maxillectomy defects based on the concept of buttress reconstruction. *Head Neck*, 26:247-256.

Yazar, S., Cheng, MH., Wei, FC., Hao, SP., Chang, KP. (2006). Osteomyocutaneous peroneal artery perforator flap for reconstruction of composite maxillary defects. *Head Neck*, 28:297-304.

APPENDIX A: Clearance certificate

UNIVERSITY OF THE WITWATERSRAND JOHANNESBURG

R14/49 Dr Brampie Mpumpile Mogajane

HUMAN RESEARCH ETHICS COMMITTEE (MEDICAL)

CLEARANCE CERTIFICATE NO. M190233

NAME: (Principal Investigator)	Dr Brampie Mpumpile Mogajane
DEPARTMENT:	Maxillofacial and Oral Surgery Chris Hani Baragwanath Academic Hospital Charlotte Maxeke Johannesburg Academic Hospital
PROJECT TITLE:	Audit of Maxillectomy at Wits Maxillofacial and Oral Surgery Unit
DATE CONSIDERED:	22/02/2019
DECISION:	Approved unconditionally
CONDITIONS:	
SUPERVISOR:	Prof Ephrahim Rikhotso
APPROVED BY:	Dr CB Penny, Chairperson, HREC (Medical)
DATE OF APPROVAL:	03/04/2019

This clearance certificate is valid for 5 years from date of approval. Extension may be applied for.

DECLARATION OF INVESTIGATORS

To be completed in duplicate and **ONE COPY** returned to the Research Office Secretary on the Third Floor, Faculty of Health Sciences, Phillip Tobias Building, 29 Princess of Wales Terrace, Parktown, 2193, University of the Witwatersrand. I/we fully understand the conditions under which I am/we are authorized to carry out the above-mentioned research and I/we undertake to ensure compliance with these conditions. Should any departure be contemplated, from the research protocol as approved, I/we undertake to resubmit the application to the Committee. **I agree to submit a yearly progress report**. The date for annual re-certification will be one year after the date of convened meeting where the study was initially reviewed. In this case, the study was initially reviewed in **February** and will therefore be due in the month of **February** each year. Unreported changes to the application may invalidate the clearance given by the HREC (Medical).

Principal Investigator Signature

Date 09.04.2019

PLEASE QUOTE THE PROTOCOL NUMBER IN ALL ENQUIRIES

APPENDIX B: Data collection sheet

DATA COLLECTION SHEET

Patient no: Age:

Gender: Male:

Female:

Aetiology of Maxillectomy

Trauma:

Pathology

Malignant: Benign:

Name: Name:

Classification (Brown's classification):

Rehabilitative Method:

Obturator:

Surgical:

Combined:

Complications: Tumour recurrence

Flap failure

Instable obturator

Demised

Other