

https://dspace.org/

The role of human papilloma virus (HPV) in oropharyngeal squamous cell carcinoma: a clinicopathologic and molecular analysis

Disenyane, Dineo

2024

https://hdl.handle.net/10539/37830

Downloaded from a DSpace repository. https://dspace.org/



THE ROLE OF HUMAN PAPILLOMA VIRUS (HPV) IN OROPHARYNGEAL SQUAMOUS CELL CARCINOMA: A CLINICOPATHOLOGIC AND MOLECULAR ANALYSIS

Dr Dineo Disenyane

A research report submitted to the Faculty of Health Sciences, University of the Witwatersrand, Johannesburg, in partial fulfilment of the requirements for the degree of Master in Medicine (MMed) in the field of Anatomical Pathology

Johannesburg, 2022

DECLARATION

I, Dineo Lillian Disenyane declare that this Research Report is my own, unaided work. It is being submitted for the degree of Master of Medicine in the branch of Anatomical Pathology at the University of the Witwatersrand, Johannesburg. It has not been submitted before for any degree or examination at any other University.



Signature of Candidate

02th of March 2023

DEDICATION

I dedicate this work to my son, Atlehang Mahloane and my parents Tshidiso and Boitumelo Disenyane for their love and support in the realisation of my degree. To God be the glory.

“The store of wisdom does not consist of hard coins which keep their shape as they pass from hand to hand; it consists of ideas and doctrines whose meaning change with the minds that entertain them.”
John Plamenatz

PRESENTATIONS AT SCIENTIFIC MEETINGS

Disenyane D, Meer S. P16 expression in non-keratinising squamous cell carcinoma of the head and neck. Poster presentation. 24th *International Congress of the International Academy of Pathology*. 30 September – 5th October 2012, Cape Town International Convention Centre, Cape Town, South Africa.

PUBLISHED ABSTRACTS

Disenyane D, Meer S. P16 expression in non-keratinising squamous cell carcinoma of the head and neck. Head and Neck Pathology 2012; 389:61 (Suppl. 1); 1-233.

ABSTRACT

Context: Human papillomavirus (HPV) is an established aetiology in a subset of oropharyngeal squamous cell carcinoma (OPSCC). However, literature on the association between HPV and OPSCC in the African context is lacking.

Objective: To determine the association of HPV in OPSCC and to correlate it with the clinicopathologic and molecular analysis.

Design: A total of 60 OPSCCs were evaluated with HPV *in-situ* hybridisation (HPV ISH) and immunohistochemistry (IHC) for p16, p53 and Ki67. This was correlated with the site of occurrence of the tumours, the patients' smoking and alcohol usage and microscopic features of tumours (NKSCC;*n*=30 and KSCC;*n*=30).

Results: HPV DNA was found in 24/60 (40%) cases. HPV16, was positive in 18/60 (30%) cases and HPV6 in 8/60 (13.3%) tumours. Two of the 60 (3.3%) cases were positive for both HPV16 and HPV6. HPV positive (+ve) tumours occurred more in males (*n*=22; 73%) than females (*n*=7; 23%); median age: 62.5 years. The primary tumour sites were the tonsil (*n*=7; 11.6%) and posterior tongue (*n*=6; 10%). Of the NKSCCs, 11 (36.7%) were HPV16+ve and 8 (26.7%) HPV6+ve. Seven (23.3%) KSCC were HPV16+ve and none (0%) HPV6+ve. Of the 24 HPV+ve tumours, 13 (54.1%) were p16+ve and 14 (58.3%) were p53+ve. Three (12.5%) tumours exhibited the molecular phenotype: p16+ve in > 70% of tumour cells, a low (<25%) to negative p53 staining and high Ki67 (>25%) proliferation index.

Conclusion: HPV positive OPSCC is seen more in older male patients. The distinct molecular phenotype, (p16 positive, low p53, high KI67) highlights tumours that are of true viral aetiology. In this study, the low p16 IHC stain sensitivity towards HPV ISH positive tumours infers that p16 is less reliable when used alone as a surrogate marker for HPV associated OPSCC. Therefore, in OPSCC with a high suspicion for HPV and which display a basaloid and non-keratinising morphology, a negative p16 IHC stain should be followed by other molecular techniques such as HPV ISH.

ACKNOWLEDGEMENTS

Prof Shabnum Meer

Alain Lombardi

Steven Nonyane

TABLE OF CONTENTS

DECLARATION I
DEDICATION II
PRESENTATIONS AT SCIENTIFIC MEETINGS III
ABSTRACT IV
ACKNOWLEDGEMENTS V
TABLE OF CONTENTS VI
LIST OF TABLES IX
LIST OF FIGURES IX
GLOSSARY X
CHAPTER 1 1
1.0 INTRODUCTION 1
CHAPTER 2 3
2.0 LITERATURE REVIEW 3
2.1 Introduction 3
2.2 HPV Life Cycle 3
2.3. HPV+ve OPSCC 5
2.3.1 Epidemiology and risk factors 5
2.3.2 Clinical characteristics 6
2.4 The 4th Edition of the World Health Organisation Classification of Head and Neck Tumours: Oropharynx (Westra and Lewis, 2017) 6
2.5 Histological characteristics 7
2.6 Molecular subtype 7
2.7 Staging 8
2.8 p16 as a surrogate marker 8
2.9 Testing 10
2.9.1 RT-PCR mRNA 11
2.9.2 HPV DNA PCR 11
2.9.3 *In situ* hybridisation 11
2.9.3.1 RNA *in situ* hybridisation 11
2.9.3.2 DNA *in situ* hybridisation 12

2.9.4 Liquid-phased assay 12
2.9.5 Other HPV testing modalities 12
2.10 Current treatments 12
2.11 Prognosis 14
2.12 Prevention 14
CHAPTER 3 17
3.0 AIMS AND OBJECTIVES 17
3.1 Aim 17
3.2 Objectives 17
CHAPTER 4 18
4.0 MATERIAL AND METHODS 18
4.1 Study Sample 18
4.2 Ethics clearance 18
4.3 Clinicopathologic investigation 18
4.4 *In Situ* Hybridisation 19
4.5 Immunohistochemistry 19
4.6 Statistical analysis 20
CHAPTER 5 21
5.0 RESULTS 21
5.1 Demographics 21
5.2 Patients' habits 22
5.2.1 Smoking 22
5.2.2 Alcohol 23
5.3 Tumour site 24
5.4 Microscopic findings and histological category 24
5.5 HPV ISH and genotypes 28
5.5.1 HPV16 ISH status 28
5.5.2 HPV6 ISH status 31
5.3 p16 Immunohistochemistry 32
5.4 p53 Immunohistochemistry 33
5.5 Molecular phenotype 33

CHAPTER 6 34
6.0 DISCUSSION ..... **ERROR! BOOKMARK NOT DEFINED.**4
7.0 CONCLUSION 400
CHAPTER 8 411
8.0 REFERENCES 411
CHAPTER 9 - APPENDICES 533
9.1 Appendix A: Raw Data 533
9.1.1 Controls 533
9.1.2 Cases 544
9.2 Appendix B: Ethics Clearance Certificate 555

LIST OF TABLES

Table 4.1. List of the ISH used in this study 19
Table 4.2. List of the IHC markers used in this study 20
Table 5.1. Summary of the clinical characteristics of the patients with OPSCC categorised by histologic type (Fisher's exact test) ……..……. 28
Table 5.2. Summary of the clinical characteristics of patients with OPSCC, p16, p53, Ki67 and molecular phenotype by HPV ISH and subtype …….. 32

LIST OF FIGURES

Figure 5.1. An overview of the site of tumour within the oropharynx 21
Figure 5.2. Total Count Proportions Smoking 22
Figure 5.3. Total Count Proportions of Alcohol..... 22
Figure 5.4. Total Count Proportions of p16 23
Figure 5.5. Total count proportions of tumour site amongst OPSCC ……24
Figure 5.6. NKSCC with basaloid morphology (H&E, original magnification X10) ..…... 25
Figure 5.7. NKSCC tumour cells arranged in nests exhibiting a basaloid morphology (H&E, original magnification X20) …….. 25
Figure 5.8. Strong and diffuse nuclear and cytoplasmic p16+ve staining in 100% p16 immunohistochemical stain (x10) in NKSCC ……... 27
Figure 5.9. Focal moderate p53+ve nuclear staining NKSCC tumour cells (x10) ……. 27
Figure 5.10. HPV16+ve ISH in NKSCC cells seen as blue nuclear dot staining (x10) ……..... 29
Figure 5.11. Dense blue nuclear dot HPV16+ve ISH in NKSCC tumour cells (x10) …. 29
Figure 5.12. Dense brown nuclear Ki67+ve NKSCC cells (x10) …… 30

GLOSSARY

AJCC	American Joint Committee on Cancer
ASCO	American Society of Clinical Oncology
BOT	base of tongue
CAP	College of American Pathologists
CDK	cyclin dependent kinase
CDKN2A	cyclin dependant kinase inhibitor 2A
CDW	central data warehouse
cDNA	complementary
DNA	deoxyribonucleic acid
FDA	Food and Drug Administration
FOM	floor of mouth
GSK	GlaxoSmithKline Pharmaceuticals Ltd
H&E	haematoxylin and eosin
HIER	heat induced epitope retrieval
HIV	human immunodeficiency virus
HNC(s)	head and neck cancer (s)
HNSCC(s)	head and neck squamous cell carcinoma(s)
HPV	human papilloma virus
HR	high risk
HSV	herpes simplex virus
IHC	immunohistochemistry/ immunohistochemical
ISH	*in situ* hybridisation
Kb	Kilobyte
KSCC	keratinising squamous cell carcinoma
M1	metastatic disease
mRNA	messanger ribonucleic acid
MSD	Merck & Company Inc
NHLS	National Health Laboratory Services
NKSCC	non-keratinising squamous cell carcinoma
NPV	negative predictive value

OPC(s)	oropharyngeal carcinoma(s)
OPSCC(s)	oropharyngeal squamous cell carcinoma(s)
PCR	polymerase chain reaction
PPV	positive predictive value
Rb	Retinoblastoma
RNA	ribonucleic acid
RT-PCR	real-time polymerase chain reaction
SCC(s)	squamous cell carcinoma(s)
SNOMED	systematized Nomenclature of Medicin
S-phase	synthesis phase
SV40	simian virus 40
TNM	tumour nodes metastasis
TP53	tumour protein 53
USA	United States of America
+ve	Positive
-ve	Negative

CHAPTER 1

1.0 INTRODUCTION

The incidence of head and neck squamous cell carcinoma (HNSCC) has increased over the last thirty years making it the eighth most common malignancy worldwide (Donà et al., 2020; Gougousis et al., 2021; Lechner et al., 2022). This increase has been attributed to tobacco-associated oral cancers (Jethwa and Khariwala, 2017) and the human papillomavirus (HPV) oropharyngeal squamous cell carcinomas (OPSCC) (Lewis Jr, 2020). The oropharynx is the primary site for HPV-associated head and neck cancers (HNCs), which has recently surpassed cervical cancer in the developed world as the most common HPV-related cancer (Economopoulou et al., 2020; Lewis Jr, 2020).

The link between HPV and oropharyngeal carcinomas (OPCs) was first hypothesised in the early 1900's. However, a significant association was only described by Wain et al. in 1986 (Chernock et al., 2010). Subsequently, several studies validated this association (Boscolo-Rizzo et al., 2013; Chai et al., 2015; Schache et al., 2013). HPV is now accepted as an aetiological agent in the epidemic of viral-induced OPSCCs (Chernock et al., 2011; Ndiaye et al., 2013). The high-risk (HR) oncogenic subtypes of HPV are implicated as an aetiological factor and show a global cancer burden of 99% cervical cancers, 25-60% HNCs, 70% vaginal cancers, 88% anal cancers, 43% vulvar cancer and 50% penile cancers (Dok and Nuyts, 2016). They may result in potentially malignant lesions and the subsequent development of carcinomas (Dok and Nuyts, 2016; Economopoulou et al., 2020).

HPV positive (HPV+ve) OPSCCs are non-keratinising, and some display a basaloid morphology (El-Mofty and Patil, 2006). The prime location is the tonsil and base of the tongue (BOT) (Dok and Nuyts, 2016). These tumours are seen in patients of a higher socioeconomic status and lower smoking history (El-Mofty and Patil, 2006). The majority present with advanced nodal disease, which shows cystic changes and necrosis (Economopoulou et al., 2020; Kato et al., 2020). The non-keratinising subtypes demonstrate a unique immunohistochemical (IHC) profile, with overexpression of p16 in >70% of tumour cells (El-Naggar and Westra, 2012) and less frequent p53 mutation. Changes to the staging of HPV+ve OPSCC in the

American Joint Committee on Cancer (AJCC) 8th Edition Cancer staging manual is currently according to p16 overexpression (nuclear and cytoplasmic in >75% of tumour cells, with at least moderate [+2/3] staining intensity) (Lydiatt et al., 2017). In addition, extranodal extension has been omitted in HPV+ve OPSCC, focusing solely on the number of lymph node metastasis. Thus HPV+ve OPSCC Stage IV is reserved for patients with distant metastatic disease (any M1). Since HPV+ve OPSCCs have been shown to have a progression free and significantly better overall survival than their HPV negative (HPV-ve) counterpart they are treated differently with reduced radiation and chemotherapy dosage (Lewis Jr, 2020; Mirghani et al., 2015; Wang et al., 2015).

There are very few studies done in South Africa on the association, role, incidence and tumorigenesis of HPV-associated OPSCC. Regional studies have shown little or no association of HPV with OPSCC (Davidson et al., 2014; Dapaah et al., 2022). In a study by Dapaah et al. (2022), only 5% of the 266 OPSCCs had high risk HPV (HR HPV). Davidson et al. (2014) showed similar findings of a prevalence of 5.6% in their study sample of 125 patients with OPSCC, suggesting that HPV may be of minor pathogenic aetiology in OPC in the Southern African geographic region. School based HPV vaccination introduced in South Africa for young girls aged 9 to 13 years since 2014 was implemented to reduce the long-term effect of HPV cervical cancer morbidity and mortality (Delany-Moretlwe et al., 2018). The positive effects the HPV vaccine against HR HPV types 6,11,16 and 18 is expected to help in eradicating HPV+ve OPSCC.

With very little written in the African context regarding the prevalence of HPV+ve OPSCC, the purpose of this study is to determine the prevalence, clinical, histological, IHC and molecular profile of a subset of patients with HPV+ve OPSCC in Johannesburg, South Africa for future vaccine efficacy.

CHAPTER 2

2.0 LITERATURE REVIEW

2.1 Introduction

The past decade has seen a changing trend in the incidence of OPSCC. Whilst the incidence of OPSCC has decreased due to a modification in risk factors, such as tobacco and alcohol usage (Gillison, 2004), there has been an increase in the incidence of OPC related deaths worldwide and in sub-Saharan countries. This has been attributed to HPV emerging as the causative agent in a subset of OPSCCs (Faggons et al., 2015). Very little has been written in the literature about HPV and its association with OPSCC in the African context. As HPV+ve OPSCC has a better prognosis than HPV-ve OPSCC, it is important to recognise these tumours in order to expedite therapy and long-term survival.

2.2 HPV Life Cycle

Oncogenic mechanisms: entry, replication, E5, E6, E7

HPV was previously classified as part of the Papovaridiae family of viruses, which includes SV40 and polyoma virus. It is now recognised as its own viral family, Papillomaviridae, which comprise a heterogenous group of small non-enveloped epitheliotropic deoxyribonucleic acid (DNA) viruses (de Villiers et al., 2004). The HPV genome is an approximately 8 kb double stranded DNA (Dalianis, 2014). The genome is organised into three major regions (Taberna et al., 2017):

- an upstream regulatory region which is the origin of replication
- an early region encoding for six genes involved in multiple functions, which includes viral replication and cell transformation (E1, E2, E4, E5, E6, E7) and
- a late region which encodes for the L1 and L2 capsid proteins, which self-assemble to yield the virion

HPV classification is based on DNA sequence and genomes. There are more than 150 HPV subtypes that have been completely sequenced, and outlined into five HPV genera (α, β, γ, ν, μ). Those of the γ and β genera end their life cycle without obvious disease and cause asymptomatic infection in immunocompetent individuals. The α genera group are inclusive of HPV subtypes that infect cutaneous or mucosa sites. The mucosa HPV subtypes are further subdivided into high and low risk (LR)

groups depending on the association with carcinogenesis. There are twelve HR subtypes (16, 18, 31, 33, 35, 39, 45, 51, 52, 56, 58 and 59). Eight of the HR subtypes are now recognised to be carcinogenic (Boscolo-Rizzo et al., 2013). The LR subtypes (HPV 6, 11, 43, 43, 44), are responsible for epithelial proliferation and mostly cause genital warts and non-malignant lesions (Snijders et al., 1992). HPV16 is by far the most common HPV type detected in OPC accounting for 90–95% of the HPV+ve tumours (Feller et al., 2010; Gillison, 2004; Snijders et al., 1992).

The HPV reproductive cycle in squamous epithelium is associated with differentiation factors expressed within the different layers of the host epithelium (Attner et al., 2010; Rautava and Syrjänen, 2012). HPV enters epithelial surfaces at the squamous-columnar junction at the level of tonsillar crypts and glottides. The squamous-columnar junction displays the greatest susceptibility to HPV as the basal cells are more exposed in this region. The squamous-columnar layer is also the only layer of epithelium that is actively dividing (Münger et al., 2004). The processes that allow the uptake and ultimate incorporation of the viral genome into the nucleus are not known. Replication is dependent on S-phase entry since it requires DNA machinery (Rautava and Syrjänen, 2012). Once the viral DNA is incorporated into the cell, early proteins, E1-E2, encoded by the early region are expressed (Dalianis, 2014).

These proteins are important for gene regulation, replication and pathogenesis. They assist with the integration of the virus into host genome (Dalianis, 2014). HPV is then kept at a low copy number in infected host cells. In terminally differentiated cells, HPV replicates exponentially and late genes, E6 and E7 are expressed in the suprabasal layers (Münger et al., 2004). E6 and E7 are oncogenes with a high affinity to p53 and pRb. Binding of E6 to p53 causes degradation, preventing control of DNA damage and cell repair or apoptosis (Dalianis, 2014). When E7 binds to pRb, it stops deregulation of the cell cycle control by binding and degrading retinoblastoma protein. This prevents inhibition of transcription factor E2F. In addition, the functional inactivation of Rb (retinoblastoma gene) leads to an increased expression of the cyclin dependent kinase (CDK) inhibitor p16 encoded by the CDKN2A tumour suppressor gene (Oguejiofor et al., 2013; Rautava and Syrjänen, 2012). Furthermore, E7 allows epithelial cells to re-enter S-phase of the cell cycle to avail the cellular replication machinery for viral DNA replication. The virus escapes

the shedding of epithelial cells by activating late viral gene expression (Gupta and Gupta, 2015).

2.3. HPV+ve OPSCC

2.3.1 Epidemiology and risk factors

HPV causes approximately 5% of cancer related deaths globally, of which HNSCC is estimated to be 25-60% (Dok and Nuyts, 2016). Several studies have shown that the increase in the incidence of OPSCC throughout the world is mainly attributed to HPV infection (Chaturvedi et al., 2011). Variation in geographic location is evident, with the highest variations observed in North America, and North and Central Europe. In western countries, about 50% of OPSCC are HPV+ve, with higher rates in the United States of America (USA) (72%) and Scandinavia, and lower rates in Southern Europe (17%), Taiwan (12.6%), central Europe (4.4%) and Latin America (4.4%) (Machczyński et al., 2020). Numerous other countries show this increased incidence, seen particularly in the USA, where HPV+ve OPSCC now accounts for almost 90% of OPCs (Donà et al., 2020); previously reported as 40-80% (Amini et al., 2016). There is however a dearth in the data reported in South Europe and Africa (Donà et al., 2020).

Oral HR HPV infection is reported at 3.5-3.7% of the general population, with greater rates in HIV-infected persons (Machczyński et al., 2020). In 2005 and 2021, the global prevalence of HPV OPSCC was 35.6% and 33% respectively (Lechner et al., 2022; Machczyński et al., 2020). More than three quarter of the HPV-related cases are found in males (Woods Sr et al., 2014). Individuals infected by human immunodeficiency virus (HIV) show increased rates of HPV infection (Woods Sr et al., 2014).

Data on the prevalence and incidence of HPV in OPSCC is limited in sub-Saharan countries. Blumberg et al. (2015), found a low prevalence of 14.5% in HPV+ve OPSCC in Mozambique, which they attributed to a reduced practice of oral sex. A study from Cameroon shows similar findings, also attributing the reduced prevalence levels to limited oral sexual practices (Rettig et al., 2019).

Reviews from Sudan regarding HPV association and OPSCC, show 25% of 217 tumours to be HPV+ve (Jalouli et al., 2010). In another study from Sudan, 155

OPSCC were tested for HPV and Herpes simplex virus (HSV), but there was no mention of status, site, stage, behaviour of the tumour or risk factors in relation to the previous study from Sudan (Faggons et al., 2015).

2.3.2 Clinical characteristics

HPV+ve OPSCCs have unique clinical and morphological features, and a characteristic immunophenotype (Chernock, 2012). They include tumours that arise from the tonsil, BOT, soft palate and pharyngeal wall (Attner et al., 2010; Marklund et al., 2012). Approximately 79% of HPV+ve OSCC arise in the tonsil and 73% at the BOT. In contrast, 17% of HPV+ve OSCC are seen in other parts of the oral cavity (Attner et al., 2010; Marklund and Hammarstedt, 2011).

Patients presenting with HPV+ve OPSCC are generally younger, middle aged (40-60 years), healthier and show a male bias (M:F=2.6:1) (Ramqvist et al., 2015; You et al., 2019). The patients are Caucasians, particularly white males, of a high socio-economic class, and have a minimal or no history of smoking and alcohol abuse when compared to the HPV-ve tumours (Ramqvist et al., 2015; You et al., 2019). Patients usually present with a more advanced disease stage, nodal metastasis and small primary tumours (Ramqvist et al., 2015).

HPV+ve OPSCC is strongly associated with a history of multiple sexual partners and or orogenital sexual partners (Ramqvist et al., 2015; You et al., 2019). Various studies show a strong association of HPV+ve OPSCC to markers of HR behaviours, such as young age of first intercourse, number of lifetime sexual partners, and number of vaginal, oral or anal sexual partners (Woods Sr et al., 2014).

Immunodeficiency plays a significants role in HPV+ve OPSCC. HIV-infected patients show a 2-6 times greater risk of HPV+ve HNSCC; this risk is greater for SCC in the anogenital area than for OPSCC (Woods Sr et al., 2014).

2.4 The 4th Edition of the World Health Organisation Classification of Head and Neck Tumours: Oropharynx (Westra and Lewis, 2017)

The changes in the classification of head and neck tumours primarily divides the oral cavity and oropharynx into different chapters. In addition, it classifies SCC on the basis of HPV status. It divides SCC according to the presence or absence of

transcriptionally-active HPV. The recommended terminology for OPSCC found to be HPV+ve is “squamous cell carcinoma, HPV positive” (SCC HPV+ve). The HPV-ve OPSCCs are termed “squamous cell carcinoma, HPV negative” (SCC HPV-ve). The classification is used for tumours in the oropharynx as the significance of HPV in non-oropharyngeal tumours is less clear. Furthermore, the classification excludes the histological grading of HPV+ve OPSCC (Westra and Lewis, 2017).

The importance of these changes relates to the growing increase in the prevalence and impact of HPV. The classification helps in the identification and explaination of the trends in the epidemiology as well as in the interpretation of clinical trials. The cancer registry shows a sharp rise in the incidence of HPV in the past 15-20 years and a constant and declining incidence of oral cancers (Chaturvedi, 2012; Westra and Lewis, 2017).

2.5 Histological characteristics

HPV-associated OPSCC has a distinct morphology and commonly originates from the tonsillar crypts. The tumours are non-keratinising, basaloid or undifferentiated (Taberna et al., 2017; Westra, 2012). They have a prominent pushing border and grow in sheets, nests and trabeculae. A minimal desmoplastic stromal response is seen. The tonsillar tissue shows a dense lymphoid stroma. The tumour cells have distinct cell borders and high nuclear to cytoplasmic ratios, with hyperchromatic nuclei and inconspicuous nucleoli. The tumour cells may also be spindled with a fusiform nucleus. Brisk mitotic activity is evident with comedo-type necrosis (Westra, 2012). The morphological spectrum of HPV+ve OPSCC includes papillary and basaloid squamous cell carcinoma (SCC), adenosquamous, sarcomatoid, lymphoepithethelial (undifferentiated) and ciliated adenosquamous carcinoma (Westra and Lewis, 2017).

2.6 Molecular subtype

OPSCC that are HPV driven have a distinct molecular profile that differentiates them from tumours that are HPV-unrelated. This molecular profile is characterised by p16 overexpression, lack of p53 mutation and an increased Ki67 proliferation index (p16+/p53-/Ki67 increased). In HPV induced tumours, p16, a tumour suppressor protein is overexpressed due to inhibition of Rb by the E7 oncoprotein. The tumour suppressor gene, p53, is not mutated in HPV driven tumours. Wild-type p53 protein

is degraded by the E6 oncoprotein thus, leading to <25% or no IHC staining. HPV unrelated tumours show mutation of p53 tumour suppressor gene (Chernock et al., 2010). Ki67, an antigen expressed during the cell cycle (during the G1, S and G2 phases) is a marker of proliferation and measures growth of tumour (Liu et al., 2015). In HPV+ve OPSCC, a higher mitotic count is seen when compared to HPV unrelated tumours (El-Mofty and Patil, 2006). Therefore, strong and diffuse immunostaining for p16 combined with focal or negative p53 immunostaining and an elevated Ki67 index is considered to be a molecular signature for HPV-induced SCC (Chernock et al., 2010; El-Mofty and Patil, 2006).

2.7 Staging

The 8th edition AJCC staging of HR HPV published in October 2016 was implemented in January 2018 (Amini et al., 2016; Panwar et al., 2017). Important changes in the Head and Neck section of the 8th edition AJCC staging manual have been introduced since the 7th edition. The revisons now allow for better treatment planning, measuring differences and outcomes between stage groups and providing a better prognostic outcome. The current edition delineates OPSCC into HPV driven and non-HPV driven tumours, compared to the 7th edition, which reflected on the behaviour of smoking related SCC (Gougousis et al., 2021; Machczyński et al., 2020). In addition, the 7th edition did not focus on the behaviour and prognosis of HPV+ve disease (Lydiatt et al., 2017).

A separate staging algorithm specific for OPC has now been created for HPV+ve SCC that is different from HPV-ve SCC (Panwar et al., 2017). The reason for this delineation is to provide an accurate and reasonable estimate for survival of newly diagnosed patients with HPV+ve OPSCC when compared to HPV-ve OPSCC (Lydiatt et al., 2017), and it further stratifies the risk in patients with HPV+ve OPSCC (Gougousis et al., 2021; Machczyński et al., 2020; Panwar et al., 2017).

2.8 p16 as a surrogate marker

p16, a CDK, is one of the four key regulators of the cell cycle. It is a tumour suppressor that binds to the cyclin D1 CDK4/CDK6 complex, thus Rb is kept in an inactive hypophospharylated form. Dysregulation of p16 leads to a loss of normal cell cycle control and malignant transformation (Augustin et al., 2020). p16 protein overexpression may indirectly express E6 and E7 proteins with cell cycle

upregulation in HPV+ve OPSCC (Augustin et al., 2020). Numerous studies validate this finding and show a strong association between p16 overexpression and integrated HPV (Woods Sr et al., 2014). Thus, the College of American Pathologists (CAP) and the 8th edition of the TNM classification recommend p16 as a surrogate marker for HR HPV as it marks transcriptionally active HR HPV (Augustin et al., 2020).

The CAP guidelines have provided recommendations to define a positive p16 IHC both in fresh frozen paraffin-embedded tissue and cytology specimens. A positive result is defined as moderate to strong diffuse nuclear and cytoplasmic staining in 70% or more of tumour cells, whilst 50-70% diffuse nuclear and cytoplasmic staining in tumour cells is interpreted as a borderline result. It is recommended that HPV specific testing (real-time polymerase chain reaction (RT-PCR), polymerase chain reaction (PCR) or *in situ* hybridisation (ISH)) be performed in order to classify tumours into HPV+ve and HPV-ve OPSCC (Kim et al., 2018). Cases of unknown primary tumour site, the tumour morphology and the level of lymph node involvement provide guidance of whether additional specific HPV testing should be performed (Jalaly et al., 2020).

The sensitivity and specificity of p16 for HR HPV infection range from 80-98% (Augustin et al., 2020). In one study, 46-98% of HPV+ve OPSCC cases were p16+, whilst in another study, HPV+ve OPSCC demonstrated p16 positivity in 3-51% of cases (Woods Sr et al., 2014).

Whilst p16 IHC is highly sensitive for transcriptionally active OPSCC, overexpression can be seen in several other lesions. These lesions range from benign lesions to malignant neoplasms that are not HPV related, and include benign squamous cells from branchial cleft cyst, non-squamous basaloid carcinomas and sinonasal carcinomas (Kim et al., 2018; Lewis Jr, 2020). The aberrant expression can also be due to dysregulation of multiple transcription factors or epigenetic controls (Woods Sr et al., 2014). p16+ results are seen in 20-30% of primary lung and head and neck cutaneous SCC. A small percentage of non-oropharyngeal SCC also stains positively for HPV. This staining pattern is seen without positive staining for HR HPV (Kim et al., 2018; Lewis Jr, 2020).

Woods Sr et al. (2014) failed to demonstrate overexpression of p16 in a subgroup of OPSCC with active HPV infection in 2-54% of cases. This was attributed to latent HPV infection, and it further clarifies why HPV+ve/p16- tumours have a somewhat poorer prognosis. Thus combination testing for HPV DNA positivity and p16 overexpression, improves specificity by excluding cases with inactive infection. This ensures that transcriptionally active HR HPV is demonstrated, which is the gold standard for the detection of biologically relevant HPV infection (Woods Sr et al., 2014; Schache et al., 2013).

2.9 Testing

It is recommended that all patients with OPSCC and cervical lymph node metastasis of unknown origin be tested for HPV as part of their work up. The CAP compiled evidence-based guidelines of HPV testing in OPSCC; published in May 2018 and endorsed by the American Society of Clinical Oncology (ASCO) (Fakhry et al., 2018). The guidelines include a set of 14 recommendations on HPV testing, application, interpretation and reporting in tissue specimens.

The most important recommendations include:

- testing of all OPSCC patients for p16; strong nuclear and cytoplasmic p16 positive staining in 70% or more of malignant cells
- no need for testing for non-OPSCC or for non-squamous OPSCC cases
- no need for testing LR HPV (Lewis Jr et al., 2018)

Recommendations for cytology specimens have not been released except for the testing of a cervical mass of unknown primary. To date, there are no set guidelines with regards to HPV testing in cytology specimens (Jalaly et al., 2020).

There are different testing methods for HPV with the primary function being to accurately test for oncogenic HPV infection. These techniques are commercially available and have been pre-approved by the food and drug administration (FDA). Many of these techniques are validated for cervical cancer (Lewis Jr, 2020).

2.9.1 RT-PCR mRNA

This entails reverse transcribing messenger ribonucleic acid (mRNA) into complementary DNA (cDNA) and then amplifying the target DNA sequence of interest using PCR. This is attained by using fresh frozen tissue and recently formalin-fixed paraffin-embedded tissue (Kim et al., 2018). This method has a high sensitivity and specificity (Economopoulou et al., 2020).

2.9.2 HPV DNA PCR

HPV DNA detection alone is not sufficient to detect HPV status. Studies have found that there is a low sensitivity (Economopoulou et al., 2020).

The limitations of the PCR assays include false positive results from contamination or from surrounding non-neoplastic tissue that is HPV infected. Secondly, PCR cannot differentiate tumour cells that are transcriptionally active from those that are not. Thirdly, one cannot identify positivity directly in tumour cells as there is no tissue context for the results (Kim et al., 2018).

2.9.3 *In situ* hybridisation

In situ hybridisation (ISH) plays a role in detection of HPV in OPSCC. It is coupled with p16 IHC to rule out false positive results. ISH options that are available include those that target viral DNA or RNA (ribonucleic acid).

2.9.3.1 RNA *in situ* hybridisation

HPV RNA ISH detects mRNA and viral oncoproteins, E6 and E7. RNA ISH shows high accuracy compared to DNA ISH. This is attributed to high sensitivity in tumours with low to intermediate HPV viral copy numbers. Some studies show evidence that it can be used as a standalone test for diagnosis and prediction of prognosis (Lewis Jr, 2020). The sensitivity and specificity ranges from 87-100% and 95% respectively. The advantages include feasibility on paraffin-embedded tissue and interpretation (readable on a conventional optic light microscope) (Augustin et al., 2020). The disadvantages include cost, as it is not freely available in all diagnostic laboratories. The second disadvantage is the incapability to test which of the HR HPV is present in the tumour (Augustin et al., 2020). Furthermore, research shows that RNA ISH is slightly superior to p16 as a biomarker (Lewis Jr, 2020).

Most reports agree that the validity of RNA ISH has not been widely studied. Thus, further larger research studies are needed for confirmation (Keung et al., 2020; Lewis Jr, 2020).

2.9.3.2 DNA *in situ* hybridisation

DNA ISH involves hybridised probes against specific sequences of DNA. When compared to RNA ISH, it is cheaper. The specificity and sensitivity depends on the type of probes that target HPV (Augustin et al., 2020). When compared to other methods, such as PCR, RT-PCR and p16 IHC, HPV DNA ISH has high specificity and low sensitivity. False negative results are usually due to low viral load. There is interobserver variation in 10% of the cases (Kim et al., 2018).

2.9.4 Liquid-phased assay

This modality is widely used in cytopathology to specifically evaluate metastasis of unknown primaries in cervical lymph nodes. An array of tests and test kits have been validated by the FDA and made commercially available. These have been validated for use in cervical cytology, and none in head and neck specimens (Kim et al., 2018).

2.9.5 Other HPV testing modalities

Newer tests for different specimen types such as saliva and plasma are being developed as biomarkers for recurrence. These are focussed more on investigating before and after treatment (Kim et al., 2018).

2.10 Current treatments

There are different treatment modalities for the management of HPV-associated OPSCC. Currently, a single ideal treatment modality is not well-defined. Treatment includes surgery, chemotherapy and radiation therapy. These modalities can be used singly or in combination (Vokes et al., 2015). Treatment is based on the general condition of the patient and the stage of disease (Boscolo-Rizzo et al., 2013). Since the patients are younger, with a more prolonged survival time, an aggressive multi-disciplinary treatment approach is not suitable (Laskar and Swain, 2015).

Treatment is usually the same for both HPV+ve OPSCC and HPV-ve OPSCC. The only exceptions are when patients are in a clinical trial and treatment considerations include long-term effects such as oropharyngeal function preservation and late treatment-related toxicity (Galloway et al., 2019).

The first modality includes surgical treatment, which comprises trans-oral surgery, performed by oral laser microsurgery or trans-oral robotic surgery. Trans-oral surgery has reduced morbidity and mortality and shows excellent functional outcome (Boscolo-Rizzo et al., 2013). This modality leads to a decrease in the use of chemotherapy and adjuvant radiation therapy (Buckley et al., 2016; Dietz et al., 2017).

The second treatment modality is radiation therapy, used either singly or in combination with chemotherapy. Radiation therapy is usually indicated in patients with limited disease burden (T1-2, N0 disease) (Panwar et al., 2017). Recent treatment involves intensity modulated radiation therapy together with cisplatin-based chemotherapy. Systemic therapy is used to in order to reduce both acute and late toxic effects (De Felice et al., 2019). Chemoradiation therapy is indicated for active smokers, heavy smokers or those with a positive node showing some HR features suspicious for an advanced primary tumour, or nodal involvement based on clinical and radiological features (Garden et al., 2016; Hall et al., 2017).

The above treatment modalities may be severe in order to achieve a cure for patients. Research has shown that there is an increase in treatment-induced toxicity when the modes of therapy such as chemotherapy, radiation therapy or surgery are used in combination (Kelly et al., 2016). In this regard, treatment has been directed towards a more de-intensification approach in order to improve oncologic outcomes and reduce treatment related toxicity, and thus improve quality of life (Buckley et al., 2016; Dietz et al., 2017). Although some authors are of the opinion that de-escalating treatment might negatively impact general outcome, others are of the opinion that treatment procedures offer better compliance to chemoradiotherapy strategies (Boscolo-Rizzo et al., 2013). Deintensification treatments are still being investigated and are undergoing phase II trials.

2.11 Prognosis

HPV-associated OPSCC has a favourable prognosis and responds better to treatment than the HPV-ve counterparts (Laskar and Swain, 2015). Gillison et al. (2000) found a 74% decrease in risk of death from cancer in a patient with HPV+ve OPSCC compared to a patient with non-HPV OPCC. Several factors have an impact on the prognosis of HPV+ve OPSCC. These factors include young age at diagnosis, superior performance status, lower smoking and alcohol related morbidity, distinct cancer biology, reduced risk of second primary tumours or a more aggressive treatment strategy (Boscolo-Rizzo et al., 2013).

In patients with HPV+ve OPSCC the likelihood of dying from the disease is four times lower than in the HPV-ve tumours (Lewis Jr, 2020). Tribius et al. (2019) showed HPV DNA+ tumours to have a 58% reduction in the risk of death and a 51% reduction in the risk of relapse or death when compared to HPV DNA-ve OPSCC.

In other studies, p16 is found to be an important prognostic factor independent of HPV status (Woods Sr et al., 2014). Selcuk (2016) shows that p16 is a prognostic indicator more so in the tonsil and base of tongue (BOT), but not in other sites of the oropharynx. p16 measures long term survival and cancer free interval (Selcuk, 2016). When compared to p16-ve tumours, p16+ve tumours do not show late recurrences. p16 alone does not yield better prognostic information than a combination of HPV/p16. HPV+ve/p16+ve OPSCC has an improved cancer free-interval than HPV-ve/p16-ve. HPV-ve/p16+ve tumours have an intermediate survival (Wendt et al., 2021).

2.12 Prevention

One of the most recent advances in HPV infection is the development of prophylactic vaccinations for prevention of HPV-related tumours. The objective is to reduce the prevalence of HPV infections and ultimately prevent HPV-associated) tumours (Powell and Evans 2015). Thus, vaccination should be targeted more to third world countries where majority of the population are of middle to low socioeconomic status, there is high prevalence of disease, patients are lost to follow up and management resources are limited (Powell and Evans, 2015).

Preventative strategies are divided into primary and secondary prevention. Primary prevention entails HPV immunisation. This stage targets the L1 capsid proteins (Taberna et al., 2017). Secondary prevention involves screening tests. Many modalities have been proposed to form part of screening for HPV-associated OPSCC. These include transcervical ultrasound, HPV DNA detection in oral rinses and HPV antibodies. HPV16 E6 serology, is seen as a predictive marker for HPV-associated OPSCC. All these modalities have not been validated as preventative screening tools (Taberna et al., 2017). In non-vaccinated individuals, these modalities may not be ideal, as they ought to identify specific premalignant lesions. In OPSCC, it is difficult to obtain samples of premalignant cells due to the anatomy and architecture of the tonsillar epithelium forming deep crypts that penetrate the lymphoid structure of the tonsil (Powell and Evans, 2015; Ramqvist et al., 2015). When considering the role of persistent HPV infection after completion of treatment as a tertiary prevention tool, it must be remembered that this method cannot simply be adopted as a clinical potential test due to low sensitivity, low confidence in the positive predictive value (PPV), and the high number needing treatments (Taberna et al., 2017).

The incidence of HPV in non-vaccinated individuals is between 3-7%, with HR HPV16 being the common subtype. In contrast to vaccinated individuals, HPV prevalence is lower, and thought to be due to the vaccination effect. Clinical control trials show that prophylactic HPV vaccination has an efficacy of 90-100% in preventing vaccine-type HPV infection. Only a single trial showed a decrease in the prevalence of oral HPV infection after 4 years of the HPV vaccine compared to the placebo (Taberna et al., 2017). Therefore, vaccinating HPV unexposed individuals against HPV16 may prevent not only HPV-associated OPSCC, but other HPV-associated cancers (Ramqvist et al., 2015).

In 2008, two HPV vaccines were accepted by the Medicine Control Council of South Africa: Gardsil ® (MSD), a quadrivalent vaccine, and Cervarix ® (GSK). They prophylactically protect against HR oncogenic subtypes, HPV16 and HPV18. They are most effective when administered in pre-pubertal individuals before exposure to infection (Delany-Moretlwe et al., 2018).

In March 2014, the South African National Department of Health launched an HPV vaccination program aimed at vaccinating girls aged 9-12 years in a national school-based HPV campaign. The objective is to decrease the prevalence of HPV and HPV-associated tumours (Delany-Moretlwe et al., 2018). As of 2020, 75% of adolescent girls aged 15 years received at least a single dose of the vaccine, while 61% received two doses. Despite this achievement, there has been a downward trend in the progress of this vaccine program. The challenges include reduced public demand for vaccination, and HPV and HIV co-infection in adolescent females and young women in South Africa. National policy makers and implementers are recommended to improve age eligibility criteria, vaccine dose schedules and implement strategies to support vaccine uptake (Amponsah-Dacosta et al., 2022).

CHAPTER 3

3.0 AIMS AND OBJECTIVES

3.1 Aim

The aim of the study is to characterise the clinico-pathologic and molecular role of HPV in OPCs.

3.2 Objectives

3.2.1. To review OPCs of the tonsils and base of tongue in patients of all age groups and to classify them according to their microscopic features into non-keratinising squamous cell carcinoma (NKSCC) (*n*=30) and keratinising squamous cell carcinoma (KSCC) (*n*=30), with basaloid features

3.2.2 To analyse the clinico-pathologic profile of each case from the histopathology reports

3.2.3 To characterise the molecular phenotype of all the tumours with IHC

3.2.4 To determine the prevalence and genotype of HPV DNA in representative cases of the NKSCCs with basaloid features via ISH assay

3.2.5 To correlate tumour morphology (keratinising versus non-keratinising) to the presence or absence of HPV

CHAPTER 4

4.0 MATERIAL AND METHODS

4.1 Study Sample

A retrospective record and histological review of archived surgical specimens were performed in the Department of Oral Pathology, University of the Witwatersrand, Johannesburg South Africa. The study sample was randomly selected from cases diagnosed over a ten-year period (2011-2021) via the National Health Laboratory Service's Corporate Data Warehouse (NHLS CDW). The following Systemised Nomenclature of Medicine – Clinical Terms (SNOMED CT) codes were used M-80733, M-80743, M-80723, R-F5789, R-100CE, DF-006D7, D5-F0228, T-C5100, T-C5101, T-53000, T-53001, T-5300C and T-5300D. Haematoxylin and eosin stained sections were reviewed and the tumours were classified according to their histological features into NKSCC and KSCC. Thirty cases of NKSCC showing basaloid features were selected for evaluation for HR HPV ISH, p16, Ki67 and p53 IHC. Thirty cases of KSCC were selected as controls.

4.2 Ethics clearance

Ethics approval (M210490) for this study was granted by the local Human Research Ethics Committee (Medical) of the University of the Witwatersrand, Johannesburg, South Africa in accordance with the Declaration of Helsinki (2013) [Appendix 1].

4.3 Clinicopathologic investigation

The clinical findings such as the patient's age, gender, site of the tumour, smoking history and alcohol history were documented from the clinical history submitted on the request form together with the surgical specimen and histological reports.

All the haematoxylin and eosin (H&E) stained sections from the cases were allocated random numbers. The H&E stained sections were reviewed by the primary investigator together with the specialist pathologist in order to confirm the histological features and diagnosis of NKSCC with basaloid features.

4.4 *In Situ* Hybridisation

4µ sections of paraffin-embedded tissue were prepared on silanated slides. The tissue sections were deparaffinised, rehydrated and digested with proteinase 3 (10µg/mL). Biotinylated oligonucleotide probes complementary to HPV16 and HPV6 (INFORM HPV 111 Family 16 Probe and INFORM HPV 11 Family 6 Probe (Roche Diagnostics, Mannheim, Germany) were applied in a 30% formamide hybridisation buffer, and the slides were hybridised overnight at 37ºC (Table 4.1). Following post hybridisation washes, an avidin-alkaline phosphatase conjugate (Vector Laboratories Inc., Newark, USA) was applied to each slide. The slides were washed and placed in a colour developing solution consisting of nitrobluetetrazolim and 5-bromo-4-chloro-3-indolyl phosphate (Gibco BRL, Burlington, Ontario, Canada). The integrity of the RNA in each tissue section was evaluated by a biotinylated oligod (T) probe directed against the polyadenylated mRNA tail. A control slide, prepared from a paraffin-embedded tissue block containing a known HPV+ve viral lesion, as a positive control accompanied each hybridisation run. A negative control run was run for each case by omitting the HPV probes. Positive staining was identified as dense blue nuclear dots. Any definitive nuclear staining in the tumour cells was considered positive. Cases were classified in a binary manner as either positive or negative.

Table 4.1. List of the ISH used in this study

ISH	Clone	Dilution	Manufacturer
HPV16	Inform HPV III family 16 probe	Predilute	Roche Diagnostics, Mannheim, Germany
HPV6	Inform HPV II family 6 probe	Predilute	Roche Diagnostics, Mannheim, Germany

4.5 Immunohistochemistry

IHC was performed on deparaffinised 4µm sections on selected cases and mounted on a coated glass slide. The immunostaining was performed by an immunohistotechnologist in the Department of Anatomical Pathology in conjunction with the principal investigator on commercially available kits using standard recommended manufacturer IHC techniques and procedures. A summary of the antibodies used in the study is outlined in Table 4.2.

Table 4.2. List of the IHC markers used in this study

Antibody	Clone	Dilution	Manufacturer
p16	E6H4	Predilute	Roche Diagnostics, Mannheim, Germany
p53	D0-7	1:25 - 1:50	DakoCytomatation, Glostrup, Denmark
Ki67	MIB-1	1:75 - 1:150	DakoCytomatation, Glostrup, Denmark

Antigen retrieval was obtained via citrate buffer (pH 8.5 - 9.0) using heat induced epitope retrieval (HIER) incubated overnight at 48ºC. Endogenous peroxidase was blocked with 0.05% hydrogen peroxide for 30 minutes. After incubation with a 1:20 dilution of normal horse serum to reduce non-specific binding, the slides were incubated with primary antibodies against p53, Ki67 and p16 using the Envision FLEX visualisation system (Dako Autostainer, Link 48, DakoCytomation, Glostrup, Denmark). All slides were counterstained with haematoxylin. After each step the sections were washed with phosphate buffered saline.

The p16 staining pattern was classified as positive (strong and diffuse positive staining in >70% tumour cells) or negative. p53 immunostaining was classified according to the percentage of positive cells as either negative (<25% nuclear staining) or positive (25% or greater) nuclear staining. This scoring system is based on the concept that cases with greater than 25% of cells nuclear staining are more likely to harbour p53 mutations (El-Mofty and Patil, 2006).

Semiquantative scores were used for Ki67 staining. This was according to the percentage of cells that stain positive (+ <25%, ++ 25-50%, +++ 50-70%, ++++ > 75%) (El-Mofty and Patil, 2006).

4.6 Statistical analysis

The data in this study was descriptive and was computed for each of the variables. The Chi-square test of independence was used to explore possible relationships between the variables of interest. These relationships and their significance were further tested by the Fisher's Exact test and Cramer's V test to reinforce the results found. Analysis was performed using "R Software (version 4.1.3; http://www.Rproject.org).

CHAPTER 5

5.0 RESULTS

5.1 Demographics

The study comprised a total of 60 cases of OPSCC, consisting of 30 cases of NKSCC subtype and 30 cases of KSCC used as controls. There were 46 (76.7%) males, 12 (20%) females and 2 (3.3%) patients of unknown gender (**Figure** 5.1). There was a male gender bias, with a ratio of 3.83:1 (males: females).

The mean age of patients with OPSCC was 59.16 (range 34-87, SD 10.25) (**Figure** 5.2). Most cases (23; 38.3%) occurred in the 6th decade, followed by the 4th (10; 16.7%), 5th (15; 25%), 7th (9; 15%) and 3rd (1; 1.7%) and 8th (1; 1.7%) decades respectively. The age was missing in 1 (1.7%) case.

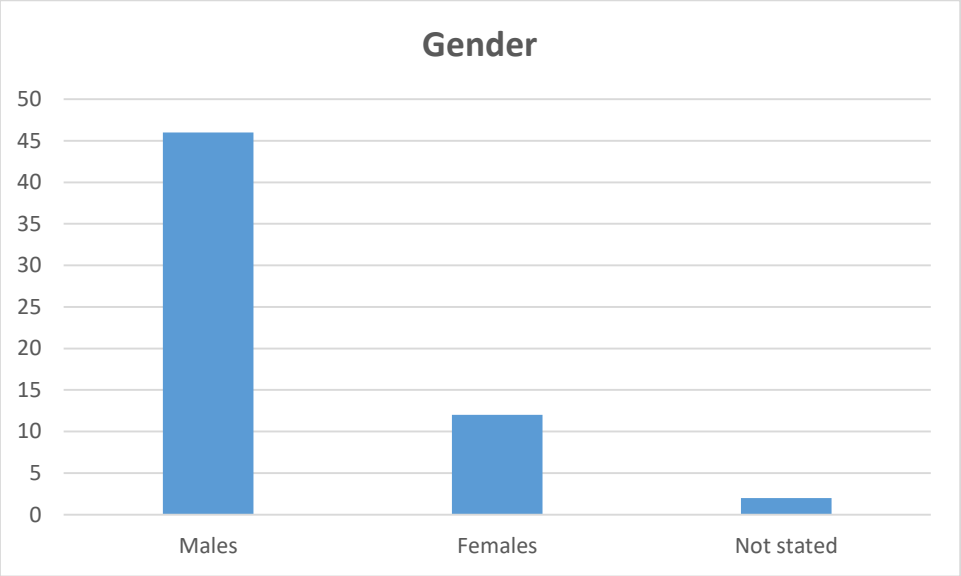

Figure 5.1. Gender distribution of patients with OPSCC

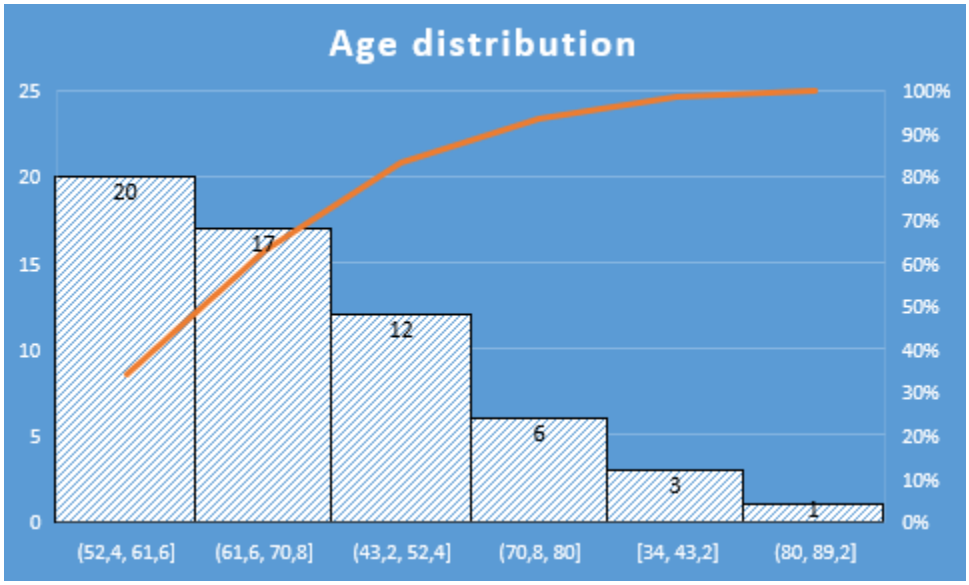

Figure 5.2. Age distribution of patients with OPSCC

5.2 Patients' habits

5.2.1 Smoking

Ten (16.67%) of the patients with OPSCC had a known smoking history. Eight (13.3%) patients were current smokers at diagnosis and 2 (3.3%) were previous smokers. The remaining patients (50; 83.3%) showed no details of a smoking history (**Figure** 5.3). Tumours of 4 (6.7%) patients who were current smokers occurred in the posterior tongue; 2 (3.3%) in the posterior FOM, 1 (1.7%) in the tonsil and 1 (1.7%) in the retromolar region. Only 1 (12.5%) of the 8 OPSCCs in patients that were current smokers was p16+ve, with the remaining 7 (87.5%) tumours being p16-ve.

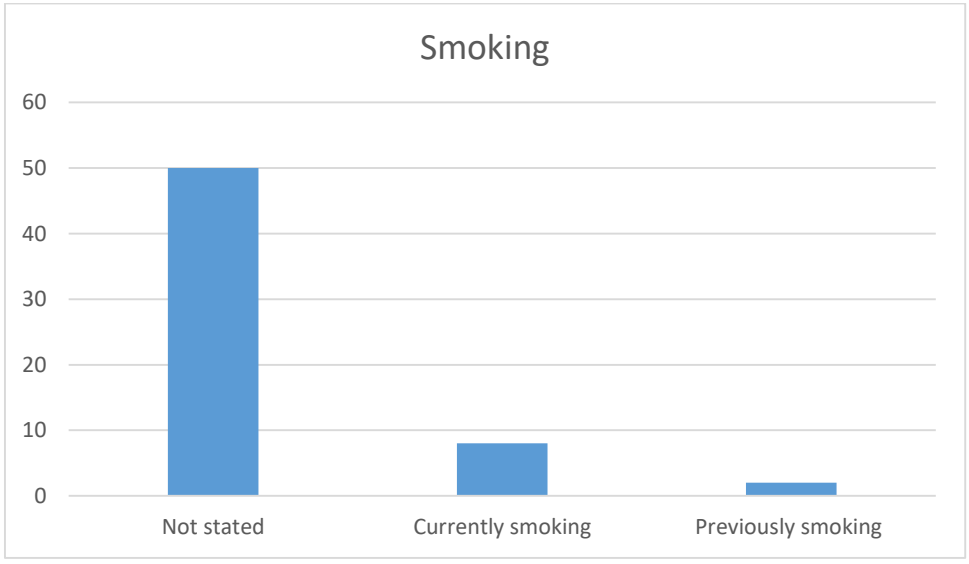

Figure 5.3. Smoking history of patients with OPSCC

5.2.2 Alcohol

Four (6.7%) OPSCCs occurred in patients that were current alcohol consumers at the time of diagnosis (**Figure** 5.4). There was no history of alcohol consumption in the remaining patients with OPSCC (56; 93.3%). Of the 4 OPSCCs in patients that were alcohol users, 3 (75%) occurred in the posterior tongue and 1 (25%) in the BOT. All of the tumours in patients that were alcohol consumers were p16 -ve.

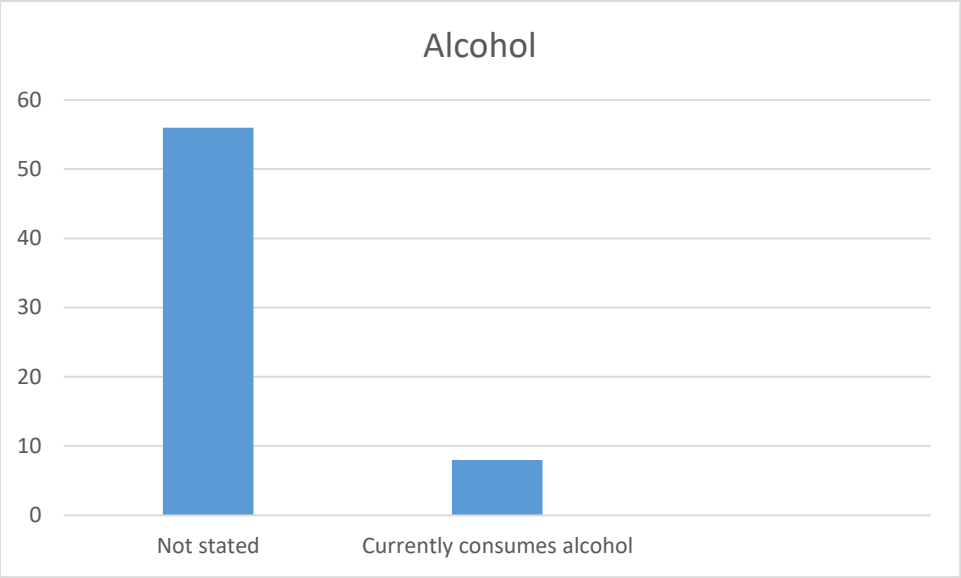

Figure 5.4. Alcohol history of patients with OPSCC

5.3 Tumour site

OPSCC occurred mainly in the tonsils (23; 38.3%), followed by the posterior tongue (22; 36.7%) and BOT (8; 13.3%) (**Figure** 5.5).

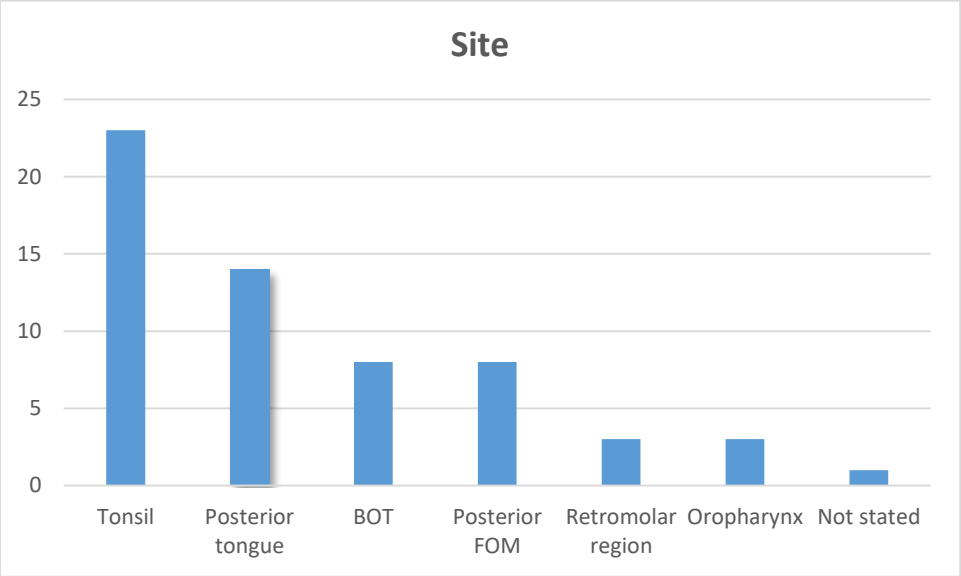

Figure 5.5. Total count proportions of tumour site amongst OPSCC

5.4 Microscopic findings and histological category

Of the 60 OPSCC cases, 30 were KSCC and 30 were NKSCC (**Figures** 5.6 and 5.7). The NKSCC showed a basaloid or undifferentiated morphology, with some tumours exhibiting a pushing border. The malignant cells were arranged in sheets, nests and trabeculae with a distinctive basaloid morphology. The tumour cells displayed distinct cell borders, high nuclear to cytoplasmic ratios, hyperchromatic nuclei and inconspicuous nucleoli. There was brisk mitotic activity. A minimal desmoplastic stromal response was seen. The cells of the KSCC were arranged in irregular nests and cords with single cell infiltration of the malignant cells. The malignant cells had well defined cell borders, eosinophilic cytoplasm, round to oval nuclei and conspicuous nucleoli. Brisk mitotic activity was evident. A desmoplastic stromal response was present.

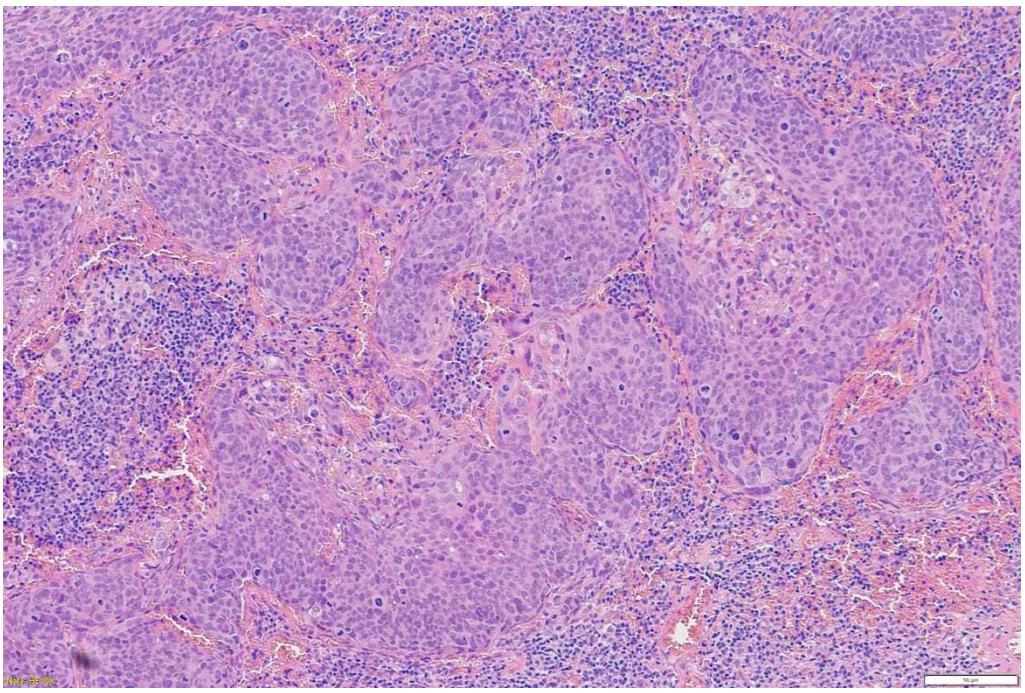

Figure 5.6. NKSCC with basaloid morphology (H&E, original magnification X10)

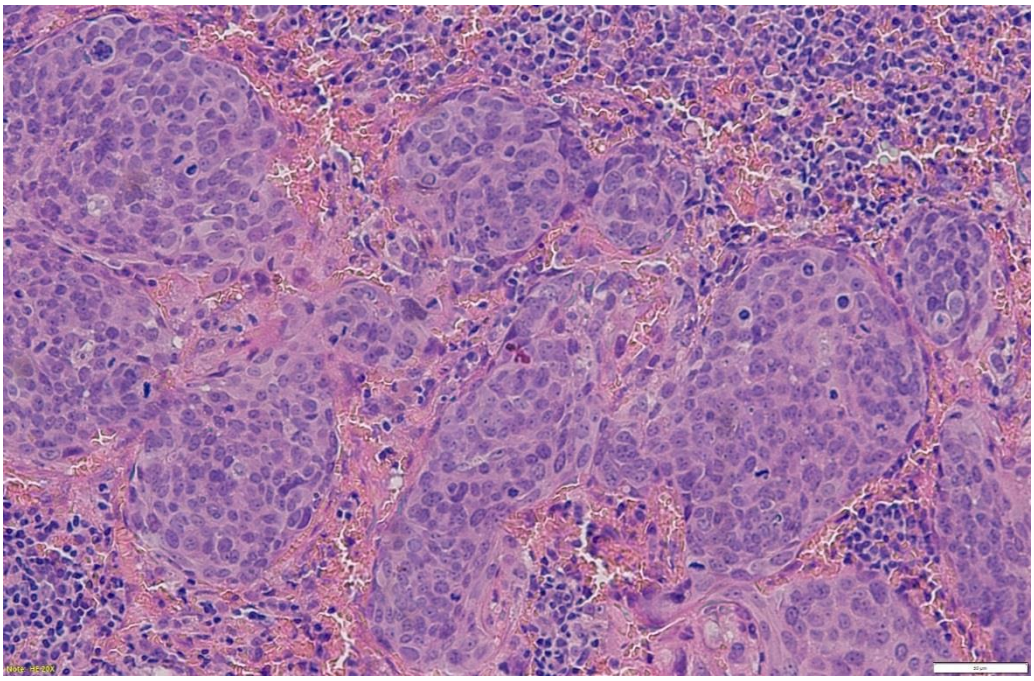

Figure 5.7. NKSCC tumour cells arranged in nests exhibiting a basaloid morphology (H&E, original magnification X20)

The gender distribution of the patient with KSCC and NKSCC cases are shown in **Table** 5.1.

HR HPV16 was seen in a small proportion of KSCC verses slightly higher proportion of NKSCCs (**Table** 5.1). The NKSCC subtype showed staining in a proportion of the cases. The LR HPV6, however, was not seen in all the KSCC subtype and there was statistically significant difference in the HPV6 ISH by morphology (Pearson Chi-Square; $p<0.01$) as shown in **Table** 5.1.

The immunohistochemical profiles of the NKSCC and KSCCs differed (**Table** 5.1). Strong and diffuse staining was seen in the majority of the NKSCC (**Figure** 5.8). Concerning p53, both tumours subtypes (NKSCC and KSCC) stained almost equally the same (**Figure** 5.9 and **Table** 5.1). The NKSCC showed a molecular phenotype p16+ve/ p53-ve/elevated Ki67 in contrast to the KSCCs as shown in **Table** 5.1.

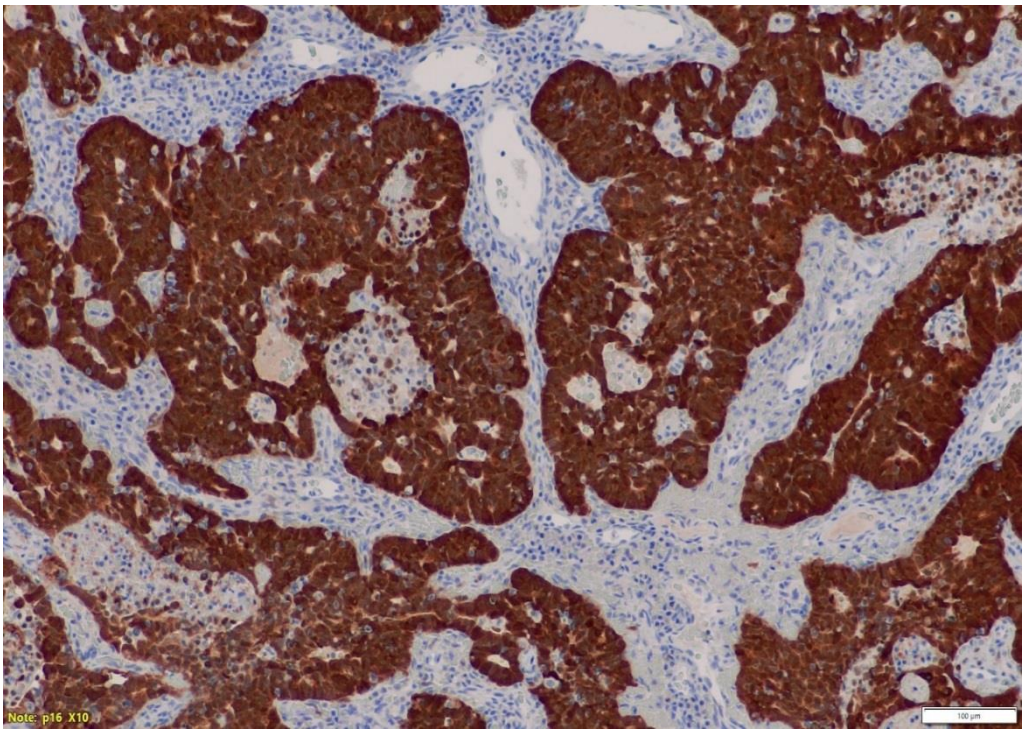

Figure 5.8. Strong and diffuse nuclear and cytoplasmic p16+ve staining in 100% of the NKSCC tumour cells (x10)

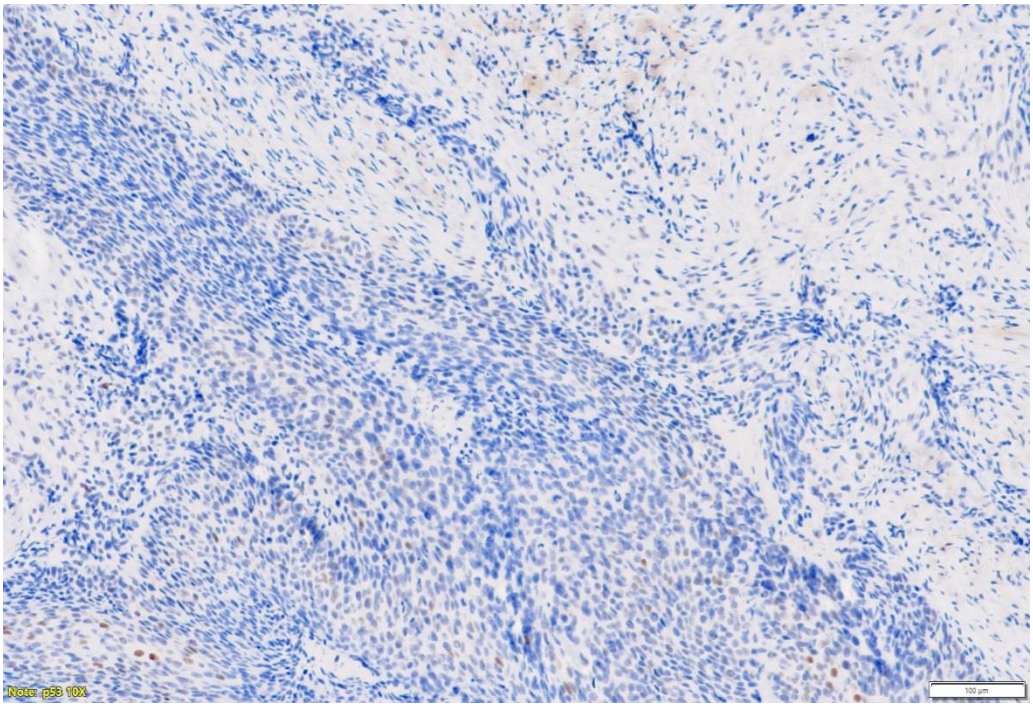

Figure 5.9. Focal moderate p53+ve nuclear staining NKSCC tumour cells (x10)

Table 5.1 Summary of the clinical characteristics of the patients with OPSCC categorised by histologic type (Fisher's exact test)

Histologic type	**NKSCC (*n*=30)**		**KSCC (*n*=30)**	
	n	**%**	***n***	**%**
Gender				
Male	22	73.3	24	80
Female	7	23.3	5	16.7
Not stated	1	3.3	1	3.3
HR HPV (16) ISH	11	36.7	7	23.3
LR HPV (6) ISH	8	26.7	0	0
P value	*p*=0.260		-	
p16	17	56.7	5	16.7
p53-ve	12	40	14	46.7
p16+ve/ p53-ve/ elevated Ki67	3	10	0	0

5.5 HPV ISH and genotypes

HPV (HPV16 and HPV6) was positive in 24/60 (40%) OPSCCs and negative in 36/60 (60%). The mean age of patients with HPV+ve OPSCC was 60.67 years; (range 34-87, SD, 10.25). The primary sites for HPV+ve OPSCC were the BOT (6; 10%) and the tonsil (6; 10%). The other sites included the posterior tongue (4; 6.7%), posterior FOM (3; 5%), retromolar region (2; 3.3%), oropharynx (1; 1.7%), posterior pharyngeal wall (1; 1.7%) and tonsillar fossa (1; 1.7%). Of these, 42/60 (70%) were HPV16-ve and 18/60 (30%) were HPV16+ve; and 52/60 (86.7%) were HPV6-ve and 8/60 (13.3%) were HPV6+ve. Two cases (3.3%) showed positivity for both HPV16 and HPV6.

5.5.1 HPV16 ISH status

The HPV16 ISH status was available for all 60 OPSCC cases. Of these, 42 (70%) were HPV16-ve and 18 (30%) were HPV16+ve as shown in (**Table** 5.2). Of the 18 HPV+ve OPSCCs, 7 (38.9%) were KSCC and 11 (61.1%) were NKSCC. (**Figures** 5.10 and 5.11). There was no statistically significant difference in the HPV16 ISH status of KSCC and the NKSCC (Pearson Chi-Square; p=0.260).

HPV 16 was seen more in male patients as shown in **Table** 5.2. The location of the tumours is summarised in **Table** 5.2.

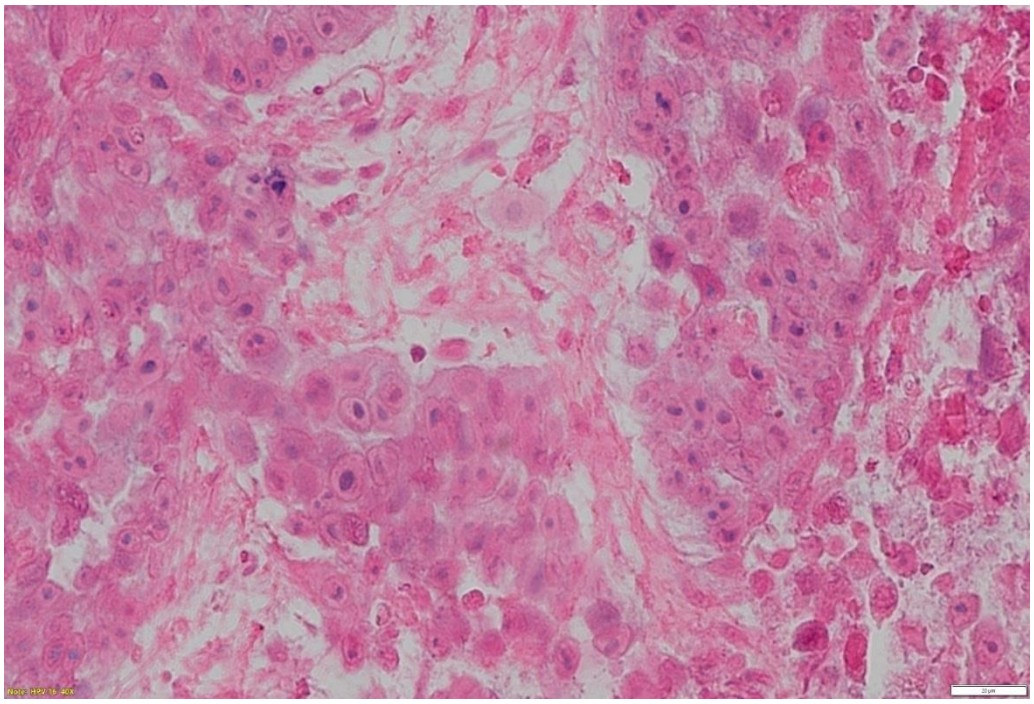

Figure 5.10. HPV16+ve ISH in NKSCC cells seen as blue nuclear dot staining (x10)

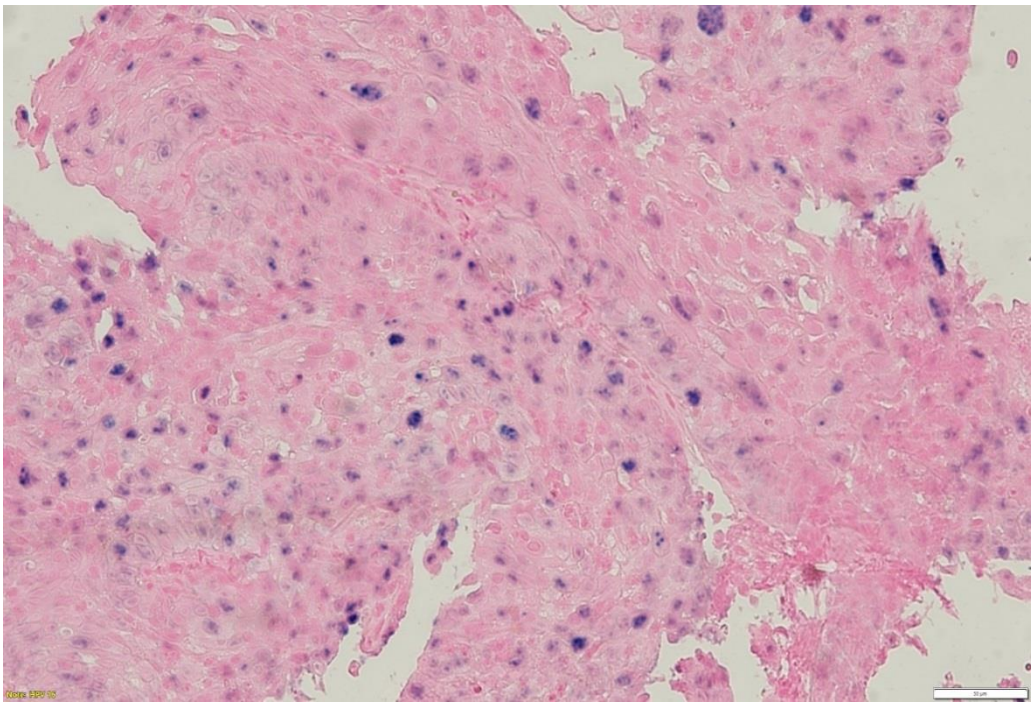

Figure 5.11. Dense blue nuclear dot HPV16+ve ISH in NKSCC tumour cells (x10)

5.5.1.2 p16 Immunohistochemistry

Of the 18 HPV16+ve cases, 10 (55.6%) were positive for p16 and 8 (44.4%) cases were negative for p16. There was no statistically significant difference in the HPV16 ISH status with regards to p16 (Pearson Chi-Square; *p*=1).

5.5.1.3 p53 Immunohistochemistry

Of the 18 HPV16+ve cases, 8 (44.4%) cases were positive for p53 and 8 (44.4%) cases were negative for p53. The tissue washed off in 2 (11.1%) cases. There was no statistically significant difference in the HPV16 ISH status with regards to p53 (Pearson Chi-Square; *p*=0.3993).

5.5.1.4 Ki67 Immunohistochemistry

The Ki67 score in the 18 HPV16+ve cases was < 25% in 1 (5.6%) case, 25-50% in 12 (66.7%) cases and 50-75% in 3 (16.7%) cases (**Figure** 5.12). The tissue washed off in 2 (11.1%) cases.

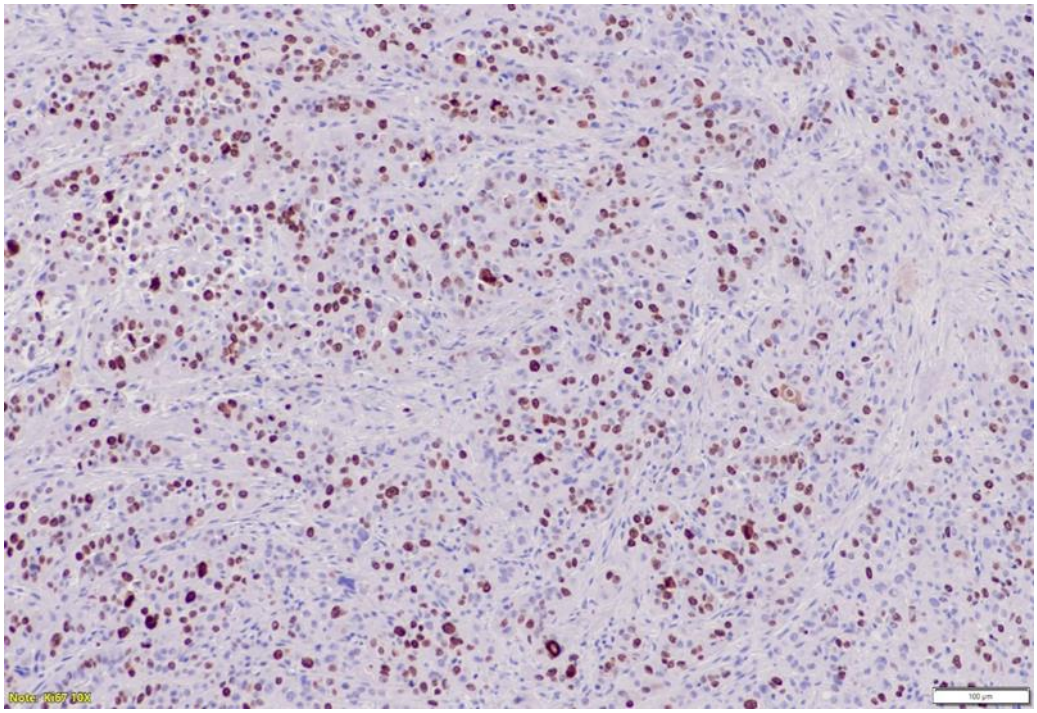

Figure 5.12. Dense brown nuclear Ki67+ve NKSCC cells (x10)

5.5.1.5 Molecular phenotype

Of the HPV16+ve cases, 3/18 (16.7%) showed the p16+ve/p53-ve/elevated Ki67 molecular phenotype.

5.5.1.6 Comparison of HPV16 ISH status with P16 IHC

When comparing HPV16 and p16, there were 10/18 (55.6%) p16+ve HPV16+ve tumours and 8/18 (44.4%) p16+ve HPV-ve tumours. There was no statistically significant difference (p=1). The PPV in this case was 76.92%. The negative predictive value (NPV) in this case was 27.27 %. The sensitivity was calculated as 55.56 % and the specificity as 50%.

5.5.1.7 Comparison of HPV16 status with P53 IHC

In the HPV16+ve tumours, there were 9/60 (15%) p53-ve and 13/60 (21.7%) p53+ve tumours. The p53 positivity status was not statistically significantly different for HPV16 (Pearson Chi-Square; p<0.3993).

5.5.2 HPV6 ISH status

HPV6 ISH status was available for 60 OPSCC cases. Of these, 52 (86.7%) were HPV6-ve and 8 (13.3%) were HPV6+ve (**Table** 5.2). All 8 HPV6+ve cases were NKSCCs. There was no statistically significant difference (Pearson Chi-Square; p=0.002).

The ages and gender distribution of patients is shown in **Table** 5.2 . The location of all tumours is summurised in **Table** 5.2.

5.5.2.1 p16 Immunohistochemistry

Of the 8 HPV6+ve cases, 3 (37.5%) were positive for p16 and 5 (62.5%) were negative for p16. There was no statistical significance in the HPV6 ISH status with regards to p16 (Pearson Chi-Square; p=0.38).

5.5.2.2 p53 Immunohistochemistry

Of the 8 HPV6+ve cases, 6 (75%) were positive for p53 and 2 (25%) were negative for p53. There was no statistically significant difference in the HPV6 ISH status with regards to p53 (Pearson Chi-Square; p=0.46).

5.5.2.3 Ki67 Immunohistochemistry

Of the 8 HPV6+ve cases, 5 (62.5%) cases showed Ki67 scores of between 25-50% and 3 (37.5%) cases showed Ki67 scores of between 50-75%.

5.2.2.4 Comparison of HPV6 status with p16 IHC

When comparing HPV6 and p16, there were 3/60 (5%) p16+ve HPV6+ve tumours and 5/60 (8.3%) HPV-ve tumours. There was no statisticallly significant difference (*p*=0.3833). The PPV in this case was 23.08% and the NPV was 54.55 %. The sensitivity was now calculated as 37.5% and the specificity as 37.5%.

5.2.2.5 Comparison of HPV6 ISH status with P53 IHC

In the HPV6+ve tumours, there were 2/60 (3.3%) p53-ve and 6/60 (10%) p53+ve tumours. This was not statistically significantly different (Pearson Chi-Square; *p*=0.4683).

Table 5.2 Summary of the clinical characteristics of patients with OPSCC, p16, p53, Ki67 and molecular phenotype by HPV ISH subtype

HPV ISH	**HR HPV 16+ (18)**		**LR HPV 6+ ISH (8)**	
Age (mean SD)	63.44 ± 10.31		62 ± 11.92	
	N	%	*n*	%
Gender				
Male	13	72.2	7	87.5
Female	5	27.38	1	12.5
P value	*p*=0.281		*p*=0.6337	
Site				
Tonsil	6	33.3	1	12.5
Posterior tongue	3	16.7	2	25
BOT	4	22.2	3	37.5
Posterior FOM	3	16.7	0	0
Oropharynx	1	5.5	1	12.5
Retromolar region	1	5.5	1	12.5
P value	*p*=0.260		*p*=0.002	

5.3 p16 Immunohistochemistry

p16 IHC was performed in 58 of the OPSCCs; 2 cases had insufficient tissue for analysis. Of these 58 cases, 22 (37.9%) were p16+ve and 36 (62.1%) were p16-ve. Of the 22 p16+ve cases, 11 (50%) were from the tonsils, 4 (18.2%) were from the BOT, 4 (18.2%) from the posterior tongue, 2 (9.1%) from the oropharynx, and the

site was not stated in 1 (4.5%) case. The p16 positivity status showed a statistically significant difference for site (Pearson Chi-Square; $p<0.001$).

5.4 p53 Immunohistochemistry

p53 IHC was performed in 57 of the OPSCCs. Three cases did not have enough tissue for analysis. Of the 57 cases, 31 (54.4%) were p16+ve and 26 (45.6%) were p16-ve. Of the 26 p53-ve cases, 9 (34.6%) were from the tonsils, 8 (30.8%) from the posterior tongue, 4 (15.4%) from the posterior FOM, 3 (11.5%) from the retromolar region, 1 (3.8%) from oropharynx, and the site was not stated in 1 (3.8%) case. The p53 positivity status did not show a statistically significant difference for site (Pearson Chi-Square; $p<0.28$).

5.5 Molecular phenotype

Of the HPV OPSCC, 3/60 (5%) showed the p16+ve/p53-ve/elevated Ki67 molecular phenotype.

CHAPTER 6

6.0 DISCUSSION

The prevalence of HPV infection (HPV16 and HPV6 ISH) in OPSCC in this study sample of patients from Johannesburg, South Africa was 40%. The percentage reflects similar findings by Wittekindt et al. (2019) of an HPV prevalence of 40% in Giessen, central Germany. The global HPV prevalence varies, mainly due to differences in geographic location, anatomic site of the tumours, or different methods used to detect HPV, e.g. ISH versus PCR (Chernock et al., 2010; Lechner et al., 2022). The study by Lechner et al. (2022) showed a global HPV prevalence of 33% in 2021. Likewise, Elrefaey et al. (2014) showed an HPV prevalence of up to 30% in central Europe. Contrary to the Western studies, sub-Saharan studies show a lower prevalence of HPV in OPSCC when compared to studies from the USA and Europe, despite increased rates of HPV infection in cancer of the cervix (Lechner et al., 2022). Studies from Mozambique and Cameroon found the prevalence of HPV to be 14.5% and 3.4% respectively (Ndiaye et al., 2013). South African studies show similar results to those of other sub-Saharan countries. Studies by Wood et al. (2020) and Dapaah et al. (2022) respectively show an overall pooled HPV prevalence of 11% and HR HPV positivity prevalence of 5% in South Africa. Although these studies show a lower prevalence, there has been a single report that showed a prevalence of 49.1% in their cohort of black South Africans confirming the role of HPV in the pathogenesis of OPSCC in these patients (Paquette et al., 2013).

Most of the HPV+ve OPSCC in our study were from were older males (median age of diagnosis: 62.5 years) with a male to female ratio of 3.83:1. Even though there was a male gender bias for HPV+ve OPSCC, the results showed this to be true for HPV-ve OPSCC too. There was no association between gender and HPV (p=0.6752). Due to the small cohort of patients in this study, there exists an imbalance of gender representation between the groups and a true association between HPV and gender thus could not be fully explored.

Similarly, Lechner et al. (2022) found that globally HPV+ve OPSCC is seen more in older males globally. In a study from America, the prevalence of HPV was 75% and seen more in white males, followed by a prevalence of 53.7-68.8% in non-Caucasian

females (Faraji et al., 2019). In contrast, Elrefaey et al. (2014) found HPV+ve OPSCC more in younger (median age at diagnosis: 54 years), affluent patients (caucasian:black = 8.5:1) with a similar male bias (M:F = 3.1). A study from the USA shows an increased OPSCC incidence in both men (3.9%) and woman (2.1%) between the ages of 20 and 44 years. Similarly, a report from Sweden also shows a 2.9 fold increase in men and women (2.6% and 1.1% per year respectively) over a 31-year period (Elrefaey et al., 2014).

Many studies confirm the strong aetiologic link between smoking and alcohol consumption in HPV-ve OPSCC, with less exposure to tobacco and alcohol in HPV+ve OPSCC. The smoking and alcohol history was not stated in most cases in our study compromising adequate comparison to other similar studies. However, many studies show that smoking and alcohol consumption are largely seen in HPV-ve OPSCC (Elrefaey et al., 2014).

In our study, HPV+ve OPSCC occurred most commonly in the tonsil, followed by the posterior tongue. However, there was no statistically significant relationship between HPV and site (p=0.2174). This increased incidence of HPV-associated OPCs, especially of the tonsil and tongue is well established (Andrews et al., 2009; (Elrefaey et al., 2014, Ramqvist et al., 2015). Both of these sites comprise lymphoid tissue, which is susceptible to HPV infection and carcinogenesis (Maroun et al., 2020; Ramqvist et al., 2015). Further, the predilection of HPV for the oropharynx is enigmatic. Studies have likened the histology of the transitional mucosa in the oropharynx, and especially the tonsil to that of the cervical mucosa. Yet others have suggested the genetic characteristics of HPV16 seen in >90% of OPSCC to preferably involve the tonsillar crypt epithelium. This together with the mucosal invaginations of the tonsil enhance and preserve HPV within the proliferating basal cells of the epithelium. Tonsillar tissue thus creates a pool for HPV infection that is significant to the host immune response (Elrefaey et al., 2014).

Many studies demonstrate a link between HPV, more so HPV16 and OPSCC. Similar to other HPV-associated cancers, namely cervical and anogenital cancer and non-pharyngeal SCC, HPV16 has been implicated in the aetiology of OPSCC (Elrefaey et al., 2014; Lechner et al., 2022; Weinberger et al., 2006). In our study, both HPV16+ve and HPV6+ve tumours were seen mainly in the tonsil and BOT.

Most of these HPV+ve OPSCC were HPV16+ve (30%) compared to HPV6 (26.7%). Furthermore, HPV6+ve tumours were also notably found in the posterior FOM, when compared to HPV16+ve tumours. Both HPV16+ve and HPV6+ve tumours were seen mainly in elderly males with a median age of 62.5 years and 57.5 years, and a male to female ratio of 3.8:1 and 6.9:1 respectively.

The tumour suppressor protein, p16 shows overexpression in HPV-associated tumours, especially the high-risk oncogenic subtypes. p16 IHC is reported to be a prognostic and surrogate marker for the oncogenic HPV subtype and is thus not ideal as a test for OPSCC patients (Lewis Jr 2020). p16 shows high sensitivity for transcriptionally active HPV E6 and E7 oncoproteins (Sritippho et al., 2016). Some reports have previously advocated the use of p16 IHC as a stand-alone test, yet others argue that p16 does not measure transcriptionally active HPV E6 and E7 oncoproteins (Chi et al., 2020; Lewis Jr, 2012). This is of concern when p16 staining is used for risk stratification, since patients with aggressive tumours that are p16+ve but HPV-ve will be classified as low-risk. Recent studies, however show that p16+ve tumours have a favourable outcome independently from HPV (Chi et al., 2020). Lewis Jr et al. (2010) report that the addition of HPV ISH does not improve survival correlation. Later, Lewis Jr et al. (2020) suggest that the gold standard testing modality be testing for high risk HPV E6/E7 mRNA. Although previously not practically and clinically viable, HPV RNA ISH is increasingly more usable in routine clinical practice (Lewis Jr et al., 2020).

In our study, p16 IHC as a marker of oncogenic HPV infection in HPV16+ve OPSCC showed 16.7% positivity and yielded a specificity of 50% and a sensitivity of 55.56%. This is similar to the findings of Dapaah et al. (2022), who demonstrated p16 positivity of 14% in their cohort of 266 OPSCCs in sub-Saharan Africa, of which only 5% of these OPSCC were positive for transcriptionally active HR HPV by PCR. Likewise, a study from Northeast China found p16 overexpression and HVP positivity in 5.1% and 5.31% respectively of the 1470 OPSCCs analysed (Meng et al., 2018). However, a study from Germany found an elevated p16 level in most HPV DNA-containing tumours, and found that all HPV16+ve tumours evaluated expressed p16 (Geißler et al., 2013). In contrast, a Taiwanese study suggests the sensitivity and specificity of p16+ve IHC attests to p16 being used as a surrogate marker for HR HPV (Sritippho et al., 2016).

There is a discrepancy in the p16 sensitivity and specificity findings in our study when compared to other reports; the latter showing p16 overexpression with high sensitivity and specificity for transcriptionally active HR HPV. A study from the USA found 82% p16 positivity, and 84% HPV mRNA positivity, with an overall double positivity (P16+ve/HPV+ve) in 81% of the 467 OPSCCs in their study (Shinn et al., 2021). The discrepancies in the regional studies, more specifically African, Western and Asian countries may well relate to the HPV incidence of the population, sexual practices and the HPV subtypes. The low sensitivity in our study attests to the fact that p16 cannot be used as a surrogate marker for HR HPV infection in the setting of our population.

Even though there is a link between HPV and HR HPV16, biologically significant HPV should be determined. HPV can initiate carcinogenesis but it is not enough to induce transformation into malignant cells (Weinberger et al., 2006). Many tumours express HPV DNA; however, they need to express HPV oncoproteins for malignant transformation to occur (Weinberger et al., 2006). Various studies determine the tumour biology/molecular phenotype by using p16+ve, p53-ve, with/without the Ki67 index (Weinberger et al., 2006). The molecular phenotype or tumour biology of HPV+ve OPSCC was seen in 5% (n=3) of the tumours confirming a viral aetiology. Weinberger et al. (2006) found that of the 17% of cases that express HPV DNA, only 8% expressed HPV oncoproteins (E6/E7) (Lechner et al., 2022). The most common HR HPV subtype in the OPSCC is HPV16 (Nichols et al., 2013).

TP53, the guardian genome, is a tumour suppressor gene that inhibits cells from accumulating damaged DNA, as it induces pathways that ultimately lead to apoptosis or to cell cycle arrest (Cruz et al., 2002). Mutated forms of p53 do not have these functions and are associated with human cancers, more specifically KSCC of the upper aero-digestive tract (El-Mofty and Patil, 2006). An inverse relationship is seen with HPV+ve NKSCC (Elrefaey et al., 2014). In our study, 45.6% HPV+ve OPSCC were p53 negative. There was no statistically significant relationship between HPV and p53.

The majority of HPV16+ve and HPV6+ve tumours showed a Ki67 proliferation index between 25-50%, findings similar to that of El-Mofty and Patil (2006). In our study,

the prevalence of HPV16 and HPV6 genotype in NKSCC was 36.67% and 20% respectively. In the KSCC, the prevalence of HPV16 and HPV6 genotype was 23.3% and 0% respectively. HPV16 is thus the more common genotype. Fakhry et al. (2020) also found HPV16 to be the most common oncogenic type detected in tumours with oncogenic HPV infection (Fakhry et al., 2020). Other studies similarly record a higher prevalence of HPV16 in their cohorts among the HR HPV subtypes involved in head and neck carcinogenesis, with a prevalence of over 80% in OPSCC, followed by HPV18 (3%) (Castellsagué et al., 2016; Ndiaye et al., 2014). The HPV negative cases in our study may be due to the presence of other HPV subtypes that were not investigated (Chernock et al., 2010). Studies show that other HR oncogenic subtypes of HPV such as HPV18 and HPV33 occur in 1-3% of oropharyngeal tumours (Klussmann et al., 2003). The variability in HPV findings could also be due to the different techniques used to investigate HPV such as ISH or PCR. Both these methods, ISH and PCR, have limitations (Chernock et al., 2010; Lechner et al., 2022). HPV ISH is less sensitive than PCR and PCR identifies the virus and not specific tumour cells, which may not be clinically relevant (Chernock et al., 2010).

In our study, both NKSCC and KSCC occurred in older patients, mostly affecting males. There was a strong association between the presence of HPV6 and NKSCC and KSCC. In contrast, this association was not evident between HPV16 and the tumours. In addition, there was a strong association p16 and NKSCC and KSCC.

A small subset of NKSCC HPV+ve cases (5%) in our study showed the distinct molecular phenotype, HPV+ve/p16+ve/p53-ve/increased Ki67. This molecular phenotype commonly occurs in poorly differentiated OPSCC with a proven viral aetiology, and which are associated with a favourable outcome (Weinberger et al., 2006; Lewis Jr, 2017). Not all HPV+ve KSCCs showed this distinct molecular phenotype, possibly inferring a non-viral aetiology. Weinberger et al. (2006) also note that tumours with this molecular signature are poorly differentiated; show decreased local recurrence rates and occur in patients that are smokers and consume alcohol. Other molecular subgroups observed are the HPV+ve/p16-ve subgroup and HPV-ve subgroup regardless of the Ki67 index. These two subgroups show high local recurrence (Weinberger et al., 2006). Klussmann et al. (2003) show that two (11%) of the HPV18+ve tumours did not express p16, and that both these tumours recurred.

Most of the HPV+ve NKSCCs in our study were negative for p53, or showed <25% p53 staining, corroborating previous reports that show that HPV OPSCC does not harbour p53 mutations (Lechner et al., 2022). On the other hand, most KSCCs are p53+ve and show the TP53 mutation, which is associated with poor response to therapy (Cruz et al., 2002).

Even though previous reports state that HPV+ve NKSCC has a favourable outcome compared to KSCC, current data now suggests that HPV+ve KSCC shows a similar favourable outcome as that seen in HPV+ve NKSCC. Thus regarding prognosis, molecular testing for HPV is proven superior to morphologic assessment (Lewis Jr, 2017). Unfortunately, in our study, patients were lost to follow up and thus the void in data on patient outcome and prognosis.

In 2008, two HPV vaccines were accepted by the Medicine Control Council of South Africa., and subsequently a vaccination program was launched in South Africa in 2014 which was aimed at school going girls between the ages of 9 and 14 years. A bivalent vaccine, targeting HPV16 and HPV18 was used (Delany-Moretlwe et al., 2018). Since there are numerous other HR HPV subtypes, adequte coverage by the vaccine may not be attainable.

The small cohort of patients in our study proved to be a limitation of the study, especially regarding adequate statistical analysis. This was further compounded by the fact that tissue washed off or cut away in a few cases. A further limitation was the lack of clinical information in most patients regarding the smoking and alcohol use history, and thus an association with HPV was not possible. Due to limited funding, only two genotypes were tested and other HR oncogenic subtypes were not explored. Patients were lost to follow-up and could not be traced patient to determine final outcomes, in terms of treatment and prognosis.

Nevertheless, the strength of this study is that provides a pertinent overview of HPV in a defined population in Johannesburg, South Africa. Furthermore it supports previous findings and despite the limitations provides a baseline for future studies on HPV OPSCC studies, especially in South Africa.

CHAPTER 7

7.0 CONCLUSION

This study confirmed the increased prevalence of HPV in OPSCC, particularly HPV16 in a defined subset of patients in the Department of Oral Pathology, University of the Witwatersrand, Johannesburg, South Africa.

As with international and specifically African trends, HPV+ve OPSCC was common in older males, in the tonsil and exhibited a distinct basaloid, non-keratinising morphology.

A small proportion of the HPV+ve OPSCCs shows a distinct molecular profile, p16+ve (> 70%/ p53-ve or <25% +ve/Ki67+ve (> 25%) establishing a viral aetiology.

The low p16 IHC staining sensitivity towards HPV16+ve tumours infers that p16 is less reliable when used alone as a surrogate marker for HPV OPSCC. Thus, it is imperative that in cases of OPSCC with a basaloid, non-keratinisng morphology in which there is a high suspicion for HPV, a negative p16 IHC stain should be followed by other molecular techniques such as HPV ISH.

The South African population, like that of Africa has a different clinical and genetic profile compared to that of other parts of the world. Although HPV OPSCC aetiopathogenesis is associated with oral sexual practices, this may not be true for the African population. Thus, further studies from Africa are needed to expand on the association of HPV with OPSCC, especially looking at other HPV HR subtypes that are endemic in this region and other risk factors that are pertinent to this continent.

The current HPV laboratory cocktails used do not encompass all HPV subtypes. Larger studies are thus needed to establish the true viral aetiology of HPV OPSCC, specifically by identifying transcriptionally active E6 and E7 oncoproteins using more sensitive techniques such as RNA ISH. The true identity of HPV subtypes in OPSCC is important if we are to render vaccination programs that will specifically target the HPV in the African population.

CHAPTER 8

8.0 REFERENCES

Amini, A., Jasem, J., Jones, B.L., Robin, T.P., McDermott, J.D., Bhatia, S., Raben, D., Jimeno, A., Bowles, D.W., Karam, S.D. (2016). Predictors of overall survival in human papillomavirus-associated oropharyngeal cancer using the National Cancer Data Base. *Oral Oncology*. 56, p.1-7.

Amponsah-Dacosta, E., Blose, N., Nkwinika, V.V., Chepkurui, V. (2022). Human papillomavirus vaccination in South Africa: programmatic challenges and opportunities for integration with other adolescent health services? *Frontiers in Public Health*. 10.

Andrews, E., Seaman, W.T., Webster-Cyriaque, J. (2009). Oropharyngeal carcinoma in non-smokers and non-drinkers: a role for HPV. *Oral Oncology*. 45 (6), p. 486-491.

Attner, P., Du, J., Näsman, A., Hammarstedt, L., Ramqvist, T., Lindholm, J., Marklund, L., Dalianis, T., Munck-Wikland, E. (2010). The role of human papillomavirus in the increased incidence of base of tongue cancer. *International Journal of Cancer*. 126 (12), p. 2879-2884.

Augustin, J.G., Lepine, C., Morini, A., Brunet, A., Veyer, D., Brochard, C., Mirghani, H., Péré, H., Badoual, C. (2020). HPV detection in head and neck squamous cell carcinomas: what is the issue? *Frontiers in Oncology*. 10, p.1751.

Blumberg, J., Monjane, L., Prasad, M., Carrilho, C., Judson, B.L. (2015). Investigation of the presence of HPV related oropharyngeal and oral tongue squamous cell carcinoma in Mozambique. *Cancer Epidemiology*. 39 (6), p. 1000-1005.

Boscolo-Rizzo, P., del Mistro, A., Bussu, F., Lupato, V., Baboci, L., Almadori, G., DA Mosto, M.C., Paludetti, G. (2013). New insights into human papillomavirus-associated head and neck squamous cell carcinoma. *ACTA Otorhinolaryngologica Italica*. 33 (2), p. 77-87.

Buckley, L., Gupta, R., Ashford, B., Jabbour, J., Clark, J.R. (2016). Oropharyngeal cancer and human papilloma virus: evolving diagnostic and management paradigms. *ANZ Journal of Surgery*. 86 (6), p. 442-447.

Castellsagué, X., Alemany, L., Quer, M., Halec, G., Quirós, B., Tous, S., Clavero, O., Alòs, L., Biegner, T., Szafarowski, T., Alejo, M., Holzinger, D., Cadena, E., Claros, E., Hall, G., Laco, J., Poljak, M., Benevolo, M., Kasamatsu, E., Mehanna, H., Ndiaye, C., Guimerà, N., Lloveras, B., León, X., Ruiz-Cabezas, J.C., Alvarado-Cabrero, I., Kang, C-S., Oh, J-K., Garcia-Rojo, M., Iljazovic, E., Ajayi, O.F., Duarte, F., Nessa, A., Tinoco, L., Duran-Padilla, M.A., Pirog, E.C., Viarheichyk, H., Morales, H., Costes, V., Félix, A., Germar, M.J. V., Mena, M., Ruacan, A., Jain, A., Mehrotra, R., Goodman, M.T., Lombardi, L.E., Ferrera, A., Malami, S., Albanesi, E.I., Dabed, P., Molina, C., López-Revilla, R., Mandys, V., González, M.E., Velasco, J., Bravo, I.G., Quint, W., Pawlita, M., Muñoz, N., de Sanjosé, S., Bosch, F.X. ICO International HPV in head and neck cancer study group. (2016). HPV involvement in head and neck cancers: comprehensive assessment of biomarkers in 3680 patients. *Journal of the National Cancer Institute*. 108 (6), p. djv403.

Chai, R.C., Lambie, D., Verma, M., Punyadeera, C. (2015). Current trends in the etiology and diagnosis of HPV-related head and neck cancers. *Cancer Medicine*. 4 (4), p. 596-607.

Chaturvedi, A.K. (2012). Epidemiology and clinical aspects of HPV in head and neck cancers. *Head and Neck Pathology*. 6 (Suppl 1), p. S16-S24.

Chaturvedi, A.K., Engels, E.A., Pfeiffer, R.M., Hernandez, B.Y., Xiao, W., Kim, E., Jiang, B., Goodman, M.T., Sibug-Saber, M., Cozen, W., Liu, L., Lynch, C.F., Wentzensen, N., Jordan, R.C., Altekruse, S., Anderson, W.F., Rosenberg, P.S., Gillison, M.L. (2011). Human papillomavirus and rising oropharyngeal cancer incidence in the United States. *Journal of Clinical Oncology*. 29 (32), p. 4294-4301.

Chernock, R.D. (2012). Morphologic features of conventional squamous cell carcinoma of the oropharynx: ‘keratinizing’ and ‘nonkeratinizing’ histologic types as the basis for a consistent classification system. *Head and Neck Pathology*. 6 Suppl 1 (Suppl 1), p. S41-S47.

Chernock, R.D., Lewis Jr, J.S., Zhang, Q., El-Mofty, S.K. (2010). Human papillomavirus-positive basaloid squamous cell carcinomas of the upper aerodigestive tract: a distinct clinicopathologic and molecular subtype of basaloid squamous cell carcinoma. *Human Pathology*. 41 (7), p. 1016-1023.

Chernock, R.D., Zhang, Q., El-Mofty, S.K., Thorstad, W.L., Lewis Jr, J.S. (2011). Human papillomavirus-related squamous cell carcinoma of the oropharynx: a comparative study in whites and African Americans. *Archives of Otolaryngology-Head and Neck Surgery*. 137 (2), p. 163-169.

Chi, J., Preeshagul, I.R., Sheikh-Fayyaz, S., Teckie, S., Kohn, N., Ziemba, Y., Laser, A., Frank, D., Ghaly, M., Kamdar, D., Kraus, D., Paul, D., Seetharamu, N. (2020). Evaluating of HPV-DNA ISH as an adjunct to p16 testing in oropharyngeal cancer. *Future Science OA*. 6 (9), p. FSO606.

Cruz, I., Snijders, P.J.F., van Houten, V., Vosjan, M., Van der Waal, I., Meijer, C.J.L.M. (2002). Specific p53 immunostaining patterns are associated with smoking habits in patients with oral squamous cell carcinomas. *Journal of Clinical Pathology*. 55 (11), p. 834-840.

Dalianis, T. (2014). Human papillomavirus and oropharyngeal cancer, the epidemics, and significance of additional clinical biomarkers for prediction of response to therapy (Review). *International Journal of Oncology*. 44 (6), p. 1799-1805.

Dapaah, G., Hille, J., Faquin, W.C., Whittaker, J., Dittrich, C.M., Ebrahim, A-K., Schneider, J.W., van Wyk, A.C., Opperman, J., Merven, M., Naidoo, K., Loock, J.W., Afrogheh, A.H. (2022). The prevalence of human papillomavirus-positive oropharyngeal squamous cell carcinoma at one of the largest tertiary care centers in sub-Saharan Africa. *Archives of Pathology & Laboratory Medicine*. 146 (8), p. 1018-1023.

Davidson, C.L., Richter, K.L., Van der Linde, M.D., Coetsee, J., Boy, S.C. (2014). Prevalence of oral and oropharyngeal human papillomavirus in a sample of South African men: a pilot study. *South African Medical Journal*. 104 (5), p. 358-361.

De Felice, F., Tombolini, V., Valentini, V., de Vincentiis, M., Mezi, S., Brugnoletti, O., Polimeni, A. (2019). Advances in the management of HPV-related oropharyngeal cancer. *Journal of Oncology*. 2019:9173729.

de Villiers, E-M., Fauquet, C., Broker, T.R., Bernard, H-U., zur Hausen, H. (2004). Classification of papillomaviruses. *Virology*. 324 (1), p. 17-27.

Delany-Moretlwe, S., Kelley, K.F., James, S., Scorgie, F., Subedar, H., Dlamini, N.R., Pillay, Y., Naidoo, N., Chikandiwa, A., Rees, H. (2018). Human papillomavirus

vaccine introduction in South Africa: implementation lessons from an evaluation of the national school-based vaccination campaign. *Global Health: Science and Practice*. 6 (3), p. 425-438.

Dietz, A., Wichmann, G., Wiegand, S. (2017). Should we de-escalate the treatment for HPV-positive tumors? *Recent Results in Cancer Research*. 206, p. 173-181.

Dok, R., Nuyts, S. (2016). HPV positive head and neck cancers: molecular pathogenesis and evolving treatment strategies. *Cancers (Basel)*. 8 (4), p. 41.

Donà, M.G., Rollo, F., Pichi, B., Spriano, G., Moretto, S., Covello, R., Pellini, R., Benevolo, M. (2020). Evolving profile of HPV-driven oropharyngeal squamous cell carcinoma in a National Cancer Institute in Italy: a 10-year retrospective study. *Microorganisms*. 8 (10), p. 1498.

Economopoulou, P., Kotsantis, I., Psyrri, A. (2020). Special issue about head and neck cancers: HPV positive cancers. *International Journal of Molecular Sciences*. 21 (9), p. 3388.

El-Mofty, S.K., Patil, S. (2006). Human papillomavirus (HPV)-related oropharyngeal nonkeratinizing squamous cell carcinoma: characterization of a distinct phenotype. *Oral Surgery, Oral Medicine, Oral Pathology, Oral Radiology, and Endodontology*. 101 (3), p. 339-345.

El-Naggar, A.K., Westra, W.H. (2012). p16 expression as a surrogate marker for HPV-related oropharyngeal carcinoma: a guide for interpretative relevance and consistency. *Head & Neck*. 34 (4), p.459-461.

Elrefaey, S., Massaro, M.A., Chiocca, S., Chiesa, F., Ansarin, M. (2014). HPV in oropharyngeal cancer: the basics to know in clinical practice. *ACTA Otorhinolaryngologica Italica*. 34 (5), p. 299-309.

Faggons, C.E., Mabedi, C., Shores, C.G., Gopal, S. (2015). Review: Head and neck squamous cell carcinoma in sub-Saharan Africa. *Malawi Medical Journal*. 27 (3), p. 79-87.

Fakhry, C., Fung, N., Tewari, S.R., D'Souza, G. (2020). Unique role of HPV16 in predicting oropharyngeal cancer risk more than other oncogenic oral HPV infections. *Oral Oncology*. 111:104981.

Fakhry, C., Lacchetti, C., Rooper, L.M., Jordan, R.C., Rischin, D., Sturgis, E.M., Bell, D., Lingen, M.W., Harichand-Herdt, S., Thibo, J., Zevallos, J., Perez-Ordonez, B. (2018). Human papillomavirus testing in head and neck carcinomas: ASCO clinical practice guideline endorsement of the College of American Pathologists guideline. *Journal of Clinical Oncology*. 36 (31), p.3152-3161.

Faraji, F., Rettig, E.M., Tsai, H-L., El Asmar, M., Fung, N., Eisele, D.W., Fakhry, C. (2019). The prevalence of human papillomavirus in oropharyngeal cancer is increasing regardless of sex or race, and the influence of sex and race on survival is modified by human papillomavirus tumor status. *Cancer*. 125 (5), p. 761-769.

Feller, L., Wood, N.H., Khammissa, R.A.G., Lemmer, J. (2010). Human papillomavirus-mediated carcinogenesis and HPV-associated oral and oropharyngeal squamous cell carcinoma. Part 1: human papillomavirus-mediated carcinogenesis. *Head & Face Medicine*. 6, p.14.

Galloway, T., Amdur, R.J. (2012). Management of late complications of head and neck cancer and its treatment. In: Posner, M.R., Brizel, D.M., Brockstein, B.E., Deschler, D.G. and Ganz, P.A., ed, *UpToDate*. Waltham, Massachusetts: *Retrieved February, 2022.*

Garden, A.S., Fuller, C.D., Rosenthal, D.I., William Jr, W.N., Gunn, G.B., Beadle, B.M., Johnson, F.M., Morrison, W.H., Phan, J., Frank, S.J., Kies, M.S., Sturgis, E.M. (2016). Radiation therapy (with or without neck surgery) for phenotypic human papillomavirus-associated oropharyngeal cancer. *Cancer*. 122 (11), p. 1702-1707.

Geißler, C., Tahtali, A., Diensthuber, M., Gassner, D., Stöver, T., Wagenblast, J. (2013). The role of p16 expression as a predictive marker in HPV-positive oral SCCHN--a retrospective single-center study. *Anticancer Research*. 33 (3), p. 913-916.

Gillison, M.L. (2004). Human papillomavirus-associated head and neck cancer is a distinct epidemiologic, clinical, and molecular entity. *Seminars in Oncology*. 31 (6), p 744-754.

Gillison, M.L., Koch, W.M., Capone, R.B., Spafford, M., Westra, W.H., Wu, L., Zahurak, M.L., Daniel, R.W., Viglione, M., Symer, D.E., Shah, K.V., Sidransky, D. (2000). Evidence for a causal association between human papillomavirus and a subset of head and neck cancers. *Journal of the National Cancer Institute*. 92 (9), p. 709-720.

Gougousis, S., Mouchtaropoulou, E., Besli, I., Vrochidis, P., Skoumpas, I., Constantinidis, I. (2021). HPV-related oropharyngeal cancer and biomarkers based on epigenetics and microbiome profile. *Frontiers in Cell and Developmental Biology*. 8:625330.

Gupta, S., Gupta, S. (2015). Role of human papillomavirus in oral squamous cell carcinoma and oral potentially malignant disorders: a review of the literature. *Indian Journal of Dentistry*. 6 (2), p. 91-98.

Hall, S.F., Liu, F-F., O'Sullivan, B., Shi, W., Rohland, S., Griffiths, R., Groome, P. (2017). Did the addition of concurrent chemotherapy to conventional radiotherapy improve survival for patients with HPV+ve and HPV-ve oropharynx cancer? A population-based study. *British Journal of Cancer*. 117 (8), p. 1105-1112.

Jalaly, J.B., Hosseini, S.M., Shafique, K., Baloch, Z.W. (2020). Current status of p16 immunohistochemistry and HPV testing in fine needle aspiration specimens of the head and neck. *Acta Cytologica*. 64 (1-2), p. 30-39.

Jalouli, J., Ibrahim, S.O., Mehrotra, R., Jalouli, M.M., Sapkota, D., Larsson, P-A., Hirsch, J-M. (2010). Prevalence of viral (HPV, EBV, HSV) infections in oral submucous fibrosis and oral cancer from India. *Acta Oto-laryngologica*. 130 (11), p.1306-1311.

Jethwa, A.R., Khariwala, S.S. (2017). Tobacco-related carcinogenesis in head and neck cancer. *Cancer and Metastasis Reviews*. 36 (3), p. 411-423.

Kato, M.G., Baek, C-H., Chaturvedi, P., Gallagher, R., Kowalski, L.P., Leemans, C.R., Warnakulasuriya, S., Nguyen, S.A., Day, T.A. (2020). Update on oral and oropharyngeal cancer staging – international perspectives. *World Journal of Otorhinolaryngology - Head & Neck Surgery*. 6 (1), p. 66-75.

Kelly, J.R., Husain, Z.A., Burtness, B. (2016). Treatment de-intensification strategies for head and neck cancer. *European Journal of Cancer*. 68, p. 125-133.

Keung, E.S., Souers, R.J., Bridge, J.A., Faquin, W.C., Graham, R.P., Hameed, M.R., Lewis Jr, J.S., Merker, J.D., Vasalos, P., Moncur, J.T. (2020). Comparative performance of high-risk human papillomavirus RNA and DNA in situ hybridization on College of American Pathologists proficiency tests. *Archives of Pathology & Laboratory Medicine*. 144 (3), p. 344-349.

Kim, K.Y., Lewis Jr, J.S., Chen, Z. (2018). Current status of clinical testing for human papillomavirus in oropharyngeal squamous cell carcinoma. *Journal of Pathology: Clinical Research*. 4 (4), p. 213-226.

Klussmann, J.P., Gültekin, E., Weissenborn, S.J., Wieland, U., Dries, V., Dienes, H.P., Eckel, H.E., Pfister, H.J., Fuchs, P.G. (2003). Expression of p16 protein identifies a distinct entity of tonsillar carcinomas associated with human papillomavirus. *American Journal of Pathology*. 162 (3), p. 747-753.

Laskar, S.G., Swain, M. (2015). HPV positive oropharyngeal cancer and treatment deintensification: how pertinent is it? *Journal of Cancer Research and Therapeutics*. 11 (11), p. 6-9.

Lechner, M., Liu, J., Masterson, L., Fenton, T.R. (2022). HPV-associated oropharyngeal cancer: epidemiology, molecular biology and clinical management. *Nature Reviews Clinical Oncology*. 19 (5), p.306-327.

Lewis Jr, J.S. (2020). Human papillomavirus testing in head and neck squamous cell carcinoma in 2020: where are we now and where are we going? *Head and Neck Pathology*. 14 (2), p. 321-329.

Lewis Jr, J.S. (2017). Morphologic diversity in human papillomavirus-related oropharyngeal squamous cell carcinoma: catch me if you can! *Modern Pathology*. 30 (s1), p.S44-S53.

Lewis Jr, J.S. (2012). p16 immunohistochemistry as a standalone test for risk stratification in oropharyngeal squamous cell carcinoma. *Head and Neck Pathology*. 6 Suppl 1 (Suppl 1), p. S75-S82.

Lewis Jr, J.S., Thorstad, W.L., Chernock, R.D., Haughey, B.H., Yip, J.H., Zhang, Q., El-Mofty, S.K. (2010). p16 positive oropharyngeal squamous cell carcinoma:an entity with a favorable prognosis regardless of tumor HPV status. American Journal of Surgical Pathology. 34 (8), p. 1088-1096.

Lewis Jr, J.S., Beadle, B., Bishop, J.A., Chernock, R.D., Colasacco, C., Lacchetti, C., Moncur, J.T., Rocco, J.W., Schwartz, M.R., Seethala, R.R., Thomas, N.E., Westra, W.H., Faquin, W.C. (2018). Human papillomavirus testing in head and neck carcinomas: guideline from the College of American Pathologists. *Archives of Pathology & Laboratory Medicine*. 142 (5), p. 559-597.

Liu, J., Zhang, M., Rose, B., Veillard, A-S., Jones, D., Zhang, X., Soon Lee, C., Milross, C., Hong, A. (2015). Ki67 expression has prognostic significance in relation to human papillomavirus status in oropharyngeal squamous cell carcinoma. *Annals of Surgical Oncology*. 22 (6), p 1893-1900.

Lydiatt, W.M., Patel, S.G., O'Sullivan, B., Brandwein, M.S., Ridge, J.A., Migliacci, J.C., Loomis, A.M., Shah, J.P. (2017). Head and neck cancers-major changes in the American Joint Committee on cancer eighth edition cancer staging manual. *CA: A Cancer Journal for Clinicians*. 67 (2), p. 122-137.

Machczyński, P., Majchrzak, E., Niewinski, P., Marchlewska, J., Golusiński, W. (2020). A review of the 8th edition of the AJCC staging system for oropharyngeal cancer according to HPV status. *European Archives of Oto-Rhino-Laryngology*. 277 (9), p.2407-2412.

Marklund, L., Hammarstedt, L. (2011). Impact of HPV in oropharyngeal cancer. *Journal of Oncology*. 2011:509036.

Marklund, L., Näsman, A., Ramqvist, T., Dalianis, T., Munck-Wikland, E., Hammarstedt, L. (2012). Prevalence of human papillomavirus and survival in oropharyngeal cancer other than tonsil or base of tongue cancer. *Cancer Medicine*. 1 (1), p. 82-88.

Maroun, C.A., Al Feghali, K., Traboulsi, H., Dabbous, H., Abbas, F., Dunya, G., Ziade, G., Mahfouz, R., Youssef, B., Tamim, H., Geara, F., Khalifeh, I., Moukarbel, R. V. (2020). HPV-related oropharyngeal cancer prevalence in a middle eastern population using E6/E7 PCR. *Infectious Agents and Cancer*. 15, p. 1.

Meng, H-X., Miao, S-S., Chen, K., Li, H-N., Yao, G., Geng, J., Wang, H., Shi, Q-T., He, J., Mao, X., Tong, F-J., Wei, L-L., Sun, J., Tan, D., You, Q., Li, X., Geng, J-S. (2018). Association of p16 as prognostic factors for oropharyngeal cancer: evaluation of p16 in 1470 patients for a 16 year study in Northeast China. *Biomed Research International*. 2018.

Mirghani, H., Amen, F., Blanchard, P., Moreau, F., Guigay, J., Hartl, D.M., Lacau St Guily, J. (2015). Treatment de-escalation in HPV-positive oropharyngeal carcinoma: ongoing trials, critical issues and perspectives. *International Journal of Cancer*. 136 (7), p.1494-1503.

Münger, K., Baldwin, A., Edwards, K.M., Hayakawa, H., Nguyen, C.L., Owens, M., Grace, M., Huh, K. (2004). Mechanisms of human papillomavirus-induced oncogenesis. *Journal of Virology*. 78 (21), p.11451-11460.

Ndiaye, C., Alemany, L., Diop, Y., Ndiaye, N., Diémé, M-J., Tous, S., Klaustermeier, J.E., Alejo, M., Castellsagué, X., Bosch, F.X., Trottier, H., de Sanjosé, S. (2013). The role of human papillomavirus in head and neck cancer in Senegal. *Infectious Agents and Cancer*. 8 (1), p. 14.

Ndiaye, C., Mena, M., Alemany, L., Arbyn, M., Castellsagué, X., Laporte, L., Bosch, F.X., de Sanjosé, S., Trottier, H. (2014). HPV DNA, E6/E7 mRNA, and p16INK4a detection in head and neck cancers: a systematic review and meta-analysis. *The Lancet Oncology*. 15 (12), p.1319-1331.

Nichols, A.C., Dhaliwal, S.S., Palma, D.A., Basmaji, J., Chapeskie, C., Dowthwaite, S., Franklin, J.H., Fung, K., Kwan, K., Wehrli, B., Howlett, C., Siddiqui, I., Salvadori, M.I., Winquist, E., Ernst, S., Kuruvilla, S., Read, N., Venkatesan, V., Todorovic, B., Hammond, J.A., Koropatnick, J., Mymryk, J.S., Yoo, J., Barrett, J.W. (2013). Does HPV type affect outcome in oropharyngeal cancer? *Journal of Otolaryngology - Head & Neck Surgery*. 42 (1), p. 9.

Oguejiofor, K.K., Hall, J.S., Mani, N., Douglas, C., Slevin, N.J., Homer, J., Hall, G., West, C.M.L. (2013). The prognostic significance of the biomarker p16 in oropharyngeal squamous cell carcinoma. *Clinical Oncology (The Royal College of Radiologists)*. 25 (11), p. 630-638.

Panwar, A., Interval, E., Lydiatt, W.M. (2017). Emergence of a novel staging system for oropharyngeal squamous cell carcinoma based on HPV status. *Oncology (Williston Park)*. 31 (12), e. 33-40.

Paquette, C., Evans M.F., Meer S.S., Rajendran, V., Adamson C. S-C., Cooper, K. (2013). Evidence that alpha-9 human papillomavirus infections are a major etiologic factor for oropharyngeal carcinoma in black South Africans. *Head and Neck Pathology*. 7 (4), p.361-372.

Powell, N.G., Evans, M. (2015). Human papillomavirus-associated head and neck cancer: oncogenic mechanisms, epidemiology and clinical behaviour. *Diagnostic Histopathology*. 21 (2), p. 49-64.

Ramqvist, T., Grün, N., Dalianis, T. (2015). Human papillomavirus and tonsillar and base of tongue cancer. *Viruses*. 7 (3), p. 1332-1343.

Rautava, J., Syrjänen, S. (2012). Biology of human papillomavirus infections in head and neck carcinogenesis. *Head and Neck Pathology*. 6 Suppl 1 (Suppl 1), p. S3-S15.

Rettig, E.M., Gooi, Z., Bardin, R., Bogale, M., Rooper, L., Acha, E., Koch, W.M. (2019). Oral human papillomavirus infection and head and neck squamous cell carcinoma in rural Northwest Cameroon. *OTO Open*. 3.

Schache, A.G., Liloglou, T., Risk, J.M., Jones, T.M., Ma, X-J., Wang, H., Bui, S., Luo, Y., Sloan, P., Shaw, R.J., Robinson, M. (2013). Validation of a novel diagnostic standard in HPV-positive oropharyngeal squamous cell carcinoma. *British Journal of Cancer*. 108 (6), p. 1332-1339.

Selcuk, O.T. (2016). Human papillomavirus positive oropharyngeal cancer: the general information. *Egyptian Journal of Ear, Nose, Throat and Allied Sciences*. 17 (3), p. 127-132.

Shinn, J.R., Davis, S.J., Lang-Kuhs, K.A., Rohde, S., Wang, X., Liu, P., Dupont, W.D., Plummer Jr, D., Thorstad, W.L., Chernock, R.D., Mehrad, M., Lewis Jr, J.S. (2021). Oropharyngeal squamous cell carcinoma with discordant p16 and HPV mRNA results: incidence and characterization in a large, contemporary United States cohort. *American Journal of Surgical Pathology*. 45 (7), p. 951-961.

Snijders, P.J., F., Cromme, F. V., van den Brule, A.J., C.D., Schrijnemakers, H.F., Snow, G.B., Meijer, C.J., Walboomers, J.M. (1992). Prevalence and expression of human papillomavirus in tonsillar carcinomas, indicating a possible viral etiology. *International Journal of Cancer*. 51 (6), p. 845-850.

Sritippho, T., Pongsiriwet, S., Lertprasertsuke, N., Buddhachat, K., Sastraruji, T., Iamaroon, A. (2016). p16 - a possible surrogate marker for high-risk human papillomaviruses in oral cancer? *Asian Pacific Journal of Cancer Prevention*. 17 (8), p. 4049-4057.

Taberna, M., Mena, M., Pavón, M.A., Alemany, L., Gillison, M.L., Mesía, R. (2017). Human papillomavirus-related oropharyngeal cancer. *Annals of Oncology*. 28 (10), p. 2386-2398.

Tribius, S., Würdemann, N., Laban, S., Hoffmann, T.K., Sharma, S.J., Klussmann, J.P. (2019). [Update on HPV-associated head and neck cancer-highlights from the 2019 ASCO Annual Meeting] [article in German]. Abstract. *HNO*. 67 (12), p. 912-917.

Vokes, E.E., Agrawal, N., Seiwert, T.Y. (2015). HPV-associated head and neck cancer. *Journal of the National Cancer Institute*. 107 (12), p. djv344.

Wang, M.B., Liu, I.Y., Gornbein, J.A., Nguyen, C.T. (2015). HPV-positive oropharyngeal carcinoma: a systematic review of treatment and prognosis. *Otolaryngology-Head and Neck Surgery*. 153 (5), p. 758-769.

Weinberger, P.M., Yu, Z., Haffty, B.G., Kowalski, D., Harigopal, M., Brandsma, J., Sasaki, C., Joe, J., Camp, R.L., Rimm, D.L., Psyrri, A. (2006). Molecular classification identifies a subset of human papillomavirus--associated oropharyngeal cancers with favorable prognosis*. Journal of Clinical Oncology*. 24 (5), p. 736-747.

Wendt, M., Hammarstedt-Nordenvall, L., Zupancic, M., Friesland, S., Landin, D., Munck-Wikland, E., Dalianis, T., Näsman, A., Marklund, L. (2021). Long-term survival and recurrence in oropharyngeal squamous cell carcinoma in relation to subsites, HPV, and p16-status. *Cancers (Basel)*. 13 (11):2553.

Westra, W.H. (2012). The morphologic profile of HPV-related head and neck squamous carcinoma: implications for diagnosis, prognosis, and clinical management. *Head and Neck Pathology*. 6 Suppl 1 (Suppl 1), p. S48-S54.

Westra, W.H., Lewis Jr, J.S. (2017). Update from the 4th Edition of the World Health Organization classification of head and neck tumours: oropharynx. *Head and Neck Pathology*. 11 (1), p. 41-47.

Wittekindt, C., Wagner, S., Bushnak, A., Prigge, E-S., von Knebel Doeberitz, M., Würdemann, N., Bernhardt, K., Pons-Kühnemann, J., Maulbecker-Armstrong, C., Klussmann, J.P. (2019). Increasing incidence rates of oropharyngeal squamous cell carcinoma in Germany and significance of disease burden attributed to human papillomavirus. *Cancer Prevention Research*. 12 (6), p. 375-382.

Wood, N.H., Makua, K.S., Lebelo, R.L., Redzic, N., Benoy, I., Vanderveken, O.M., Bogers J. (2020). Human papillomavirus prevalence in oral and oropharyngeal rinse and gargle specimens of dental patients and of an HIV-positive cohort from Pretoria, South Africa. *Advances in Virology*. 2020:2395219.

Woods Sr, R.S., O'Regan, E.M., Kennedy, S., Martin, C., O'Leary, J.J., Timon, C. (2014). Role of human papillomavirus in oropharyngeal squamous cell carcinoma: a review. *World Journal of Clinical Cases*. 2 (6), p. 172-193.

You, E.L., Henry, M., Zeitouni, A.G. (2019). Human papillomavirus-associated oropharyngeal cancer: review of current evidence and management. *Current Oncology*. 26 (2), p. 119-123.

CHAPTER 9 - APPENDICES

9.1 Appendix A: Raw Data

9.1.1 Controls

HPV-16	*HPV-6*	*p16*	*p53*	*Ki67*	*Age*	*Gender*	*Site*	*Smoking*	*Alcohol consumption*	*Tumour type*
negative	negative	negative	positive	30	46	male	tonsil	not stated	not stated	mdkscc
negative	negative	positive >70%	positive	15	63	male	tonsil	not stated	not stated	mdkscc
negative	negative	negative	positive	10	53	male	posterior FOM	yes	yes	mdkscc
positive	negative	positive >70%	positive	10	87	male	BOT	not stated	not stated	mdkscc
positive	negative	positive >70%	positive	missing	61	male	posterior tongue	not stated	not stated	mdkscc
negative	negative	negative	positive	10	62	male	tonsil	not stated	not stated	mdkscc
positive	negative	negative	positive	10	62	male	posterior tongue	not stated	not stated	mdkscc
positive	negative	negative	negative	40	70	male	posterior FOM	yes	not stated	mdkscc
negative	negative	negative	positive	20	70	male	posterior FOM	not stated	not stated	mdkscc
negative	negative	negative	negative	10	52	male	posterior FOM	not stated	not stated	mdkscc
negative	negative	negative	positive	15	65	male	tonsil	not stated	not stated	mdkscc
positive	negative	negative	negative	5	44	male	tonsil	not stated	not stated	mdkscc
negative	negative	negative	positive	15	67	male	tonsil	yes	not stated	mdkscc
positive	negative	negative	negative	5	44	male	tonsil	not stated	not stated	mdkscc
negative	negative	negative	negative	10	70	male	tonsil	not stated	not stated	mdkscc
negative	negative	negative	positive	10	not stated	male	tonsil	not stated	not stated	mdkscc
negative	negative	negative	negative	10	61	male	tonsil	not stated	not stated	mdkscc
negative	negative	negative	negative	15	60	female	tonsil	not stated	not stated	mdkscc
negative	negative	negative	positive	10	61	male	tonsil	not stated	not stated	mdkscc
negative	negative	negative	positive	20	62	male	posterior FOM	not stated	not stated	mdkscc
negative	negative	negative	positive	10	47	male	posterior tongue	not stated	not stated	mdkscc
negative	negative	negative	negative	20	47	female	posterior tongue	not stated	not stated	mdkscc
negative	negative	negative	negative	30	51	male	posterior tongue	not stated	not stated	mdkscc
negative	negative	positive >70%	negative	60	53	male	posterior tongue	yes	not stated	mdkscc
negative	negative	negative	positive	50	68	male	posterior tongue	yes	yes	mdkscc
positive	negative	positive >70%	positive	50	60	male	posterior tongue	not stated	not stated	mdkscc
negative	negative	negative	negative	10	58	female	posterior FOM	not stated	not stated	mdkscc
negative	negative	negative	negative	10	67	not stated	posterior tongue	not stated	not stated	mdkscc
negative	negative	negative	negative	20	55	female	posterior tongue	not stated	not stated	mdkscc
negative	negative	negative	negative	15	55	female	posterior tongue	not stated	not stated	mdkscc

9.1.2 Cases

HPV-16	*HPV-6*	*p16*	*p53*	*Ki67*	*Age*	*Gender*	*Site*	*Smoking*	*Alcohol consumption*	*Tumour type*
positive	negative	negative	negative	10	60	female	oropharynx	not stated	not stated	nkscc with basaloid morphology
negative	negative	positive >70%	negative	40	77	not stated	not stated	not stated	not stated	nkscc with basaloid morphology
positive	negative	negative	negative	40	68	female	retromolar region	not stated	not stated	nkscc with basaloid morphology
negative	negative	negative	positive	missing	66	male	BOT	not stated	not stated	nkscc with basaloid morphology
positive	negative	positive >70%	positive	50	65	male	tonsil	not stated	not stated	nkscc with basaloid morphology
positive	positive	negative	positive	30	61	female	BOT	not stated	not stated	nkscc with basaloid morphology
positive	negative	positive >70%	positive	10	52	female	tonsil	not stated	not stated	nkscc with basaloid morphology
negative	negative	negative	negative	40	52	male	posterior tongue	yes	yes	nkscc with basaloid morphology
positive	negative	positive >70%	missing	40	63	male	BOT	not stated	not stated	nkscc with basaloid morphology
negative	negative	missing	positive	60	46	male	tonsil	not stated	not stated	nkscc with basaloid morphology
negative	negative	positive >70%	negative	40	59	male	tonsil	not stated	not stated	nkscc with basaloid morphology
positive	positive	negative	negative	10	65	male	posterior FOM	not stated	not stated	nkscc with basaloid morphology
negative	positive	negative	negative	60	60	male	retromolar region	not stated	not stated	nkscc with basaloid morphology
negative	positive	negative	positive	30	55	male	posterior FOM	not stated	not stated	nkscc with basaloid morphology
negative	negative	positive >70%	positive	30	40	male	oropharynx	not stated	not stated	nkscc with basaloid morphology
negative	negative	negative	negative	40	58	male	retromolar region	yes	not stated	nkscc with basaloid morphology
negative	positive	positive >70%	positive	30	71	male	oropharynx	not stated	not stated	nkscc with basaloid morphology
positive	negative	positive >70%	positive	20	62	male	BOT	previous smoker	not stated	nkscc with basaloid morphology
negative	negative	positive >70%	negative	50	41	female	tonsil	not stated	not stated	nkscc with basaloid morphology
negative	positive	negative	positive	20	45	male	BOT	not stated	not stated	nkscc with basaloid morphology
negative	negative	missing	missing	missing	54	male	BOT	not stated	not stated	nkscc with basaloid morphology
negative	negative	positive >70%	positive	20	54	female	tonsil	not stated	not stated	nkscc with basaloid morphology
positive	negative	positive >70%	negative	40	72	male	tonsil	previous smoker	not stated	nkscc with basaloid morphology
negative	negative	negative	negative	10	77	male	posterior tongue	yes	yes	nkscc with basaloid morphology
positive	negative	positive >70%	positive	60	72	male	posterior tongue	not stated	not stated	nkscc with basaloid morphology
negative	positive	positive >70%	positive	50	49	male	BOT	not stated	not stated	nkscc with basaloid morphology
negative	positive	positive >70%	positive	70	34	male	tonsil	not stated	not stated	nkscc with basaloid morphology
negative	negative	positive >70%	negative	50	60	male	tonsil	not stated	not stated	nkscc with basaloid morphology
negative	negative	positive >70%	positive	80	58	male	tonsil	not stated	not stated	nkscc with basaloid morphology
positive	negative	positive >70%	missing	missing	74	female	tonsil	not stated	not stated	nkscc with basaloid morphology

9.2 Appendix B: Ethics Clearance Certificate

UNIVERSITY OF THE WITWATERSRAND, JOHANNESBURG

R14/49 Dr Dineo Disenyane

HUMAN RESEARCH ETHICS COMMITTEE (MEDICAL)

CLEARANCE CERTIFICATE NO. M210490

NAME: (Principal Investigator)	Dr Dineo Disenyane
DEPARTMENT:	Anatomical Pathology Division of Oral Pathology
PROJECT TITLE:	The role of human papilloma virus (HPV) in oropharyngeal squamous cell carcinoma: a clinicopathologic and molecular analysis
DATE CONSIDERED:	Ad Hoc
DECISION:	Approved unconditionally
CONDITIONS:	Renewal of M120531under Dr Dineo Disenyane
SUPERVISOR:	Prof Shabnum Meer
APPROVED BY:	Dr C Penny, Chairperson, HREC (Medical)
DATE OF APPROVAL:	12/05/2021

This clearance certificate is valid for 5 years from date of approval. Extension may be applied for.

DECLARATION OF INVESTIGATORS

To be completed in duplicate and **ONE COPY** returned to the Research Office Secretary in Room 301, Third floor, Faculty of Health Sciences, Phillip Tobias Building, 29 Princess of Wales Terrace, Parktown, 2193, University of the Witwatersrand. I/we fully understand the conditions under which I am/we are authorized to carry out the above-mentioned research and I/we undertake to ensure compliance with these conditions. Should any departure be contemplated, from the research protocol as approved, I/we undertake to resubmit the application to the Committee. **I agree to submit a yearly progress report**. The date for annual re-certification will be one year after the date of convened meeting where the study was initially reviewed. In this case, the study was initially reviewed April and will therefore be due in the month of April each year. Unreported changes to the application may invalidate the clearance given by the HREC (Medical).

Principal Investigator Signature

13/05/2021
Date

PLEASE QUOTE THE PROTOCOL NUMBER IN ALL ENQUIRIES