

https://dspace.org/

Management of ventricular tachycardia in patients with cardiac sarcoidosis

Viwe Mtwesi; Nery Pablo; Birnie David

https://hdl.handle.net/10539/35333
WOS

Downloaded from a DSpace repository. https://dspace.org/

TOPICS IN REVIEW

Management of ventricular tachycardia in patients with cardiac sarcoidosis

Mtwesi Viwe, MD, MB ChB, MMED,*† Pablo Nery, MD,‡ David H. Birnie, MD, MB, ChB‡

*From the *Division of Cardiology, Department of Medicine, McMaster University, Hamilton, Canada, †Division of Cardiology, Department of Internal Medicine, School of Clinical Medicine, Faculty of Health Sciences, University of the Witwatersrand, Johannesburg, South Africa, and ‡Arrhythmia Service, Division of Cardiology, Department of Medicine, University of Ottawa Heart Institute, Ottawa, Canada.*

Sarcoidosis is a multisystem granulomatous disease with 2 different phases (inflammation and scar). In the current era of targeted use of implantable cardioverter-defibrillators and modern heart failure therapy, recent data indicate the prognosis of cardiac sarcoidosis (CS) is much improved, and hence more patients are presenting with recurrent ventricular tachycardia (VT). This review highlights our current understanding of the pathophysiology and management of ventricular arrhythmias in CS with the major focus on indications, techniques, and outcomes of ablation.

It is likely macroreentry phenomena around areas of fibrosis is the most frequent mechanism of ventricular arrhythmia in CS. It is also possible that inflammation may play a role in initiating reentry with ventricular ectopy in CS patients, or by slowing conduction in diseased tissue. The best available data would suggest annual rates of VT of perhaps 1%–2% and 10%–15% in patients with initially clinically silent and clinically manifest disease, respectively. Current guidelines recommend a stepwise approach to VT management. The first suggested step is treatment with immunosuppression if there is evidence of active inflammation. Antiarrhythmic medications are often started at the same time, with catheter ablation considered if VT cannot be controlled. Activation and entrainment mapping and ablation are favored in the setting of hemodynamically tolerated VT. Substrate ablation targets areas of abnormal electrogram and favorable pace mapping using linear and/or cluster lesion sets with the goal of abolishing critical isthmuses and/or blocking VT exit sites. Epicardial mapping ablation is required in 20%–35% of cases. In general, more morphologies of VT are induced (often 3–4) and subsequent outcomes (recurrence rates 40%–50%) are less favorable than in other forms of nonischemic cardiomyopathy.

The prognosis of CS is much improved and, as a result, more patients are developing VT during follow-up. Likely principally related to the complex disease substrate, VT ablation is technically challenging, with moderate outcomes, and much remains to be learned.

KEYWORDS Cardiac sarcoidosis; Immunosuppressive therapy; Radiofrequency ablation; Steroids; Ventricular arrhythmias; Ventricular tachycardia

(Heart Rhythm O2 2021;2:412–422) © 2021 Heart Rhythm Society. Published by Elsevier Inc. This is an open access article under the CC BY-NC-ND license (http://creativecommons.org/licenses/by-nc-nd/4.0/).

Introduction

Approximately 5% of patients with sarcoidosis have clinically manifest cardiac involvement. In these patients the cardiac symptoms are usually dominant over extracardiac, as most patients with clinically manifest cardiac sarcoidosis (CS) have modest extracardiac disease.[1–5] Certainly, this seems consistent in the phenotype of primarily white patients of Northern European descent we and others have described.[1,5,6] Clinical features of CS are dependent on the location, extent, and activity of the disease. The principal manifestations are conduction abnormalities, ventricular arrhythmias including sudden death, and heart failure. Another 20%–25% of patients have asymptomatic (ie, *clinically silent*) cardiac involvement. This latter finding was established initially from autopsy studies that estimated the prevalence of cardiac involvement.[7] These data are aligned with more recent data using late gadolinium-enhanced cardiac magnetic resonance (LGE-CMR) technology.[8] Studies suggest an increasing prevalence of CS; however, this is most likely the result of enhanced imaging technology and/or more in-depth investigation. For example, in the United States the incidence of patients with CS as the etiology of cardiomyopathy who underwent transplantation rose to 0.5% (between 2010 and 2014) from 0.1% (between 1994 and 1997).[9] Similarly, in Finland, CS was diagnosed at a rate that increased more than 50-fold between 1988 and 2014.[5] In addition, there is increasing evidence that CS can be the first manifestation of sarcoidosis in any organ.[2,3,10,11]

The first international expert consensus statement for CS diagnosis and arrhythmia management was published in

Address reprint requests and correspondence: Dr David H. Birnie, Professor, University of Ottawa, 40 Ruskin St, Ottawa, ON, Canada, K1Y 4 W7. E-mail address: dbirnie@ottawaheart.ca.

2666-5018/© 2021 Heart Rhythm Society. Published by Elsevier Inc. This is an open access article under the CC BY-NC-ND license (http://creativecommons.org/licenses/by-nc-nd/4.0/).

https://doi.org/10.1016/j.hroo.2021.07.005

KEY FINDINGS

- Sarcoidosis is a multisystem granulomatous disease with 2 different phases (inflammation and scar).
- In the current era of targeted use of implantable cardioverter-defibrillators and modern heart failure therapy, recent data indicate the prognosis of cardiac sarcoidosis is much improved and hence more patients are presenting with recurrent ventricular tachycardia (VT).
- Macroreentry phenomena around areas of fibrosis is the most frequent mechanism of ventricular arrhythmia in cardiac sarcoidosis.
- Current guidelines recommend a stepwise approach to VT management.
- Likely principally related to the complex disease substrate, VT ablation is technically challenging, with moderate outcomes, and much remains to be learned.

2014 by experts chosen by the Heart Rhythm Society (HRS) in collaboration with as multiple other societies.[12] Until this statement was released, the only published diagnostic guidelines were the World Association of Sarcoidosis and Other Granulomatous Disorders Sarcoidosis Organ (WASOG) Assessment Instrument created in 1999 and updated in 2014[13] and the Japanese Ministry of Health and Welfare criteria.[14] The HRS document was closely aligned with the WASOG document.[12,13] The Japanese Circulation Society published new guidelines for the diagnosis of CS in 2019.[15]

Generally, the prognosis for CS patients is less favorable than for those without cardiac involvement. In the current era of earlier diagnosis, targeted use of implantable cardioverter-defibrillators (ICDs), and modern heart failure therapy, including cardiac transplantation, the prognosis is much improved. In a recent Finnish nationwide study, 10-year cardiac survival was 92.5% in 102 patients with manifest CS.[5] Other recent studies have also shown a much improved prognosis in the current era.[16,17] Very importantly, it follows that with survival improving we are seeing more patients with recurrent ventricular tachycardia (VT). This review highlights our current understanding of pathophysiology and management of ventricular arrhythmias in CS with the major focus on indications, techniques, and outcomes of ablation.

Pathophysiology and mechanism of ventricular arrhythmias in CS

Sarcoidosis is a poorly understood disease thought to be initiated by heterogeneous triggers in susceptible host.[18] The disease has 2 main histological stages, namely: active inflammation/granulomatous infiltration and fibrosis (Figures 1 and 2). This disease's progression and, most importantly, the extent of fibrosis is highly variable between patients. The disease affects the endocardium, myocardium, and pericardium. In the myocardium location of the granulomas in decreasing order of frequency is the left ventricular free wall, septum, right ventricle, and atria. It is likely that macroreentry phenomena around areas of fibrosis is the most frequent mechanism of ventricular arrhythmia in CS.[19,20] It is also possible that inflammation may play a role in initiating reentry with ventricular ectopy in CS patients, or by slowing conduction in diseased tissue.[21]

Incidence and time course of ventricular arrhythmias in CS

Ventricular arrhythmias, usually monomorphic VT, can be the first presentation of unrecognized CS. In a prospective study that screened consecutive patients with VT of unknown etiology for sarcoidosis, 4 of 14 patients (29%) were diagnosed with CS.[2] In a study by Tung[11] of 103 patients (85% white, 7% African American, and 8% Asian) with VT and nonischemic cardiomyopathy, 17 of 103 (16.5%) had undiagnosed CS. The reported incidence of VT in CS is highly variable, dependent on the cohort studied. In a large administrative data study of 2231 patients with systemic sarcoidosis

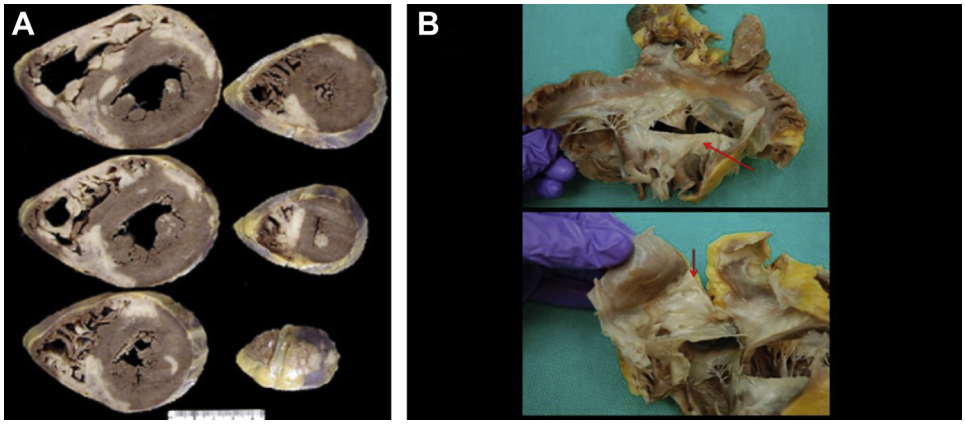

Figure 1 **A:** Different patterns of cardiac sarcoidosis scar involvement (image reproduced with permission from Tavora et al[70]). **B:** Top: Explanted heart. Note dense basal septal scar located on superior right ventricular (RV) septum, under tricuspid valve apparatus. Bottom: RV outflow tract. Note scar and transmural ablation line on anterior RV outflow tract (image courtesy of Dr J. Veinot, Univesity Of Ottawa).

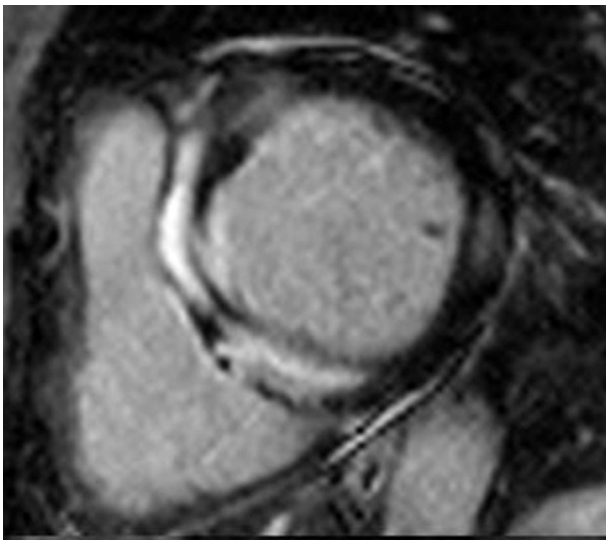

Figure 2 Cardiac magnetic resonance short-axis image showing extensive septal late gadolinium enhancement in a patient with cardiac sarcoidosis.

(not reported how many had CS), the annual rate of VT was about 0.08%.[22] In a meta-analysis of 7 studies involving 694 sarcoidosis patients in whom 199 had LGE on CMR (and mostly had clinically silent CS), the annual rate of VT was about 1.5%.[23] The highest rate of VT, as expected, occurs in patients with initially clinically manifest disease. For example, Kandolin and colleagues[24] followed 18 CS patients who presented with complete heart block and found 10 of 18 (56%) developed VT, with an annual rate of 14%. Similar data come from CS patients with ICDs (most patients had clinically manifest CS). In 3 large published series, annualized appropriate therapy rates for VT were 8.6%, 13.2%, and 14.5%, respectively.[25–27] There are limited data on the time course of VT development. Segawa and colleagues[28] followed 68 newly diagnosed clinically manifest CS patients over a mean period of 5.5 years and found 20 of 68 (29%) had VT, with 14 of 20 cases (70%) occurring in the first 12 months after diagnosis (Figure 3).[28]

Role of immunosuppression for management of ventricular arrhythmias in CS

Most experts have been proponents of treating CS despite the scarcity of data. It is not clear whether it is best to treat all CS patients, or only those with clinically manifest disease with evidence of ongoing myocardial inflammation. Our group has published 2 systematic reviews of corticosteroids for the treatment of CS (Table 1).[29,30] The data related to ventricular arrhythmia was too limited to conclude whether steroids and immunosuppressive therapy (IST) are helpful. There were 2 main issues with the data: (1) most patients were treated simultaneously with a combination of corticosteroids and/or IST and antiarrhythmic drugs, and sometimes ablation too; and (2) few studies examined outcomes related to the disease activity with gallium or 18-fluorodeoxyglucose positron emission tomography (FDG-PET) scanning. The HRS consensus document recommended a stepwise approach (Table 2). The first suggested step is treatment with immunosuppression if there is evidence of active inflammation on FDG-PET (Figure 4 shows FDG-PET images before and after therapy). Antiarrhythmic medications are often started at the same time, with catheter ablation considered if VT cannot be controlled.[12] Yalagudri and colleagues[31] examined this approach to ventricular arrhythmia management. Patients with VT in the scar phase responded well to antiarrhythmic

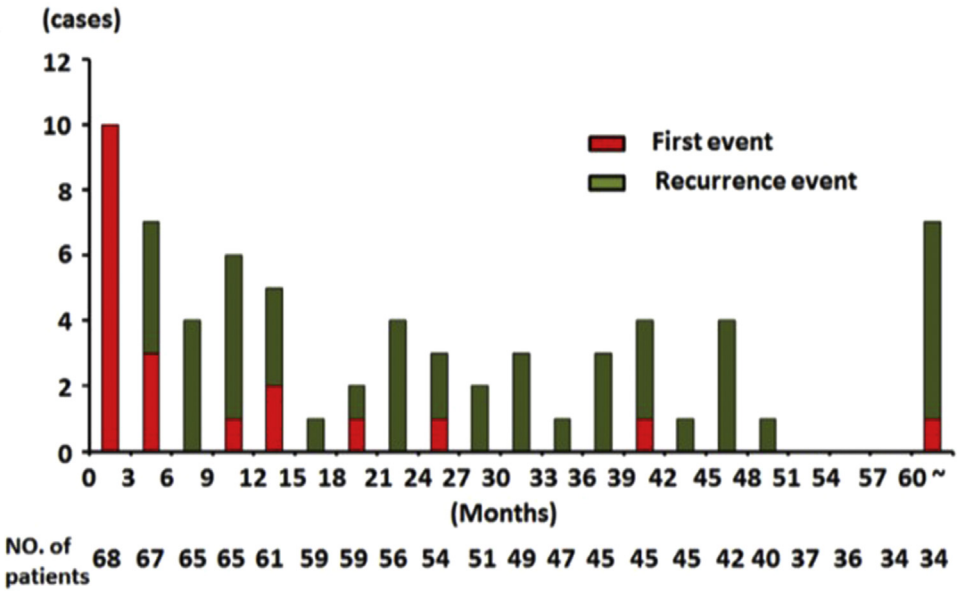

Figure 3 The time course of the number of patients with ventricular tachyarrhythmias (VT). First event: number of patients with the first VT event after the initiation of corticosteroid therapy. Recurrent event: number of patients with any VT recurrence event after the initiation of corticosteroid therapy (reproduced with permission from Segawa et al[28]).

Table 1 Studies evaluating the effect of immunosuppression on recurrence of ventricular arrhythmias in patients with cardiac sarcoidosis

	First author	Follow-up (months)	Endpoints	Number of patients treated corticosteroids and/or other IST[†]	Arrhythmia recurrence, n/N (%)	Number of patients not treated with immunosuppressants	Arrhythmia recurrence	Comments
A. Studies investigating effect of steroids and/or other IST on sustained VT/VF								
2006	Futamatsu[59]	48.8 ± 38.7	Sustained VT/VF	7	1/7 (14%)	0		5 of 6 patients with no recurrence were also started on amiodarone
2016	Segawa[28]	66	Sustained VT/VF	17	12/17 (71%)	0		Presteroid VT was an independent predictor: 7.64 (3.05–19.14) of poststeroid VT
2017	Padala[60]	19	Sustained VT/VF	11	3/11 (33%)	3	3/3	
2017	Yalagudri[31]	38	Sustained VT/VF	14	4/14 (36%)	4	0/4 (all treated with ablation)	
2018	Muser[61]	35 (20–66)	Sustained VT/VF	20	12 (60%)	0		All patients also had ablation; patients stratified to PET responders and nonresponders. Responders: 2/9 (22%) had VA recurrence' nonresponders: 10/11 (91%) had VA recurrence
TOTAL				69		7		
B. Studies investigating effect of steroids and/or other IST on PVC burden ± nonsustained VT								
2007	Banba[62]		PVC burden	9	No change in PVC burden before and after steroids	9		All patients had positive gallium scan before initiation of steroids
2011	Yodogawa[63]	7.3±5.9	NSVT or PVC burden	31	No change in PVC burden or NSVT prevalence	31		
2020	Medor[64]	13.1 ± 11	NSVT or PVC burden	20	See comments	20	See comment	Significant increase in both endpoints after corticosteroids (for NSVT $P = .017$, for PVC $P = .008$)
TOTAL				60		60		

IST = immunosuppressive therapy; NSVT = nonsustained ventricular tachycardia; PET = positron emission tomography; PVC = premature ventricular contraction; VA = ventricular arrhythmia; VF = ventricular fibrillation; VT = ventricular tachycardia.

[†]All studies used corticosteroid monotherapy for immunosuppression except (1) Yalagudri et al, where all 14 patients were treated with methotrexate and corticosteroids combination[31]; and (2) Muser et al, where 14 patients were treated with corticosteroid monotherapy and 6 patients received both corticosteroids and methotrexate.[61]

Table 2 Expert consensus recommendations for the management of ventricular arrhythmias.[12]

Class IIa	1. Assessment of myocardial inflammation with FDG-PET can be useful in CS patients with ventricular arrhythmias 2. Immunosuppression can be useful in CS patients with frequent ventricular ectopy or nonsustained VT and evidence of myocardial inflammation 3. Immunosuppression can be useful in CS patients with sustained ventricular arrhythmias and evidence of myocardial inflammation 4. Antiarrhythmic medication therapy can be useful in patients with ventricular arrhythmias refractory to immunosuppressive therapy 5. Catheter ablation can be useful in patients with CS and ventricular arrhythmias refractory to immunosuppressive and antiarrhythmic therapy 6. Catheter ablation can be useful in patients with incessant ventricular arrhythmias

CS = cardiac sarcoidosis; FDG-PET = 18-fluorodeoxyglucose positron emission tomography; VT = ventricular tachycardia.

drugs and ablation. Fourteen had positive FDG-PET scans and were treated with immunosuppression. Four patients in the inflammatory group had recurrence of VT during follow-up. Three were found to have disease reactivation. Intensified immunosuppression suppressed VT in all, and in 1 patient VT recurrence was found to be scar-related and was successfully treated with ablation.[31]

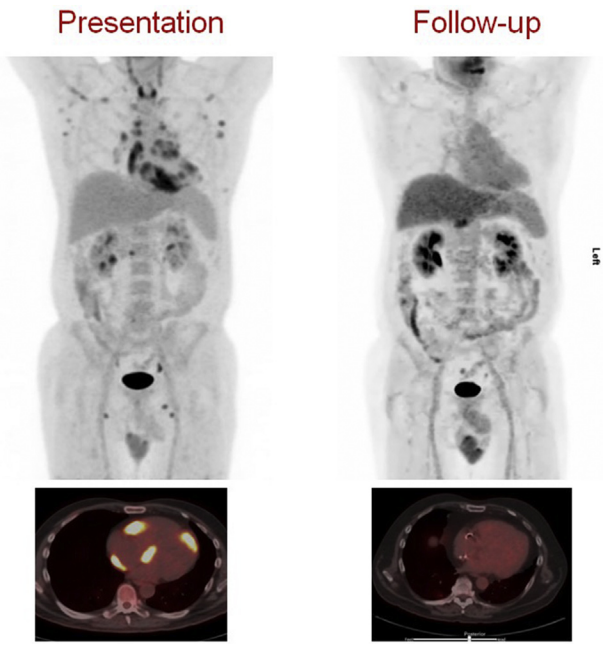

Figure 4 Whole-body 18-fluorodeoxyglucose positron emission tomography (FDG-PET) images (upper panels) and transaxial views of fused FDG-PET / computed tomography thorax images (lower panels). The left panels acquired before treatment demonstrates patchy FDG uptake in the left ventricle, right ventricle, and right atrium as well as lymph node FDG uptake. The right panels were acquired after 3 months of prednisolone 0.5 mg/kg and demonstrate absent cardiac and lymph node FDG uptake (images courtesy of Dr R. Beanlands, University of Ottawa Heart Institute).

Characterization of VT substrate in CS patients

While abnormal automaticity or triggered activity may lead to VT in the setting of active CS, scar-related reentry is most common in the chronic phase. VT involving the Purkinje system has been reported in patients with conduction system disease and an HV interval $\geq$55 ms.[32] The heterogeneous, patchy scar pattern in CS predisposes patients to multiple VT morphologies originating from the right ventricle (RV) or left ventricle (LV). Preprocedural imaging using CMR or PET scanning is useful to characterize the complex arrhythmogenic substrate. Advanced imaging can assist with preprocedural planning and identification of epicardial, septal, or intramural scar.

Kumar and colleagues[33] demonstrated widespread and confluent RV low-voltage areas (LVA) while the LV LVA was patchy, with a predilection for the basal septum, anterior wall, and perivalvular regions. RV LVA was common on the septum, RV outflow tract, peritricuspid region, inferior wall, and RV free wall. Muser and colleagues[34] also reported involvement of LV basal septum in 57% of patients, followed by anterior basal wall (33%); RV involvement was most common on the basal septum (56%), RV outflow tract (56%), peritricuspid region/free wall (33%), and inferior wall (20%). LVA are defined as in mapping of other nonischemic cardiomyopathy substrates (ie, bipolar signal amplitude $\leq$1.5 mV in the endocardium and $\leq$1.0 mV in the epicardium). Endocardial unipolar mapping using amplitude cut-off $\leq$8.3 mV in the LV and RV septum and $\leq$5.5 mV in the RV free wall can help identify subjects with epicardial substrate.[19,35] CMR data show subepicardial LV LGE in 43%, midmyocardial LGE in 52%, and subendocardial LGE in 22%.[34] A cohort study identified endocardial and/or epicardial abnormal (fractionated, late, or split) electrograms in all.[36] Of note, up to 40% of abnormal electrograms were detected outside areas of LVA when using standard voltage cut-off values. High-density bipolar mapping and unipolar voltage mapping may be used to assist with the identification of regions of endocardial abnormal electrograms[36] that are potential targets for catheter ablation.[37]

It should be noted that endocardial mapping can also be useful for guiding biopsies in cases with uncertain diagnosis. Lymph node or lung biopsy is usually targeted first in patients with sarcoidosis because of lower procedural risk and higher diagnostic yield. However, occasionally endomyocardial biopsy has to be considered to confirm the diagnosis. However, unguided endomyocardial biopsy has low sensitivity owing to the disease's focal nature. Imaging-guided (PET or CMR)[1] or electrophysiological-guided[38,39] biopsy procedures have been described, and are now recommended by consensus guidelines.[12] With these techniques positive biopsy rates have risen to 40%–50%.[4,39]

Catheter ablation for ventricular tachycardia in cardiac sarcoidosis

Catheter ablation in patients with CS follows principles of ablation employed in other forms of nonischemic cardiomyopathy. Characterization of VT substrate in patients with CS requires

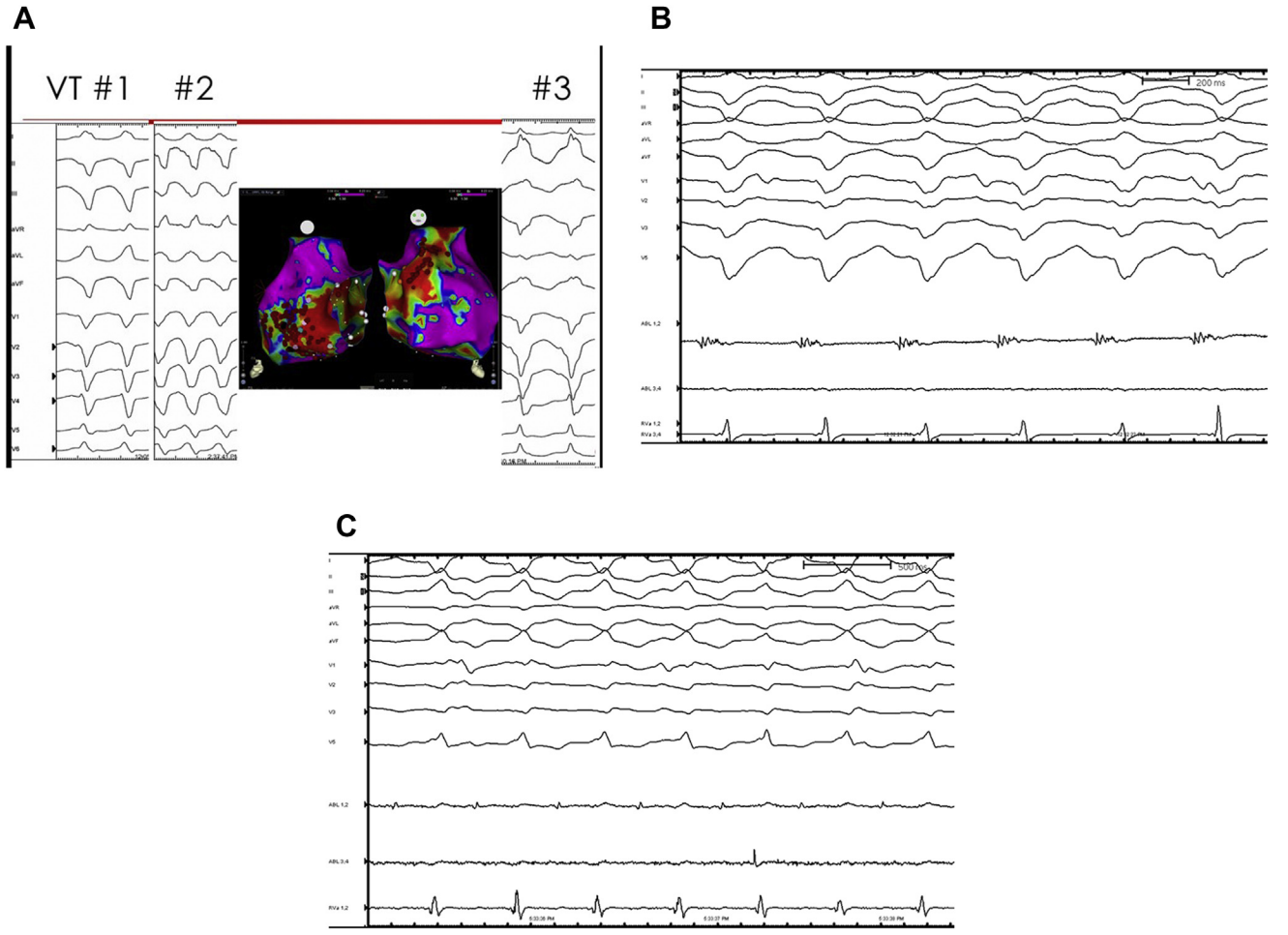

Figure 5 **A:** Case example of a 48-year-old female patient who presented with atrioventricular block and developed ventricular tachycardia (VT) 3 months later. She was treated with amiodarone initially but VT recurred, and follow-up fluorodeoxyglucose positron emission tomography scan showed complete disease suppression on prednisone and methotrexate. Three morphologies of VT were induced, all of which were hemodynamically unstable; hence an extensive substrate modification was performed, and she was not inducible thereafter. The figure shows the 3 VT morphologies. The inset shows the electroanatomical map of the left ventricular endocardium with bipolar voltage displayed. Areas of low voltage are displayed in red and green, and ablation was performed in border zones between normal and abnormal voltage (brown dots represent ablation lesions). **B:** Ablation site location at site of concealed entrainment (bipolar voltage 0.11 mV). **C:** Ablation at isthmus site with subsequent termination of VT #2.

biventricular endocardial voltage mapping in the vast majority of patients and epicardial mapping in 20%–35% of cases.[33,34] This includes a combination of activation mapping and high-density substrate mapping in sinus rhythm or during ventricular pacing. Activation and entrainment mapping and ablation are favored in the setting of hemodynamically tolerated VT. Substrate ablation targets areas of abnormal electrogram and favorable pace mapping using linear and/or cluster lesion sets with the goal of abolishing critical isthmuses and/or blocking VT exit sites.[40,41] Several substrate-based ablation strategies have been reported, and may be employed according to local expertise.[41,42] Irrigated radiofrequency energy is preferred to ablate areas of interest using power of 25–50 W and a target impedance drop of 10–15 ohms.[34] Procedural outcome evaluation using noninducibility as an objective endpoint is favored.[42] An example case is shown in Figure 5.

A total of 6 observational studies have reported outcomes in patients with CS (Table 3). Jefic and colleagues[19] showed that peritricuspid circuits were common in the setting of RV involvement. A strategy of lesions connecting LVA to the tricuspid annulus was employed. In 5 patients with 6 Purkinje-related VT, successful catheter ablation involved the left anterior fascicle in 2, left posterior fascicle in 2, and right bundle in 2 patients. Among scar-related VTs, entrainment mapping was performed in all, showing critical isthmus sites on the RV septum, LV septum, perimitral region, and peritricuspid valve. Muser and colleagues[34] performed substrate modification for hemodynamically unstable VT in 19 of 31 (64%) patients. A median of 3 (1–5) VTs were inducible. The clinical VT was monomorphic in 28 of 31 (90%) patients and polymorphic in 3 of 31 (10%); multiple VT morphologies were observed in 15 of 31 (48%) patients. Activation/entrainment mapping was feasible in 36%; substrate-based approach in sinus rhythm with limited entrainment/activation mapping was performed in 64%. The LV endocardium was mapped in 21 of 31 (68%) patients and the RV endocardium in 18 of 31 (58%). Epicardial mapping was completed in 11 of 31 (31%) and performed when

Table 3 Ablation approach and outcomes

Study	Patients	Mean number of induced morphologies per patient	Sites of ablation	Mapping and ablation approach	Noninducible at end	Follow-up (months)	VT recurrence rate, n %	VT burden decrease, n (%)	Redo procedure, n (%)	Procedural complications, % (n)	Predictors of procedural success (freedom from VT relapse)
Jefic 2009[19]	9	4	Endocardial = 8 (RV = 5, LV = 3), epicardial = 1	Pace and entrainment mapping with critical isthmuses as ablation target	5 (55%)	20	4 (44%)	9 (100%)	3 (33%)	0	No data
Dechering 2013[69]	8	3.7	Endocardial mapping only; specific chamber data not available	Pace and entrainment mapping with critical isthmus as ablation target	5 (63%)	6	4 (50%)	8 (100)	1 (12.5%)	No data	No data
Naruse 2014[32]	14	no data	Endocardial mapping only; specific chamber data not available	Pace and entrainment mapping with critical isthmuses as ablation target	6 (67%)	33	6 (43%)	No data	4 (28.6%)	not available	No data
Kumar 2015[33]	21	3	Endocardial (LV = 15, RV = 18, both = 12); epicardial = 8	Pace and entrainment mapping with critical isthmuses as ablation targets, substrate mapping and ablation in some patients	9 (43%)	24 (median)	15 (71%)	16 (76%)	9 (43%)	Electromechanical dissociation, requiring biventricular assistant device and transplant, 4.7% (1)	No data
Muser 2016[34]	31	3	Endocardial (LV = 21, RV = 18); epicardial = 11	Activation and entrainment mapping in 36% of procedures, substrate-based approach in the rest; critical isthmuses, LPs, mid-diastolic potentials as targets	24 (77%)	30 (median)	16 (52%)	28 (90%)	9 (29%)	Perforation of the CS requiring surgery (1) Total occlusion of a small coronary branch while ablating the epicardium (1)	LVEF, RV dysfunction, NYHA class Positive baseline PET scan LGE in MRI
Kaur 2020[57]	24	2.71±2	Endocardial = 19 (LV = 12, RV = 7, both = 4, left coronary cusp = 1); epicardial = 10	Substrate, entrainment, activation, and pace mapping all, ablation targets = critical isthmuses, LPs	16 (66%)	60 ± 36	11 (45%)	16 (66%)	No data	Pericardial effusion pericardio centesis (1)	Absence of active disease on FDG-PET

CS = cardiac sarcoidosis; FDG-PET = 18-fluorodeoxyglucose positron emission tomography; LGE = late gadolinium enhancement; LPs = late potentials LV = left ventricle; LVEF = left ventricular ejection fraction; MRI = magnetic resonance imaging; NYHA = New York Heart Association; PET = positron emission tomography; RV = right ventricle.

Table 4 Predictors of success in VT ablation in cardiac sarcoidosis

Clinical presentation	Early presentation (preserved EF, limited MRI scar, early steroid therapy)[20,65,66]
Phase/stage of disease	Absence of active inflammation[34,57]
Response to immunosuppression	Decreased inflammation[67]
Anatomical site	Absence of intramural lesions, sparing of the para-Hisian region, and absence of extensive RV scarring[33,68]
Electrophysiological features	Absence of: -multiple induced VT -varying VT cycle lengths -Purkinje-driven tachycardia[32]

EF = ejection fraction; MRI = magnetic resonance imaging; RV = right ventricle; VT = ventricular tachycardia.

VT remained inducible despite endocardial ablation. Epicardial ablation was required in 8 of 21 (26%). All clinical and nonclinical VTs were targeted. A total of 44 procedures were required for adequate arrhythmia control.

Kumar and colleagues[33] performed endocardial mapping and ablation in all patients, epicardial mapping in 8 of 21 (38%), and epicardial ablation in 5 of 21 (23%). RV mapping detected LVA in 16 of 21 (76%), showing more confluent LVA when compared to the LV, where patchy LVA was detected frequently on the LV septum, anterior wall, and perivalvular regions. A median of 3 VTs were inducible (range, 1–8) during the first procedure. A total of 9 patients required repeat ablation for VT recurrence (44%). Among 9 patients treated for VT storm, ablation was successful in terminating VT storm in 7 (78%).

Challenging scenarios and emerging approaches to ablation

Failure to suppress VT has been reported owing to septal intramural circuits (9 procedures), widespread RV scar with multiple reentry circuits (6 procedures), VT circuit in close proximity to the left anterior descending coronary artery (3 procedures) or the ramus intermedius (1 procedure), or the para-Hisian region (1 procedure).[33] Bipolar ablation,[43,44] chemical ablation using ethanol injection,[45–47] or half-normal saline irrigation[48,49] have the potential to address intramural reentrant circuits in selected cases. Of note, half-normal saline use is associated with an increased risk of steam pop.[48] Catheter ablation using a retractable needle catheter can be useful and may be considered in the setting of recurrent VT secondary to septal or intramural substrate.[42,50] Pulsed field ablation is an emerging energy source that has the advantage of tissue specificity.[51] Therefore this technology has the potential to address challenges faced in VT ablation.[51] Experimental studies show that pulsed field ablation can achieve transmural ablation lesions without injury to coronary arteries and the risk of collateral damage to adjacent structures (eg, phrenic nerve).[52] Further studies are needed to clarify its role in catheter ablation for VT. Sympathetic denervation targeting the stellate ganglia may be considered in selected cases as a bridge to VT ablation or in cases of failed VT ablation.[53] Vaseghi and colleagues[54] reported a reduction in ICD shocks and VT survival almost by 60% a year after cardiac sympathectomy in those with VT storm or uncontrolled VT post ablation.[54] Another case series with 5 patients who had cardiac sympathectomy in the setting of failed catheter ablation and medical therapy had promising results for decreased ICD shocks post procedure.[53]

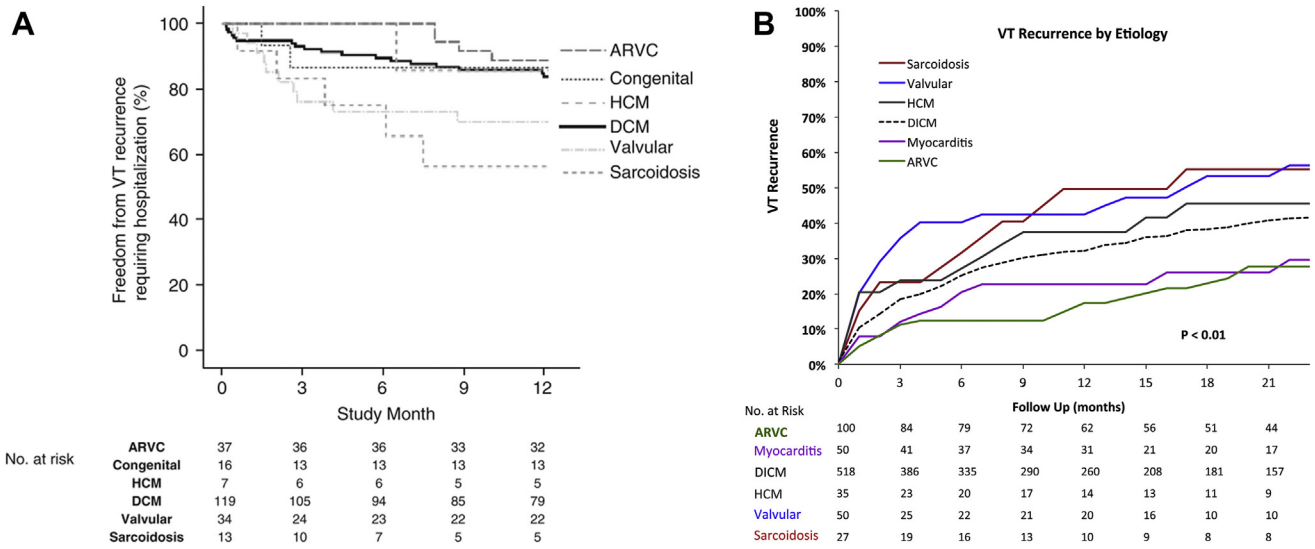

Figure 6 **A:** Kaplan-Meier analysis of freedom from ventricular tachycardia (VT) recurrence requiring hospitalization after ablation according to the type of nonischemic heart disease (reproduced with permission from Tokuda et al[55]). **B:** Unadjusted VT recurrence rates after ablation by etiology. Sarcoidosis and valvular cardiomyopathy have the highest rates of VT recurrence at 1 year of disease (reproduced with permission from Vaseghi et al[53]). ARVC = arrhythmogenic right ventricular cardiomyopathy; DCM = dilated cardiomyopathy; HCM = hypertrophic cardiomyopathy.

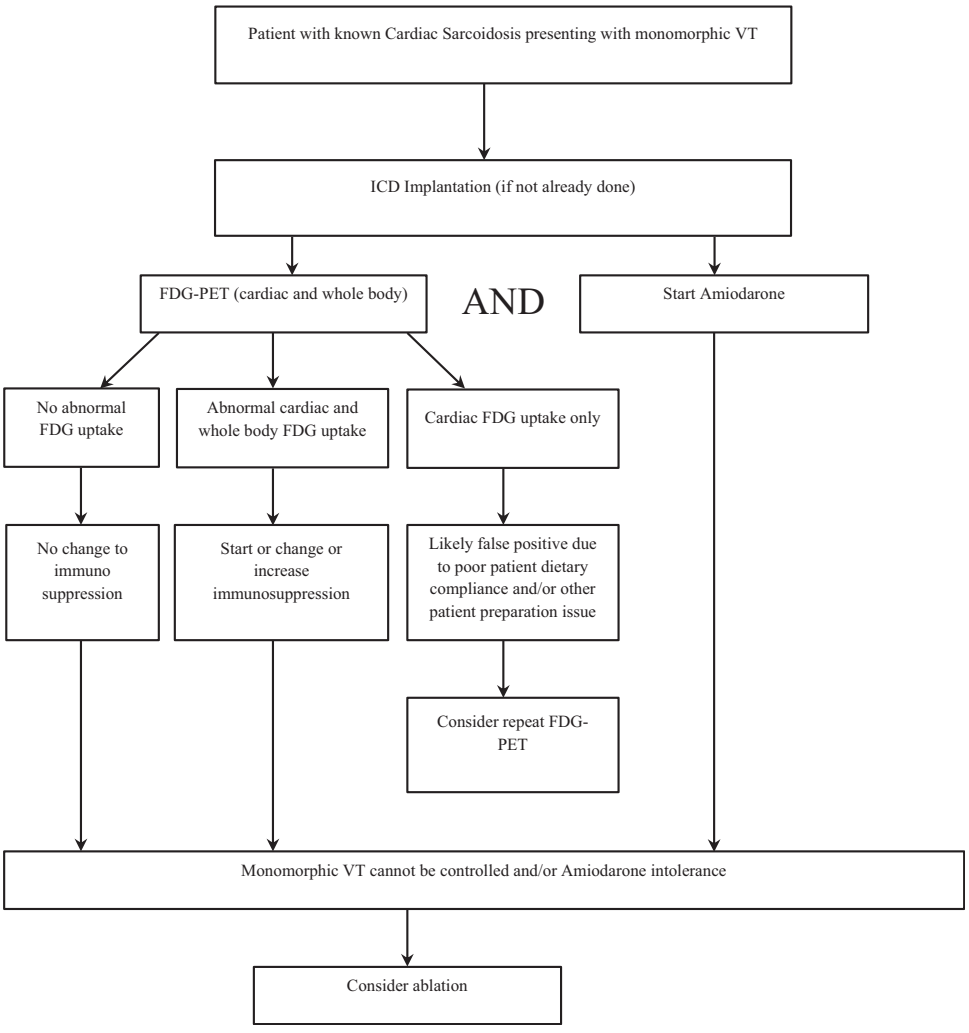

Figure 7 Suggested algorithm for management of ventricular tachycardia in patients with cardiac sarcoidosis. FDG = fluorodeoxyglucose; ICD = implantable cardioverter-defibrillator; PET = positron emission tomography; VT = ventricular tachycardia.

Results and predictors of outcome

Outcome data varies between series, because of differences in disease activity, extent of chamber involvement at the time of ablation, and use of IST (see Table 4 for summary). Ablation failure is mostly attributed to intramural substrates and presence of epicardial fat in patients with epicardial substrate.[19,33,34,55] Papageorgiou and colleagues[56] published a systematic review of all case series of CS patients undergoing VT ablation until September 2016. Five studies reporting on 83 patients were identified; the mean age of patients was 50 ± 8 years and the mean ejection fraction was 39.1% ± 3.1%. The median number of induced VT was 3 (2.6–4.9) per patient. Over a median follow-up of 25 months, recurrence occurred in 45 of 83 (54.2%). However, 61 of 83 (88.4%) patients had a reduction in VT burden following ablation (Figure 6A); 26 of 83 (31%) required a second ablation while 3 of 83 (3.6%) required a third ablation.[56] The complication rate was 2.7% and no procedural deaths were reported.[56] However, it seems that outcomes are generally poorer than in others with nonischemic cardiomyopathy (NICM) substrates (Figure 6B). For example, Tokuda and colleagues[55] published outcomes of catheter ablation in 226 patients in a single center. Patients with CS (13/226; 6%) had the greatest risk of VT recurrence. Vaseghi and colleagues[53] reported on 780 NICM patients from 12 centers; 3% had CS. They concluded that etiology of NICM is a significant predictor of outcomes, with arrhythmogenic right ventricular cardiomyopathy, myocarditis, and dilated cardiomyopathy having similar but superior outcomes to hypertrophic cardiomyopathy, valvular cardiomyopathy, and sarcoidosis, after adjusting for potential covariates. Hence, while procedural risks are acceptable in view of the likelihood of poor outcomes secondary to recurrent VT in this population, patient selection for catheter ablation is key. A multidisciplinary team approach involving heart failure/transplant specialists, cardiac electrophysiologists, and cardiac surgery specialists is recommended.

Table 4 summarizes factors that have been associated with VT ablation success. Muser and colleagues[34] showed that a positive baseline FDG-PET scan led to an almost 4-fold increased rate of events in follow-up, primarily VT recurrence. Similarly Kaur and colleagues[57] showed that among patients in the inflammatory phase, 10 out of 17 had a

recurrence of VT (58.8%), while only 1 out of 7 patients in the scar phase had VT recurrence over a mean follow-up of 5.7 ± 3.9 years. These findings suggest the importance of optimizing steroids/IST for control of VT prior to ablation.[57]

Management of ventricular fibrillation/VT storm

Patients with CS have an important risk of VT storm.[58] Schuller and colleagues[26] followed 116 CS patients with ICDs, and 14.3% patients developed electrical storm during mean follow-up of 29.2 months. Predictors of electrical storm were LV and RV dysfunction.[26] The time course of VT storm had 2 peaks: in the first 12 months after diagnosis and very late, after 60 months. Electrical storm is often the direct indication for ablation in CS patients.[19,32,33] In patients with VT/ventricular fibrillation storm, the HRS consensus suggested that initial treatment should be a combination of antiarrhythmic medication (usually amiodarone) and immunosuppression (if there is evidence of active inflammation). If the clinical situation or setting does not permit an urgent FDG-PET scan, then empiric immunosuppression should be given. If ventricular arrhythmias cannot be adequately controlled with medical therapy, then VT ablation should be considered even if there is active inflammation.

Conclusion

In the current era of targeted use of ICDs and modern heart failure therapy, recent data indicate the prognosis of CS is much improved. Very importantly, with improved survival we are seeing more patients with recurrent VT. It is likely that macroreentry phenomena around areas of fibrosis is the most frequent mechanism of ventricular arrhythmia in CS. The HRS consensus document recommended a stepwise approach to management (summarized in Figure 7). Likely principally related to the complex disease substrate, VT ablation is technically challenging, often requiring epicardial ablation, with modest outcomes; and much remains to be learned.

Funding Sources

This research did not receive any specific grant from funding agencies in the public, commercial, or not-for-profit sectors.

Disclosures

The authors have no conflicts to disclose.

Authorship

All authors attest they meet the current ICMJE criteria for authorship.

References

1. Kandolin R, Lehtonen J, Graner M, et al. Diagnosing isolated cardiac sarcoidosis. J Intern Med 2011;270:461–468.
2. Nery PB, Mc Ardle BA, Redpath CJ, et al. Prevalence of cardiac sarcoidosis in patients presenting with monomorphic ventricular tachycardia. Pacing Clin Electrophysiol 2013;364–374.
3. Nery PB, Beanlands RS, Nair GM, et al. Atrioventricular block as the initial manifestation of cardiac sarcoidosis in middle-aged adults. J Cardiovasc Electrophysiol 2014;25:875–881.
4. Simonen P, Lehtonen J, Kandolin R, et al. F-18-fluorodeoxyglucose positron emission tomography-guided sampling of mediastinal lymph nodes in the diagnosis of cardiac sarcoidosis. Am J Cardiol 2015;116:1581–1585.
5. Kandolin R, Lehtonen J, Airaksinen J, et al. Cardiac sarcoidosis: epidemiology, characteristics, and outcome over 25 years in a nationwide study. Circulation 2015;131:624–632.
6. Juneau D, Nery P, Russo J, et al. How common is isolated cardiac sarcoidosis? Extra-cardiac and cardiac findings on clinical examination and whole-body (18)F-fluorodeoxyglucose positron emission tomography. Int J Cardiol 2018;253:189–193.
7. Iwai K, Tachibana T, Takemura T, Matsui Y, Kitaichi M, Kawabata Y. Pathological studies on sarcoidosis autopsy. I. Epidemiological features of 320 cases in Japan. Acta Pathol Jpn 1993;43:372–376.
8. Coleman GC, Shaw PW, Balfour PC Jr, et al. Prognostic value of myocardial scarring on CMR in patients with cardiac sarcoidosis. JACC Cardiovasc Imaging 2017;10:411–420.
9. Al-Kindi SG, Oliveira GH. Letter by Al-Kindi and Oliveira regarding article "cardiac sarcoidosis: epidemiology, characteristics, and outcome over 25 years in a nationwide study.". Circulation 2015;132:e211.
10. Kandolin R, Lehtonen J, Kupari M. Cardiac sarcoidosis and giant cell myocarditis as causes of atrioventricular block in young and middle-aged adults. Circ Arrhythm Electrophysiol 2011;4:303–309.
11. Tung R, Bauer B, Schelbert H, et al. Incidence of abnormal positron emission tomography in patients with unexplained cardiomyopathy and ventricular arrhythmias: the potential role of occult inflammation in arrhythmogenesis. Heart Rhythm 2015;12:2488–2498.
12. Birnie DH, Sauer WH, Bogun F, et al. HRS expert consensus statement on the diagnosis and management of arrhythmias associated with cardiac sarcoidosis. Heart Rhythm 2014;11:1305–1323.
13. Judson MA, Costabel U, Drent M, et al. The WASOG Sarcoidosis Organ Assessment Instrument: an update of a previous clinical tool. Sarcoidosis Vasc Diffuse Lung Dis 2014;31:19–27.
14. Diagnostic standard and guidelines for sarcoidosis. Jpn J Sarcoidosis Granulomatous Disord 2007;27:89–102.
15. Terasaki F, Azuma A, Anzai T, et al. JCS 2016 guideline on diagnosis and treatment of cardiac sarcoidosis - digest version. Circ J 2019;83:2329–2388.
16. Zhou Y, Lower EE, Li HP, Costea A, Attari M, Baughman RP. Cardiac sarcoidosis: the impact of age and implanted devices on survival. Chest 2017;151:139–148.
17. Chapelon-Abric C, Sene D, Saadoun D, et al. Cardiac sarcoidosis: diagnosis, therapeutic management and prognostic factors. Arch Cardiovasc Dis 2017;110:456–465.
18. Reich JM. What is sarcoidosis? Chest 2003;124:367–371.
19. Jefic D, Joel B, Good E, et al. Role of radiofrequency catheter ablation of ventricular tachycardia in cardiac sarcoidosis: report from a multicenter registry. Heart Rhythm 2009;6:189–195.
20. Koplan BA, Soejima K, Baughman K, Epstein LM, Stevenson WG. Refractory ventricular tachycardia secondary to cardiac sarcoid: electrophysiologic characteristics, mapping, and ablation. Heart Rhythm 2006;3:924–929.
21. Furushima H, Chinushi M, Sugiura H, Kasai H, Washizuka T, Aizawa Y. Ventricular tachyarrhythmia associated with cardiac sarcoidosis: its mechanisms and outcome. Clin Cardiol 2004;27:217–222.
22. Te AL, Lin YJ, Chen YY, et al. Increased risk of ventricular tachycardia in patients with sarcoidosis during the very long term follow-up. Int J Cardiol 2017;228:68–73.
23. Hulten E, Agarwal V, Cahill M, et al. Presence of late gadolinium enhancement by cardiac magnetic resonance among patients with suspected cardiac sarcoidosis is associated with adverse cardiovascular prognosis: a systematic review and meta-analysis. Circ Cardiovasc Imaging 2016;9:e005001.
24. Nordenswan H-K, Lehtonen J, Ekström K, et al. Outcome of cardiac sarcoidosis presenting with high-grade atrioventricular block. Circ Arrhythm Electrophysiol 2018;11:e006145.
25. Betensky BP, Tschabrunn CM, Zado ES, et al. Long-term follow-up of patients with cardiac sarcoidosis and implantable cardioverter-defibrillators. Heart Rhythm 2012;9:884–891.
26. Schuller JL, Zipse M, Crawford T, et al. Implantable cardioverter defibrillator therapy in patients with cardiac sarcoidosis. J Cardiovasc Electrophysiol 2012;23:925–929.
27. Kron J, Sauer W, Schuller J, et al. Efficacy and safety of implantable cardiac defibrillators for treatment of ventricular arrhythmias in patients with cardiac sarcoidosis. Europace 2013;15:347–354.

28. Segawa M, Fukuda K, Nakano M, et al. Time course and factors correlating with ventricular tachyarrhythmias after introduction of steroid therapy in cardiac sarcoidosis. Circ Arrhythm Electrophysiol 2016;9:e003353.
29. Sadek MM, Yung D, Birnie DH, Beanlands RS, Nery PB. Corticosteroid therapy for cardiac sarcoidosis: a systematic review. Can J Cardiol 2013;29:1034–1041.
30. Fazelpour S, Beanlands RS, Tzemos N, Toma M, Birnie DH. Corticosteroid and immunosuppressant therapy for cardiac sarcoidosis: a systematic review. J Am Heart Assoc 2021. in press.
31. Yalagudri S, Zin Thu N, Devidutta S, et al. Tailored approach for management of ventricular tachycardia in cardiac sarcoidosis. J Cardiovasc Electrophysiol 2017; 28:893–902.
32. Naruse Y, Sekiguchi Y, Nogami A, et al. Systematic treatment approach to ventricular tachycardia in cardiac sarcoidosis. Circ Arrhythm Electrophysiol 2014; 7:407–413.
33. Kumar S, Barbhaiya C, Nagashima K, et al. Ventricular tachycardia in cardiac sarcoidosis: characterization of ventricular substrate and outcomes of catheter ablation. Circ Arrhythm Electrophysiol 2015;8:87–93.
34. Muser D, Santangeli P, Castro SA, et al. Long-term outcome after catheter ablation of ventricular tachycardia in patients with nonischemic dilated cardiomyopathy. Circ Arrhythm Electrophysiol 2016;9:e004328.
35. Hutchinson MD, Gerstenfeld EP, Desjardins B, et al. Endocardial unipolar voltage mapping to detect epicardial ventricular tachycardia substrate in patients with nonischemic left ventricular cardiomyopathy. Circ Arrhythm Electrophysiol 2011;4:49–55.
36. Muser D, Santangeli P, Liang JJ, et al. Characterization of the electroanatomic substrate in cardiac sarcoidosis: correlation with imaging findings of scar and inflammation. JACC Clin Electrophysiol 2018;4:291–303.
37. Arenal A, Glez-Torrecilla E, Ortiz M, et al. Ablation of electrograms with an isolated, delayed component as treatment of unmappable monomorphic ventricular tachycardias in patients with structural heart disease. J Am Coll Cardiol 2003; 41:81–92.
38. Nery PB, Keren A, Healey J, Leug E, Beanlands RS, Birnie DH. Isolated cardiac sarcoidosis: establishing the diagnosis with electroanatomic mapping-guided endomyocardial biopsy. Can J Cardiol 2013;29. 1015.e1–e3.
39. Liang JJ, Hebl VB, DeSimone CV, et al. Electrogram guidance: a method to increase the precision and diagnostic yield of endomyocardial biopsy for suspected cardiac sarcoidosis and myocarditis. JACC Heart Fail 2014;2:466–473.
40. Marchlinski FE, Callans DJ, Gottlieb CD, Zado E. Linear ablation lesions for control of unmappable ventricular tachycardia in patients with ischemic and nonischemic cardiomyopathy. Circulation 2000;101:1288–1296.
41. Cronin EM, Bogun FM, Maury P, et al. 2019 HRS/EHRA/APHRS/LAHRS expert consensus statement on catheter ablation of ventricular arrhythmias: executive summary. Heart Rhythm 2020;17:e155–e205.
42. Deyell MW, AbdelWahab A, Angaran P, et al. 2020 Canadian Cardiovascular Society/Canadian Heart Rhythm Society position statement on the management of ventricular tachycardia and fibrillation in patients with structural heart disease. Can J Cardiol 2020;36:822–836.
43. Sauer WH, Steckman DA, Zipse MM, Tzou WS, Aleong RG. High-power bipolar ablation for incessant ventricular tachycardia utilizing a deep midmyocardial septal circuit. HeartRhythm Case Rep 2015;1:397–400.
44. Igarashi M, Nogami A, Fukamizu S, et al. Acute and long-term results of bipolar radiofrequency catheter ablation of refractory ventricular arrhythmias of deep intramural origin. Heart Rhythm 2020;17:1500–1507.
45. Markowitz SM, Minutello RM, Kim LK, Ip JE, Thomas G, Lerman BB. Treatment of intramural ventricular tachycardia in cardiac sarcoidosis with transcoronary ethanol ablation. Europace 2017;19:1921.
46. Tedrow UB, Sobieszczyk P, Stevenson WG. Transvenous ethanol ablation of ventricular tachycardia. Heart Rhythm 2012;9:1640–1641.
47. Tavares L, Valderrabano M. Retrograde venous ethanol ablation for ventricular tachycardia. Heart Rhythm 2019;16:478–483.
48. Tschabrunn CM, Pothineni NVK, Sauer WH, et al. Evaluation of radiofrequency ablation irrigation type: in vivo comparison of normal versus half-normal saline lesion characteristics. JACC Clin Electrophysiol 2020;6:684–692.
49. Gaeta S, Schroder JN, Daneshmand MA, et al. Catheter ablation of midmyocardial ventricular tachycardia by simultaneous unipolar radiofrequency ablation with half-normal saline irrigation. JACC Clin Electrophysiol 2018; 4:1263–1264.
50. Stevenson WG, Tedrow UB, Reddy V, et al. Infusion needle radiofrequency ablation for treatment of refractory ventricular arrhythmias. J Am Coll Cardiol 2019; 73:1413–1425.
51. Koruth JS, Kuroki K, Iwasawa J, et al. Endocardial ventricular pulsed field ablation: a proof-of-concept preclinical evaluation. Europace 2020;22:434–439.
52. Stewart MT, Haines DE, Verma A, et al. Intracardiac pulsed field ablation: proof of feasibility in a chronic porcine model. Heart Rhythm 2019;16:754–764.
53. Okada DR, Assis FR, Gilotra NA, et al. Cardiac sympathectomy for refractory ventricular arrhythmias in cardiac sarcoidosis. Heart Rhythm 2019; 16:1408–1413.
54. Vaseghi M, Hu TP, Tung R, et al. Outcomes of catheter ablation of ventricular tachycardia based on etiology in nonischemic heart disease: an international ventricular tachycardia ablation center collaborative study. JACC Clin Electrophysiol 2018; 4:1141–1150.
55. Tokuda M, Tedrow UB, Kojodjojo P, et al. Catheter ablation of ventricular tachycardia in nonischemic heart disease. Circ Arrhythm Electrophysiol 2012; 5:992–1000.
56. Papageorgiou N, Providencia R, Bronis K, et al. Catheter ablation for ventricular tachycardia in patients with cardiac sarcoidosis: a systematic review. Europace 2018;20:682–691.
57. Kaur D, Roukoz H, Shah M, et al. Impact of the inflammation on the outcomes of catheter ablation of drug-refractory ventricular tachycardia in cardiac sarcoidosis. J Cardiovasc Electrophysiol 2020;31:612–620.
58. Carbucicchio C, Santamaria M, Trevisi N, et al. Clinical perspective. Circulation 2008;117:462–469.
59. Futamatsu H, Suzuki JI, Adachi S, et al. Utility of gallium-67 scintigraphy for evaluation of cardiac sarcoidosis with ventricular tachycardia. Int J Cardiovasc Imaging 2006;22:443–448.
60. Padala SK, Peaslee S, Sidhu MS, Steckman DA, Judson MA. Impact of early initiation of corticosteroid therapy on cardiac function and rhythm in patients with cardiac sarcoidosis. Int J Cardiol 2017;227:565–570.
61. Muser D, Santangeli P, Castro SA, et al. Prognostic role of serial quantitative evaluation of (18)F-fluorodeoxyglucose uptake by PET/CT in patients with cardiac sarcoidosis presenting with ventricular tachycardia. Eur J Nucl Med Mol Imaging 2018;45:1394–1404.
62. Banba K, Kusano KF, Nakamura K, et al. Relationship between arrhythmogenesis and disease activity in cardiac sarcoidosis. Heart Rhythm 2007;4:1292–1299.
63. Yodogawa K, Seino Y, Ohara T, Takayama H, Katoh T, Mizuno K. Effect of corticosteroid therapy on ventricular arrhythmias in patients with cardiac sarcoidosis. Ann Noninvasive Electrocardiol 2011;16:140–147.
64. Medor MC, Spence S, Nery PB, et al. Treatment with corticosteroids is associated with an increase in ventricular arrhythmia burden in patients with clinically manifest cardiac sarcoidosis: insights from implantable cardioverter-defibrillator diagnostics. J Cardiovasc Electrophysiol 2020;31:2751–2758.
65. Hoogendoorn JC, Sramko M, Venlet J, et al. Electroanatomical voltage mapping to distinguish right-sided cardiac sarcoidosis from arrhythmogenic right ventricular cardiomyopathy. Clin Electrophysiol 2020;6:696–707.
66. Muser D, Santangeli P, Pathak RK, et al. Long-term outcomes of catheter ablation of ventricular tachycardia in patients with cardiac sarcoidosis. Circ Arrhythm Electrophysiol 2016;9:e004333.
67. Stees CS, Khoo MS, Lowery CM, Sauer WH. Ventricular tachycardia storm successfully treated with immunosuppression and catheter ablation in a patient with cardiac sarcoidosis. J Cardiovasc Electrophysiol 2011;22:210–213.
68. Vita T, Okada DR, Veillet-Chowdhury M, et al. Complementary value of cardiac magnetic resonance imaging and positron emission tomography/computed tomography in the assessment of cardiac sarcoidosis. Circ Cardiovasc Imaging 2018;11:e007030.
69. Dechering DG, Kochhäuser S, Wasmer K, et al. Electrophysiological characteristics of ventricular tachyarrhythmias in cardiac sarcoidosis versus arrhythmogenic right ventricular cardiomyopathy. Heart Rhythm 2013;10:158–164.
70. Tavora F, Cresswell N, Li L, Ripple M, Solomon C, Burke A. Comparison of necropsy findings in patients with sarcoidosis dying suddenly from cardiac sarcoidosis versus dying suddenly from other causes. Am J Cardiol 2009;104:571–577.