

https://dspace.org/

Minimally invasive posterior spinal fusion in unstable thoracolumbar

Khan, Shahzad Ali

2017
http://hdl.handle.net/10539/23179

Downloaded from a DSpace repository. https://dspace.org/

Minimally Invasive Posterior Spinal Fusion in Unstable Thoracolumbar Fractures

Shahzad Ali Khan
MBBS
FC-Orth (SA)
Student No: 9900388H

Supervisor

Professor Mkhululi Lukhele
MBChB, MMed (Orth), FCS (Orth) SA
Head of Orthopedic Surgery
Charlotte Maxeke Johannesburg Academic Hospital
University of Witwatersrand
Johannesburg

A research report submitted to the Faculty of Health Sciences, University of the Witwatersrand, in partial fulfillment of the requirements for the degree of

Master of Medicine in the branch of Orthopaedic Surgery

Johannesburg, 2017

Declaration

I, Shahzad Ali Khan, declare that this research report is my own work. It is being submitted for the degree of Master of Medicine in the branch of Orthopaedic Surgery in the University of the Witwatersrand, Johannesburg. It has not been submitted before for any degree or examination at this or any other University.



……

1st day of June 2017

Dedication

I dedicate this study to my wife Dr. Sonet Pretorius for her unshakable belief in me and my supervisor Professor M. Lukhele for his infinite amount of patience.

Acknowledgements

Prof Mkhululi Lukhele, Supervisor

Prof Bischof

Mr. M. Poopedi

Dr. D. Ramushu

Dr. Dmitri Dimitriou

Dr. Brenda Milner

Dr. Maxwell Jingo

Spine Unit Registrars & Interns

Spine patients

Table of contents

Topic Number	Page Number	Content
	i	Declaration
	ii	Dedication
	iii	Acknowledgements
	viii	List of Figures
	ix	List of Tables
	x	Nomenclature
	xi	Abstract
1	1	Chapter 1: Introduction and Literature Review
1.1	1	Incidence of Thoracolumbar Fractures
1.2	1	Anatomy and Biomechanical Considerations
1.2.1	1	Bony spinal column
1.2.2	2	Spinal Cord
1.3	3	Mechanism of injuries
1.4	3	Evaluation of the patients
1.5	3	Radiology
1.5.1	3	Plain X-rays
1.5.2	5	CT scan

1.5.3	5	MRI scan
1.6	6	Classification Systems
1.6.1	6	Historical Classification Systems
1.6.2	8	Recent Classification Systems
1.7	12	Treatment
1.7.1	12	Non-operative Treatment
1.7.2	13	Operative Treatment
1.7.2.1	13	Surgical Approaches
1.7.2.1.1	13	Open Approach
1.7.2.1.2	15	Minimally invasive posterior approach
1.7.2.1.3	16	Percutaneous fixation of thoracolumbar fractures
1.7.2.1.3.1	16	Advantages of percutaneous fixation
1.7.2.1.3.2	18	Limitations of percutaneous fixation
2	19	Chapter 2: Study Aims and Methodology
2.1	19	Aim of the study
2.1.1	19	Objectives
2.2	19	Methods
2.2.1	19	Study settings
2.2.2	19	Type of study
2.2.3	19	Recruitment of patients
2.2.4	20	Surgeon

2.2.5	20	Inclusion criteria
2.2.6	20	Exclusion criteria
2.2.7	20	Sample size
2.2.8	21	Data collection
2.2.9	21	Consent
2.2.10	21	Neurological assessment
2.2.11	21	Radiology
2.2.12	21	Follow Ups
2.2.13	22	Ethics Approval
2.2.14	22	Funding
2.2.15	22	Statistical measurements
3	23	Chapter 3: Results and Discussion
3.1	24	Gender distribution
3.2	24	Age distribution in years
3.3	25	Vertebral distribution
3.4	25	AO fracture types
3.5	26	Duration since operation (months)
3.6	26	Cobb’s Angle of fracture kyphosis
3.7	28	Discussion
4	30	Chapter: Conclusion
	31	References

	35	Appendix A

List of Figures

Figure Number	Page Number	Content
1.1	2	A lateral view of the vertebral column
1.2	4	Typical methods used to measure fracture kyphosis
1.3	9	The load-sharing classification
2.1	2	Three columns of Denis classification
3.1	24	A pie chart showing gender distribution
3.2	24	Age distribution
3.3	25	Distribution of vertebra involved
3.4	25	Fractures types according to AO classification
3.5	26	Duration of last follow up since the time of surgery (in months)
3.6	26	Distribution of Cobb's angle of fracture kyphosis

List of Tables

Table Number	Page Number	Content
1.1	7	A table showing Denis classification of major injuries of thoracolumbar fractures
1.2	10	AO Comprehensive Classification
1.3	12	A table showing TLICS
3.1	27	Cobb's angle of fracture kyphosis
3.2	28	A table comparing the loss of correction in the current study *versus* other studies

Nomenclature

ASIA	American Spinal Injury Association
ASIF	Association of the Study of Internal Fixation (ASIF)
AO	Arbeitsgemeinschaft für Osteosynthesefragen
ATLS	Advanced Trauma Life Support
CEO	Chief Executive Officer
CT	Computerised Tomography
K-wire	Kirschner wire
L	Lumbar
MISS	Minimally Invasive Spinal Surgery
MRI	Magnetic Resonance Imaging
SAE	Serious Adverse Event
T	Thoracic
TLJ	Thoracolumbar junction
TLICS	Thoraco-Lumbar Injury Classification and Scoring

Abstract

Background

Unstable Thoracolumbar spinal fractures are conventionally treated by open reduction and internal fixation. This involves extensive mobilization of paraspinal muscles, which in turn leads to long-term disability in the form of chronic backache. One of the reasons fractures are stabilized is to prevent kyphotic deformity.

Posterior lumbar stabilization done through a minimally invasive technique can achieve the same result as the open technique at the expense of less mobilization of the paraspinal muscles.

Aim of the study

The aim of the study was to assess the effectiveness of minimally invasive posterior spinal fixation in unstable Thoraco-lumbar fractures in our setting at Charlotte Maxeke Academic Hospital.

Objectives

To assess the effectiveness of Minimally Invasive Spine Surgery over a short term of minimum of 12 months regarding:

Maintaining the correction of fracture kyphosis,

Re-operations and

Any serious Adverse Events

Methodology

This was a prospective interventional pilot study. Fractures were classified according to the AO comprehensive system. AO Comprehensive classification fractures A3, B1, B2, C1 and C2 were considered suitable for this technique. Pre-operative, immediate post-operative and one year follow up Cobb's angles of fracture kyphosis were measured on plain lateral x-rays. Any Serious Adverse Events (SAE) that may have required re-operations were recorded over the minimum of 12 months follow up.

Results

Twenty patients met the inclusion criteria for this study. Post-operative follow up ranged between 12 and 22 months. There were 14 males and 6 females. The age ranged between 16 years to 54 years with mean of 33.9 years. L1 was the most commonly fractured vertebra. Eleven out of 20 patients sustained fracture of L1, 6 patients had fracture of L2 whereas 3 patients sustained fracture of T12. The AO classification types included one B1, five B2, seven C1 and seven C2 fractures. The pre-operative Cobb's angle ranged from 7 degrees to 38 degrees with mean of 21.2 degrees. The immediate post-operative Cobb's angle ranged between zero degrees to 16 degrees with mean of 8.3 degrees. The last follow up Cobb's angle ranged between zero degrees to 21 degrees with a mean of 10.7 degrees. The loss of correction of fracture kyphosis ranged between zero degrees to 6 degrees with a mean of 2.4 degrees. The post-operative Cobb's angle was maintained. There was no deterioration of pre-operative neurological status. There was no serious adverse event requiring a re-operation.

Conclusion

Minimally Invasive Posterior Spinal stabilization for thoracolumbar fractures had an acceptable outcome in our hands in appropriately selected cases. The average loss of correction of 2.4 degrees was in keeping with that found in open technique as well as MIS at other centers. While the number is less, this procedure can be recommended for well selected patients where skills are available.

Chapter 1

Introduction and Literature review

1.1 Incidence of Thoracolumbar Fractures

Spine fractures are common in men than in women. Two third of these fractures occur in men and one third occurring in females. According to statistics, approximately, 150,000 - 160,000 patients sustain injury to the spinal column every year in United States of America.(1)

The majority of these fractures occur in cervical and Thoracolumbar junction followed by thoracic spine, Lumbar and sacral spine. Approximately 15% to 20% of these fractures occur at the Thoraco-lumbar junction (T10 – L2). Spinal cord is injured in about 10% to 30% of spinal fractures. The German Society of traumatology reported 22– 51% incidence of spinal cord injuries in thoracolumbar fractures depending on the type of fractures. AO Type A-fractures resulted in 22%, type B- fractures had associated 28% whereas type -C fractures had associated 51% spinal cord injuries. The incidence of complete paraplegia was 5% in patients with thoracolumbar fractures.(2)

1.2 Anatomy and Biomechanical considerations

1.2.1 Bony spinal column

The Thoracic spine consists of T1 – T10 vertebrae. This area of spine is in kyphosis, stiff as this is connected to the sternum through ribs. There is very minimal movement occurring in this region. The kyphotic angle range between 20 degrees to 40 degrees in general population. The Thoraco Lumbar Junction (TLJ) extends between T10 to L2 vertebrae. This is neutral in alignment in both coronal and sagittal planes and is the transitional zone between kyphotic thoracic spine and lordotic lumbar spine. In the lumbar spine, there is lordosis between L3 to S1 ranging between 40 – 60 degrees. The spine here is very mobile. Grossly, the spine moves from relatively stiff thoracic spine to very mobile lumbar spine. The transitional area of TLJ is exposed to enormous shearing forces. The susceptibility of the Thoraco- lumbar transition is attributed mainly to the following anatomical reasons:

The transition from a relatively rigid thoracic kyphosis to a more mobile lumbar lordosis occurs at T11 – 12. The T11 and T12 ribs are floating free as they are not connected to the sternum anteriorly. Therefore, they provide less stability to the spine in this region. (3)

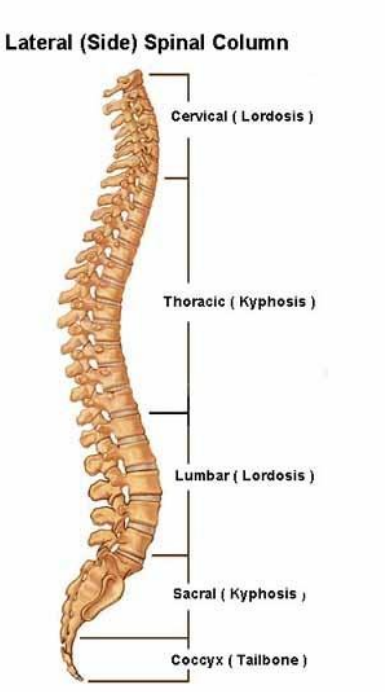

Figure 1.1: A lateral view of the vertebral column.(4)

The facet joints orientation differs in Thoracic and Lumbar area. The facet joints of the thoracic spine are orientated in the coronal (frontal) plane whereas in the lumbar spine the facet joints are orientated in the sagittal plane. The orientation of the facet joints in different regions of the spinal column accounts for the degree of movement. There is limited flexion coupled with extension in the thoracic spine and increased flexion and extension movement in the lumbar spine. (2)

1.2.2 Spinal Cord

The spinal cord ends between L1 – L2. Fractures at Thoraco- lumbar junction give rise to different patterns of spinal cord injury. Severe injuries above the L1 vertebra will generally give rise to paraplegia. Injuries below L2 vertebra will injure the Cauda Equina nerve roots and give rise to flaccid paralysis. The fractures at L1 level give rise to a peculiar picture of Conus Medullaris Syndrome. In this syndrome, patients generally will lose control of their bowel and bladder but the lower lumbar nerve roots escape the injury. Patients generally will have nearly normal motor function in the lower limbs.(3)

1.3 Mechanism of injuries

The majority of these injuries occur in high energy motor vehicle accidents or falls. Approximately 40% to 80% of fractures belong to high energy trauma.(3)

Avanzi et al. quoted motor vehicle accidents to be responsible for 64% and falls 36% for Thoracolumbar fractures in their study.(5)

1.4 Clinical Evaluation of the patients

All the patients admitted to the emergency room should be managed according to the Advanced Trauma Life Support (ATLS) protocol. This includes general examination of the patient, identifying the associated injuries, carrying out the primary and secondary surveys. When spine injury is suspected a careful history will point to the area of injury. All suspected spinal injuries are considered as unstable until proven otherwise. Patients are generally log rolled for examination of the spine. During this examination spine is inspected for any bruises, swellings and palpated for kyphotic angulation, step offs, and point tenderness, which is present in injuries to the osteo-ligamentous complex. A full neurological examination is done and neurology is chartered according to the American Spinal Injury Association (ASIA) scoring. (3)

1.5 Radiology

1.5.1 Plain X-rays

Most of the trauma centers have Lodox machines. On arrival at the emergency department, patients are exposed to Lodox for the whole body x-rays. A plain radiograph is the first radiological investigation in the assessment of the Thoracolumbar fractures. Standard radiographs include an Antero-posterior and a Lateral view. Plain x-rays are not only used to identify the level and pattern of fracture but also used to measure the fracture kyphosis.

There are five ways described to measure the fracture kyphosis.

1. The Cobb angle: this is measured from the superior end plate of the vertebra above to the inferior end plate of the vertebra below the fractured vertebra.(6)
2. The Gardner's Method: This is measured from the superior end plate of the vertebrae above to the inferior end plate of the fractured vertebra.(6)

3. The posterior walls angle: this is the angle formed by the lines drawn at the posterior vertebral body line of the vertebra above and the regular below the fractured vertebra.(6)
4. The adjacent end plate method: This is the angle formed by the inferior end plate of the vertebra above and the superior end plate of the vertebra below the fracture.(6)
5. The wedge angle: this is the angle formed by a line drawn along the superior and inferior end plates of the fractured vertebra.(6)

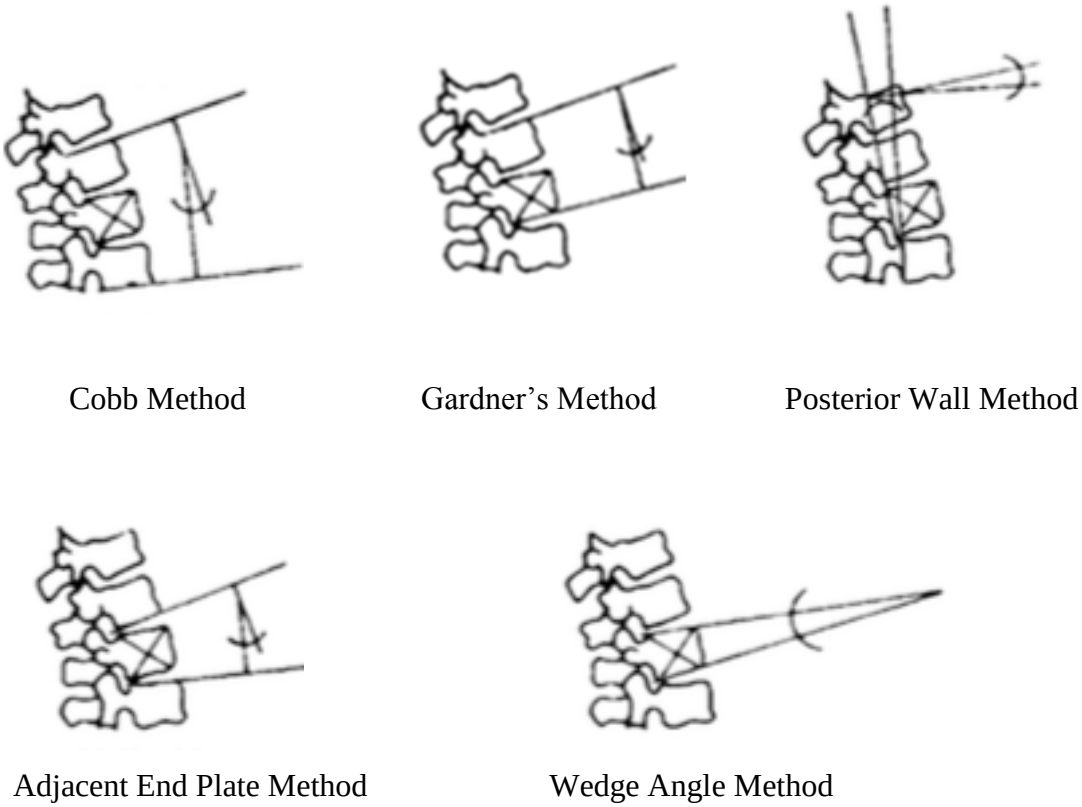

Figure 1.2: Typical methods used to measure fracture kyphosis.(6)

Of all the techniques to measure the fracture kyphosis, the Cobb method was the most prevalent and frequently used. In a study by Sidiqi et al., an online multicenter survey was conducted from most regions of the world. Between 71.0 – 75.7% of the participants used Cobb method as the preferred choice to measure the fracture kyphosis.(6)

Cobb's angle, Gardner method and sagittal index were compared in measurement of the fracture kyphosis of Thoraco-lumbar burst fracture. The result clearly showed as the Cobb's

method being the most reliable intra and inter-observer in assessment of the Thoraco-lumbar burst fracture kyphosis. (7)

1.5.2 CT scan

This is the investigation of choice for bony definition of the spinal column. This provides the three dimensional view of the fractures and help classify the fracture pattern. CT scan reveals the comminution of the vertebral body which helps in the Load Sharing Classification. It identifies the transverse process fractures which help with rotational component of the AO classification system. It is used for identification of the intact pedicles, diameter and length of pedicles. Intact pedicles are available for insertion of pedicle screws for additional strength. The CT scan also helps identify the Reverse Cortical and Pseudoreverse Cortical signs.

The posterior wall of the vertebral body is generally involved in burst fractures of Thoracolumbar spine. A reverse cortical sign also called a "Flipped sign" is the one where "the cortex of the posterior wall fragment appeared to be sitting anteriorly and the cancellous portion of the piece seems to be lying posteriorly in the spine canal".(8)

The whole fragment is rotated 180 degrees. This is because of rupture of the posterior longitudinal ligament.(8)

A Pseudoreverse Cortical Sign is where the superior dense wall flips 90 degrees and appears to sit anteriorly. The posterior cancellous part seems to face posteriorly into the spinal canal. Posterior longitudinal ligament remain attached. This has been shown on the MRI scan.

CT scan can differentiate reverse Cortical and Pseudoreverse Cortical Signs.(8)

1.5.3 MRI Scan

An MRI Scan is vital in patients presenting with neurological fallout in Thoracolumbar fractures. It helps in defining the integrity or otherwise of the posterior ligamentous complex. This is especially helpful in patients with suspected Posterior Ligamentous Complex rupture in classifying the patients according to Thoraco Lumbar Injury Classification & Scoring system (TLICS). There are certain points which one must note reading an MRI scan in relation to Thoracolumbar fractures. They are bony elements, soft tissues such as Posterior Ligamentous Complex(PLC), discs, longitudinal ligaments, spinal cord and Cauda Equina injuries, injuries to the nerve roots and a hematoma within spinal canal.(9)

1.6 Classification Systems

A good classification system should cover following points when it comes to Thoracolumbar fractures: Pattern, instability, guidelines on treatment, outcome, easy communication and its reliability in research.

There are several classification systems available for Thoracolumbar fractures. Some of these systems are of historical values and the others are recent and in use on a daily basis.

1.6.1 Historical Classification Systems

(i) Holdsworth

In this classification system, injuries were simply differentiated between stable and unstable injuries. Stable injuries were simple wedge fractures, Burst fractures and extension injuries. Unstable injuries comprised of dislocations, rotational flexion–distraction and shear fractures. (9)

(ii) Kelly and Whiteside

This classification system consisted of two columns; An Anterior weight bearing column of vertebral bodies and a posterior column of neural arches resisting the tensile forces. (9)

(iii) Denis Classification

Denis classification consists of three columns namely anterior, middle and posterior. The anterior column consists of anterior two thirds of the vertebral body, Anterior Longitudinal Ligament and the disc. The middle column consists of posterior one third of the vertebral body, Posterior Longitudinal Ligament and the disc. The posterior column consists of facet joints and inter- spinous ligament. This classification system is too complex for daily use. Denis subdivides the burst fracture into five subtypes. The treatment remains the same and therefore there is little value. Denis differentiated between minor and major spinal column injuries. The minor injuries include transverse process fractures, pars inter-articularis fractures and spinous process fractures. The major injuries are shown in the following table (see Table 1.1).

Table 1.1: A Table showing Denis classification of major injuries of Thoracolumbar fractures.(10)

Type	**Mechanism**	**Columns Involved**
Compression	**Flexion**	
Anterior	Anterior Flexion	Anterior column compression without posterior column distraction
Lateral	Lateral flexion	
Burst		
A	Axial load	
B	Axial load plus flexion	Anterior and middle column compression with/without posterior column distraction
C	Axial load plus flexion	
D	Axial load plus rotation	
E	Axial load plus lateral flexion	
Seat Belt	Flexion - distraction	Anterior column intact or distracted, middle and posterior column distracted
Fracture-dislocation		
Flexion – rotation	Flexion – rotation	Any column can be affected (alone or in combination)
Shear	Anterior – posterior or posterior – anterior	
Flexion - distraction	Flexion – distraction	

(iv) MacAfee Classification

McAfee and colleagues presented their classification based on CT scan. In 100 patients who presented with Thoracolumbar fractures, the CT scan analysis lead to a new classification system based on mechanism of injury. They described three types of mechanisms of injury. These were axial compression, axial distraction and translation in the transverse axis. Translational injuries were considered the most unstable injuries in their classification system. (11)

1.6.2 Recent Classification Systems

The classification systems of Thoracolumbar fractures have undergone evolution. The most frequent classifications used currently include McCormack's Load Sharing Classification, AO Classification and TLICS System. The McCormack's Load Sharing Classification is frequently used to identify the stability of the weight bearing anterior column. The AO group presented their classification system. Since its introduction, it has undergone modification. In 2005, the spine trauma group presented classification called TLICS.

(i) Load Sharing Classification

McCormack et al. presented their classification also known as load sharing classification. They studied 28 of their patients with Thoracolumbar burst fractures who underwent posterior stabilization. Using this classification they could predict the failure of their implants.

This classification used x-rays and CT scan for analysis of Thoracolumbar fractures. They took into account three factors.

- Percentage of comminution of the vertebral body in sagittal plane
- Displacement of the fracture fragments
- Amount of deformity correction in hyperextension by Cobb's method

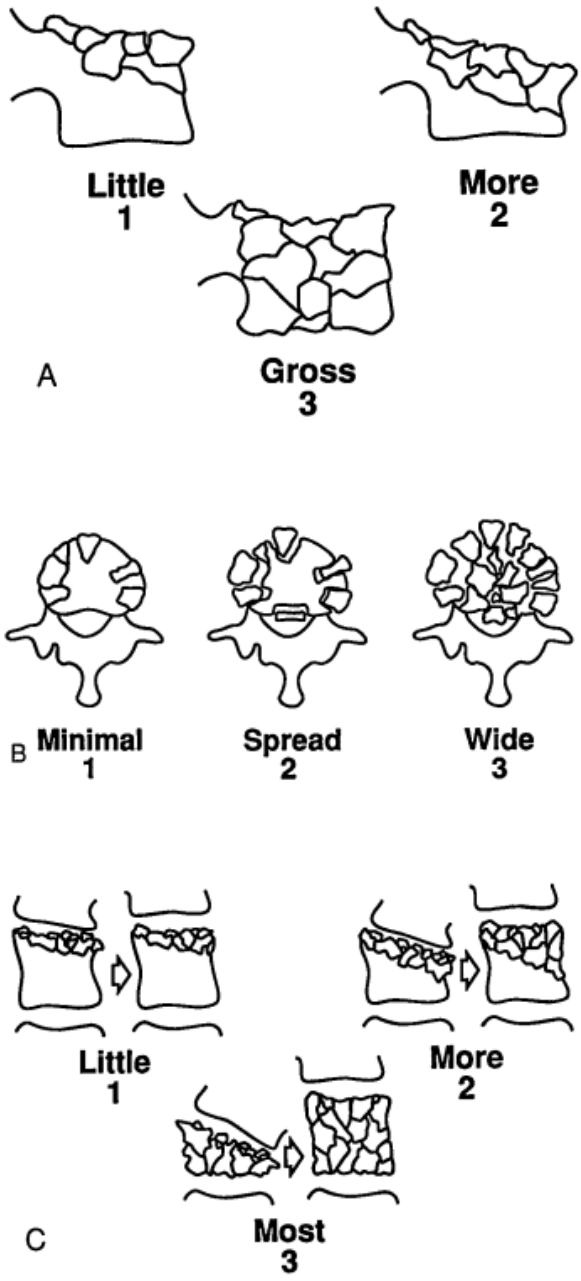

Figure 1.3: The load sharing classification. A) Comminution/involvement. Little (1) = <30% comminution on sagittal plane section computerised tomography (CT). More (2) = 30% to 60% comminution. Gross (3) = > 60% comminution. B) Apposition of fragments. Minimal (1) = minimal displacement on axial CT cut. Spread (2) = at least 2mm displacement < 50% cross-section of body. Wide (3) = at least 2mm displacement > 50% cross-section of body. C) Deformity correction. 1 = kyphotic correction ≤ 3° on lateral plain films. 2 = kyphotic correction 4° to 9°. 3 = kyphotic correction ≥ 10°.(12)

Parker et al. in 2000 applied load sharing classification in 51 patients with Thoracolumbar fractures suitable for surgical stabilization for anterior or posterior approach. They concluded that patients with score of up to 6 were managed satisfactorily by posterior stabilization. Those with scores of 7 or above were at high risk of implants failure. They were managed with combined anterior and posterior approach as the reconstruction of the anterior column was thought mandatory.(13)

(ii) AO Comprehensive Classification

Table 1.2: A table showing AO/Magerl Classification.(14)

AO/Magerl Classification		
Type	**Group**	**Subgroup**
A **(Compression)**	**A1:**Impaction fractures	A1.1 End plate Impaction A1.2 Wedge impaction A1.3 Vertebral body collapse
	A2: Split Fractures	A2.1 sagittal split A2.2 coronal split A2.3 pincer fracture
	A3: Burst fractures	A3.1 incomplete burst fracture A3.2 burst split fracture A3.3 complete burst fracture
B **(Distraction)**	**B1:** Posterior ligamentary lesion (subluxation)	B1.1 With disc rupture B1.2 with Type A fracture
	B2: Posterior osseous lesion (Spondylolysis)	B2.1 transverse bi-column B2.2 with disc rupture

	B3: Anterior disc rupture	B2.3 with type – A fracture B3.1 hyperextension – subluxation B3.2 hyperextension – Spondylolysis B3.3 posterior dislocation
C **(Rotational Injury)**	**C1:** Type – A with rotation (Anterior – Posterior dislocation) **C2:** Type – B with rotation (Lateral shear) **C3:** Rotational (Rotational Burst)	C1.1 rotational wedge fracture C1.2 rotational split fracture C1.3 rotational burst fracture C2.1 B1 lesion with rotation C2.2 B2 with rotation C2.3 B3 with rotation C3.1 Slice fracture C3.2Oblique fracture

(iii)TLICS (Thoraco – Lumbar Injury Classification and Scoring)

The Spine Trauma Study Group introduced the TLICS system in 2005. TLICS was designed to provide a definitive classification system that accounts for several shortcomings of previously used systems. This system was developed based on opinions collated from a multinational group consisting of 40 spinal surgeons (see Table 1.4).

Table 1.3: A table showing TLICS.(15)

Thoracolumbar Injury Classification & Severity Score (TLICS)		
Parameter	**Categories**	**Points**
Morphology	Compression Burst Rotational/Translational Distraction	1 point +1 point 3 points 4 points
Posterior Ligamentous Complex	Intact Suspected/Indeterminate Injured	0 point 2 points 3 points
Neurological Status	Intact Nerve Root Injury Cord/Conus Complete Injury Cord/Conus Incomplete Injury Cauda Equina	0 point 2 points 2 points 3 points 3 points
Score Interpretation • Total Score <4 points → Non – surgical treatment • Total Score = 4 points →Non – surgical or Surgical treatment • Total Score > 4 points → Surgical treatment		

1.7 Treatment

The majority of Thoracolumbar fractures are treated non-operatively. Only 30% of fractures need surgical stabilization.(16)

1.7.1 Non-operative Treatment

Ideal patient for non-operative treatment is the one who has only bony injury, no neurological fallout, no tenderness posteriorly at the fracture site and absence of gross mal-alignment. Generally, AO type – A fractures fall in this category.

Some of the modalities used for non-operative treatment are plaster casting and braces.

1.7.2 Operative Treatment

Generally, unstable fractures are treated with surgical stabilization. There are certain advantages to surgical stabilization such as early mobilization facilitate nursing care in polytrauma patients, better pain management, early return to work and prevention of delayed neurological complications.

1.7.2.1 Surgical approaches

There are several surgical approaches utilized for surgical fixation of Thoraco-lumbar fractures. These are:

1. Open Technique
    - Posterior approach
    - Anterior approach
    - Combined Anterior and posterior approaches
2. Minimally Invasive approach

1.7.2.1.1 Open Approach

(i) <u>Posterior Approach</u>

This is the workhorse of the surgical stabilization of Thoracolumbar fractures. Spine is exposed through a midline posterior approach. Muscles are mobilized. Once levels are identified under image intensifier, pedicle screws are placed in the intact vertebrae above and below. With this construct, a good reduction and stable fixation is reliably achieved. Care should be taken to identify the Reverse Cortical Fragment on the CT scan. A Reverse Cortical fragment is a contraindication for this approach. Posterior approach relies on 'Ligamentotaxis' on fracture reduction. This fragment has lost its attachment to the posterior longitudinal ligament and will not reduce. On the contrary, it is likely to worsen the neurology. It should not be confused with the pseudo-reverse cortical sign where the fragment has retained its attachment to the posterior longitudinal ligament and will respond to ligamentotaxis method of reduction. Posterior approach is appropriate in cases with Pseudoreverse Cortical sign

Posterior technique of Thoracolumbar fracture fixation has undergone modification. The biomechanical studies have shown that 60% of the strength of pedicle screw comes from the pedicle alone.(17)

In newer technique the intact pedicles of the fractures vertebra are utilized for additional strength. (18)

(ii) Loss of Reduction of corrected kyphosis

In the study conducted by Rajasekaran et al. used short segment fixation technique where they instrumented the intact pedicle(s) of the fractured vertebra. The mean loss of fracture kyphosis was 11.6 degrees at 2 years follow up.(18)

(iii) Anterior Approach

About 80% of the axial load of spine is supported by anterior column.(19) In high energy trauma, the anterior column sustains severe comminution. Restoration of anterior column is utmost important otherwise implant failure and subsequent development of kyphosis occurs which may lead to neurological compromise.

Load sharing classification helps identify the cases where an anterior approach may be indicated.

Other indications of anterior approach include delayed presentation, patients presenting with neurological fallout and presence of Reverse cortical fragment.(8, 12, 16, 20)

(iv) Combined Anterior – Posterior Approach

If the anterior column is severely comminuted, posterior stabilization alone may not be sufficient. In this case, combined anterior and posterior approaches are utilized for stable construct. This is especially true in cases where load sharing classification score is seven or above.

Combined approach also offers much better decompression in patients with neurological compromise allows for better reconstruction of the anterior column as well as takes advantage of pedicle screws used in the posterior stabilization approach.(21, 22)

1.7.2.1.2 Minimally Invasive Posterior approach

(i) Evolution of Minimally Invasive Spine Surgery (MISS)

The use of MISS in the spine has gained recognition over the past several years and is now routinely utilized to treat degenerative spine disorders. Furthermore, minimally invasive spine surgery has been shown to be as effective as open surgery. MISS is increasingly being used for the treatment of unstable fractures at Thoracolumbar junction (23)

Traditionally, a posterior spinal stabilization requires muscle dissection for insertion of implants and placement of bone graft. This muscle dissection is accompanied by facet joint denervation. Together they lead to weakening of the supportive tissues and gives rise to the concept of "Fusion Disease".(24)

Airaksinen et al. showed that even a simple laminectomy could lead to muscle atrophy and a poor clinical outcome. To determine the clinical outcome, they compared the results of decompressive surgery for lumbar spinal stenosis and evaluated the density of lumbar muscles by Computed Tomography (CT) at the L2–L4 levels in patients four years post-surgery. Furthermore, the Oswestry questionnaire and a walking test were also included to determine the clinical outcome. Overall, their results showed that twenty patients had an excellent clinical outcome (high muscle density) whereas sixteen patients had a very poor outcome (low muscle density). A decrease in lumbar muscle density may result from disuse or inactivity.(25)

(ii) Minimally Invasive Spine Surgery (MISS) for Thoracolumbar fracture in damage control spine stabilization

The application of MISS techniques for the treatment of Thoracolumbar fractures has many attractions, especially in the setting of damage control spine stabilization. The techniques and instrumentation used are continuously being developed. Those patients who are not stable enough for open spine surgery and has unstable spine are ideal candidates for internal splinting in acute settings. Once stable, the definitive surgery in the form of reconstruction of the anterior column is carried out through an anterior approach.(26, 27)

1.7.2.1.3 Percutaneous Fixation of thoracolumbar fractures

MISS has developed rapidly over the past decade. New implants and techniques, as well as sophisticated imaging technologies have been introduced. It is generally expected that MISS will produce similar results as conventional surgery however, with less morbidity. Initially, the technique was developed to improve functional results in surgery for degenerative spine disease. (28)

1.7.2.1.3.1 Advantages of MISS

MISS spares the paravertebral musculature. There is less blood loss as it does not involve extensive muscle mobilization, therefore, the rate of infection, post-operative pain and length of hospital stay is reduced. Patients also start their rehabilitation earlier.

(i) <u>Muscle preservation</u>

In a cadaver study by Regev et al., the authors reported that the "Multifidus motor nerve was injured in 20% of cases when screws were implanted percutaneously versus 80% when the screws were implanted during an open procedure". (29)

Kim et al. carried out a clinical study on degenerative diseases. They reported that patients who underwent an open procedure took more pain killers following the operation. Furthermore, their muscle enzyme levels were higher on day one and day seven. Muscle atrophy also increased and this was visible by magnetic resonance imaging (MRI). The group of patients who received percutaneous fixation had better muscle strength postoperatively compared to those who underwent an open procedure. (30)

Lehmann et al. conducted a study on sheep and reported that the levels of muscle enzyme did not increase as much when the screws were placed percutaneously compared to an open procedure. Their findings were independent of the operative time. (31)

(ii) <u>Blood loss</u>

Wild et al. reported statistically lower blood loss in trauma cases after an internal fixator was implanted percutaneously compared to when it was implanted during an open procedure. (32)

In a study by Schmidt et al. described a series of 76 MISS cases for the thoracic spine. A blood transfusion was required in three cases where an anterior procedure was performed in addition to posterior percutaneous fixation. (33)

In a study by Merom et al. they found that there was less blood loss (50ml less than the average) in patients who underwent percutaneous fixation compared to those who had open fixation. (34)

(iii) Operative time

Merom et al. reported that with short-segment fixation, the operative time for percutaneous fixation was slightly less (73-85 minutes) compared to open fixation (78-102 minutes). (34) Similarly, Ni et al. also reported a shorter operative time with MISS as opposed to the open procedure. (35)

(iv) Hospital Stay

In a study by Merom et al., patients who underwent MISS were able to walk one or two days following surgery. In contrast, patients who underwent open fixation were only able to walk three or four days following surgery.(34) Other authors have also reported a shorter hospital stay in patients who underwent MISS versus open fixation. (35, 36)

(v) Infection rate

In a study by Ni et al. consisting of 36 patients who underwent percutaneous fixation, the authors reported a single superficial infection. The patient was treated with antibiotics alone.(35) Similarly, in a study (N=64) by Palmisani et al., the authors reported a single case of infection that required the removal of instrumentation. (37) In a study by Schmidt et al. there were no infections reported in their study that consisted of 76 patients. (33)

1.7.2.1.3.2 Limitations of percutaneous fixation

(i) Exposure to X-rays

This poses a major risk to the surgeon. The hands and thyroid gland are the major recipients of radiation. Several studies suggested exposure time to be roughly twice the time when compared to the conventional open technique. Radio-protective gloves, navigation techniques and special instruments are some of the modalities that are used to reduce the exposure to radiation.(38, 39)

(ii) Neurological decompression

Decompression in patients presenting with thoracolumbar fractures and neurological fallout poses a challenge. There are procedures described by which the pedicle screws are placed using a minimally invasive technique. The spine is then exposed through a mini open mid-line incision for decompression. (40)

(iii) Instrumentation removal

Currently there is no consensus regarding the timing and technique used to remove implants that have been placed during MISS. Despite the lack of evidence, Agarwal et al. described a minimally invasive technique to remove the pedicle screws and rods.(41)

Chapter 2

Study Aims and Methodology

2.1 Aim of the study

The aim of the study is to assess the effectiveness of minimally invasive posterior spinal fixation in unstable Thoracolumbar fractures in our setting.

2.1.1 Objectives

- To assess the correction of kyphosis and maintance of the correction over minimum of 12 months
- Re-operation
- To evaluate any Serious Adverse Events

2.2 Methods

2.2.1 Study Settings

According to stats SA, in 2015, South Africa has a population of 55.6 million. Gauteng province population breached the 13 million inhabitants in 2015. Population was estimated to be 13.40 million in 2016.

Johannesburg is the largest city in Gauteng province and Republic of South Africa. The greater Johannesburg population is estimated to be 9.3 million in 2015 according to Statistics SA and City of Johannesburg has 4.9 million inhabitants. Spine service is provided by three academic hospitals that are Chris Hani Baragwanath Hospital, Charlotte Maxeke Johannesburg Academic Hospital and Helen Joseph Hospital. Patients for the study were recruited from Charlotte Maxeke Johannesburg Academic Hospital. The total number of beds at the hospital is 1088. The beds assigned to orthopedic department are 103. Spine unit has 12 beds at its disposal.

2.2.2 Type of study

This was a prospective Interventional study.

2.2.3 Recruitment of patients

All patients who met the inclusion criteria were consecutively recruited from December 2012 to February 2015.

2.2.4 Surgeon

The candidate and the supervisor were assigned to carry out the procedures. Both had attended the cadaver workshop for training for the MISS.

2.2.5 Inclusion Criteria

- Fractures AO type A3, B1, B2, C1, c2
- Age >18 years
- Mentally competent
- Fracture level T10 – L2

2.2.6 Exclusion Criteria

- Open fractures
- Osteoporotic fractures
- Pathological fractures
- Fractures involving more than 2 motion segments
- More than one region involvement
- Associated injuries that may prevent standard rehabilitation program

2.2.7 Sample Size

Consecutive patients with Thoracolumbar fractures were recruited between December 2012 and February 2015.From the admission profile at spine unit, Charlotte Maxeke Johannesburg Academic Hospital and guidance from the studies at other centers, a sample size of 20 patients met the inclusion criteria and were considered suitable for the study.

Grossbach et al. from May 2003 to March 2013 recruited 39 patients with flexion – distraction Thoracolumbar fractures. They considered 11 patients suitable for MISS technique. (42)

Carlos et al. recruited 17 patients between 2009 and 2011. They presented their clinical and radiological results after one year follow up (43)

Zhang et al. included 60 patients with Thoracolumbar fractures over a period of 3 years. Thirty of those patients were treated with percutaneous technique of spinal stabilization.(40)

Rajasekaran et al. presented two year follow up of 32 patients who were treated with an open technique for thoracolumbar fractures.(18)

2.2.8 Data Collection

Each patient was given a number to protect his/her identity. The data was collected in Microsoft Excel.

2.2.9 Consent

Consent was taken from the patient after explaining the details of the procedure in the language of his/her preference. None of the patients declined the minimally invasive method of fracture fixation. All patients were given the choice of alternative open technique of fracture fixation.

2.2.10 Neurological assessment

Each patient had a neurological assessment according to ASIA scoring system.

2.2.11 Radiology

On admission each patient had standard plain x-rays with Antero-Posterior (AP) & lateral views and a CT scan. These were used to classify the fracture and to measure the pre-operative fracture kyphosis angle.

Each patient had immediate postoperative plain x-rays (AP & Lateral views) to record the degree of correction of the kyphosis angle.

Plain x-rays (Standard AP & Lateral views) were obtained on each follow up visit and kyphosis angles were measured.

2.2.12 Follow Ups

Patients were regularly followed up in the clinic for wound check, clinical evaluation for pain and infections. Fracture kyphosis was measured using Cobb's method at a minimum of 12 months.

2.2.13 Ethics approval

The University of Witwatersrand Ethics Committee (medical) approved the application (certificate number: M121198) (see Appendix A).

2.2.14 Funding

Medtronic South Africa was chosen as the supplier of the implants for the study. It was agreed that implants would be supplied at the same price as those used for the conventional open technique. Approval had been obtained from the CEO office of Charlotte Maxeke Johannesburg Academic Hospital.

2.2.15 Statistical Measurements

Patient demographics were recorded and the data are presented in tables, pie & graphs. The fracture kyphotic angles were measured using Cobbs method and the change in angle was depicted in graphs and table.

Chapter 3

Results and Discussion

Twenty patients were available with a minimum of twelve months post-operatively for follow up. Of these patients, 14 were males and 6 were females (see Figure 3.1). The age of patients ranged from 16 years to 54 years (see Figure 3.2). The majority of the patients included in this study had an L1 fracture. The L1 vertebra was fractured in 11 patients. Six patients had a fracture of L2 and three patients had a fracture of T12 (See figure 3.3). According to the AO classification system, seven patients had C1 and seven patients had C2 type fractures. Five patients had a B2 fracture and one patient had a B1 type fracture (See figure 3.4). Patients available for follow up ranged from 12 months to 22 months (See figure 3.5). The distribution of the Cobb's angle is shown in Figure 3.6.

In two patients (Patient No: 4 and Patient No12), a fracture in the upper instrumented vertebra was not appreciated at the pre-operative x-rays analysis. This may have added to a loss of reduction that was more than expected. Despite the missed fracture, Patient No 4 lost 4 ° and Patient No 12 lost only 3 ° of correction at the last follow up.

In six patients, the Cobb's angle remained unchanged between the immediate post-operative x-rays and the final follow up. In 14 patients, loss of reduction between the immediate post-operative x-rays and final follow up ranged between one and six degrees. (See figure 3.7)

3.1 Gender Distribution

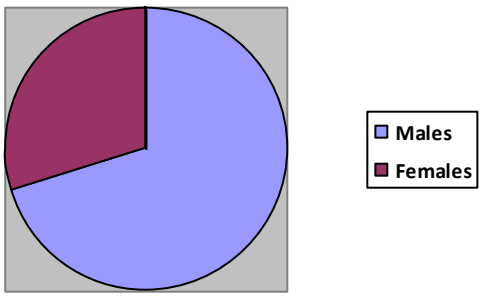

Figure 3.1: A pie chart showing gender distribution. Of the 20 patients, 14 were males and 6 were females.

3.2 Age Distribution in years

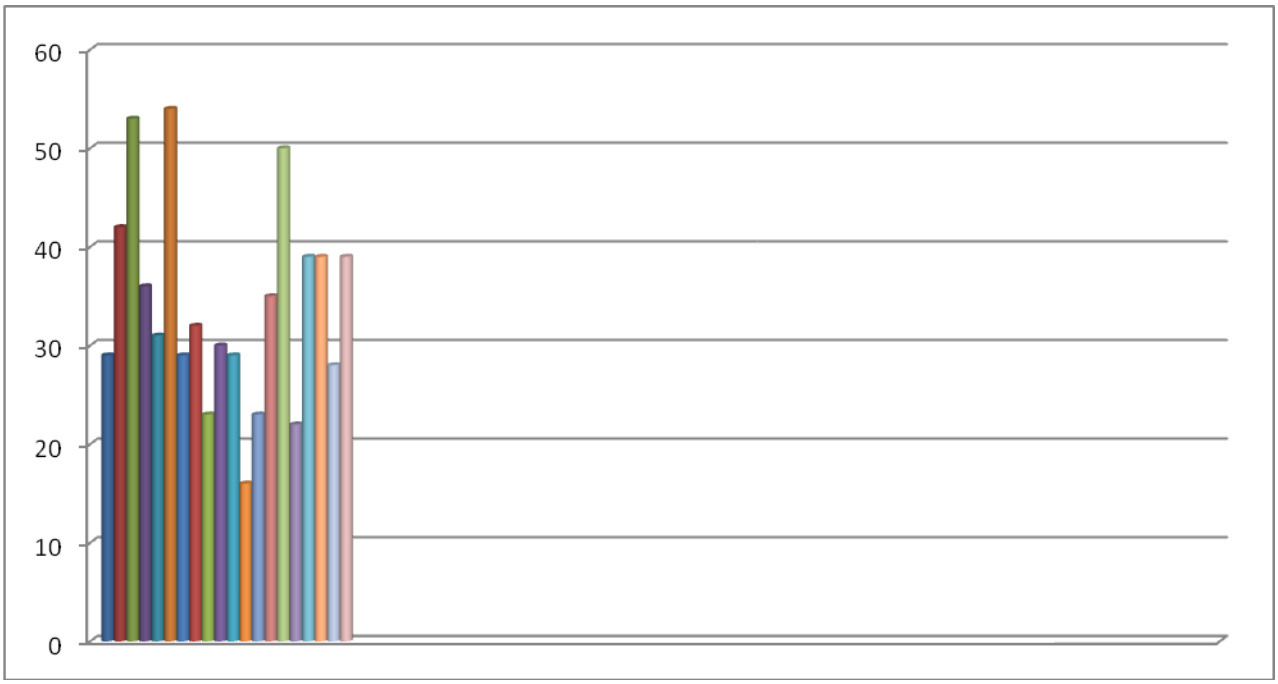

Figure 3.2: Age distribution. The youngest patient in the study was 16 years and the oldest patient was 54 years old.

3.3 Vertebra Distribution

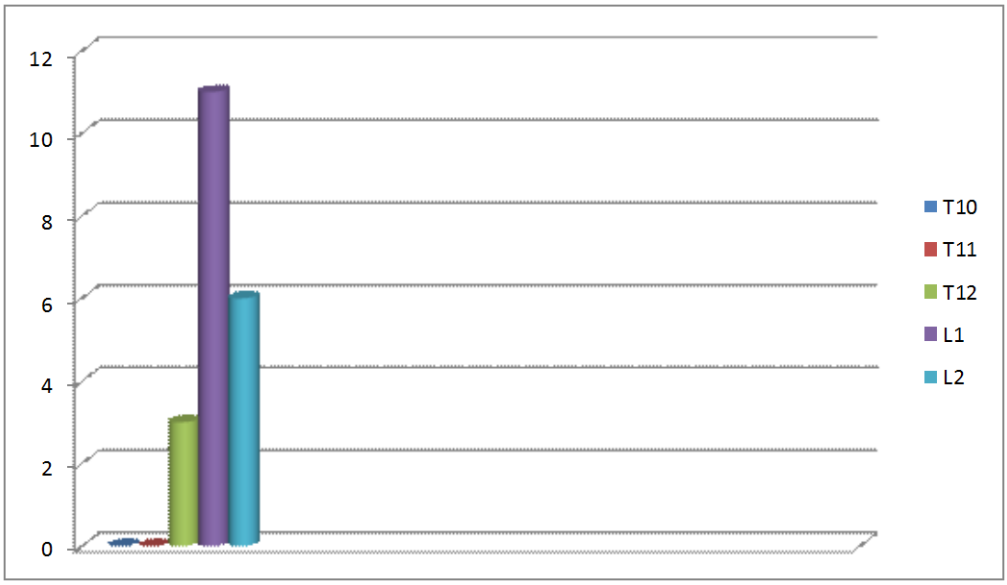

Figure 3.3: Distribution of vertebra involved. In this series, the majority of the patients had a fracture of L1. L1 vertebra was fractured in 11 patients, L2 in 6 patients and T12 was fractured in 3 patients. None of the patients had fracture of T10 and T11.

3.4 AO Fracture Types

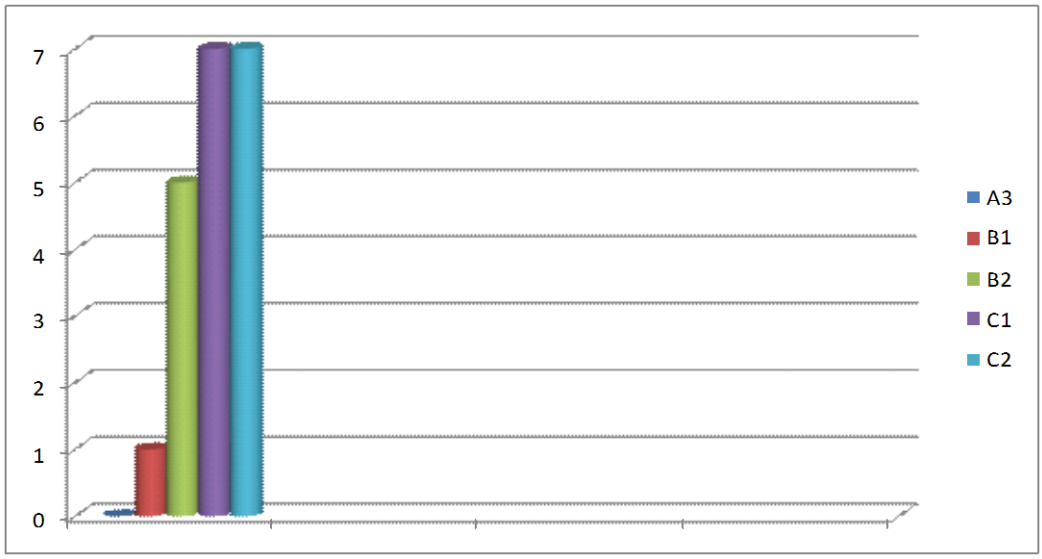

Figure 3.4: Fracture types according to AO classification. AO Type C1 and C2 counted for the majority of the fractures. There was one B1, five B2, seven C1 and seven C2 fractures.

3.5 Duration since Operation (months)

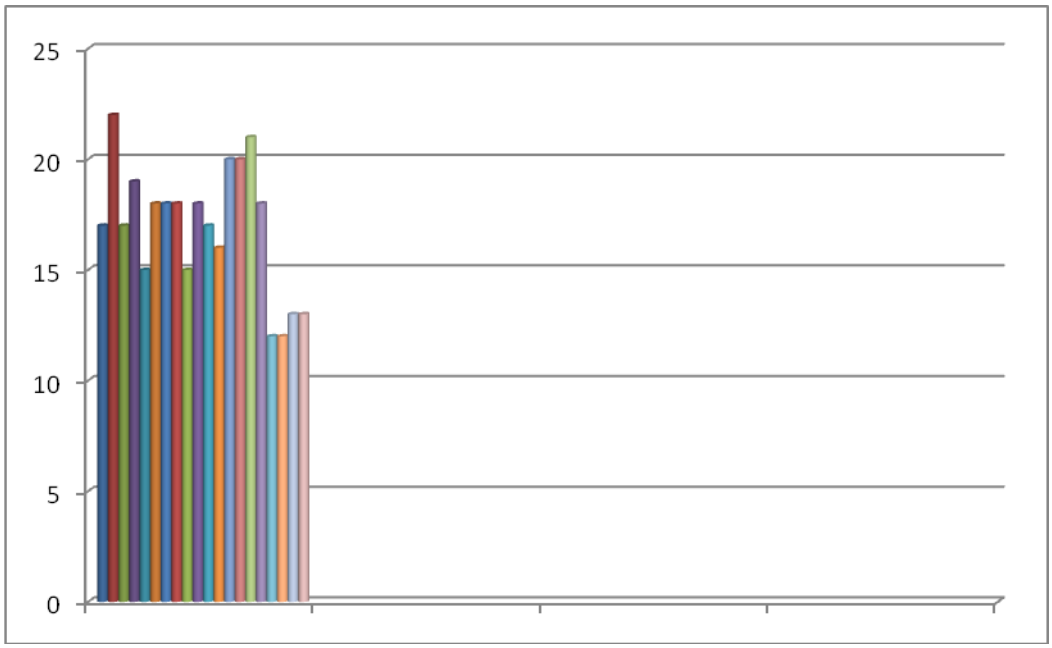

Figure 3.5: Duration of last follow up since the time of surgery (in months). The post –op follow up ranged from 12 months to 22 months.

3.6 Cobb's Angle of fracture kyphosis

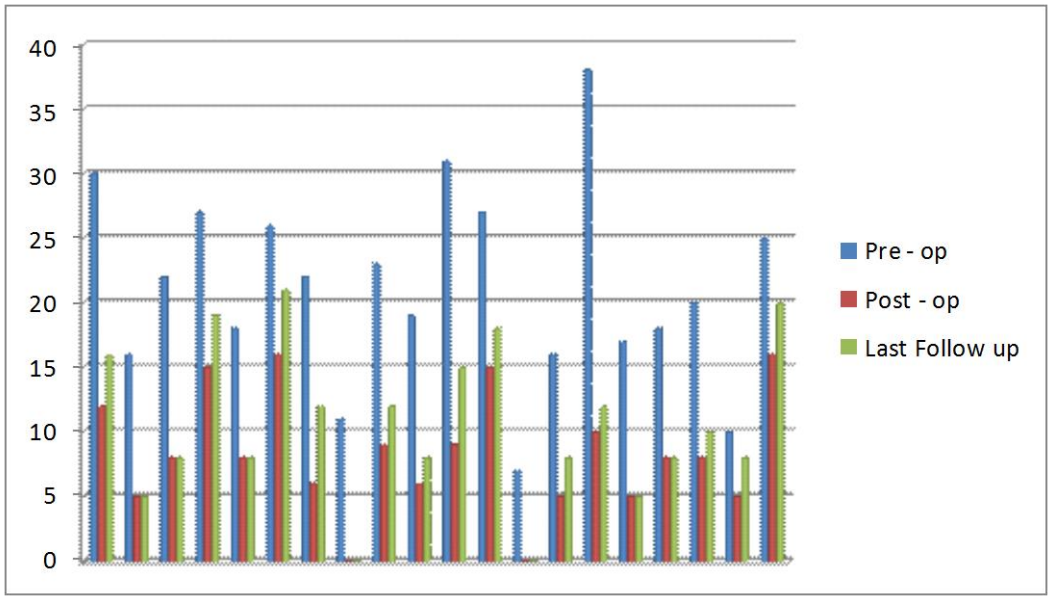

Figure 3.6: Distribution of Cobb's angle of fracture kyphosis. Patient No 8 and patient No 13 had immediate post – op and last follow up Cobb's angle of zero degrees.

Table 3.1: Cobb's Angle of fracture kyphosis.

Patient No	**Pre – op Cobbs' angle**	**Immediate Post – op Cobbs' angle**	**Cobbs' angle at final Follow up**	**Loss of correction**
1	30	12	16	4
2	16	5	5	0
3	22	8	8	0
4	27	15	19	4
5	18	8	8	0
6	26	16	21	5
7	22	6	12	6
8	11	0	0	0
9	23	9	12	3
10	19	6	8	2
11	31	9	15	6
12	27	15	18	3
13	7	0	0	0
14	16	5	8	3
15	38	10	12	2
16	17	5	5	0
17	18	8	9	1
18	20	8	10	2
19	10	5	8	3
20	25	16	20	4
Total	423	166	214	48
Mean	21.2	8.3	10.7	2.4

*Mean loss of fracture kyphosis was 2.4 degrees.

None of the patients in our series suffered deterioration of neurology. There were no Severe Adverse Events that necessitated re-operation in any of the patients.

3.7 Discussion

On analysis of the results, it is clear that over the period from the time of surgery to the last follow-up, there was some loss of reduction. As is evident from the table below some degrees of loss of correction is possible over time. However, the loss is within acceptable range when compared with studies conducted at other centers.

Table 3.2: A table comparing the loss of correction in the current study *versus* other studies.

Study	Pre – op Cobbs' Angle (Degrees)	Immediate post – op Cobb's Angle (Degrees)	Final Follow up Cobbs' Angle (Degrees)	Loss of Correction (Degrees)
Palmisani et al. (37)	12	5.9	8.7	2.8
Carlos et al. (43)	5.53	2.18	3.19	1.01
Proiettiet al. (44)	13.3	5.8	8	2.2
Rajasekaran et al. (18)	23	9.7	10.9	1.2
Current study	21.2	8.3	10.7	2.4

The rationale behind using the minimally invasive technique is to decrease the morbidity associated with the conventional open technique. MISS has become very popular among spine surgeons and patients. The fundamental premise of MISS is that it is better for the patient as it reduces the amount of tissue trauma associated with the use of the open technique. Certainly short-term results indicate benefits for the patient with MISS as it reduces the use of narcotics and hospital stay. There are many studies that have shown that open midline spine approaches are associated with paraspinal muscle damage.
(23, 25, 45-48)

Thoracolumbar junction (T10 – L2) is a transitional zone and deformities here are poorly tolerated. The spine in this area is neutral. A kyphosis of 20 degrees or more at this area is associated with poor functional tolerance. Thus deformities have serious long-term effects resulting in debilitating chronic pain. (1, 49)

Most of the unstable fractures (such as AO type A3, B and C) are treated surgically to prevent long term complications whereas stable fractures are treated successfully conservatively.

In cases where there is polytrauma, psychological disease, venous disease or previous deep venous thrombosis, obesity, and bronchopulmonary diseases, conservative treatment is not advisable.

Minimally invasive spine surgery is mainly reserved for those fractures where the anterior column is restored after reduction and is as such held by the instrumentation. A careful application of load sharing classification helps make the decision between posterior only, anterior only or a combined anterior-posterior approach. The pedicle screws and rods construct act mainly as an internal fixator.

Palmisani et al. reported loss of correction, which was observed during the follow-up for cases treated with multiaxial screws. They may have resulted due to these screws having slight movement, even after implantation, between the head and the arm of the screw. They recommended the use of monoaxial screws for this kind of surgery. (37)
Carlos et al. had similar experience with using polyaxial screws and agreed with Palmisani et al. in regard to loss of correction.(43)

MISS technique is often criticised for inability to achieve fusion. New techniques have described to achieve fusion. However, Wang et al. compared in their study, patients who underwent MISS technique. They divided their patients into two groups. Their study compared the treatment of burst fractures at the thoracolumbar junction using the percutaneous technique of fracture fixation. In one group, all fractures after surgical stabilization had additional fusion whereas, the second group had no fusion. Their results showed statistically no significant difference between the two groups in the long term. The "No Fusion" group showed a slight advantage both clinically and radiologically over the "fusion" group. This study strongly recommended the use of the minimally invasive technique for fracture fixation. (50)
The use of MISS for B1 needs careful consideration as this is a pure ligamentous that does better when fusion is added to the instrumentation.

Chapter 4

Conclusion

Minimally Invasive Spine surgery is certainly gaining popularity. It has been extensively used in degenerative spine surgery, spinal biopsy, kyphoplasty & vertebroplasty of osteoporotic fractures. Its application in trauma surgery is evolving. We have been heartened with our results with this technique. There is a learning curve and we strongly advise that the surgeons familiarize themselves with the technique by attending a cadaver workshop. In carefully selected cases this technique is a good alternative to the conventional open technique.

References

1. Buchowski JM, Bridwell KH, Lenke LG. Management of Posttraumatic Kyphosis After Thoracolumbar Injuries. Seminars in Spine Surgery.22(2):92-102.
2. Heinzelmann M, Wanner GA. Thoracolumbar Spinal Injuries. In: Boos N, Aebi M, editors. Spinal Disorders: Fundamentals of Diagnosis and Treatment. 1. Berlin Germany: Springer; 2008. p. 883-924.
3. Wood KB, Li W, Lebl DR, Ploumis A. Management of thoracolumbar spine fractures. The spine journal : official journal of the North American Spine Society. 2014;14(1):145-64.
4. Highsmith.J.M. 2016 [Available from: https://floridajointspine.com/vertebral-column-backbone-of-the-spine/.
5. Avanzi o, Chih LY, Meves R, Caffaro MFS, Rezende R, Castro CA. McCormack's Classsification and Kyphotic Deformity in Thoracolumbar Burst Fractures. Acta Ort Bras. 2007;15(5):251-3.
6. Sadiqi S, Verlaan JJ, Lehr AM, Chapman JR, Dvorak MF, Kandziora F, et al. Measurement of kyphosis and vertebral body height loss in traumatic spine fractures: an international study. European spine journal : official publication of the European Spine Society, the European Spinal Deformity Society, and the European Section of the Cervical Spine Research Society. 2016.
7. Jiang SD, Wu QZ, Lan SH, Dai LY. Reliability of the measurement of thoracolumbar burst fracture kyphosis with Cobb angle, Gardner angle, and sagittal index. Archives of orthopaedic and trauma surgery. 2012;132(2):221-5.
8. Arlet V, Orndorff DG, Jagannathan J, Dumont A. Reverse and pseudoreverse cortical sign in thoracolumbar burst fracture: radiologic description and distinction--a propos of three cases. European spine journal : official publication of the European Spine Society, the European Spinal Deformity Society, and the European Section of the Cervical Spine Research Society. 2009;18(2):282-7.
9. Gamanagatti S, Rathinam D, Rangarajan K, Kumar A, Farooque K, Sharma V. Imaging evaluation of traumatic thoracolumbar spine injuries: Radiological review. World journal of radiology. 2015;7(9):253-65.
10. Denis F. Spinal instability as defined by the three-column spine concept in acute spinal trauma. Clinical orthopaedics and related research. 1984(189):65-76.
11. McAfee PC, Yuan HA, Fredrickson BE, Lubicky JP. The value of computed tomography in thoracolumbar fractures. An analysis of one hundred consecutive cases and a new classification. The Journal of bone and joint surgery American volume. 1983;65(4):461-73.
12. McCormack T, Karaikovic E, Gaines RW. The load sharing classification of spine fractures. Spine. 1994;19(15):1741-4.
13. Parker JW, Lane JR, Karaikovic EE, Gaines RW. Successful short-segment instrumentation and fusion for thoracolumbar spine fractures: a consecutive 41/2-year series. Spine. 2000;25(9):1157-70.
14. Magerl F, Aebi M, Gertzbein SD, Harms J, Nazarian S. A comprehensive classification of thoracic and lumbar injuries. European spine journal : official publication of the European Spine Society, the European Spinal Deformity Society, and the European Section of the Cervical Spine Research Society. 1994;3(4):184-201.
15. Lee JY, Vaccaro AR, Lim MR, Oner FC, Hulbert RJ, Hedlund R, et al. Thoracolumbar injury classification and severity score: a new paradigm for the treatment of

thoracolumbar spine trauma. Journal of orthopaedic science : official journal of the Japanese Orthopaedic Association. 2005;10(6):671-5.
16. McLain RF. The biomechanics of long versus short fixation for thoracolumbar spine fractures. Spine. 2006;31(11 Suppl):S70-9; discussion S104.
17. Cho W, Cho SK, Wu C. The biomechanics of pedicle screw-based instrumentation. The Journal of bone and joint surgery British volume. 2010;92(8):1061-5.
18. Kanna RM, Shetty AP, Rajasekaran S. Posterior fixation including the fractured vertebra for severe unstable thoracolumbar fractures. The spine journal : official journal of the North American Spine Society. 2015;15(2):256-64.
19. Harms J, Stoltze D. The indications and principles of correction of post-traumatic deformities. European spine journal : official publication of the European Spine Society, the European Spinal Deformity Society, and the European Section of the Cervical Spine Research Society. 1992;1(3):142-51.
20. Zhang S, Thakur JD, Khan IS, Menger R, Kukreja S, Ahmed O, et al. Anterior stabilization for unstable traumatic thoracolumbar spine burst fractures. Clinical neurology and neurosurgery. 2015;130:86-90.
21. Xia Q, Xu BS, Zhang JD, Miao J, Li JG, Zhang XL, et al. Simultaneous combined anterior and posterior surgery for severe thoracolumbar fracture dislocations. Orthopaedic surgery. 2009;1(1):28-33.
22. Reinhold M, Knop C, Beisse R, Audige L, Kandziora F, Pizanis A, et al. Operative treatment of 733 patients with acute thoracolumbar spinal injuries: comprehensive results from the second, prospective, Internet-based multicenter study of the Spine Study Group of the German Association of Trauma Surgery. European spine journal : official publication of the European Spine Society, the European Spinal Deformity Society, and the European Section of the Cervical Spine Research Society. 2010;19(10):1657-76.
23. Hsieh PC, Koski TR, Sciubba DM, Moller DJ, O'Shaughnessy BA, Li KW, et al. Maximizing the potential of minimally invasive spine surgery in complex spinal disorders. Neurosurgical focus. 2008;25(2):E19.
24. Abdel-Ghany M.I YMA, Abdel-Salam A.I, Abdel-Aziz A, Al-Wardany M. Clinical Outcome Percutaneous Fixation in Symptomatic Lumbosacral Spondylolisthesis. Egypt J Neurol Psychiat Neurosurg. 2014;51(3):287-93.
25. Airaksinen O, Herno A, Kaukanen E, Saari T, Sihvonen T, Suomalainen O. Density of lumbar muscles 4 years after decompressive spinal surgery. European spine journal : official publication of the European Spine Society, the European Spinal Deformity Society, and the European Section of the Cervical Spine Research Society. 1996;5(3):193-7.
26. Tannous O, Shiu B, Koh EY. Minimally invasive spine surgery for thoracolumbar fractures: Damage-control spine stabilization. Seminars in Spine Surgery.25(3):170-5.
27. Giorgi H, Blondel B, Adetchessi T, Dufour H, Tropiano P, Fuentes S. Early percutaneous fixation of spinal thoracolumbar fractures in polytrauma patients. Orthopaedics & traumatology, surgery & research : OTSR. 2014;100(5):449-54.
28. Foley KT, Gupta SK, Justis JR, Sherman MC. Percutaneous pedicle screw fixation of the lumbar spine. Neurosurg Focus. 2001;10(4):E10.
29. Regev GJ, Lee YP, Taylor WR, Garfin SR, Kim CW. Nerve injury to the posterior rami medial branch during the insertion of pedicle screws: comparison of mini-open versus percutaneous pedicle screw insertion techniques. Spine (Phila Pa 1976). 2009;34(11):1239-42.
30. Kim DY, Lee SH, Chung SK, Lee HY. Comparison of multifidus muscle atrophy and trunk extension muscle strength: percutaneous versus open pedicle screw fixation. Spine (Phila Pa 1976). 2005;30(1):123-9.

31. Lehmann W, Ushmaev A, Ruecker A, Nuechtern J, Grossterlinden L, Begemann PG, et al. Comparison of open versus percutaneous pedicle screw insertion in a sheep model. Eur Spine J. 2008;17(6):857-63.
32. Wild MH, Glees M, Plieschnegger C, Wenda K. Five-year follow-up examination after purely minimally invasive posterior stabilization of thoracolumbar fractures: a comparison of minimally invasive percutaneously and conventionally open treated patients. Arch Orthop Trauma Surg. 2007;127(5):335-43.
33. Schmidt OI, Strasser S, Kaufmann V, Strasser E, Gahr RH. Role of early minimal-invasive spine fixation in acute thoracic and lumbar spine trauma. Indian J Orthop. 2007;41(4):374-80.
34. Merom L, Raz N, Hamud C, Weisz I, Hanani A. Minimally invasive burst fracture fixation in the thoracolumbar region. Orthopedics. 2009;32(4).
35. Ni WF, Huang YX, Chi YL, Xu HZ, Lin Y, Wang XY, et al. Percutaneous pedicle screw fixation for neurologic intact thoracolumbar burst fractures. J Spinal Disord Tech. 2010;23(8):530-7.
36. Korovessis P, Hadjipavlou A, Repantis T. Minimal invasive short posterior instrumentation plus balloon kyphoplasty with calcium phosphate for burst and severe compression lumbar fractures. Spine (Phila Pa 1976). 2008;33(6):658-67.
37. Palmisani M, Gasbarrini A, Brodano GB, De Iure F, Cappuccio M, Boriani L, et al. Minimally invasive percutaneous fixation in the treatment of thoracic and lumbar spine fractures. European spine journal : official publication of the European Spine Society, the European Spinal Deformity Society, and the European Section of the Cervical Spine Research Society. 2009;18 Suppl 1:71-4.
38. Bindal RK, Glaze S, Ognoskie M, Tunner V, Malone R, Ghosh S. Surgeon and patient radiation exposure in minimally invasive transforaminal lumbar interbody fusion. Journal of neurosurgery Spine. 2008;9(6):570-3.
39. Mroz TE, Abdullah KG, Steinmetz MP, Klineberg EO, Lieberman IH. Radiation exposure to the surgeon during percutaneous pedicle screw placement. Journal of spinal disorders & techniques. 2011;24(4):264-7.
40. Zhang W, Li H, Zhou Y, Wang J, Chu T, Zheng W, et al. Minimally Invasive Posterior Decompression Combined With Percutaneous Pedicle Screw Fixation for the Treatment of Thoracolumbar Fractures With Neurological Deficits: A Prospective Randomized Study Versus Traditional Open Posterior Surgery. Spine. 2016;41 Suppl 19:B23-b9.
41. Agrawal A. Simple Technique for Removing Broken Pedicular Screws. Malaysian Orthopaedic Journal. 2014;8(1):66-7.
42. Grossbach AJ, Dahdaleh NS, Abel TJ, Woods GD, Dlouhy BJ, Hitchon PW. Flexion-distraction injuries of the thoracolumbar spine: open fusion versus percutaneous pedicle screw fixation. Neurosurgical focus. 2013;35(2):E2.
43. Carlos FP, Anderson L, Mario BN, P. D, Marcello HNB, Helton LAD. Percutaneous fixation of fractures of the spine: 1 year c;inical and radiological follow up. Coluna/Columna vol13 no4 São Paulo. 2014;Vol 13:310 4.
44. Proietti L, Scaramuzzo L, Schiro GR, Sessa S, D'Aurizio G, Tamburrelli FC. Posterior percutaneous reduction and fixation of thoraco-lumbar burst fractures. Orthopaedics & traumatology, surgery & research : OTSR. 2014;100(5):455-60.
45. Weber BR, Grob D, Dvorak J, Muntener M. Posterior surgical approach to the lumbar spine and its effect on the multifidus muscle. Spine (Phila Pa 1976). 1997;22(15):1765-72.
46. Kawaguchi Y, Matsui H, Tsuji H. Back muscle injury after posterior lumbar spine surgery. Part 2: Histologic and histochemical analyses in humans. Spine (Phila Pa 1976). 1994;19(22):2598-602.

47. Styf JR, Willen J. The effects of external compression by three different retractors on pressure in the erector spine muscles during and after posterior lumbar spine surgery in humans. Spine (Phila Pa 1976). 1998;23(3):354-8.
48. Rantanen J, Hurme M, Falck B, Alaranta H, Nykvist F, Lehto M, et al. The lumbar multifidus muscle five years after surgery for a lumbar intervertebral disc herniation. Spine (Phila Pa 1976). 1993;18(5):568-74.
49. Munting E. Surgical treatment of post-traumatic kyphosis in the thoracolumbar spine: indications and technical aspects. European spine journal : official publication of the European Spine Society, the European Spinal Deformity Society, and the European Section of the Cervical Spine Research Society. 2010;19 Suppl 1:S69-73.
50. Wang ST, Ma HL, Liu CL, Yu WK, Chang MC, Chen TH. Is fusion necessary for surgically treated burst fractures of the thoracolumbar and lumbar spine?: a prospective, randomized study. Spine (Phila Pa 1976). 2006;31(23):2646-52; discussion 53.

Appendix A

Human Research Ethics Committee (Medical) Clearance Certificate

UNIVERSITY OF THE WITWATERSRAND, JOHANNESBURG
Division of the Deputy Registrar (Research)

HUMAN RESEARCH ETHICS COMMITTEE (MEDICAL)
R14/49 Dr Shahzad Ali Khan

CLEARANCE CERTIFICATE	**M121198**
PROJECT	Minimally Invasive Posterior Spinal Fusion for Unstable Thoracolumbar Spine Fractures (Resubmission M120474)
INVESTIGATORS	Dr Shahzad Ali Khan.
DEPARTMENT	Orthopaedic Surgery
DATE CONSIDERED	30/11/2012
DECISION OF THE COMMITTEE*	Approved unconditionally

Unless otherwise specified this ethical clearance is valid for 5 years and may be renewed upon application.

DATE 06/03/2013 **CHAIRPERSON** .....
(Professor PE Cleaton-Jones)

*Guidelines for written 'informed consent' attached where applicable
cc: Supervisor : Prof Mkhululi Lukhele

DECLARATION OF INVESTIGATOR(S)
To be completed in duplicate and **ONE COPY** returned to the Secretary at Room 10004, 10th Floor, Senate House, University.
I/We fully understand the conditions under which I am/we are authorized to carry out the abovementioned research and I/we guarantee to ensure compliance with these conditions. Should any departure to be contemplated from the research procedure as approved I/we undertake to resubmit the protocol to the Committee. **I agree to a completion of a yearly progress report.**

PLEASE QUOTE THE PROTOCOL NUMBER IN ALL ENQUIRIES...