

https://dspace.org/

The Use of a Bony Kernel for CT-Brain in Head Trauma

Bove, Michele

2017
https://hdl.handle.net/10539/24892

Downloaded from a DSpace repository. https://dspace.org/

The Use of a Bony Kernel for CT-Brain in Head Trauma

Michele Bove

0402590H

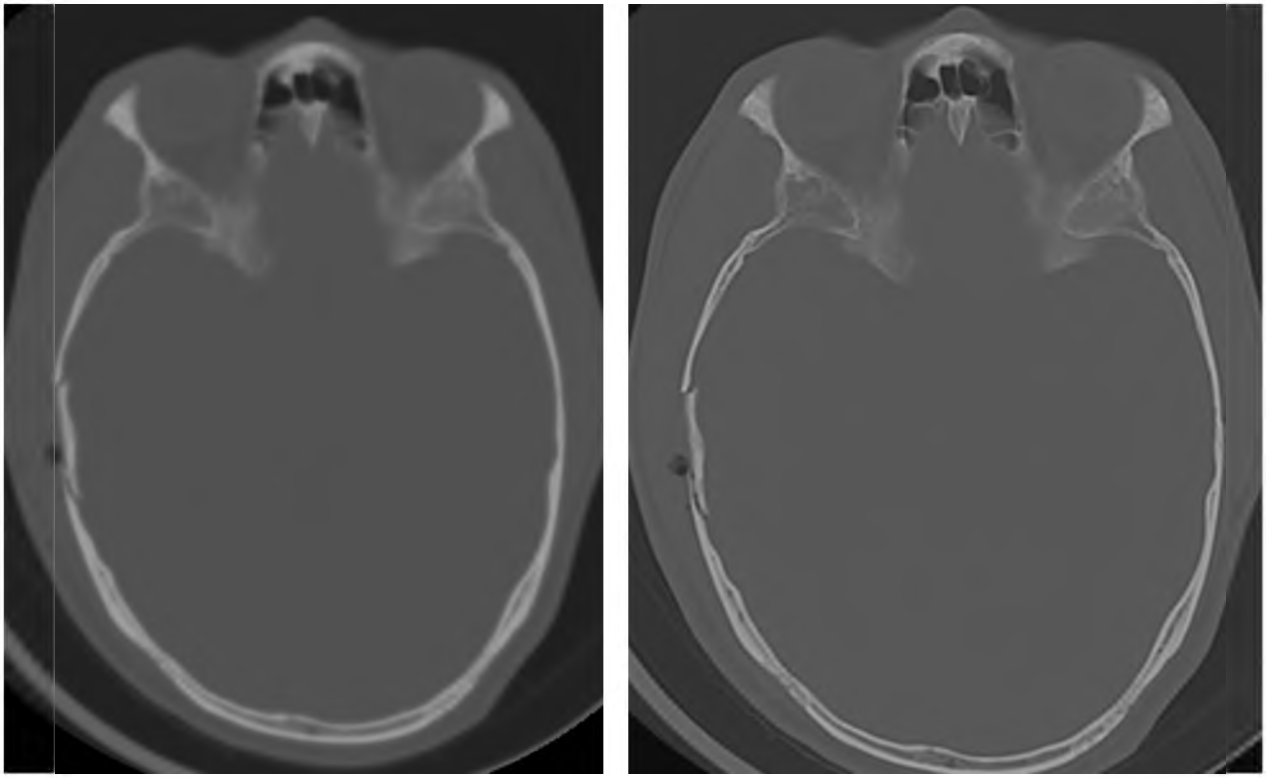

A research report submitted to the Faculty of Health Sciences, University of the Witwatersrand, Johannesburg, in partial fulfilment of the requirements for the degree of

Master of Medicine in Diagnostic Radiology

Johannesburg, 2017

Declaration

I, **Michele Bove**, declare that this research report is my own work. It is being submitted for the degree of MMed (RadD) at the University of the Witwatersrand, Johannesburg. It has not been submitted before for any degree or examination at this or any other University.

_____

DR MICHELE BOVE

On this 24th day of August 2017

To **Lucia**, may I hear that sarcasm and ridicule all the days of my life.

Publications and presentations

This work has never been published.

It has never been presented at a congress.

Abstract

Introduction:

Head trauma is a common cause of mortality and computed tomography of the brain (CT-Brain) remains the gold standard investigation for head injuries. Locally a bony kernel is reconstructed routinely in addition to a brain kernel on the assumption that it improves fracture detection. This additional kernel increases scanning time, reporting time and storage required on picture archiving and communication systems (PACS).

Aim:

The aim was to determine if a bony kernel is superior to a brain kernel for detecting fractures of the skull.

Objectives:

Objectives were to document patient and fracture characteristics seen locally, to identify patient and fracture characteristics that may require the use of a bony kernel and to determine if the bony kernel needs to be stored on a PACS.

Methods:

A retrospective study was undertaken. 216 CT-Brains were collected with associated demographic data and mechanisms of injury, attempting to match fracture cases to controls. Two expert readers in consensus formed a gold standard by evaluating all studies. The majority decision between three general readers was then used to test for a difference between the kernels for fracture detection.

Results:

There was no significant difference in the sensitivity or specificity between the two kernels (p=0.74 and 1.00). Interpersonal violence between adult males and pedestrian vehicle accidents in ambulant children were noted to be common indications for CT-Brain requests locally.

Conclusions:

The use of only the brain kernel is advised in adults, resulting in decreased scanner time, reporting time and required storage space on PACS. Further research is suggested to investigate its use in younger patients.

Acknowledgements

Professor Victor Mngomezulu: our influential mentor, thank you for opportunities, your informed suggestions, corrections and guidance.

Doctor Linda Tebogo Hlabangana: for stepping in to guide the construction of this work.

Expert Readers: for your efforts at reporting.

General Readers: for the hours put in reading the scans and then for doing it again.

Chris Hani Baragwanath Academic Hospital: for the thousands of lives saved and the subsequent medical education that follows.

CT Radiographers: for time taken teaching me how to reconstruct, retrieve and export studies.

Table of Contents

Declaration ii

Publications and presentations iv

Abstract v

Acknowledgements vi

List of Figures xi

List of Tables xii

List of Acronyms xiii

1. Introductory Chapter: 1

1.1. Introduction 1

1.1.1. Head trauma and CT-brain imaging 1

1.2. Literature Review 3

1.2.1. CT-Brain techniques used in skull fracture detection 3

1.2.1.1. Brain and bone kernel reconstruction: 3

1.2.1.2. Maximum Intensity Projection: 4

1.2.1.3. Unfolded Iso-surface Curved MIP CT: 5

1.2.1.4. Volume rendering, Surface Shaded Display and Multiplanar Rendering: 6

1.2.1.5. High-Resolution MPR CT: 7

1.2.1.6. Comparison of imaging techniques: 8

1.2.1.7. Miscellaneous factors affecting fracture detection: 9

1.2.2. Common head trauma skull fracture patterns 10

1.3. Problem Statement 13

1.4. Aim of the study 14

1.5. Objectives of the study 14

2. Central Chapter: 15

2.1. Materials and Methods 15

2.1.1. Study Sample 16

2.1.1.1. Inclusion Criteria 17

2.1.1.2. Exclusion Criteria 17

2.1.2. Data collection 17

2.1.3. Statistical analysis 18

2.1.3.1. Sample size calculation 18

2.1.4. Ethics 19

2.2. Results 20

2.2.1. Characteristics of the sample group 20

2.2.1.1. Age: 20

2.2.1.2. Gender: 21

2.2.1.3. Mechanism of injury: 21

2.2.1.4. Fracture type and location: 22

2.2.2. Inter-reader analysis 23

2.2.2.1. Inter-reader reliability for the detection of patients with fractures: 23

2.2.2.2. Inter-reader bias between the general readers: 24

2.2.2.3. Sensitivity and specificity of each reader for the detection of patients with fractures: 25

2.2.2.4. The difference in proportion of patients with fractures detected between kernels: 26
2.2.3. Comparing the use of both kernels using the majority decision data for the general readers 26
2.2.3.1. Sensitivity and specificity: 26
2.2.3.2. Comparing the correctly identified fracture group to the missed fracture group: 28
2.2.3.3. Findings of the risk factor analysis using the brain kernel: 30
2.2.3.4. Findings of the risk factor analysis using the bony kernel: 30
3. Concluding Chapter: 31
3.1. Discussion 31
3.1.1. Results in context 31
3.1.1.1. Head trauma in South Africa: 31
3.1.1.2. Fracture patterns noted from results: 32
3.1.1.3. Comparing the bony kernel to a brain kernel: 33
3.1.2. Limitations of the study 35
3.1.3. Current applications 36
3.1.4. Future applications 37
3.2. Conclusion 39
Appendix A: Ethics Clearance Certificate 40
Appendix B: Reporting Tick Sheet 41
Appendix C: Inter-reader bias between general readers cross-tabulation 42
4. References 43

List of Figures

Figure 1.1. a and b: Brain and bony kernel. 4

Figure 1.2. Unfolded Iso-surface Curved MIP. 6

Figure 1.3. a and b: HR-MPR Computed Tomography. 8

Figure 1.4. a, b and c: Frontal basal fracture types. 11

Figure 1.5. a,b,c and d: Sphenoid basal skull fracture types. 12

Figure 1.6. a and b: Temporal ridge basal skull fracture types. 12

Figure 2.1. Age distribution of the study group (in years). 20

Figure 2.2. Distribution of mechanisms of injury of the study population. 21

Figure 2.3. Fracture segment distribution in the patients with fractures. 22

Figure 2.4. Distribution of correctly identified fractured segments for both kernels. 28

List of Tables

Table 2.1. Percentages of fractures found for each general reader. 23

Table 2.2. The determination of agreement and bias between readers for the brain kernel. 24

Table 2.3. The determination of agreement and bias between readers for the bone kernel. 24

Table 2.4. Sensitivity and specificity of each reader for both kernels. 25

Table 2.5. Proportion of patients with fractures identified by each reader. 26

Table 2.6. Sensitivity and specificity of the brain and bony kernels. 26

Table 2.7. Distribution of correctly and incorrectly identified fracture segments. 27

Table 2.8. Comparison of patients with fractures correctly identified to those that had missed fractures. 29

List of Acronyms

CHBAH: Chris Hani Baragwanath Academic Hospital

CISS: Three Dimensional (3D) Constructive Interference in Steady State

CSF: Cerebrospinal Fluid

CT: Computed Tomography

DICOM: Digital Imaging and Communications in Medicine Format

HR-MPR: High-Resolution Multi-planar Rendering

JPEG: Joint Photographic Experts Group Format

MIP: Maximum Intensity Projection

MPR: Multi-planar Rendering

MRI: Magnetic Resonance Imaging

MVA: Motor Vehicle Accident

PACS: Picture Archiving and Communication System

PVA: Pedestrian Vehicle Accident

RSA: Republic of South Africa

SSD: Surface Shaded Display

USA: United States of America

VR: Volume Rendering

1. Introductory Chapter:

1.1. Introduction

1.1.1. Head trauma and CT-brain imaging

Head trauma is one of the leading causes of death, especially in young adults, with over 1.5 million people being affected in the USA alone each year (1). More than 50% of deaths related to trauma are as a result of head injury (2). Accidental head trauma in children is common, leading to fifty thousand hospital admissions per year in the USA (3). In South Africa, it is thought that the incidence of head trauma may be around 316 per 100000 persons per annum (4). Road traffic injuries, especially affecting children, and interpersonal violence have been identified as significant problems (4, 5). The mortality of South African head trauma patients may be higher than global comparisons (4).

Modern guidelines advise CT-Brain for most, if not all patients, who experience some form of head trauma, enabling rapid assessment of intracranial injuries and fracture extent (1, 3, 6, 7). Skull Radiographs are now obsolete in this setting (7, 8). CT-Brain is widely available, quick, cost-effective and has the ability to accommodate unstable patients (9). However, because the risk of fatality from low level falls in children has been shown to be less than one in a million, it can be extrapolated that many normal brains are scanned as a result of this accessibility (3).

The early and accurate identification of traumatic injury on CT-Brain is important, especially when patients show limited symptoms, as these patients have the best prognosis with early intervention (10). It has been shown that the presence of a skull

fracture is an independent risk factor for predicting intracranial haemorrhage, either at the time of the initial CT-Brain or later in the clinical course (8, 11).

Several complications of skull fractures have been recognised, most of which may be diagnosed on CT-Brain. These include: surface and brain haemorrhages, brain oedema, CSF leakage, infections, pneumocephalus, cranial nerve injuries, hearing loss, arterial dissection, dural venous sinus thrombosis and carotid-cavernous fistula. All of these complications may manifest at any time after the actual injury (1, 2, 12, 13). Most of these complications may only be recognised by their association with a specific skull fracture. Some patient categories may be more at risk of complications associated with skull fractures. Adolescents in particular are more prone to the development of intracranial haemorrhage in the presence of a skull fracture (11). Fractures with more displacement show higher rates of complications (2, 10, 13).

Skull fracture detection using CT-Brain has been assumed to be close to 100%, with no literature confirming this. The only attempts to provide information on the accuracy of CT-Brain at diagnosing skull fractures arise from forensic pathological studies comparing imaging to post mortem findings (1, 14). These studies have shown that it is difficult to diagnose non-displaced fractures of the skull (14). Specifically, the anterior and middle cranial fossa of the skull base, are the most difficult fractures to diagnose. In fact most fractures of the minor wing of sphenoid are missed on CT-Brain (14). These missed fractures were all confirmed at post mortem or surgery after CT-Brains were reported as normal using bony kernels by radiologists (13, 14). Having said this, the diagnosis of

hairline fractures in the absence of complications or clinical symptoms, may be superfluous, as the management may be conservative (14).

At many institutions a separate bony kernel is reconstructed in addition to a simple brain kernel with the hope of improving fracture detection. This extra data set increases reconstruction time and adds to the required hard disk storage space required on PACS. It also would increase reporting time, as the radiologist has to review an additional series of images. The aim of this study was to determine whether a bony kernel is superior to a brain kernel for diagnosing fractures of the skull in patients who have sustained head trauma.

1.2. Literature Review

1.2.1. CT-Brain techniques used in skull fracture detection

1.2.1.1. Brain and bone kernel reconstruction:

A bony kernel is an edge-sharpening CT reconstruction algorithm obtained form the raw data of a helical CT scan, which is designed to make bony structures appear sharper when viewed using a bony window. A more standard brain kernel is designed to smoothen tissue margins and allows for greater viewing variability when assessing multiple tissue types by making better use of a constellation of window settings (see figure 1.1) (6). A brain kernel is used to visualise brain in better detail but can be used to image bone by changing window settings. It is the standard method of CT-Brain reconstruction. When reconstructing a bony kernel visualisation of brain detail is traded-off in order to see bone to a better extent i.e. other tissue types will not be seen to an adequate extent when

changing from a bony window. Both kernels are stored as a separate stack of images on a PACS system (i.e. a bony kernel will double the volume of hard disk space needed for storage) (±500mb for both).

At many centres locally a bony kernel is reconstructed routinely in addition to a standard brain kernel on the assumption that it improves fracture detection. This additional kernel increases scanning time, reporting time and storage required on PACS.

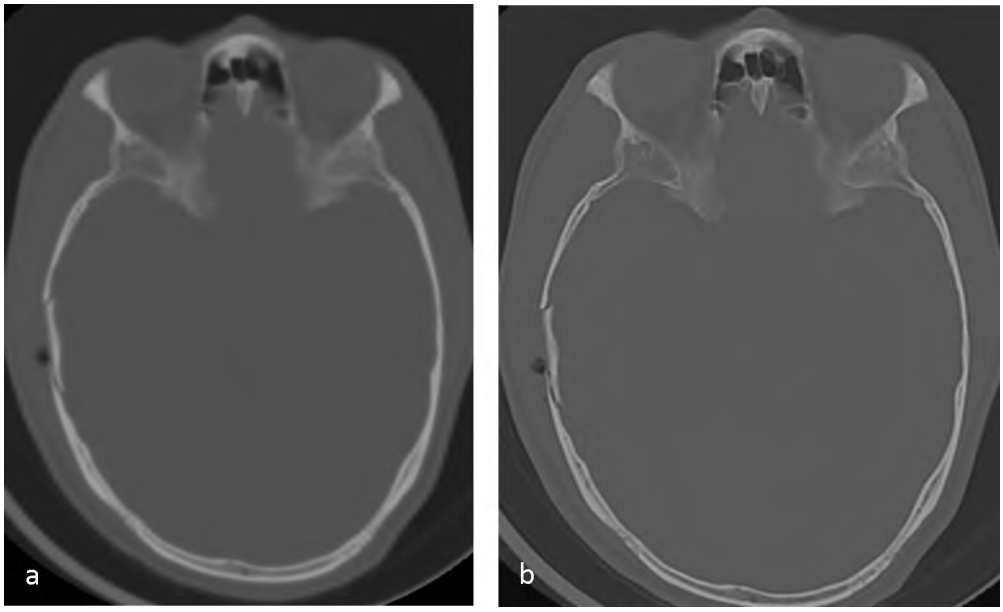

Figure 1.1. a and b: Brain and bony kernel.

An example of a brain kernel (1.1a left) and corresponding bony kernel (1.1b right) axial image showing a right sided parietal fracture. Note the ancillary finding of air in the scalp tissues.

1.2.1.2. Maximum Intensity Projection:

Maximum Intensity Projection (MIP) is a CT post-processing technique whereby all the structures with a relatively high attenuation are displayed as more prominent using thickened slices. It is typically used for the visualisation of vasculature, but recently has

been shown to have incidental applications for the identification of lung nodules and bony fractures (1, 15).

It has been shown that the viewing of MIP reconstructions, made available through advances in isotropic voxel CT imaging, have resulted in improved fracture detection rates (6, 9, 15). One study showed that when either inexperienced or experienced radiologists reported head trauma CT-Brains using new thick MIP reformats, as apposed to using only transverse sections, a significantly higher detection rate for fractures of the skull was seen (1). Experienced radiologists tend to detect more fractures when not making use of post processing tools such as Multi-planar Rendering (MPR), MIP or Volume Rendering as apposed to their more inexperienced counterparts (1, 9). Emergency medicine clinicians are much poorer at detecting fractures on radiographs and CT-Brains when compared to radiology residents and radiologists (7, 8, 10, 14). MIP reconstructions may better fracture detection rates among these clinicians.

1.2.1.3. Unfolded Iso-surface Curved MIP CT:

Unfolded Iso-surface Curved MIP CT reformat software, which creates a user friendly, thickened view of the outer table of the skull vault or base using just a few images or even only one image, has shown promise in closing the experience gap in fracture detection (see figure 1.2) (1, 9). This is probably because 3D images appear more descriptive and are more intuitive when presenting normal or pathological structures (9). It is difficult to compare studies directly because different gold standards are used but alternatives like Unfolded Iso-surface Curved MIP CT may be more worthwhile stored on

a PACS system than a full bony kernel reconstruction in addition to the original brain kernel.

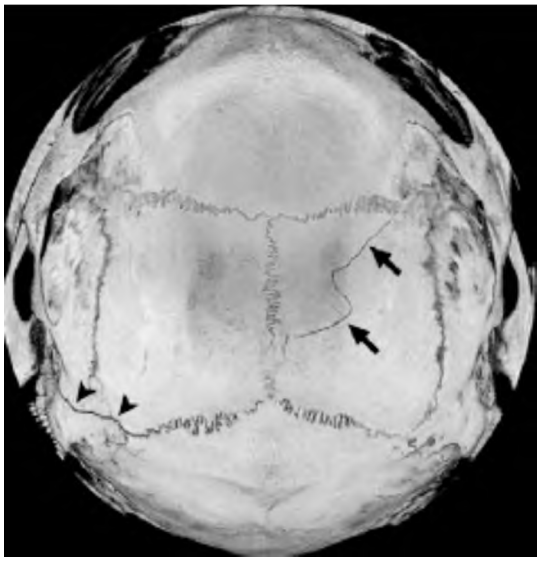

Figure 1.2. Unfolded Iso-surface Curved MIP.
An example of the image generated from the CT raw data (*adapted from Ringl, H. et. al.)* (1).

1.2.1.4. Volume rendering, Surface Shaded Display and Multiplanar Rendering:

Volume Rendering (VR), Surface Shaded Display (SSD) and Multiplanar Rendering (MPR) are usually only used in difficult cases when the fracture is not clearly seen on transverse sections due to its complexity (9). Visualisation of complex fractures may be improved, but the poor spatial resolution of CT comes into play when looking for small fractures using these techniques (1, 16). These techniques may seem time-consuming to the radiologist who has to wait for them to be rendered (1, 9). Reading of the transverse sections alone may provide limited diagnostic capability, probably because vascular channels and other misleading normal anatomical structures may mimic fractures in one plane (1, 6, 9, 14, 15). Beam hardening artefacts may also imitate fractures unless multiple planes are reviewed (10). An early study showed limited use for VR at identifying

skull base fractures (6). Having said this, it is however recommended that all fractures seen on VR reconstructions be confirmed to be present on the transverse sections as well (1, 6). VR is extremely useful in depicting the consequences of fractures of the middle and inner ear for ENT surgeons (14, 16).

1.2.1.5. High-Resolution MPR CT:

High-Resolution MPR CT (HR-MPR) techniques obtained after the suggestion of possible skull base fracture on ordinary CT-Brain (e.g. by observing ancillary findings) or by observing latent clinical signs, improve the diagnosis of skull base fractures (see figure 1.3) (1, 6, 17). It is suggested that HR-MPR reformats viewed with a bony kernel and a slice thickness of less than 1,25mm and some overlap yield the highest accuracy in detecting fractures of the skull base (6, 13, 17). Two studies confirm these findings: the one having a sample of more than 800 patients (6, 17). It must be noted that these studies are referring to thin slice and overlapping high resolution CT scans which require a completely new scan and cannot simply be reconstructed from standard CT-Brain raw data as opposed to a simple bony kernel.

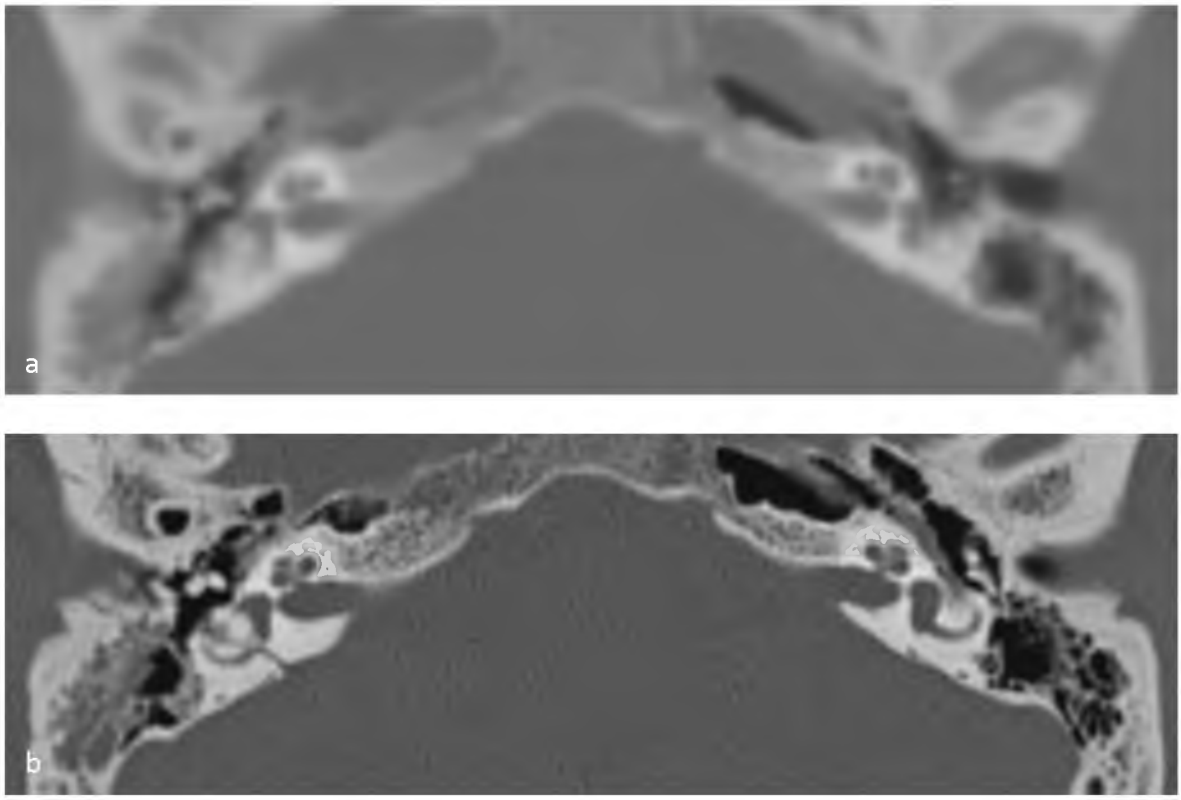

Figure 1.3. a and b: HR-MPR Computed Tomography.

An example of a patient with a transverse right temporal ridge fracture. Brain kernel image (1.3a top) from a standard CT-Brain barely allows for visualization of the fracture. The HR-MPR image (1.3b bottom) shows the obvious fracture extending into the right horizontal canal and facial nerve canal. The ossicles are also dislocated. This patient presented with facial nerve paralysis after head trauma.

1.2.1.6. Comparison of imaging techniques:

One study comparing MIP, VR and HR-MPR techniques for the diagnosis of skull fractures is available in the literature (6). This is a small study with a sample of only 130 cases. In this study the authors concluded that HR-MPR reconstructions read using MPR and MIP were more likely to identify fractures than solid or transparent VR images used in isolation.

Standard MIP and VR images have also been compared for fracture detection and it has been proven that MIP is the better option (1). However, MIP has shown limitation in the

assessment of the skull base with all its complex anatomy (1). HR-MPR reformats are the gold standard when looking at the skull base. Schuknecht *et al.* suggested the importance of very thin collimation (e.g. 0.75mm) HR-MPR scans of the anterior cranial fossa. These, again, are very different from bony kernel reconstructions of raw data from standard CT-Brains already undertaken for the general workup of head trauma (14, 18).

1.2.1.7. Miscellaneous factors affecting fracture detection:

Ancillary findings seen on CT-Brain assist in fracture detection. The most common examples are mastoid or para-nasal sinus air-space opacification seen with most temporal and anterior cranial fossa fractures respectively, and abnormal air seen adjacent to most skull vault fractures from associated scalp injuries (14). Conversely it has been suggested that the likelihood of a missed radiological finding on CT-Brain is higher if another unrelated major finding distracts the radiologist (10).

It has been suggested that increased time spent looking for fractures may assist in their improved detection and that radiologists may not be investing enough time in fracture detection (6). There is no significant discrepancy seen between senior radiology residents and consultant neuroradiologists in the interpretation of posttraumatic CT-Brains (2).

Factors affecting the storage of CT-Brain images after their acquisition may affect fracture detection. Compression of CT images on a PACS system using "Lossy 60:1" compression in order to save on permanent storage space has been proven to reduce the ability of radiologists to diagnose fractures (19). Image compression using "Lossy 30:1" or "Lossless" protocols do not affect fracture detection. Given the volume of data created in

medical imaging today these storage formats are helpful. CHBAH does not make use of "Lossy 30:1" or "Lossless" image compression. Alternative methods are needed to save on permanent storage space. Compression of studies used to visualise fractures should never be done by converting them into JPEG format as the loss of high-frequency information will degrade the study (19).

The increasing volume of data generated by medical imaging is already a problem in the first world (19). Some PACS vendors also charge on a per series or case basis. Therefore, it can be extrapolated that strict protocols are needed in our setting to determine exactly which series are most necessary to store on PACS.

1.2.2. Common head trauma skull fracture patterns

The direction of the transmitted force determines the complexity and nature of a skull fracture. However, a few common fracture tracts have been identified (12).

Fronto-basal fractures of the skull base occur in 3 or 4 variations: an isolated linear anterior skull base fracture along the lateral margin of the cribriform plate (type 1), a linear fracture extending anteriorly into the fronto-nasal sinuses (type 2), and those where there is comminution and involvement of the orbital roof (type 3) as demonstrated in figure 1.4 (12, 13). Involvement of the cribriform plate is important as this related to CSF leakage and pneumocephalus (12, 13). Identification of this fracture results in earlier primary surgical repair of dural tears reducing morbidity and mortality (12, 13). Fractures of the orbital roof are associated with numerous facial and frontal bone fractures (14).

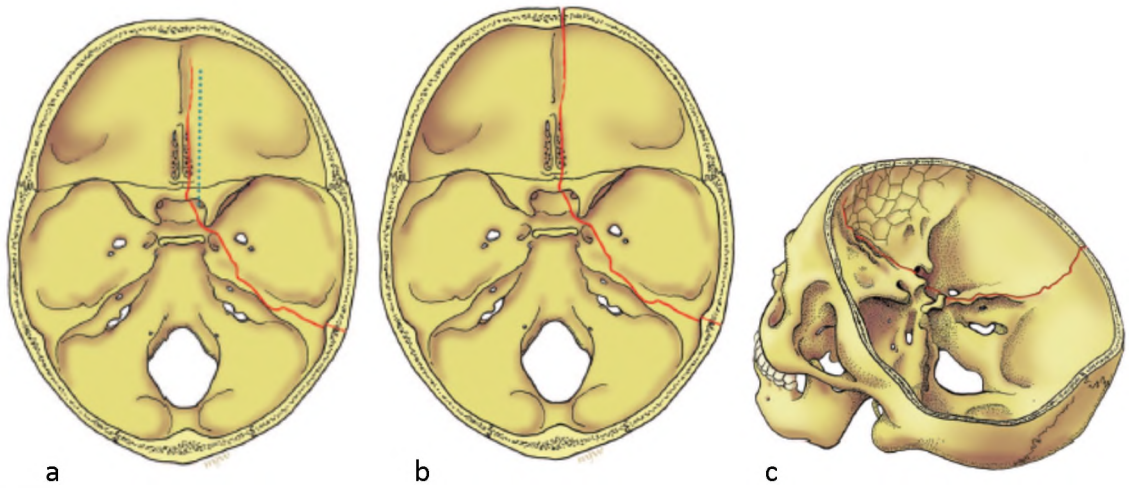

Figure 1.4. a, b and c: Frontal basal fracture types.

Diagram of the three major frontal basal fracture types: type 1 (1.4a left), type 2 (1.4b centre) and type 3 (1.4c right) *(adapted from Manson P.N. et. al.)* (12).

The temporal bone and the sphenoid bone are commonly fractured simultaneously and when this occurs bilaterally one can assume severe head trauma and subsequent injuries (2, 14). Unfortunately, it has been shown that these fractures are commonly missed even when using HR-MPR bony reformats (6). Sphenoid fractures through the pituitary fossa may be divided into an anterior transverse, a lateral frontal diagonal, a posterior transverse or a mastoid diagonal pattern as shown in figure 1.5 (2).

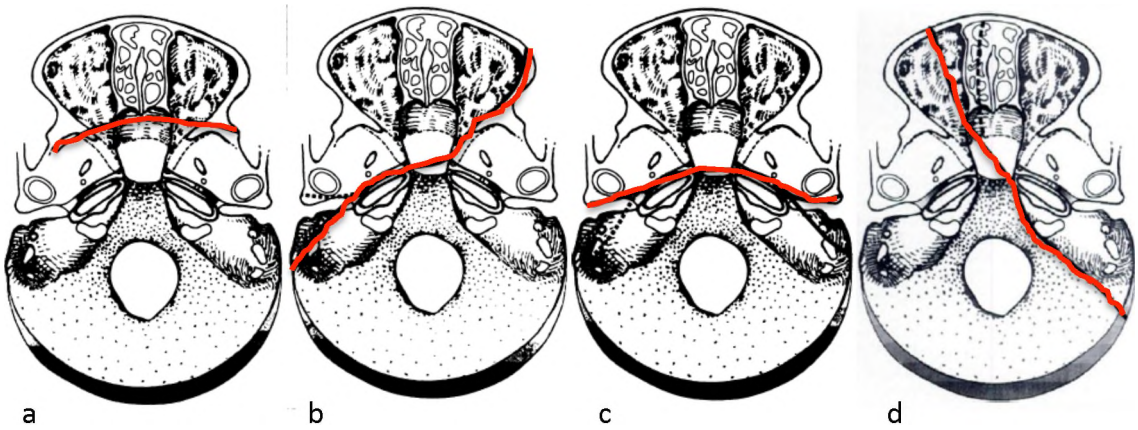

Figure 1.5. a,b,c and d: Sphenoid basal skull fracture types.

Diagram showing the anterior transverse (1.5a left), lateral frontal diagonal (1.5b left, centre), posterior transverse (1.5c right, centre) and mastoid diagonal (1.5d right) fracture types *(adapted from West, O.C. et. al.)* (2).

Temporal bone fractures are either longitudinal, transverse or mixed depending on their orientation in relations to the longitudinal axis of the petrous ridge. Transverse fractures are associated with sensory-neural hearing loss and longitudinal fractures with conductive hearing loss (see figure 1.6) (16).

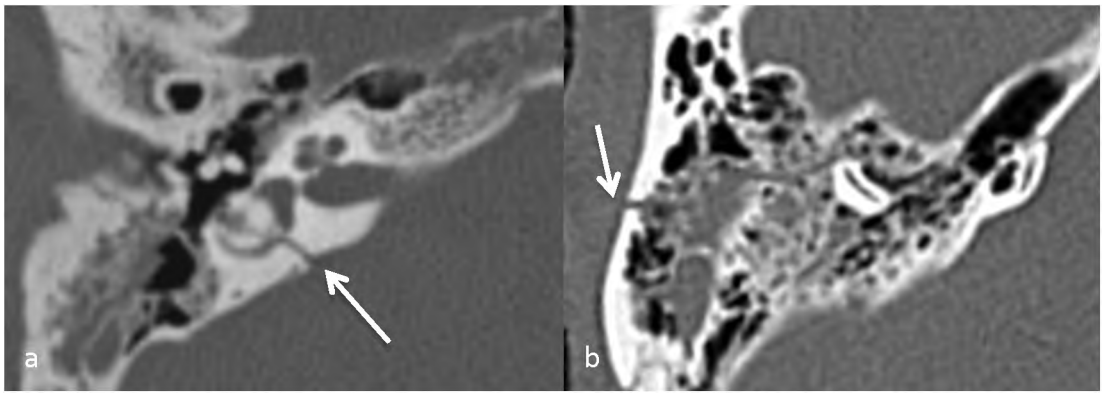

Figure 1.6. a and b: Temporal ridge basal skull fracture types.

Examples of a transverse (1.6a left) and longitudinal (1.6b right) basal temporal bone fracture. Note their orientation to the petrous ridge.

***

1.3. Problem Statement

The additional reconstruction time required to reconstruct a bony kernel may contribute to delayed patient throughput in a radiology department. Extra time spend reviewing the additional image series by the radiologist results in decreased patient throughput. The addition of an extra series data set is an additional cost when stored on a PACS system. If a bony kernel is not superior to a brain kernel for the identification of fractures then it can be assumed that not routinely reconstructing a bony kernel will result increased patient through-put, decreased reporting time and increased cost effectiveness in a radiology department.

After determining the extent to which trauma affects our population, understanding the associations which go together with most skull fractures, after venturing into modern alternatives for fracture detection and by knowing the common fracture patterns the researcher has designed this study with the objectives defined below.

1.4. Aim of the study

The aim of this study is:

1. To determine whether a bony kernel is superior to a brain kernel for diagnosing fractures of the skull in patients who have sustained head trauma.

1.5. Objectives of the study

The objectives of this study are:

1. To document characteristics of patients who sustain head trauma in South Africa by documenting the age, gender and mechanism of injury sustained by the sample and control groups.
2. To characterize fracture locations, segments and characteristics seen at CHBAH.
3. To identify fracture types and patient factors which may benefit from the use of a bony kernel over a brain kernel for diagnosis.
4. To determine if only the brain kernel can be stored on a PACS system in an attempt to improve cost-effectiveness.
5. To determine if only a brain kernel may be interpreted by a radiologist with a view to the shortening of reporting times.

2. Central Chapter:

2.1. Materials and Methods

A retrospective comparative study was undertaken at Chris Hani Baragwanath Academic Hospital (CHBAH) between the 01 Jan 2013 and 31 Dec 2014. Random reports of CT-Brains for head trauma were reviewed with the view of collecting case controls with no fractures and cases reported with skull fractures. The patient name, hospital number, age, gender, mechanism of injury as well as the date of study were recorded.

These studies were then retrieved from the PACS system if they contained both a brain and bony kernel. All cases were exported in DICOM format onto an external hard drive and then imported into "OsiriX DICOM Viewer Version 5.8.5" which was utilized to make all studies anonymous through the allocation of a random study number. All studies were also read using this DICOM viewer.

The CT Scanner used at CHBAH was a:

- Philips Ingenuity 128-slice CT Scanner: 70cm aperture, 80/100/120/140KVp settings, 20–665mA range, and solid-state array detector with 128 detectors.

The scanning protocol parameters used for CT-Brain in head trauma are:

- 120KVp and 300mAs, reconstructed into both a brain and bony kernel using a slice thickness of ±1.0mm at intervals of ±0.5mm. Rotation time is set at 1.0s with a FOV of 140,0.

Two "Expert Readers" were used to form the gold standard by finding a consensus. Both were senior radiologists with more than five years experience. Each CT-brain was reported using a "Reporting Tick Sheet" that was developed by the principal investigator and supervisor (Appendix B). The expert readers were allowed to view both the brain and bony kernel, making use of all available post processing tools including window manipulation, MIP, MPR and VR. Cases where a consensus was not reached were resolved by facilitated discussion between the two readers.

Three "General Readers" were used in the study. These comprised a consultant radiologist with more than five years post qualification experience, a senior registrar with more than two years experience and a junior registrar with less than one year of experience. All studies were read using only transverse sections at a window level of 350 and a width of 2700 Hounsfield Units (HU). The use of MIP, MPR and VR tools was prohibited. First the brain kernel was read. One month later the bony kernel was read. The majority decision between the three readers was taken as the result used for statistical comparisons.

2.1.1. Study Sample

The study population comprised 216 selected patients who underwent CT-Brain for head trauma at CHBAH between the 01 Jan 2013 and 31 Dec 2014. According to the Expert Reader consensus 46.8% (n=101) of these cases were deemed to actually have one or more fractures despite aiming for a case:control ratio of 1:1.

2.1.1.1. Inclusion Criteria

- The indication for CT-Brain had to be for head trauma.
- Both a brain and bony kernel reconstructed from the same raw data in the same sitting had to be available.

2.1.1.2. Exclusion Criteria

- All CT-Brains containing more than three non-congruent fractures.

2.1.2. Data collection

All data were collected from all readers using a "Reporting Tick Sheet" (Appendix B) for each case. The parameters recorded were those in the "Reporting Tick Sheet." The skull was divided into a skull base and skull vault as per standard anatomy. Each fracture was described in terms of bony segments defined by the anatomical borders of the bones of the skull. Although tick boxes were used, readers were asked to depict each fracture in order to assist with interpretation. If two bony segments that were not adjacent to one another were fractured then these counted as two separate fractures i.e. a congruent fracture line traversing more than one contiguous bony segment was judged to be one fracture.

The expert reader consensus formed the descriptive objective of this study and the gold standard. Expert consensus was used to identify if the fractures were displaced or not. Displacement was not tested between the three general readers. No specific definition of displacement was provided to the readers.

The general readers took part in two sets of readings. The first was for the brain kernel and the second was for the bone kernel. These were taken one month apart and studies were randomized once again to ensure the brain kernel did not affect the bone kernel reading. General readers were prohibited from discussing cases and all the readers were blinded to the identity of the other readers. This was undertaken to prevent bias.

All data were captured into a "Report Analysis Spreadsheet" whilst making use of anonymously allocated study numbers. All descriptive interpretations and statistical analyses were then drawn from this spreadsheet.

2.1.3. Statistical analysis

Data analysis was carried out with the assistance of a statistician. The statistical software used was SAS (SAS Institute Inc., SAS Software, version 9.3 for Windows, Cary, NC, USA: SAS Institute Inc. (2002-2010)). The 5% level of significance was used throughout, unless otherwise specified. In all cases the majority decision between the general readers was compared to the gold standard provided by consensus between the expert readers.

2.1.3.1. Sample size calculation

Sample size was calculated based on the primary research objective which was to compare the proportion of correctly identified fracture cases between the brain and bony kernels. McNemar's test was utilized, using a 5% level of significance and a power of 80%. In a study by Ringl *et al.* published in a core radiological journal the investigators determined that when using only transverse sections, experienced readers could detect 70% of fractures, whilst when using a new MIP technique, 87% of fractures could be

detected (1). Based on this information, the sample size for patients with fractures was calculated to be 93 and given the aim for equal matching of controls; the required sample size was 186. The actual sample size of 216 was thus adequate.

2.1.4. Ethics

Written consent for this study was obtained from the Head of the Department of Radiology at CHBAH. The CHBAH Medical Review Board granted approval for this study. Approval was granted for this study from the Medical Health Research Ethics Committee of the University of the Witwatersrand (Appendix A).

All investigations were originally undertaken for clinical indications. No additional radiation exposure to patients or staff took place. No additional departmental or governmental expenditure took place as a result of this study. Patient anonymity was maintained at all times through the use of allocated study numbers. The decipher code to these was stored on a password protected computer only accessible to the investigator.

2.2. Results

2.2.1. Characteristics of the sample group

A total of 216 patients were included in the study. Of these patients 46.8% (n=101) were deemed to have one or more fractures by the expert readers.

2.2.1.1. Age:

The mean age of the patients was 29.5 years (σ =12.9 years). Their ages ranged from 6 months to 80 years. Age could not be determined in 4.6% of cases. The distribution of ages is shown in figure 2.1.

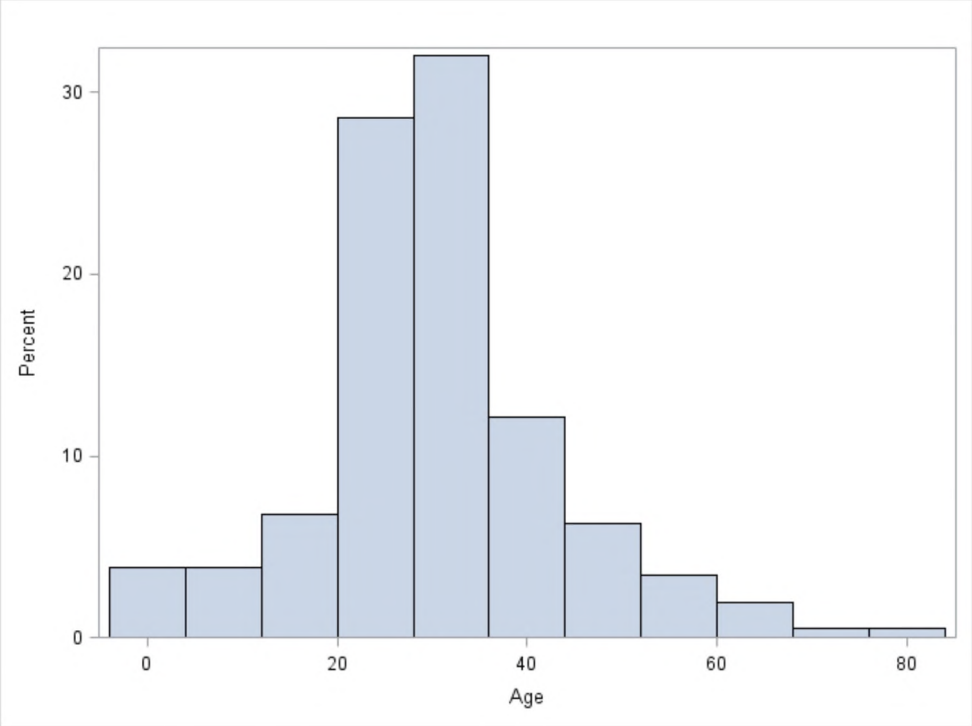

Figure 2.1. Age distribution of the study group (in years).

2.2.1.2. Gender:

Eighty-four percent (84.3%, n=182) of the patients were male, whilst only 15.3% (n=33) were female. In 0.5% of cases the age could not be determined. Ninety-one percent (90,9%, 101 of 111) of the patients who had a mechanism of assault were male.

2.2.1.3. Mechanism of injury:

Assault was shown to be the most common mechanism of injury at 51.9% (n=112). This was followed by motor vehicle accidents (MVA) at 16.7% (n=36) and pedestrian vehicle accidents at 16.2% (n=35). Gunshot wounds were an uncommon cause of head injury as demonstrated in figure 2.2. Pedestrian vehicle accidents (PVA) followed by falls from height were the most common indications for CT-Brain in children under 16 years of age.

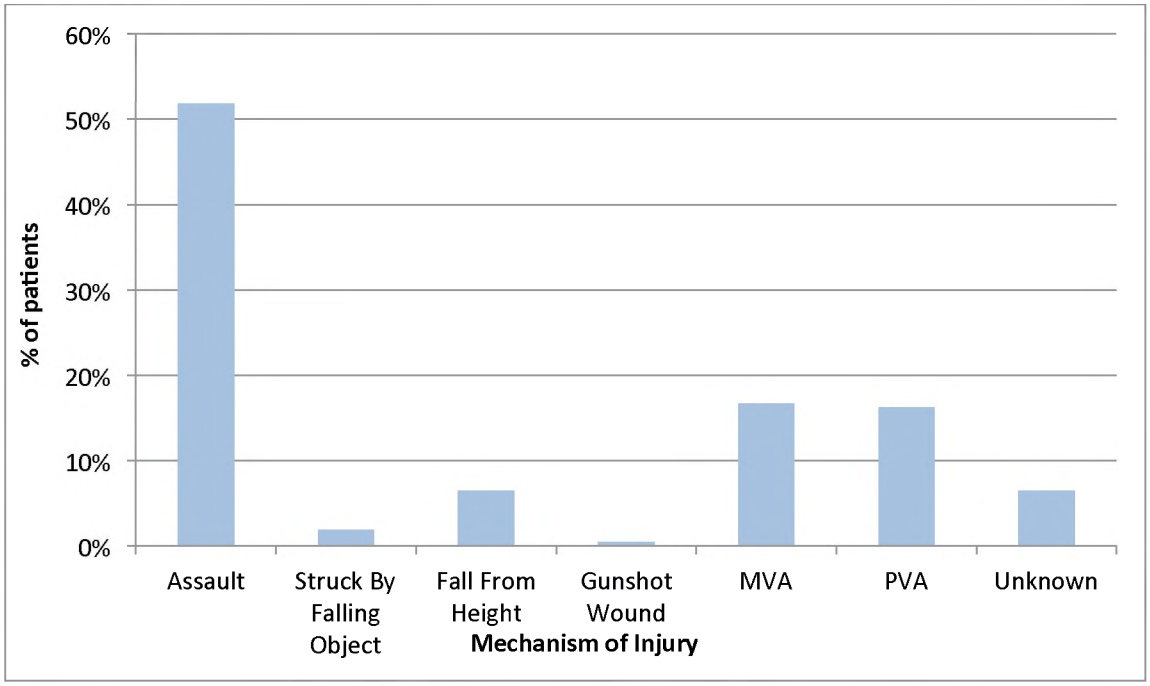

Figure 2.2. Distribution of mechanisms of injury of the study population.

2.2.1.4. Fracture type and location:

Forty-seven percent (46.8%, n=101) of the patients were deemed to have one or more fractures. Of these 101 patients, 72.3% (n=73) had a single fracture, whiles 26.7% (n=27) and 1.0% (n=1) had two and three fractures, respectively. Fifty percent (49.5%, n=50) of the patients had displaced fractures. The most commonly fractured segment was the frontal skull vault (59.4%; n=60), followed by the parietal skull vault (44.6%; n=45). The frontal segment was the most common fracture location in the skull base (31.7% or n=32 patients) followed by very similar numbers shared between the temporal, sphenoid and ethmoid skull base (n=19, 18 and 16 patients respectively). The basal occipital bone was the least likely bone to fracture in this patient sample (figure 2.3).

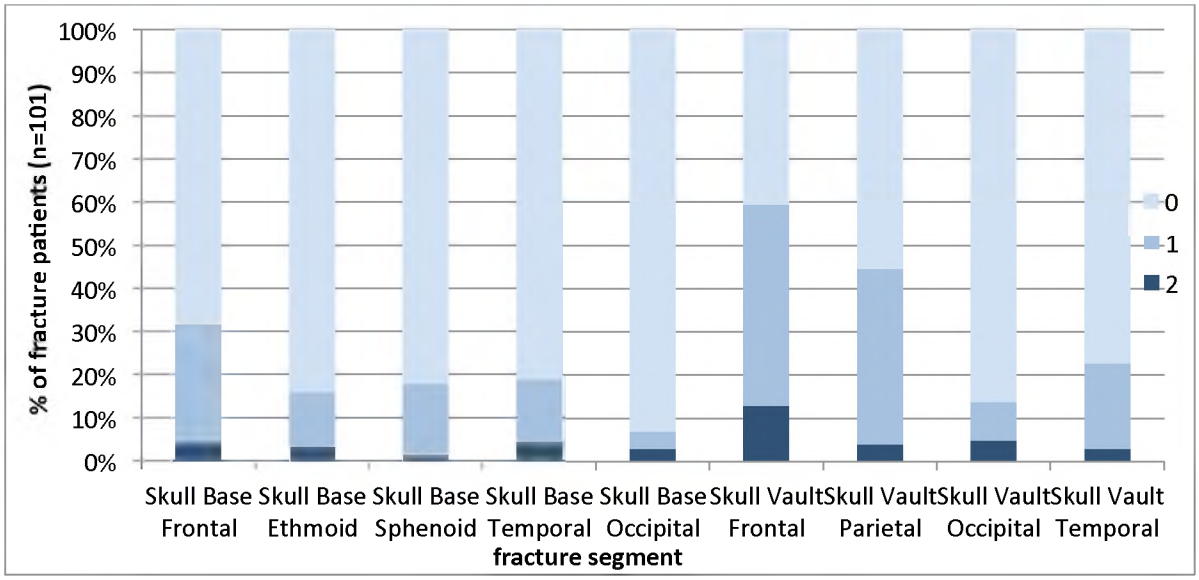

Figure 2.3. Fracture segment distribution in the patients with fractures.

2.2.2. Inter-reader analysis

2.2.2.1. Inter-reader reliability for the detection of patients with fractures:

The percentage of cases with fractures identified by each general reader is shown below in table 2.1.

Table 2.1. Percentages of fractures found for each general reader.

Reader:	Percentage of patients with fractures (%):	
	Brain kernel:	Bony kernel:
1	42.1	44.0
2	53.7	52.8
3	44.9	44.0

Reader 2 stood out as having identified a higher proportion of patients as having one or more fractures. To determine the agreement between readers, the Fleiss' Kappa for multiple readers with a binary outcome was determined:

$$\hat{\mathrm{K}}_f = 1 - \frac{\sum_{i=1}^{k} y_i(n_i - y_i)}{kn(n-1)\hat{\pi}(1-\hat{\pi})}$$

Where:
k = number of subjects (=216)
y_i = number of positive readings for subject *i*
n_i = number of readings for subject *i* (=3)
$\hat{\pi} = \sum_{i=1}^{k} \frac{y_i}{nk}$ (20)

The raw agreement (i.e. that all three scored 0 or all three scored 1) between all three readers was 75.9% and 86.5% for the brain and bony kernels respectively. The kappa chance-corrected measure of agreement was 0.68 and 0.83, which corresponded to 'substantial' and ' almost perfect' agreement for the brain and bony kernels respectively (21).

2.2.2.2. Inter-reader bias between the general readers:

Cochran's Q statistic was used to test for inter-reader bias among the three general readers. This was significant ($p<0.0001$) for both kernels, indicating significant bias between the readers in determining the presence or absence of fractures. In order to investigate these findings, the agreement and bias between each pair of readers was reviewed to find reasons for the low kappa and significant bias between the three readers. For each pair of readers, the cross-tabulation of their readings (Appendix C), the chance-corrected kappa and the test of inter-reader bias (McNemar's test for two readers) were determined as shown tables 2.2 and 2.3.

Table 2.2. The determination of agreement and bias between readers for the brain kernel.

Brain kernel:			
Readers:	**Kappa:**	**Interpretation of kappa:**	***p-value for Cochrane's Q / McNemar's test:***
Overall	0.68	Substantial agreement	<0.0001
1 vs 2	0.53	Moderate agreement	0.0005
1 vs 3	0.87	Almost perfect agreement	0.11
2 vs 3	0.64	Substantial agreement	0.0023

Table 2.3. The determination of agreement and bias between readers for the bone kernel.

Bony kernel:			
Readers:	**Kappa:**	**Interpretation of kappa:**	***p-value for Cochrane's Q / McNemar's test:***
Overall	0.83	Almost perfect agreement	<0.0001
1 vs 2	0.73	Substantial agreement	0.0004
1 vs 3	1.00	Perfect agreement	n/a
2 vs 3	0.73	Substantial agreement	0.0004

From these two tables it is shown that for both kernels there was significant bias, and low agreement, between readers 1 and 2, and 3 and 2. Readers 1 and 3 agreed well and there was no significant bias in their relative ratings. For both kernels, the cross-

tabulations showed that reader 2 showed a tendency to give more positive (presence of fracture) ratings than readers 1 and 3. Thus there were clear differences between readers 1 and 3 on the one hand, and reader 2 on the other hand. However, these differences were unlikely to have had much effect on the majority decision data.

2.2.2.3. Sensitivity and specificity of each reader for the detection of patients with fractures:

Some significant differences were found between the three readers using McNemar's test as shown in table 2.4.

Table 2.4. Sensitivity and specificity of each reader for both kernels.

Brain kernel:				
Reader:	Sensitivity (%):		Specificity (%):	
	Estimate:	95% confidence interval:	Estimate:	95% confidence interval:
1	84.2	75.6 - 90.7	94.8	89.0 - 98.1
2	87.1	79.0 - 93.0	75.7	66.8 - 83.2
3	94.1	87.5 - 97.8	98.3	93.9 - 99.8
Bony kernel:				
Reader:	Sensitivity (%):		Specificity (%):	
	Estimate:	95% confidence interval:	Estimate:	95% confidence interval:
1	92.1	85.0 - 96.5	98.3	93.9 - 99.8
2	91.1	83.8 - 95.8	80.9	72.5 - 80.6
3	92.1	85.0 - 96.5	98.3	93.9 - 99.8

For the brain kernel, the sensitivity for reader 1 was significantly lower than that of reader 3. This improved with use of the bony kernel in that there was no significant difference. The specificity of all three readers differed significantly. For the bony kernel, the specificity for readers 1 and 3 differed significantly from that of reader 2. It was concluded that for the brain kernel, reader 3 did best and for the bony kernel, both readers 1 and 3 did best.

2.2.2.4. The difference in proportion of patients with fractures detected between kernels:

Using McNemar's test, it was shown that within each reader, there was no significant difference in the proportion of patients identified with fractures using either kernel (table 2.5).

Table 2.5. Proportion of patients with fractures identified by each reader.

Reader:	Percentage of patients with fractures (%):		*p-value for H0: no difference between proportions:*
	Brain kernel:	Bony kernel:	
1	42.1	44.0	0.41
2	53.7	52.8	0.74
3	44.9	44.0	0.56

2.2.3. Comparing the use of both kernels using the majority decision data for the general readers

2.2.3.1. Sensitivity and specificity:

The sensitivity and specificity for the detection of patients with fractures for the brain and bony kernels are shown in table 2.6 below. There was no significant difference in the sensitivity or specificity between the two kernels (McNemar's test; p=0.74 and 1.00, respectively).

Table 2.6. Sensitivity and specificity of the brain and bony kernels.

Kernel:	Sensitivity (%):		Specificity (%):	
	Estimate:	95% confidence interval:	Estimate:	95% confidence interval:
Brain	93.1	86.2 - 97.2	98.3	93.9 - 99.8
Bony	92.1	85.0 - 96.5	98.3	93.9 - 99.8

There was no significant difference in terms of the proportion of correctly identified patients with fractures between the two kernels. 95.8% and 95.4% of the brain and bony kernel CT-Brains were correctly classified in terms of the presence or absence of a fracture. The difference was not significant (McNemar's test; p=0.78).

The percentage of correct assessments for the 'number of fractures' and their 'location' (fracture segment) for each kernel are shown below in table 2.7 and figure 2.4. Overall, the classifications of the 'number of fractures,' 'frontal skull base' and 'parietal skull vault' were most problematic for the two kernels. However, these were not significant differences between the two kernels, with the exception of the 'number of fractures.' The brain kernel was more accurate at determining the correct number of distinct fractures (McNemar's test; p=0.022). The brain kernel was almost found to be significantly better at identifying frontal skull vault fractures (p=0.052).

Table 2.7. Distribution of correctly and incorrectly identified fracture segments.

Variable:	Brain Kernel:				Bone Kernel:				*p-value for H0: no difference between brain and bony kernel:*
	Incorrectly:		*Correctly:*		*Incorrectly:*		*Correctly:*		
	n	%	n	%	n	%	n	%	
Fracture (y/n)	9	4.2%	207	95.8%	10	4.6%	206	95.4%	0.78
Within cases:									
Fracture (y/n)	7	6.9%	94	93.1%	8	7.9%	93	92.1%	0.74
Number of fractures	16	15.8	85	84.2%	27	26.7	74	73.3%	0.022
Skull base frontal	16	15.8	85	84.2%	15	14.9	86	85.1%	0.82
Skull Base Ethmoid	7	6.9%	94	93.1%	8	7.9%	93	92.1%	0.78
Skull Base Sphenoid	8	7.9%	93	92.1%	9	8.9%	92	91.1%	0.74
Skull Base Temporal	8	7.9%	93	92.1%	11	10.9	90	89.1%	0.26
Skull Base Occipital	5	5.0%	96	95.0%	5	5.0%	96	95.0%	1.00
Skull Vault Frontal	8	7.9%	93	92.1%	15	14.9	86	85.1%	0.052
Skull Vault Parietal	21	20.8	80	79.2%	18	17.8	83	82.2%	0.47
Skull Vault Occipital	11	10.9	90	89.1%	12	11.9	89	88.1%	0.56
Skull Vault Temporal	10	9.9%	91	90.1%	14	13.9	87	86.1%	0.21

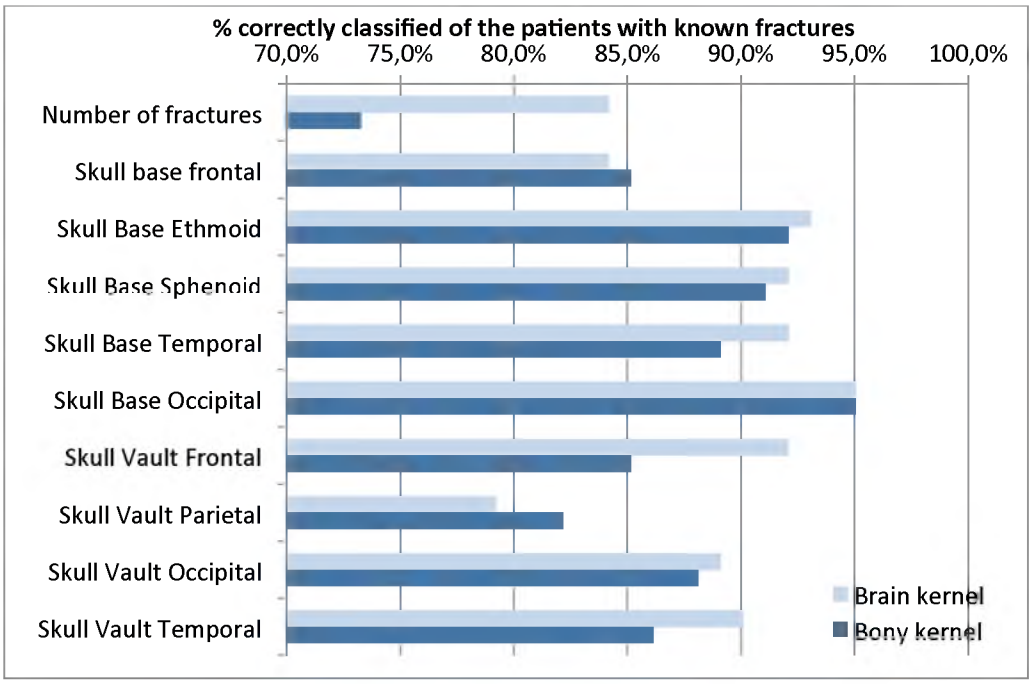

Figure 2.4. Distribution of correctly identified fractured segments for both kernels.

2.2.3.2. Comparing the correctly identified fracture group to the missed fracture group:

The group of patients with correctly identified fractures was compared to the group with missed fractures for each kernel to determine if the 'number of fractures,' 'displacement,' 'location' (fracture segment), 'age' or 'mechanism of injury' could be identified as independent significant risk factors for a missed fracture. For this analysis each location was classified as either only present or absent (i.e. the number of fractures in each segment and laterality were ignored) and only the assault and PVA groups of 'mechanism of injury' were used as group sizes for the other mechanisms of injury were too small for missed fractures. The group size for missed fractures was in fact extremely small, which

made the between group tests underpowered. Hence the results must be interpreted with caution. The results are shown in table 2.8.

Table 2.8. Comparison of patients with fractures correctly identified to those that had missed fractures.

Variable:	Category:	Brain kernel:				p-value for between-group difference	Bony kernel:				p-value for between group difference:
		Missed:		Identified:			Missed:		Identified:		
		n	%	n	%		n	%	n	%	
Within cases which had fractures(n=101)		**7**		**94**			**8**		**93**		
Number of fractures	1	6	8.2%	67	91.8%	0.014 (phi=0.39)	8	11.0%	65	89.0%	0.17
	2	0	0.0%	27	100.0		0	0.0%	27	100.0	
	3	1	100.0	0	0.0%		0	0.0%	1	100.0	
Displacement	No	4	7.8%	47	92.2%	1.00	8	15.7%	43	84.3%	0.0058 (phi=0.29)
	Yes	3	6.0%	47	94.0%		0	0.0%	50	100.0	
Skull Base Frontal	No	7	10.1%	62	89.9%	0.09	7	10.1%	62	89.9%	0.43
	Yes	0	0.0%	32	100.0		1	3.1%	31	96.9%	
Skull Base Ethmoid	No	7	8.2%	78	91.8%	0.59	8	9.4%	77	90.6%	0.35
	Yes	0	0.0%	16	100.0		0	0.0%	16	100.0	
Skull Base Sphenoid	No	7	8.4%	76	91.6%	0.35	6	7.2%	77	92.8%	0.63
	Yes	0	0.0%	18	100.0		2	11.1%	16	88.9%	
Skull Base Temporal	No	7	8.5%	75	91.5%	0.34	8	9.8%	74	90.2%	0.35
	Yes	0	0.0%	19	100.0		0	0.0%	19	100.0	
Skull Base Occipital	No	5	5.3%	89	94.7%	0.07	6	6.4%	88	93.6%	0.09
	Yes	2	28.6%	5	71.4%		2	28.6%	5	71.4%	
Skull Vault Frontal	No	6	14.6%	35	85.4%	0.017 (phi=0.25)	5	12.2%	36	87.8%	0.26
	Yes	1	1.7%	59	98.3%		3	5.0%	57	95.0%	
Skull Vault Parietal	No	4	7.1%	52	92.9%	1.00	8	14.3%	48	85.7%	0.0081 (phi=0.26)
	Yes	3	6.7%	42	93.3%		0	0.0%	45	100.0	
Skull Vault Occipital	No	5	5.7%	82	94.3%	0.25	7	8.0%	80	92.0%	1.00
	Yes	2	14.3%	12	85.7%		1	7.1%	13	92.9%	
Skull Vault Temporal	No	5	6.4%	73	93.6%	0.66	7	9.0%	71	91.0%	0.68
	Yes	2	8.7%	21	91.3%		1	4.3%	22	95.7%	
Gender	Female	1	10.0%	9	90.0%	0.53	2	20.0%	8	80.0%	0.18
	Male	6	6.7%	84	93.3%		6	6.7%	84	93.3%	
MOI	Assault	4	6.7%	56	93.3%	0.60	5	8.3%	55	91.7%	0.63
	PVA	2	12.5%	14	87.5%		2	12.5%	14	87.5%	

2.2.3.3. Findings of the risk factor analysis using the brain kernel:

Between the identified fracture group and the missed fracture group there was a statistically significant difference with regard to the number of fractures identified on the study (p=0.014). Patients with a frontal skull vault fracture were more likely to be identified than those without one (p=0.017). Less than 100% identification was seen for displaced fractures, occipital skull base and frontal, parietal and temporal skull vault fractures. Both types of mechanism of injury showed less than 100% identification with no significant difference between the two. These were all not statistically significant.

2.2.3.4. Findings of the risk factor analysis using the bony kernel:

Patients with displaced fractures were more likely to be identified than those with undisplaced fractures (p=0.0058). Parietal skull vault fractures were also more likely to be identified than missed (p=0.0081). Younger patients were more likely to have their fractures identified compared to older patients (p=0.041). In this case 'younger patients' referred to those left of the mean for the age distribution. Less than 100% identification was seen for a range of skull vault and base fractures and both mechanisms of injury, but none of these findings were significant between the two groups.

3. Concluding Chapter:

3.1. Discussion

3.1.1. Results in context

3.1.1.1. Head trauma in South Africa:

The average age of the study sample was 29.5 years as shown in figure 2.1. The majority of patients were young adults and this was in keeping with global trends (4). It is accepted that the most common cause of death in young adults is trauma and our study is coherent with this given the likelihood of death from head trauma. Male patients were more likely to suffer head trauma in our setting (n=182, 84.3%). Ninety-one percent (90.9%, n=101) of the patients who presented with a mechanism of assault were in fact male.

The most common mechanism of injury was assault. This suggests a high incidence of interpersonal violence in our setting (4). From our experience, most of these were in the form of blunt force trauma either with fists or with blunt objects. Bullet wounds formed a small proportion of the mechanisms of injury documented in the study population (n=1, 0.5%) (figure 2.2). MVAs were a common mechanism of injury for head trauma in keeping with global trends (n=36, 16.7%) (4).

Eleven percent (11.1% (n=24)) of the patients who suffered head trauma were less than 17 years of age. The most common mechanisms of injury in children were a fall from height, especially in non-ambulant children (n=8), and pedestrian vehicle accidents (n=7) in children who were ambulant. Whilst concerned parents could explain falls from height

in younger children, one must question the incidence of children involved in pedestrian vehicle accidents. Previous studies have identified this issue as a significant problem and this study further supports this opinion (4, 5).

3.1.1.2. Fracture patterns noted from results:

Interestingly 27.7% (n=28) of patients who had a fracture had multiple fractures. This should encourage radiologists to not simply settle for satisfaction of search when a solitary fracture is found on CT-Brain. Concerted efforts need to be made to search for secondary fractures, as over one in four cases will have a one.

This study showed that about half (n=51, 50.5%) of fractures seen on CT-Brain were undisplaced. Analysis of data from the bony kernel reading found that undisplaced fractures were more likely to be missed than displaced fractures (p=0.0058). Radiologists should scrutinize every segment of the skull to avoid missing these fractures. A reason for these findings may be that undisplaced fractures are associated with fewer adjacent ancillary findings. Further research is needed to confirm this. Use of the bony kernel did not result in improved detection of undisplaced fractures in this study.

The skull vault was more commonly fractured when compared to the skull base. Not surprisingly, the most commonly fractured bones were the frontal and parietal bones of the skull vault. These are the largest and most exposed bones of the head. In the skull base the frontal bones were most commonly fractured, usually from extension of a frontal vault fracture into the skull base. This is significant because many of these fractures could extend into type 2 or 3 fractures resulting in CSF sino-nasal leakage.

Temporal bone skull base fractures were shown to be as common as the ethmoid and sphenoid bone fractures suggesting that equal time should be spent reviewing these areas. This study was underpowered for determining if specific mechanisms of injury resulted in certain fracture locations in the skull base. However no specific trends were noticed. There was no difference in detection of skull base fractures between both kernels.

3.1.1.3. Comparing the bony kernel to a brain kernel:

There was no significant difference in the sensitivity or specificity between the two kernels (p=0.74 and 1.00). Even when looking for an improvement in fracture detection for individual readers, there was no significant improvement for any of them. The use of a bony kernel did not add any value other than simply making fractures appear sharper.

Although the study was underpowered for missed fractures of the skull, no trends were seen to suggest any improvement in fracture detection with the use of a bony kernel for specific fracture locations. One reason, which has been put forward for these findings, may be that most clinically relevant fractures are accompanied by ancillary findings (14). Examples include abnormal air adjacent to a fracture, pneumocephalus, blood in the paranasal sinuses, localized scalp inflammation and opacification of the middle and inner ear. This study shows that the brain kernel correctly identifies over 90% of ethmoid, sphenoid and temporal bone fractures in isolation. In keeping with previous articles, fractures of the frontal skull base were among the most difficult fractures to identify (±85%) (figure 2.4) (14).

Overall the sensitivity and specificity of the brain kernel alone were good at 93.1% and 98.3% respectively. These were actually higher than anticipated compared to previous studies (1, 6). These results show that the brain kernel may be used in isolation. The researcher suggests that, given the current literature on the topic and the finding that the bony kernel does not improve fracture detection, only the brain kernel should be routinely reconstructed. In cases where a missed fracture is suspected by a clinician at a later stage, an alternative study should be performed. An example of such a scenario would be a patient with a facial nerve palsy and a previously normal CT-Brain post head trauma. A HR-MPR CT of the temporal bones would add much more value despite the additional radiation dose as suggested in previous studies (1, 6, 17). A similar scenario would be a patient presenting with CSF rhinorrhoea after head trauma. These patients would benefit more from a heavily T2 weighed 3D gradient echo MRI sequence (e.g. CISS) than from exhausting efforts to delineate the fracture using a bony kernel. Communication with the referring clinician when suggesting further imaging is mandatory.

The finding of a significant difference between the numbers of fractures identified between the missed fracture group and the identified fracture group when using the brain kernel was largely due to one case where three fractures were missed on one study. The researcher can only assume this was a reading error made by the general readers or an error in study number allocation during randomization.

The use of a bony kernel in children less than 16 years of age did not improve fracture detection. Numerous normal suture lines are present on the CT-Brain of a child and these

are sometimes difficult to differentiate from fractures. It seems that the brain kernel images were adequate to make this differentiation although this study was not designed to test this in children specifically, and the number of children included in this study was very small. The bony kernel may help differentiate an undisplaced fracture from a normal suture line but further research is required to test this. The researcher therefore cannot refute the use of a bony kernel reconstruction for children less than 16 years of age. The addition of a HR-MPR CT would also add to radiation dose, which is better avoided in children. Volume rendered images may also be beneficial in a similar manner (15).

This study showed a significant bias between the findings of the general readers from one reader who tended to "overcall" fractures as can be seen in table 2.1. This reader was in fact the most junior reader with less than one years experience. It may be the case that junior radiologists may need a specific amount of training before reaching the capabilities of their more experienced colleagues. The bony kernel alone did not change this experience gap but other methods of image manipulation have shown promise in doing so (1, 9).

3.1.2. Limitations of the study

- This study was eventually underpowered for determining risk factors for missed fractures with regard to fracture location, fracture characteristics and patient demographics. The reason for this was that not only was the study number initially determined from the primary objective for the most part, but also the likelihood of a missed fracture was actually much lower than expected from

previous studies (1, 6). The sensitivity for the brain kernel was 93.1% i.e. there were few false negatives. The missed fracture groups were consequently very small.

- Sampling bias was a limitation of this study. The exact likelihood of a fracture being found on a CT-Brain for head trauma in our setting is unknown to the researchers knowledge. Therefore fracture cases were matched with control cases.
- This study was undertaken at a tertiary referral hospital with a level 1 trauma centre. Minor head trauma not referred was subsequently not included in the study. Patients with asymptomatic fractures may have not been investigated and hence were not included.
- A significant bias existed between the three general readers that was statistically significant. However it had little effect on the outcome of the study because the majority decision was taken between the three readers.

3.1.3. Current applications

- There is no statistically significant difference in the detection of patients with fractures of the skull between a brain and bony kernel. The author therefore suggests that only a simple brain kernel is initially needed for the investigation of head trauma. If clinical findings suggest the likelihood of a significant missed fracture (most likely a frontal, ethmoidal or temporal skull base fracture) then further investigation with HR-MPR CT or MRI is suggested where appropriate.

- The detection of skull base fractures is not improved through the use of a bony kernel.
- It is suggested that a bony kernel be added to the routine reconstructions of a CT-Brain for head trauma in children less than 16 years of age, in order to help differentiate suture lines from fractures, until further studies are available.
- A bony kernel does not need to be routinely added to a brain kernel for storage on a PACS system. This should directly improve on permanent hard disc storage capacity and cost effectiveness as many vendors charge on a per image basis.
- Radiographers would shorten reconstruction times allowing for faster patient throughput. Reporting times would also be shortened, as there would be one less unnecessary reconstruction for the radiologist to review.

3.1.4. Future applications

- Interpersonal violence amongst males is a major problem locally, with the most common mechanism of injury being assault in this study. Further epidemiological studies are necessary to ascertain why and how this occurs.
- The finding of a significant number of ambulant children presenting for investigation of head trauma with the mechanism of PVA was worrying. Research into local stressors, which put children at risk of the aforementioned, is advised.
- Radiologists are likely to detect fractures because of ancillary findings on CT-Brain. This is likely the reason why no difference in detection of fractures was found between kernels. Further research to ascertain which ancillary findings are

specific for commonly missed fractures may provide guidance on how to avoid these cases.

- Clinical audit into the volume of CT-Brains done for head trauma in South Africa or at CHBAH is advised. Determining the amount of patients found to have fractures on these studies could provide a baseline for comparison with international standards. These studies would ensure that indications are sound, that patient workup is cost-effective given local budget constraints, and that radiation exposure is kept to a minimum.
- Further research is required to determine if this study's findings can be extrapolated to children less than 16 years of age.

3.2. Conclusion

This study shows that there is no statistically significant difference in the detection of fractures between a brain and bony kernel in an adult population. A simple brain kernel is all that is needed for a radiologist to adequately exclude fractures in a patient who has suffered head trauma. A bony kernel does not need to be stored on a PACS system. These findings should improve throughput of patients through the CT Scanner, allow for shorter reporting times from radiologists and improve the cost effectiveness of PACS. Bony kernel reconstructions should however be reviewed in cases where children have sustained significant head trauma. In cases where a missed fracture is likely on clinical grounds, further imaging is suggested through the used of a HR-MPR CT of the area of interest. The incidental finding of a local high incidence of interpersonal violence necessitating the use of CT-Brain in particularly male patients needs further study. The high incidence of pedestrian vehicle accidents amount young children must also be addressed.

Appendix A: Ethics Clearance Certificate

M140625

HUMAN RESEARCH ETHICS COMMITTEE (MEDICAL)

CLEARANCE CERTIFICATE NO. M140625

NAME: (Principal Investigator)	Dr Michele Bove
DEPARTMENT:	Radiology CHBAH
PROJECT TITLE:	The Use of a Bony Kernel for CT-Brain Head Trauma
DATE CONSIDERED:	27/06/2014
DECISION:	Approved unconditionally
CONDITIONS:	
SUPERVISOR:	Prof Victor Mngomezulu
APPROVED BY:	Professor PE Cleaton-Jones, Chairperson, HREC (Medical)

DATE OF APPROVAL: 25/07/2014

This clearance certificate is valid for 5 years from date of approval. Extension may be applied for.

DECLARATION OF INVESTIGATORS

To be completed in duplicate and **ONE COPY** returned to the Secretary in Room 10004, 10th floor, Senate House, University.

I/we fully understand the conditions under which I am/we are authorized to carry out the above-mentioned research and I/we undertake to ensure compliance with these conditions. Should any departure be contemplated, from the research protocol as approved, I/we undertake to resubmit the application to the Committee. **I agree to submit a yearly progress report**.

Principal Investigator Signature M140625Date

PLEASE QUOTE THE PROTOCOL NUMBER IN ALL ENQUIRIES

Appendix B: Reporting Tick Sheet

"The Use of a Bony Kernel for CT Brain in Head Trauma"

Reporting Tick Sheet Case No: ☐

Tick where applicable. ☑
Report on all fractures you see involving the skull base or skull vault only.
You can make use of only the bony window in transverse section.
Depict all fractures seen on the diagrams labeling them as Fracture 1 or 2.

Is a fracture present: ☐ yes ☐ no

How many fractures are seen: ☐ 1 ☐ 2 ☐ 3 or more

☐ **Fracture 1:**
Displaced: ☐ yes ☐ no
Side: ☐ right ☐ left
Location:
Skull Base: ☐ Frontal ☐ Ethmoid ☐ Sphenoid ☐ Temporal ☐ Occipital
Skull Vault: ☐ Frontal ☐ Parietal ☐ Occipital ☐ Temporal

☐ **Fracture 2:**
Displaced: ☐ yes ☐ no
Side: ☐ right ☐ left
Location:
Skull Base: ☐ Frontal ☐ Ethmoid ☐ Sphenoid ☐ Temporal ☐ Occipital
Skull Vault: ☐ Frontal ☐ Parietal ☐ Occipital ☐ Temporal

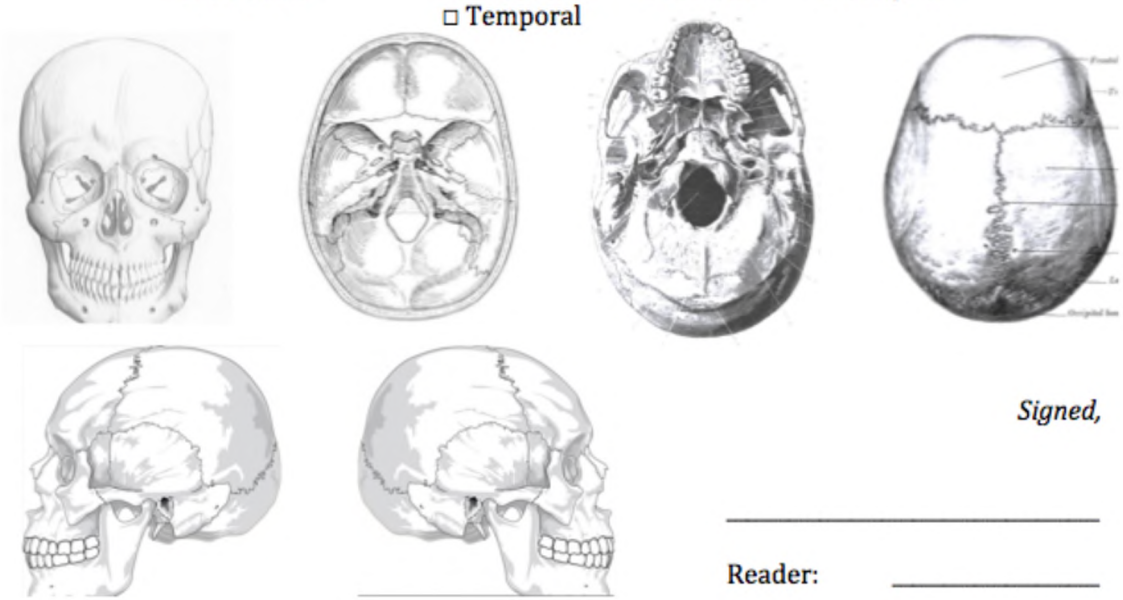

Signed,

_____

Reader: _____

Appendix C: Inter-reader bias between general readers cross-tabulation

Table of GR1_Brain_Kernel_Fracture_Present by GR2_Brain_Kernel_Fracture_Present			
GR1_Brain_Kernel_Fracture_Present	GR2_Brain_Kernel_Fracture_Present		
	0	1	Total
0	87	38	125
1	13	78	91
Total	100	116	216

Table of GR1_Brain_Kernel_Fracture_Present by GR3_Brain_Kernel_Fracture_Present			
GR1_Brain_Kernel_Fracture_Present	GR3_Brain_Kernel_Fracture_Present		
	0	1	Total
0	115	10	125
1	4	87	91
Total	119	97	216

Table of GR2_Brain_Kernel_Fracture_Present by GR3_Brain_Kernel_Fracture_Present			
GR2_Brain_Kernel_Fracture_Presen	GR3_Brain_Kernel_Fracture_Present		
	0	1	Total
0	90	10	100
1	29	87	116
Total	119	97	216

Table of GR1_Bone_Kernel_Fracture_Present by GR2_Bone_Kernel_Fracture_Present			
GR1_Bone_Kernel_Fracture_Present	GR2_Bone_Kernel_Fracture_Present		
	0	1	Total
0	97	24	121
1	5	90	95
Total	102	114	216

Table of GR1_Bone_Kernel_Fracture_Present by GR3_Bone_Kernel_Fracture_Present			
GR1_Bone_Kernel_Fracture_Present	GR3_Bone_Kernel_Fracture_Present		
	0	1	Total
0	121	0	121
1	0	95	95
Total	121	95	216

Table of GR2_Bone_Kernel_Fracture_Present by GR3_Bone_Kernel_Fracture_Present			
GR2_Bone_Kernel_Fracture_Present	GR3_Bone_Kernel_Fracture_Present		
	0	1	Total
0	97	5	102
1	24	90	114
Total	121	95	216

4. References

1. Ringl H, Schernthaner RE, Schueller G, Balassy C, Kienzl D, Botosaneanu A, et al. The skull unfolded: a cranial CT visualization algorithm for fast and easy detection of skull fractures. Radiology. 2010 May;255(2):553-62.
2. West OC, Mirvis SE, Shanmuganathan K. Transsphenoid basilar skull fracture: CT patterns. Radiology. 1993 Aug;188(2):329-38.
3. Thomas AG, Hegde SV, Dineen RA, Jaspan T. Patterns of accidental craniocerebral injury occurring in early childhood. Arch Dis Child. 2013 Oct;98(10):787-92.
4. Naidoo D. Traumatic brain injury: the South African landscape. S Afr Med J. 2013 Sep-Aug 2;103(9):613-4.
5. Schrieff LE, Thomas KG, Dollman AK, Rohlwink UK, Figaji AA. Demographic profile of severe traumatic brain injury admissions to Red Cross War Memorial Children's Hospital, 2006 - 2011. S Afr Med J. 2013 Sep-Jul 29;103(9):616-20.
6. Ringl H, Schernthaner R, Philipp MO, Metz-Schimmerl S, Czerny C, Weber M, et al. Three-dimensional fracture visualisation of multidetector CT of the skull base in trauma patients: comparison of three reconstruction algorithms. Eur Radiol. 2009 Oct;19(10):2416-24.
7. Yates D, Charter N, Cooper P, Dent H, Editors. Head Injury: Assessment, Investigation and Early Management of Head Injury in Infants, Children and Adults: National Institute Of Clinical Excellence (NICE); 2007. 231 p.
8. Lloyd DA, Carty H, Patterson M, Butcher CK, Roe D. Predictive value of skull radiography for intracranial injury in children with blunt head injury. Lancet. 1997 Mar 22;349(9055):821-4.
9. Kim ES, Yoon DY, Lee HY, Ku YJ, Han A, Yoon SJ, et al. Comparison of emergency cranial CT interpretation between radiology residents and neuroradiologists: transverse versus three-dimensional images. Diagn Interv Radiol. 2014 May-Jun;20(3):277-84.
10. Wysoki MG, Nassar CJ, Koenigsberg RA, Novelline RA, Faro SH, Faerber EN. Head trauma: CT scan interpretation by radiology residents versus staff radiologists. Radiology. 1998 Jul;208(1):125-8.
11. Chan KH, Mann KS, Yue CP, Fan YW, Cheung M. The significance of skull fracture in acute traumatic intracranial hematomas in adolescents: a prospective study. J Neurosurg. 1990 Feb;72(2):189-94.
12. Manson PN, Stanwix MG, Yaremchuk MJ, Nam AJ, Hui-Chou H, Rodriguez ED. Frontobasal fractures: anatomical classification and clinical significance. Plast Reconstr Surg. 2009 Dec;124(6):2096-106.
13. Sakas DE, Beale DJ, Ameen AA, Whitwell HL, Whittaker KW, Krebs AJ, et al. Compound anterior cranial base fractures: classification using computerized tomography scanning as a basis for selection of patients for dural repair. J Neurosurg. 1998 Mar;88(3):471-7.
14. Jacobsen C, Bech BH, Lynnerup N. A comparative study of cranial, blunt trauma fractures as seen at medicolegal autopsy and by computed tomography. BMC Med Imaging. 2009 Oct 16;9:18.
15. Medina LS. Three-dimensional CT maximum intensity projections of the calvaria: a new approach for diagnosis of craniosynostosis and fractures. AJNR Am J Neuroradiol. 2000 Nov-Dec;21(10):1951-4.

16. Fatterpekar GM, Doshi AH, Dugar M, Delman BN, Naidich TP, Som PM. Role of 3D CT in the evaluation of the temporal bone. Radiographics. 2006 Oct;26(Suppl 1):S117-32.
17. Connor SE, Flis C. The contribution of high-resolution multiplanar reformats of the skull base to the detection of skull-base fractures. Clin Radiol. 2005 Aug;60(8):878-85.
18. Schuknecht B, Graetz K. Radiologic assessment of maxillofacial, mandibular, and skull base trauma. European radiology. 2005 Mar;15(3):560-8.
19. McEntee MF, Nikolovski I, Bourne R, Pietrzyk MW, Evanoff MG, Brennan PC, et al. The effect of JPEG2000 compression on detection of skull fractures. Acad Radiol. 2013 Jun;20(6):712-20.
20. Shoukri MM. Measures of interobserver agreement. 2nd edition. New York: Chapman & Hall; 2004. ISBN 13 978-14398-1080-4.
21. Landis JR, Koch GG. The measurement of observer agreement for categorical data. Biometrics. 1977;33:159-7.

M140625

HUMAN RESEARCH ETHICS COMMITTEE (MEDICAL)

CLEARANCE CERTIFICATE NO. M140625

NAME: Dr Michele Bove
(Principal Investigator)

DEPARTMENT: Radiology
CHBAH

PROJECT TITLE: The Use of a Bony Kernel for CT-Brain Head Trauma

DATE CONSIDERED: 27/06/2014

DECISION: Approved unconditionally

CONDITIONS:

SUPERVISOR: Prof Victor Mngomezulu

APPROVED BY:

Professor PE Cleaton-Jones, Chairperson, HREC (Medical)

DATE OF APPROVAL: 25/07/2014

This clearance certificate is valid for 5 years from date of approval. Extension may be applied for.

DECLARATION OF INVESTIGATORS

To be completed in duplicate and **ONE COPY** returned to the Secretary in Room 10004, 10th floor, Senate House, University.

I/we fully understand the conditions under which I am/we are authorized to carry out the above-mentioned research and I/we undertake to ensure compliance with these conditions. Should any departure be contemplated, from the research protocol as approved, I/we undertake to resubmit the application to the Committee. **I agree to submit a yearly progress report**.

Principal Investigator Signature M140625Date

PLEASE QUOTE THE PROTOCOL NUMBER IN ALL ENQUIRIES

MMedWriteUpBove20170419REEXAMINE223.docx

ORIGINALITY REPORT

8%	5%	4%	2%
SIMILARITY INDEX	INTERNET SOURCES	PUBLICATIONS	STUDENT PAPERS

PRIMARY SOURCES

1	Submitted to University of Witwatersrand Student Paper	1%
2	www.asnr.org Internet Source	1%
3	www.biomedcentral.com Internet Source	<1%
4	media.proquest.com Internet Source	<1%
5	www.ajnr.org Internet Source	<1%
6	Submitted to Mancosa Student Paper	<1%
7	www.cgap.org.uk Internet Source	<1%
8	Tyvin A Rich. "Clinical and pathologic review of 48 cases of chordoma", Cancer, 07/01/1985 Publication	<1%
9	Abdominal Imaging, 2013. Publication	<1%

10	www.dirjournal.org Internet Source	<1%
11	Orman, Gunes, Matthias W. Wagner, Daniel Seeburg, Carlos A. Zamora, Alexander Oshmyansky, Aylin Tekes, Andrea Poretti, George I. Jallo, Thierry A. G. M. Huisman, and Thangamadhan Bosemani. "Pediatric skull fracture diagnosis: should 3D CT reconstructions be added as routine imaging?", Journal of Neurosurgery Pediatrics, 2015. Publication	<1%
12	issuu.com Internet Source	<1%
13	Submitted to University of Westminster Student Paper	<1%
14	dyuthi.cusat.ac.in Internet Source	<1%
15	Martin Bland. "Categorical Variables: Rates and Proportions", Medical Statistics, 01/01/2005 Publication	<1%
16	search.oecd.org Internet Source	<1%
17	Submitted to Buckinghamshire Chilterns University College Student Paper	<1%

18	Bobinski, Matthew, Peter Shen, and Arthur Dublin. "Basic Imaging of Skull Base Trauma", Journal of Neurological Surgery Part B Skull Base, 2016. Publication	<1%
19	Helmut Ringl. "Three-dimensional fracture visualisation of multidetector CT of the skull base in trauma patients: comparison of three reconstruction algorithms", European Radiology, 05/14/2009 Publication	<1%
20	Ieva, Antonio, Laurent Audigé, Robert Kellman, Kevin Shumrick, Helmut Ringl, Joachim Prein, and Christian Matula. "The Comprehensive AOCMF Classification: Skull Base and Cranial Vault Fractures – Level 2 and 3 Tutorial", Craniomaxillofacial Trauma and Reconstruction, 2014. Publication	<1%
21	Submitted to Universiti Sains Malaysia Student Paper	<1%
22	Shaahinfar, Ashkon, Kevin D. Whitelaw, and Karim M. Mansour. "Update on abusive head trauma :", Current Opinion in Pediatrics, 2015. Publication	<1%
23	abjs.mums.ac.ir Internet Source	<1%

24	Vercauteren, Tom, Xiaodong Wang, and Alberto Lopez Toledo. "Adaptive Optimization of CSMA/CA MAC Protocols Based on Bayesian State Estimation", Adaptation and Cross Layer Design in Wireless Networks, 2008. Publication	<1%
25	erk.fe.uni-lj.si Internet Source	<1%
26	Mateo Ziu. "Diagnosis and treatment of cerebrospinal fluid rhinorrhea following accidental traumatic anterior skull base fractures", Neurosurgical FOCUS, 06/2012 Publication	<1%
27	"Nerve blocks (subcostal, lateral cutaneous, femoral, triple, psoas) for hip fractures", Cochrane Database of Systematic Reviews, 2002. Publication	<1%
28	www.tbrieder.org Internet Source	<1%
29	uir.unisa.ac.za Internet Source	<1%
30	Tekeli, K.M.. "Unusual case of post-traumatic lingual paraesthesia", British Journal of Oral & Maxillofacial Surgery, 200803 Publication	<1%
	kjronline.org	

31	Internet Source	<1%
32	www.deepdyve.com Internet Source	<1%
33	www.deafblindinformation.org.au Internet Source	<1%
34	www.ruralneuropractice.com Internet Source	<1%
35	Mackway-Jones, K. "Towards evidence based emergency medicine: best BETs from the Manchester Royal Infirmary. (BEST EVID", Emergency Medicine Journal, Nov 2001 Issue Publication	<1%
36	C. Matula. "Fractures of the Anterior Skull Base Associated with CSF Leak", Osteosynthesis and Trauma Care, 05/2006 Publication	<1%
37	bmcvetres.biomedcentral.com Internet Source	<1%
38	Brain Degeneration and Dementia in Sub-Saharan Africa, 2015. Publication	<1%
39	Katırcıoğlu, Yasemin Arslan, Ugur Emrah Altıparmak, and Sunay Duman. "Comparison of Three Methods for the Treatment of Pterygium: Amniotic Membrane Graft,	<1%

Conjunctival Autograft and Conjunctival Autograft plus Mitomycin C.", Orbit, 2007.
Publication

40	146.141.12.21 Internet Source	<1%
41	Cui, Hua, Yixin Hu, Changming Hong, Guoliang Hu, and Li Fan. "A 15 years study of the causes of death among elderly hypertensive patients in a hospital-based sample of China", Archives of Gerontology and Geriatrics, 2012. Publication	<1%
42	www.infona.pl Internet Source	<1%
43	X. Liu. "Comparison of 3D Free-Breathing Coronary MR Angiography and 64-MDCT Angiography for Detection of Coronary Stenosis in Patients with High Calcium Scores", American Journal of Roentgenology, 12/01/2007 Publication	<1%
44	"34 Skull Base Traumatology", Handbook of Skull Base Surgery, 2016. Publication	<1%
45	www.moh.gov.my Internet Source	<1%
46	core.ac.uk Internet Source	<1%

47	researchbank.rmit.edu.au Internet Source	<1%
48	Raybagkar, Deepti A., Nina Kohn, and Suchitra S. Acharya. "Single institutional experience of prevalence and risk factors of thromboembolic events in children with solid tumors :", Blood Coagulation & Fibrinolysis, 2013. Publication	<1%
49	Kadar, Abdul Aleem. "Test Band", Encyclopedia of Otolaryngology Head and Neck Surgery, 2013. Publication	<1%
50	Ringl, H., R. E. Schernthaner, G. Schueller, C. Balassy, D. Kienzl, A. Botosaneanu, M. Weber, C. Czerny, S. Hajdu, T. Mang, C. J. Herold, and W. Schima. "The Skull Unfolded: A Cranial CT Visualization Algorithm for Fast and Easy Detection of Skull Fractures", Radiology, 2010. Publication	<1%
51	Takasaki, Kenji, Hidetaka Kumagami, Akiko Baba, Daisuke Fujiyama, and Haruo Takahashi. "A case with posterior fossa epidermoid cyst showing audiovestibular symptoms caused by insufficiency of anterior inferior cerebellar artery – usefulness of free DICOM image viewing and processing software", Acta Oto-Laryngologica, 2009.	<1%

Publication

EXCLUDE QUOTES	ON	EXCLUDE MATCHES	OFF
EXCLUDE BIBLIOGRAPHY	ON		