

https://dspace.org/

The prevalence of recurrent ameloblastoma at the Wits oral health centre

Chokoe, Nare Hemelton

2018
https://hdl.handle.net/10539/25232

Downloaded from a DSpace repository. https://dspace.org/

THE PREVALENCE OF RECURRENT AMELOBLASTOMA AT THE WITS ORAL HEALTH CENTRE

UNIVERSITY OF THE WITWATERSRAND, JOHANNESBURG

Nare Hemelton Chokoe

A research report submitted to the Faculty of Health Sciences, University of the Witwatersrand, Johannesburg, in partial fulfilment of the requirements for the degree of Master of Science in Dentistry

8TH JUNE 2018

Declaration

I Nare Hemelton Chokoe declare that this research report is my own, unaided work. It is being submitted for the Master of Science at the University of the Witwatersrand, Johannesburg. It has not been submitted before for any degree or examination at any other University.

_____

(Signature of candidate)

8th day of June 2018 in Parktown

Dedication

I dedicate this piece of work to my lovely and supportive wife (Hope Phasha) and to our adorable kids (daughter, Lethabo and son, Lebogang)

Abstract

Background

Ameloblastoma is a slow growing, locally invasive, benign tumour of odontogenic origin. Ameloblastoma is the most common odontogenic tumour with varying recurrence rates, depending on the adequacy of the tumour removal. A number of factors including inadequate removal of tumour have been associated with recurrence

Aim

The aim of the study was to determine the prevalence of recurrent ameloblastoma in patients treated at the Wits Oral Health Centre.

Methods

This study was a retrospective analysis of 246 records of patients diagnosed with ameloblastoma over a 24 year period (January 1992 to December 2015) in order to determine factors associated with recurrence. Descriptive statistics of mean, standard deviation, frequencies, percentages and proportions were used to summarize the data. Chi- squared and multivariate logistic regression was used to determine the association between the variables and recurrence associated with AMB.

Results

Males (49.6%) and females (50.4%) were equally affected with a mean age of 31 years (range 7-82 years). AMB affected the mandible (96%) more than the maxilla (4%). Multicystic AMB represented the majority (76.8%) of cases. Most AMB's (92.7%) presented with bone perforation. Nineteen cases (7.7%) recurred, mostly in soft tissues, fifteen of which were treated radically and four conservatively. Fifteen (78.95%) recurrent AMB's presented within 10 years of surgical treatment with the remainder (2, 1 and 1) presenting 13, 17 and 21 years post-treatment, respectively. AMB's larger than 4cm in greatest diameter were associated with 84.21% of the recurrences. Multicystic AMB accounted for 84.21% of the recurrences.

Conclusions

This study is in agreement with most studies with regard to demographic data and clinico-pathological features of AMB. Large multicystic AMB with soft tissue encroachment have a high propensity to recur even when treated by radical resection. Recurrence is a significant associated with histological margins and the surgical method of treatment.

Acknowledgments

To the Head of School, Prof Nemutandani, thank you for granting me the opportunity to conduct my study.

To the Head of Dept. (Maxillo-Facial and oral Surgery), Dr Rikhotso, thank you for your support

To my supervisors, Dr's Mabongo and Ngwenya, no words to express how grateful I am. From the bottom of my heart, thank you for your guidance, contribution and support.

To my colleagues, Dr's Galane and Mahlangu, thank you for your guidance and encouragement

To my mother, Ms Chokoe, thank you for your support and encouragement

Table of Contents

Declaration II

Dedication III

Abstract IV

Acknowledgments V

List of figures VII

List of tables VIII

List of Abbreviations IX

Chapter 1 11

Objectives 16

Rationale for the study 16

CHAPTER 2 17

RESEARCH METHODOLOGY 17

CHAPTER 3 21

Chapter 4 33

References 41

ANNEXURE A. 52

Proforma 52

ANNEXURE B 55

Ethics Clearance Certificate 55

ANNEXURE C 56

Letter of approval from the Head of Oral Health Sciences/Wits Oral Health Centre 56

ANNEXURE D 57

Letter of approval from the Head of Department of Oral Pathology 57

ANNEXURE E 58

Patient identifier 58

List of figures

Figure 3.1 Age (in years) distribution of ameloblastomas
Figure 3.2 Anatomical site
Figure 3.3 Size of ameloblastomas
Figure 3.3 Size of ameloblastomas
Figure 3.4 Bone perforation by ameloblastomas
Figure 3.5 Types of ameloblastomas
Figure 3.6 Treatment options for ameloblastomas
Figure 3.7 Site of recurrence
Figure 3.8 Surgical procedures (recurrence)
Figure 3.9 Histological types (recurrence)

List of tables

Table 3.1 Gender distribution of ameloblastomas
Table 3.2 Ameloblastoma variants, growth patterns and histological types
Table 3.3 Histological margins of ameloblastomas
Table 3.4 Recurrence rate of ameloblastomas
Table 3.5 Age recurrence
Table 3.6 Gender recurrence
Table 3.7 Recurrence period of ameloblastomas
Table 3.8 Bone perforation (Recurrence)
Table 3.9 Tumor size (recurrence)
Table 3.10 Chi-squared test of association
Table 3.11 Multivariate logistic regression analyses
Table 3.12 Second multivariate logistic regression analysis
Table 3.13 Histopathological types (recurrence)

List of Abbreviations

WHO- World Health Organization

MMF- Maxillomandibular fixation

AME- Ameloblastoma

Chapter 1
Introduction

Ameloblastoma is a slow growing, locally invasive, benign tumour of odontogenic origin (Odeli et al., 2017). It was formerly known as an adamantinoma (Ivery et al., 1930). The first author to describe this tumour was Cusack in 1827. Globally, it has been estimated to affect 0.5 cases per million persons per year (Larsson et al., 1978). Keszler and Dominguez., (1986), reported that 10-15% of ameloblastoma occur in childhood. The tumour comprises approximately 1% of oral-maxillofacial tumours (Neville et al., 2016) and 14% of all odontogenic tumours (Lasisi et al., 2013: Oginni et al., 2015).

Ameloblastoma is the most common tumour in Africa (Mosadomi A., 1975) and Asia (Lu et al., 1998; Kim and Jang., 2001) while in Western countries such as the United States and Canada; the odontoma is the most common followed by ameloblastoma (Regezi et al., 1978; Daley at el., 1994).

The peak incidence is between the 3rd and 7th decades of life (Neville et al., 2016). Olusanya et al., (2013) in Nigeria, reported a mean age of 34.2 years while Oomens and van der Waal., (2014) in Netherlands, reported a mean age of 44.1 years. Males and females are equally affected. Nearly 85% of ameloblastomas occur in the mandible, most often in the posterior area. (Neville et al., 2016)

The aetiology of ameloblastoma is unknown; although, multiple factors including trauma, inflammation, nutritional deficiency, non-specific irritation from extractions and dental caries have been implicated (Brown and Betz., 2015). Ameloblastoma may arise from rests of Malassez and Serres, reduced enamel epithelium, the epithelial lining of an odontogenic cyst, or from the basal cells of the oral mucosa (Neville et al., 2016)

Two recurrent mutations associated with the molecular pathogenesis of ameloblastoma involving the mitogen-activated protein kinase (MAP) and sonic hedgehog (SHH) pathways have been identified (Kurppa et al., 2014; Brown et al., 2014; Sweeney et al 2014). The most common mutation in the MAPK pathway is the BRAFV600E mutation seen mostly in the mandibular ameloblastomas, while the smoothened (SMO) mutation is associated with maxillary ameloblastomas. The identification of these mutations has led to studies that

demonstrated the efficacy of BRAF inhibitor therapy for ameloblastomas with BRAFV600E mutations (Kaye et al., 2015, Faden et al., 2017)

Literature review

The World Health Organisation 2017 classification of odontogenic tumours (WHO, 2017) classified ameloblastomas into conventional, extraosseous / peripheral, unicystic, and metastasizing ameloblastomas. Conventional ameloblastoma has replaced solid/multicystic ameloblastoma in the 2015 WHO classification of odontogenic tumours (El-Naggar et al., (2017). The desmoplastic ameloblastoma is no longer deemed a separate clinicopathological entity but a variant of ameloblastoma. The classification of ameloblastic carcinoma as the malignant counterpart of the benign ameloblastoma has been retained; metastasizing ameloblastoma has however been classified benign and removed from the malignant category, chiefly due to indistinguishable histological features between primary metastasizing ameloblastoma, it's metastatic counterpart and benign ameloblastoma (Wright and Vered., 2017).

Solid/multicystic or conventional ameloblastoma has a peak incidence in the fourth and fifth decades of life. Males and females are affected equally (WHO, 2017). While most studies report a predilection for the African population, a few have reported no racial predilection (Simon et al., 2005; Oginni et al., 2015). Approximately 80% to 85% of multicystic ameloblastoma involve the mandible and 15% to 20% affect maxilla (Neville et al., 2016).

Early solid/multicystic or conventional ameloblastoma is often asymptomatic; smaller lesions may only be detected on radiographs. However, the more common presentation is that of a slow growing, painless mass with cortical expansion (Adebiyi et al., 2006). Large tumours may be asymptomatic (Neville et al., 2016) or present with loose teeth, malocclusion, paraesthesia, pain, soft tissue infiltration, facial deformity, trismus, dysphagia, and airway obstruction (WHO, 2017). Solid/multicystic ameloblastoma radiologically presents as a well corticated, multilocular radiolucency with a soap-bubble or honeycomb appearance (Oginni et al., 2015).

Multicystic ameloblastoma has variable cystic and solid components; histologically the tumour is characterised by a follicular or plexiform growth pattern with various histological types (Neville et al., 2017). The histological types of ameloblastoma include acanthomatous,

granular, basaloid, and desmoplastic may be admixed in the same tumour El-Naggar et al., (2017).

Robinson and Martinez (1977), described unicystic ameloblastoma as a well circumscribed unilocular, radiolucent tumour that has a better prognosis than multicystic ameloblastoma. The incidence of unicystic ameloblastoma peaks in the second decade of life. The tumour has a male predilection and comprises 5-22% of all ameloblastomas (Philipsen et al., 2001). It most commonly presents as painless jaw expansion.

Unicystic ameloblastoma is histologically classified into luminal, intraluminal, and mural subtypes (Ackermann et al., 1988). The epithelium of the luminal unicystic ameloblastoma is confined to the luminal surface. In the Intraluminal unicystic ameloblastoma, the epithelium proliferates into the lumen and forms what protrude into the cyst lumen (Regezi et al., 1978).

The mural unicystic ameloblastoma is characterized by epithelial proliferation into the surrounding fibrous connective tissue wall. The infiltrative nature of the mural unicystic ameloblastoma renders it more aggressive than the other two unicystic ameloblastoma types. and similarly, aggressive as the solid/multicystic ameloblastoma.

The peripheral or extraosseous ameloblastoma variant is a benign neoplasm that occurs exclusively in the gingiva; it originates from either extraosseous remnants of the dental lamina or the basal cell layer of surface epithelium (Buchner and Sciubba., 1987). Peripheral ameloblastoma is rare and accounts for about 1 to 10% of the ameloblastoma variants and affects males more frequently than females (Philipsen et al., 2001). Histopathologically, peripheral ameloblastomas have the same features as the intraosseous form of the ameloblastoma (Barnes et al., 2005). Recurrence rates between 15% and 20% have been reported (Pogrel et al., 2009). Recurrent and primary peripheral ameloblastoma are treated by local excision (Pogrel et al., 2009). Malignant transformation of a peripheral ameloblastoma is infrequent (Neville., 2016).

Although some authors support conservative treatment of all ameloblastoma variants, many are in disagreement as a result of the more aggressive nature of the multicystic ameloblastoma and support radical treatment of multicystic ameloblastoma (Nakamura et al., 2002). Radical management of multicystic ameloblastoma involves resection of 1 to 1.5 cm of seemingly unaffected bony margins and adjacent soft tissue (Carlson and Marx, 2006; Pogrel et al.,

2009). They also reported 60-80% of recurrence rate following conservative management. Hertog et al., (2010) supported the radical approach with wider resection margins of 1.5 to 2cm of uninvolved bony margins. Muller and Slootweg (1985) reported a 5-15 % recurrence rate following radical resection including adjacent soft tissues. Sehdev et al., (1974) reported a 90% - 100% recurrence rate following curettage of ameloblastomas.

Unicystic ameloblastomas are treated conservatively or radically, depending on the preference of the surgeon (Neville et al., 2016). Concerning management of unicystic ameloblastoma, Seintou et al., (2014) observed good prognosis following conservative management of luminal unicystic ameloblastoma in a paediatric population sample. In contrast, intraluminal and mural type frequently resulted in recurrence. While Hirschhorn (2013) advocated a conservative approach in children with unicystic ameloblastoma and reserved the radical approach for recurrences, Swapnil et al., (2014), recommended radical resection of unicystic ameloblastomas in order to avoid further complications and recurrence. Georgios et al., (2014) suggested that smaller lesions be managed conservatively, even though the radical approach is the preferred treatment modality. Pogrel et al., (2009), recommended enucleation, curettage and physicochemical treatment with liquid nitrogen or Carnoy's solution. Radical treatment is recommended only if liquid nitrogen or Carnoy's solution is not available with resection margins of 0.5- to 1-cm (Pogrel et al., 2009).

Lee et al., (2004), suggested that the use of Carnoy's solution after enucleation of unicystic ameloblastoma is adequate; however, they reported a 10% recurrence rate. Lau et al., (2006) in their systematic review, reported recurrence rates of 3.6% for resection, 30.5% for enucleation and 16% for enucleation followed by Carnoy's solution for the management of unicystic ameloblastoma.

More than 50% of recurrences are diagnosed in the first year following primary surgery (Reichart et al., 1995; Olaitan et al., 1998; Hertog et al., (2010) However, Eckardt et al., (2009), recommended long term follow-up. Incomplete removal of ameloblastoma facilitates the spread of residual tumour cells leading to recurrence (To et al., 2002). Of the histological types follicular, granular, and acanthomatous had high recurrence, while desmoplastic had low recurrence; the plexiform growth pattern had lower recurrence than follicular, and unicystic ameloblastoma showed lower recurrence rates than multicystic ameloblastoma (Hong et al., 2007). According to Pogrel and Montes (2009), histological types are of no prognostic significance and demonstrate no association with ameloblastoma recurrence.

Hertog et al., (2010) demonstrated an association between recurrence and the method of surgical treatment; and no association between recurrence and the histological type. Abdel-Aziz and Amin (2012) reported a significant association between CD10 expression and Ki67 labeling index and ameloblastoma recurrence. Sweeney et al., (2014) suggested that SMO gene mutation appears to be associated with recurrence. Ameloblastic carcinoma is an uncommon malignant odontogenic tumour with a predilection for the posterior mandible and male patients above 45 years. The ameloblastic carcinoma may arise de novo or from a pre-existing peripheral or intra-osseous ameloblastoma (WHO, 2017). Clinically it may present with rapid growth, perforation of the cortex, infiltration of adjacent structures, cortical expansion and pain. Radiologically ameloblastic carcinoma is ill-defined and may show cortical destruction (Neville et al. 2016).

Histologically, ameloblastic carcinoma shows cytological atypia and the histological patterns of an ameloblastoma. Most metastases present in the lungs; cervical lymph node metastases are unusual (Kruse et al., 2009). The median survival rate is 17.6 years. The maxillary tumours are twice more likely to cause death than mandibular tumours (Rizzlitelli et al., 2015). Radical surgical excision is associated with a local recurrence of 28%. According to Yoon et al., (2009) radiotherapy is of little value in the management of this malignancy. Haung et al., (2014), however, advocates radiation therapy for management of ameloblastic carcinoma. Aggressive multimodality treatment is recommended (Li et al., 2014).

Metastasizing ameloblastoma is defined as a solid or multicystic ameloblastoma that metastasises despite its benign histological appearance. It represents 2% of benign ameloblastoma (Dissanayeke et al., 2011; Verneuli et al., 2002), and frequently involves the posterior mandible. Ameloblastic carcinoma and metastasizing ameloblastoma predominantly present in African males (Rizzitelli et al., 2015). The overall incidence is 1.79 cases per 10 million population per year.

Similar to ameloblastic carcinoma metastatic deposits are common in lung, followed by lymph nodes and bone (Dissanayeke et al., 2011). Approximately 50% of cases with metastases and long-term follow-up have died of their disease (Neville et al., 2016). Prognosis is poor and overall 5-year survival is 70%, depending on the site of metastatic deposits and surgical ease of access. Rizzitelli et al., (2015) reported that radiotherapy and chemotherapy have shown no benefit, the authors advocate neck dissection for cervical metastasizing ameloblastoma.

Aim

To determine the prevalence rate, clinic-pathologic and demographic factors that influence the recurrence of ameloblastoma in patients treated at the Wits Oral Health Centre.

Objectives

I. To describe clinicopathological and demographic features that affect the recurrence of ameloblastoma.
   - Histological type and growth patterns associated with recurrence.
   - Relationship between tumour size and recurrence.
   - Surgical treatment procedures associated with recurrence.
   - Patient demographics which includes age, gender and site of occurrence

II. To assess the prevalence rate in our unit in relation to what is reported in the literature

Rationale for the study

Recurrence rates are indicative of the inadequacy of the treatment procedure and may help inform the review of protocols for optimal management of ameloblastomas. Knowledge gained in determining factors associated with recurrence will help in reviewing ameloblastoma management protocols in order to minimize or prevent recurrences.

CHAPTER 2

RESEARCH METHODOLOGY

INTRODUCTION

In this chapter, we focus on the materials and methods used to conduct the study. This study was implemented in phases. A proforma was designed to enable the principal investigator to collect data. Permission to conduct the study was granted by various stakeholders prior to collection of data. The following phases are elaborated thoroughly: study design, study setting, inclusion and exclusion criteria, data collection, data analysis and ethical consideration.

Study design

A retrospective, cross-sectional, descriptive study was conducted on records of patients treated for ameloblastomas in the last twenty-four years (January 1992- December 2015).

Study setting

This study was conducted at the Wits Oral Health Centre, School of Oral Health Sciences, Faculty of Health Sciences at the University of the Witwatersrand. Only cases that were treated for ameloblastoma in the Department of Maxillofacial and Oral Surgery at their two academic facilities in Charlotte Maxeke Johannesburg Academic Hospital and Chris Hani Baragwanath Academic Hospital were considered. The Wits Oral Health Centre is situated in Johannesburg in the Gauteng province of the Republic of South Africa. Both hospitals submit biopsy specimen to the Department of Oral Pathology for microscopic examination and histopathological diagnosis. Data was extracted from the histopathological reports in the archives of the Department of Oral Pathology and from theatre notes.

Surgical protocol

The surgical protocol followed for radical resection of ameloblastomas in the Department of Maxillofacial and Oral Surgery has been reported (Ferretti et al., 2013). Surgical dissection is

supra-periosteal in the presence of cortical bone perforation or subperiosteal in the absence of cortical perforation. The tumour is resected 1-2 cm into uninvolved bone. A custom made 2.4 mm titanium reconstruction plate is used to reconstruct the bony defect. In cases, where disarticulation of the condyle is performed, a prosthesis called the 'Ferretti condyle' is used to replace the resected condyle, while a spacer is used to maintain the space of the mandibular defect in order to expedite secondary reconstruction phase. In the first seven days post-surgery, the patient feeds through a nasogastric tube. Maxillomandibular fixation (MMF) is applied for six weeks in order to prevent movement and is followed by reconstruction surgery. A particulated corticocancellous bone graft is harvested from the iliac crest bone and grafted to the mandibular defect; a costochondral graft is used to replace the 'Ferretti condyle'. MMF is then applied again for six more weeks during the healing phase of the graft. Implants are placed four months post the reconstruction phase, followed by rehabilitation with implant supported prosthesis. Six monthly reviews are conducted in first year of treatment followed by lifetime annual review. The surgery is performed by senior consultants assisted by senior registrars in the Department of Maxillofacial and Oral Surgery.

Inclusion criteria

The following inclusion criteria were used:

- A diagnosis of ameloblastoma must have been confirmed histologically by an oral pathologist.
- All patients treated for ameloblastomas from January 1992 - December 2015.
- All treatment modalities of ameloblastomas were included.
- All histological types of ameloblastomas treated were included.
- All ameloblastomas presenting in the mandible, maxilla and skull areas were included.

Exclusion criteria

The following exclusion criteria were used:

- Missing records.
- More than 20% missing data on variables for each case.

Data collection

A proforma (data collection tool) was design in order to assist in extraction of data. The following variables were included, age, gender (male/female), site of the tumour (mandible/maxilla/skull), tumour location (anterior/posterior), size of the tumour (less than 4cm/greater than 4cm), involvement of the inferior border (mandible) by the tumour (yes/no), tumour bony perforation (yes/no), ameloblastoma variant (unicystic/multicystic/peripheral), subtypes of unicystic ameloblastoma (luminal/intraluminal/mural), growth patterns of multicystic ameloblastoma (follicular/plexiform), histological types of multicystic ameloblastoma (basal/granular/acanthomatous/desmoplastic), treatment option (enucleation/enucleation and peripheral ostectomy/enucleation, peripheral ostectomy and cryotherapy/marginal resection/complete resection), histological margins (bone clear/not clear/soft tissue clear/not clear), site with close margins (buccal/lingual/inferior/proximal/distal), recurrence (yes/no), site of recurrence (primary bone/soft tissue/grafted tissue), time between primary surgery and recurrence (See annexure A).

Data analysis

Data was captured into a Microsoft excel spreadsheet and subsequently exported to Stata IC/14 software for analysis. Descriptive statistics of mean, standard deviation, frequencies, percentages and proportions were used to summarize the data.
Inferential statistics of Chi-squared test was used to determine the association between the categorical variables. Multivariate logistic regression was performed to determine the predictors of ameloblastoma recurrence. All statistical analysis was performed using a two-sided test at 0.05 level of significant.

Ethical consideration

Ethical clearance was obtained from both the Human Research and Ethics Committee (HREC) of Witwatersrand University and the Hospital Research and Ethics Committee (Wits Oral Health Centre) prior to data collection. The HREC clearance certificate was issued with reference no: M150841 (see Annexure B). The Hospital Research and Ethics Committee

reference no: WOHC/HREC/OCT/2015/03 (see Annexure C). Permission was also granted by the Head of the Department of Oral Pathology (see Annexure D). Strict confidentiality was adhered to. Codes were allocated to patient histological reports in order to protect patient identity. All patient identifiers were removed and kept on a separate link form (see Annexure E). Patient identifiers are only accessible to the principal investigator.

CHAPTER 3

General overview of treated ameloblastomas at Wits Oral Health Centre between the years 1992-2015

The study evaluated the histopathological reports of 254 ameloblastoma cases treated at the Wits Oral Health Centre from 1992 to 2015. More than 20% of the assessed variables were missing in eight cases which were thus excluded from the study. A total of 246 histopathological reports fulfilled the inclusion criteria. Males (49.6%) and females (50.4%) were equally represented (Table 3.1).

Table 3.1 Gender distribution of ameloblastoma

GENDER	NO OF PATIENTS	PERCENT
Female	124	50.4
Male	122	49.6

The mean age for ameloblastoma diagnosis was 31 years (age range: 3-82 years) (Fig 3.1). Most cases presented in the third decade of life (34.6%) followed by the second (21.5%), and fourth (18.70%) decades.

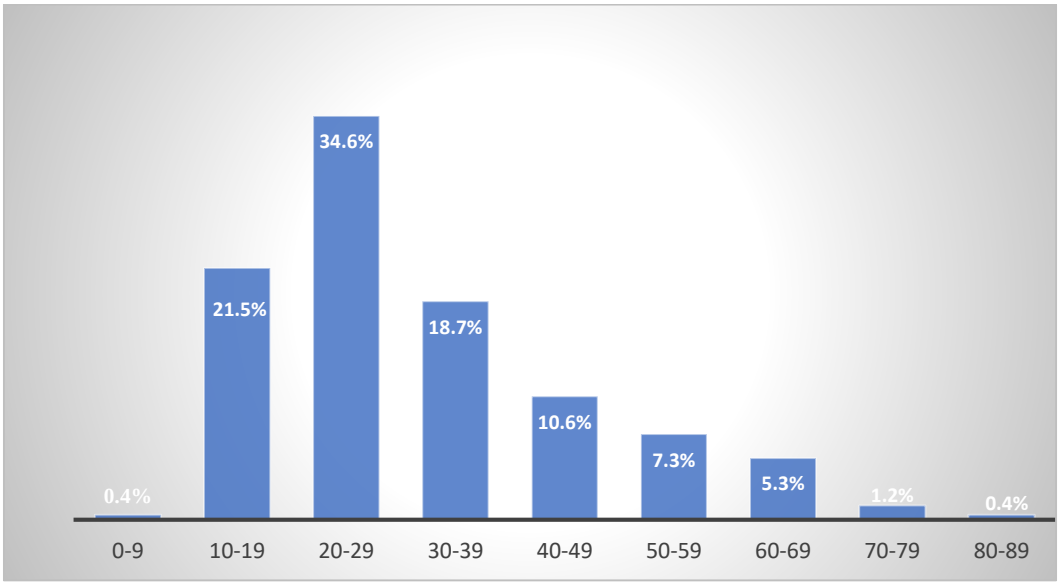

Fig 3.1 Age at treatment (in years) distribution of ameloblastoma

The majority (96%, n=235) of cases presented in the mandible while 4,47 % presented in the maxilla (Fig 3.2).

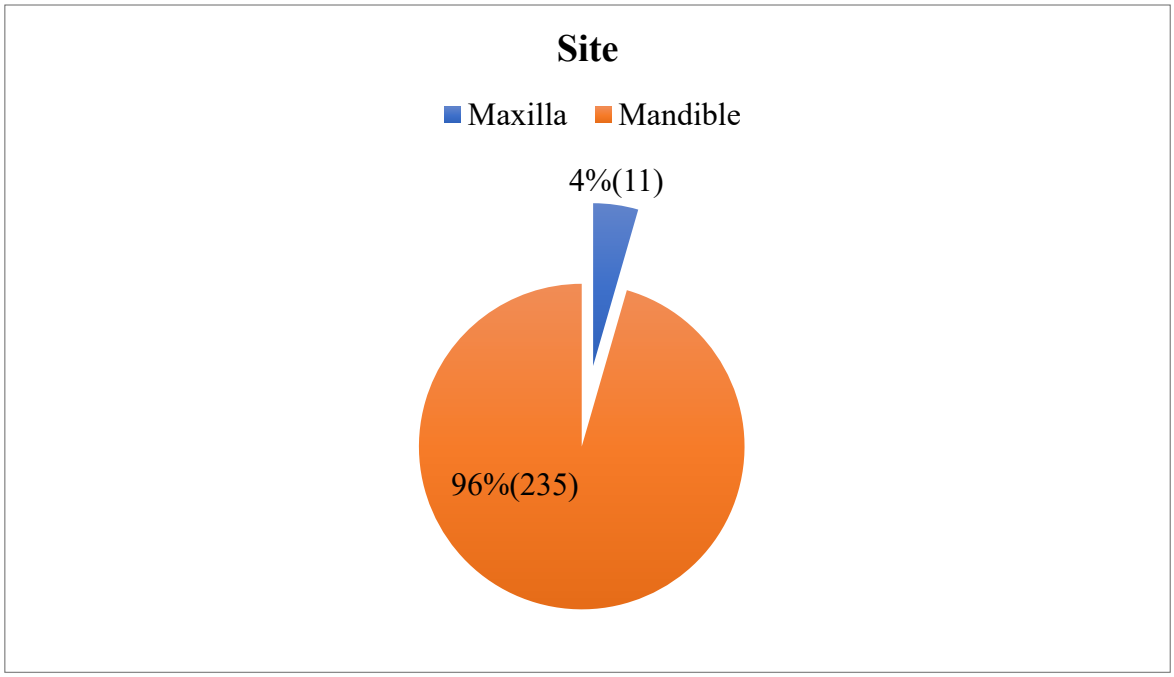

Figure 3.2 Anatomical site of involvement

The size of the tumour was recorded in 244 cases. Of these, 85% (209) were 4 cm or larger in greatest diameter and 14% were less than 4cm. (Fig 3.3).

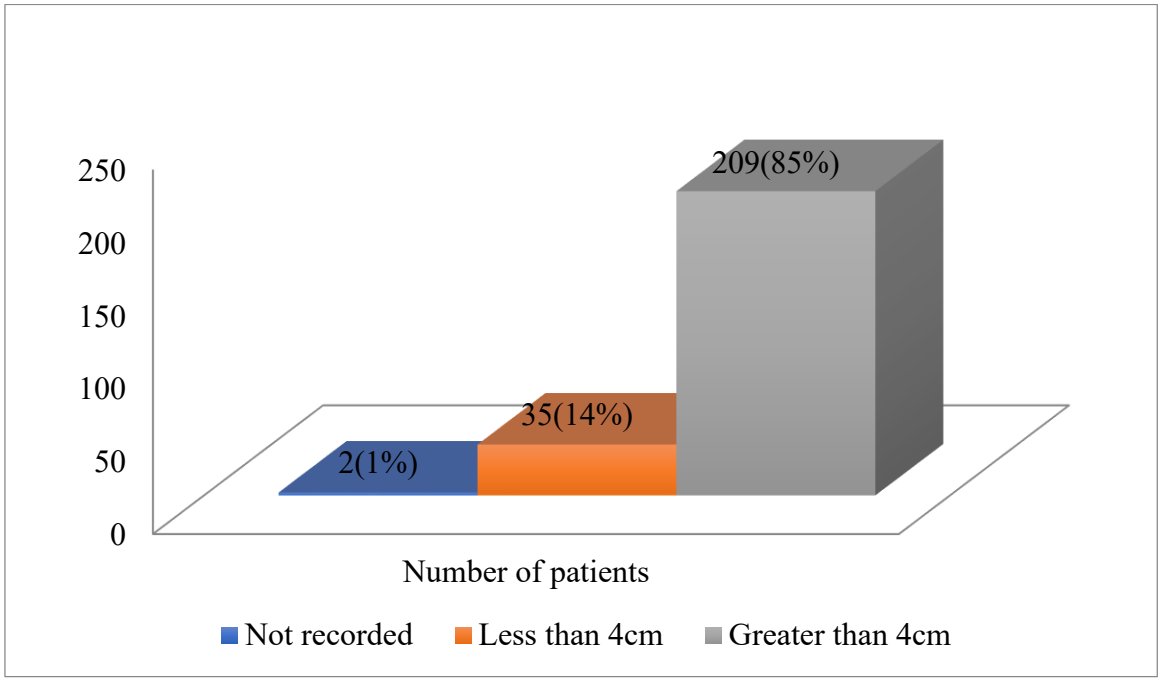

Figure 3.3 Size of ameloblastoma

The majority of the ameloblastomas (92.7%), had perforated the bone and encroached on the soft tissues at the time of treatment. (Fig 3.4).

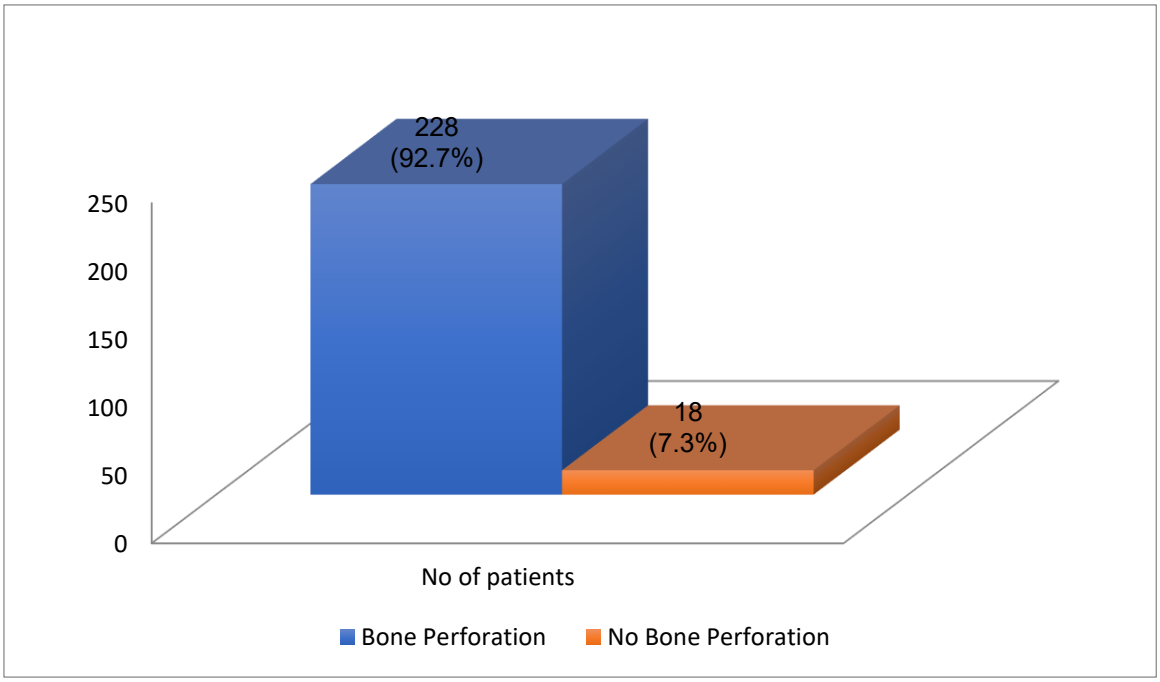

Figure 3.4 Bone perforation by ameloblastoma

Of the 246 cases, 231 were diagnosed as benign AMB's comprising 189 multicystic, 41 unicystic and one peripheral ameloblastoma, one adenoid ameloblastoma with dentinoid ghost cells, two malignant ameloblastomas; 13 cases were not subtyped. (Fig 3.5).

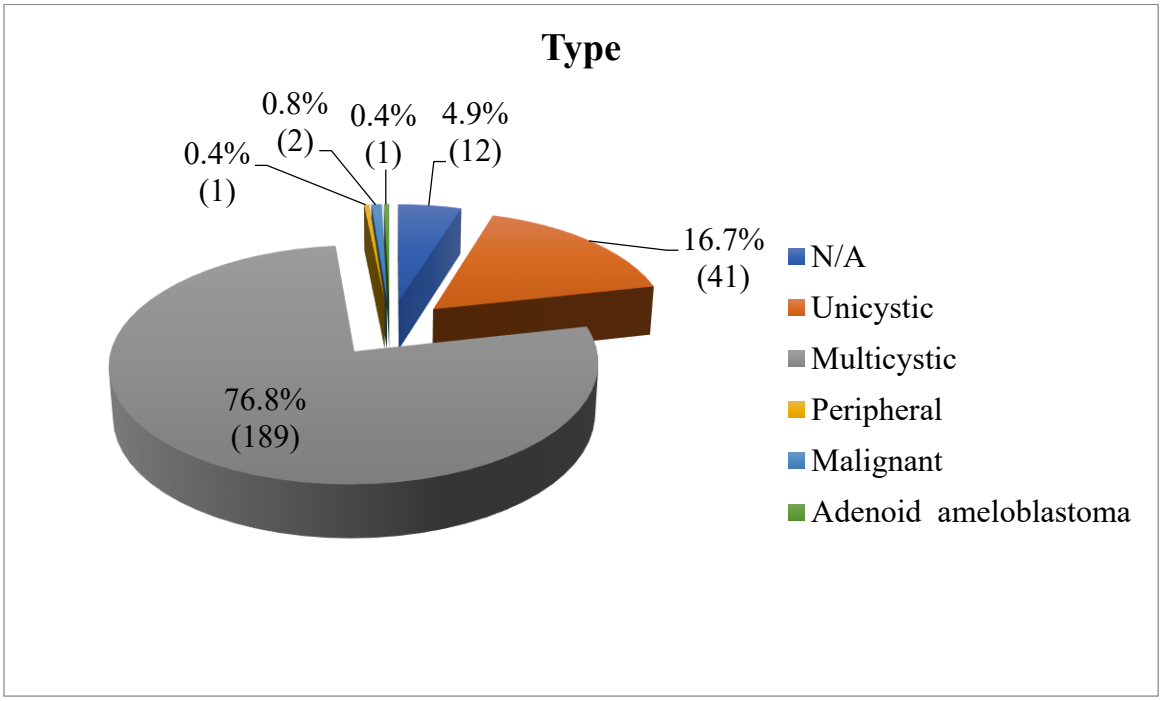

Figure 3.5 Ameloblastoma variants

Ameloblastoma variants, growth patterns and histological types were not specified in 125(51%) cases. Thirty-nine (95.12%) unicystic ameloblastomas were subtyped into luminal (28.20%, n=11), intraluminal (17.95%, n=7), and mural (53.85%; n=21). The growth pattern was reported in 67 cases of multicystic ameloblastoma and included follicular (28), plexiform (8) and mixed follicular-plexiform (26). The histological subtypes reported include basal, granular, acanthomatous and desmoplastic ameloblastoma (Table 3.2).

Table 3.2 Ameloblastoma variants, growth patterns and histological types

SUBTYPE	**FREQUENCY**	**PERCENT**
Not available	125	51
UNICYSTIC VARIANT		
Luminal	11	5
Intraluminal	7	3
Mural	21	9
TOTAL:	39	
GROWTH PATTERNS OF MULTICYSTIC AMELOBLASTOMA		
Follicular	28	9
Plexiform	13	3
Follicular and plexiform	26	9
TOTAL	67	
HISTOLOGICAL TYPES OF MULTICYSTIC OF MULTICYSTIC AMELOBLASTOMA		
Basal	6	1
Granular	20	3
Acanthomatous	1	0
Desmoplastic	1	0
TOTAL:	28	

Of the 246 cases, 244 were treated either conservatively or radically. The treatment option could not be discerned in 2(0.2%) cases. Twenty-eight cases were treated conservatively; 8 (3.3) by enucleation only, 17(6.9%) by enucleation and peripheral ostectomy, 2 by marsupialization and 1(0.4%) by excision. Of the 216 cases treated radically, 213 were completely resected while 3 were marginally resected (Fig 3.6).

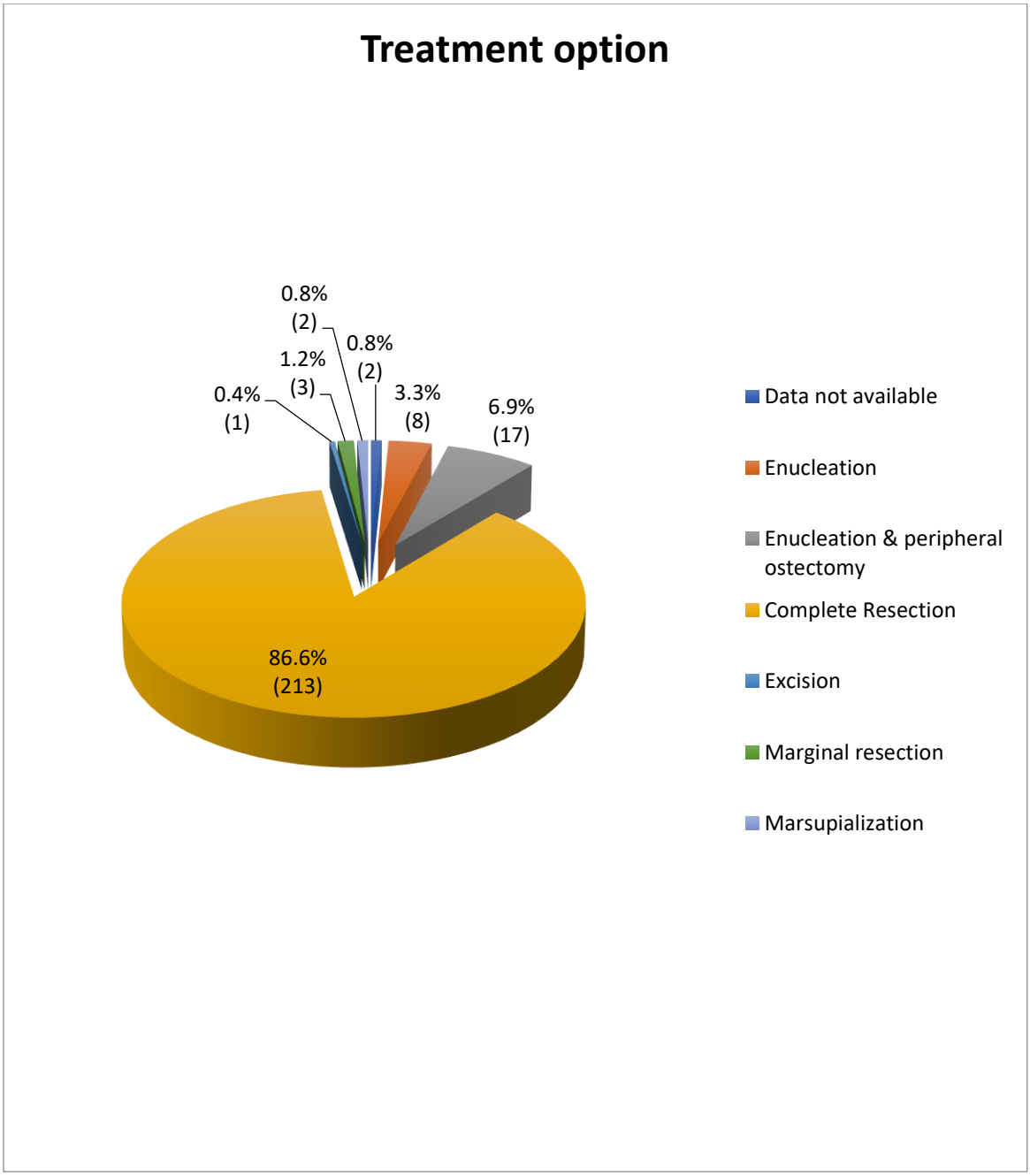

Figure 3.6 Treatment options for ameloblastoma

The assessment of histological margins was carried out in radically treated cases only. The nature of the histological margins was not reported in 10 cases. The bone and soft tissue margins were reported to be clear in 135 cases. The soft tissue margins were not clear in 63 cases, while bony margins were not clear in 7. In one case both the bony and soft tissue margins were not clear (Table 3.3).

Table 3.3 Nature of histological margins of ameloblastoma

MARGIN	FREQUENCY	PERCENT
Not available	3	4.63
Clear	135	62.5
Soft tissue not clear	63	29.17
Bone not clear	7	3.24
Bone and soft tissue not clear	1	0.46

Of the 246 patients treated either conservatively or radically, 7 % (n=19) presented with recurrent ameloblastoma. No recurrence was recorded in the remaining 227 patients (92.3%), however, most patients were lost to follow up (Table 3.4).

Table 3.4 Recurrence rate of ameloblastoma

RECURRENCE	FREQUENCY	PERCENT
No	227	92.3
Yes	19	7.7

3.2.1. Association between clinicopathological factors and recurrence

The mean age of patients with recurrent AMB was 33 years (range: 7 -61 years). Most recurrences occurred in the third (n= 5; 26.32%) and fifth (n=4; 21.05%) decades of life. The first and seventh decades were the least affected. (1%) (Table 3.5).

Table 3.5 Association between age and recurrence

AGE	NO OF PATIENTS	PERCENT
0-9	1	5.26
10-19	3	15.79
20-29	5	26.32
30-39	3	15.79
40-49	4	21.05
50-59	2	10.53
60-69	1	5.26

Although ameloblastoma showed no significant gender predilection, 63% of the recurrences occurred in females (Table 3.6).

Table 3.6 Association between gender and recurrence

GENDER	NO OF PATIENTS	PERCENT
Female	12	63.16
Male	7	36.84

Three sites of recurrence were identified: primary bone, soft tissue and grafted tissue. Most of the recurrences occurred in soft tissue (52.63%), 31.58%% in primary bone and 15.79% cases in grafted tissue (Fig 3.7).

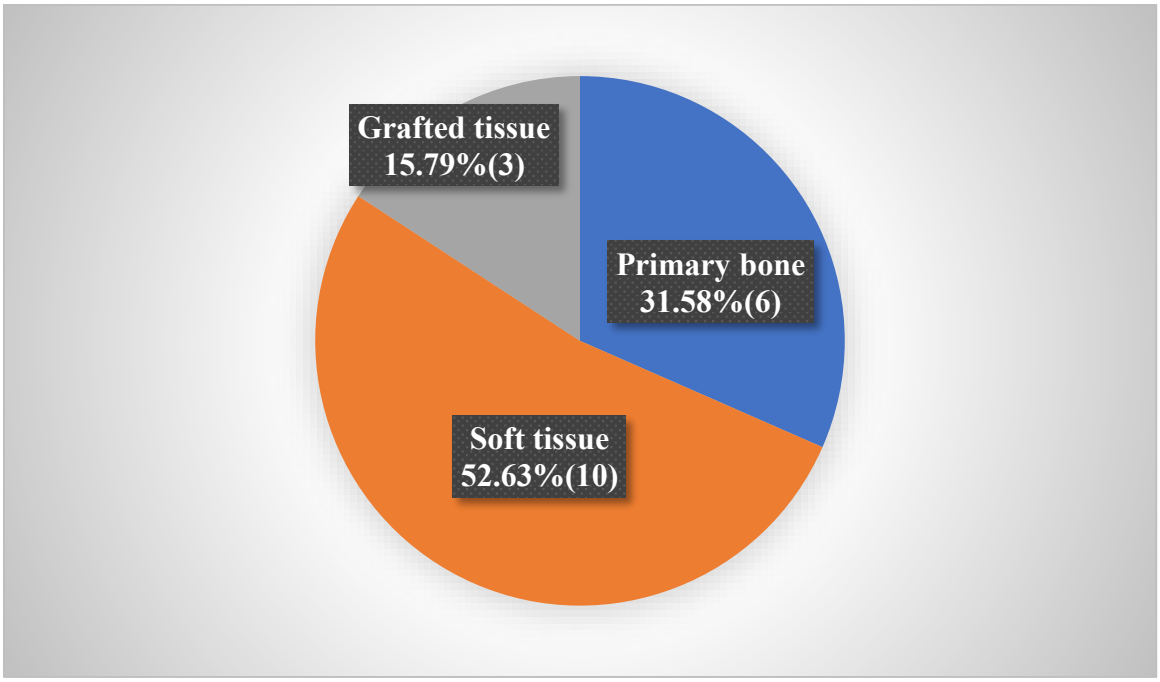

Figure 3.7 Site of recurrence

Fifteen (78.95%) recurrent ameloblastomas presented within 10 years of the surgical treatment with the remaining three cases presenting 13, 17 and 21 years post treatment. (Table 3.7)

Table 3.7 Association between post-surgical treatment period and recurrence

RECURRENCE TIME (YEARS)	FREQUENCY	PERCENT
1	4	21.05
3	2	10.53
4	2	10.53
8	4	21.05
9	2	10.53
10	1	5.26
13	2	10.53
17	1	5.26
21	1	5.26

Most recurrent ameloblastomas had perforated the bone at the time of treatment (n=16; 84,21%), with only 3 (15.79%) not demonstrating bone perforation. (Table 3.8). Ameloblastomas larger than 4cm in greatest diameter showed a high propensity to recur (84, 21%) (Table 3.9).

Table 3.8 Association between bone perforation and recurrence

Bone perforation	Frequency	Percent
No	3	15.79
Yes	16	84.21

Table 3.9 Association between tumour size and recurrence

Size of the tumor	Frequency	Percent
Less than 4cm	3	15.79
Greater than 4cm	16	84.21

3.2.2. Association between the clinicopathological and demographic variables and recurrence

Table 3.10 Chi-squared test of association

Variables	**Pearson chi2**	**P-value**
Age	6.17	0.63
Gender	1.34	0.25
Site	1.77	0.18
Size	0.21	0.90
Bone perforation	2.18	0.14
Ameloblastoma variant	2.23	0.82
Subtype	26.7	0.063
Treatment option	17.03	0.009
Histological margins	19.57	0.001

Chi-square test of association was performed between the clinicopathological and demographic variables (age, gender, site, size, bone perforation, type, subtype, treatment option, histological margins) and ameloblastoma recurrence. The association between recurrence and ameloblastoma subtypes was marginally significant (p=0.063). The association between treatment option and the nature of histological margins was statistically significant (p = 0.009 and p= 0.001 respectively).

Multivariate logistic regression analysis was performed to determine the risk of recurrence. The clinicopathological and demographic variables with p values ≤ 0.01 from the chi-squared analysis were entered into logistic regression.

Table 3.11 Multivariate logistic regression analysis for the risk of recurrence

Variable	Odds ratio	P-value	95% Confidence interval	
Site	0.094	0.329	-0.095	0.284
Bone perforation	0.055	0.500	-0.106	0.217
subtype	-0.002	0.534	-0.010	0.004
Treatment option	-0.013	0.703	-0.083	0.056
Histological margin	0.094	0.011	0.037	0.152

Treatment option, ameloblastoma subtype and bone perforation had the highest significant p-values (p=0.703, p=0.534 and p=0.500) respectively and were eliminated. The second logistic regression was performed.

Table 3.12 Second multivariate logistic regression analysis for the risk of recurrence

Variable	Odds ratio	P-value	95% Confidence interval	
Site	0.082	0.370	-0.098	0.263
Histological margin	0.084	0.002	0.030	0.139

The site of involvement showed a statically insignificant association with recurrence (p value =0.370). Histological margins showed a statistical significant association with recurrence (p value = 0.002). Histological margins have a 0.08 likelihood to be associated with recurrence at 95% CI (0.030-0.139).

3.2.3. Association between surgical treatment option and recurrence

Fifteen (78.95%) of the 19 cases that recurred were radically treated by complete resection while 4 were treated conservatively. Of the 4 conservatively treated cases, 1 (5.26%) was marsupialised, and 3 (15.79%) enucleated (Fig 3.8).

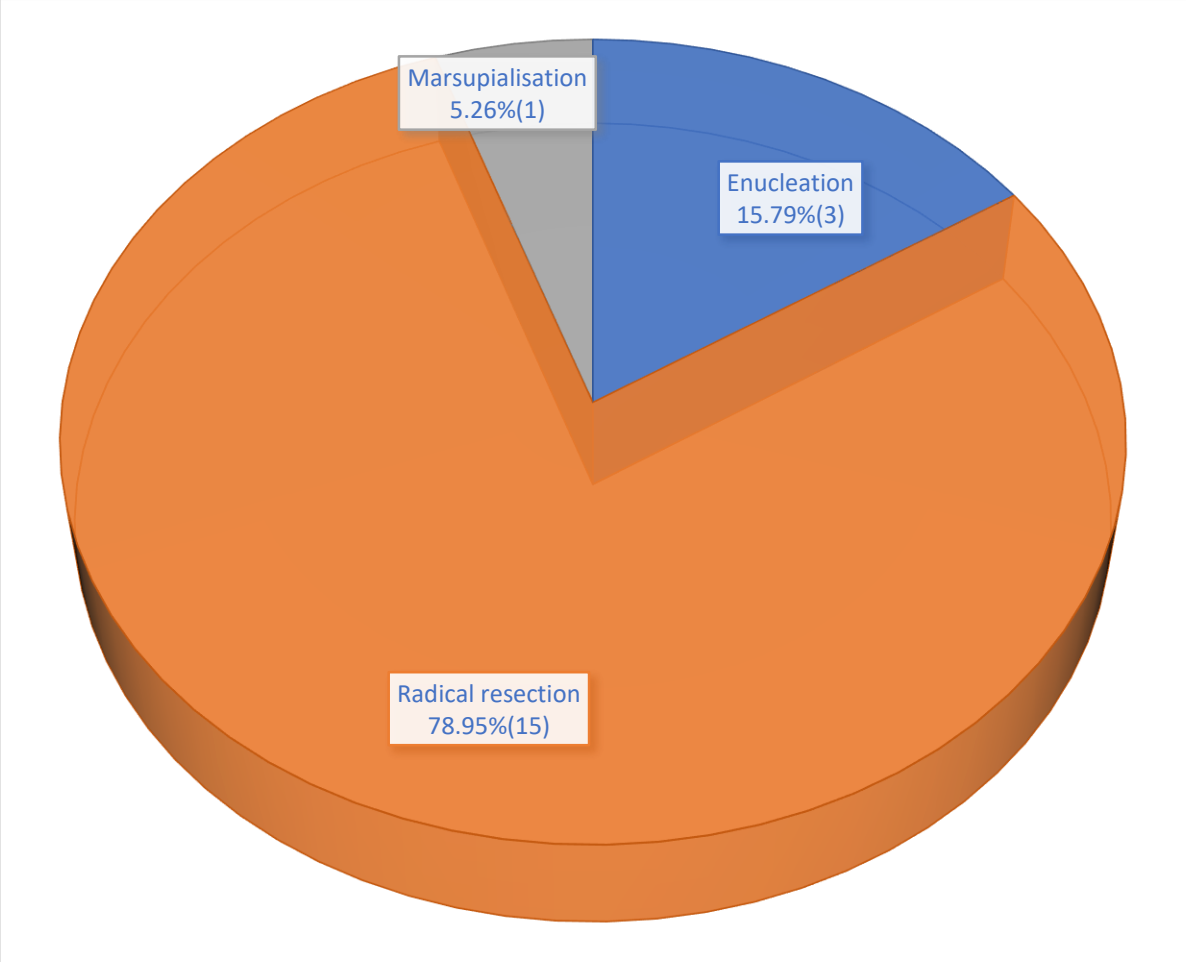

Fig 3.8 Association between surgical procedure option and recurrence

Three (11%) unicystic and 16 (89%) solid/ multicystic ameloblastomas presented with recurrence (Fig 3.9). The unicystic ameloblastomas comprised one mural and two intraluminal subtypes. Of these, two were mixed follicular and plexiform, two were follicular and the growth pattern of the remaining three is unknown. Reported histopathological subtypes include granular, and acanthomatous. (Table 3.13)

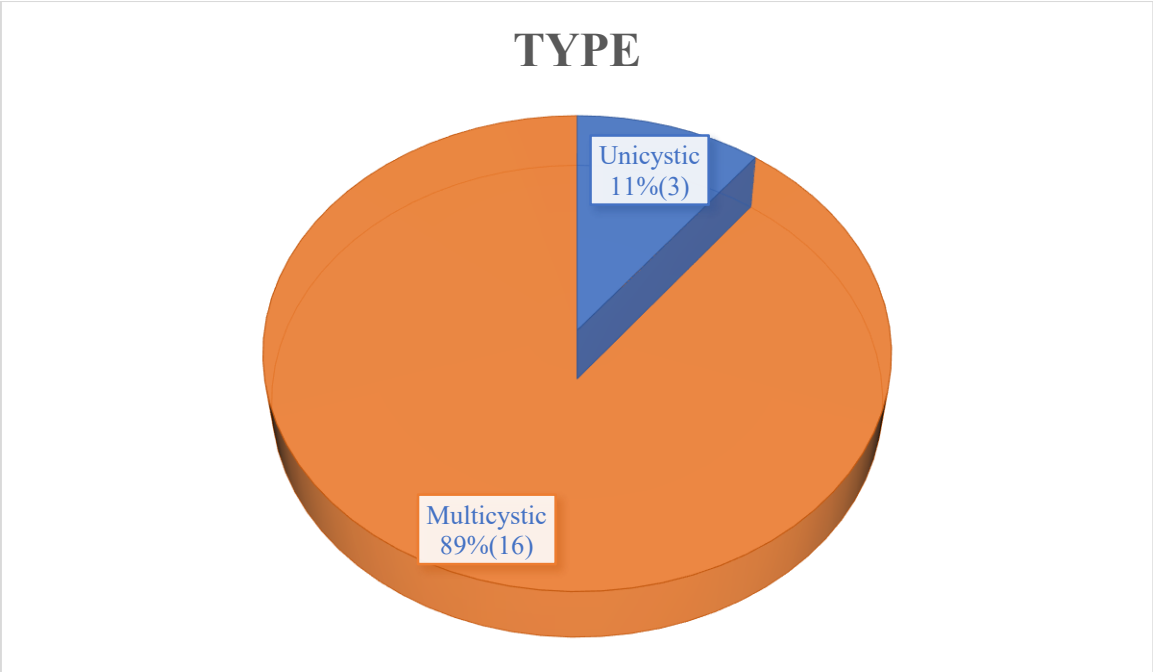

Figure 3.9 Association between ameloblastoma variants and recurrence

Table 3.13 Association between histological type of ameloblastoma, growth pattern and recurrence

SUBTYPE	FREQUENCY	PERCENT
Not available	9	47.37
Intraluminal	2	10.53
Mural	1	5.26
Follicular	2	10.53
Granular	2	10.53
Acanthomatous	1	5.26
Follicular and plexiform	1	5.26
Follicular and plexiform and granular	1	5.26

Chapter 4

Introduction

In this chapter, we discuss the current results compared to the findings of previous studies. We summarise our outcomes which form the basis of recommendations made. Limitations are acknowledged and reflected upon.

Discussion

The incidence of ameloblastoma in South Africa is 2.4-fold higher than the global incidence per million population per year (Shear et al., 1978). Several West African studies (Sawyer et al., 1985; Odukoya et al., 1995; Ajayi et al., 2004) have reported similar findings. The reported discrepancies in the relative frequency of ameloblastoma and clinicopathological features have been attributed to genetic and external factors (Philipsen et al., 1998). Contrarily, a study from Tanzania, East Africa reported an ameloblastoma incidence of 0.68 per million per year, similar to those reported in European countries such as the Netherlands and Sweden (Simon et al., 2005). This finding was confirmed by Oginni et al., (2015) who conducted a prospective study of patients presenting with odontogenic tumours at all Oral and Maxillofacial Departments in Nigeria. The authors reported a relative frequency of 0.76 per million per year comparable to the global incidence of 0.5 per million per year. Ameloblastoma is the most common benign odontogenic tumour in China (Lu et al., 1998) and Africa (Mosadomi, 1995; Barnes et al., 2005)

Age

In this study, the age at treatment ranged from 7-82 years with a mean age of 31 years. Similarly, Adeline et al., (2008), in their 10-year audit of ameloblastoma in Kenya, reported a mean age of 30.2 years while Olaitan et al., (1993) reported a mean age of 30 years at the time of treatment. Santos et al., (2014), in their review of 112 cases of ameloblastoma, reported a slightly higher mean age of 35.1 years. Multicystic ameloblastoma is rarely seen in the first two decades of life, conversely unicystic ameloblastomas occurs earlier in life, mostly in the second decade (Neville et al., 2016).

Only 21.05% recurrences were detected in patients younger than 20 years. This study found that the mean age at recurrence was 33.32 years (range: 7-61 years). This is lower than the 26.4 years (range, 11-52 years) reported in a Korean study (Kim and Young., 2001). No significant association was documented between age and recurrence.

Gender

Although most recurrences presented in females, no statistically significant association was found between recurrence and gender as documented in other studies (Abdel-Aziz and Amin., 2012; Ahlem et al., 2015; Hong et al., 2007). No significant gender predilection was seen in primary ameloblastoma with 50, 4% females and 49, 6% males. This result concurs with the findings of numerous published series (Simon et al., 2005; Ladeinde et al., 2006; Okada et al., 2007; Adeline et al., 2008; Gunawardhana et al., 2010;). However, some studies, particularly in Africa and Asia have reported a male predilection. Olaitan et al., (1993) documented 61.9% ameloblastomas presenting in males and 38.1% in females. This finding corroborates that of Kim and Jang (2001) who reported 55% males and 45% females in a Korean sample. Furthermore, in India, Nalabolu et al., (2016), reported a male predilection with 69, 6% males afflicted by ameloblastoma.

Localisation

There is consensus amongst researchers that ameloblastomas have a predilection for the lower jaw with approximately 80% presenting in the mandible in most studies (McClary et al., 2015). Mandibular predilection as high as 87.3% (Kim and Young., 2001) and 92% (Ahlem et al., 2015) has been reported. The findings in the abovementioned studies corroborate my results which showed 96% mandibular involvement. Nevertheless, noteworthy discrepancies in the mandible-maxilla ratios have been demonstrated. The mandible-maxilla ratio in this study was 1: 0.05 while in Egypt and Nigeria, Tawfik et al., (2010) and Adebiyi et al., (2006) reported ratios of 1: 0.1 and 1: 0.03 respectively. In Sri Lanka, ratios of 1: 0.06 and 1: 0.13 were reported three years apart by different authors (Okada et al., 2007; Gunawardhana et al., 2010). This study documented recurrences mostly in the mandible (89.47%) with only 2 of 19 (10.53%) presenting in the maxilla thus corroborating the findings of previous studies (Olaitan et al., 1993; Reichart et al., 1995). Comparison of the findings with those of Hong et al., (2006), confirms that the association between the risk of recurrence and the location of the tumour is not significant.

Tumour Size

The impact of socioeconomic factors on demographic features and clinical outcome cannot be overemphasised (Butt et al., 2011). In developed countries such as the Netherlands, ameloblastomas are often diagnosed early during routine radiographic examination as an incidental finding (Hertog et al., 2012). Tumours reported in African and Asian literature tend to be larger than those reported in other regions of the world (Adekeye et al., 1986; Olaitan et al., 1998; Adebayo et al., 2011). Factors contributing to the larger size include delay in presentation, often following consultation with traditional healers or patients seeking medical attention only when aesthetically and/or functionally compromised, limited access to healthcare services; refusal of treatment, skill shortage, lack of adequate facilities, low socioeconomic status and level of education (Simon et al., 2005; Adebayo et al., 2011).
In accordance with several African studies most tumours (85%) were larger than 4 cm in greatest diameter and involved both the anterior and posterior regions of the affected jaws. Santos et al., (2014), in their Brazilian study, reported tumour diameters ranging from 3.0 - 6.9 cm in 63% of 112 ameloblastomas reviewed while Dandriyal et al., (2011), observed tumour sizes between 4 and 8 cm. Fifty percent of tumours in a study by Ruhin-Poncet et al., (2011) were 5 to 13 cm in greatest diameter. A Tunisian study documented a mean tumour size of 4 cm, a range of 5-15 cm (Ahlem et al., 2015) and smaller than the average tumour size of 4.3 cm and maximum size of 24 cm reported by Reichart et al., (1995) in one of the largest reviews of ameloblastomas. Carlson and Marx (2006) cautioned that large tumours complicated by airway compromise and metabolic abnormalities may be potentially life threatening. Similar to Abdel-Aziz and Amin (2012) who reported a higher recurrence rate in large ameloblastomas, most recurrences in this study occurred in tumours larger than 4 cm. Nonetheless, in both studies, this finding did not translate to a statistically significant risk of recurrence in relation to the size of the tumour.

At the time of treatment, 93% of the ameloblastomas had perforated the bone leading to supraperiosteal dissection and soft tissue encroachment. This finding may be due to the large tumour size at the time of treatment. The larger the tumour, the greater the risk of cortical perforation and subsequent soft tissue infiltration. In contrast, a study conducted in Thailand reported bone perforation in only 6,7% of their ameloblastomas (Intapa, 2017).

Ameloblastoma variants

The solid/multicystic ameloblastoma was the most common variant (76.8%) followed by unicystic (16.7%), peripheral (1%) and malignant ameloblastoma (1%). The present findings are consistent with other research which found similar relative frequencies for the different ameloblastoma variants. Adeline et al., (2008) and Santos et al., (2014) reported slightly higher relative frequencies for solid/multicystic ameloblastoma at 83% and 83.8% respectively, while the former reported a relative frequency of, 5.3% for unicystic ameloblastoma and 0.5% for peripheral ameloblastoma, the latter reported a higher relative frequency of 15.3% for unicystic ameloblastoma and 0 % for peripheral ameloblastoma. Siar et al., (2012), in a retrospective analysis of 340 cases in a Malaysian population, reported 65%, 28% and 0.6% solid/multicystic, unicystic and peripheral ameloblastomas respectively.

Histological type of Ameloblastoma

Solid/multicystic ameloblastoma may show follicular and plexiform growth patterns and varied histological types including basaloid, granular, acanthomatous, and desmoplastic (Kramer et al., 1992). In the current study, the growth pattern was specified in 56 (29.63%) of 189 multicystic ameloblastomas. In agreement with studies conducted in America (Waldron et al., 1987; Tanzania (Simon et al., 2005); Nigeria (Odukoya et al., 2008; Chukwuneke et al., 2016), France (Ruhin-Poncet et al., 2011), and Tunisia (Ahlem et al., 2015), the follicular growth pattern was more common than the plexiform, although, most tumours with a specified growth pattern showed a mixed follicular-plexiform (n= 26, 46.43%) growth pattern. In contrast some studies have reported the plexiform as the more common growth pattern (Kim and Young., 2001; Nakamura et al., 2002; Tawfik et al., 2010; Saghravanian et al., 2017).

Ameloblastoma Growth Patterns

Ueno et al., (1989), Nakamura et al., (2002) and Ruhin-Poncet et al., (2011) reported significantly higher recurrence rates in follicular ameloblastoma than in plexiform ameloblastoma. Hong et al., (2007) reported a statically significant association between the risk of recurrence and the follicular growth pattern as well as the granular and acanthomatous histological types of ameloblastoma. In contrast, no significant association was demonstrated between recurrence and growth patterns in this study. Additionally, the histology type was of

no prognostic significance and was specified in 28 (41.81%) of 189 multicystic ameloblastomas, which included granular (20), basal (6), acanthomatous (2) and desmoplastic (1) ameloblastoma. There is general consensus that ameloblastoma histology type is not a predictor of biological behaviour or recurrence. These results parallel those of numerous studies including Pogrel et al., (2009) and Hertog at el., (2012). Conversely, Carlson and Max, (2006) stated that the histological type may be an important prognostic indicator.

Surgical treatment methods

The mainstay of treatment for ameloblastoma is surgical intervention comprising radical or conservative approaches (Effiom et al., 2017). Radical treatment encompasses marginal, segmental or complete resection with a margin of 1-1.5 cm. Adebayo et al., (2011) suggested a margin of 1.5 -2 cm for maxillary ameloblastomas. Conservative treatment includes enucleation without adjuvant therapy, enucleation with peripheral ostectomy, cryotherapy or Carnoy's solution as adjuvant therapy or on its own. Different authors advocate different treatment options based on a number of factors including ameloblastoma variant, size of the lesion and age of the patient. The choice of surgical treatment is an important factor in predicting the risk of recurrence, even more so if the primary ameloblastoma is inadequately removed (Rastogi et al., 2010). Recurrence is therefore perceived to be indicative of failure of the initial tumour treatment (Mosadomi et al., 1975; Demeulemeester et al., 1988; Olaitan et al., 1993; Hong et al., 2007; Adebayo et al., 2011). The choice of treatment is often a balance between adequate removal of tumour to prevent recurrence and preservation of adjacent tissue to minimise morbidity attributable to complications associated with aesthetics, function and psychological well-being of the patient (Hong et al., 2007). Researchers, who advocate the radical approach, consider the locally aggressive nature of ameloblastoma as intermediate between benign and malignant neoplasms (Hong et al., 2007). Slootweg and Muller (1984) recommended radical treatment following observation of metastases post conservative management of primary ameloblastomas, hence the recommendation of a radical approach by the authors. Sampson and Pogrel (1999) and Dandriyal et al., (2011) advocate radical treatment following the observation of high recurrence rates in conservatively managed tumours. As proponents of conservative management, Sammartino et al., (2007) and Feinberg et al., (1996) argue that although ameloblastomas are locally aggressive, they are benign tumours, they rarely metastasise and should therefore be treated accordingly. Furthermore, the authors are of the view that the significant morbidity associated with radical treatment is not justifiable. For these reasons Sammartino et al., (2007), McClary et al., (2015) and Haqa et

al., (2016) support conservative management for ameloblastomas irrespective of size or variant.

The choice of treatment in this sample was mainly determined by the size of the tumours. Due to the large, infiltrative and expansive nature of tumours at the time of presentation, most were treated radically either by complete (86.6%) or marginal (1.2%) resection. This practice is in line with a recommendation by Antonoglou and Sandor (2015) to treat smaller tumours conservatively and larger tumours or solid/multicystic ameloblastomas radically. Dandriyal et al., (2011) and Kovács et al., (1999) advocated radical resection for large expansive tumours as seen in this study. Most tumours had perforated the cortical bones with subsequent infiltration of the adjacent soft tissue and were therefore treated by radical resection. Of the conservatively treated tumours, most were treated by enucleation with peripheral ostectomy. According to Hong et al., (2007) the association between the treatment of choice and the risk of recurrence is statistically significant; this result is in agreement with the findings in this study.

Factors associated with ameloblastoma recurrence include inadequate surgical removal of the primary tumour and the resultant infiltration of adjacent tissue by residual tumour cells (To et al., 2002), tumour growth patterns and histological types, (Hong et al., 2007), method of surgical treatment (Hertog et al., 2010), and local invasiveness (Ribeiro et al., 2009: Zhang et al., 2010). In the maxilla, site of tumour involvement, root resorption, and infiltration of maxillary antrum are associated with increased risk of recurrence (Yang et al., 2017).

Robinson et al (1977) reported a lower recurrence rate for conservatively treated unicystic ameloblastomas than multicystic ameloblastoma. Muller et al., (1985) confirmed these findings when they reported recurrence rates of 75% and 20% following conservative treatment of multicystic and unicystic ameloblastomas respectively. In a key systematic review and meta-analysis of recurrence rates in ameloblastoma Almeida et al., (2016) documented a 3.15-fold greater relative risk of recurrence following conservative treatment of multicystic ameloblastoma compared to radical treatment. In the current study, of the 7.7% (19 of 246) ameloblastomas that recurred, 3 (11%) and 16 (89%) were in primary unicystic and multicystic ameloblastomas respectively. This finding supports previous research which documented the highest rate of recurrence in multicystic ameloblastomas (Ueno et al., 1989; Nakamura et al., 2002; Hong et al., 2007; Antonoglou and Sandor., 2015). Although Olaitan et al (1998) reported a comparable overall ameloblastoma recurrence rate of 8.9% in Nigeria;

the authors did not distinguish the rate of recurrence between unicystic and multicystic variants.

Histological Margins

Tumours were resected with margins of 1-2cm; the margins were assessed histologically to confirm complete removal of tumour. Logistic regression was performed to determine the association between the variables investigated and recurrence. The association between histological margins and recurrence was statistically significant (p *value = 0.002*). Histological margins had 0.08 likelihood to be associated with recurrence at 95% CI. To et al (2002) reported a similar finding; inadequate surgical removal of tumour is associated with a risk of recurrence.

More recurrences are seen in primary bone than in soft tissue. Adebayo et al., (2011) reported a case that recurred in soft tissue 21 years after radical resection. Four (19%) of 21 recurrences reported by Olaitan et al., (1998) were in soft tissue and 17(81 %) in bone. Arotiba et al., (2007) documented 4/30 (13.3%) recurrent ameloblastomas. Contrarily, most recurrences in this study occurred in soft tissue (53%) followed by 31% in primary bone and 15.79% in grafted tissue. Although not as common, recurrences in bone grafts have been reported by Choi et al., (2006) and Eckardt et al., (2009).

In our sample, 42% and 79% recurrences occurred within 5 and 10 years of treatment of the primary tumour. The mean follow-up period (7, 5 years) is lower than the 10.5 years reported by Hertog et al., (2012) and consistent with numerous studies with inadequate follow up periods. Although recurrences can occur up to 50 years after treatment of the primary tumour, 50% occur within 5 years of the primary surgery (Muller and Slootweg, (1985); Reichart et al., 1995; Kim and Jang., 2001; Pogrel et al., 2009; Hertog et al., 2012). Olaitan et al., 1998 reported 80% recurrence within the first five years. Morita et al., (2013) reported two cases that recurred 40 and 50 years after radical treatment of the primary ameloblastomas. These late recurrences have led to recommendations of life long follow up periods (Reichart et al., 1995; Olaitan et al., 1998; Adebayo et al., 2011)

4.2 Limitations

Missing data compromised the study, particularly the evaluation of histological types. The follow up period was inadequate with most patients lost to follow up, however this is a frequently reported limitation in similar studies. A small number of ameloblastomas were treated conservative thus compromising the analysis in this subgroup

4.3 Conclusion

Our findings are in agreement with most published studies with regard to demographic data and clinico-pathological features of ameloblastoma. Multicystic ameloblastoma is associated with a higher risk of recurrence than other variants. We therefore recommend marginal resection of smaller multicystic ameloblastoma. Enucleation with peripheral ostectomy was effective treatment approach for small unicystic ameloblastoma. Prior to adoption as standard protocol, more studies with large sample sizes and long-term follow-up are recommended. Statistically significant associations were identified between histological margins and recurrence as well as between surgical procedure and recurrence. We therefore recommend a radical approach with resection margins of 1 to 2 cm as the treatment of choice for larger tumours.

References

Abdel-Aziz, A., Amin, M.M., 2012. EGFR, CD10 and proliferation marker Ki67 expression in ameloblastoma: possible role in local recurrence. Diagn Pathol 7(14): 1-17.

Ackermann, G.L., Altini, M., Shear, M., 1988. The unicystic ameloblastoma: a clinico-pathological study of 57 cases. J Oral Pathol 17: 541-546.

Adebiyi, K.E., Ugboko, V.L., Omoniyi-Esan, G.O., Ndukwe, K.C., Oginni, F.O., 2006. Clinicopathological analysis of histological variants of ameloblastoma in a suburban Nigeria population. Head Face Med 2: 42-49.

Adekeye, E.O., Lavery, K.M., 1986. Recurrent Ameloblastoma of the Maxillo-Facial Region: Clinical Features and Treatment. J max fac Surg 14: 153-157.

Adeline, V.L., Dimba, E.A., Wakoli, K.A., Njiru, A.K., Awange, D.O., Onyango, J.F., et al., 2008. Clinicopathologic features of ameloblastoma in Kenya. A 10year audit. J Craniofac Surg 19: 1589- 1593.

Ahlem, B., Wideda, A., Amanib, L., Nadiaa, Z., Amiraa, A., Fatena, F., 2015. Study of Ki67 and CD10 expression as predictive factors of recurrence. European Annals of Otorhinolaryngology, Head and Neck diseases 132: 275–279.

Ajayi, O.F., Ladeinde, A.L., Adeyemo, W.L., Ogunlewe, M.O., 2004. Odontogenic tumours in Nigerian children and adolescents – a retrospective study of 92 cases. World J Surg Oncol 2:39.

Antonoglou, G.N., Sandor, G.K., 2015. Recurrence rates of intraosseous ameloblastomas of the jaws: A systematic review of conservative versus aggressive treatment approaches and meta-analysis of non-randomized studies. Journal of Cranio-Maxillo-Facial Surgery 43: 149e-157e.

Barnes, L., Everson, J.W., Reichart, P., Sidransky, D., editors., 2005. Pathology and genetics of head and neck tumours. IARC Press, Lyon. 215-19

Brown, N.A., Betz, B.L., 2015. Ameloblastoma: a review of recent molecular pathogenetic discoveries. Biomark Cancer 7:19-24.

Brown, N.A., Rolland, D., McHugh, J.B., Weigelin, H.C., Zhao, L., Lim, M.S., et al., 2014. Activating FGFR2-RAS-BRAF mutation in ameloblastoma. Cli Cancer Res 20(21): 5517-26.

Buchner, A., Sciubba, J.J., 1987. Peripheral epithelial odontogenic tumours: a review. Oral Surg Oral Med Oral Pathol 63: 688-697.

Buchner, A., Merrell, P.W., Capenter, W.M., 2006. Relative frequency of central odontogenic tumors: a study of 1,088 cases from Northern California and comparison to studies from other parts of the world. J Oral Maxillofac Surg 64:1343-52.

Carlson, E.R., Marx, R.E., 2006. The ameloblastoma: Primary curative surgical management. J Oral Maxillofac Surg 64; 484-494.

Chukwuneke, F.N., Anyanechi, C.E., Akpeh, J.O., Chukwuka, A., Ekwueme, O.C., 2016. Clinical characteristics and presentation of ameloblastoma: An 8year retrospective study of 240 cases in Eastern Nigeria. British J Oral Maxillofac Surg 54: 384-387.

Cusack, J.J.W., 1827. Report of the amputation of the lower jaw. Dubliln Hop Rec 4: 1-38.

Daley, T.D., Wysocki, G.P., Pringle, G.A., 1994. Relative incidence of odontogenic tumors and oral and jaw cysts in a Canadian population. Oral Surg Oral Med Oral Pathol 77(3): 267-280.

Dandriyal, R., Gupta, A., Pant, S., Baweja, H.H., 2011. Surgical management of ameloblastoma: conservative or radical approach. Natl J Maxillofac Surg 2: 22-27.

Demeulemeester, L.M-J., Mommaerts, M.Y., Fossion, E., Bossuyt, M., 1988. Late loco-regional recurrences after radical resection for mandibular ameloblastoma. Int J Oral Maxillofac Surg 17: 316-8.

Dissanayeke, R.K., Yajasooriya, P.R., Siriwardena, D.J., Tilakaretne, W.M., 2011. Review of metastasizing (malignant) ameloblastoma (METAM): pattern of metastasis and treatment. Oral Surg Oral Med Oral Pathol Oral Radiol Endod 111: 734-41.

Eckardt, A.M., Kokemuller, H., Flemming, P., Schultze, A., 2009. Recurrent ameloblastoma following osseous reconstruction- A review of twenty years. J Cranio-Maxillofacial Surg 37: 36-41.

Effiom, O.A., Ogundana, O.M., Akinshipo, A.O., Akintoye., 2017. Ameloblastoma: current etiopathological concepts and management. Oral Disease: 1-10.

El-Naggar, Chan, J.K.C., Grandis, J.R., Takata, T., Slootweg. P., editors., 2017. WHO classification of Head and Neck Tumours. Chapter 8: Odontogenic and maxilofacial bone tumours. 4th ed., IARC: Lyon, 205-260.

Faden, D.L., Algazi, A., 2017. Durable treatment of ameloblastoma with single agent BRAFi Re: clinical and radiographic response with combined BRAF- targeted therapy in stage 4 ameloblastoma. J Natl Cancer Inst 109(1): 190-194

Feinberg, S.E., Steinberg, B., 1996. Surgical management of ameloblastoma. Oral Surg Oral Med Oral Path Oral Radiol Endod 81: 383-388.

Ferretti, C., Rikhotso, E., Muthray, E., Reyneke, J., 2013. Interim reconstruction and space maintenance of mandibular continuity defects preceding definitive osseous reconstruction. Br J Oral Maxillofac Surg 51: 319-325.

Gardner, D.G., 1996. Some current concepts on the pathology of ameloblastoma. J Oral Maxillofac 82: 660-669.

Georgios, N.A., George, K.S., 2015. Recurrence rates of intraosseous ameloblastomas of the jaws: A systematic review of conservative versus aggressive treatment approaches and meta-analysis of non-randomised studies. J Cran-Max-Fac-Surg 43: 149-157.

Gunawardhana, K.S.N.D., Jayasooriya, P.R., Rambukewela, I.K., Tilakaratne, W.M., 2010. A clinico-pathological comparison between mandibular and maxillary ameloblastomas in Sri Lanka. Oral Pathol Med 39: 236–241.

Haqa, J., Siddiquib, S., McGurkc, M., 2016. Argument for the conservative management of mandibular ameloblastomas. British Journal of Oral and Maxillofacial Surgery 54: 1001–1005.

Hertog, D., van der Waal, I., 2010. Ameloblastoma of the jaws: A critical reappraisal based on a 40 years' single institution experience. Oral Oncol 46: 61-64.

Hertog, D., Bloemena, E., Aartman, I.H., van-der-Waal, I., 2012. Histopathology of ameloblastoma of the jaws; some critical observations based on a 40 years single institution experience. Med Oral Patol Oral Cir Bucal 17(1): e76-82.

Hirschhorn, A.I., Vered, M., Buchner, A., Greenberg, G., Yahalom R., 2013. Unicystic ameloblastoma in an infant: A management dilemma. J Cran-Max-Fac-Surg 41: 226-230.

Hong, J., Yun, P.Y., Chung, I.H., et al. 2007. Long term follow up on recurrence of 305 ameloblastoma cases. Int J Oral Maxillofac Surg 36: 283-288.

Huang, C.M., Chen, J.Y., Chen H.C., Huang, C.J., 2014. Radiotherapy for a repeatedly recurrent ameloblastoma with malignant transformation. Head Neck 36: E1-E3.

Intapa, C., 2017. Analysis of prevalence and clinical features of ameloblastoma and its histopathological subtypes in Southeast Myanmar and lower Northern Thailand population: A 13-year retrospective study. J Clinical Diagnostic Research 11(1): 102-106.

Ivery, R.H., Churchill, H.R., 1930. The need of a standardized surgical and pathological classification of tumors and anomalies of dent origin. Am Assoc Dent Sch Trans 7: 240-245.

Jhamb, T., Kramer, J.M., 2014. Molecular concepts in the pathogenesis of ameloblastoma: implications for therapeutics. Exp Mol Pathol 97: 345-353.

Kaye, F.J., Ivey, A.M., Drane, W.E., Mendenhall, W.M., Allan, R.W., 2014. Clinical and Radiographic response with combine BRAF-targeted therapy in stage 4 ameloblastoma. J Natl Cancer Inst 109(1). 378

Kennedy, W.R., Werning, J.W., Kaye F.J., Mendenhall, W.M., 2016. Treatment of ameloblastoma and ameloblastic carcinoma with radiotherapy. Eur Arch Otorhinolaryngol 273: 3293-3297.

Keszler, A., Dominguez, F.V., 1986. Ameloblastoma in childhood. J Oral Maxillofacial Surg 44: 609-613.

Kim, SG., Jang HS., 2001. Ameloblastoma: A clinical, radiographic, and histopathologic analysis of 71 cases. Oral Radiol Endod 91: 649-653.

Kovács, A., Mathias Wagner, M., Ghahremani, M., 1999. Ameloblastoma and soft tissue recurrence. Rev Med Hosp Gen Mex 62 (1): 48-53.

Kramer, I.R.H., Pindborg, J.J., Shear, M., 1992. Histological typing of odontogenic tumors. Berlin: springer Verlag: 11-4.

Kruze, A.L., Zwahlen, R.A., Gratz, K.W., 2009. New classification of maxillary ameloblastic carcinoma based on an evidence-based literature review over the last 60 years. Head Neck Oncol 1(31): 1-13.

Kurppa, K.J., Caton, J., Morgan, P.R., Ristimaki, A., Ruhin, B., Kellokoski, J., et al., 2014. High frequency of BRAF V6OOE mutations in ameloblastoma. J Pathol 232(5): 492-8

Ladeinde, A.L., Oguneiwe, M.O., Bamgbose, B.O., Adeyemo, W.L., Ajayi, O.F., Arotiba, G.T., et al 2006. Ameloblastoma: Analysis of 207 cases in a Nigerian teaching hospital. Quintessence int 37: 69-74.

Larsson, A., Almeren, H., 1978. Ameloblastoma of the jaws. An analysis of a consecutive series of all cases reported to the Swedish Cancer Registry during 1958-1971. Acta Pathol Microbio Scand A 86A (5): 337-349.

Lasisi, T.J., Adisa, A.O., Olusanya, A.A., 2013. Appraisal of the jaw swelling in a Nigerian tertiary healthcare. J Clin Exp Dent 5: e42-e47.

Lau, S.L., Samman, N., 2006. Recurrence related to treatment modalities of unicystic ameloblastoma: a systemic review. Int J Oral Maxillofac Surg 35: 681- 690.

Lee, P.K., Samman, N., Ng, I.O., 2004. Unicystic ameloblastoma- use of Carnoy's solution after enucleation. Int J Oral Maxillofac Surg 33: 263-267.

Li. J., Du, H., Li, P., Zhang, J., Tian, W., Tang, W., 2014. Ameloblastic carcinoma: an analysis of 12 cases with a review of the literature. Oncol Lett 8: 914-920.

Lu, Y., Xuan, M., Takata, T., Wang. C., He, Z., Zhou, z., et al., 1998. Odontogenic tumors. A demographic study of 759 cases in a Chinese population. Oral Surg Oral Med Oral Pathol Oral Radiol Endod 86(6): 707-714.

McClary, A.C., West, R.B., McClary, A.C., Pollack, J.R., Fischbein, N.J., Holsinger, C.F., et al., 2016. Ameloblastoma: a clinical review and trends in management. Eur Arch Otorhinolaryngol 273(7):1649-61.

Mehlisch, D.R., Dahlin, D.C., Masson, J.K., 1972. Ameloblastoma: a clinicopathologic report. J Oral Surg 30(1): 9-22.

Mosadomi, A., 1975. Odontogenic tumors in an African population. Analysis of twenty-nine cases seen over a 5-year period. Oral Surg Oral Med Oral Pathol 40(4): 502-521.

Muller, H., Slootweg, P.J., 1985. The ameloblastoma, the controversial approach to therapy. J Max Fac Surg 13: 79-84.

Nalabolu, G.R.K., Mohiddin, A., Hiremath., S.K.S., Manyam, R., Bharath, T.S., Raju, P.R., 2016. Epidemiological study of odontogenic tumors: An institutional experience. J Infect Public Health 597:1-7.

Nakamura, N., Higuchi, Y., Mitsayasa, T., Sandra, F., Ohishi, M., 2002. Comparison of long term results between different approaches to ameloblastoma. Oral Surg Oral Med Oral Pathol Oral Radiol Endod 93: 13-20.

Neville, B.W., Damm, D.D., Allen, C.M., Bouqout, J., 2016. Oral and Maxillofacial Pathology. 3rd ed, Saunders, St Louis. 653-662

Odeli, E.W., Muller, S., Richardson, M., 2017. Odontogenic / ameloblastic carcinomas. In: EL-Naggar. A.K., Chan, J.K.C., Gradis, J.R., Takata, T., Slootweg, P.J., editors. World Health Organization Classification Head and Neck Tumours. Lyon: IARC Press: 206–21.

Odukoya, O., 1995. Odontogenic tumour: analysis of 289 Nigerian cases. J Oral Pathol Med 24:454–7.

Oginni, F.O., Stoelinga, P.J., Ajike, S.A., et al., 2015. A prospective epidemiological study on odontogenic tumors in a black African population, with emphasis on the relative frequency of ameloblastoma. Int J Oral Maxillofac 44: 1099-1105.

Olaitan, A.A., Adeola, D.S., Adekeye, E.O., 1993. Ameloblastoma: clinical features and management of 315cases from Kaduna, Nigeria. J Craniomaxillofac Surg 21(8): 315-355.

Olaitan, A.A., Arole, G., Adekeye, E.O., 1998. Recurrent ameloblastoma of the jaws: A follow-up study. Int J Oral Maxillofac Surg 27: 456-460.

Olusanya, A.A., Adisa, A.O., Lawal, A.O., Arotiba, J.T., 2013. Gross surgical features and treatment outcome of ameloblastoma at a Nigerian tertiary institution hospital. Afr J Med Sci 42:59-64.

Okada, H., Yamamoto, H., Tilakaratne, W.M., 2007. Odontogenic tumors in Sri Lanka: Analysis of 226 cases. J Oral Maxillofac Surg 65:875- 882.

Oomens, M.A., van der Waal, I., 2014. Epidemiology of ameloblastoma of the jaws: a report from the Netherlands. Med Oral Patol Oral Cir Bucal 19: e581-e583.

Philipsen, H.P., Reichart, P.A.,1998. Unicystic ameloblastoma. A review of 193 cases from the literature. Oral Oncol 34: 317-25.

Philipsen, H., Reichart, P., Nikai, H., Takara, T., Kudo, Y., 2001. Peripheral ameloblastoma: biological profile based on 160 cases from the literature, Oral Oncol 37: 17-27.

Philipsen, H.P., Reichart, P.A., Takata, T., 2001. Desmoplastic ameloblastoma (including "hybrid" lesion of ameloblastoma). Biological profile based on 100 cases from the literature and own files. Oral Oncol 37: 455-460.

Pogrel, M.A., Montes, D.M., 2009. Is there a role for enucleation in the management of ameloblastoma? Int J Oral Maxillofac Surg 38; 807-812.

Rastogi, V., Pandilwar, P.K., Maitra, S., 2010. Ameloblastoma: an evidence based study. J Maxillofac Oral Surg 9: 173-177.

Regezi, J.A., Kerr, D.A., Courtney, R.M., 1978. Odontogenic tumors: analysis of 706 cases. J Oral Surg 36(10): 771-778.

Reichart, P.A., Philipsen, H.P., Sonner, S., 1995. Ameloblastoma: Biological Profile of 3677 Cases. Oral Oncol Eur J Cancer 31B: 86-99.

Ribeiro, B.F., Iglesias, D.P., Nascimento, G.J., Galvao, H.C., Medeiros, A.M., Freitas, R.A.2009 Immunoexpression of MMPs-1, 2, and -9 in ameloblastoma and odontogenic adenomatoid tumor. Oral Dis 15: 472-477.

Rizzitelli, A., Smoll, N.R., Chae, M.P., Rozen, W.M., Hunter-Smith, D.J., 2015. Incidence and overall survival of malignant ameloblstoma. PLos One 10: e0117789.

Robinson, L., Martinez, M.G., 1977. Unicystic ameloblastoma: a prognostically distinct entity, Cancer 40: 2278-2285.

Ruhin-Poncet, B., Bouattour, A., Picard, A., et al., 2011. Ameloblastoma of the jaws. A retrospective analysis from 1994 to 2007. Rev stomatal Chir Maxillofac 11: 269-279.

Saghravanian, N., Salehinejad, J., Ghazi, N., Shirdel, M., Razi, M., 2017. A retrospective clinicopathological study of ameloblastoma in Iran. Asian Pac J Cancer Prev 17(2): 619-623.

Sammartino, G., Zarrelli, C., Urciuolo, V., di Lauro, A.E., di Lauro, F., Santarelli, A., et al., 2007. Effectiveness of a new decisional algorithm in managing mandibular ameloblastomas: a 10-years' experience. Br J Oral Maxillofac Surg 45: 306–310.

Sampson, D.E., Pogrel, M.A., 1999. The clinical basis for a treatment algorithm. J Oral Maxillofac 30: 1074-1077.

Santos, Td.S., Piva, M.R., Andrade, E.S., Vajgel, A., Vasconcolos, R.J., Martin-Filho, P.R., 2014. Ameloblastoma in the Northeast region of Brazil: a review of 112 cases. J Oral Maxillofac Pathol 18: 66-71.

Sauk, J.J., Nikitakis, N.G., Scheper, M.A., 2010. Are we on the brink of nonsurgical treatment for ameloblastoma? Oral Surg Oral Med Oral Pathol Oral Radiol Endod 110: 68-78.

Sawyer, D.R., Mosadomi, A., Page, D.G., Svirsky, J.A., Kekere-Ekun, A.T., 1985 Racial predilection of ameloblastoma? A probable answer from Lagos (Nigeria) and Richmond Virginia(USA). J Oral Med 40: 27–31.

Sehdev, M.K., Huvos, A.G., Strong, E.W., Grold, F.P., Willis, G.W., 1974. Ameloblastoma of maxilla and mandible. Cancer 33: 324-333.

Seintou, A., Martinelli-klay, C.P., Lombardi, T., 2014. Unicystic ameloblastoma in children: Systematic review of clinicopathological features and treatment outcomes. Int J Oral & Maxillofacial Surg 43: 405-412.

Shear, M., Singh. S., 1978. Age-standardized incidence rates of ameloblastoma and dentigerous cyst on the Witwatersrand, South Africa. Community Dent Oral Epidemiol. 6: 195-9

Siar, C.H., Lau, S.H., Ng, K.H., 2012. Ameloblastoma of the jaws: A retrospective analysis of 340 cases in a Malaysian population. J Oral Maxillofac Surg 70: 608-615.

Simon, E.N., Merkx, M.A., Vuhavula, E., Ngassapa, D., Stoelinga, P.J., 2005. A four-year prospective study on epidemiology and clinicopathological presentation of odontogenic tumours in Tanzania. Oral Surg Oral Med Oral Pathol Oral Radiol Endod 99: 598–602.

Slootweg, P., Muller H., 1984. Malignant ameloblastoma or ameloblastic carcinoma. Oral Surg 57: 168-176.

Swapnil, S.D., Rishikesh, C.D., Aarti, M.M., Rahul, P., Nilima, P., 2014. Plexiform unicystic ameloblastoma: A rare variant of ameloblastoma, Case Rep Dent: 146989: 1-6.

Sweeney, R.T., McClary, A.C., Myers, B.R., et al., 2014. Identification of recurrent SMO and BRAF mutations in ameloblastoma. Nat Genet 46: 722-725.

Tawfik, M.A., Zyada, M.M., 2010. Odontogenic tumors in Dakahlia, Egypt: Analysis of 82 cases. Oral Surg Oral Med Oral Pathol Oral Radiol Endod 99: 67- 73.

To, W.H., Tsang, W.M., Pang, C.W., 2002. Recurrent ameloblastoma presenting in the temporal fossa. Am J Otolaryngology 23:105-107.

Verneuil, A., Sapp, P., Huang, C., Abemayor, E., 2002. Malignant ameloblastoma: classification, diagnostic, and therapeutic challenges. Am J Otolaryngol 23: 44–48.

Wright, J.M., Odell, E.W., Speight, P.M., Takata. T., 2014. Odontogenic Tumors, WHO 2005: Where do we go from here? Head Neck Pathol 8: 373-382.

Wright, J.M., Vered, M., 2017. Update from the 4th Edition of the World Health Organization Classification of Head and Neck Tumours: Odontogenic and Maxillofacial Bone Tumors. Head and Neck Pathol 11: 68–77.

Yoon, H.J., Hong, S.P., Lee, J.L, Lee, S.S., Hong, S.D., 2009. Ameloblastic carcinoma: an analysis of 6 cases with review of the literature. Oral Surg Med Oral Pathol Oral Radiol Endod 108: 904-913.

Yang, R., Peng, C., Cao, W., Ji, T., 2017. Maxillary ameloblastoma: Factors associated with risk of recurrence. Wiley Online Library. DOI 10. 1002/hed.24720.

Zhang, B., Zhang, J., Huang, H.Z., Xu, Z.Y., Xie, H.L., 2010. Expression and role of metalloproteinase-2 and endogenous tissue regulator in ameloblastoma. J Oral Pathol Med 39: 219-222.

.

ANNEXURE A.

Proforma

Patient code……

Age		
Gender	Male	Female

Ameloblastoma			
Site	Mandible	Maxilla	skull
Location	anterior	Posterior	
Size	Less than 4cm	Greater than 4cm	
Involvement of the inferior border (mandible)		Yes	No
Bone perforation	Yes	No	

Type		
Unicystic	Multicystic	Peripheral

Subtypes unicystic

Luminal	Intraluminal	Mural

Subtypes multicystic

Growth pattern	Follicular	Plexiform

Histopathology type	Basal	Granular	Acanthomatous	Desmoplastic

Treatment option (procedure and year)

Enucleation	Enucleation and peripheral ostectomy	Enucleation, peripheral ostectomy and cryotherapy

Marginal resection	Complete resection	Year:

Histological margins

Bone	Clear	Not clear

Soft tissue	Clear	Not clear

Site with close margins

Buccal	Lingual	Inferior

Proximal	Distal

Recurrence

Yes	No

Site of recurrence

Primary bone	Soft tissue	Grafted tissue

Time between primary surgery and recurrence

ANNEXURE B

Ethics Clearance Certificate

R14/49 Dr Chokoe Nare Hemelton

HUMAN RESEARCH ETHICS COMMITTEE (MEDICAL)

CLEARANCE CERTIFICATE NO. M150841

NAME: (Principal Investigator)	Dr Chokoe Nare Hemelton
DEPARTMENT:	Maxillofacial and Oral Surgery School of Oral Sciences
PROJECT TITLE:	The Recurrence Incidence of Ameloblastoma in Johannesburg
DATE CONSIDERED:	28/08/2015
DECISION:	Approved unconditionally
CONDITIONS:	
SUPERVISOR:	Dr Mzubanzi Mabongo and Dr Sizakele Ngwenya

APPROVED BY: Professor P Cleaton-Jones, Chairperson, HREC (Medical)

DATE OF APPROVAL: 02/09/2015

This clearance certificate is valid for 5 years from date of approval. Extension may be applied for.

DECLARATION OF INVESTIGATORS

To be completed in duplicate and **ONE COPY** returned to the Secretary in Room 10004, 10th floor, Senate House, University.
I/we fully understand the conditions under which I am/we are authorized to carry out the above-mentioned research and I/we undertake to ensure compliance with these conditions. Should any departure be contemplated, from the research protocol as approved, I/we undertake to resubmit the application to the Committee. **I agree to submit a yearly progress report**.

Principal Investigator Signature Date

PLEASE QUOTE THE PROTOCOL NUMBER IN ALL ENQUIRIES

ANNEXURE C

Letter of approval from the Head of Oral Health Sciences/Wits Oral Health Centre

GAUTENG PROVINCE
HEALTH
REPUBLIC OF SOUTH AFRICA

WITS ORAL HEALTH CENTRE

Private Bag X15 Braamfontein, Johannesburg, 2017
Enquiries: Mrs. JC Pretorius/Ms L Huygen
Tel: (011)488-4906, Fax(011)488-4869
E-mail: Rina.Pretorius@wits.ac.za
Liza.huygen@wits.ac.za

15 October 2015

Dr N Chokoe
School of Oral Health Sciences
University of the Witwatersrand
Johannesburg

REGARDING: **PERMISSION TO ACCESS WOHC HISTOPATHOLOGICAL REPORTS AND THEATRE NOTES**

REFERENCE: **WOHC/HREC/OCT/2015/03**

It is my pleasure to grant final approval to utilize resources at Wits Oral Health Centre in order to conduct your research. The Hospital Research and Ethics Committee allocated a unique reference number to this application – Kindly quote this reference number in all future correspondence regarding this research.

Please note that the Hospital Research and Ethics Committee should be informed of the estimated date the research will commence, as well as regular status reports until the research have been concluded. Within a month after conclusion of the research project, a written report must be submitted to the Head of School / CEO, summarizing the final results / outcome as well as recommendations made based on the research conducted.

Regards,

Prof P Hlongwa
CEO/Head of School

ANNEXURE D

Letter of approval from the Head of Department of Oral Pathology

Department of Oral Pathology
School of Oral Health Sciences
Faculty of Health Sciences
3E22, 3rd floor, Wits Medical School
7 York Road, PARKTOWN, 2193
Private Bag 3, Wits 2050, South Africa
Tel: 0117172139/97
Fax: 0117172146
Email: HOD: Sizakele.Ngwenya@wits.ac.za
Secretary: Phindile.Mashinini@wits.ac.za

06 August 2015

Human Research Ethics Committee (Medical)
Research Office
Faculty of Health Sciences

Applications for HREC (Medical) Ethics Clearance

Dear Sir/Madam

I, **Sizakele Ngwenya** in my capacity as **Head of the Department of Oral Pathology** grant **Dr CHOKOE NH** access to the department's histopathological reports to retrieve demographic and clinicopathological data as specified in his data collection sheet. The research is in partial fulfilment towards the MSc (Dent) Oral and Maxillofacial degree, for his study entitled; **The Recurrence Incidence Of Ameloblastoma In Johannesburg.**

Yours Sincerely,

Dr SP NGWENYA
HOD: ORAL PATHOLOGY

ANNEXURE E

Patient identifier

Patient code…….

Patient Name…….

Medical record number / File number……

Laboratory Number……....