

https://dspace.org/

Prevalence, demographic and histological subtypes of hurthle cell tumors of the thyroid: a histopathological audit

Malith, V J W

2017
http://hdl.handle.net/10539/23399

Downloaded from a DSpace repository. https://dspace.org/

Prevalence, demographic and histological subtypes of Hurthle cell tumors of the thyroid: a histopathological audit

VJW Malith
W01-01-89



A Dissertation submitted to the Faculty of Health Sciences of University of the Witwatersrand, Johannesburg, in fulfillment of the requirements for the degree of Master of Medicine in Surgery.

Johannesburg, 2017

Candidate: Victor Malith

MBBS, University of Juba, Sudan

Student No. 527446

Department of Surgery,

University of Witwatersrand

Degree of Master of Medicine in Surgery

Supervisors:

Prof: TE Luvhengo, MB ChB, FCS (SA).

Dr. I Bombil, MD, MMed (wits), FCS (SA), FACS.

Dr. N Harran, MB ChB, MMed (wits), FCS (SA), Cert GIT (SA).

Declaration

I, Victor VJW Malith declare that this dissertation is of my own unaided work. It is being submitted for the Degree of Master of Medicine in Surgery at the University of the Witwatersrand, Johannesburg. It has not been submitted before for any degree or examination at any other University.

_____ ----------

Signed Date

Dedication

This work is dedicated to my young family; my wife Anyang and her triplets: Jal, Malith and Achol

Abstract

Background: Hurthle cell neoplasms (HCN) are considered a variant of follicular thyroid neoplasms, and accounts for 3-10% of neoplasms of the thyroid gland. They include Hurthle cell adenomas (HCA) and carcinomas (HCC). Differentiating HCA from HCC preoperatively is currently not possible. We retrospectively searched for demographic and histopathological factors which can be used to predict the risk of malignancy in HCN.

Aim: To determine the prevalence of HCC and its demographic factors and histopathological features that can be used to predict the risk of malignancy in HCN.

Methods: Records of all patients who underwent thyroidectomy at Academic Hospitals associated with University of the Witwatersrand from January 2001 to October 2015 were reviewed. Patients' demographic data and the final histology of HCN were further analyzed including pre-operative fine needle aspiration cytology (FNAC) results. Data collected included patients' demographic, final histology, tumor size and preoperative FNAC result. Data was entered into Excel Spreadsheet and analyzed using STATICA 13.1 program.

Results: At total of 2641 records of thyroidectomies were found of which 25.6% (676/2641) were for thyroid neoplasms**.** Only 15.8% (107/676) of the neoplasms were HCNs and 25.2% (27/107) of HCNs were HCCs. Hurthle cell carcinoma made up 5.6% (27/481) of thyroid carcinomas. **7**0.4% (19/27) of HCCs were incidentally found following thyroidectomy for multinodular goiter (MNG). The mean tumor size was significantly greater for carcinomas than for adenomas (4.9 cm vs. 3.5 cm; p = 0.016). The risk of malignancy increased from 11.1% when the size was less or equal to 1cm, through 33.3% for size of 1-4cm to 51.8% when the size was greater than 4cm in diameter.

A total of 58 FNACs results of 107 HCNs were available for further analysis. Thirty one (53.4%: 31/58) of FNAC results were suspicious for HCN (Bethesda IV), seven (12.1%: 7/58) suspicious of papillary carcinoma (Bethesda V) and eight (13.8%: 8/58) were reported as benign (Bethesda II). Around 10.3% (6/58) were non-diagnostic (Bethesda I) whereas 8.6% (5/58) were reported as atypia of unknown significance (Bethesda III). Both HCA and HCC were more prevalent in females, 88.7% (71/80) and 77.8% (21/27); respectively. The mean age of the patients who had HCA and HCC in years was 52.3+/- 15.6 SD and 55.0 +/- 15.0 SD, respectively.

Conclusion: Majority of HCCs are diagnosed following thyroidectomy for benign disease. Close to a quarter of HCNs are malignant and the risk of malignancy increases with size. Age and gender are not useful to predict malignancy in HCNs. We recommend total thyroidectomy for thyroid nodule greater than 4cm in diameter if FNAC result is suggestive of HCN as the risk of malignancy is above 50%.

Acknowledgements

To my supervisors; Dr N Harran, Dr I Bombil and especially Prof TE Luvhengo, thank you for your guidance, support and encouragement. Your expertise and knowledge did not go unnoticed. I have gained overwhelming wealth of knowledge from you. I would not have done it without you.

I sincerely appreciate and am highly thankful to Prof Mannell for her support, patience and guidance when I was lagging behind with this MMed as well as coining the title of this dissertation.

List of abbreviations and symbols

APC: Adenomatous polyposis coli.

ATA: American Thyroid Association.

ATC: Anaplastic thyroid carcinoma.

AUS: Atypia of undetermined significance.

CHBAH: Chris Hani Baragwanath Academic Hospital.

CMJAH: Charlotte Maxeke Johannesburg Academic Hospital.

CT: Computer tomography.

DTC: Differentiated thyroid cancers.

EBRT: External beam radiotherapy.

ETE: Extra-thyroidal extension.

FA: Follicular adenoma.

FAP: Familial adenomatous polyposis.

FC: Follicular carcinoma.

FMTC: Familial medullary thyroid carcinoma.

FN: Follicular neoplasm.

FNAC: Fine needle aspiration cytology.

FTC: Follicular thyroid carcinoma.

HC: Hurthle cells.

HCA: Hurthle cell adenoma.

HCC: Hurthle cell carcinoma.

HCN: Hurthle cell neoplasm.

HJH: Helen Joseph Hospital.

MEN: Multiple endocrine neoplasia.

MEN2A: Multiple endocrine neoplasia type 2A.

MEN2B: Multiple endocrine neoplasia type 2 B.

MNG: Multinodular goiter.

MTC: Medullary thyroid carcinoma.

NHLS: National Health Laboratory Services.

PET: Positron emission tomography.

PTC: Papillary thyroid cancer.

RAI: Radioactive iodine.

SFN: Suspicious of follicular neoplasm.

Tg: Thyroglobulin.

T4: Thyroxine.

T3: Tri-iodothyronine.

TSH: Thyroid-stimulating hormone.

TIRADS: Thyroid imaging reporting and data system.

US: Ultrasound.

USE: Ultrasound Elastography.

WHO: World Health Organization.

List of tables

Table 1: Histological classification of thyroid neoplasms.

Table 2: Thyroid Imaging Report and Data System (2015 ATA).

Table 3a: The Bethesda System for Reporting Thyroid Cytopathology: Recommended Diagnostic Categories.

Table 3b: The Bethesda System for Reporting Thyroid Cytopathology: Implied Risk of Malignancy and Recommended Clinical Management.

Table 4: Tumor-Node-Metastasis staging system of differentiated thyroid.

Table 5: Distribution of thyroid tumors according to histology reports.

Table 6: Characteristics of 107 patients with Hurthle cell tumors.

Table 7: FNAC categories of 107 Hurthle cell tumours.

Table 8: Fine-needle aspiration cytology and Histology results of Hurthle cell tumors.

Table 9: Surgical procedures for Hurthle cell tumors.

Table 10: Findings in HCC patients treated with lobectomy (n=13).

List of figures

Figure 1a: Breakdown of histology results of thyroidectomies specimens.

Figure 1b: Abbreviated breakdown of histology results of thyroidectomies specimens.

Figure 2: Breakdown of thyroid tumors of the thyroid based on histology reports.

Figure 3: Mean age of 107 HCN patients.

Figure 4: Gender of 107 HCN patients.

Figure 5: Sensitivity and specificity of FNAC to diagnose HCC.

Figure 6: Tumor size (cm) and risk of malignancy (%).

Figure 2: Malignant tumors of the thyroid.

Table of Contents

DECLARATION ..... **II**
DEDICATION ..... **III**
ABSTRACT ..... **IV**
ACKNOWLEDGEMENTS ..... **VI**
LIST OF ABBREVIATIONS AND SYMBOLS ..... **VII**
LIST OF TABLES ..... **IX**
LIST OF FIGURES ..... **X**
TABLE OF CONTENTS ..... **XI**
CHAPTER ONE **1**
1.1. INTRODUCTION 1
1.2. BACKGROUND TO THE RESEARCH PROBLEM 1
1.3. STATEMENT OF THE RESEARCH PROBLEM 2
1.4. AIM AND OBJECTIVES OF THE STUDY 3
1.4.1: Study aim *3*
1.4.2: Study objectives *3*
1.5. SIGNIFICANCE OF THE STUDY 3
CHAPTER TWO **4**
LITERATURE REVIEW **4**
2.1: INTRODUCTION 4
2.2: CLASSIFICATION OF THYROID NEOPLASMS 5
I. PRIMARY **6**
2.3: EPIDEMIOLOGY 7
2.4: RISK FACTORS FOR THYROID CANCERS 7
2.5: TYPES OF THYROID CANCERS 8
2.5.1: Papillary thyroid carcinoma *8*
2.5.2: Follicular thyroid carcinoma *9*
2.5.3: Poorly differentiated thyroid carcinoma *9*
2.5.4: Anaplastic thyroid carcinoma *9*
2.5.5: Medullary thyroid carcinoma *9*
2.6: HURTHLE CELL NEOPLASMS 10

2.6.1: Epidemiology of Hurthle cell neoplasms *10*

2.6.2: Pathology of Hurthle cell neoplasms *10*

2.6.3: Prognosis of Hurthle cell carcinoma *11*

2.6.4: Risk factors for Hurthle cell carcinoma *11*

2.7. DIAGNOSTIC EVALUATION OF THYROID NODULES 12

2.7.1: Introduction *12*

2.7.2: Clinical evaluation of a patient presenting with thyroid nodule *12*

2.7.3: Biochemical evaluation of a patient presenting with thyroid nodule *12*

2.7.4: Radiological evaluation of a patient presenting with thyroid nodule *13*

CHAPTER 2 SONOGRAPHIC PATTERN **14**

CHAPTER 3 US FEATURES **14**

CHAPTER 4 MALIGNANCY RISK % **14**

CHAPTER 5 HIGH SUSPICION **14**

CHAPTER 6 SOLID HYPOECHOIC NODULE OR SOLID HYPOECHOIC COMPONENT OF A PARTIALLY CYSTIC NODULE WITH ONE OR MORE OF THE FOLLOWING FEATURES **14**

II. MICRO CALCIFICATIONS, ... **14**

III. TALLER THAN WIDE SHAPE, ... **14**

IV. RIM CALCIFICATIONS WITH SMALL EXTRUSIVE SOFT TISSUE COMPONENT, ... **14**

V. EVIDENCE OF ETE **14**

2.7.5: The role of fine needle aspiration cytology in evaluation of HCNs *15*

2.8: STAGING OF HURTHLE CELL CARCINOMA 20

2.9: MANAGEMENT OF HURTHLE CELL NEOPLASMS 21

2.10. FOLLOW UP OF PATIENTS WHO HAVE HURTHLE CELL NEOPLASM 22

CHAPTER THREE **23**

RESEARCH METHODOLOGY **23**

3.1: INTRODUCTION 23

3.2: STUDY AIM AND OBJECTIVES 23

3.2.2: Study objectives *23*

3.3: Methodology *24*

3.3.1: Research design *24*

3.3.2: Setting *24*

3.3.3: Study population *24*

3.3.4: Inclusion criteria *25*

3.3.5: Ethics and Permission *25*

3.3.6: 2.7 Data collection and Statistical Analysis *25*

CHAPTER FOUR **26**

4.1: RESULTS 26

4.2: NEOPLASMS OF THYROID GLAND 27

4.3: DEMOGRAPHIC OF PATIENTS WITH HURTHLE CELL NEOPLASMS 29

4.4: DIAGNOSIS OF HCN 31

4.5: RISK OF MALIGNANCY 33

PATIENTS MANAGEMENT 34

CHAPTER FOUR **36**

DISCUSSION **36**

LIMITATIONS 38

CHAPTER FIVE **39**

CONCLUSION **39**

RECOMMENDATION 40

LISTS OF REFERENCES **41**

APPENDICES **51**

APPENDIX 1 51

APPENDIX 2 52

CHAPTER ONE

1.1. INTRODUCTION

Hurthle cells (HC) are commonly reported on fine-needle aspiration cytology (FNAC) from thyroid nodules [1]. Report of Hurthle cells or Hurthle cell changes in cytology result often lead to anxiety to the surgical team due to controversies associated with diagnosis, management and prognosis of Hurthle cell carcinoma (HCC) [1]

Before 1991, all Hurthle cell neoplasms were thought to have malignant potential and were therefore subjected to total thyroidectomy [2]. The above was due to inability of thyroid FNAC to distinguish Hurthle cell adenoma (HCA) from HCC. Similar to follicular carcinoma (FC), diagnosis of HCC is only made if there is evidence of vascular and/or capsular invasion which is not possible to confirm on cytology specimen [1-3]. Frozen section is not reliable either in the diagnostic work-up of HCN. Similarly, molecular analysis and Ki67 index evaluation of FNAC specimen are not helpful [1]. Total thyroidectomy is sometimes preferred and recommended because HCC is more aggressive as compared to other differentiated cancers of the thyroid of follicular cell origin. Furthermore, HCC has higher propensity for multifocality and distant metastasis.

Diagnostic work-up of a patient presenting with a thyroid nodule include history taking emphasizing on patient's complaints, family history and environmental factors. Male gender, extremes of age, previous neck irradiation and family history, if positive should be of concern.

1.2. BACKGROUND TO THE RESEARCH PROBLEM

Thyroid carcinoma is the most common endocrine cancer, accounting about 3% of newly diagnosed cancers annually [3, 4]. The incidence has been rising attributed to increase usage of screening tools and in part due to environmental factors which have led to surge of these cancers [5]. Thyroid carcinoma is more common in women than men. The average age range from 20-85 years but any age group can be affected [6]. Generally, thyroid malignancies are

broadly divided into primary and secondary cancers. Primary neoplasms are further subdivided into epithelial and non-epithelial neoplasms. Epithelial carcinomas include follicular and parafollicular C cells derived cancers. These are papillary, follicular and Hurthle cell carcinoma, anaplastic and medullary.

Hurthle cell carcinoma is a relatively rare thyroid neoplasm, only consists of 5% of all differentiated thyroid carcinoma [7]. Hurthle cell neoplasm is considered as a variant of follicular thyroid neoplasm, but many authors think they are separate entities [8, 9]. Therefore, handful institutions have accumulated more experiences on the diagnosis and management of HCN. Many controversies exist regarding the diagnosis, management and prognosis of HCC [1]. After a literature search, we could not find a study has been done in Southern Africa, regarding HCN. The researchers carry out a retrospective analysis of histopathological and FNAC reports to determine prevalence HCN and if there clinicopathological factors that can be used to predict malignancy in HCN.

1.3. STATEMENT OF THE RESEARCH PROBLEM

Until not long time ago, patients with HCN where all subjected to total thyroidectomy leading to unnecessary complications. It was because all HCNs were having malignant potential. Until recently, patients who were suspected to be having HCN on FNAC are pre-operatively risk stratified into low and high risk groups. Patients with low risk potential were managed with lobectomy only unless the subsequent histology showed widely invasive HCC [10].Clinicopathological factors that are used to predict risk of malignancy among HCN are; older age, male gender and size of tumor more than 4cm in diameter. The researchers try to look for these risk stratifying clinical and histopathological factors in patients seen and operated at the university teaching hospitals.

1.4. AIM AND OBJECTIVES OF THE STUDY

1.4.1: Study aim

To determine the prevalence of HCC and its demographic factors and histopathological features that can be used to predict the risk of malignancy in HCN.

1.4.2: Study objectives

i. To determine the demographic and histopathological findings in patients who had HCN.

ii. To determine what proportion of patients who had thyroidectomy for HCN were on histology confirmed to be having HCC.

iii. To determine if fine needle aspiration cytology is able to distinguish HCA from HCC.

iv. To determine if there are factors which are predictive of malignancy in patients presenting with HCN.

1.5. Significance of the study

The results of our study will shade a light into how common is HCCs in our clinical settings and will also increase our knowledge on diagnosis and decision making in term of management of HCN.

CHAPTER TWO

LITERATURE REVIEW

2.1: INTRODUCTION

Thyroid nodules are common in clinical practice, occurring in 4%–10% of the population [11]. More than 60% of thyroid nodules are non-palpable and are detected incidentally during a radiologic procedure such as ultrasound (US), computed tomography (CT), or positron emission tomography (PET) scanning [12, 13][14-18]. Thyroid nodules come to clinical attention when noted by the patient, relatives or a physician during physical examination. Differential diagnoses of nodular goiter include multinodular goiter (MNG), chronic lymphocytic thyroiditis, thyroid cyst, follicular adenomas (FA), Hurthle cell adenoma (HCA), and thyroid cancer [1].

Key concern in a patient who has euthyroid nodule is the possibility that the nodule may be malignant. However, only 5-15% of thyroid nodules irrespective of their size are malignant [1, 14-21]. The prevalence of cancer is higher in thyroid nodules in children and individuals who are younger than 30 years, adults over 60 years; and if there is history of head and neck irradiation. Other patients may have a family history of thyroid cancer [14, 15, 22, 23] . Common cancers of the thyroid are papillary thyroid carcinoma (PTC) and follicular thyroid carcinoma (FTC).

Thyroid neoplasms are increasingly diagnosed nowadays due to widespread availability and use of the imaging tools, and perhaps due to environmental and biological factors [5]. They are broadly divided into primary and secondary cancers (Table 1) [6, 24]. Secondary thyroid tumors originate from a primary cancer either above (mostly) or below the clavicle. These secondary cancers include breast, renal cell and squamous cell carcinomas [25].

2.2: CLASSIFICATION OF THYROID NEOPLASMS

Primary thyroid tumors are divided into epithelial and non-epithelial tumors. Benign epithelial tumors include FA and its oncocytic subtype called HCA. Malignant epithelial tumors are however more common and include PTC and FTC, which are more prevalent. The other types of primary malignant thyroid tumors are medullary thyroid carcinoma (MTC), poorly differentiated thyroid cancer (PDTC), anaplastic thyroid carcinoma (ATC), thyroid lymphoma (TL) and metastatic carcinoma [18, 21, 26]. Both poorly differentiated and anaplastic thyroid cancers arise from dedifferentiated PTC or FTC [24]. Medullary thyroid carcinoma originates from parafollicular cells (C-cells) and may be hereditary or sporadic. Hurthle cell carcinoma of the thyroid is a rare cancer of the thyroid. Non-epithelial tumors are extremely rare and examples are lymphoma, malignant teratoma and sarcomas.

According to the World Health Organization (WHO) classification of thyroid neoplasms HCA and HCC are considered variants of FA and FTC, respectively [2, 8, 20, 27]. Both HCA and HCC show histological characteristics which are similar to what is found in classical follicular neoplasms such as follicular growth pattern and encapsulation. Similarly, HCC is subcategorized into minimal invasive and widely invasive subtypes like FTC. Their genetic basis and clinical behavior are however different. Some authors however consider HCA and HCC as separate entities from FA and FTC [8].

Poorly differentiated thyroid carcinoma is a different type of thyroid cancer [6]. It has various subtypes which are categorized based on their growth not on cytological features. The consensus diagnostic criteria for poorly differentiated carcinoma have been proposed based on the results of an international conference held in Turin, Italy in 2006 [6]. When using these criteria, these neoplasms fall into a separate intermediate group between well-differentiated papillary and follicular carcinomas, and anaplastic carcinoma. Another group of primary thyroid neoplasm is the hyalinising trabecular neoplasm which has benign course although its share cytologic features similar to that of papillary thyroid carcinomas [6]

Table 1: Histological classifications of thyroid neoplasms [6]

I. Primary		II. Secondary
1. Epithelial	2. Non-epithelial	
A. Follicular cell origin	Primary lymphoma and plasmacytoma	
A.1. Benign - Follicular adenoma a. Conventional type b. Oncocytic Type	Teratoma	
A.2.Uncertain malignant potential - Hyalinizing trabecular tumor	Solitary fibrous tumor	
A.3. Malignant - Papillary carcinoma - Follicular carcinoma a. Conventional type b. Oncocytic type -Poorly differentiated carcinoma -Anaplastic carcinoma	others	
B. C-cell origin - Medullary carcinoma		
C. Mixed follicular and C-cell origin - Mixed MTC and FTC - Mixed MTC and PTC		

NB: MTC= medullary thyroid carcinoma, PTC= Papillary thyroid carcinoma, FTC= Follicular thyroid carcinoma.

2.3: EPIDEMIOLOGY

Thyroid malignancies are the most common endocrine cancers and accounts for 3-10% of newly diagnosed cancers annually [1, 3, 4, 14]. The incidence varies worldwide depending on geographical location, sex, age and ethnicity. High incidence of thyroid cancer is seen in South Korea, North America and Australia[6]. Thyroid cancer can occur at any age but is rare in children. The average age of patients with thyroid cancer is around 50-60 years. Thyroid cancer is three times more common in women than men and in Caucasians than in black ethnic group [6]

The incidence of thyroid carcinoma has been rising especially papillary thyroid carcinoma. It is attributed to two main factors [6]. These are improvement in detection rate of thyroid nodule based on ultrasound followed by FNAC and improved understanding of follicular variant of papillary thyroid carcinoma which was initially classified as a follicular thyroid carcinoma [6].

2.4: RISK FACTORS FOR THYROID CANCERS

Risk factors for thyroid neoplasms include genetic and environmental factors. Genetic susceptibility is well established in medullary thyroid carcinoma such as in multiple endocrine neoplasia (MEN 2a and 2B) [6]. It is also observed in familial adenomatous polyposis (FAP) associated papillary thyroid carcinoma (PTC) of the thyroid which is due to mutation of adenomatous polyposis coli (APC) gene. Thyroid neoplasms are also seen in PTEN gene mutations which lead to susceptibility to follicular neoplasms although papillary carcinoma can also occur. Rarely, thyroid neoplasia is seen as part of Carney complex components of which include Werner syndrome, Peutz–Jeghers syndrome, and MEN syndromes. Family history of thyroid malignancy is another risk factor. Most of these thyroid neoplasms are known as familial non-medullary thyroid carcinomas and approximately 90% are papillary in nature and occur in first-degree relatives [6]. Few cases of genetically predisposed HCC have been reported [28].

Environmental factors which may predispose a patient to thyroid cancer include previous radiation exposure and iodine status in the region [29]. Head and neck irradiation during early

childhood dramatically increases the risk of developing thyroid cancer and the risk of developing cancer is dependent on the dose and the time period which has elapsed following exposure. The likely cancer which would develop after irradiation damage is papillary carcinoma which often is multifocal. However HCC can also occur.

Both iodine deficient and replete states predispose to thyroid cancer. Follicular carcinoma is more prevalent in areas where iodine deficiency is endemic whereas papillary carcinoma predominates in iodine supply is sufficient [30-32]. Universal iodine supplementation has led to change in the profile of thyroid cancers in low and middle income countries [33, 34]. As HCC is often preceded by Hurthle metaplasia such as in MNG, it is highly probable that iodine deficiency would also influence its occurrence.

2.5: TYPES OF THYROID CANCERS

Common primary thyroid cancers are papillary, follicular including Hurthle cell subtype, medullary and anaplastic thyroid cancers which constitute approximately 80%, 15%, 3% and less than 2%; respectively [3].

2.5.1: Papillary thyroid carcinoma

Papillary thyroid carcinoma is observed in iodine-sufficient areas and its main risk factor is ionizing irradiation to the head and neck region during childhood. It is a disease of young adults as majority of the patients are less than 45 years at presentation. It is indolent tumor with very good prognosis despite propensity to metastasize to regional lymph nodes. Pathologically it has papillary proliferation with gray to white color on gross examination. Microscopically, cells have large nuclei, the so called “Orphan-Annie” eyes and nuclear grooving. The cells may also contain psammoma bodies. Many subtypes of papillary carcinoma are observed and are thought to play a role in determining aggressiveness of the disease. Some of these subtypes of PTC include follicular, tall cell, Sclerosing and solid variants [3, 35]. Hurthle cell papillary thyroid carcinoma has been described and it has both cytological features of HCC and PTC [36].

2.5.2: Follicular thyroid carcinoma

Follicular thyroid carcinoma (FTC) represents about 15% of thyroid cancers. It is however more common in iodine deficient areas. Pathologically, it usually presents as a solitary encapsulated nodule with no papillary proliferation and is gray-tan in color. Follicular thyroid carcinoma is seen at average age of 50 years [37]. Confirmation of the diagnosis of FTC requires demonstration of capsular invasion, vascular invasion or both; which is not possible on FNAC. They are of two types of FTC which are minimally or widely invasive FTC [3, 6]. Hurthle cell carcinoma is considered a variant of FTC. Oxyphilic FTC has been described, see below [26, 37].

2.5.3: Poorly differentiated thyroid carcinoma

Poorly differentiated thyroid cancers are different entities and sit between well differentiated and undifferentiated cancers of the thyroid gland. They arise as a result of dedifferentiation of a longstanding PTC or FTC [38-40].

2.5.4: Anaplastic thyroid carcinoma

Anaplastic thyroid carcinoma (ATC) is an aggressive undifferentiated cancer mostly due to de-differentiation of differentiated follicular and papillary thyroid carcinomas. It consists of spindle cells and squamous cells [3].

2.5.5: Medullary thyroid carcinoma

Medullary thyroid carcinoma (MTC) represents about 3% of thyroid cancers. It is a neuroendocrine tumor arising from C-cells which produce calcitonin. There are two types of MTCs which are sporadic and syndromic MTCs. Familial MTC accounts for 10-30% of MTCs overall and is seen in MEN 2a, MEN 2b and familial medullary thyroid carcinoma (FMTC) [3]. Oxyphilic medullary thyroid carcinoma has been described, see below [26, 37].

2.6: HURTHLE CELL NEOPLASMS

Hurthle cell neoplasms are rare types of thyroid tumors and include non-neoplastic and neoplastic HCNs (HCA and HCC) [1, 4, 10]. They make up about 3-10%of all epithelial thyroid tumors [41]. According to WHO Classification, HCN is categorized under follicular neoplasms and named as oncocytic subtype. However some authors consider it as a separate entity [3, 8, 20, 42, 43].

2.6.1: Epidemiology of Hurthle cell neoplasms

Hurthle cell neoplasms (HCN) are encapsulated tumors that consist predominantly or entirely of Hurthle cells i.e. more than 50-75% [7, 44]. They are two types: Hurthle cell adenoma (HCA) and Hurthle cell carcinoma (HCC). Hurthle cell carcinoma of the thyroid gland represents between 5-10% of all differentiated thyroid carcinomas (DTC) [7, 8, 20, 45]. The incidence of Hurthle cell carcinoma is varied and estimated between 13-67% [1]. It has no racial predilection. The average age range is 50-60 years 10 above that of other epithelial cancers.

2.6.2: Pathology of Hurthle cell neoplasms

Hurthle cells in thyroid gland are named as oncocytic cells [4]. When observed without a tumor the condition is called oncocytic change, which is a metaplastic condition. The metaplasia occurs in chronic thyroiditis, Graves' disease and multinodular goiter (MNG). If the condition is not reversed it may lead to neoplasm known as Hurthle cell neoplasm. Hurthle cells are also found in other tissues including salivary glands and the esophagus [1, 4, 46].

Hurthle cell neoplasm is an encapsulated tumor composed of more than 50-75% of Hurthle cells with scanty colloid. Diagnosis of HCC cannot be conclusively made on FNAC. Differentiating HCA from HCC requires histological confirmation of capsular invasion, vascular invasion or both [8, 20, 27, 42, 47]. Histologically HCC is divided into minimally and

widely invasive HCC, as its follicular counterpart. It is classified as minimally invasive subtype when it has less than four (4) foci of capsular or vascular invasion while more than four foci are needed for diagnosis of widely invasive HCC [10]. Rare variants of HCC include Hurthle cell papillary thyroid carcinoma, Hurthle cell follicular carcinoma and Hurthle cell medullary carcinoma [10].

2.6.3: Prognosis of Hurthle cell carcinoma

Hurthle cell carcinoma behaves more aggressively in comparison to other differentiated thyroid cancers, especially in elderly patients [48]. It has high likelihood of multi-centricity and distant metastasis compared to other DTCs. It has a high metastatic potential in comparison to PTC and FTC, which is estimated to be about 10-20% at initial presentation [49, 50]. Hurthle cell carcinoma is susceptible to metastasize to regional lymph node, about 10% unlike the follicular counterpart [6, 51]. Common sites of distant metastasis are bones, brain and lungs.

Hurthle cell carcinoma is less avid and therefore relatively resistant to radioactive iodine therapy [43]. Even the papillary thyroid carcinoma and follicular thyroid carcinoma variants of HCC are not responsive to ^{131}I therapy [26, 37]. The overall mortality of HCC is estimated to be between 9-28% [50, 52].

2.6.4: Risk factors for Hurthle cell carcinoma

Risk factors associated with the development of HCC are generally the same as with other differentiated thyroid cancers. Some specific etiological factors are adenoma-carcinoma sequence which is not universally accepted, somatic gene mutation, oncogene activation (e.g. *ras* mutation), p53 gene over expression and gene rearrangement (RET/PTC) which is seen in Hurthle cell papillary thyroid carcinoma [28, 53]. Other variants of HCC include Hurthle cell follicular carcinoma and medullary Hurthle cell carcinoma [54]. Patients who are at risk for HCC are of older age, male gender and have tumors which are larger than 4-6cm [1, 6, 8, 17, 20, 42, 46-48, 54-58].

2.7. DIAGNOSTIC EVALUATION OF THYROID NODULES

2.7.1: Introduction

The initial evaluation of all patients with thyroid nodules whether discovered by a physician or incidentally on radiologic procedures (US, CT, MRI or PET) and suspicious for malignancy includes clinical assessment, measurement of serum TSH and ultrasound to confirm the presence of nodule. Ultrasound also allows for confirmation of whether the nodule is cystic or solid and if it solid to check if it has worrisome features [55].

2.7.2: Clinical evaluation of a patient presenting with thyroid nodule

Although history and examination are not accurate for diagnosis of thyroid cancer, there are several factors in history that may suggest an increased likelihood of malignancy [1, 15]. These factors include history of head and neck irradiation, painless mass which is rapidly enlarging, hoarseness of voice, cervical lymphadenopathy and family history of thyroid cancer [14, 15, 22]. Symptoms suggestive of hyperfunction of the thyroid gland such as heat intolerance and palpitations are uncommon in patients who have thyroid cancer [59]. Physical findings of hard mass which is fixed, cervical lymphadenopathy, Horner's syndrome or vocal cord paralysis are all suggestive thyroid cancer.

2.7.3: Biochemical evaluation of a patient presenting with thyroid nodule

The initial laboratory investigation to be done in all patients with thyroid nodules is testing for serum level of TSH. Additional laboratory tests such as free thyroxine (T4), free tri-iodothyronine (T3), thyroglobulin (Tg) and calcitonin level are done selectively [14, 18]. Serum TSH above 2.00 mIU/l is an independent predictive factor for malignancy in a patient who has a thyroid nodule [60, 61]. The level of thyroglobulin was found by some authors to be independent predictive factor for follicular or Hurthle cell carcinomas [62-64]. Thyroglobulin levels have been used for triage in patients having Hurthle cell lesions.

2.7.4: Radiological evaluation of a patient presenting with thyroid nodule

Ultrasound should be done in all patients suspected of solitary or multinodular goiter on physical examination or incidentally found on other imagining studies such as CT scan and scintigraphy [13]. It is the first-line diagnostic tool to detect and characterizes patient's thyroid nodules following test for TSH level [65]. Ultrasound scan (US) is a quick, inexpensive, readily available and non-invasive investigation tool for thyroid nodules [42, 66-69]. If TSH is low or subnormal thyroid scintigraphy and/or color-flow Doppler ultrasound are/is added.

The following are sonographic features which categorize the patients into highly suspicious of malignant nodule (hypoechoic mass, micro calcification, central vascularity, irregular margins, incomplete halo, nodule taller than wide and larger size) [13]. Thyroid Imaging Report and Data System (TIRADS) is a new way to characterize the nodule from benign to highly suspicious of malignancy (Table 2) [13, 15, 70-72]. Horvath et al, correlated FNAC of 500 nodules and following TIRADS categories were established [70-72]:

- TIRADS 1: Normal thyroid gland
- TIRADS 2: Benign condition (0% malignancy)
- TIRADS 3: Probably benign (<5% malignancy)
- TIRADS 4: Suspicious for malignancy (4a 5-10%, 4b 10-80% malignancy)
- TIRADS 5: Probably malignant
- TIRADS 6: Biopsy proven malignancy

Table 2: Expanded TIRADS [15]

Sonographic Pattern	US features	Malignancy risk %
High suspicion	Solid hypoechoic nodule or solid hypoechoic component of a partially cystic nodule with one or more of the following features i. Irregular margins (infiltrative, micro lobulated), ii. Micro calcifications, iii. Taller than wide shape, iv. Rim calcifications with small extrusive soft tissue component, v. Evidence of ETE	70-90%
Intermediate suspicion	Hypoechoic solid nodule with smooth margins without micro calcifications, ETE, or taller than wide shape.	10-20%
Low suspicion	Isoechoic or hyperechoic solid nodule, or partially cystic nodule with eccentric solid areas, without micro calcification, irregular margin or ETE, or taller than wide shape.	5-10%
Very low suspicion	Spongiform or partially cystic nodules without any of the sonographic features described	<3%

	in low, intermediate, or high suspicion patterns	
Benign	Purely cystic nodules (no solid component)	<1%

NB: ATA 2015= American thyroid association, ETE= extra-thyroidal extension

Ultrasound is not diagnostic for HCC as there are no classical findings. Similar sonographic features such solid architecture, hypo- or hetero-echogenicity, micro calcifications, increased intra-nodal vascularity and irregular border are found in HCC.

Ultrasound Elastography (USE)/elastosonography is a new diagnostic modality that assesses hardness as an indicator of malignancy in thyroid nodules. It has a high specificity and sensitivity independent of the nodule size [67]. It is used for further evaluation of Bethesda III and IV lesion (table 3a). There is scarcity of report regarding its role in the diagnostic evaluation HCNs. Thyroid scintigraphy has a limited role in evaluation of euthyroid solitary nodule, even if it is HCN [14].

2.7.5: The role of fine needle aspiration cytology in evaluation of HCNs

Fine-needle aspiration cytology is the gold standard in the management of thyroid nodule [73, 74]. Indications for FNAC assessment of thyroid nodule include patients' risk profile, nodule size and sonographic features suspicious for malignancy [14, 15]. FNAC can be done blindly or preferably under ultrasound guidance to target the suspicious nodules especially if the nodule is less than 2cm in diameter or is posteriorly situated [75]. Tissue samples are obtained by using 23-27 gauge needle attached to 10ml syringe. Materials are smeared on slide, fixed with alcohol and stained. Fine needle aspiration cytology is deemed adequate if it is diagnostic or if the sample contains four to six (4 to 6) groups of well-preserved cells each having 10 to 12 follicular cells. It is sometimes difficult obtain adequate sample from cystic nodules [76].

Fine-needle aspiration cytology is a simple and safe procedure that has reduced the number of patients undergoing unnecessary thyroidectomy. Pain and hematomas are common but minor complications following FNAC procedure. Tracheal puncture, needle track seeding by malignant cells and recurrent laryngeal nerve injury are rare.

In experienced hands adequate sampling is obtained in 90.0 to 97.0% of thyroid nodules [47, 55, 75, 77]. The overall accuracy of FNAC exceeds 95.0% [20]. Sensitivity and specificity of thyroid FNAC for the diagnosis of malignancy are 94.0% and 98.5%, respectively [78]. Recently, published international guidelines report the average sensitivity and specificity for thyroid FNAC of 83.0% and 92.0% respectively and the accuracy of 84.0-95.0% for PTC, MTC, and lymphoma [79]. However, these sensitivity and specificity data are not applicable to FCNs and HCNs 85-90.0% [20, 77, 78, 80].

For interpretation of thyroid FNAC result, The Bethesda System for Reporting Thyroid Cytopathology (Bethesda System) is currently preferred [81]. The Bethesda System places thyroid FNAC results into six diagnostic categories. Please see Table 3a and 3b for diagnostic categories and recommended management [20].

Table 3a: The Bethesda System for Reporting Thyroid Cytopathology: Recommended Diagnostic Categories [20]

I. Non-diagnostic or Unsatisfactory
Cyst fluid only
Virtually acellular specimen
Other (obscuring blood, clotting artifact, etc.)
II. Benign
Consistent with a benign follicular nodule (includes adenomatous nodule, colloid nodule, etc.)
Consistent with lymphocytic (Hashimoto) thyroiditis in the proper clinical context
Consistent with granulomatous (subacute) thyroiditis

Other

III. Atypia of Undetermined Significance or Follicular Lesion of Undetermined Significance

IV. Follicular Neoplasm or Suspicious for a Follicular Neoplasm

Specify if Hurthle cell (oncocytic) type

V. Suspicious for Malignancy

Suspicious for papillary carcinoma

Suspicious for medullary carcinoma

Suspicious for metastatic carcinoma

Suspicious for lymphoma

Other

VI. Malignant

Papillary thyroid carcinoma (PTC)

Poorly differentiated carcinoma

Medullary thyroid carcinoma (MTC)

Undifferentiated (anaplastic) carcinoma

Squamous cell carcinoma

Carcinoma with mixed features (specify)

Metastatic carcinoma

Non-Hodgkin lymphoma

Other

Table 3b: The Bethesda System for Reporting Thyroid Cytopathology: Implied Risk of Malignancy and Recommended Clinical Management [20]

Diagnostic category	**Risk of malignancy (%)**	**Recommended management**
Non-diagnostic or unsatisfactory	1-4	Repeat FNA with ultrasound guidance
Benign	0-3	Clinical follow-up
AUS or FLUS	~5-15	Repeat FNA
Suspicious for follicular neoplasm	15-30	surgical lobectomy
Suspicious for malignancy	60-75	Near-total thyroidectomy or surgical lobectomy
Malignant	>95	Near-total thyroidectomy or surgical lobectomy

NB: AUS= Atypia of unknown significance, FLUS= follicular lesion of unknown significance

There is uncertainty in thyroid cytology because of the category of follicular neoplasm as it cannot differentiate between adenoma from carcinoma. Bethesda I and Bethesda III add to this uncertainty [20, 46, 82, 83]. These indeterminate groups constitute around 10% of all FNAC results [58, 84]. Molecular markers including Ki67 index and mutational analysis are used to assist to either rule-in or rule out malignancy when FNAC is inconclusive [74]. The mutational analyses include three tests; Gene Expression Classifier (GEC)[85], 7-gene panel of genetic mutation and rearrangement testing[86] and multiplexed next-generation sequencing [15] (NGS) panel [10] None however has been found to be reliable for diagnosis of HCC.

Non-diagnostic FNAC (Bethesda I) smears occur when there are insufficient follicular cells to make a cytological diagnosis which happens in 5-10% of FNACs and malignant risk is about 1-4% [14, 15]. A repeat FNAC under ultrasound guidance is indicated unless two or more

FNACs have been done and are non-diagnostic as the patient has to be taken for biopsy which entails as minimum lobectomy of the index side [58]. Diagnostic total thyroidectomy is sometimes indicated in high risk patients such as patients with strong family history, previous neck irradiation, multi-nodularity, bilateral nodules and if the thyroid nodule is greater than 4cm in diameter [42, 87]. Hurthle cell neoplasm is unlikely to fall under this category.

Fine needle aspiration cytology yields benign diagnosis (Bethesda II) in 60-70% of cases. Some of these benign conditions include colloid goiter, adenomatous nodule and hyperplastic nodules [15, 20]. The risk of malignancy in Bethesda II lesion is about 0-4% [20]. These patients should be followed up with sonar and physical exam six monthly and thereafter yearly depending on risk profile. A large benign nodule may necessitate thyroidectomy if it is causing pressure symptoms or for cosmetic reasons. Hurthle cells are not a rare finding in benign conditions such MNG and chronic thyroiditis. Despite a benign report management of these patients should be guided by clinical risk profile.

Atypia of undetermined significance (Bethesda III) accounts for 3-6% of thyroid FNAC results and has a malignant risk ranging from 5-15%. A repeat FNAC is therefore warranted [20, 77]. Diagnostic lobectomy may be indicated based on patient's risk profile namely clinical risk, and radiologic features [15]. Some HCNs will fall into this group.

As FNAC cannot discriminate between follicular adenoma and carcinoma, the term "follicular neoplasm" (FN) is used. Approximately 15-30% FNs will turn out to be malignant on subsequent lobectomy [12, 58, 77, 78, 83]. Hurthle cell adenoma and carcinoma are oncocytic variants of follicular adenoma (FA) and follicular carcinoma (FC), respectively. Cellular samples made almost exclusively of Hurthle cells are called HCN rather than FN. About 16-25% will be proven to be non-neoplastic proliferation of Hurthle cells known as Hurthle cell change. Nearly 15% to 45% of nodules will be proven to be malignant and the remainders will be HCA [17, 20, 88]. This designated class required diagnostic lobectomy and isthmusectomy of the involved side. Total thyroidectomy is performed occasionally for high risk lesion [42, 87].

Majority of thyroid cancers are diagnosed with certainty on FNAC. It however is not the case with follicular variant of PTC. Fine needle aspiration cytology result may return 'suspicious for malignancy' or specifically suspicious for papillary carcinoma (Bethesda V). The rate of

malignancy in Bethesda V lesion is 60-75% [20]. These patients are managed with total thyroidectomy. Bethesda V finding is less likely in HCN.

In about 3-7% of FNAs, FNAC yield a papillary thyroid cancer (PTC) and occasionally medullary (MTC) or anaplastic cancer (Bethesda VI). These patients should undergo total thyroidectomy with or without lymph node dissection [20]. As HCC cannot be diagnosed on FNAC it is highly unlikely that any of HCN tumors return a Bethesda VI report.

2.8: STAGING OF HURTHLE CELL CARCINOMA

Various prognostic factors and staging systems are used in the management of DTC and HCC [4, 19, 20, 43, 45, 46, 57, 58, 89, 90]. These include the tumor, node and metastasis (TNM) system of AJCC (Table 4).

Table 4: Tumor-Node-Metastasis staging system of differentiated thyroid carcinoma [15, 91, 92]

Stage	Age <45	Age >45
1	**Any T, any N, M0**	**T1, N0, M0**
2	**Any T, Any N, M1**	**T2 or T3, N0, M0**
3		**T4 or N1, M0**
4		**Any T, any N, M1**

Tumor staging:	Nodal status	Metastasis
T1 < 1cm	N0= no nodal metastasis	M0= no metastasis
T2 > cm < 4cm	N1= nodal metastasis	M1= Metastasis
T3 > 4cm		
T4 beyond thyroid		

The TNM staging system is most (NCCN and AJCC 7th Edition (2010) accepted system worldwide. Clinicopathological factors which are used for TNM system are age of patient, gender of the patient, size of tumor, metastasis and presence or absence of extra-thyroidal extension. The other prognosticating scoring systems are AGES (for age, grade, extent and size), AMES (for age, metastasis, extent and size) and MACIS (for metastasis, age, complete excision, extra-thyroidal extension and size [93].

2.9: MANAGEMENT OF HURTHLE CELL NEOPLASMS

Treatment of differentiated thyroid carcinomas includes surgery, TSH suppression, chemotherapy and radioactive iodine treatments [94]. Surgery is the mainstay of treatment for patients with DTCs [15, 21]. Based on risk profile, patients may undergo either thyroid lobectomy, total thyroidectomy alone, or total thyroidectomy and lymph node dissection. TSH suppression and Iodine 131 (^{131}I) ablation are added in patients who have intermediate and high risk DTC [15].

Diagnostic lobectomy is indicated in the low risk patient while total thyroidectomy is preferred for intermediate and high risk patients. Subsequently, TSH suppression with thyroxine, radioiodine therapy and adjuvant external beam radiotherapy are added. Thyroid hormone (either T4 or T3) is added Thyroxine to prevent hypothyroidism and to decrease TSH, which if it rises may stimulate growth of residual thyroid tissue including metastasis [10, 95]. The level TSH suppression depends on ATA 2015 risk stratification, and ranges from 0.5mU/L for low risk patients to <0.1 mU/L in high risk patients [15]. Bone lost, atrial fibrillation and cardiac dysfunction are some of toxic effects of thyroxine therapy. The level of TSH suppression is therefore tailored based on patient's risk profile [96, 97].

Radioactive iodine is used to ablate residual thyroid tissue and cancer, deposit in the tumor bed and metastasis in DTCs. However HCC generally has low uptake of radioactive iodine. Addition of radioactive iodine therapy (RAT) is also subject to risk stratifying patients. Adjuvant chemotherapy for DTCs include cytotoxic chemotherapy such as doxorubicin; kinase inhibitors e.g. sorafenib and BRAF inhibitor like vemurafenib [15].

The accepted surgical approach for a patient suspected to be having HCC is diagnostic lobectomy and isthmusectomy except if the patient has high risk clinical features such as

previous neck irradiation, multiple foci and family history of thyroid cancer or the tumor is larger than 4cm in diameter [10]. If histology confirms HCC, then completion thyroidectomy is considered based on risk profile. If histology showed a minimally invasive tumor with size less than 1 cm in diameter, completion thyroidectomy is not indicated. Widely invasive HCC is managed based on ATA risk stratification profile and total thyroidectomy is mandated [68].

2.10. FOLLOW UP OF PATIENTS WHO HAVE HURTHLE CELL NEOPLASM

Post-surgical treatment of patients with DTC includes scheduled follow up to monitor response to treatment as well as detection of recurrence. In the first year neck ultrasound, serum TSH and thyroglobulin levels are measured during each visit, 3-6 months [15]. Subsequent imaging modalities are required based on risk profile and level of Tg and TSH [15, 98]. These procedures include FDG-PET scan, magnetic resonance imaging (MRI) and CT scan. Clinical outcome is classified based on former tools into one of the following categories:

i. Excellent response: no clinical, radiological and biochemical evidence of disease.

ii. Biochemical incomplete response: only abnormal Tg or Tg antibodies.

iii. Structural incomplete response: persistent or new loco-regional or distant metastasis.

iv. Indeterminate response: nonspecific biochemical and structural findings [72].

Subsequently patients are screened in annually basis using the same above mentioned parameters. Follow-up of patients following thyroidectomy for HCC is similar.

CHAPTER THREE

RESEARCH METHODOLOGY

3.1: INTRODUCTION

Hurthle cell neoplasm is a variant of follicular thyroid neoplasms [99]. Distinction between HCA and HCC remains a challenge [87]. No single preoperative diagnostic test is able to demonstrate this distinction, however molecular study is promising. After literature search, there is no reported incidence of this type of cancer has been conducted in this province. We retrospectively search for demographic factors and histopathological features which can be used to predict of HCC in patients with HCN.

3.2: STUDY AIM AND OBJECTIVES

3.2.1: Study aim

To determine the prevalence of HCC and its demographic factors and histopathological features that can be used to predict the risk of malignancy in HCN.

3.2.2: Study objectives

i. To determine the demographic and histopathological findings in patients who had Hurthle cell neoplasms.

ii. To determine what proportion of patients who had thyroidectomy for Hurthle cell neoplasm were on histology confirmed to be having Hurthle cell carcinoma.

iii. To determine if fine needle aspiration cytology is able to distinguish Hurthle cell adenoma from Hurthle cell carcinoma.

iv. To determine if there are factors which are predictive of HCC in patients presenting with Hurthle cell neoplasms.

3.3: Methodology

3.3.1: Research design

Audit based on histopathology results of the National Health Laboratory Services (NHLS), Department of Anatomical Pathology.

3.3.2: Setting

Three academic hospitals of Johannesburg, South Africa namely: Chris Hani Baragwanath Academic Hospital (CHBAH), Helen Joseph Hospital (HJH), Charlotte Maxeke Johannesburg Academic Hospital and the Department of Anatomical Pathology of the NHLS.

i. Chris Hani Baragwanath Hospital (CHBAH) is a public hospital located in southern part of Gauteng (Soweto), Johannesburg, South Africa.
ii. Helen Joseph Hospital (HJH) is a public hospital located in Auckland Park, Johannesburg, South Africa.
iii. Charlotte Maxeke Academic Hospital (CMJAH) is a public hospital located in Parktown, Johannesburg, South Africa.

3.3.3: Study population

Histopathology and FNAC results of all consecutive patients, who underwent thyroidectomy in the University hospital between January 2001 and October 2015.

3.3.4: Inclusion criteria

1. Histopathology reports of all patients who had thyroidectomy
2. All available FNA results
3. All ages

3.3.5: Exclusion Criteria

Thyroidectomy results for benign diseases.

3.3.6: Ethics and Permission

Ethical approval was obtained from the Human Research Ethics Committee of the University of the Witwatersrand (Clearance No. M150944). Permission to carry out the study was obtained from Department of Anatomical Pathology of NHLS and Research Review Boards of respective hospitals. All study participants were given a study number to ensure anonymity of data.

3.3.7: Data collection and Statistical Analysis

Demographic and histopathological characteristics data were captured using Excel spreadsheet and analyzed using Statistics/Data Analysis software 2015 (version 13.1). Continuous data for age and tumor size were presented as mean +/- standard deviation. Fisher's exact test was used for categorical data. Parameters data were compared using student's t-test. The level of significance was set at P-value of less 0.05.

CHAPTER FOUR

4.1: RESULTS

A total of 2641 histopathological reports of consecutive patients who underwent thyroidectomy were found and majority was for benign disease 74.4% (1965/2641) (Figure 1a and 1b) and were excluded.

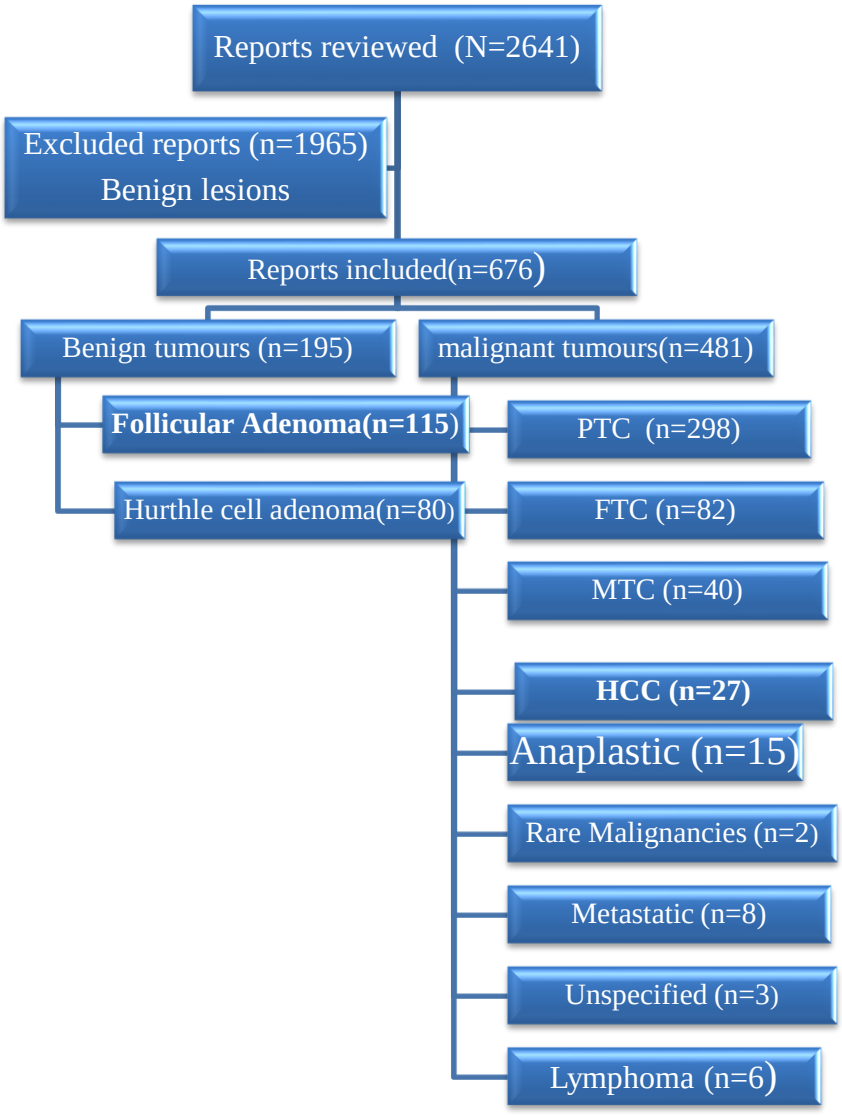

Figure 1a: Breakdown of histology results of thyroidectomy specimens

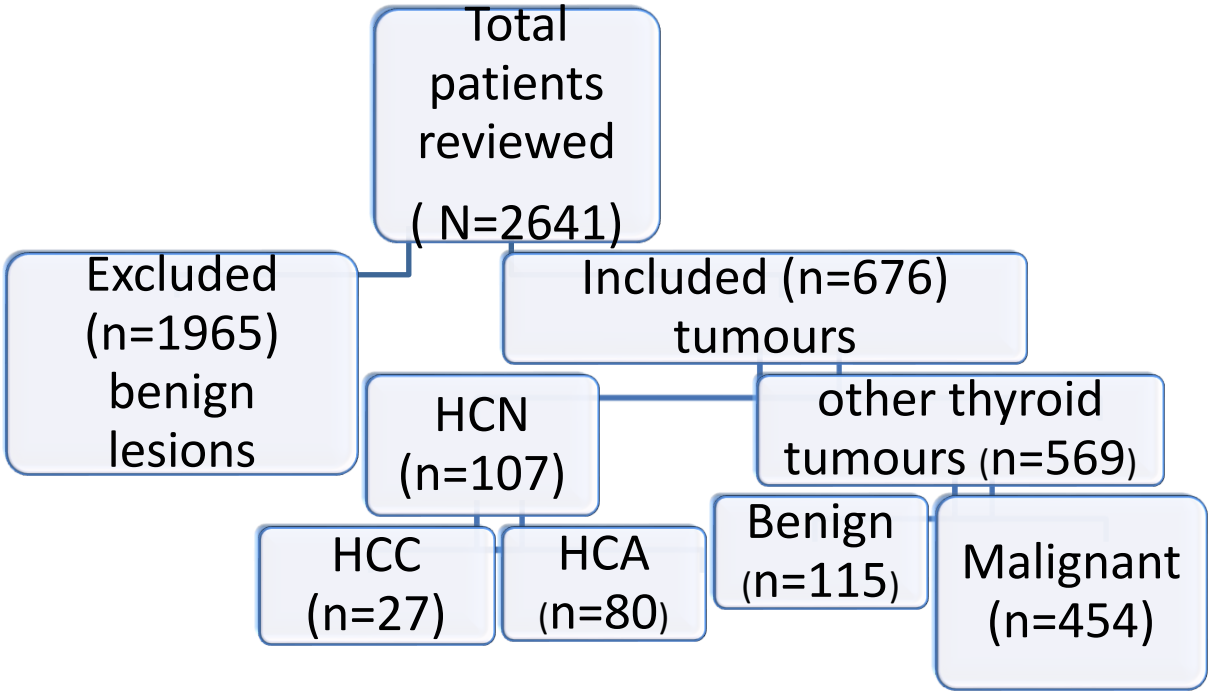

Figure 1b: Abbreviated breakdown of histology results of thyroidectomies.

4.2: Neoplasms of thyroid gland

25.6% (676/2641) of thyroidectomies were for benign and malignant tumours (Table 5 and Figure 1a and 1b). The mean age of patients who had thyroidectomy for tumours in years was 47.3 +/- 15.9 (SD) and 82.5% (558/676) were females. However 71.2% (481/676) were malignant of which 62.0% (298/481) were papillary and 5.6% (27/481) Hurthle cell carcinomas (Table 5).

Table 5: Distribution of thyroid tumors according to histology reports.

Pathological diagnosis	n=676	Percent
Benign tumors (n=195)		
Follicular adenoma	115	59.0%
Hurthle cell adenoma	80	41.0%
malignant tumors (n=481)		
Papillary carcinoma	298	62.0%
Follicular carcinoma	82	17%
Medullary carcinoma	40	8.3%
Hurthle cell carcinoma	27	5.6%
Anaplastic carcinoma	15	3.1%
Lymphoma	6	1.3%
Metastatic carcinoma	8	1.7%
unspecified carcinoma	3	0.6%
Malignant teratoma of thyroid	1	0.2%
Malignant solitary fibrous tumor	1	0.2%

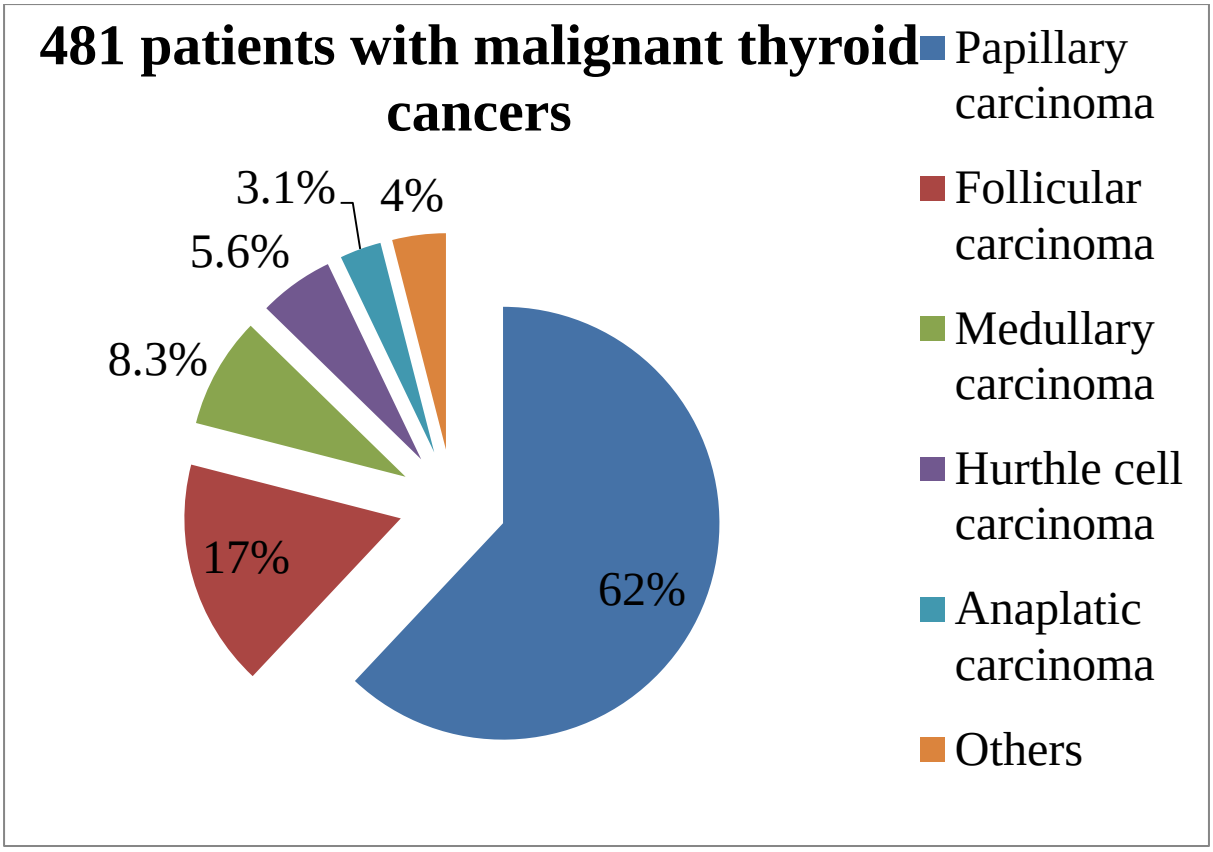

Figure 2: Breakdown of thyroid tumors of the thyroid based on histology reports. NB: others= malignant teratoma and malignant solitary fibrous carcinoma of the thyroid

4.3: Demographic of patients with Hurthle cell neoplasms

A total of 107 patients had HCN of which 75.0% (80/107) were HCA and 25.0% were HCC. The majority of patients with HCA were females (86.0%). Patients with HCC included 21 females and six (6) males with a female to male ratio of 4.5:1 and a mean age of 55.0 years (32-84). Patients with HCA were 71 females and nine males (at ratio of 8.9:1) with a mean age of 52.3 years (23-95) (Figure 3 and 4). The difference of age and gender were not statistically significant between two groups (P=0.156), (Table 6). Around 86.o% of the study cohort were females. Nonetheless, the malignancy rate was 22.8% in females compare to 40% in males who had HCN.

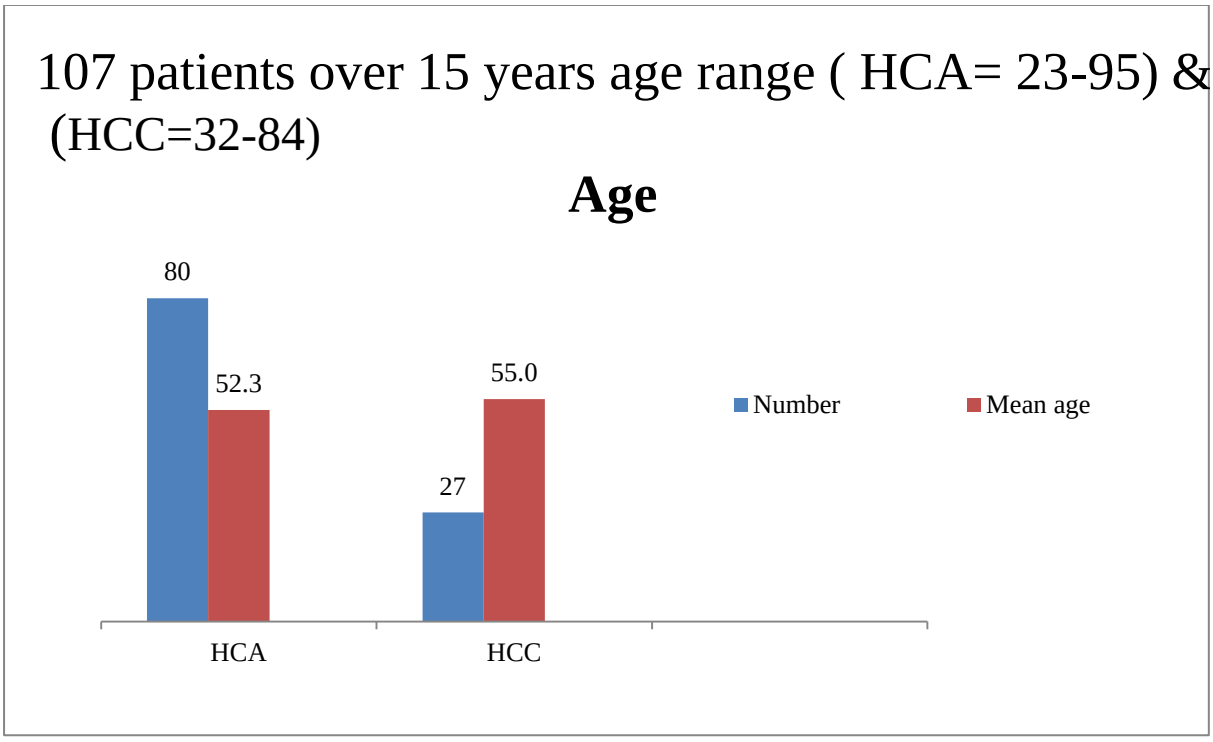

Figure 3: Mean age of 107 HCN patients.

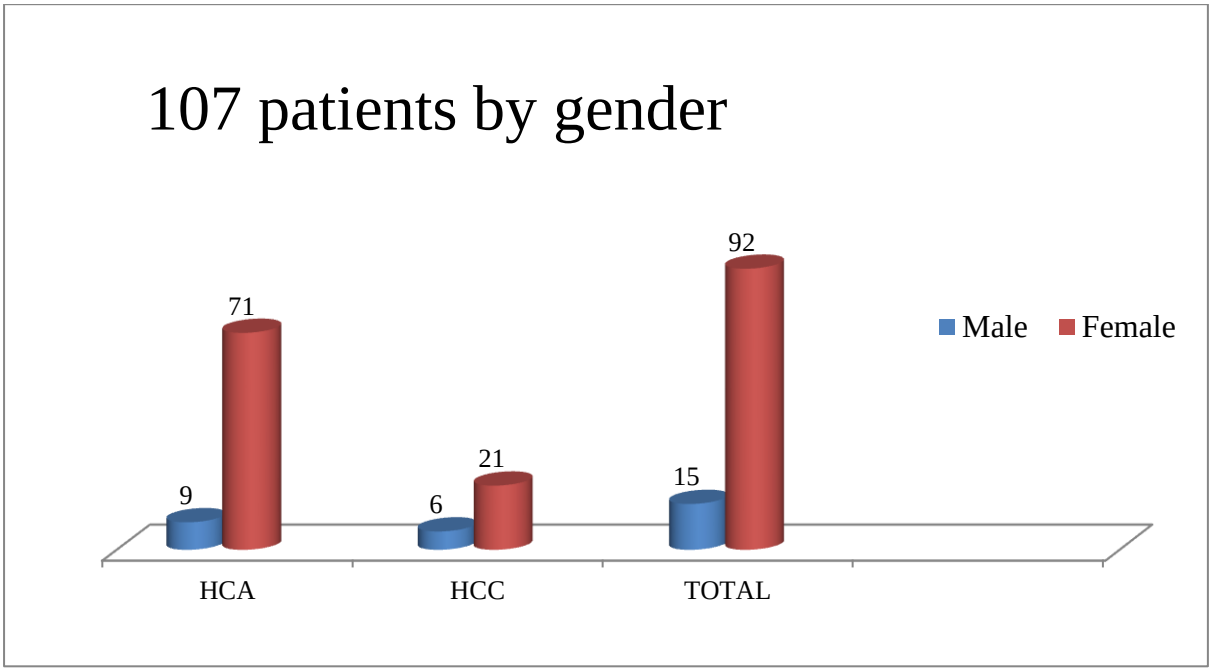

Figure 4: Gender of 107 HCN patients.

Table 6: Characteristics of 107 patients with Hurthle cell tumors

Parameter	Hurthle cell carcinoma	Hurthle cell adenoma	*P value*
No. of patients	27	80	
Male	6 (22.2%)	9 (11.3%)	
Female	21 (77.8%)	71 (88.7%)	
ratio (M/F)	1.0: 4.5	1.0: 8.9	0.156
Patient's age (years)			
<45	7 (26%)	29 (36.3%)	NS
45-65	13 (48%)	31 (38.8%)	NS
>65	6 (22%)	19 (24.9%	NS
Age (yrs.), mean +/- SD	55.0 +/15.0years	52.3+/15.6 years	0.274
Range	32-84	23-95	
Tumor size, mean (cm) +/-SD	4.9 +/- 2.7	3.5+/- 2.0	0.016
Range (cm)	0.8-10.0	0.2-9.0	
<1.0 cm	3/26 (11.1%)		NS
1-4.0 cm	9/26 (33.3%)	34/52 (65.4%	NS
>4.0 cm	14/26 (52.8)	18/52 (34.6%)	NS

4.4: Diagnosis of HCN

Of 107 patients, 58 had preoperative FNAC results (Table 7). Of these, 36 FNACs were Bethesda III and IV (Table 7) and (Figure 5) and 27.8% (10/36) of the indeterminate FNACs were proven to be malignant on Histology.

Table 7: FNAC category and Hurthle cell neoplasms

FNA Category	HCC	HCA	total
Malignant	0	7	7
Benign	1	7	8
AUS	1	4	5
FN or FLUS	9	22	31
Suspicious of Malignant	1	0	1
Nondiagnostic	1	5	6
Total	13	45	58

HCC= Hurthle cell carcinoma, HCA= Hurthle cell adenoma, AUS= Atypia of undetermined significance, FN= Follicular neoplasm, FLUS= follicular lesion of undetermined significance

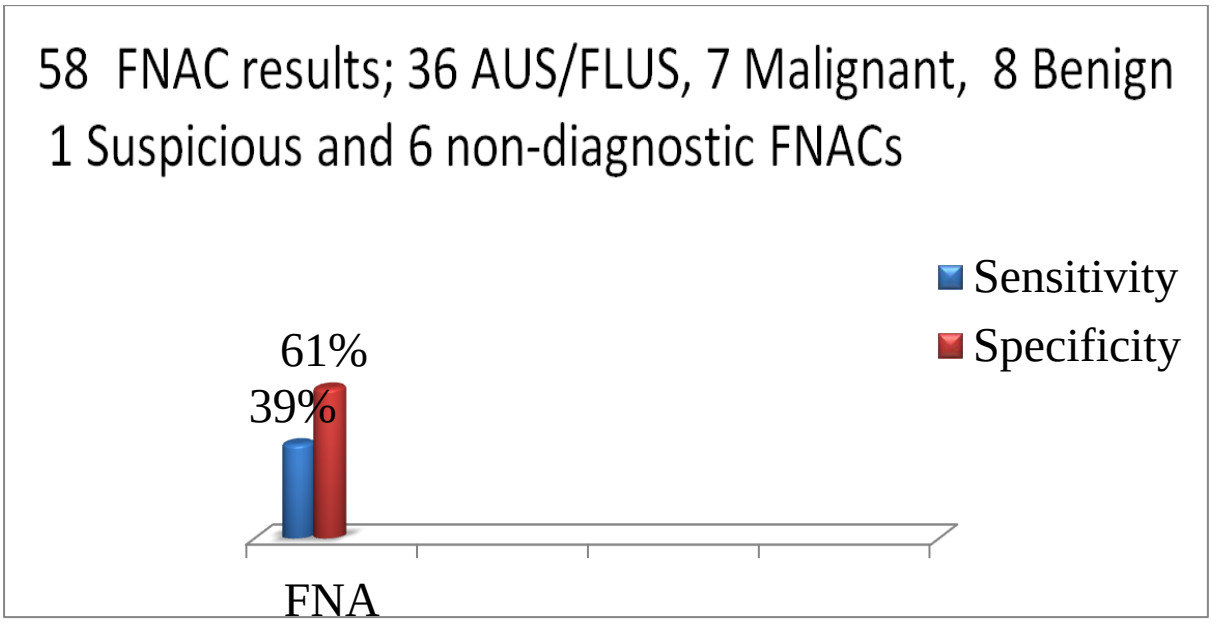

Figure 5: Sensitivity and specificity of FNAC to diagnose HCC.

Sensitivity and specificity of FNAC for diagnosis HCC was 39% and 61% sensitivity and specificity for HCC, respectively (Tables 8, Figure 5).

Table 8: Fine-needle aspiration cytology and histology results of 107 Hurthle cell tumors

	Final Histology	
FNA	HCC	HCA
FNA	27	80
Not available = 14 v 35	14/27 (51.9%)	35/80 (43.8%)
Available =13 v 45	13/27 (48.1%)	45/80 (56.2%)
False negative FNA= 1	1/13	
True positive =0	0/13	

4.5: Presence and Absence of malignancy

Statistical analysis showed a significant statistical difference between the tumour size of HCA and HCC. Malignancy was associated with bigger size (4.9 v 3.5; p= 0.016 (Figure 6). Of 27 patients with HCC, 18 were follicular variant HCC, three were papillary variant HCCs and the rest were classical HCCs.

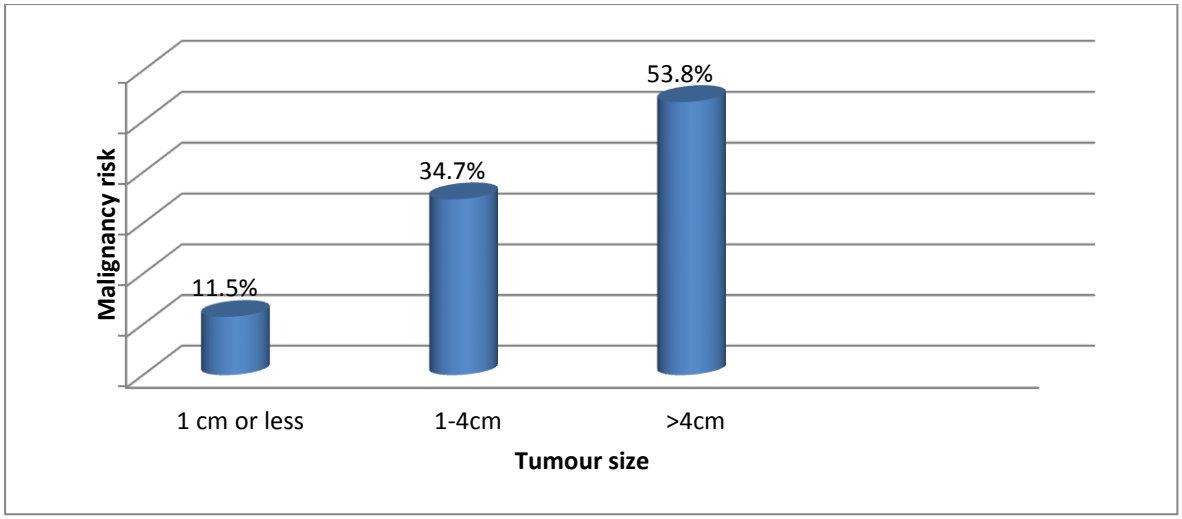

Figure 6: Tumour size (cm) and risk of malignancy (%).

Patients Management

Close to 41% (44/107) of patients underwent total thyroidectomy and 50.5% (54/107) had thyroid lobectomy. Most of the operations were done for multinodular goitre (MNG). Of 27 patients with HCC; 22.2% (6/27) had total thyroidectomy for MNG in which HHCC was incidentally discovered on final histopathology and 48.1% (13/27) had lobectomy and isthmusectomy indicated for MNG (Table 8). Total thyroidectomy was done in 33 of the 80 HCA due to MNG, (Table 9).

Table 9: Surgical procedures for Hurthle cell neoplasms.

Operative procedures	HCA	HCC	Total
Total Thyroidectomy	33	11	44
Hemithyroidectomy	41	13	54
Subtotal Thyroidectomy	3	2	5
Completion Thyroidectomy	2	1	3
All	79	27	106

Table 10: Findings in HCC patients treated with lobectomy (n=13)

Parameter	**Age (yrs.)**	**Gender (M/F)**	**Maximum diameter**	**C I (+/-)**	**VI (+/-)**	**Variant**
Case 1	38	F	3.0cm	+	+	Follicular variant HCC
Case 2	42	F	8.5cm	+	+	Classical HCC
Case 3	46	F	6.2cm	+	-	Follicular variant HCC
Case 4	49	M	4.5cm	+	+	Follicular variant HCC
Case 5	50	F	1.5cm	+	+	Classical HCC
Case 6	51	F	7.5cm	+	-	Follicular variant HCC
Case 7	51	F	4.0cm	+	-	Follicular variant HCC
Case 8	57	F	6.0cm	+	+	Papillary variant HCC
Case 9	58	M	6.0cm	+	+	Follicular variant HCC
Case 10	63	F	2.5cm	+	+	Classical HCC
Case 11	79	F	2.4cm	+	-	Papillary variant HCC
Case 12	82	F	3.5cm	+	-	Classical HCC
Case 13	84	F	2.0cm	+	+	Follicular variant HCC

NB. CI= capsular invasion, VI= vascular invasion

CHAPTER FOUR

DISCUSSION

Majority of thyroidectomies 74.4% (1965/2641) were due to benign thyroid diseases. Only 25.6% (676/2641) of thyroidectomies were done for thyroid tumors in which 71.2% (481/676) were malignant neoplasms. Papillary carcinoma was the more common carcinoma with 62% (298/481) followed by FTC 17% (82/481). In our study, the prevalence of PTC was lower than it has been reported in the literature. The explanation may be due to the fact that in the past follicular variant of PTC were classified as follicular neoplasms/carcinoma [6].

The incidence of HCN ranges from 3-10% of differentiated thyroid tumors [8, 42, 45, 49, 68, 100, 101]. Many studies have shown that the prevalence of malignant HCN ranges from 5-35% [37, 42, 45, 57, 68, 101] and benign HCN to be 80% or more especially, when found on the background of MNG and lymphocytic thyroiditis [101]. In our study Hurthle cell carcinoma represented 5.6% of all differentiated thyroid carcinomas treated during the study period. The prevalence of malignancy among HCNs was 25.2% (27/107) which is the same as what have been reported in the literature [37, 42, 101].

The diagnosis of Hurthle cell carcinoma is made on the demonstration of capsular and/or vascular invasion which can be either minimally or widely invasion on histology. In our study, of the 27 patients with HCC, all had capsular invasion whereas 16 of these had both capsular and vascular invasion [62, 102]. Several studies have shown that FNAC is a reliable test to diagnose HCNs [8, 20, 37, 50]. However, the distinction between benign and malignant HCN pre-operatively is not possible [8, 13, 37, 42, 62, 100]. This differentiation is so critical because definitive surgery, such as total thyroidectomy can be done for carcinoma upfront [43, 58, 101], and thyroid lobectomy reserved for HCA [4, 19, 26, 42, 44, 45, 62, 66, 100, 103-105]. Appropriate surgical treatment is important as HCC is relatively resistant to RAI ablative therapy [42, 57, 106]. Some experts recommend total thyroidectomy for HCN based on evidence that suggest that HCC is an aggressive tumor with high metastasis potential, limited RAI uptake and an overall poor prognosis [3, 20, 107].

Of 58 patients with adequate FNAC, 37 were suspicious of HCN of which 11 were histologically confirmed HCC comprising of about 29.7%. Similar results were reported by

Chen et al, that 20-30% of Bethesda III and IV FNAC will turn up to be malignant on final histology [42] .

Many Hurthle cell neoplasms, many clinicohistopathological features which are predictive for malignancy have been studied; these include patient's age, gender, and tumor size [2, 4, 8, 19, 26, 42, 43, 45, 46, 57, 58, 67, 68, 82]. Patients with HCC are older than HCA counterpart as reported by Carcangiu et al [2] and Lopez-Penabad et al [56, 57]. In this study, none of the clinical factors found to be statistically significant. Hurthle cell neoplasm patients with HCC diagnosed on final histopathology, compared with patients with benign pathology were of similar age (mean age 55.0+/- 15 vs. 52.3) [58]. Distribution by gender was also not statistically significant between these two groups. Many investigators have reported that the size of tumor increase the likelihood of HCC among patients with HCN [2, 4, 42, 46, 108]. Straziser et al reported that the malignancy rate in patients with tumor size between 1cm and 4cm and greater than 4cm were 20% and 40%, respectively [4]. Chen et al also reported that tumor which is 1cm or less has 17% malignancy risk compared to 23% and 65% HCN with tumor size of 1-4cm and > 4cm, respectively [42]. Discordant results were observed in our study. Malignancy rate was 46% and 53% for tumor < 4 cm and > 4 cm, respectively. In this report, tumor size was predictive for HCC as illustrated by both univariate and multivariate analysis. Many authors cited the unpredictability of the behavior of HCC in keeping with the variation in aggressiveness related to its variants [7, 8].

There are three variants of HCC; papillary variant of HCC, Hurthle cell follicular variant and oncocytic variant of medullary carcinoma [109]. HCPTC is composed of cells with typical nuclear features of PTC as well as with features of oncocytic lesions (granular cytoplasm with >75% of oncocytic cells) [110]. HCPTC is common in the fifth decade, with 10-15% nodal involvement unlike classical HCC (<5% nodal involvement) and poor prognosis as well as insensitivity to RAI. Unlike HCC, oncocytic variant PTC do show RET/PTC gene rearrangement. Hurthle cell follicular variant is identical to classical HCC in term of age, aggressive behavior, hematogenously spread and insensitivity to RAI except on morphology where HCC has cells which are polygonal, large with granular cytoplasm and scanty colloid. Oncocytic variant of medullary carcinoma is not truly a variant of HCC although it is composed of some oncocytic cells which have very small nuclei unlike pleomorphic nuclei of HCC [50, 51].

Management of HCNs is not standardized due to the controversies regarding the diagnosis and the biological behavior. Some investigators recommended thyroid lobectomy as an initial surgical procedure, followed by completion thyroidectomy upon histological diagnosis of HCC [13, 42]. Others suggest total thyroidectomy because of the unpredictable behavior [42], multifocality [43], and high prevalence of the malignancy [4, 42, 43, 45].

Regarding initial management of our patients, majority underwent either total thyroidectomies (44/107) or thyroid lobectomy/isthmusectomy (54/107) mainly on the background of MNG, and incidentally found to be harboring HCC. It is worth mentioning that 48.0 % of patients with HCC were managed with thyroid lobectomy only.

Limitations

Like any other retrospective study, our study has many limitations. Our study is the audit of histopathological report only. Therefore, the subsequent management for HCC in term of completion thyroidectomy and RAI ablation therapy were not looked into. Also long term follow-up of patients with HCC was not apparent in order to assess the biological aggressive in term of survival and recurrence. Also most of the FNA results were not available for review.

CHAPTER FIVE

CONCLUSION

Majority of HCCs are diagnosed following thyroidectomy for benign disease. About a quarter of HCNs are malignant and the risk of malignancy increases with size. Age and gender are not useful to predict malignancy in HCNs.

Malignant thyroid neoplasms were accounting 71.2% of all epithelial and non-epithelial neoplasms. 62% were papillary thyroid carcinoma, the percentage which is lower than described in the literature. This may be attributed to the fact, in the past follicular variant of papillary thyroid carcinoma were categorized as follicular carcinoma.

In our local settings, HCC is not uncommon in comparison to outside world. It has the incidence of 5.6% among differentiated thyroid cancers and prevalence of 25.2% among HCNs. 86% of study cohort were females and the malignancy risk among female was 22.8% comparable to 40% in male. Therefore, thyroid disease is common in female but when nodules are found in male chances of being malignant is high. This was not demonstrated by statistical analysis as a significant factor in this report. Other independent risk factors associated with malignant HCN are older age, and large tumor size. The average age for benign versus malignant HCN were relatively similar (52.3 v 55). Tumor size was larger for HCC versus HCA (4.9 v 3.5). Total thyroidectomy and thyroid lobectomy/isthmusectomy were complimentarily done for our patients, mainly due to MNG and HCN were incidentally found. Interestingly, 13/27 of patients HCC were managed only with thyroid lobectomy. Regarding variant of HCC, 77.8% (21/27) were both Hurthle cell follicular 85.7% (18/21) and Hurthle cell papillary carcinoma 14.3% (3/21). These variants are associated with worst prognosis unlike classical HCC.

Our data showed that the size of the Hurthle cell neoplasm is the only predictive clinicopathological factor associated with risk of malignancy. Hence, Hurthle cell neoplasm with large size on solitary nodule or on background of multinodular goiter suspected on preoperative FNAC should undergo total thyroidectomy, because of higher probability of malignancy.

Recommendation

We recommend total thyroidectomy thyroid nodule greater than 4cm in diameter if FNAC result is suggestive of HCN as the risk of malignancy is above 50%.

LISTS OF REFERENCES

1. Cannon J. The significance of Hurthle cells in thyroid disease. The Oncologist, 2011; 16(10): p. 1380-1387.
2. Carcangiu M, Bianchi S, Savino D, Voynick I, Rosai J. Follicular Hurthle cell tumors of the thyroid gland. Cancer, 1991; 68(9): p. 1944-1953.
3. Katoh H, Yamashita K, Enomoto, T, Watanabe M. Classification and general considerations of thyroid cancer. Ann Clin Pathol. 2015; 3(1): p. 1045-1054.
4. Strazisar B, Petric R, Sesek M, Zgajnar J, Hoceva, M, Besic N. Predictive factors of carcinoma in 279 patients with Hürthle cell neoplasm of the thyroid gland. J Surg Oncol. 2010; 101(7): p. 582-586.
5. Chen AY, Jemal A. Ward EM, Increasing incidence of differentiated thyroid cancer in the United States, 1988–2005. Cancer, 2009; 115(16): p. 3801-3807.
6. Nikiforov YE. Thyroid tumors: classification, staging and general considerations. Diagnostic pathology and molecular genetics of the thyroid. Baltimore: Lippincott Williams &Wilkins, 2012: p. 108-118.
7. Barnabei A, Ferretti E, Baldelli R, Procaccini A, Spriano G, Appetecchia M. Hurthle cell tumours of the thyroid. Personal experience and review of the literature. Acta Otorhinolaryngol Ital. 2009 Dec; 29(6): 305-311.
8. Ganly I, Ricarte FJ, Eng S Ghossein R, Morris L, Liang Y et al. Genomic dissection of Hurthle cell carcinoma reveals a unique class of thyroid malignancy. J Clin Endocrinol Metab. 2013; 98(5): p. E962-E972.
9. Masood S Auguste LJ, Westerband A, Belluco C, Valderama E, Attie J, et al., Differential oncogenic expression in thyroid follicular and Hürthle cell carcinomas. The American journal of surgery, 1993; **166**(4): p. 366-368.
10. Ahmadi S, Stang M, Xiaoyin SJ Sosa JA. Hurthle cell carcinoma: current perspectives. OncoTargets and Therapy, 2016; 9: p. 6873-6884.
11. Tepeoğlu M, Bilezikci B, Bayraktar S. A histological assessment of the Bethesda system for reporting thyroid cytopathology (2010) abnormal categories: a series of 219 consecutive cases. Cytopathology, 2014; 25(1): p. 39-44
12. Hegedüs L. The thyroid nodule. N Engl J Med. 2004; 351(17): p. 1764-1771.
13. Lin, J-D. Thyroid cancer in thyroid nodules diagnosed using ultrasonography and fine needle aspiration cytology. J Med Ultrasound. 2010; 18(3): p. 91-104.

14. Cooper DS, Doherty GM, Haugen BR, Kloos RT, Lee SL, Mandel SJ et al. revised American thyroid association management guidelines for patients with thyroid nodules and differentiated thyroid cancer: the American Thyroid Association (ATA) guidelines taskforce on thyroid nodules and differentiated thyroid cancer. Thyroid, 2009; 19(11): p. 1167-1214.
15. Haugen BR, Alexander EK, Bible KC, Doherty GM, Mandel SJ, Nikiforov YE et al. 2015 American thyroid association management guidelines for adult patients with thyroid nodules and differentiated thyroid cancer: the American thyroid association (ATA) guidelines task force on thyroid nodules and differentiated thyroid cancer. Thyroid, 2015; 26(1): p.1-133.
16. Lienart F. Thyroid nodule: benign or malignant? Rev Med Brux. 2012; 33(4): p. 254-262.
17. Macias A, Arumagum D, Arlow RL, Eng OS, Lu S-E, Javidian P et al. A risk model to determine surgical treatment in patients with thyroid nodules with indeterminate cytology. Ann Surg Oncol. 2015; 22(5): p. 1527-1532.
18. Yeung MJ, Serpell JW. Management of the solitary thyroid nodule. The Oncologist, 2008. 13(2): p. 105-112.
19. Castro MR., Espiritu RP, Bahn RS, Henry MR, Gharib H, Caraballo PJ, et al. Predictors of malignancy in patients with cytologically suspicious thyroid nodules. Thyroid, 2011; 21(11): p. 1191-1198.
20. Cibas ES, Ali SZ. The Bethesda system for reporting thyroid cytopathology. Am J Clin Pathol. 2009; 132(5): p. 658-665.
21. Pacini F, Castagna MG, Brilli L. Pentheroudakis G. Differentiated thyroid cancer: ESMO clinical recommendations for diagnosis, treatment and follow-up. Ann Oncol. 2009; 20(suppl 4): p. iv143-iv146.
22. Li FP, Fraumeni, JF, Mulvihill, JJ, Blattner WA, Dreyfus, MG, Tucker MA et al. A cancer family syndrome in twenty-four kindreds. Cancer Res. 1988; 48(18): p. 5358-5362.
23. Mackenzie EJ, Mortimer RH. Thyroid nodules and thyroid cancer. Med J Aust. 2004; 180(5): p. 242-249.
24. Nikiforov YE, Seethala RR, Tallini G, Baloch ZW, Basolo F, Thompson LD, et al. Nomenclature revision for encapsulated follicular variant of papillary thyroid

carcinoma: A paradigm shift to reduce overtreatment of indolent tumors. JAMA Oncol. 2016; 2(8): p. 1023-1029.

25. Chen H, Nicol TL, Udelsman R. Clinically significant, isolated metastatic disease to the thyroid gland. World J Surg. 1999; 23(2): p. 177-181.
26. Montone KT, Baloch ZW, LiVolsi VA. The thyroid Hürthle (oncocytic) cell and its associated pathologic conditions: a surgical pathology and cytopathology review. Arch Pathol Lab Med. 2008; 132(8): p. 1241-1250.
27. Giorgadze T, Rossi ED, Fadda, G, Gupta, PK, LiVolsi, VA, Baloch ZW. Does the fine-needle aspiration diagnosis of ted meta-cell neoplasm/follicular neoplasm with oncocytic feature the thyroid gland? World Journal of Diagnostic Cytopathology, 2004. 31(5): p. 307-312.
28. Nikiforov YE Fagin JA. Risk factors for thyroid cancer. Trends in Endocrinology & Metabolism, 1997. 8(1): p. 20-25.
29. Schneider AB, Sarne DH. Long-term risks for thyroid cancer and other neoplasms after exposure to radiation. Nat Clin Pract End Met, 2005. 1(2): p. 82-91.
30. Kalk W. Sitas F, Patterson A. Thyroid cancer in South Africa--an indicator of regional iodine deficiency. South African medical journal= Suid-Afrikaanse tydskrif vir geneeskunde, 1997. 87(6): p. 735-738.
31. Mulaudzi TV, Ramdial PK, Madiba TE, Callaghan RA. Thyroid carcinoma at King Edward VIII Hospital, Durban, South Africa. East African medical journal, 2001. 78(5): p. 242-245.
32. Rumstadt B, Klein B, Kirr H, Kaltenbach N, Homenu W, Schiling D. Thyroid surgery in Burkina Faso, West Africa: experience from a surgical help program. World J Surg. 2008; 32(12): p. 2627-2630.
33. Bombil I, Bentley A, Kruger D, Luvhengo TE. Incidental cancer in multinodular goitre post thyroidectomy. South African Journal of Surgery, 2014. 52(1): p. 5-9.
34. Zimmermann MB, Jooste PL, Pandav CS. Iodine-deficiency disorders. The Lancet, 2008. 372(9645): p. 1251-1262.
35. Wreesmann VB, Ghossein RA, Hezel M. Follicular variant of papillary thyroid carcinoma: genome-wide appraisal of a controversial entity. Genes Chromosomes Cancer, 2004. 40: p. 355-364.
36. Beckner ME, Heffess CS, Oertel JE. Oxyphilic Papillary Thyroid Carcinomas. Am J Clin Pathol. 1995; 103(3): 280-287.

37. Sobrinho-Simoes M, Eloy C, Magalhaes J, Lobo C, Amaro T. Follicular thyroid carcinoma. Mod Pathol, 2011. 24(S2): p. S10-S18.
38. Hannallah J, Rose J, Guerrero MA. Comprehensive literature review: recent advances in diagnosing and managing patients with poorly differentiated thyroid carcinoma. International journal of endocrinology, 2013; 2013: p. 1-7
39. Lote K, Andersen K, Nordal E, Brennhovd I. Familial occurrence of papillary thyroid carcinoma. Cancer, 1980; 46(5): p. 1291-1297.
40. Paik S-S, Kim W-S, Hong E-K, Park M-H, Lee J-D. Poorly differentiated (" insular") carcinoma of the thyroid gland. J Korean Med Sci. 1997 Feb; 12(1): 70-74
41. Paunovic I, Krgovic K, Tatic, S, Diklic A, Zivaljevic V, Kalezic N, et al. Surgery for thyroid Hurthle cell tumours—a single institution experience. European Journal of Surgical Oncology (EJSO), 2006. 32(4): p. 458-461.
42. Chen H, Nicol, TL, Zeiger MA, Dooley, WC, Ladenson, PW, Cooper DS, et al. Hurthle cell neoplasms of the thyroid: are there factors predictive of malignancy? Ann Surg. 1998; 227(4): p. 542.
43. Pisanu A, Di Chiara B, Reccia, I, Uccheddu A, et al. Oncocytic cell tumors of the thyroid: factors predicting malignancy and influencing prognosis, treatment decisions, and outcomes. World J Surg. 2010; 34(4): p. 836-843.
44. Parikh PP, Allan BJ Lew JI. Surgeon-performed ultrasound predictors of malignancy in patients with Hürthle cell neoplasms of the thyroid. J Surg Res. 2013; 184(1): p. 247-252.
45. Lee KH, Shin JH, Ko ES, Hahn SY, Kim JS, Kim J-H, et al. Predictive factors of malignancy in patients with cytologically suspicious for Hurthle cell neoplasm of thyroid nodules. Int J Surg. 2013; 11(9): p. 898-902.
46. Kim TH, Lim JA, Ahn HY, Lee EK, Min HS, Won Kim K, et al. Tumor size and age predict the risk of malignancy in Hürthle cell neoplasm of the thyroid and can therefore guide the extent of initial thyroid surgery. Thyroid, 2010; 20(11): p. 1229-1234.
47. Gharib H, Goellner JF. Fine-needle aspiration biopsy of the thyroid: An appraisal. Ann Intern Med. 1993; 118(4): p. 282-289.
48. Guerrero, M.A., Suh I, Vriens MR, Shen WT, Gosnell J, Kebebew E, et al. Age and tumor size predicts lymph node involvement in Hürthle Cell Carcinoma. J Cancer 2010; 1: p. 23-26

49. Haigh PI, Urbach DR. The treatment and prognosis of Hürthle cell follicular thyroid carcinoma compared with its non-Hürthle cell counterpart. Surgery, 2005; 138(6): p. 1152-1158.
50. Besic N, Hoceva, M, Zgajnar J, Petric R, Pilko G. Aggressiveness of therapy and prognosis of patients with Hürthle cell papillary thyroid carcinoma. Thyroid, 2006; 16(1): p. 67-72.
51. Herrera MF, Hay, ID, Wu P, Goellner JR, Ryan JJ, Ebersold JR, et al. Hürthle cell (oxyphilic) papillary thyroid carcinoma: a variant with more aggressive biologic behavior. World J Surg. 1992; 16(4): p. 669-674.
52. Sanders LE, Silverman M. Follicular and Hürthle cell carcinoma: Predicting outcome and directing therapy. Surgery. 1998; 124(6): p. 967-974.
53. Sobrinho-Simoes M, Maximo V, Vieira de Castro I. Hurthle (oncocytic) cell tumors of thyroid: etiopathogenesis, diagnosis and clinical significance. Int J Surg Pathol, 2005. 13: p. 29-35.
54. Asa S. My approach to oncocytic tumours of the thyroid. J Clin Pathol. 2004; 57(3): p. 225-232.
55. Gharib H, Papini E. Thyroid nodules: clinical importance, assessment, and treatment. Endocrinol Metab Clin N Am. 2007; 36(3): p. 707-735.
56. Jaheen H, Sakr M. Predictors of Malignancy in Patients with Solitary and Multiple Thyroid Nodules. J Surgery, 2016; 12(3): 105-110
57. Lopez-Penabad L, Chiu AC, Hoff AO, Schultz P, Gaztambide S, Ordonez NG, et al. Prognostic factors in patients with Hürthle cell neoplasms of the thyroid. Cancer, 2003; 97(5): p. 1186-1194.
58. Melck A, Bugis S, Baliski C, Irvine R, Anderson DW, Wilkins G, et al. Hemithyroidectomy: the preferred initial surgical approach for management of Hurthle cell neoplasm. The American Journal of Surgery, 2006; 191(5): p. 593-597.
59. Ikejiri K, Furuyama M, Muranaka T, Anai H, Takeo S, Sakai, K, et al. Carcinoma of the thyroid manifested as hyperthyroidism caused by functional bone metastasis. Clin Nucl Med. 1997; 22(4): p. 227-230.
60. Boelaert K, Horacek J, Holder RL, Watkinson JC, Sheppard MC, Franklyn JA, et al. Serum thyrotropin concentration as a novel predictor of malignancy in thyroid nodules investigated by fine-needle aspiration. J Clin Endocrinol Metab. 2006; 91(11): p. 4295-4301.

61. Boelaert K. The association between serum TSH concentration and thyroid cancer. Endocrine-related cancer, 2009; 16(4): p. 1065-1072.
62. Petric R, Perhavec A, Gazic B, Besic N. Preoperative serum thyroglobulin concentration is an independent predictive factor of malignancy in follicular neoplasms of the thyroid gland. J Surg Oncol. 2012; 105(4): p. 351-356.
63. Besic H Besic N. Preoperative serum thyroglobulin concentration as a predictive factor of malignancy in small follicular and Hürthle cell neoplasms of the thyroid gland. World J Surg Oncol. 2014; 12(1): p. 1.
64. Hocevar, M Auersperg M. Role of serum thyroglobulin in the pre-operative evaluation of follicular thyroid tumours. Eur J Surg Oncol (EJSO. 1998; 24(6): p. 553-557.
65. Corrias A, Mussa A. Thyroid nodules in pediatrics: which ones can be left alone, which ones must be investigated, when and how. J Clin Res Ped Endocrinol. 2013; 5(Suppl 1): p. 57-69.
66. Ahn JE, Lee JH, Yi JS, Shong YK, Hong SJ, Lee DH, et al. Diagnostic accuracy of CT and ultrasonography for evaluating metastatic cervical lymph nodes in patients with thyroid cancer. World J Surg. 2008; 32(7): p. 1552-1558.
67. Pu RT, Yang J, Wasserman PG, Bhuiya T, Griffith KA, Michael CW. Does Hurthle cell lesion/neoplasm predict malignancy more than follicular lesion/neoplasm on thyroid fine-needle aspiration? Diagn Cytopathol. 2006; 34(5): p. 330-334.
68. Stojadinovic A, Ghossein RA, Hoos A, Urist MJ, Spiro RH, Shah JP, et al. Hürthle cell carcinoma: a critical histopathologic appraisal. J Clin Oncol. 2001; 19(10): p. 2616-2625.
69. Woodruff SL, Arowolo OA, Akute OO, Afolabi, AO, Nwariaku F. Global variation in the pattern of differentiated thyroid cancer. The American Journal of Surgery, 2010. 200(4): p. 462-466.
70. Horvath E, Sergio M, Ricardo R, Carmen F, Juan PN, Alex C, t al. An Ultrasonogram Reporting System for Thyroid Nodules Stratifying Cancer Risk for Clinical Management. J Clin Endocrinol Metab. 2009; 94(5): p. 1748-1751.
71. Kwak JY, Han KH, Yoon, JH, Moon HJ, Son EJ, Park SH, et al. Thyroid imaging reporting and data system for US features of nodules: a step in establishing better stratification of cancer risk. Radiology. 2011; 260(3): p. 892-899.

72. Sánchez JF. TI-RADS classification of thyroid nodules based on a score modified according to ultrasound criteria for malignancy. Rev Argent Radiol. 2014; 78(3): p. 138-148.
73. Vidal-Casariego A, López-González L, Jiménez-Pérez A, Ballesteros-Pomar MD, Kyriakos GUrioste-Fondo, A, et al. Accuracy of ultrasound elastography in the diagnosis of thyroid cancer in a low-risk population. Experimental and Clinical Endocrinology & Diabetes. 2012. 120(10): p. 635-638.
74. De Napoli L, Bakkar S, Ambrosini CE, Materazzi G, Proietti A, Macerola, E, et al. Indeterminate Single Thyroid Nodule: Synergistic Impact of Mutational Markers and Sonographic Features in Triaging Patients to Appropriate Surgery. Thyroid, 2016. 26(3): p. 390-394.
75. Yassa L, Cibas, Edmund S, Benson C B, Frates MC, Doubilet PM, Gawande AA, et al. Long-term assessment of a multidisciplinary approach to thyroid nodule diagnostic evaluation. Cancer. 2007; 111(6): p. 508-516.
76. Rosen IB, Wallace Ch, Strawbridge HG, Walfish PG. Reevaluation of needle aspiration cytology in detection of thyroid cancer. Surgery. 1981. 90(4): p. 747-756.
77. Baloch ZW, LiVolsi, VA, Asa SL, Rosai J, Merino MJ, Randolph G, et al. Diagnostic terminology and morphologic criteria for cytologic diagnosis of thyroid lesions: a synopsis of the National Cancer Institute Thyroid Fine-Needle Aspiration State of the Science Conference. Diagn Cytopathol. 2008; 36(6): p. 425-437.
78. Yang J, Schnadig V, Logrono R, Wasserman PG, et al. Fine-needle aspiration of thyroid nodules: A study of 4703 patients with histologic and clinical correlations. Cancer; 111(5): p. 306-315.
79. Rani C, Lal P, Mahmood T. Comparative study for the evaluation of solitary thyroid nodule: ultrasonography versus fine needle aspiration cytology. Pak J Surg. 2014; 30(1): p. 14-17.
80. Wu H, Clouse J, Ren R. Fine-needle aspiration cytology of Hürthle cell carcinoma of the thyroid. Diagn Cytopathol. 2008; 36(3): p. 149-154.
81. Sakorafas G.H. Thyroid nodules; interpretation and importance of fine-needle aspiration (FNA) for the clinician–Practical considerations. Surgl oncol. 2010. 19(4): p. e130-e139.

82. Sorrenti S, Trimboli P, Catania A, Uliss, S, De Antoni E, D'Armiento M. Comparison of malignancy rate in thyroid nodules with cytology of indeterminate follicular or indeterminate Hürthle cell neoplasm. Thyroid. 2009; 19(4): p. 355-360.
83. Layfield LJ, Morton MJ, Cramer HM, Hirschowitz S. Implications of the proposed thyroid fine-needle aspiration category of thyroid finegy in detection of thyroid cancer. Surgery,-year multi-institutional analysis. Diagn Cytopathol. 2009; 37(10): p. 710-714.
84. Mijović T, Rochon L, Gologan O, Hier MP, Black, MJ, Young J. et al. Fine-needle aspiration biopsies in the management of indeterminate follicular and Hurthle cell thyroid lesions. Otolaryngology--Head and Neck Surgery. 2009; 140(5): p. 715-719.
85. Alexander EK, Kennedy GC, Baloch, ZW, Cibas ES, Chudova D, Diggans J, et al. Preoperative Diagnosis of Benign Thyroid Nodules with Indeterminate Cytology. N Engl J Med. 2012; 367(8): p. 705-715.
86. Nikiforov YE, Ohori NP, Hodak SP, Carty SE, LeBeau SO, Ferris RL, et al. Impact of Mutational Testing on the Diagnosis and Management of Patients with Cytologically Indeterminate Thyroid Nodules: A Prospective Analysis of 1056 FNA Samples. J Clin Endocrinol Metab. 2011; 96(11): p. 3390-3397.
87. Dahl LD, Myssiorek D, Heller KS. Hurthle Cell Neoplasms of the Thyroid. The Laryngoscope. 2002; 112(12): p. 2178-2180.
88. Sangalli G Serio G, Zampatti C, Bellotti M, Lomuscio G. Fine needle aspiration cytology of the thyroid: a comparison of 5469 cytological and final histological diagnoses. Cytopathology. 2006; 17(5): p. 245-250.
89. Stang MT Carty SE. Recent developments in predicting thyroid malignancy. Curr Opin Oncol. 2009; 21(1): p. 11-17.
90. McHenry CR, Thomas SR, Slusarczyk SJ, Khiyami A. Follicular or Hu¨rthle cell neoplasm of the thyroid: Can clinical factors be used to predict carcinoma and determine extent of thyroidectomy? Surgery. 1999; 126(4): p. 798-804.
91. Tuttle R, Ball DW, Byrd D, Dickson P, Duh QY, Farrar WB. NCCN Clinical Practice Guidelines in Oncology-Thyroid Carcinoma-Version 2. 2013. NCCN Guidelines. 2013.
92. Tuttle RM, Tala H, Shah J, Leboeuf R, Ghossein R, Gonen M, et al. Estimating risk of recurrence in differentiated thyroid cancer after total thyroidectomy and radioactive iodine remnant ablation: using response to therapy variables to modify the initial risk estimates predicted by the new American Thyroid Association staging system. Thyroid. 2010. 20(12): p. 1341-1349.

93. Lundgren CI, Hall P, Dickman PW, Zedenius J. Clinically significant prognostic factors for differentiated thyroid carcinoma. Cancer. 2006. 106(3): p. 524-531.
94. Handkiewicz-Junak D, Wloch J, Roskosz J, Krajewska J, Kropinska A, Pomorski L, et al. Total Thyroidectomy and Adjuvant Radioiodine Treatment Independently Decrease Locoregional Recurrence Risk in Childhood and Adolescent Differentiated Thyroid Cancer. J Nucl Med. 2007. 48(6): p. 879-888.
95. Ford D, Giridharan S, McConkey C, Hartley A, Brammer C, Watkinson JC, et al. External beam radiotherapy in the management of differentiated thyroid cancer. Clin Oncol (R Coll Radiol). 2003; 15(6): p. 337-341.
96. Biondi B Cooper DS. Benefits of thyrotropin suppression versus the risks of adverse effects in differentiated thyroid cancer. Thyroid. 2010. 20(2): p. 135-146.
97. Ross DS. Hyperthyroidism, thyroid hormone therapy, and bone. Thyroid. 1994. 4(3): p. 319-326.
98. Mazzaferri EL, Robbins RJ, Spencer CA, Braverman LE, Pacini F, Wartofsky L, et al. A Consensus Report of the Role of Serum Thyroglobulin as a Monitoring Method for Low-Risk Patients with Papillary Thyroid Carcinoma. J Clin Endocrinol Metab. 2003. 88(4): p. 1433-1441.
99. Zhang H, Zeng L, Liang C, Qiu H, Zhang M, Zhu Y, et al. Successful Treatment of Hurthle Cell Thyroid Carcinoma with Lung and Liver Metastasis Using Docetaxel and Cisplatin. Jpn J Clin Oncol. 2012 Nov; 42(11): p. 1086-1090.
100. Tabain I, Matesa N, Kusic Z. Fine Needle Aspiration of Hurthle Cell Neoplasms of the Thyroid: A Clinicocytomorphologic Study. Acta Clin Croat. 2002; 41(4): p. 335-340.
101. Alaedeen D, Khiyami A McHenry CR. Fine-needle aspiration biopsy specimen with a predominance of Hürthle cells: a dilemma in the management of nodular thyroid disease. Surgery, 2005. 138(4): p. 650-657.
102. Kushchayeva Y, Duh Q-Y, Kebebew E, D'Avanzo A, Clark OHl. Comparison of clinical characteristics at diagnosis and during follow-up in 118 patients with Hurthle cell or follicular thyroid cancer. The American Journal of Surgery, 2008. 195(4): p. 457-462.
103. Rago T Vitti P. Role of thyroid ultrasound in the diagnostic evaluation of thyroid nodules. Best Pract Res Clin Endocrinol Metab. 2008; 22(6): p. 913-928.

104. Russ G, Leboulleux S, Leenhardt L, Hegedüs L. Thyroid incidentalomas: epidemiology, risk stratification with ultrasound and workup. Eur Thyroid J. 2014 Sep; 3(3): p. 154-163.
105. Woliński K, Szkudlarek M, Szczepanek-Parulska E, Ruchała M. Usefulness of different ultrasound features of malignancy in predicting the type of thyroid lesions: a meta-analysis of prospective studies. Pol Arch Med Wewn. 2014; 124(3): p. 97-104.
106. Giuliani M, Brierley J. Indications for the use of external beam radiation in thyroid cancer. Curr Opin Oncol. 2014 Jan. 26(1): p. 45-50.
107. Sippel RS, Elaraj DM, Khanafshar E, Zarnegar R, Kebebew E, Duh Q-Y, et al. Tumor size predicts malignant potential in Hürthle cell neoplasms of the thyroid. World J Surg, 2008. 32(5): p. 702-707.
108. Ho AS, Sarti EE, Jain KS, Wang H, Nixon IJ, Shaha AR, etal. Malignancy rate in thyroid nodules classified as Bethesda category III (AUS/FLUS). Thyroid, 2014. 24(5): p. 832-839.
109. Cheung CC, Ezzat S, Ramyar L, Freeman JL, Asa SL. Molecular Basis of Hurthle Cell Papillary Thyroid Carcinoma 1. The Journal of Clinical Endocrinology & Metabolism, 2000. 85(2): p. 878-882.
110. Terris DJ, Duke W. Thyroid and Parathyroid Diseases. Medical and Surgical Management. New York: Thieme, (2016).

APPENDICES

Appendix 1

Data Sheet:

Prevalence, demographic and histological sub-types of Hurthle cell tumours of the thyroid: a histopathological audit.

Demographic Data's:

1. Age: -------- Gender: Male/Female: ----
2. Others: ---------

FNAC result

a) Adequacy:
b) Bethesda Category:
c) FNAC diagnosis:

Histology result

a) Type of specimen:
b) Size:
c) Diagnosis:
d) Other diagnosis:
e) Lymph node involvement: Y/N

Surgical Intervention:

1. Thyroid Lobectomy: ----------
2. Total Thyroidectomy: ---------

Appendix 2a

Human Research Ethics Committee (Medical)

Research Office Secretariat: Senate House Room SH 10004, 10th floor. Tel +27 (0)11-717-1252
Medical School Secretariat: Phillip Tobias Building, 2nd Floor Tel +27 (0)11-717-2700
Private Bag 3, Wits 2050, www.wits.ac.za. Fax +27 (0)11-717-1265

05 October 2015

To Whom It May Concern

SUBJECT: **CONFIRMATION OF STUDY APPROVAL**

Protocol Ref No: M150944

Protocol Title: Prevalence, demographic and histological sub- types of Hurthle cell tumours of the thyroid: a histopathological audit

Principal Investigator: Dr V Malith

Department: Surgery

This letter serves to confirm that the Human Research Ethics Committee (Medical) has approved the above mentioned study. In order for a clearance certificate to be issued, the researcher is required to submit written approval to conduct the study in your district/institution.

The researcher has been informed that this study cannot commence without your approval and receipt of the Clearance certificate from the HREC (Medical).

Should you have any queries, you may contact me at tel 011 717 1252/1234/2700 or by email Zanele.ndlovu@wits.ac.za.

Yours Faithfully,

UNIVERSITY OF THE WITWATERSRAND
OFFICE OF THE DEPUTY VICE CHANCELLOR RESEARCH
05 OCT 2015
RESEARCH OFFICE HREC (Medical)
JOHANNESBURG

Ms Zanele Ndlovu
Administrative Officer
Human Research Ethics Committee (Medical)

Appendix 2b

R14/49 Dr Victor Malith

HUMAN RESEARCH ETHICS COMMITTEE (MEDICAL)

CLEARANCE CERTIFICATE NO. M150944

NAME: (Principal Investigator)	Dr Victor Malith
DEPARTMENT:	Surgery Chris Hani Baragwanath Academic Hospital, Charlotte Maxeke Johannesburg Academic Hospital and Helen Joseph Hospital
PROJECT TITLE:	Prevalence, Demographic Histological Sub-types of Hurthle Cell Tumours of the Thyroid : a Histopathological Audit
DATE CONSIDERED:	02/10/2015
DECISION:	Approved unconditionally
CONDITIONS:	
SUPERVISOR:	Prof Thifhelimbilu Luvhengo
APPROVED BY:	Professor P Cleaton-Jones, Chairperson, HREC (Medical)
DATE OF APPROVAL:	06/11/2015

This clearance certificate is valid for 5 years from date of approval. Extension may be applied for.

DECLARATION OF INVESTIGATORS

To be completed in duplicate and **ONE COPY** returned to the Secretary in Room 10004, 10th floor, Senate House, University.
I/we fully understand the conditions under which I am/we are authorized to carry out the above-mentioned research and I/we undertake to ensure compliance with these conditions. Should any departure be contemplated, from the research protocol as approved, I/we undertake to resubmit the application to the Committee. **I agree to submit a yearly progress report**.

Principal Investigator Signature Date

PLEASE QUOTE THE PROTOCOL NUMBER IN ALL ENQUIRIES

Appendix 3

NATIONAL HEALTH LABORATORY SERVICE
UNIVERSITY OF THE WITWATERSRAND – JOHANNESBURG

SCHOOL OF PATHOLOGY
Division of Anatomical Pathology

NATIONAL HEALTH LABORATORY SERVICE

P.O. Box 1038, Johannesburg 2000
Tel : +27-11-489-8477
+27-11- 489-8479
Fax::+27-11-489-8512

Division of Anatomical Pathology
Faculty of Health Sciences
York Road
Parktown e-mail : martin.hale@nhls.ac.za

Professor MJ Hale MBChB (Rhodesia) FCPath (SA). LRCP, LRCS, LRCP&S (Edinburgh & Glasgow)
Professor & Head: Division of Anatomical Pathology,

Human Research Ethics Committee (Medical)
University of the Witwatersrand
Johannesburg
20000

July 8, 2015

Re: Consent for access to NHLS database

This letter serves to confirm that the Department of Anatomical Pathology at the University of the Witwatersrand and NHLS is happy to assist Dr Victor Malith with his study entitled "A retrospective study of prevalence, demographic and histological types of Hurthle Cell tumours of the thyroid in the provincial hospitals in Gautend as identified in the data base of NHLS from 2000 to 2015".

Notwithstanding the requirement that research projects should comprise the researchers work only, it is recognized that publication of such work is encouraged. In the event that the information used comprises the diagnosis only then joint authorship from a member of staff in the Department of Anatomical Pathology would not be expected. However should additional information be extracted from the report for purposes of further interpretation such as morphological details and immunohistochemical profiles, it would be expected that this would be done in conjunction with a member of staff in the Department of Anatomical Pathology and that joint authorship would follow in resulting publications. Dr Malith will be in contact with the Department of Anatomical Pathology in respect of this.

Assuring you of the Department of Anatomical Pathology's co-operation in this and future research projects.

With best wishes.

Yours sincerely,

Professor MJ Hale
Head: Department of Anatomical Pathology

08/07/2015
Date