

https://dspace.org/

Secretory epithelium in the lining of dental cysts

Shear, M.

1960
http://hdl.handle.net/10539/20179
Shear, M. 1960. Secretory epithelium in the lining of dental cysts. Journal of the dental association of South Africa;15(4):117-122

Downloaded from a DSpace repository. https://dspace.org/

SECRETORY EPITHELIUM IN THE LINING OF DENTAL CYSTS

M. SHEAR, B.D.S., H.DIP.DENT. (RAND)

Department of Dentistry, University of the Witwatersrand

THE great majority of dental cysts are lined by stratified squamous epithelium. This is to be expected, as these cysts develop by a proliferation of the epithelial debris of Malassez which has its origin in the basal layer of the epithelium of the stomadeum.

Occasionally, however, dental cysts are found to be lined partially or completely by a secretory type of epithelium. Hopewell Smith (1903) quotes Turner and Baker regarding the occurrence of ciliated columnar epithelium in dental cysts. Turner considered that it might be a "reversion to type or a freak of growth," while Baker based his argument on the mode of regeneration of denuded ciliated epithelium. Kronfeld (1939) described a dental cyst partly lined by ciliated columnar epithelium but demonstrated a direct communication between the cyst and the maxillary antrum. Stafne and Millhon (1945) examined 88 periodontal cysts, one of which was lined with ciliated columnar epithelium. This case was one of two that had been reported by Lovestedt (1944). He was of the opinion that although there were no obvious communications with the antrum, the presence of ciliated epithelium did suggest that early communication with the antrum must have been present.

Linell (1948) found four cases with goblet cells within the stratified squamous epithelium in a series of 70 dental cysts. Hodson (1956) found mucous cells in 20 cases (22 per cent) within the epithelial linings of a series of 89 odontogenic cysts. Twelve out of 53 (22 per cent) were found in the maxilla and eight out of 36 (22 per cent) in the mandible. Because of the similar incidences in mandible and maxilla, Hodson concluded that proximity to antrum or nose did not explain their presence. He considered that they "arise by metaplasia of squamous, and possibly intermediate cells." Willis (1958), commenting on Hodson's report, illustrates a similar occurrence in a dental cyst attached to the root of a maxillary canine tooth from a man aged 56.

Gorlin (1957) in a review of 200 mandibular cysts, found goblet cells in 11 cases. One of these, from the second molar region, was lined by typical pseudostratified ciliated columnar epithelium. Of his 11 cases, eight were in the second or the third molar region, two in the first molar region and one in the midline. Gorlin explains the presence of this secretory epithelium on the "pluripotential nature of oral epithelium."

MATERIALS AND METHODS

The cases reported in this communication are from a series of 200 consecutive dental cysts taken from the files of the Oral Pathology Department, Institute of Dental Surgery, London. The specimens had all been fixed in formol-saline and were paraffin-imbedded. All the sections were stained with haematoxylin and eosin and a few by the periodic acid Schiff method.

RESULTS

Ciliated epithelium was present in 20 cases (10 per cent). In 19 of these, stratified squamous epithelium was also present and in one the entire epithelial lining was ciliated (Table 1). Fourteen of these cases were from the maxilla, four from the mandible and in two instances the positions were not mentioned in the clinical notes. Nine of the 13 maxillary cases involved the anterior region, two the posterior and three the intermediate region. Of the

four mandibular cases, one was in the anterior region and three in the third molar region (Table 2).

TABLE 1.—Incidence of ciliated epithelium in dental cyst linings

Type of Epithelium	*No.*	%
Stratified Squamous	198	99
Ciliated	20	10
Stratified Squamous only . .	179	89·5
Ciliated only	1	0·5
Stratified Squamous and Ciliated mixed	19	9·5
No Epithelial Lining	1	0·5
Total	200	100

TABLE 2.—Distribution of 20 dental cysts lined by ciliated epithelium

Position	*Maxilla*	*Mandible*
Anterior region	9	1
Intermediate region	3	0
Posterior region	2	3
	14	4
Not known	2	
Total	20	

Goblet cells were found in 36 (18 per cent) cases. Twenty-four of these were in the maxilla (21·4 per cent of a total of 112 maxillary cysts); nine in the mandible (12·3 per cent of a total of 73 mandibular cysts); and in three cases the position of the cyst was not indicated in the clinical notes. In 17 cases the goblet cells were associated with ciliated epithelium and in 19 with stratified squamous epithelium.

Twelve of the 19 cases with goblet cells found within the stratified squamous epithelial linings were in the maxilla (63 per cent); and six were found in the mandible (32 per cent). In one instance the position was not recorded. Of the 17 cases associated with ciliated epithelium, 12 were in the maxilla (70 per cent), three in the mandible (17·6 per cent), and the positions of two were not recorded (12·4 per cent) (Table 3).

Of the 24 cysts in the maxilla containing goblet cells, 12 (50 per cent) were from the anterior region, seven (29 per cent) from the intermediate region and two (8 per cent) from the posterior region. The positions of three were not known. Of the nine cases in the mandible, one involved the anterior region, three the intermediate and three the posterior region. The positions of two were not known (Table 4).

DISCUSSION

The single cyst lined solely by ciliated epithelium was removed from 21|12 re-

Table 3.—Distribution of goblet cells

Position	*Within Stratified Squamous Epithelium*		*Within Ciliated Epithelium*		*Total*	
	No.	%	*No.*	%	*No.*	*% of all Cases*
Maxilla	12	63	12	70	24	21·4
Mandible	6	32	3	18	9	12·3
Not known	1	5	2	12	3	—
Total	19	100	17	100	36	—

TABLE 4.—Distribution of 33 dental cysts containing goblet cells

Position	*Maxilla*	*Mandible*
Anterior region	12	1
Intermediate region	7	3
Posterior region	2	3
Not known	3	2
Total	24	9
	33	

gion. The epithelium was regular and two cell layers thick. There was no inflammatory cell infiltration in the epithelium but a moderate lymphocytic infiltration was present in the cyst wall. Although this cyst had no mucous glands within its wall and the clinical diagnosis was "dental cyst," it is highly probable that this is in fact an incisive canal cyst.

Further analysis of the remaining 13 maxillary cysts partially lined by ciliated epithelium, reveals some significant facts. In one case an oro-antral fistula was present; in another there was an associated nasal discharge (Fig. 1); in a third, part of the antral lining was removed with the cyst, and the two epithelia were lying "back to back" in the sections, separated only by a narrow band of woven bone.

These cases demonstrate the close proximity that may exist between a maxillary cyst and either the antrum or nasal passages. Once direct communication occurs, it is quite feasible that part of the cyst may become lined by respiratory epithelium. In fact, once such communication is established, provided that the opening remains patent, the cyst can no longer increase in size and will behave like an accessory antrum.

Three more cases from the anterior region (2|, 32|, and the premaxilla) may also be nasopalatine cysts. However, they were diagnosed clinically as dental cysts and no mention was made in the clinical notes as to the presence of caries or vitality in the associated teeth.

In two cases the ciliated epithelium lies on the surface of the stratified squamous epithelium, giving the appearance of grafting. If this is indeed the case, one would certainly expect that there has been some communication between the epithelial lining of the cyst and respiratory epithelium.

Two of the cysts were removed from |7 and 876| regions in the same patient. Both had ciliated epithelium present. One of the cysts was in close proximity to the antrum radiologically but there was no clinical connection. In another case from 6| region, although no connection with the maxillary antrum was noted, most of the epithelium was of the ciliated columnar variety. In the absence of any communication, one must consider the possibility of metaplasia from stratified squamous to ciliated epithelium.

The presence of ciliated epithelium



FIG. 1.—Cyst removed from the maxilla of a 67-year-old man. There was an associated nasal discharge. Cilia are present on the surface of the epithelium.
H. and E. x 500

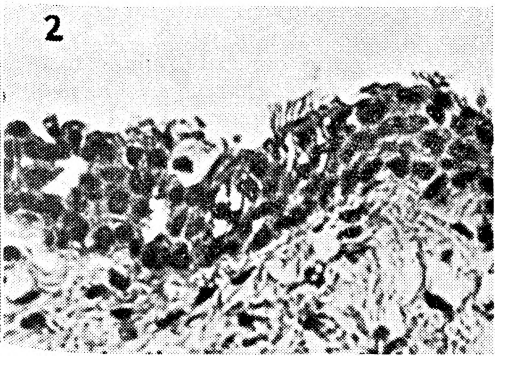

FIG. 2.—Cyst removed from the mandibular third molar region of a 25-year-old man. Cilia are present on the surface of the stratified squamous epithelium.
H. and E. x 500

within the mandibular cysts is an extraordinary finding. The cases reported by Gorlin (1957) have already been mentioned. In this series, ciliated epithelium was present in four cysts of the mandible. Two of these were in the third molar region, one extended throughout the body of the mandible and one between $\overline{4}$-8 (Fig. 2). In these positions neither grafting nor direct communication can possibly be the reason for the existence of ciliated epithelium lining a cyst wall. Fell (1957) describes the metaplasia from stratified squamous to ciliated epithelium produced in the skin of chickens in tissue culture, under the influence of excess vitamin A.

Some of the features seen in the sections of this series are remarkably similar to those described by Fell. During the process of mucous metaplasia in Fell's explants, cells which had begun to cornify or would shortly do so, could not adapt themselves to the altered environment of excess vitamin A. "Prevented from forming keratin, they first produced a curious material which was neither normal keratin nor mucin but had some of the staining properties of both; then they degenerated and were sloughed. The least differentiated cells composing the deepest layers of the epidermis, when blocked from following their normal course of development, switched to an alternative path and differentiated into a secretory epithelium."

Fell also described how an orderly secretory layer forms on the surface but that there is often an irregular intermediate layer of cells, some of which are typical prickle cells and others beginning to acquire a secretory character. Occasionally a cell in the intermediate layers degenerated *in situ*, "and as it shrunk away from the surrounding tissue it left a small cavity in the substance of the epithelium." Both these features are commonly found in the epithelium of dental cysts containing goblet cells (Figs. 3, 4 and 5).

Fell's findings demonstrate that metaplasia to a more highly differentiated epithelium is a possible occurrence.

Willis (1958) states: "As far as I know, glandular metaplasia in non-neoplastic epidermis has not been observed; but it does occur in dental cysts, the epithelium of which is closely akin to epidermis." He then quotes Hodson's work and illustrates his own case.



FIG. 3.—Cyst removed from the $\overline{7}$ region of a 53-year-old woman. The photomicrograph shows degeneration and sloughing of the superficial cells of the stratified squamous epithelial lining. Some goblet cells are present in the most superficial layer. H. and E. x 650



FIG. 4.—From the same case as Fig. 3. The cells in the intermediate layer have degenerated leaving cavities in the substance of the epithelium.
H. and E. x 650

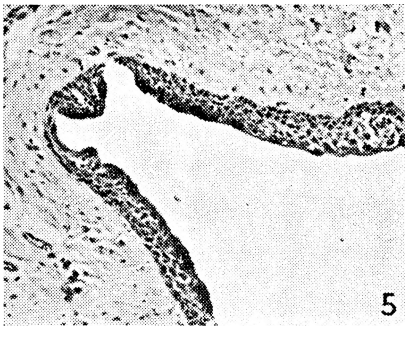

FIG. 5.—From the same case as Figs. 2 and 3. This photomicrograph shows an orderly secretory layer on the surface of the stratified squamous epithelium.
P.A.S. x 210

The second possible explanation for the presence of respiratory epithelium in cysts of the mandible may be made on embryological grounds. The endodermal part of the foregut is pluripotential in that the part that becomes floor of mouth, pharynx and most of the oesophagus is lined by stratified squamous epithelium, while that part that forms the respiratory tract is lined by pseudostratified ciliated columnar epithelium. In fact, during development in man, the upper end of the oesophagus is initially lined by a simple colunmar epithelium which is first transformed into a two-layered ciliated epithelium and eventually into a stratified squamous epithelium (Willis, 1958).

It seems, therefore, a reasonable theoretical possibility that part of such ciliated epithelium may be included during formation of the mandible. The work of Gillman (1940) is interesting in this regard. He found ciliated epithelium and mucous cells in 20 per cent of 80 Bantu pituitary glands. He considered that its presence had either resulted from embryonic cells which had differentiated into ciliated cells in Rathke's pharyngeal pouch, or was metaplastic in origin.

The third possibility is that a stable, well-organised stratified squamous epithelial lining, uninfluenced by inflammatory stimuli, may undergo metaplasia to a more highly differentiated type of ciliated columnar epithelium in response to the presence of fluid within the cyst cavity. In other words, it behaves like the epithelium of the maxillary antra, whose ciliary movements evacuate its contents. In support of this theory, three of the four mandibular cysts were free of any inflammatory cell infiltration in their epithelial linings. In the fourth case there was a minimal polymorphonuclear and lymphocytic infiltration. Of the 14 maxillary cases, six showed no inflammatory cell infiltration of their epithelial linings and six showed minimal changes. Of the remaining two with a more marked cellular infiltration, one had an associated oro-antral fistula. Ten of the 14 cases had a regular epithelium a few cell layers thick. Gorlin, too, comments on the well-organised nature of the epithelial linings in his cases.

The presence of goblet cells within ciliated epithelium is to be expected. Reasons for their presence within stratified squamous epithelium must, however, be sought. Twelve of the 19 cases found within stratified squamous epithelium were in the maxilla, and of these, six were in the anterior region. The maxillary cases may be accounted for in a similar manner to the maxillary cysts containing ciliated epithelium.

The same theories that were discussed to explain the presence of ciliated epithelium are applicable to the six mandibular cysts containing goblet cells within their epithelial linings.

CONCLUSIONS AND SUMMARY

A respiratory type of epithelium containing either cilia or goblet cells, or both, is occasionally found in apparent dental cysts in both maxilla and mandible. Thirty-nine specimens in this series of 200 dental cysts contained epithelium of this type.

As far as the maxillary cysts are concerned, the presence of respiratory epithelium may, in some instances, be ascribed to the fact that the cyst is derived from the epithelial remnants of the naso-palatine ducts and is not a dental cyst. In other cases the growth of the dental cyst may result in a perforation into the nose or maxillary antrum. Under such circumstances it is quite understandable that respiratory epithelium may be found lining part of the cyst. Thirdly, it would appear that in some true dental cysts, respiratory epithelium may form part of the lining when there is close proximity to the nose or antrum without actual communication. Such a finding is probably the result of metaplasia from stratified squamous to secretory epithelium. The reason for this metaplasia is not definitely known, but a number of suggestions have been discussed in the text.

The presence of a respiratory type of epithelium in cysts of the mandible may be explained either on the basis of metaplasia or on embryological grounds.

ACKNOWLEDGMENTS

This paper forms part of a study made while the writer was on the staff of the Pathology Department, Institute of Dental Surgery, London. I am grateful to Professor F. C. Wilkinson who was Director of the Institute at that time, for allowing

me the use of the material and the facilities for its study. I am also indebted to Mr. I. R. H. Kramer, Head of the Department of Pathology at the Institute, for his constant advice and encouragement during this and other studies of the histology of dental cysts.

I also wish to thank Mr. A. Smith of the Pathology Department, Institute of Dental Surgery, and Mrs. A. Vorster of the C.S.I.R. Dental Research Unit, University of the Witwatersrand, Johannesburg, for photographic assistance.

BIBLIOGRAPHY

FELL, H. (1957). "The effect of excess vitamin A on cultures of embryonic chicken skin explanted at different stages of differentiation." Proc. Roy. Soc., **146,** 242.

GILLMAN, T. (1940). "The incidence of ciliated epithelium and mucous cells in the normal Bantu pituitary." S. Afr. J. Med. Sci., **5,** 30.

GORLIN, R. J. (1957). "Potentialities of oral epithelium manifested by mandibular dentigerous cysts." Oral Surg., Oral Med., Ora Path., **10,** 271.

HODSON, J. J. (1956). "Muco-epidermoid odontogenic cysts of the jaws with special reference to those in the mandible."

HOPEWELL-SMITH (1903). The Histology and Patho-Histology of the Teeth. 1st ed., The Dental Manufacturing Co. Ltd., London, p. 525.

KRONFELD, R. (1939). Histopathology of the Teeth and their Surrounding Parts. 2nd ed. Lea and Febiger, Philadelphia, p. 203.

LINELL, F. (1948). "Mucus-secreting and cystic epidermoid carcinomas of the mucous - and salivary glands." Acta path. et microbiol. Scand., **25,** 801.

LOVESTEDT, S. A. (1944). "Cysts of the jaws lined with ciliated columnar epithelium." Am. J. Orthodontics, **30,** 16.

STAFNE, E. C. and MILLHON, J. A. (1945). "Periodontal Cysts." J. Oral Surg., **3,** 102.

WILLIS, R. (1958). The Borderland of Embryology and Pathology. 1st ed. Butterworth and Co. (Publishers) Ltd., London. Pages 82, 258 and 507.

MODERN BRIDGE RESTORATION

A CHAIRSIDE CLINIC

FRANK D. DUNWORTH, B.D.S. (SYD.), D.D.S. (N.U.)

Reproduced from the Aust. D.J., 4 : 2, *with due acknowledgments to the author and publishers*

INTRODUCTION

THE task selected was the replacement of the upper left first molar and first bicuspid with a fixed partial denture[1]; the clinic was designed to demonstrate techniques and to use materials readily available to the general practitioner which would involve a minimum expenditure of time and cost.

The completed restoration consisted of a cast gold structure, having plastic facings on the full coverage abutments and utilizing long pin porcelain facings with built on ridge laps. The aesthetic disadvantages of a full gold occlusal surface cannot reasonably be overcome without resort to the recent special alloys with baked on porcelain[2, 3, 4, 5, 6]. This is a more specialized, and certainly more expensive field. Without resort to these new materials and techniques, the most feasible method of countering the uncertainty of the plastic facings is not to permanently cement the restoration. Instead, a "temporary" cement is used to set the completed case. It should then be removed for periodic inspection and prophylaxis[7]. When the acrylic facings discolour and/or wear, they can readily be replaced.

Study models and roentgenograms are shown in Figures 1, 2, 3 and 4.

Evaluation of the abutment potential of a tooth requires a careful examination including:

(*a*) Checking of roentgenograms for evidence of periodontal or periapical abnormality, caries, number and size of roots, quality and quantity of bone support.

(*b*) Clinical examination of the gingival crevice with a smooth periodontal probe.