

https://dspace.org/

Insights into a Hypercoagulable case of Thyrocardiac Disease and Literature Overview

Pin-yi Wu; Ruchika Meel

AMER COLL PHYSICIANS
https://hdl.handle.net/10539/44601
WOS

Downloaded from a DSpace repository. https://dspace.org/

WITS-2025-0003454

Annals of Internal Medicine
CLINICAL CASES

CASE REPORT

Insights Into a Hypercoagulable Case of Thyrocardiac Disease and Literature Overview

Pin-Yi Wu, MBCHB*[1]; and Ruchika Meel, MBCHB, MMED, Cert. Cardiology, PhD*[2]

[1]Department of Internal Medicine, Chris Hani Baragwanath Academic Hospital, University of the Witwatersrand, Johannesburg, South Africa

[2]Department of Internal Medicine, Faculty of Health Sciences, University of the Witwatersrand, Johannesburg, South Africa

Published online at
https://www.acpjournals.org/
doi/10.7326/aimcc.2022.1342

Open Access
This is an open access article distributed in accordance with the Creative Commons Attribution-NonCommercial-NoDerivatives 4.0 International License (CC BY-NC-ND), which allows reusers to copy and distribute the material in any medium or format in unadapted form only, for noncommercial purposes only, and only so long as attribution is given to the creator. See: https://creativecommons.org/licenses/by-nc-nd/4.0/legalcode.

Publication date: 15 August 2023

* Both authors contributed equally to this case report.

Acknowledgment
The authors thank Dr. Mpazi Siwale for providing the intraoperative photograph.

Disclosures
Disclosure forms are available with the article online.

Corresponding Author
Pin-Yi Wu, MBCHB; 7 York Rd, Park Town, Johannesburg, Gauteng 2193, South Africa; e-mail, pinyilindawu@gmail.com.

How to Cite
Wu P-Y, Meel R. Insights into a hypercoagulable case of thyrocardiac disease and literature overview. AIM Clinical Cases. 2023;2:e221342. doi:10.7326/aimcc.2022.1342

co-published by
ACP American College of Physicians
American Heart Association.

Keywords
Thyroid hormones, Hyperthyroidism, Thyroid-stimulating hormone, Thyroid, Thrombosis, Heart diseases, Storms, Pulmonary arteries, Echocardiography, Deep vein thrombosis

Abstract

Hyperthyroidism is associated with a hypercoagulable state and has been described previously in case studies in the context of cerebral vein thrombosis and pulmonary emboli. In this case report, we present a middle-aged man with a rare combination of rheumatic mitral valve disease and thyroid storm complicated by enormous intracardiac thrombus burden. We aim to highlight the hypercoagulable state associated with thyrocardiac disease and to alert the physician to remain vigilant for not only this clinical entity but also for multiple disease states occurring in 1 patient.

Background

Thyrocardiac disease is a well-described medical entity. Its association with coagulation and fibrinolysis has been described increasingly in the last 2 decades; however, it is still currently underappreciated (1). Several studies including case reports have focused on hyperthyroidism causing thromboembolic disease both with and without atrial arrhythmias (2–8).

Objective

This case highlights the prothrombotic state associated with hyperthyroidism and cardiac disease.

Case Presentation

A 45-year-old African man with no pertinent medical history presented to a tertiary hospital in a thyroid storm secondary to Graves disease. He reported palpitations, fatiguability, bipedal edema, weight loss, and diarrhea in the preceding weeks. Of note, he was a smoker with a 10 pack-year history.

On clinical examination, he was found to be afebrile with a blood pressure of 136/87 mm Hg (MAP 103 mm Hg) and fast atrial fibrillation (AF) with ventricular rates of 170 beats/min confirmed on electrocardiogram (Figure 1). He had bipedal edema and no obviously noted

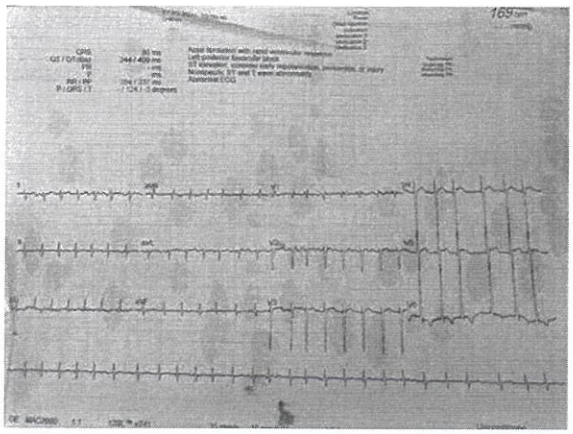

Figure 1. **Twelve-lead electrocardiogram shows rapid atrial fibrillation, biventricular hypertrophy, and right axis deviation.**

© 2023 Authors. Published in partnership by the American College of Physicians and American Heart Association

Downloaded from https://annals.org by 105.186.138.147 on 11/23/2023.

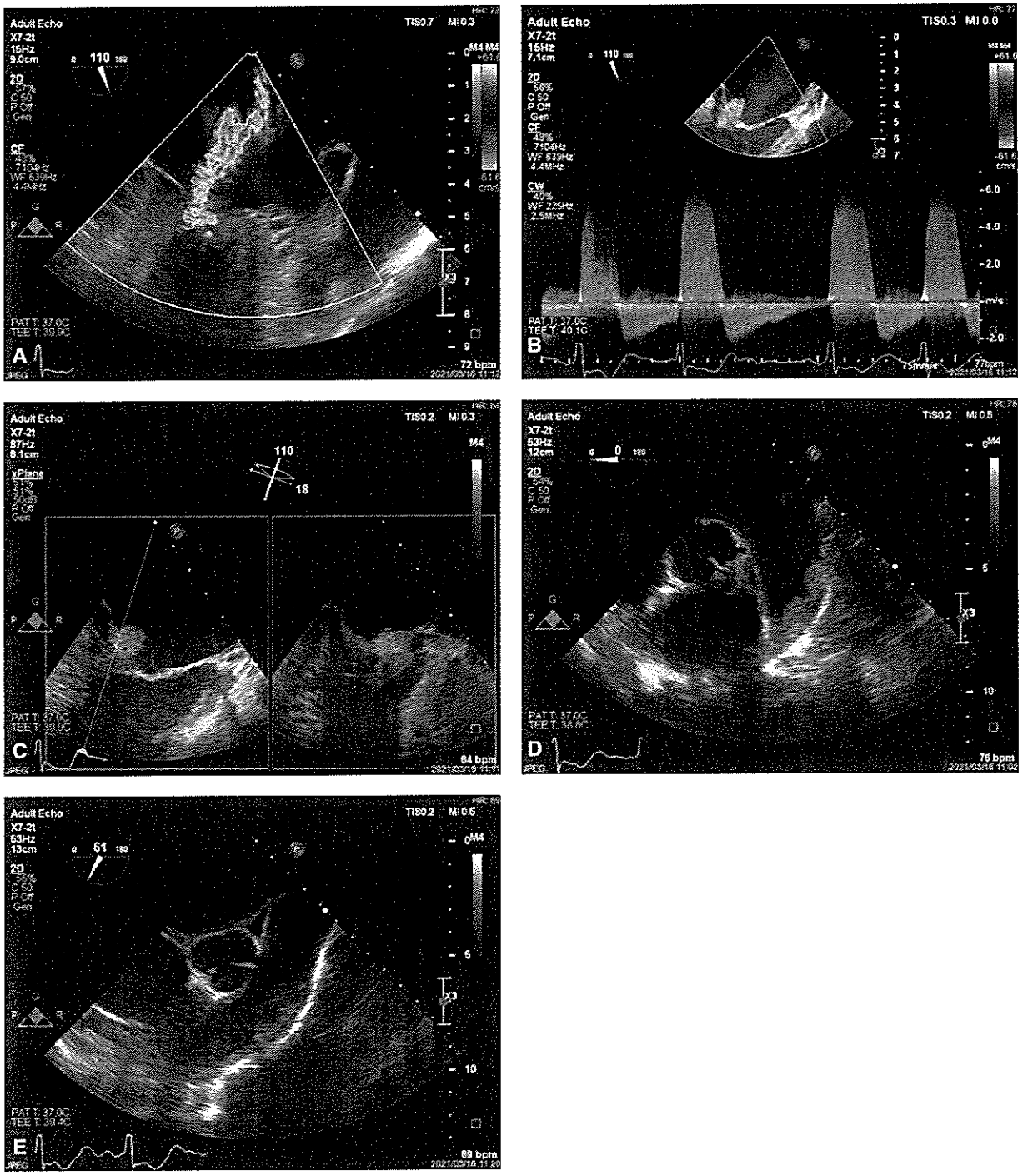

Figure 2. **(A and B) Dilated left atrium with rheumatic mitral regurgitation and mitral stenosis. (C) Rheumatic mitral stenosis with thrombus on the posterior mitral leaflet is noted. (D) Rheumatic mitral stenosis with thrombus in left atrial appendage. (E) Extensive thrombus along the right ventricular outflow tract and pulmonary artery.**

goiter. Cardiac auscultation revealed S1 with loud, palpable P2 with pansystolic murmurs in the tricuspid and mitral areas. Transthoracic echocardiography revealed biventricular enlargement, left atrial dilatation (59 mm) with rheumatic moderate mitral stenosis, severe mitral regurgitation, and severe tricuspid regurgitation. Left ventricular ejection fraction was reduced at 39% and pulmonary artery systolic pressure was elevated at 77 mm Hg. Multiple intracardiac thrombi were found on the left atrial appendage, posterior mitral leaflet, right ventricular outflow tract (RVOT), and the proximal pulmonary artery that were confirmed on transesophageal echocardiography (Figure 2A–E).

© 2023 Authors. Published in partnership by the American College of Physicians and American Heart Association

Downloaded from https://annals.org by 105.186.138.147 on 11/23/2023.

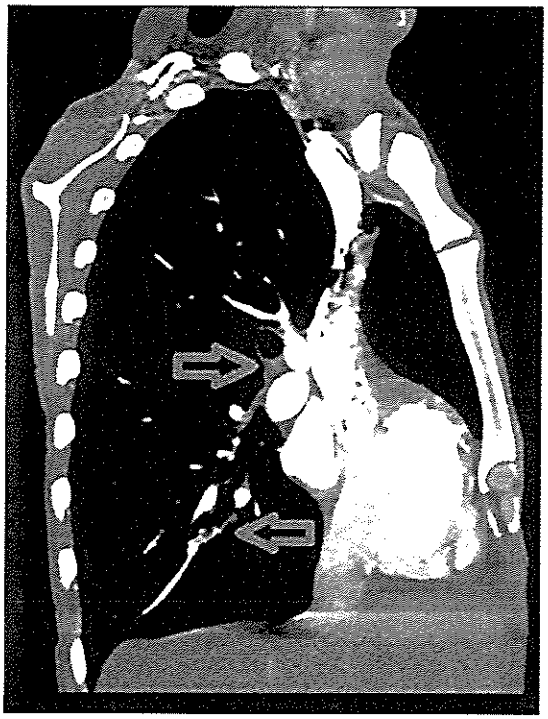

Figure 3. Sagittal view of the chest with filling defect in the segmental branch pulmonary artery suggestive of pulmonary embolism (*arrows*).

Thyroid function tests revealed thyroid-stimulating hormone level of <0.01 mIU/L, free T4 level 39.2 pmol/L, and thyroid-stimulating hormone receptor antibody of 39.33 IU/L, which was indicative of hyperthyroidism secondary to Grave's disease. A raised D-dimer of 5.48 mg/L also was noted.

Once the patient was successfully anticoagulated and a reasonable drop in FT4 was seen, a computed tomography pulmonary angiogram was done to confirm peripheral pulmonary emboli (Figure 3). Bilateral lower-lobe acute pulmonary emboli were noted. Due to low clinical suspicion for deep venous thrombosis (DVT) and a Wells score of zero, no further studies for lower-limb DVT testing were done.

It is important to emphasize that in this case, there were multiple possibilities to entertain the origin of the intracardiac clots. Rheumatic mitral valve disease (MVD) complicated by AF, thrombophilia, a possible patent foramen ovale, infective endocarditis, nonbacterial thrombotic endocarditis, and hypercoagulable state due to hyperthyroidism were considered. An intracardiac shunt was excluded by a negative bubble test finding on transesophageal echocardiography study, and thrombophilia and nonbacterial thrombotic endocarditis were excluded with negative antiphospholipid antibodies and negative autoimmune studies. The patient failed to fulfill the Duke's criteria for infective endocarditis. Rheumatic MVD complicated by AF explained the left-sided thrombi. However, in view of RVOT and pulmonary artery thrombi, hyperthyroidism was likely the main contributor to the hypercoagulable state.

The patient was followed up a month later. The AF had resolved, and repeat transthoracic echocardiography showed no thrombi in the RVOT or pulmonary artery; however, there was a hypermobile thrombus on the posterior mitral valve leaflet secondary to partial clot dissolution (Figure 4A and B). Due to the high risk for embolization, the patient was transferred urgently for mitral valve replacement. Rheumatic MVD and presence of left atrial appendage thrombus were confirmed intraoperatively (Figure 4C). Histologic specimens revealed valvular tissue with calcification. No vegetation was seen. He had a good postoperative outcome and was well at 1 month of follow-up. Written informed consent was obtained from the patient for publication of this article and the accompanying images.

Discussion

Since 1912, numerous case reports have been written up eluding to the link between hyperthyroidism and venous thrombosis—in the form of DVT, pulmonary emboli, as well as cerebral vein thrombosis (2–6). Hyperthyroidism affects the coagulation system and causes a hypercoagulable and decreased fibrinolytic state, with increased levels of von Willebrand factor, factor VIII, and fibrinogen, among others (1, 9–11). Histologic comparison of clots from euthyroid individuals and patients with hyperthyroidism showed denser fibrin network in the latter group and increased clot lysis time, which is consistent with decreased fibrinolysis (10). The proposed mechanisms by which the thyroid hormone affects the coagulation system have been divided into genomic and nongenomic groups (10, 11). Genomic influences involve thyroid hormone receptor subtype B (THRB)-mediated effects on the production of coagulation factors (11). Patients with defective THRB have elevated circulating thyroid hormones; however, they do not respond to the hormones at a tissue level (11). The hypothesis is structured around the fact that THRB is abundant in the liver, which is responsible for the synthesis of some coagulation factors (11).

Nongenomic pathways include mechanisms that do not rely on the interaction between thyroid hormone and the nuclear receptors (10). They include thyroid hormone–mediated increase in procoagulants including platelet activation as well as the release of specific cytokines (10).

Our patient had multiple factors that portended to the high thrombus burden. Aside from the hypercoagulability and endothelial dysfunction caused by the hyperthyroidism, AF combined with heart failure and valve disease exacerbated stasis of blood and contributed to the prothrombotic state. In the current case, the combination of multiple comorbidities contributing to an extreme state of hypercoagulability is an uncommon presentation and to our knowledge has not been described previously. It serves to draw attention of the clinician to maintain a state of vigilance and do a complete examination and investigations of comorbidities such as valvular heart disease, as in this case, and not merely attribute the heart failure and hypercoagulable state to hyperthyroidism and AF.

© 2023 Authors. Published in partnership by the American College of Physicians and American Heart Association

Downloaded from https://annals.org by 105.186.138.147 on 11/23/2023.

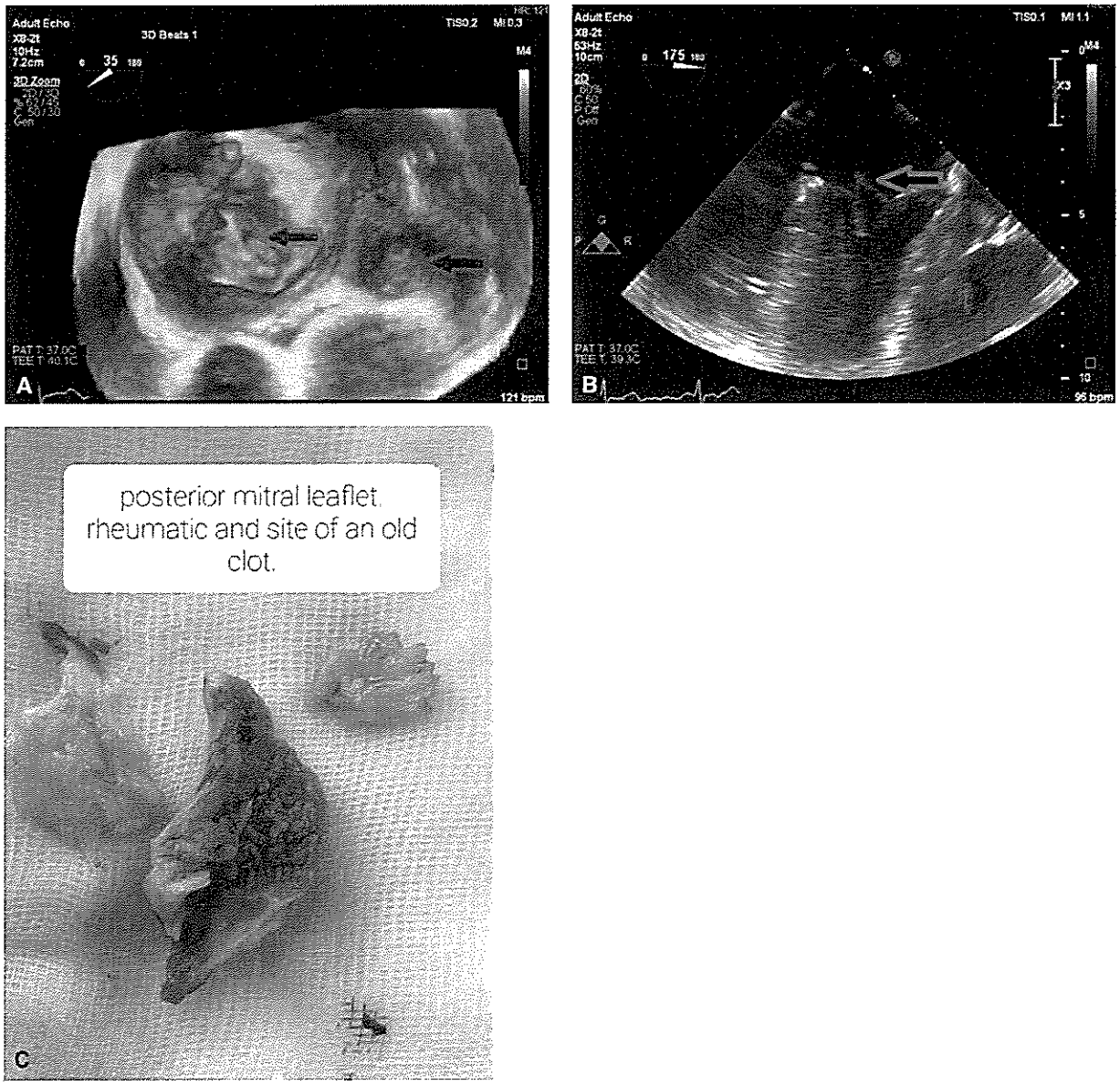

Figure 4. Transesophageal echocardiographic view with 3-dimensional reconstruction showing large mobile thrombus on the posterior mitral leaflet (A, *blue arrow*), left atrial appendage (A, *red arrow*). (B) Comparative 2-dimensional view showing thrombus (*blue arrow*) on the follow-up visit. (C) Intraoperative specimen showing rheumatic posterior mitral leaflet and the site of old thrombus.

In addition, there are currently no clear guidelines in terms of anticoagulation for high-risk patients with hyperthyroidism in the absence of AF. Of note, increased thyroid hormone levels enhance the anticoagulative effect and antithyroid agents (propylthiouracil and methimazole) decrease the anticoagulative effect of vitamin K antagonists (12). Thus, careful consideration for initiating anticoagulation as well as monitoring of international normalized ratio within recommended levels during treatment of this group of patients is necessary.

References

1. Elbers LPB, Fliers E, Cannegieter SC. The influence of thyroid function on the coagulation system and its clinical consequences. J Thromb Haemost. 2018;16:634-45. [PMID: 29573126] doi:10.1111/jth.13970
2. Gomes RR. Graves thyrotoxicosis and cerebral venous sinus thrombosis: causality or chance alone? Int Arch Endocrinol Clin Res. 2021;7:026.
3. Son HM. Massive cerebral venous sinus thrombosis secondary to Graves' disease. Yeungnam Univ J Med 2019;36:273-80. [PMID: 31620645] doi:10.12701/yujm.2019.00339
4. Grine S, Charfi N, Kamoun M, et al. Hyperthyroidism: a rare cause of pulmonary embolism: report of two cases. Indian J Endocrinol Metab. 2013;17:1104-7.
5. Elbers LPB, van Zaane B, Gerdes VEA, et al. Venous thromboembolism in overt hyperthyroidism—a direct

© 2023 Authors. Published in partnership by the American College of Physicians and American Heart Association

Downloaded from https://annals.org by 105.186.138.147 on 11/23/2023.

association with clinical implications? Neth J Med. 2014;72:242-4. [PMID: 24829185]
6. Elhassan AEE, Ali MOK, Bougaila A, et al. Hyperthyroidism as a precipitant factor for cerebral venous thrombosis: a case report. J Investig Med High Impact Case Rep. 2020;8:2324709620949309. [PMID: 32787455] doi:10.1177/2324709620949309
7. Maung AC, Cheong MA, Chua YY, et al. When a storm showers the blood clots: a case of thyroid storm with systemic thromboembolism. Endocrinol Diabetes Metab Case Rep. 2021;20:0118. [PMID: 33431706] doi:10.1530/EDM-20-0118.
8. Liu G, Yang P, He Y. Left ventricular mural thrombus and dual coronary embolization associated with hyperthyroid cardiomyopathy and atrial fibrillation: a case report. BMC Cardiovasc Disord. 2017; 17:128. [PMID: 28525971] doi:10.1186/s12872-017-0565-7
9. Squizzato A, Romualdi E, Büller HR, et al. Clinical review: Thyroid dysfunction and effects on coagulation and fibrinolysis: a systematic review. J Clin Endocrinol Metab. 2007;92:2415-20. [PMID: 17440013] doi:10.1210/jc.2007-0199
10. Davis PJ, Mousa SA, Schechter GP. New interfaces of thyroid hormone actions with blood coagulation and thrombosis. Clin Appl Thromb Hemost. 2018;24:1014-9. [PMID: 29742907] doi:10.1177/1076029618774150
11. Elbers LPH, Moran C, Gerdes BE, et al. The hypercoagulable state in hyperthyroidism is mediated via the thyroid hormone β receptor pathway. Eur J Endocrinol. 2016;174:755-62. [PMID: 26961801] doi:10.1530/EJE-15-1249
12. Traube E, Coplan NL. Embolic risk in atrial fibrillation that arises from hyperthyroidism: review of the medical literature. Tex Heart Inst J. 2011;38:225-8. [PMID: 21720457]

© 2023 Authors. Published in partnership by the American College of Physicians and American Heart Association

Downloaded from https://annals.org by 105.186.138.147 on 11/23/2023.