

https://dspace.org/

The healing mechanism in artificially created circumscribed defects in the femora of albino rats

Melcher, A. H.; Irving, J. T.

1962

http://hdl.handle.net/10539/20733

Melcher, A. H. Irving, J. T. 1962. The healing mechanism in artificially created circumscribed defects in the femora of albino rats. Journal of bone and joint surgery; 44B(4):928-936

Downloaded from a DSpace repository. https://dspace.org/

THE HEALING MECHANISM IN ARTIFICIALLY CREATED CIRCUMSCRIBED DEFECTS IN THE FEMORA OF ALBINO RATS*

A. H. MELCHER, LONDON, ENGLAND
and
J. T. IRVING, BOSTON, UNITED STATES OF AMERICA

From the Joint Council for Scientific and Industrial Research and the Dental Research Unit of the University of the Witwatersrand

Although many descriptions of the healing of fractures have been published (Ham 1953, Ham and Harris 1956, Urist and Johnson 1943, Weinmann and Sicher 1955), there is little information about the process of repair which takes place in circumscribed defects in bone. Studies on this mechanism have been reported by Ely (1927) and Bourne (1944). The purpose of this investigation is to describe the method of healing in artificially created circumscribed defects which communicate with the medullary cavity of the rat femur. The effect of mild trauma on the endosteum is also studied.

MATERIALS AND METHODS

Eighty-two albino rats of the Wistar strain, varying in weight from 150 to 400 grammes, were used. The rats were kept in well aired cages and allowed routine laboratory rations and as much water as they wanted.

In seventy-seven rats circumscribed defects communicating with the medullary cavity were made in each femur under ether anaesthesia. A longitudinal incision was made in the skin overlying the lateral aspect of the femur. The thigh muscles were separated and the lateral aspect of the femur was exposed. With a slow-running dental drill kept cool under a stream of water a defect approximately two millimetres in diameter was made in the middle of the diaphysis. The medullary cavity was exposed, the wound irrigated with saline and, in the right femora, the overlying soft tissues were immediately re-apposed. The defects in the left femora were grafted with various substances, but the results of that experiment will be described in a later paper. The rats were killed after periods varying from three days to one year.

In five rats, defects were drilled in the right femora and the endosteum on the side of the medullary cavity directly opposite the defect was scarified by means of a long straight sharp pointed probe which was passed through the defect. These animals were killed after periods varying from six days to two months after operation.

All the rats were killed by being made to inhale coal gas. After death the whole thigh was removed by disarticulation of the femur at its proximal and distal joints and fixed for two days in either formol-saline or formol-Zenker fluid. The specimens were decalcified in nitric acid and embedded in wax. Serial sections were cut at six μ and stained with haematoxylin and eosin.

RESULTS

The initial formation of the haematoma, its organisation and the development of the fibrous callus occurred in exactly the same fashion as has been previously described in fracture healing (Urist and Johnson 1943, Weinmann and Sicher 1955). In many of the specimens a condensation of fibrin formed a membrane which demarcated the external limits of the defect during this phase of healing.

* This study forms part of a dissertation submitted by A. H. M. and approved for the degree of Master of Dental Surgery in the University of the Witwatersrand, Johannesburg.

Subperiosteal changes—During the formation of the fibrin network in the haematoma there was enlargement and multiplication of cells of the cambium layer of the periosteum. This cellular proliferation occurred at some distance from the margin of the defect, lifting the



FIG. 1

Defect in femur of rat four days after operation. The defect is filled with fibrous callus. Activity of the cells of the cambium layer of the periosteum may be seen in the lower right part of the illustration. The fibrous layer of the periosteum has been lifted away from the femoral cortex. (×40.)

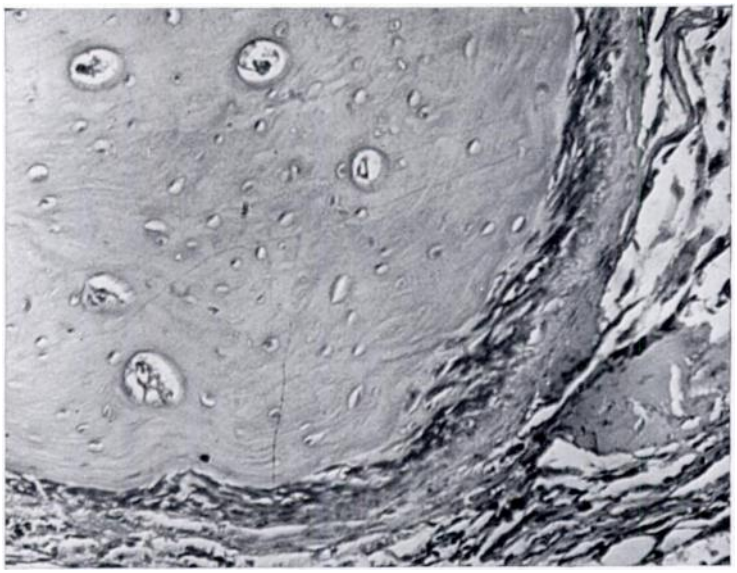

FIG. 2

A higher magnification of the area marked in Figure 1. New bone is being laid down on the femoral cortex. (×200.)

fibrous layer of the periosteum increasingly from the surface of the femur. A little later the proliferating cells became modified into osteoblasts and laid down new bone trabeculae on the periosteal surface of the femur (Figs. 1 and 2).

After the formation of fibrous callus and the initiation of subperiosteal activity there was activation of the cells of the endosteum some distance from the margin of the defect. These cells were not so far removed from the defect as were the proliferating cells of the cambium

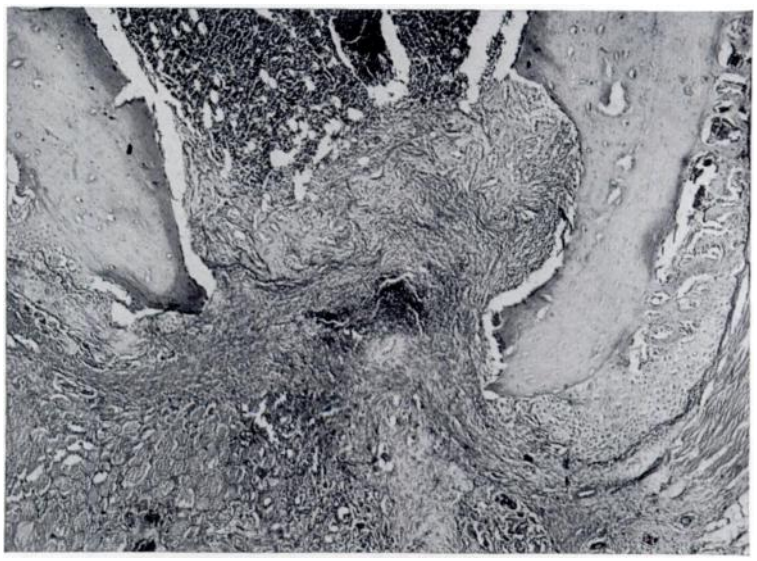

FIG. 3

Defect in femur of rat six days after operation. The subperiosteal callus on the right of the defect consists of bone and a leading edge of cartilage and developing cartilage. The endosteal callus which has almost bridged the defect may be recognised. The spaces between the bone and soft tissue are artefact. (×40.)



FIG. 4

Defect in femur of rat nine days after operation. The defect is almost filled with endosteal callus. The separation between the callus and the walls of the defect is artefact. The proliferation of subperiosteal callus has halted at the margins of the defect. (×40.)

layer of the periosteum. Within a short time bone callus was laid down on the endosteal aspect of the femur.

The subperiosteal bone, consisting of long slender trabeculae covered by plump active

osteoblasts, was laid down much more rapidly than was the endosteal bone and it developed outwards away from the surface of the femur and towards the defect. The main trabeculae were orientated at right angles to the surface and were joined to one another by shorter



FIG. 5

Defect in femur of rat twelve days after operation. The defect is filled with endosteal callus. This is being bridged by subperiosteal callus, the proliferation of which is more active to the right of the section than to the left. Early resorption of the medullary aspect of the endosteal callus may be seen to the left of the illustration. (×40.)

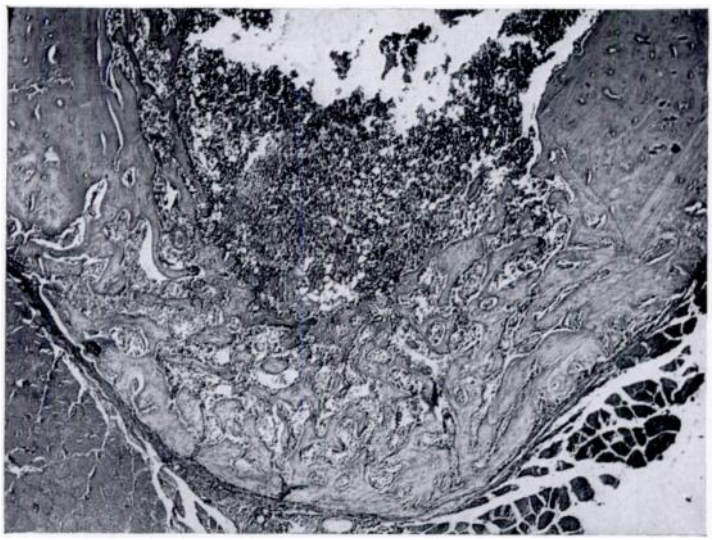

FIG. 6

Defect in femur of rat fifteen days after operation. The callus in the peripheral part of the defect is being remodelled. In the medullary aspect of the defect the endosteal callus is being resorbed. The callus lining the margins of the defect is not removed. (×40.)

trabeculae which lay approximately parallel to the bone surface. A deposit of cartilage was present in almost all the defects that were examined. The cartilage was usually situated between the bone trabeculae and the fibrous layer of the periosteum, but in a number of defects it

formed the full thickness of the leading edge of the subperiosteal callus (Fig. 3). In some defects subperiosteal callus was equally well developed on both sides of the wound, but often there were large deposits on one side only, the callus on the other side being rudimentary or wholly deficient.

The cartilage was gradually replaced by coarse fibrillar bone trabeculae in a manner like that which occurs in endochondral ossification but not so regularly. The development of callus was a progressive process and bone was never found to develop primarily in a block of cartilage. In most defects the fibrocartilaginous callus developed as far as the margin of the defect but did not, at this stage, begin to bridge it.

Endosteal changes—Proliferation of the endosteal callus, unlike that of subperiosteal callus, did not halt at the margins of the defect but immediately bridged it (Fig. 3). Callus then proliferated towards the subperiosteal aspect of the defect, being laid down along the walls and in the fibrous callus until about four-fifths of the bone wound was obliterated (Fig. 4).

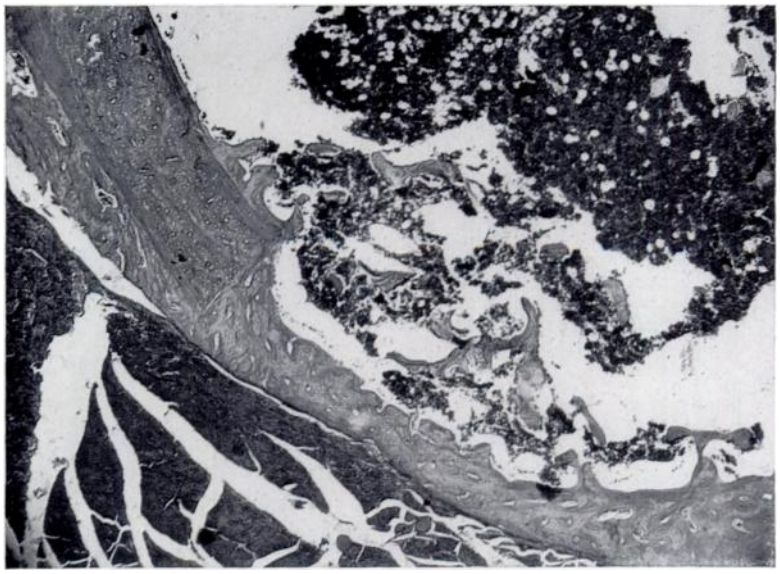

FIG. 7

Defect in femur of rat twenty-one days after operation. The healing bone in the defect occupies only about one-half of the thickness of the femoral cortex and isolated bone trabeculae and medullary tissue are present in the medullary aspect. The callus lining the wall of the defect has not been removed. Laminated bone is being deposited on the endosteal aspect of the bone in the defect. (×40.)

No isolated callus was observed to arise from either the cut bone of the wall of the defect or in the fibrous callus of the defect. Necrosis of the bone in the wall of the defect was rarely observed.

When deposition of endosteal callus reached to within a short distance of the periosteal limit of the defect there was a further proliferation of subperiosteal callus. These trabeculae were laid down on the surface of the endosteal callus so that the periosteal aspect of the defect was finally bridged by subperiosteal callus (Fig. 5). Periosteum was developed over the bridging callus.

Later changes—Gradually the subperiosteal callus covering the shaft of the femur was remodelled and converted to compact bone. No change in the underlying shaft of the femur, comparable with that which takes place in the healing of a fracture, was observed in any of the healing defects. In some specimens however, remodelling of adjacent bone on both sides of the junction of callus and femoral cortex took place and this resulted in a physical

bond between the two. After the callus had been converted into compact bone it was gradually removed by subperiosteal osteoclastic resorption.

From this stage on maturation of bone callus in the defect was restricted to the peripheral one-third to one-half. The trabeculae of the medullary aspect of the callus, with the exception



FIG. 8

Defect in femur of rat twenty-one days after operation showing the junction of the endosteal callus and the margin of the defect running from the upper left of the photomicrograph to the lower right. In the lower right hand corner an area of perivascular bone resorption extending across the junction may be seen. To the left of this are two similar areas in which new bone is being laid down. This has partially obliterated the cement line demarcating the junction. (× 210.)

of those lining the margins of the defect, were gradually resorbed (Figs. 5 and 6). Numerous large thin-walled blood vessels and osteoclasts were seen at this stage. The bone was progressively removed until the medullary one-half of the defect was occupied by isolated trabeculae lying in haemopoietic tissue. Serial sections showed that many trabeculae which appeared to be isolated were actually attached to the main body of callus. Callus lining the margins of the defect was not resorbed and the margin of the defect could be recognised by a resting line (Fig. 7).

Perivascular modelling resorption took place at points along the margin of the defect at its junction with endosteal callus, and this gave rise to oval-shaped resorbed areas which lay across the cement line. At other points new bone was laid down in these areas to form compact bone and the cement line was being obliterated (Fig. 8). No

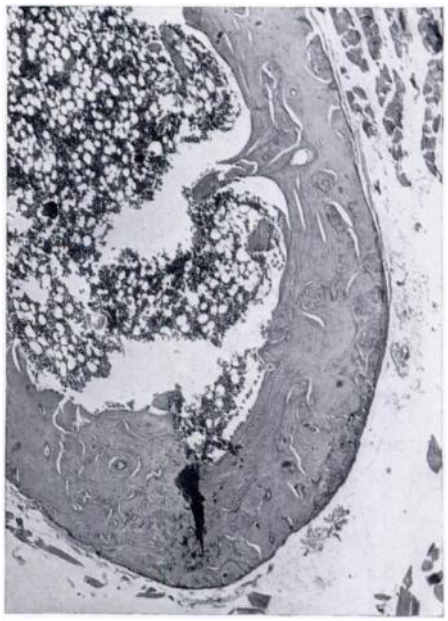

FIG. 9

One year after operation. The defect is seen in the lower right part of the field. The new bone is still not quite the same width as the rest of the cortex and, to the left, it is clearly laminated. (× 40.)

osteoclasts were observed to be associated with this resorptive process. Peripheral callus was converted to compact bone and the cells in the cambium layer of the periosteum modulated to flat or spindle shapes.

Eventually remodelling of callus was completed and usually excess subperiosteal callus was removed. The periosteum returned to a resting inactive appearance. Healing bone in the defect occupied the outer half of the defect. The cells of the endosteum lining this bone were of active appearance and were slowly laying down new inner circumferential lamellae (Fig. 7). One year after operation the bone in the defect had still not been restored fully to normal width and the medullary aspect of the healing bone consisted largely of inner circumferential lamellae (Fig. 9).

In those animals in which endosteum directly opposite the defect was scarified, a very small proliferation of endosteal trabeculae was recognised in a circumscribed area of the medulla directly opposite the defect. These trabeculae were not demonstrated in animals killed earlier than six days after operation nor later than three weeks after operation.

DISCUSSION

The relative importance of subperiosteal and endosteal callus—The results obtained from this study indicate that the healing process in a circumscribed defect in the femur of a rat is very different from that which has been described repeatedly in the healing of broken long bones. The literature on the mechanism of fracture healing, almost without exception, stresses the importance of subperiosteal callus in re-establishment of the continuity of fragments and attainment of bony union. Endosteal callus is also concerned with bringing about union, but its role is subservient to that of subperiosteal callus. One of the few authors who disagree with this concept is Enneking (1948), who maintains that healing is brought about primarily by proliferation of endosteal callus and that subperiosteal callus only bridges the fracture line after endosteal callus has filled the whole area between the cortices of bone fragments.

The results of this investigation show that in healing a circumscribed penetrating defect in the femur of a rat endosteal callus plays the major role. At no time in any of the healing defects that were examined did subperiosteal callus attempt to bridge the defect without a foundation of endosteal callus along which it could proliferate. In fact there was often such exuberant production of subperiosteal callus that the proliferation reached the margin of the defect long before endosteal proliferation had filled the wound. In these instances the development of subperiosteal callus was apparently halted and no attempt was made to cross the defect until endosteal callus was sufficiently developed to allow subperiosteal callus to use it as a scaffolding.

There is a marked contrast between the rapid proliferation of subperiosteal callus in a healing fracture and its comparatively minor role in repair of a circumscribed defect. Its varying behaviour might be explained on the basis of its two-fold function—maintenance of continuity and provision of strength. Possibly some stimuli to the development of subperiosteal callus are initiated by rupture of the periosteum, and are then progressively intensified by fracture of the bone shaft and displacement of fragments. Other stimuli may arise from functional weakening of the bone and these will also increase as the disability becomes more severe. On this premise, fracture of a long bone, particularly if there is considerable displacement, will provide an enormous stimulus to the formation of subperiosteal callus. Conversely, stimulation from a circumscribed defect will not be very marked because loss of both function and continuity are comparatively mild.

Endosteal callus appears to fill four distinct functions in the repair of this type of bone defect. First it seals off the medullary cavity from the external environment of the bone. Once this has been completed successfully it proliferates until most of the defect is filled with immature spongy coarse woven bone which provides a scaffolding on which subperiosteal

callus can be laid down. Thirdly, once the periosteal aspect of the defect has been filled by subperiosteal callus, endosteal callus is largely resorbed. This mechanism so far as is known has not been described before. It may possibly occur in order to provide additional lime salts for calcification of the maturing subperiosteal callus. Finally, endosteal callus is responsible for the attachment of bone callus in the defect to the bone of the femur. Bast, Sullivan and Geist (1925) and Bourne (1944) made saw cuts and defects in bone and noted that endosteal callus is chiefly responsible for repair, subperiosteal callus playing a subsidiary role.

Bourne (1944) found that for a reason he could not explain the whole medulla was occasionally filled with bone trabeculae. A similar phenomenon was noticed in one or two of the healing defects described in this experiment. Many trabeculae were observed to arise from cells of the endosteum on the side of the medullary cavity opposite the defect. It was thought that the endosteum had been injured by the drill during creation of the defect and that this had stimulated new bone formation. This view has been strengthened by results obtained from scarifying the endosteum.

Mechanism of healing—The trabeculae of subperiosteal callus are initially long and slender, orientated at right angles to the surface of the femur, and connected to one another by short trabeculae parallel to the surface of the bone. On the other hand, the main trabeculae of subperiosteal callus in a healing fracture are generally directed in the line of fracture forming an acute angle with the surface of the bone (Urist and Johnson 1943, Weinmann and Sicher 1955, Ham and Harris 1956). This variation in architecture probably arises because the stresses present in a long bone which has been fractured are different from those in one with just a defect. In many specimens the subperiosteal deposit on one aspect of the defect was much larger than that on the other. Bast, Sullivan and Geist (1925) made the same observation on the healing process in saw cuts in the tibiae of rabbits. It is possible that this unequal proliferation occurs in response to the functional demands of the femur as a whole.

Activity of endosteal cells is initiated after subperiosteal callus has begun to develop. This observation is contrary to the findings of Bourne (1944). No support could be found for the contention of Enneking (1948) that the late appearance of endosteal callus results from pressure of the haematoma on the cells which produce it.

It is significant that bone did not form primarily in fibrous callus and that new bone was always laid down in continuity with the bony trabeculae. Ham and Harris (1956) maintain that active osteoblasts may influence other cell types with which they are in close continuity to take on the morphology and function of osteoblasts. Thus, modification of the cells of fibrous callus to osteoblasts may take place under the influence of adjacent active osteoblasts.

In this investigation necrosis of the walls of the defect seldom took place and in most defects the vitality of border bone remained unimpaired. This observation is in contrast to findings in the repair of fractures, but is in agreement with results obtained by Ely (1927) after drilling holes in the tibiae of cats. It is noteworthy that endosteal trabeculae lining the wall of the defect are never removed in the process of resorption of endosteal callus and that in the early stages of healing the margin of the defect can be recognised readily by a cement line. However, eventually remodelling of bone brings about physical attachment between the wall of the defect and the endosteal callus, with obliteration of the cement line. In this study no osteoclasts were recognised in association with this process but, because osteoclasts are very transient cells, this does not necessarily mean that they do not participate. Thus, despite the fact that only the outer third of the defect is eventually filled with callus, it is attached to the whole length of the bone forming the margin of the defect.

SUMMARY AND CONCLUSIONS

1. An experimental study of the healing mechanism in circumscribed defects in femora of albino rats of the Wistar strain is described.

2. Only the outer one-fifth of the defect is repaired by subperiosteal bony callus, the rest of the defect being repaired by endosteal callus.
3. Subperiosteal callus does not bridge the defect until endosteal callus is developed fully.
4. As peripheral callus matures the greater part of the endosteal callus is resorbed, with the exception of trabeculae attached to the margin of the defect.
5. The resorbed area in the medullary part of the defect is gradually obliterated by deposition of inner circumferential lamellae.
6. There appear to be differences between the mechanism responsible for repair of fractures of a long bone and that which heals circumscribed bone defects.

The authors are indebted to Mrs A. Vorster who prepared the photomicrographs.

REFERENCES

BAST, T. H., SULLIVAN, W. E., and GEIST, F. D. (1925): The Repair of Bone. *Anatomical Record*, **31**, 255.
BOURNE, G. H. (1944): Relative Importance of Periosteum and Endosteum in Bone Healing and Relationship of Vitamin C to their Activities. *Proceedings of the Royal Society of Medicine*, **37**, 275.
ELY, L. W. (1927): The Internal Callus: an Experimental Study. *Archives of Surgery*, **15**, 936.
ENNEKING, W. F. (1948): The Repair of Complete Fractures of Rat Tibias. *Anatomical Record*, **101**, 515.
HAM, A. W. (1953): *Histology*. Second edition. London: Pitman Medical Publishing Co. Ltd.
HAM, A. W., and HARRIS, W. R. (1956): In *The Biochemistry and Physiology of Bone*. Edited by G. H. Bourne. New York: Academic Press Inc.
URIST, M. R., and JOHNSON, R. W., Jun. (1943): Calcification and Ossification. IV. Healing of Fractures in Man under Clinical Conditions. *Journal of Bone and Joint Surgery*, **25**, 375.
WEINMANN, J. P., and SICHER, H. (1955): *Bone and Bones*. Second edition. London: Henry Kimpton.