

https://dspace.org/

The early healing of circumscribed defects in albino rats

Wantenaar, R. P.

1970

http://hdl.handle.net/10539/19552

Wantenaar, R. P. 1970. The early healing of circumscribed defects in albino rats. Journal of the dental association of South Africa; 25(12):445-9

Downloaded from a DSpace repository. https://dspace.org/

THE EARLY HEALING OF CIRCUMSCRIBED DEFECTS IN ALBINO RATS*

R. P. WANTENAAR

Joint Dental Research Unit of the University of the Witwatersrand and the South African Medical Research Council

INTRODUCTION

MANY investigations have been directed at the healing mechanisms in fractures, extraction sockets and circumscribed bony defects in experimental animals. While there is general agreement on the pattern of healing during the later stages of repair, the initial callus formation remains a subject of controversy.

Bourne (1944), describing the healing mechanism in rat femoral defects, stated that initially they are filled by osteoid proliferation from the periosteum. Mazarow (1960) found that in the dog mandible the defect is filled in from its cut surface and by bone trabeculae stemming chiefly from the periosteum. Melcher and Irving (1962) studied the healing mechanism in circumscribed defects in rat femora. They stated that the initial callus formation is subperiosteal; it occurs some distance from the defect, and proliferates towards, but halts at its margins. Only then does endosteal callus formation begin which proliferates outwards to fill four-fifths of the defect; and the periosteal one-fifth is then covered by subperiosteal callus and thus the defect is bridged. According to these authors, no callus arises from the cut surfaces of the defect.

More recently, Pallasch (1968), who used tetracycline labelling to study the healing of experimental defects in the rat femur, found that at one week they were filled by fibrous callus. He did not state, however, where the callus originated.

Kramer, Killey and Wright (1968), in their work on defects in rat calvaria, found that callus proliferates from the endocranial aspect and to a lesser extent from the pericranium and adjacent bone. The experiments by Agren and Arwill (1968) disclosed that in the healing of experimental defects in rabbit tibiae, endosteal callus appears initially at three days followed by periosteal callus at seven days and from the margins of the cavity by the 10th day. Retief and Cleaton-Jones (1970) showed that callus proliferates from the endosteal and cut surfaces of defects in rat mandibles.

The object of this investigation was to determine the initial site of callus formation and its subsequent role in the early healing of circumscribed femoral defects in the rat.

MATERIALS AND METHODS

A total of 22 Wistar strain, male and female albino rats with an average weight of 250 grams, were used. Under neurolept anaesthesia ("Hypnorm"—Philips Duphar 0.2 mm/100 mg body weight) bilateral femoral defects communicating with the medullary cavity were made in the following way: The skin overlying the lateral aspect of the femur was incised, and the aponeurotic insertion of biceps femoris muscle was exposed and separated by blunt dissection. The underlying femur was then exposed.

Using a slowly running no 3 round bur with water coolant, a circumscribed defect was prepared in the centre of the shaft of the femur extending into the medullary cavity (Fig. 1). Particular care was taken not to injure the opposite endosteal surface. The muscles were repositioned and the skin incision sutured with silk.

The animals were sacrificed on the first, third, fifth, seventh, tenth and eleventh days after the operation, using coal gas. Immediately after death both femora were disarticulated and fixed in formal-saline. The specimens were decalcified in formic acid, embedded in paraffin wax and transverse serial sections were cut which were stained with haemotoxylin and eosin.

*The author, who has since qualified, was awarded the J.C. Middleton-Shaw prize for the best original research paper at the 1970 student meeting of the Johannesburg branch of the Odontological Society of South Africa.

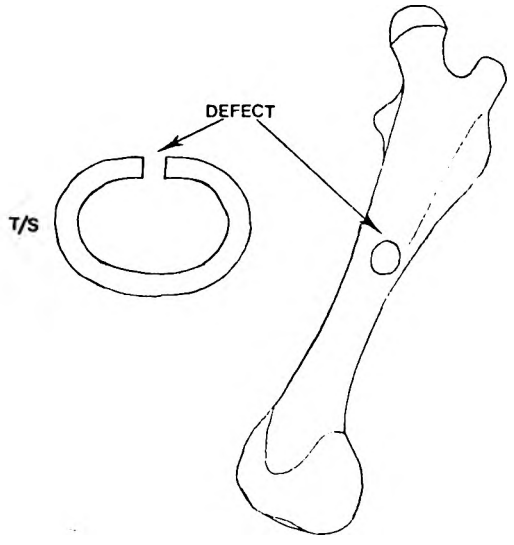

FIG. 1. Diagram showing site of femoral defect.

RESULTS

Examination of the histological sections revealed the following features:

One day after operation the defect was filled with haematoma. No callus formation had occurred either at the cut margins of the defect or the periosteal surfaces adjacent to it.

By the third day the blood clot had been organised showing cellular and fibrous proliferation. No callus was present.

Five days after operation there was bony callus within the defect (Fig. 2), which appeared to originate from its cut surface. At this stage the line demarcating that surface was well evident.

The findings seven days after operation are shown in Fig. 3. The defect was filled with bony callus whose traceculae arose from the cut margins and endosteal surface and were orientated at right angles to its floor. Periosteal callus had appeared but was distant from and in no way related to the defect (Fig. 4).

By the 10th day it was filled completely by the bony callus from the cut and endosteal surfaces (Fig. 5).



FIG. 2. Photomicrograph showing bony callus (BC) arising from cut margin (DM) on the 5th day. (× 100).



FIG. 3. Defect on the 7th day filled with bony callus from the cut margins and endosteal surface. (ES) (× 40).



FIG. 4. Periosteal callus (PC) on the 7th day is well away from the cut margin of the defect (× 40).

Eleven days after operation the periosteal callus had reached the margins of the defect and had proliferated over the underlying endosteal callus to bridge it (Fig. 6). There was remodelling of its margins.

DISCUSSION

Thompson (1958) showed that thermal necrosis of bone results when the bur speed exceeds 5,000 r.p.m. A slowly running water-cooled bur was therefore used to prepare the defects.

If during the preparation of a circumscribed femoral defect the opposite endosteum is damaged, a marked bony proliferation occurs at the site of injury (Dreyer 1970). As this might affect the healing pattern in and around the defect, appropriate precautions were taken.

The cartilage between the bone trabeculae and the fibrous layer of the periosteum described by Melcher and Irving in their study of the repair of femoral defects in rats, was not seen.

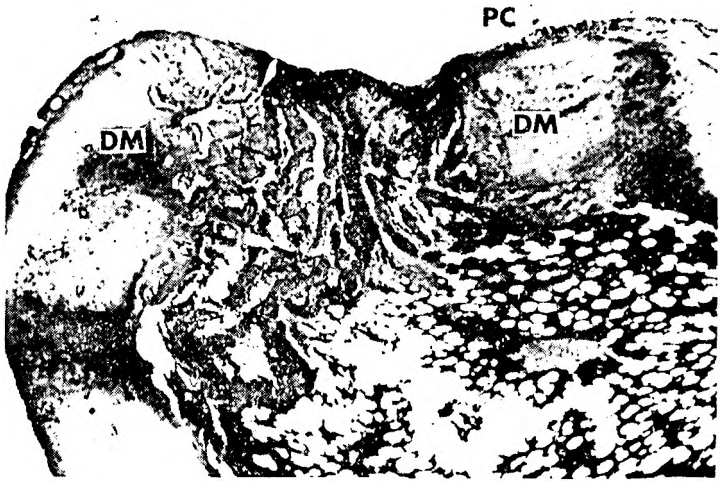

FIG. 5. Defect 10 days after operation. Defect is filled with bone and periosteal callus has reached the defect margin (× 40).



FIG. 6. On the 11th day periosteal callus is proliferating over the underlying endosteal callus to bridge the defect. Remodelling of the defect margins is occurring. (R) (× 40).

In this study the initial callus formation originated from the endosteal and cut surface of the defect and completely filled it, which differs from the pattern found by Melcher and Irving. Periosteal callus formation appeared only on the seventh day after operation distant to the margins of the defect; and it was not until the eleventh day that it contributed towards the healing process by proliferating over the underlying endosteal callus to bridge the defect.

SUMMARY

The early healing pattern of circumscribed defects in the femora of albino rats is described.

The initial callus arises from the endosteal and cut surfaces of the defect. Periosteal callus occurs initially distant to the margins of the defect and bridges it only when it has been filled by endosteal callus.

ACKNOWLEDGMENT

The author is indebted to the staff of the

Dental Research Unit of the University of the Witwatersrand and South African Medical Research Council for their help, encouragement and facilities provided for this study.

REFERENCES

AGREN, E. and ARWILL, T. (1968). High speed or conventional dental equipment for the removal of bone in oral surgery. III A histologic and microradiographic study of bone repair in the rabbit. *Acta. Odont. Scand.* 26: 223-246.

BOURNE, G. H. (1944): Relative importance of periosteum and endosteum in bone healing and the relationship of Vitamin C to their activities. *Proc. R. Soc. Med.* 37:275-279.

DREYER, C. J. (1970) Personal communication.

KRAMER, I. R. H., KILLEY, H. C. and WRIGHT, H. C. (1968). A histological and radiological comparison of the healing of defects in the rabbit calvarium with and without implanted heterogenous anorganic bone. *Archs. Oral Biol.* 13:1095-1106.

MAZAROW, H. B. (1960): Bone repair after experimentally produced defects. *J. Oral Surg. Anaes and Hosp. D. Serv.* 18:107-115.

MELCHER, A. H. and IRVING, J. T. (1962): The healing mechanism in artificially created circumscribed defects in the femora of albino rats. *J. Bone and Joint Surg.* 44-B:928-936.

PALLASCH, T. J. (1968): The healing pattern of an experimentally induced defect in the rat femur studied with tetracycline labelling. *Calc. Tiss. Res.* 2:334-342.

RETIEF, D. H. and CLEATON-JONES, P. E. (1970). The healing of circumscribed defects in the mandibles of albino rats. *J. dent. Ass. S. Afr.* 35:34-41.

THOMPSON, H. C. (1958): Effect of drilling directly into bone. *J. Oral Surg.* 16: 22-30.

TISSUE RESPONSE TO PONTIC MATERIAL AND DESIGN

FRANCIS MATARAZZO

Reproduced from Temple dent. Review., 40:2, *with due acknowledgments to the author and publishers.*

The Pontic

THE suspended member of the fixed partial prosthesis is known as the pontic and serves several purposes: replacement of the lost natural tooth, restoration of its function, and the usual occupancy of the space created by the missing tooth. In a bridge, the pontic and retainer are connected by either a rigid connector, such as the soldered joint, or a non-rigid connector, such as the precision attachment.[1]

For the "dummy," as a pontic has been called, to be satisfactory certain requirements must be met: "restore the function of the tooth which it replaces; insure its sanitation; meet the demands of esthetics and comfort; and finally, be biologically acceptable to the tissues."[2] The last, but certainly not the least important prerequisite, is the one with which my paper will be concerned.

Whether or not the pontic is biologically acceptable is determined by analyses of the tissue responses to variously constructed pontics, since the pontic material can be either entirely metal, entirely porcelain, entirely acrylic resin, or a combination of these. The gold-porcelain combination is predominately in use today. The pontic can also differ with respect to its ridge contour, being either a saddle type, a ridge-lap type, a spheroidal type, a conical-root type—all of which contact the ridge in some respect; or the completely sanitary type, in which there exists a definite space between the pontic and ridge.

The tissue in question is the mucosa covering the ridge. This is of two types: a firm, dense, and immobile type which covers the ridge proper; and a softer and more movable kind covering the base of the ridge. The former, a thin, unyielding type, is the only mucosa with which the pontic should come in contact.

Pontic Material and Its Tissue Effects

Opinions expressed with regard to the ideal pontic material for fixed partial dentures have been rather controversial, ranging from completely favourable tissue