

https://dspace.org/

Nuclear parcellation of pontine catecholaminergic and cholinergic neurons in gray parrots and pied crow brains

Pedzisai Mazengenya; Paul Manger

https://hdl.handle.net/10539/47560
SCOPUS

Downloaded from a DSpace repository. https://dspace.org/

Received: 23 August 2024 | Revised: 2 October 2024 | Accepted: 8 October 2024

DOI: 10.1002/ar.25593

RESEARCH ARTICLE

The Anatomical Record | American Association for Anatomy | WILEY

Nuclear parcellation of pontine catecholaminergic and cholinergic neurons in gray parrots and pied crow brains

Pedzisai Mazengenya[1,2,3] | **Paul R. Manger**[3]

[1]College of Medicine, Ajman University, Ajman, United Arab Emirates

[2]Center of Medical and Bio-allied Health Sciences Research, Ajman University, Ajman, United Arab Emirates

[3]School of Anatomical Sciences, Faculty of Health Sciences, University of the Witwatersrand, Johannesburg, South Africa

Correspondence
Pedzisai Mazengenya, College of Medicine, Basic Medical Sciences Department, Ajman University, Ajman, United Arab Emirates.
Email: p.mazengenya@ajman.ac.ae

Funding information
Ajman University Research Grant, Grant/Award Number: 2022-IRG-MED-3

Abstract

Employing immunohistochemical procedures with antibodies raised against tyrosine hydroxylase (TH) and choline acetyltransferase we identified and mapped the locus coeruleus complex (LoC) and the pontine laterodorsal tegmental (LDT) and pedunculopontine tegmental (PPN) cholinergic nuclei in the brains of a Congo gray parrot, a timneh gray parrot, and a pied crow. The LoC and LDT/PPN are centrally involved in the regulation and generation of different sleep states, and as all birds studied to date show both REM and non-REM sleep states, like mammals, we investigated whether these noradrenergic and cholinergic nuclei in the avian pons shared anatomical features with those in the mammalian pons. The LoC was parcellated into 3 distinct nuclei, including the locus coeruleus (A6), subcoeruleus (A7), and the fifth arcuate nucleus (A5), while distinct LDT and PPN nuclei were revealed. Several similarities that allow the assumption of homology of these nuclei between birds and mammals were revealed, including their location relative to each other and other structures within the pontine region, as well as a specific degree of topographical overlap of the noradrenergic and cholinergic neurons. Despite this, some differences were noted that may be of interest in understanding the differences in sleep between birds and mammals. Further anatomical and physiological studies are needed to determine whether these pontine nuclei in birds play the same role as in mammals, as while the homology is apparent, the functional analogy needs to be revealed.

Abbreviations: 4n, trochlear nerve; 5n, trigeminal nerve; 6n, abducens nerve; 7n, facial nerve; A10, ventral tegmental area; A11, caudal diencephalic group; A5, fifth arcuate nucleus; A6, locus coeruleus; A7, subcoeruleus; A8, retrorubral nucleus; Cb, cerebellum; CP, cerebellar peduncle; CTz, corpus trapezoideum (Papez) (trapezoid body); DLL, nucleus dorsolateralis anterior, pars lateralis; FLM, fasciculus longitudinalis medialis (medial longitudinal fasciculus); GiCRt, gigantocellular reticular nucleus; IV, nucleus nervi trochlearis (trochlear nucleus); LC, nucleus linearis caudalis (caudal linear nucleus); LDT, laterodorsal tegmental nucleus; LLD, nucleus lemnisci lateralis, pars dorsalis (nucleus of the lateral lemniscus, dorsal part); LoC, locus coeruleus complex; PCRt, parvicellular reticular nucleus; PM, nucleus pontis medialis (medial pontine nucleus); PPN, pedunculopontine tegmental nucleus; PrV, nucleus sensorius principalis nervi trigemini (principal trigeminal sensory nucleus); SLu, nucleus semilunaris; TO, optic tectum; VIId, nucleus motorius dorsalis nervi facialis (facial motor nucleus, dorsal part); VIIv, nucleus motorius ventralis nervi facialis (facial motor nucleus, ventral part); Vmd, nucleus motorius dorsalis nervi trigemini (trigeminal motor nucleus, dorsal part); Vmv, nucleus motorius ventralis nervi trigemini (trigeminal motor nucleus, ventral part).

This is an open access article under the terms of the Creative Commons Attribution-NonCommercial-NoDerivs License, which permits use and distribution in any medium, provided the original work is properly cited, the use is non-commercial and no modifications or adaptations are made.
© 2024 The Author(s). *The Anatomical Record* published by Wiley Periodicals LLC on behalf of American Association for Anatomy.

KEYWORDS

aves, catecholaminergic, choline acetyltransferase, cholinergic, immunohistochemistry, noradrenergic, RRID AB_10000323, RRID AB_2079751, tyrosine hydroxylase

1 | INTRODUCTION

A striking neurophysiological similarity of birds and mammals is the presence of both rapid eye movement (REM) and slow wave or non-REM (NREM) sleep states (e.g., Lesku & Rattenborg, 2014; Rattenborg & Martinez-Gonzalez, 2015). Equivalent sleep states have not been unambiguously observed in other vertebrates, although the possible presence of these two sleep states in nonavian reptiles has been reported (Shein-Idelson et al., 2016). At present, it is unclear whether these two sleep states were inherited from a shared ancestor, where these sleep states were clearly expressed, or whether they evolved independently and convergently in the avian and mammalian lineages (Rattenborg & Martinez-Gonzalez, 2015).

Birds and mammals show high-amplitude slow waves during NREM that propagate as traveling waves through the pallium, with increased global and local slow-wave activity following sleep deprivation and local stimulation, respectively, indicating homeostatic regulation of slow-wave activity (Rattenborg & Martinez-Gonzalez, 2015). REM sleep in both birds and mammals is characterized by a desynchronized electroencephalogram (EEG), reduced muscle tone, an absence of behavioral thermoregulation, REMs, and occasional muscular twitches (Rattenborg & Martinez-Gonzalez, 2015). REM sleep homeostasis (e.g., Tobler & Borbély, 1988) and the development of this sleep state (e.g., Scriba et al., 2013) are also comparable in birds and mammals.

Despite these similarities, there are also distinct differences. NREM thalamocortical spindles observed in mammals are not present in birds, and during REM the hippocampal theta rhythm characteristic of REM in mammals is not observed in birds (Rattenborg et al., 2011; Tobler & Borbély, 1988; van der Meij et al., 2019). To the best of our knowledge, ponto-geniculo-occipital (PGO) waves have not been reported in birds. REM sleep bouts in birds, even those that sleep on the ground, are generally shorter than 10 sec, as opposed to the several minutes a mammal spends in a bout of REM (Lesku & Rattenborg, 2014). It appears that the higher core body temperature of birds might be a causal factor in the relatively low overall amount of avian REM sleep compared to mammals (Siegel, 2022). Another difference is that in birds the pupils are maximally dilated during NREM and constrict during REM, while in mammals the pupils are maximally constricted during NREM and can dilate during REM (Ungurean & Rattenborg, 2022).

In mammals, the locus coeruleus complex (LoC, noradrenergic) and cholinergic pontine nuclei (the laterodorsal, LDT, and pedunculopontine tegmental nuclei, PPN) play a central role in the features of the global brain and body states observed through the sleep–wake cycle (e.g., Jones, 1991; Pace-Schott & Hobson, 2002; Siegel, 2004). While inactivity of LoC neurons is necessary for REM sleep to occur (Jones, 1991) and leads to REM sleep atonia (e.g., Lai et al., 2001), recent studies have implicated the varied activity patterns of LoC neurons during different sleep states in a broader functional context (Osorio-Forero et al., 2022). The pontine cholinergic neurons of the LDT and PPN are involved in the production of the desynchronized EEG of wake and REM and the generation of PGO waves during REM (Jones, 1991; Steriade et al., 1990). The generation of REM sleep is dependent on cholinergic activation and noradrenergic suppression, that may be enhanced by the overlapping distribution of these neurons (Jones, 1991; Manger et al., 2002). To the authors' knowledge, studies of the activity patterns of LoC, LDT and PPN neurons during the sleep–wake cycle have not been investigated in birds.

Despite this, LoC, LDT, and PPN are present in the avian brain (Reiner et al., 1994). The LoC has been described in parakeet (Shiosaka et al., 1981), pigeon (Kitt & Brauth, 1986), zebra finch (Botjer, 1992; Mello et al., 1998), quail (Bailhache & Balthazart, 1993), chicken (Kamkrathok & Chaiseha, 2022; Montagnese & Csillag, 1996; Moons et al., 1995), budgerigar (Roberts et al., 2001), canary (Appeltants et al., 2001), and house crow (Sen et al., 2019). The LDT and PPN have been described in the pigeon (Medina & Reiner, 1994) and young chickens (González-Cabrera et al., 2015). Despite the availability of these descriptions, the anatomical relationship between the noradrenergic and cholinergic pontine nuclei, and how this compares to what is observed in mammals (Jones, 1991; Manger et al., 2002), has not been explored. The relationships between these neuronal types may be important to sleep state transition in birds, as it is in mammals (Jones, 1991), and is thus of interest to our growing understanding of avian sleep and the similarities in avian and mammalian sleep. To this end, we examined, using immunohistochemical techniques, the distribution, nuclear parcellation, and potential topographic mingling of the noradrenergic and cholinergic pontine

neurons in two species of gray parrot and a one species of crow.

2 | MATERIALS AND METHODS

2.1 | Specimens

Brains were obtained from adult males from one Congo gray parrot (*Psittacus erithacus*), one Timneh gray parrot (*Psittacus timneh*), and one pied crow (*Corvus albus*) for use in the current study. The live birds were sourced from accredited facilities in South Africa. All birds showed no behavioral problems or stereotypies indicative of any neurological impairments. The birds used in this study were treated according to the guidelines of the University of Witwatersrand Animal Ethics Committee (Clearance number 2013/05/02B), which correspond with those of the NIH for care and use of animals in scientific experimentation. Five minutes prior to being euthanized, the birds were given an intramuscular dose of heparin (2500 units in 0.5 mL) to prevent blood clotting. The birds were then injected with an intraperitoneal dose of Euthapent (1 mL/kg). Following euthanasia, these birds were transcardially perfusion-fixed, initially with a rinse of 0.9% saline solution at a temperature of 4°C followed by 4% paraformaldehyde in 0.1 M phosphate buffer (PB) at 4°C. The brains, which showed no overt signs of neuropathology, were removed from the skull, weighed, and post-fixed in 4% paraformaldehyde in 0.1 M PB (24 h at 4°C) and allowed to equilibrate in 30% sucrose in 0.1 M PB before being stored in an antifreeze solution at −20°C until use (Manger et al., 2009).

2.2 | Sectioning and immunohistochemical staining

Blocks containing the brainstem were dissected from these brains, allowed to equilibrate in 30% sucrose in 0.1 M PB and then frozen in crushed dry ice. The frozen brain blocks were mounted to an aluminium stage and coronal sections of 50 μm thickness were cut using a sliding microtome. Brain blocks were sectioned in a coronal plane into 1 in 10 series of which four series were used in the current study. The remaining 6 series were placed in antifreeze solution and stored at −20°C for later use. The series of sections used in this study were stained for Nissl, myelin, and immunostained for tyrosine hydroxylase (TH) and choline acetyltransferae (see below). Sections used for Nissl staining were mounted on 0.5% gelatine coated glass slides, cleared in a solution of 1:1 chloroform and 100% alcohol overnight, after which the sections were stained with 1% cresyl violet. The series of sections used for myelin staining were refrigerated (4°C) for 2 weeks in 5% formalin then mounted on 1.0% gelatine coated slides and stained with a modified silver stain (Gallyas, 1979). The Nissl and myelin-stained sections were used to define the architecture of the pons and surrounding structures.

The series of sections used for TH and choline acetyltransferase (ChAT) immunohistochemistry were initially treated for 30 min with an endogenous peroxidase inhibitor (49.2% methanol: 49.2% 0.1 M PB: 1.6% of 30% H_2O_2), followed by three 10 min rinses in 0.1 M PB. Sections were then pre-incubated for 2 h, at room temperature, in blocking buffer (containing 3% normal goat serum, NGS, for TH immunostaining, or 3% normal rabbit serum, NRS, for ChAT immunostaining, plus 2% bovine serum albumin, BSA, and 0.25% Triton X-100 in 0.1 M PB). Thereafter sections were incubated in the primary antibody solution, made up of the appropriate dilution of the primary antibody (see below) in blocking buffer for 48 h at 4°C under gentle agitation. The primary antibody incubation was followed by three 10-min rinses in 0.1 M PB and the sections were then incubated in a secondary antibody solution (containing a 1:1000 dilution of biotinylated anti-rabbit IgG, BA 1000, Vector Labs, for TH immunostaining, or biotinylated anti-goat IgG, BA 5000, Vector Labs, for ChAT immunostaining, in a solution made up of 3% NGS/NRS and 2% BSA in 0.1 M PB) for 2 h at room temperature. This was followed by three 10-min rinses in 0.1 M PB, after which sections were incubated for 1 h in an avidin biotin solution (at a dilution of 1:125, Vector Labs), followed by three 10-min rinses in 0.1 M PB. Sections were then placed in a solution containing 0.05% diaminobenzidine (DAB) in 0.1 M PB for 5 min, followed by the addition of 3 μL of 30% H_2O_2 per 1 mL of solution. Chromatic precipitation was visually monitored under a low power stereomicroscope. Staining continued until the background stain was at a level that would allow for accurate architectonic delimitation without obscuring the immunopositive structures. Development was arrested by placing sections in 0.1 M PB, followed by two more rinses in this solution. Sections were then mounted on 0.5% gelatine coated glass slides, dried overnight, dehydrated in a graded series of alcohols, cleared in xylene and coverslipped with Depex. To test for nonspecific staining of the immunohistochemical protocol, in selected sections the primary antibody or the secondary antibody were omitted, which resulted in no staining of the tissue.

2.3 | Antibody characterization and specificity

2.3.1 | Tyrosine hydroxylase

To reveal the catecholaminergic neurons, that produce dopamine, noradrenaline or adrenalin, we used the AB151 anti-TH rabbit polyclonal antibody from Merck-Millipore (AB151, Merck-Millipore; RRID AB_10000323) at a dilution of 1:3000. As TH is the rate-limiting enzyme in the production of catecholamines, this antibody reliably identifies catecholaminergic neurons across a broad range of vertebrate species (e.g. Piskuric et al., 2011).

2.3.2 | Choline acetyltransferase

To reveal neurons that produce acetylcholine as a neurotransmitter, we used the AB144P anti-choline acetyltransferase goat polyclonal antibody from Merck-Millipore (AB144P, Merck-Millipore; RRID AB_2079751) at a dilution of 1:3000. This antibody reliably identifies cholinergic neurons in all regions of the brain across a range of vertebrate species (e.g. Kaiser et al., 2011; Laux et al., 2012).

2.4 | Anatomical reconstruction, microphotography, and nomenclature

A low power stereomicroscope was used to examine the Nissl and myelin-stained sections and camera lucida drawings outlining architectural borders were made. The associated TH and ChAT sections were matched to these drawings and the immunopositive neurons were marked. The drawings were then scanned and redrawn using the Canvas Draw X Draw drawing program (Canvas GFX, Inc., FL, USA). Digital photomicrographs were captured using an Axiocam 208 color camera mounted to a Zeiss Axioskop microscope (with Zeiss A-Plan 5X/012, Zeiss Plan-NeoFluar 10X/0.30, and Zeiss Plan-NeoFluar 40X/0.75 objectives). No pixilation adjustments, or manipulation of the captured images were undertaken, except for the adjustment of contrast, brightness, and levels using Adobe Photoshop. The neuroanatomical demarcations and nomenclature used in the current study was derived from Medina and Reiner (1994), Reiner et al. (2004), Izawa and Watanabe (2007), Brauth et al. (2011), Kersten et al. (2022) for the architectural delineations. The nomenclature applied to the pontine noradrenergic and cholinergic nuclei were derived from Dahlström and Fuxe (1964), Shiosaka et al. (1981), Kitt and Brauth (1986), Woolf (1991), Botjer (1992), Bailhache and Balthazart (1993), Moons et al. (1995), Montagnese and Csillag (1996), Mello et al. (1998), Roberts et al. (2001), Appeltants et al. (2001), Sen et al. (2019), Manger and Eschencko (2021), Kamkrathok and Chaiseha (2022), and Malungo et al. (2023).

3 | RESULTS

Immunohistochemical staining for TH and choline acetyltransferase revealed several catecholaminergic and cholinergic cell groups, or nuclei, respectively, within the pontine region of the brains of the two species of gray parrot and the pied crow investigated in the current study. While a significant number of catecholaminergic and cholinergic nuclei were revealed, our description here specifically focuses on the catecholaminergic (presumably noradrenergic, Moons et al., 1995) neurons forming the locus coeruleus complex (LoC) and the cholinergic neurons comprising the laterodorsal tegmental (LDT) and PPN nuclei, and the degree of independence and overlap in the distribution of neurons forming these nuclei (Figures 1–3). The descriptions provided below apply to all three species investigated except where noted. We employed a specifically "mammalocentric" approach to the description and nomenclature (see Section 2.4) applied to these nuclei to further our aim of comparing the anatomy of these nuclei between birds and mammals and their relationship to the similarities and differences in avian and mammalian sleep phenomenology (see Section 1). The pontine nuclei described herein are the adult derivatives of a subset of neurons emerging from the rhombomeres forming the isthmocerebellar or prepontine (Is, r1, r2), and pontine (r3, r4) regions of the developing brain (Watson et al., 2019).

3.1 | The locus coeruleus complex (LoC)

The LoCs in the birds investigated were comprised of three distinct, presumably homologous, nuclei, the locus coeruleus (A6), subcoeruleus (A7), and fifth arcuate nucleus (A5) (Figures 1–3). The TH immunoreactive (TH +) neurons found within the substantia grisea centralis, or periventricular gray matter, were assigned to the A6 nucleus, as often done with mammals (Manger & Eschencko, 2021). The A6 neurons were observed in the ventral lateral aspect of the periventricular gray matter, adjacent to the border of the gray matter with the adjacent pontine tegmentum (specifically the parvicellular reticular nucleus) (Figures 1–6). The TH+ neurons of the A6 formed a moderately dense cluster of strongly

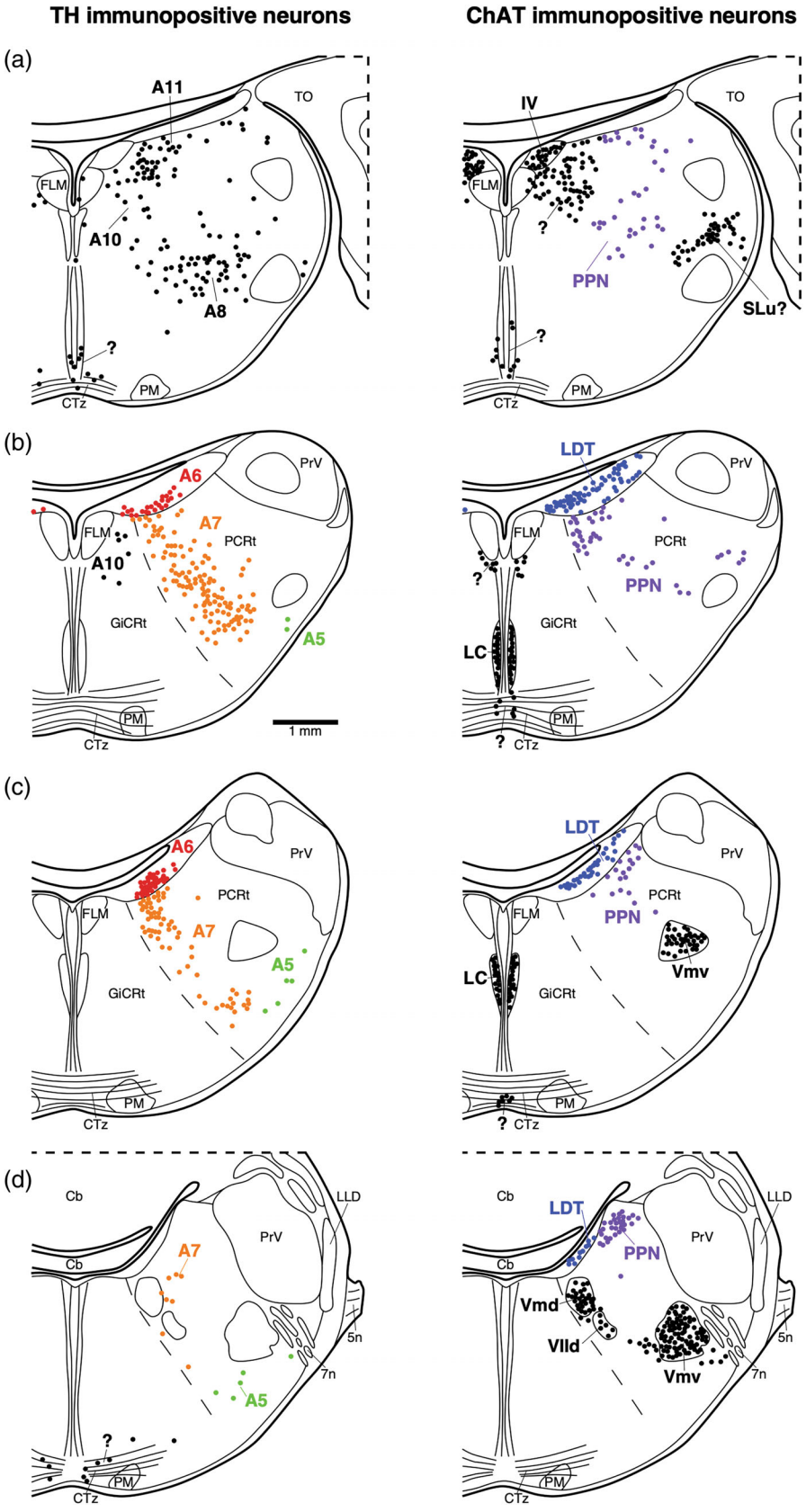

FIGURE 1 Serial drawings (a-d) of coronal sections through one half of the Congo gray parrot (*Psittacus erithacus*) pons from the caudal most level of midbrain through to the facial nerve nucleus showing the distribution of TH immunopositive neurons (left column) and choline acetyltransferase immunopositive neurons (right column). (a) is the most rostral section, (d) is the most caudal. The outlines of the architectonic regions were drawn from Nissl and myelin-stained sections. In the left column that represents the distribution of TH immunopositive neurons, those not forming part of the locus coeruleus complex are marked with black circles, while those forming specific subdivisions are marked with red circles (the A6, or locus coeruleus), orange circles (A7, or the subcoeruleus), or green circles (A5, or the fifth arcuate nucleus). In the right column that represents the distribution of ChAT immunopositive neurons, the neurons of the LDT nucleus are marked with blue circles, the neurons of the PPN are marked with purple circles, while other cholinergic neurons are marked with black circles. Each circle represents an individual neuron. The drawings are approximately 500 μm apart, and in each drawing dorsal is to the top and medial to the left. See list for abbreviations.

immunoreactive bipolar and multipolar neuronal types. While not showing an invariant dendritic orientation, the majority of the dendrites emanating from these A6 neurons evinced a roughly medio-lateral orientation running parallel to the gray matter/tegmentum border (Figures 4a,b, 5a,b, 6a,b).

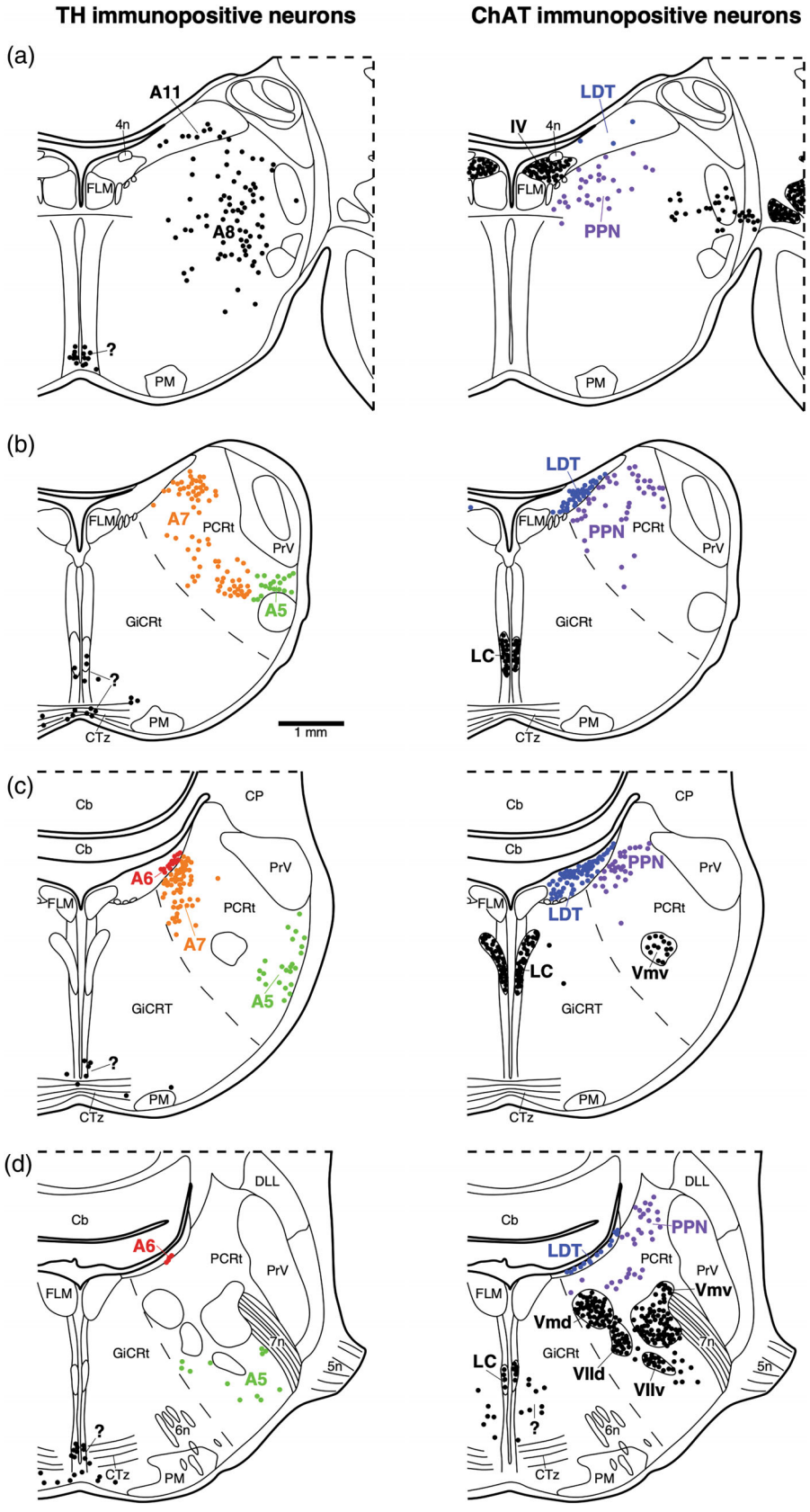

FIGURE 2 Serial drawings (a-d) of coronal sections through one half of the pied crow (*Corvus albus*) pons from the caudal most level of midbrain through to the facial nerve nucleus showing the distribution of TH immunopositive neurons (left column) and choline acetyltransferase immunopositive neurons (right column). (a) is the most rostral section, (d) the most caudal. The outlines of the architectonic regions were drawn from Nissl and myelin-stained sections. In the left column that represents the distribution of TH immunopositive neurons, those not forming part of the locus coeruleus complex are marked with black circles, while those forming specific subdivisions are marked with red circles (the A6, or locus coeruleus), orange circles (A7, or the subcoeruleus), or green circles (A5, or the fifth arcuate nucleus). In the right column that represents the distribution of ChAT immunopositive neurons, the neurons of the LDT nucleus are marked with blue circles, the neurons of the PPN are marked with purple circles, while other cholinergic neurons are marked with black circles. Each circle represents an individual neuron. The drawings are approximately 500 μm apart, and in each drawing dorsal is to the top and medial to the left. See list for abbreviations.

TH+ neurons assigned to the A7 nucleus were all located within the parvicellular reticular nucleus of the pontine tegmentum (Figures 1–6). In the two gray parrot species studied, the A7 was seen as distinct arc of neurons sweeping from the dorsomedial to the ventromedial aspect of the parvicellular reticular nucleus (Figures 1,

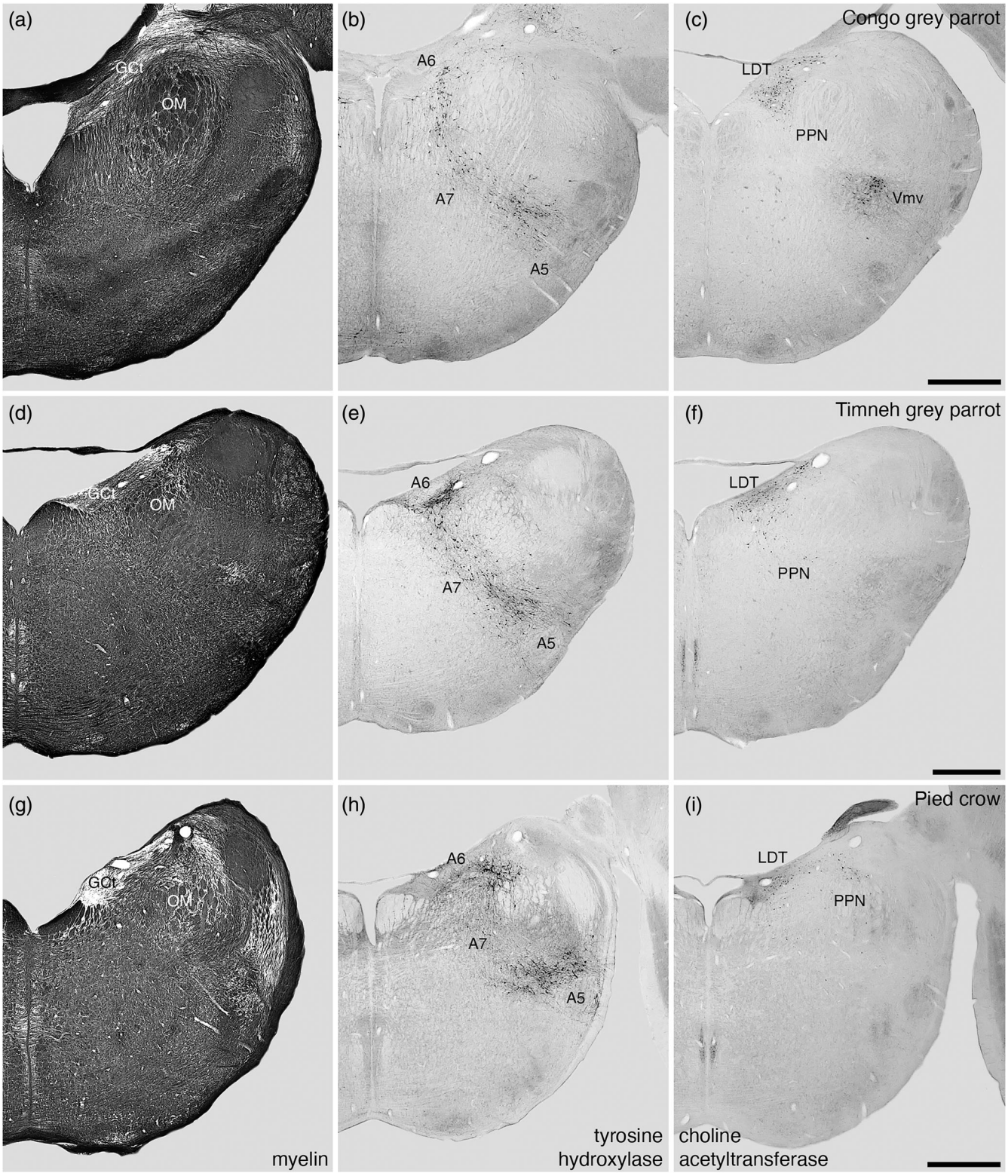

FIGURE 3 Low magnification photomicrographs of myelin (a, d, g), TH (b, e, h), and choline acetyltransferase (c, f, i) staining in coronal sections through the pontine region of the Congo gray parrot (*Psittacus erithacus*) (a–c), Timneh gray parrot (*Psittacus timneh*) (d–f), and the pied crow (*Corvus albus*) (g–i). These images show the location of the catecholaminergic (b, e, h) and cholinergic (c, f, i) neurons forming several distinct nuclei in this region of the brains of the birds studied including the A6, locus coeruleus; A7, subcoeruleus; A5, fifth arcuate nucleus; LDT, laterodorsal tegmental, and PPN, pedunculopontine tegmental nuclei in relation to the myeloarchitecture (a, d, g). Scale bar in c = 1 mm and applies to a–c. Scale bar in f = 1 mm and applies to d–f. Scale bar in i = 1 mm and applies to g–i. GCt, substantia grisea centralis; OM, occipito-mesencephalic tract.

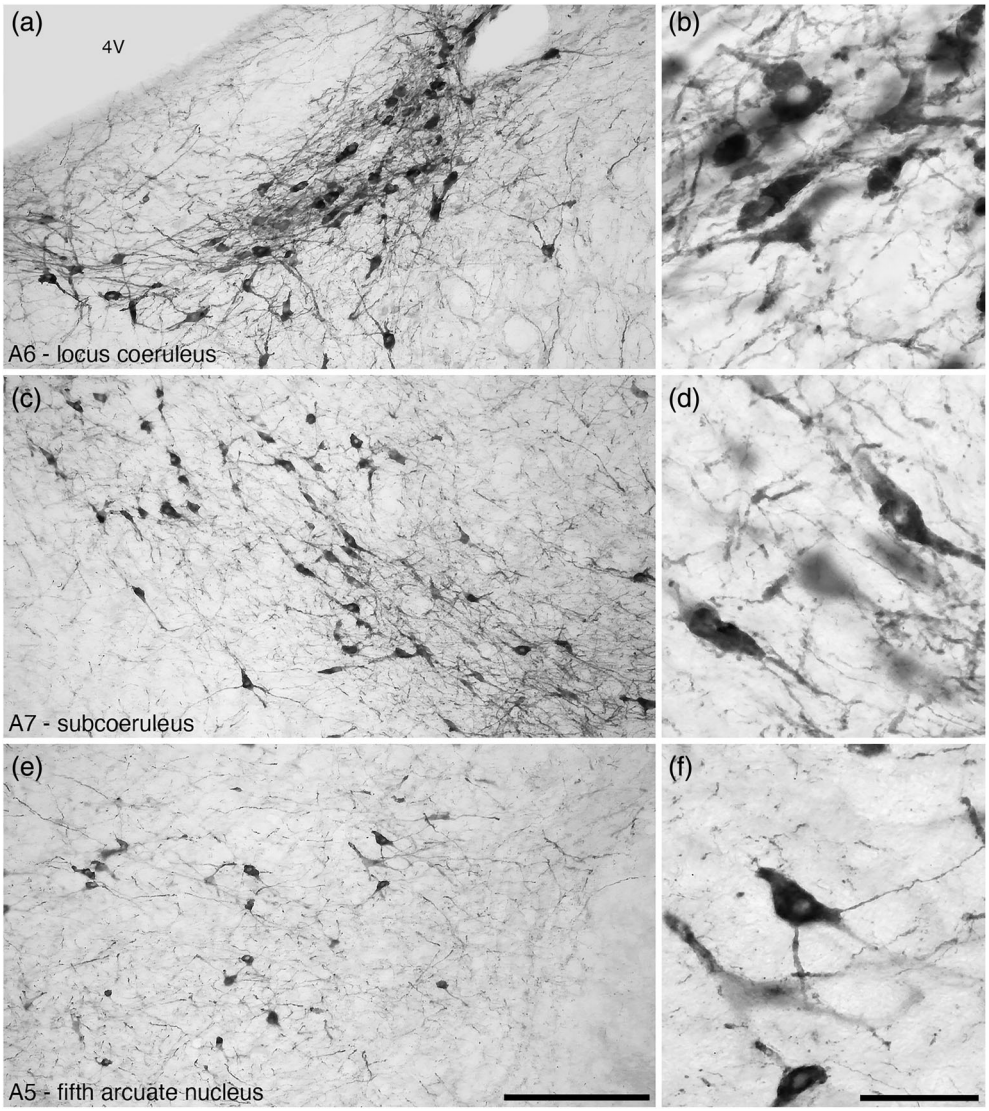

FIGURE 4 Moderate (a, c, e) and higher (b, d, e) magnification photomicrographs of TH immunoreactive neurons in the Congo gray parrot (*Psittacus erithacus*) pons. These images show the morphology of the neurons that form the A6 (locus coeruleus) (a, b), A7 (subcoeruleus) (c, d), and A5 (fifth arcuate nucleus) (e, f) nuclei comprising the locus coeruleus complex in this species of parrot. In all images dorsal is to the top and medial to the left. Scale bar in e = 250 μm and applies to a, c, e. Scale bar in f = 50 μm and applies to b, d, f. 4V, fourth ventricle.

3b,e, 4c, 5c). In the pied crow, while present, the A7 arc was not as distinct as observed in the gray parrots, perhaps due to the sectioning interval not revealing this neuronal arc as clearly as in the parrots, with a seemingly greater proportion of the neurons forming the A7 found ventrally within the parvicellular reticular nucleus (Figures 2, 3, 6c). In all species the strongly immunoreactive A7 neurons evinced both multipolar and bipolar types, with the latter being the majority (Figures 4c,d, 5c,d, 6c,d). The dendrites emanating from these neurons were primarily oriented in a mediodorsal to ventrolateral plane, aligned with the arc-like distribution of neurons forming this nucleus (Figures 4c,d, 5c,d, 6c,d).

The A5 nucleus was located ventral and ventrocaudal to the ventral border of the A7 nucleus in the ventrolateral aspect of the parvicellular reticular nucleus near the ventral surface of the brain (Figures 1–3). The strongly immunoreactive A5 neurons were a mix of multipolar and bipolar types, and unlike the adjacent A7 neurons, the dendrites emanating from the A5 neurons did not show a preferential orientation (Figures 4e,f, 5e,f, 6e,f).

3.2 | The cholinergic LDT and PPN nuclei

Immunostaining for choline acetyltransferase revealed neurons (ChAT+) that could be assigned to two distinct nuclei within the pontine region of the brains of the birds studied, the LDT and PPN nuclei (Figures 1–3, 7–9). The ChAT+ neurons assigned to the LDT were all located within the lateral aspect of the substantia grisea centralis, or periventricular gray matter, forming a distinct mediolaterally oriented column of neurons. These neurons occupied the middle of the periventricular gray matter, with the occasional neuron being observed immediately adjacent to the floor of the fourth ventricle, and some

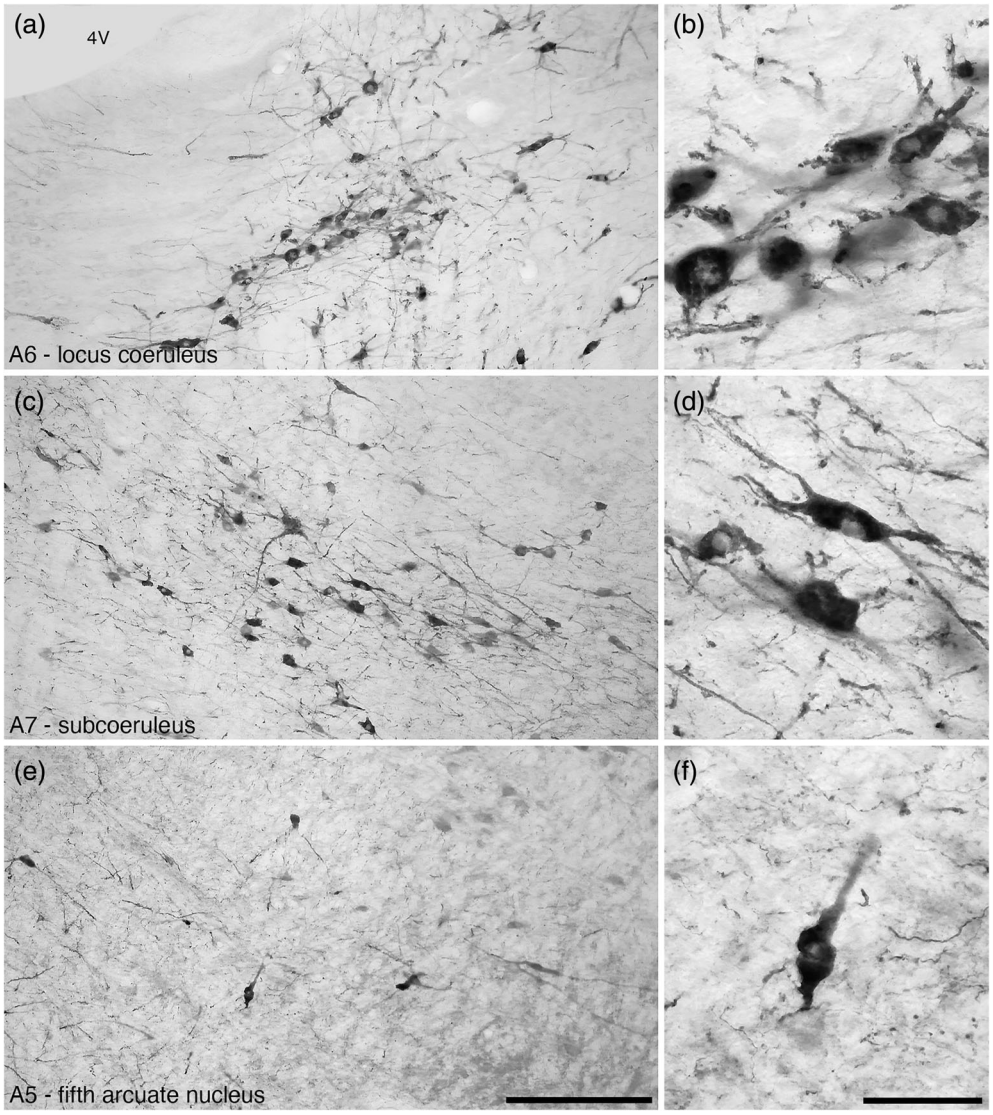

FIGURE 5 Moderate (a, c, e) and higher (b, d, e) magnification photomicrographs of TH immunoreactive neurons in the Timneh gray parrot (*Psittacus timneh*) pons. These images show the morphology of the neurons that form the A6 (locus coeruleus) (a, b), A7 (subcoeruleus) (c, d), and A5 (fifth arcuate nucleus) (e, f) nuclei comprising the locus coeruleus complex in this species of parrot. In all images dorsal is to the top and medial to the left. Scale bar in e = 250 μm and applies to a, c, e. Scale bar in f = 50 μm and applies to b, d, f. 4V, fourth ventricle.

scattered neurons being observed ventrally with the periventricular gray matter close to its border with the pontine tegmentum (Figures 1–3, 7a, 8a, 9a). The ChAT+ neurons assigned to the LDT were primarily multipolar, with the dendrites oriented in a roughly medio-lateral plane (Figures 7a,b, 8a,b, 9a,b).

The moderate density of ChAT+ neurons assigned to the PPN nucleus were restricted in their distribution to the dorsal third of the parvicellular reticular nucleus of the pontine tegmentum (Figures 1–3, 7–9). The PPN neurons in the rostral aspect of the nucleus were found close to the medial border of the parvicellular reticular nucleus. In sections taken progressively caudal, the PPN neurons were observed further lateral and abutting the cerebellar peduncle at their most caudal extent (Figures 1 and 2). Similar to the ChAT+ neurons of the LDT, the PPN neurons were mostly multipolar, although a substantive proportion of these neurons were also bipolar (Figures 7c,d, 8c,d, 9c,d).

3.3 | The complementary and overlapping distributions of LoC, LDT, and PPN nuclei

Due to the interactive nature of the effect of the noradrenergic and cholinergic neurons and the generation of REM sleep in mammals (Jones, 1991) and the complementary and overlapping distribution of these neurons in mammals (e.g., Jones, 1991; Malungo et al., 2023; Manger et al., 2002), we closely examined the distribution of these neurons in the birds investigated in the current study. Within the periventricular gray matter, the A6 and LDT neurons show a primarily complementary distribution (Figures 1, 2, 10), with the A6 neurons located at the border of the periventricular gray matter and the pontine tegmentum, while the neurons of the LDT were located dorsal to the A6 neurons; however, a small proportion of both neuronal types were intermingled (Figure 10). This intermingling of neuronal types was slightly more

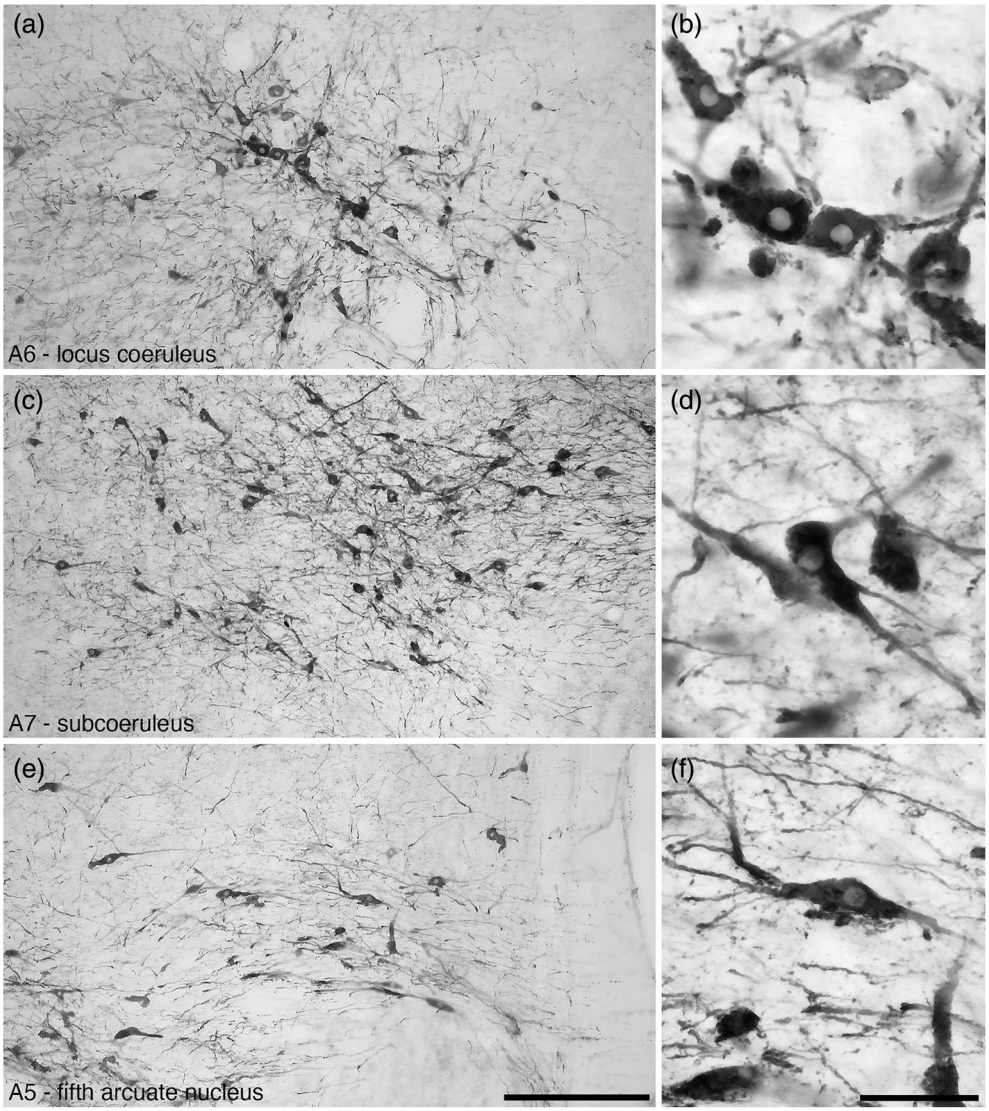

FIGURE 6 Moderate (a, c, e) and higher (b, d, e) magnification photomicrographs of TH immunoreactive neurons in the pied crow (*Corvus albus*) pons. These images show the morphology of the neurons that form the A6 (locus coeruleus) (a, b), A7 (subcoeruleus) (c, d), and A5 (fifth arcuate nucleus) (e, f) nuclei comprising the locus coeruleus complex in this species of crow. In all images dorsal is to the top and medial to the left. Scale bar in e = 250 μm and applies to a, c, e. Scale bar in f = 50 μm and applies to b, d, f.

prominent for the LDT neurons, with a greater number of these neurons being found within the A6 than A6 neurons being found in the LDT (Figure 10).

While both the A7 and PPN were found only within the parvicellular reticular nucleus, the amount of overlap of the noradrenergic and cholinergic neurons forming these nuclei was not as pronounced as observed for the A6 and LDT (Figures 1 and 2). The overlap was primarily found in the dorsal and rostral aspects of these nuclei, whereas more caudally the two neuronal types exhibited very little overlap (Figures 1 and 2). No overlap of noradrenergic A5 neurons with cholinergic neurons of the PPN was observed.

4 | DISCUSSION

The current study builds on current knowledge of the LoC and LDT/PPN in the avian brain (Appeltants et al., 2001; Bailhache & Balthazart, 1993; Botjer, 1992; González-Cabrera et al., 2015; Kamkrathok & Chaiseha, 2022; Kitt & Brauth, 1986; Medina & Reiner, 1994; Mello et al., 1998; Montagnese & Csillag, 1996; Moons et al., 1995; Reiner et al., 1994; Roberts et al., 2001; Sen et al., 2019; Shiosaka et al., 1981) through the study of additional species with significantly larger brains than those examined previously, and by using serial sections to examine the distribution of these neurons in relation to each other in the same individual bird. This was done specifically due to the observation in mammals that the generation of REM sleep is dependent on simultaneous cholinergic activation and noradrenergic suppression (Jones, 1991) and that REM sleep is a distinct avian sleep state (e.g., Lesku & Rattenborg, 2014; Rattenborg & Martinez-Gonzalez, 2015). Our results are compared to those reported in other birds and to mammals, and how the hypothetical activity of these neurons (based on mammalian studies) may be involved in avian sleep states.

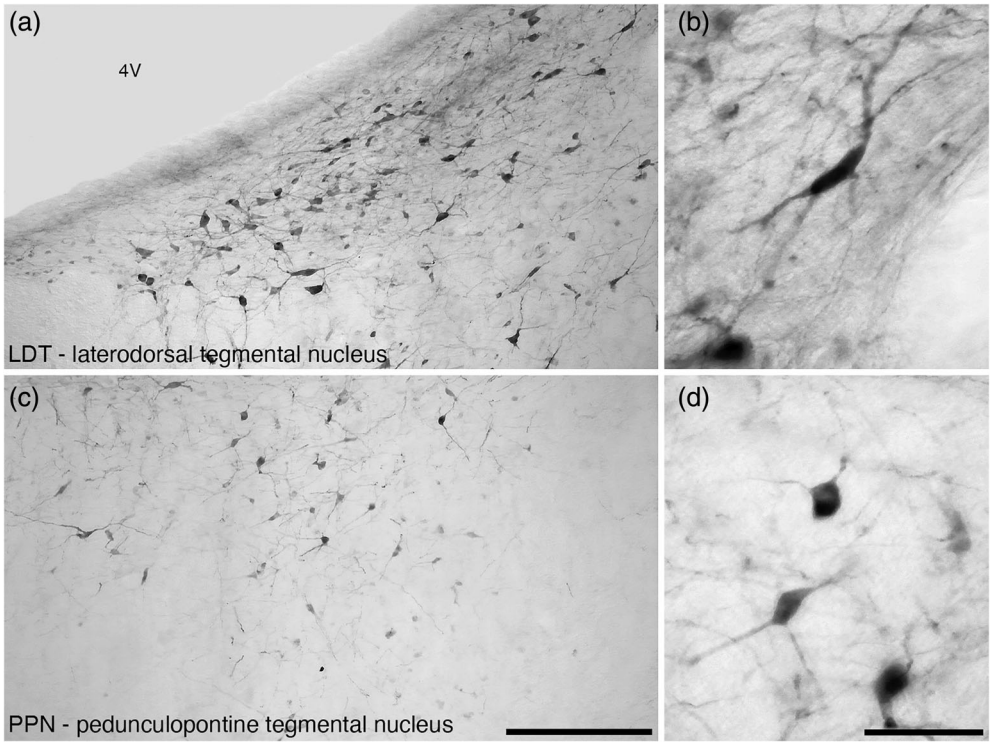

FIGURE 7 Moderate (a, c) and higher (b, d) magnification photomicrographs of choline acetyltransferase immunoreactive neurons in the Congo gray parrot (*Psittacus erithacus*) pons. These images show the morphology of the neurons that form the LDT nucleus (a, b), and the PPN (pedunculopontine tegmental nucleus) (c, d) nuclei comprising the pontine cholinergic complex in this species of parrot. In all images dorsal is to the top and medial to the left. Scale bar in c = 250 μm and applies to a, c. Scale bar in d = 50 μm and applies to b, d. 4V, fourth ventricle.

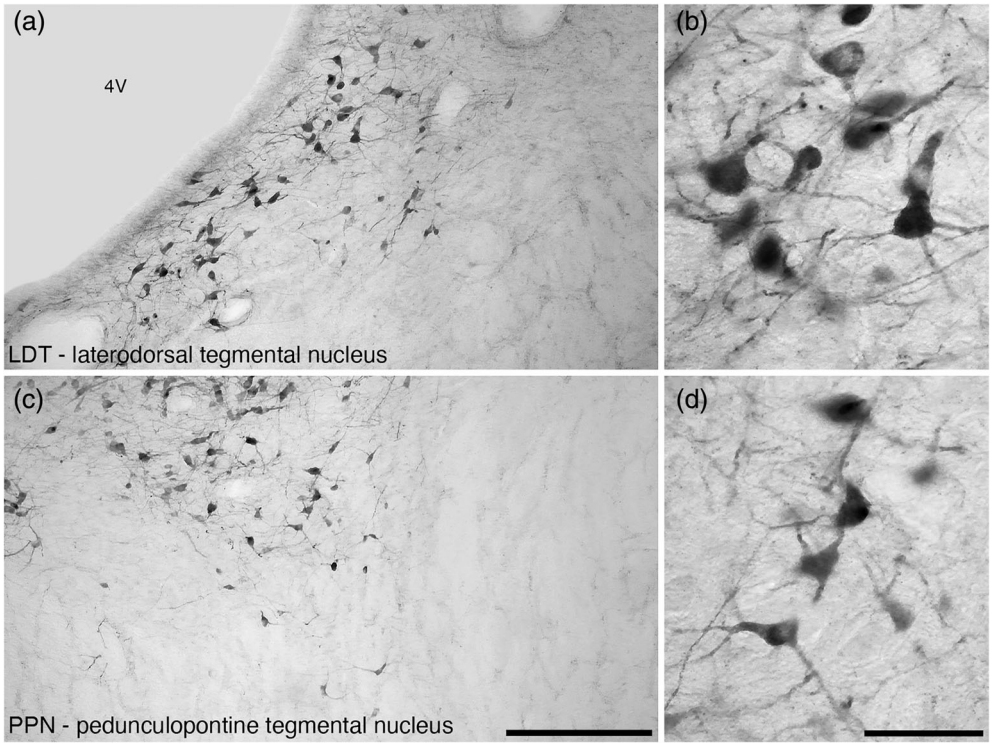

FIGURE 8 Moderate (a, c) and higher (b, d) magnification photomicrographs of choline acetyltransferase immunoreactive neurons in the Timneh gray parrot (*Psittacus timneh*) pons. These images show the morphology of the neurons that form the LDT nucleus (a, b), and the PPN (pedunculopontine tegmental nucleus) (c, d) nuclei comprising the pontine cholinergic complex in this species of parrot. In all images dorsal is to the top and medial to the left. Scale bar in c = 250 μm and applies to a, c. Scale bar in d = 50 μm and applies to b, d. 4V, fourth ventricle.

4.1 | Comparison of current findings to those previously reported for birds

Prior analyses of the avian brain with immunocytochemical markers that reveal the LoC and the LDT/PPN nuclei have been conducted on species that belong to the orders Psittaciformes (2 species), Columbiformes (1 species), Passeriformes (3 species), and Galliformes (2 species), with the birds previously investigated generally having small brains (to the exception of the house crow, Sen et al., 2019). The current study adds comprehensive mapping data of these important neuromodulatory pontine

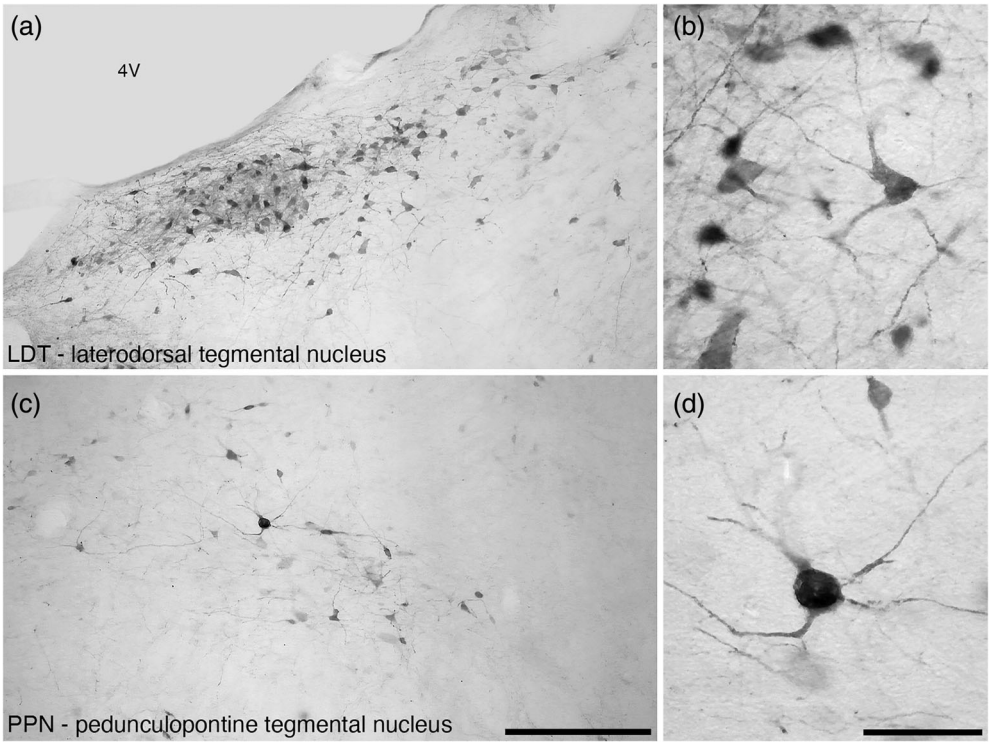

FIGURE 9 Moderate (a, c) and higher (b, d) magnification photomicrographs of choline acetyltransferase immunoreactive neurons in the pied crow (*Corvus albus*) pons. These images show the morphology of the neurons that form the LDT nucleus (a, b), and the PPN (pedunculopontine tegmental nucleus) (c, d) nuclei comprising the pontine cholinergic complex in this species of crow. In all images dorsal is to the top and medial to the left. Scale bar in c = 250 μm and applies to a, c. Scale bar in d = 50 μm and applies to b, d. 4V, fourth ventricle.

nuclei from three larger brained avian species, belonging to the orders Psittaciformes (Congo and Timneh gray parrots) and Passeriformes (pied crow). The general pattern of the neurons forming the LoC and LDT/PPN appears to be similar across avian species, but there are subtle differences that may be functionally important.

In terms of the LoC, in the current study we describe the presence of A6 (locus coeruleus, within the periventricular gray matter), A7 (subcoeruleus, within the pontine tegmentum), and A5 (fifth arcuate nucleus, within the ventrolateral pontine tegmentum) nuclei. In the parakeet (Shiosaka et al., 1981) and budgerigar (Roberts et al., 2001), species belonging to the Psittaciformes, the subdivisions of the LoC and the distribution of the neurons forming these subdivisions appear to be very similar to that observed in the two gray parrots examined in the current study. As described above, the A7 of the pied crow does not form as distinct a descending arc of neurons as found in the gray parrots (and other Psittaciformes), but the appearance of the A7 in the pied crow is very similar to that reported for the house crow (both species being within the order Passeriformes, family Corvidae), although in the house crow the A7 is referred to as the A6 (SCv), or subcoeruleus (Sen et al., 2019), thus there is a difference in nomenclature applied. This arrangement of the LoC into three distinct subdivisions appears to be consistent across the bird species studied to date, but there are minor variations (e.g., quail—Bailhache & Balthazart, 1993; chicken—Moons et al., 1995; Kamkrathok & Chaiseha, 2022; zebra finchMello et al., 1998). In the two gray parrots and the pied crow investigated in this study, we found no compelling evidence of the presence of an A4 (dorsolateral division of locus coeruleus) nucleus of the LoC, the presence of which appears to be variable across avian species (Smeets & González, 2000).

For LDT/PPN, the only study with which detailed comparisons can be made is that done in the pigeon by Medina and Reiner (1994), as the study of González-Cabrera et al. (2015) did not map these nuclei, show no images of the LDT, and only briefly indicate the location of the PPN. Medina & Reiner et al. (1994) report that the LDT is found in the periventricular gray matter, mainly dorsal to the neurons of the LoC, but with a small extent of overlap. Their description of the location of the PPN, in the isthmic tegmentum, is less detailed, but the depiction indicates that, like the LDT, the PPN in the pigeon and the two gray parrots and pied crow studied herein is very similar. Indeed, it appears that the manner in which the neurons that form the LoC and LDT/PPN nuclei in the pontine region of birds is quite similar across avian species, reflecting what has recently been described regarding the orexinergic system in birds (Mazengenya et al., 2024).

4.2 | Similarities of the LoC, LDT/PPN in birds and mammals

While anatomical and neurochemical similarities of neurons and nuclei do not necessarily mean functional

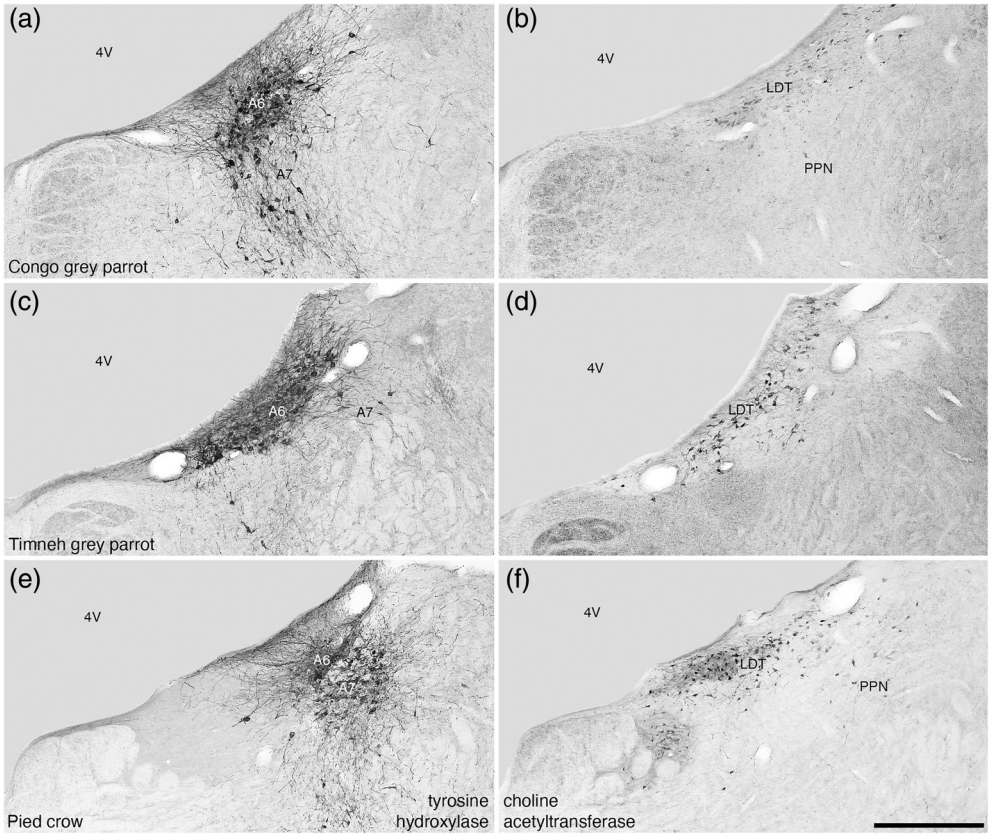

FIGURE 10 Low magnification photomicrographs of adjacent sections showing elements of the catecholaminergic (a, c, e) and cholinergic (b, d, f) nuclei within the pons of the Congo gray parrot (*Psittacus erithacus*) (a, b), Timneh gray parrot (*Psittacus timneh*) (c, d), and Pied crow (*Corvus albus*) (e, f). The neurons forming the catecholaminergic A6 (locus coeruleus) occupies the ventrolateral portion of the periventricular gray matter, while the neurons forming the LDT nucleus are found dorsal to the A6, occupying the mid-portion of the periventricular gray matter. Note that there is some mixture of these two cell types, especially LDT neurons spreading in a low density into the A6 region. The neurons forming the A7 (subcoeruleus) and PPN (pedunculopontine tegmental nucleus) are all located in the adjacent pontine tegmentum and show scattered overlap in distribution. In all images dorsal is to the top and medial to the left. Scale bar in f = 500 μm and applies to all. 4V, fourth ventricle.

analogy, they are strongly predictive. As outlined earlier (see Section 1), there are many physiological similarities when comparing avian and mammalian sleep states. These functional similarities then imply that the neural substrates initiating and maintaining sleep states are likely to be similar in species from each class.

Similarities in the anatomy and neurochemistry of the neurons forming the LoC complex in birds and mammals, based on the results of the current and previous investigations in birds and mammals (e.g., Manger & Eschencko, 2021) reveal the following similarities: (1) the neurons of the LoC, based on the presence of dopamine-ß-hydroxylase, share a noradrenergic neurochemistry (e.g., Imam et al., 2018; Moons et al., 1995; Moore & Gustafson, 1989); (2) all LoC neurons are found in the periventricular gray matter and adjacent pontine tegmentum; (3) LoC neurons are either multipolar or bipolar; (4) the A6 (locus coeruleus) neurons are found in the ventrolateral aspect of the periventricular gray matter; (5) the A7 (subcoeruleus) neurons are found exclusively within the parvicellular reticular nucleus, spanning much of the dorsoventral extent of the pontine tegmentum; and (6) the A5 (fifth arcuate nucleus) neurons are found ventrolateral to the A7 neurons in the ventrolateral aspect of the parvicellular reticular nucleus of the pontine tegmentum.

The neurons forming the LDT and PPN also show many similarities between birds (Medina & Reiner, 1994; current study) and mammals (e.g., Dell et al., 2010). In all avian and mammalian species studied to date: (1) all LDT and PPN neurons are cholinergic; (2) the neurons forming the LDT are found within the periventricular gray matter, specifically in the lateral aspect; (3) the neurons forming the PPN (also referred to as the PPT) are found exclusively within the parvicellular reticular nucleus of the pontine tegmentum; and (4) the neurons are either multipolar or bipolar. The last similarity of note is the combined adjacency and mingling of the

neurons forming the A6 and LDT in the periventricular gray matter, a feature noted in the birds in which both neuronal types have been studied in the same individual (current study) and in several mammalian species previously (e.g., Jones, 1991; Malungo et al., 2023; Manger et al., 2002).

4.3 | Differences in the LoC, LDT/PPN in birds and mammals

The similarities between these neurochemical types, their distribution and parcellation between birds and mammals, while extensive, also reveal some specific differences. While a far greater number of mammalian species have been studied compared to birds, there appears to be greater diversity in the appearance of the LoC and LDT/PPN in mammals than what has been observed in birds to date. There is no clear evidence of an A4 in the LoC of the birds studied to date, but the presence of this nucleus in mammals is also variable across species (Manger & Eschencko, 2021). In mammals the parcellation, distribution and packing density of A6 neurons, while mostly resembling what is seen in the birds studied to date, also reveal variations in parcellation, distribution and packing density in Murid rodents (but not other rodent species), megachiropteran bats, primates, and African elephants (Manger & Eschencko, 2021), while the A6 neurons appear to be absent in pangolins (Imam et al., 2018). In all mammals studied, the A7 (subcoeruleus) can be parcellated into a compact (high density of neurons in the dorsal parvicellular reticular nucleus adjacent to the periventricular gray matter) and a diffuse (lower density throughout the remainder of the parvicellular reticular nucleus) subdivision. No clear evidence for this compact and diffuse A7 parcellation has been observed in the birds studied to date.

When comparing birds and mammals, there appears to be a distinct difference in the distribution of the PPN neurons throughout the parvicellular reticular nucleus. As noted in the current study and by Medina and Reiner (1994), the majority of the cholinergic neurons forming the PPN of birds are found in the dorsal and lateral aspects of the parvicellular reticular nucleus. In mammals while cholinergic neurons are found in these regions of the parvicellular reticular nucleus, they are also found throughout the ventral and lateral aspects of the parvicellular reticular nucleus (e.g., Dell et al., 2010; Williams et al., 2021; Woolf, 1991). Thus, the distributional overlap between A7 and PPN neurons appears to be more extensive in mammals than in birds. In two species of mammals, the rock hyrax and river hippopotamus additional variations in the LDT and PPN have been noted. In the rock hyrax smaller cholinergic neurons are found surrounding and intermingling with the more typically observed larger cholinergic neurons forming these nuclei (Gravett et al., 2009). This variation in pontine cholinergic neurons co-occurs with an unusual sleep state in the rock hyrax (Gravett et al., 2012). In the river hippopotamus, similar smaller cholinergic neurons are found in the LDT (Dell et al., 2016), but it is not yet known if any unusual sleep states are present in the hippopotamus. Such variations have not been noted in the avian species studied to date.

4.4 | Pontine control of sleep in birds

When comparing the physiological features of sleep in birds and mammals, several similarities and differences are noted (see Section 1). It is known that the noradrenergic and cholinergic neurons of the pontine region are centrally involved in the generation of sleep states in mammals (e.g., Jones, 1991). The extensive similarities in the anatomical distribution, neurochemistry, and parcellation of the LoC and LDT/PPN in birds and mammals, as well as the orexinergic system (Mazengenya et al., 2024), indicates that the generation of the similarities in sleep physiology in the two vertebrate classes are likely to have similar neuronal control systems. Evidence supporting this concept has been provided for the serotonergic system in birds (Fuchs et al., 2006). While, based on our current knowledge, this is a reasonable conclusion, we again emphasize that single unit recordings of noradrenergic, pontine cholinergic, and orexinergic neurons have not yet been undertaken in birds, an important gap in our knowledge for understanding the generation of seemingly similar sleep states in these two vertebrate classes.

In addition to the similarities and the homology/analogy of these pontine nuclei in birds and mammals, the differences in sleep physiology and these nuclei is just as important to understand. In this sense, detailing the organization of these pontine (and indeed other sleep-related neurons) in birds that reveal unusual sleep states (such as ostriches, Lesku et al., 2011), and across a broader range of avian species may reveal important variances that not only help to understand avian sleep, but mammalian sleep, and vertebrate sleep more broadly. We note here that the neurochemistry of the LoC and LDT/PPN investigated herein is quite limited, to a single neurotransmitter type, although it is known that the LoC of chickens does have additional neurochemical features (von Bartheld et al., 1995). Recent molecular studies have revealed that mouse LoC neurons can produce over 20 different types of neuropeptide and express over 30 types of neuropeptide

receptors (Caramia et al., 2023), indicating a far greater functional capacity of these neurons than previously known. It would be of interest to undertake similar studies of avian (and indeed other vertebrates) LoC neurons to reveal the similarities and variances in the potential to generate different neuropeptides and express different receptors. Such a study could indicate the degree to which these homologous neurons are also analogous, especially in terms of sleep as one of the biological imperatives of vertebrate life.

AUTHOR CONTRIBUTIONS

Pedzisai Mazengenya: Conceptualization; investigation; funding acquisition; writing – original draft; methodology; validation; visualization; writing – review and editing; formal analysis; project administration. **Paul R. Manger:** Conceptualization; investigation; funding acquisition; writing – original draft; methodology; validation; visualization; writing – review and editing; formal analysis; supervision.

ACKNOWLEDGMENTS

No acknowledgements to declare.

FUNDING INFORMATION

This work was supported by an Ajman University Research Grant: 2022-IRG-MED-3 (PM).

CONFLICT OF INTEREST STATEMENT

The authors declare no conflicts of interest.

DATA AVAILABILITY STATEMENT

Data have not been shared due to this study being based on histological sections.

ORCID

Pedzisai Mazengenya https://orcid.org/0000-0003-4733-1563

Paul R. Manger https://orcid.org/0000-0002-1881-2854

REFERENCES

Appeltants, D., Ball, G. F., & Balthazart, J. (2001). The distribution of tyrosine hydroxylase in the canary brain: Demonstration of a specific and sexually dimorphic catecholaminergic innervation of the telencephalic song control nuclei. *Cell and Tissue Research*, *304*, 237–259. https://doi.org/10.1007/s004410100360

Bailhache, T., & Balthazart, J. (1993). The catecholaminergic system of the quail brain: Immunocytochemical studies of dopamine ß-hydroxylase and tyrosine hydroxylase. *Journal of Comparative Neurology*, *329*, 230–256. https://doi.org/10.1002/cne.903290206

Botjer, S. W. (1992). The distribution of tyrosine hydroxylase immunoreactivity in the brains of male and female zebra finches. *Journal of Neurobiology*, *24*, 51–69. https://doi.org/10.1002/neu.480240105

Brauth, S. E., Heaton, J. T., Roberts, T. F., & Liang, W. (2011). *Budgerigar brain atlas*. http://www.brauthlab.umd.edu/atlas.htm

Caramia, M., Romanov, R. A., Sideromenos, S., Hevesi, Z., Zhao, M., Krasniakova, M., Xu, Z.-Q. D., Harkany, T., & Hökfelt, T. G. M. (2023). Neuronal diversity of neuropeptide signaling, including galanin, in the mouse locus coeruleus. *Proceedings of the National Academic of Sciences of the United States of America*, *120*, e2222095120. https://doi.org/10.1073/pnas.2222095120

Dahlström, A., & Fuxe, K. (1964). Evidence for the existence of monoamine-containing neurons in the central nervous system. Demonstration of monoamines on the cell bodies of the brain stem neurons. *Acta Physiologica Scandinavica*, *62*, 1–55.

Dell, L.-A., Kruger, J.-L., Bhagwandin, A., Jillani, N. E., Pettigrew, J. D., & Manger, P. R. (2010). Nuclear organization of cholinergic, putative catecholaminergic and serotonergic systems in the brains of two megachiropteran species. *Journal of Chemical Neuroanatomy*, *40*, 177–195. https://doi.org/10.1016/j.jchemneu.2010.05.008

Dell, L.-A., Patzke, N., Spocter, M. A., Bertelsen, M. F., Siegel, J. M., & Manger, P. R. (2016). Organization of the sleep-related neural systems in the brain of the river hippopotamus (*Hippopotamus amphibius*): A most unusual cetartiodactyl species. *Journal of Comparative Neurology*, *524*, 2036–2058. https://doi.org/10.1002/cne.23930

Fuchs, T., Sigel, J. J., Burgdorf, J., & Bingman, V. P. (2006). A selective serotonin reuptake inhibitor reduces REM sleep in the homing pigeon. *Physiology & Behavior*, *87*, 575–581. https://doi.org/10.1016/j.physbeh.2005.12.003

Gallyas, F. (1979). Silver staining of myelin by means of physical development. *Neurological Research*, *1*, 203–209. https://doi.org/10.1080/01616412.1979.11739553

González-Cabrera, C., Garrido-Charad, F., Roth, A., & Marín, G. J. (2015). The isthmic nuclei providing parallel feedback connections to the avian tectum have different neurochemical identities: Expression of glutamatergic and cholinergic markers in the chick (*Gallus gallus*). *Journal of Comparative Neurology*, *523*, 1341–1358. https://doi.org/10.1002/cne.23739

Gravett, N., Bhagwandin, A., Fuxe, K., & Manger, P. R. (2009). Nuclear organization and morphology of cholinergic, putative catecholaminergic and serotonergic neurons in the brain of the rock hyrax, *Procavia capensis*. *Journal of Chemical Neuroanatomy*, *38*, 57–74. https://doi.org/10.1016/j.jchemneu.2009.02.005

Gravett, N., Bhagwandin, A., Lyamin, O. I., Siegel, J. M., & Manger, P. R. (2012). Sleep in the rock hyrax, *Procavia capensis*. *Brain, Behavior and Evolution*, *79*, 155–169. https://doi.org/10.1159/000335342

Imam, A., Bhagwandin, A., Ajao, M. S., Ihunwo, A. O., Fuxe, K., & Manger, P. R. (2018). Brain of the tree pangolin (*Manis tricuspis*). III. The unusual locus coeruleus complex. *Journal of Comparative Neurology*, *526*, 2570–2584. https://doi.org/10.1002/cne.24519

Izawa, E.-I., & Watanabe, S. (2007). A stereotaxic atlas of the brain of the jungle crow (*Corvus macrorhynchos*). In *Integration of comparative neuroanatomy and cognition* (pp. 215–273). Keio University Press.

Jones, B. E. (1991). The role of noradrenergic locus coeruleus neurons and neighboring cholinergic neurons of the pontomesencephalic tegmentum in sleep-wake states. *Progress in Brain*

Research, *88*, 533–543. https://doi.org/10.1016/s0079-6123(08)63832-7

Kaiser, A., Alexandrova, O., & Grothe, B. (2011). Urocortin-expressing olivocochlear neurons exhibit tonotopic and developmental changes in the auditory brainstem and in the innervation of the cochlea. *Journal of Comparative Neurology*, *519*, 2758–2778. https://doi.org/10.1002/cne.22650

Kamkrathok, B., & Chaiseha, Y. (2022). Distribution of dopamine-immunoreactive neurons in the brain of the male native Thai chicken. *Folia Histochemica et Cytobiologica*, *60*(1), 1–12. https://doi.org/10.5603/FHC.a2022.0008

Kersten, Y., Freidrich-Müller, B., & Nieder, A. (2022). A brain atlas of the carrion crow (*Corvus corone*). *Journal of Comparative Neurology*, *530*, 3011–3038. https://doi.org/10.1002/cne.25392

Kitt, C. A., & Brauth, S. E. (1986). Telencephalic projections from midbrain and isthmal cell groups in the pigeon. I. Locus coeruleus and subcoeruleus. *Journal of Comparative Neurology*, *247*, 69–91. https://doi.org/10.1002/cne.902470105

Lai, Y. Y., Kodama, T., & Siegel, J. M. (2001). Changes in monoamine release in the ventral horn and hypoglossal nucleus linked to pontine inhibition of muscle tone: An *in vivo* microdialysis study. *Journal of Neuroscience*, *21*, 7384–7391. https://doi.org/10.1523/JNEUROSCI.21-18-07384.2001

Laux, A., Delalande, F., Mouheiche, J., Stuber, D., van Dorsselaer, A., Bianchi, E., Bezard, E., Poisbeau, P., & Goumon, Y. (2012). Localization of endogenous morphine-like compounds in the mouse spinal cord. *Journal of Comparative Neurology*, *520*, 1547–1561. https://doi.org/10.1002/cne.22811

Lesku, J. A., Meyer, L. C., Fuller, A., Maloney, S. K., Dell'Omo, G., Vyssotski, A. L., & Rattenborg, N. C. (2011). Ostriches sleep like platypuses. *PLoS One*, *6*, e23203. https://doi.org/10.1371/journal.pone.0023203

Lesku, J. A., & Rattenborg, N. C. (2014). Avian sleep. *Current Biology*, *24*, R12. https://doi.org/10.1016/j/cub.2013.10.005

Malungo, I. B., Mokale, R., Bertelsen, M. F., & Manger, P. R. (2023). Cholinergic, catecholaminergic, serotonergic, and orexinergic neuronal populations in the brain of the lesser hedgehog tenrec (*Echinops telfairi*). *Anatomical Record*, *306*, 844–878. https://doi.org/10.1002/ar.25092

Manger, P. R., & Eschencko, O. (2021). The mammalian locus coeruleus complex – Consistencies and variances in nuclear organization. *Brain Sciences*, *11*, 1486. https://doi.org/10.3390/brainsci11111486

Manger, P. R., Fahringer, H. M., Pettigrew, J. D., & Siegel, J. M. (2002). The distribution and morphological characteristics of serotonergic cells in the brain of monotremes. *Brain, Behavior and Evolution*, *60*, 315–332. https://doi.org/10.1159/000067194

Manger, P. R., Pillay, P., Maseko, B. C., Bhagwandin, A., Gravett, N., Moon, D. J., Jillani, N., & Hemingway, J. (2009). Acquisition of brains from the African elephant (*Loxodonta africana*): Perfusion-fixation and dissection. *Journal of Neuroscience Methods*, *179*, 16–21. https://doi.org/10.1016/j/jneumeth.2009.01.001

Mazengenya, P., Spocter, M. A., & Manger, P. R. (2024). Nuclear parcellation and numbers of orexinergic neurons in five species of larger brained birds. *Journal of Comparative Neurology*, *532*, e25602. https://doi.org/10.1002/cne.25602

Medina, L., & Reiner, A. (1994). Distribution of choline acetyltransferase immunoreactivity in the pigeon brain. *Journal of Comparative Neurology*, *342*, 497–537. https://doi.org/10.1002/cne.903420403

Mello, C. V., Pinaud, R., & Ribeiro, S. (1998). Noradrenergic system of the zebra finch brain: Immunocytochemical study of dopamine-ß-hydroxylase. *Journal of Comparative Neurology*, *400*, 207–228. https://doi.org/10.1002/(SICI)1096-9861(19981019)400:2<207::AID-CNE4>3.0.CO;2-D

Montagnese, C. M., & Csillag, A. (1996). Comparative distribution of NADPH-diaphorase activity and tyrosine hydroxylase immunoreactivity in the diencephalon and mesencephalon of the domestic chicken (*Gallus domesticus*). *Anatomy and Embryology*, *193*, 427–439. https://doi.org/10.1007/BF00185874

Moons, L., D'Hondt, E., Pijcke, K., & Vandesande, F. (1995). Noradrenergic system in the chicken brain: Immunocytochemical study with antibodies to noradrenaline and dopamine-ß-hydroxylase. *Journal of Comparative Neurology*, *360*, 331–348. https://doi.org/10.1002/cne.903600210

Moore, R. Y., & Gustafson, E. L. (1989). The distribution of dopamine-beta-hydroxylase, neuropeptide Y and galanin in locus coeruleus neurons. *Journal of Chemical Neuroanatomy*, *2*, 95–106.

Osorio-Forero, A., Cherrad, N., Banterle, L., Fernandez, L. M., & Lüthi, A. (2022). When the locus coeruleus speaks up in sleep: Recent insights, emerging perspectives. *International Journal of Molecular Sciences*, *23*, 5028. https://doi.org/10.3390/ijms23095028

Pace-Schott, E. F., & Hobson, J. A. (2002). The neurobiology of sleep: Genetics, cellular physiology and subcortical networks. *Nature Reviews Neuroscience*, *3*, 591–605. https://doi.org/10.1038/nrn895

Piskuric, N. A., Vollmer, C., & Nurse, C. A. (2011). Confocal immunofluorescence study of rat aortic body chemoreceptors and associated neurons *in situ* and *in vitro*. *Journal of Comparative Neurology*, *519*, 856–873. https://doi.org/10.1002/cne.22553

Rattenborg, N. C., & Martinez-Gonzalez, D. (2015). Avian versus mammalian sleep: The fruits of comparing apples and oranges. *Current Sleep Medicine Reports*, *1*, 55–63. https://doi.org/10.1007/s40675-014-0001-9

Rattenborg, N. C., Martinez-Gonzalez, D., Roth, T. C., 2nd, & Pravosudov, V. V. (2011). Hippocampal memory consolidation during sleep: A comparison of mammals and birds. *Biological Reviews of the Cambridge Philosophical Society*, *86*, 658–691. https://doi.org/10.1111/j.1469-185X.2010.00165.x

Reiner, A., Karle, E. J., Anderson, K. D., & Medina, L. (1994). Catecholaminergic perikaryal and fibers in the avian nervous system. In *Phylogeny and development of catecholamine systems in the CNS of vertebrates* (pp. 135–181). Cambridge University Press.

Reiner, A., Perkel, D. J., Bruce, L. L., Butler, A. B., Csillag, A., Kuenzel, W., Medina, L., Paxinos, G., Shimizu, T., Striedter, G., Wild, M., Ball, G. F., Durand, S., Güntürkün, O., Lee, D. W., Mello, C. V., Powers, A., White, S. A., Hough, G., & Kubikova, L. (2004). Revised nomenclature for avian telencephalon and some related brainstem nuclei. *Journal of Comparative Neurology*, *473*, 377–414. https://doi.org/10.1002/cne.20118

Roberts, T. F., Cookson, K. K., Heaton, K. J., Hall, W. S., & Brauth, S. E. (2001). Distribution of tyrosine hydroxylase-containing neurons and fibers in the brain of the budgerigar (*Melopsittacus undulatus*): General patterns and labelling in

vocal control nuclei. *Journal of Comparative Neurology*, *429*, 436–454. https://doi.org/10.1002/1096-9861(20010115)429:3<436::aid-cne6>3.0.co;2-h

Scriba, M. F., Ducrest, A. L., Henry, I., Vyssotski, A. L., Rattenborg, N. C., & Roulin, A. (2013). Linking melanism to brain development: Expression of a melanism-related gene in barn owl feather follicles covaries with sleep ontogeny. *Frontiers in Zoology*, *10*, 42. https://doi.org/10.1186/1742-9994-10-42

Sen, S., Parishar, P., Pundir, A. S., Reiner, A., & Iyengar, S. (2019). The expression of tyrosine hydroxylase and DARPP-32 in the house crow (*Corvus splendens*) brain. *Journal of Comparative Neurology*, *527*, 1801–1836. https://doi.org/10.1002/cne.24649

Shein-Idelson, M., Ondracek, J. M., Loaw, H.-P., Reiter, S., & Laurent, G. (2016). Slow waves, sharp waves, ripples, and REM in sleeping dragons. *Science*, *352*, 590–595. https://doi.org/10.1126/science.aaf3621

Shiosaka, S., Takatsuki, K., Inagaki, S., Sakanaka, M., Takagi, H., Senba, E., Matsuzako, T., & Tohyama, M. (1981). Topographic atlas of somatostatin-containing neuron system in the avian brain in relation to catecholamine-containing neuron system. II. Mesencephalon, rhombencephalon, and spinal cord. *Journal of Comparative Neurology*, *202*, 115–124. https://doi.org/10.1002/cne.902020110

Siegel, J. M. (2004). The neurotransmitters of sleep. *The Journal of Clinical Psychiatry*, *65*(Suppl. 16), 4–7.

Siegel, J. M. (2022). Sleep function: An evolutionary perspective. *Lancet Neurology*, *21*, 937–946. https://doi.org/10.1016/S1474-4422(22)00210-1

Smeets, W. J. A. J., & González, A. (2000). Catecholamine systems in the brain of vertebrates: New perspectives through a comparative approach. *Brain Research Reviews*, *33*, 308–379. https://doi.org/10.1016/s0165-0173(00)00034-5

Steriade, M., Paré, D., Datta, S., Oakson, G., & Curró Dossi, R. (1990). Different cellular types in mesopontine cholinergic nuclei related to ponto-geniculo-occipital waves. *Journal of Neuroscience*, *10*, 2560–2579. https://doi.org/10.1523/JNEUROSCI.10-08-02560.1990

Tobler, I., & Borbély, A. A. (1988). Sleep and EEG spectra in the pigeon (*Columba livia*) under baseline conditions and after sleep-deprivation. *Journal of Comparative Physiology A*, *163*, 729–738. https://doi.org/10.1007/BF00604050

Ungurean, G., & Rattenborg, N. C. (2022). A mammal and bird's-eye-view of the pupil during sleep and wakefulness. *European Journal of Neuroscience*, *59*, 584–594. https://doi.org/10.1111/ejn.15983

van der Meij, J., Martinez-Gonzalez, D., Beckers, G. J. L., & Rattenborg, N. C. (2019). Intra-"cortical" activity during avian non-REM and REM sleep: Variant and invariant traits between birds and mammals. *Sleep*, *42*, zsy230. https://doi.org/10.1093/sleep/zsy230

von Bartheld, C. S., Schober, A., Kinoshita, Y., Williams, R., Ebendal, T., & Bothwell, M. (1995). Noradrenergic neurons in the locus coeruleus of birds express TrkA, transport NGF, and respond to NGF. *Journal of Neuroscience*, *15*, 2225–2239. https://doi.org/10.1523/JNEUROSCI.15-03-02225.1995

Watson, C., Bartholomaeus, C., & Puelles, L. (2019). Time for radical changes in stem nomenclature – Applying the lessons from developmental gene patterns. *Frontiers in Neuroanatomy*, *13*, 10. https://doi.org/10.3389/fnana.2019.00010

Williams, V. M., Bhagwandin, A., Swiegers, J., Bertelsen, M. F., Hård, T., Sherwood, C. C., & Manger, P. R. (2021). Distribution of cholinergic neurons in the brains of a lar gibbon and a chimpanzee. *Anatomical Record*, *305*, 1516–1535. https://doi.org/10.1002/ar.24844

Woolf, N. J. (1991). Cholinergic systems in mammalian brain and spinal cord. *Progress in Neurobiology*, *37*, 475–524. https://doi.org/10.1016/0301-0082(91)90006-m

How to cite this article: Mazengenya, P., & Manger, P. R. (2025). Nuclear parcellation of pontine catecholaminergic and cholinergic neurons in gray parrots and pied crow brains. *The Anatomical Record*, *308*(9), 2433–2449. https://doi.org/10.1002/ar.25593