

https://dspace.org/

Whole body post-mortem computed tomography versus skeletal survey in the detection of fractures in suspected cases of fatal non-accidental injury

Prince, Daniel Nicholas

2021
https://hdl.handle.net/10539/33623

Downloaded from a DSpace repository. https://dspace.org/

Whole body post-mortem computed tomography versus skeletal survey in the detection of fractures in suspected cases of fatal non-accidental injury

Dr Daniel Nicholas Prince (examination candidate and first author)

Dr Halvani Moodley (co-author)

Prof Jeanine Vellema (co-author)

A final research report submitted to the Faculty of Health Sciences, University of the Witwatersrand, Johannesburg, in partial fulfilment of the requirements for the degree of Master of Medicine in Diagnostic Radiology

2021

Declaration:

I, Daniel Nicholas Prince, declare that this research report is my own work. It is being submitted for the degree of MMed (Diagnostic Radiology) at the University of the Witwatersrand, Johannesburg. It has not been submitted before for any degree or examination at this or any other University.

Signed:



4 October 2021

Joint Declaration by Examination Candidate and Co-Authors:

4 October 2021

The Postgraduate Office

Faculty of Medicine

University of the Witwatersrand

To Whom It May Concern:

Re: Dr Daniel Prince's role as primary author for his MMed Diag. Rad. article

This is a joint declaration by all the authors that Dr Daniel Nicholas Prince is the primary author for this paper is based on him being an MMed student who was responsible for generating the entire manuscript for his project, selecting and post processing the images and captions, summarising the statistical analysis findings, as well as performing and updating the literature review.

The co - authors (study supervisor and co – supervisor) edited the manuscript.

Yours sincerely,



Dr Daniel Nicholas Prince

Radiology MMed Candidate

Department of Radiology

Chris Hani Baragwanath Hospital

University of the Witwatersrand



Dr Halvani Moodley

MMed Supervisor of Dr Daniel Prince

Head of Unit: Paediatric Radiology

Department of Radiology

Charlotte Maxeke Johannesburg Academic Hospital

University of the Witwatersrand



Professor Jeanine Vellema

MMed Co-Supervisor of Dr Daniel Prince

Head Clinical Department

Gauteng Forensic Pathology Service Southern Cluster

Department of Forensic Medicine and Pathology

University of the Witwatersrand

Dedication:

I dedicate this paper to the children unfortunate enough to have been a part of this study. Your deaths will surely help – in some small way – to bring justice to other young victims of abuse.

Acknowledgements:

Thank you to:

- Prof Jeanine Vellema. Without you, this study would quite literally not have been possible.
- Dr Halvani Moodley for guiding me so patiently through the research process and showing me that it is possible for an MMed to be more than just a requirement to pass – it can be exciting and have a real impact on local and global practice.
- All those radiographers at Charlotte Maxeke Johannesburg Academic Hospital who were willing to assist with advancing the practice of forensic imaging in that institution and in South Africa.

Table of Contents:

Declaration: 2
Joint Declaration by Examination Candidate and Co-Authors: 3
Dedication: 5
Acknowledgements: 6
Authors Guidelines for the Intended Journal (Clinical Radiology): 8
Draft Article: 9
Title Page: 9
Abstract: 11
Blinded Manuscript: 13
Introduction: 13
Materials and methods: 15
Results: 16
Discussion: 17
Tables: 22
Figures: 23
References 31
Highlights: 35
Approved Research Protocol: 36
Appendices: 51
Appendix A: Ethics Clearance Certificate 52
Appendix B: Plagiarism Declaration 53
Appendix C: Turnitin Report Cover Page 54
Appendix D: Clinical Radiology Author Information Pack 59

Authors Guidelines for the Intended Journal (Clinical Radiology):

This article will be submitted to *Clinical Radiology*.

Summary of guidelines for Original Papers:

- Maximum 4000 words.
    - No more than 10 illustrations (tables and figures).
    - Figures:
        - Minimum 300 dpi.
        - Captions to be separate from illustrations.
- Continuous line numbering.
- The journal utilises “double anonymized review”.
    - Title page with author details:
        - Title.
        - Author names and affiliations.
        - Corresponding author details.
        - Present/permanent address.
    - Blinded manuscript with no author details:
        - Unnumbered sections:
            - Introduction.
            - Materials and methods.
            - Results.
            - Discussion.
            - References:
                - Numbered in order of appearance in text.
        - Abstract:
            - Maximum 250 words.
        - Keywords.
        - Highlights in a separate document.

See Appendix D – “Clinical Radiology Author Information Pack” for full details.

Draft Article:

Title Page:

Title:

Whole body post-mortem computed tomography versus skeletal survey in the detection of fractures in suspected cases of fatal non-accidental injury.

Authors names and affiliations:

Dr Daniel Nicholas Prince, FC Rad Diag (SA), MBBCh [a, b]

Dr Halvani Moodley, FC Rad Diag (SA), MMed Diag Rad, MBChB [a, c]

Prof Jeanine Vellema, FC For Path (SA), MBBCh [d]

[a] Department of Diagnostic Radiology, Faculty of Health Sciences, University of the Witwatersrand, 7 York Road, Parktown, Johannesburg, Gauteng, South Africa, 2193

[b] Department of Diagnostic Radiology, Chris Hani Baragwanath Academic Hospital, 26 Chris Hani Road, Diepkloof, Soweto, Gauteng, South Africa, 1864.

[c] Department of Diagnostic Radiology, Charlotte Maxeke Johannesburg Academic Hospital, 7 York Road, Parktown, Johannesburg, Gauteng, South Africa, 2193

[d] Department of Forensic Medicine and Pathology, University of the Witwatersrand, 7 York Road, Parktown, Johannesburg, Gauteng, South Africa, 2193

Corresponding author:

Daniel Nicholas Prince.

Email address - dan.n.prince@gmail.com

Present/permanent address:

Daniel Nicholas Prince; Department of Diagnostic Radiology, Chris Hani Baragwanath Academic Hospital, 26 Chris Hani Road, Diepkloof, Soweto, Gauteng, South Africa, 1864.

Acknowledgments:

The authors gratefully acknowledge the radiographers, registrars and radiologists in the department who perform post-mortem imaging. Maryn Viljoen is acknowledged for providing support with the statistical analysis of the data.

Author contributions:

1 guarantor of integrity of the entire study HM
2 study concepts and design HM, JV
3 literature research DP, HM
4 clinical studies DP, HM
5 experimental studies HM
6 statistical analysis MV
7 manuscript preparation DP
8 manuscript editing HM, JV

Role of the funding source:

This research did not receive any specific grant from funding agencies in the public, commercial, or not-for-profit sectors.

Conflicts of interests:

None.

Abstract:

AIM: To compare post-mortem computed tomography (PMCT) and post-mortem skeletal survey (PMSS) in the detection and analysis of fractures in suspected cases of fatal non-accidental injury (NAI).

MATERIALS AND METHODS: A prospective study of consecutive PMCTs was performed over a year at a tertiary hospital in Johannesburg, South Africa. All decedents underwent whole body PMCT and PMSS and were reviewed by a paediatric radiologist.

RESULTS: There were twenty decedents, 9 males (45%) and 11 females (55%) and the median age 24 months. Fractures were detected in 7/20 (35%) decedents. Five had fractures recorded on both modalities: two cranial fractures and one fracture each of the humerus, radius and ulna. One had a tibial metaphyseal corner fracture detected only on PMSS, others had two mandibular, a pubic ramus and iliac crest fracture detected solely on PMCT. There was no significant difference in the number of fractures detected in all regions, the specificity of fractures locations for NAI or fracture dating. PMCT acquisition time was faster than PMSS (median time: 4.75 and 27.63 minutes respectively) [$p < 0.0001$].

CONCLUSION: We describe the first use of paediatric PMCT in South Africa in investigating suspected fatal NAI and compare it to PMSS. Whilst there was no significant difference in the number of fractures detected, PMCT proved useful in analysing the complexity of cranial fractures and uncommon fractures of the facial and pelvic bones. PMCT is acquired faster with increased radiographer satisfaction. Larger multicentre prospective studies are required to validate these results.

Keywords:

Child abuse

Forensic imaging

Fractures

Metaphyseal corner fracture

NAI – non-accidental injury

PMCT – post-mortem computed tomography

PMSS – post-mortem skeletal survey

Post-mortem imaging

Blinded Manuscript:

**Note that the final manuscript for submission to the journal requires continuous line numbering. This will be added in the final submission to the journal, but the software used in compiling this document did not allow for only a section of the document to have continuous line numbers.*

Whole body post-mortem computed tomography versus skeletal survey in the detection of fractures in suspected cases of fatal non-accidental injury

Introduction:

Paediatric post-mortem imaging is a relatively new subspeciality, gaining popularity in Europe and more recently in the USA (1–3). The use of post-mortem skeletal surveys (PMSS), post-mortem CT (PMCT) and post-mortem MRI in first world countries has been explored globally (1,2,4–6). Despite the highest rates of child abuse being accounted for by the World Health Organization (WHO) African region and with South Africa having a child homicide rate of 6.6 per 100 000 (over double that of the United States), there is scarcely research on the role and validation of forensic imaging in the paediatric population in South Africa (7,8).

All non-natural deaths in South Africa undergo a medicolegal post-mortem examination according to the Inquests Act of 1959 (9). This is usually carried out by a forensic pathologist at one of the state Forensic Pathology Service (FPS) laboratories. This examination consists of an autopsy and any other special investigations deemed appropriate by the forensic medical practitioner (10). At autopsy, the entire skeleton is not routinely dissected for examination as this would be impractical, and therefore radiological techniques are used to examine the skeleton non-invasively (2,11).

In cases of suspected non accidental-injury (NAI) it has been shown that up to 52% of children will have sustained fractures (12). Using radiological techniques, it is possible to characterise and document these injuries for later use in legal proceedings. Post-mortem skeletal survey (PMSS) is considered the current standard and adjunct to autopsy in our setting.

Recently in an unpublished South African retrospective study, Wessels *et al*. investigated the spectrum of radiographic findings in and utility of PMSS in cases of suspected fatal NAI in a Johannesburg paediatric population (13). They found that PMSS was useful in detecting occult fractures in the upper limbs in 27% and lower limbs in 21.7% of decedents with high specificity

fracture locations for NAI found in 27,7 %. Acute fractures were detected in 51.5% of cases, 48.5% had healing fractures and 15.2% had chronic fractures (13). Despite the utility of PMSS in the South African setting as demonstrated in this study as well as globally in several others, there are challenges experienced with PMSS (1).

A thorough PMSS is time-consuming and requires careful radiographic technique. All the radiographs need to be reviewed by a consultant radiologist (ideally one with paediatric and/or post-mortem imaging experience) before the decedent leaves the radiology department to ensure that all the necessary views have been performed, whether any additional views need to be taken, and that the radiographs are of adequate diagnostic quality (1,10).

Performing these post-mortem studies comes with unique challenges. If the imaging is performed within 12-24 hours after death, rigor mortis can make appropriate positioning of the decedent difficult (1). These studies are performed on deceased children, which by its nature is an upsetting task and some advocate for counselling services to be offered to those performing forensic imaging (14,15). Not only are there psychological risks associated with performing PMSS, but there are physical hazards such as the radiographers and mortuary attendants potentially being exposed to bodily fluids and other harmful pathogens during positioning, as well as the ionising radiation generated by the X-ray unit (15).

It has been shown internationally that skeletal surveys in both the living and the dead frequently do not comply with the standardised guidelines stipulated by the British Society of Paediatric Radiology (BSPR) and the American College of Radiology (ACR) in terms of adequate number of views and the technical quality of the images taken (16–18). Despite it being our departmental protocol to perform PMSS according to the modified Red Cross War Memorial Children's Hospital guidelines (Table 1), it has been shown previously that at our institution, 71.2% of studies have inadequate views and 75% show inadequate positioning of the decedent (13).

Forensic PMCT is not a new concept and was first used in 1977 in a case of fatal gunshot wounds to the head (19). In 2014 a survey found that 51% of European Society of Paediatric Radiology (ESPR) member institutions performed PMCT (20). There are concerted efforts globally to formulate standardised post-mortem imaging protocols and guide the practice of post-mortem cross-sectional imaging, with the European Society of Paediatric Radiology (ESPR) recently forming a dedicated task-force to address these issues (19,21). Attempts are being made to employ standardised terminology when publishing research on forensic imaging

(1,22). PMCT is an attractive tool in the investigation of NAI in that the usual problems of trying to minimise radiation and motion artefact in children are not considerations, thus higher-dose and higher-resolution protocols can be implemented to improve image quality (1). CT has been shown to be superior to radiography in the detection of rib fractures (23–27). It is also able to demonstrate more skull fractures than radiography (28–30).

There is very little published literature from South Africa on post-mortem imaging despite our extremely high incidence of homicide (7,8).The unpublished study by Wessels *et al.* found that PMSS in the South African setting is a valuable adjunct to autopsy and recommended that PMSS be performed in suspected fatal NAI cases at least in children up to 24 months of age (13). The only other published South African study regarding PMCT by Combrinck and Jansen van Vuuren investigated its utility in adult head trauma following assault and found it to be a useful adjunct to autopsy especially in diagnosing skull fractures (31).

There are no prospective studies directly comparing fracture detection rates in whole body PMCT versus PMSS. No studies involving PMCT in paediatric patients have been carried out in South Africa. Therefore, this study aimed to compare the fracture detection rates of PMCT with PMSS in suspected cases of fatal NAI in a tertiary hospital in South Africa. The specificity of fracture locations for NAI and fracture dating were also compared on these modalities (17,12).

Materials and methods:

In this prospective study, all decedents less than 18 years old referred to Charlotte Maxeke Johannesburg Academic Hospital from the Forensic Pathology Service, Southern Gauteng Cluster, for the period between 1 August 2019 and 31 July 2020 were recruited consecutively. These decedents were all suspected by the forensic pathologist to have been victims of fatal NAI.

All study participants first underwent a non–contrast whole body PMCT using either a 64 slice (Brilliance CT) or 128 slice (Ingenuity CT) scanner *(Philips Medical Systems, Best, the Netherlands)*. The decedents were positioned supine on the CT gantry with arms placed beside the body and were scanned in the body bags.

The PMCT protocol was adapted from the Society of Pediatric Radiology (SPR) Guidelines for post-mortem scanning (32).

The decedents were scanned in two stages – first the head and neck (120 kV, 110 – 250 mAs, 1 mm slice thickness, pitch 0.6) followed by the chest, abdomen, pelvis and limbs contiguously (140 kV, 400 mAs, 1 mm slice thickness, pitch 0.4). Scans were then reconstructed by the radiographers using both soft tissue and bone algorithms.

A routine PMSS was then immediately performed on each participant as per the modified Red Cross War Memorial Children's Hospital guidelines (Table 1).

Only one decedent's age was not known and therefore a bone age analysis was performed by the reader using the standards of Gilsanz and Ratib to estimate the age (33).

The reader (a paediatric radiologist with 4 years' experience) who was blinded to the decedents' identities other than sex and age, reported the PMSS and a month later the PMCT to minimise bias. Multiplanar reconstruction (MPR) and 3D volume rendering were used to aid in scan interpretation.

Data analysis was performed using SAS Version 9.2 (*Cary, North Carolina, USA*). Descriptive statistics, namely frequencies and percentages, were calculated for categorical data, and means and standard deviations or medians and percentiles were calculated for numerical data. Categorical variables were summarised by calculating frequencies and percentages. To compare the findings of the PMSSs and PMCTs, the Fisher's Exact Test was used to compare percentages of the two groups, and the independent T-test (or Mann-Whitney U-test) was used to compare mean (or median) values. McNemar's test was used to compare the PMSS and PMCT findings. A significance level (α) of 0.05 was used.

Ethical clearance was obtained from the Wits Human Research Ethics Committee (HREC number M181132).

Results:

A total of 20 decedents were included in the study with ages ranging from 3 months to 10 years and a median age of 24 months. The study population demographics and fractures types detected on PMSS and PMCT are summarised in Figure 1.

When comparing PMSS with PMCT, there was no statistically significant difference in the number of fractures detected in all regions ($p = 0.1573$ to $p = 1.0000$).

There were 2 decedents with cranial fractures. Both the fractures were detected on PMSS and PMCT but PMCT showed more fracture lines per patient than PMSS: 5 vs. 3 in one decedent and 4 vs. 1 in the other ($p = 0.2048$). In the latter case, PMSS demonstrated a simple linear fracture of the occipital bone, but the same fracture was deemed complex on PMCT due to the identification of additional fractures of the left temporal bone and diastasis of the left lambdoid suture (Figure 2). This fracture was therefore diagnosed as a moderate specificity fracture location for NAI on PMCT in contrast to the low specificity fracture location on PMSS.

Overall, the specificity of the fracture locations for NAI was compared and no statistically significant difference was found between PMSS and PMCT ($p = 0.1573$ to $p = 1.0000$). There was also no statistically significant difference in the dating of fractures using PMSS versus PMCT ($p = 0.1573$ to $p = 1.0000$).

PMCT demonstrated some extra findings including two decedents with scalp haematomas, one with a subdural haematoma, one with cerebral cystic encephalomalacia and a case with calcified mediastinal nodes. An additional finding recorded on both PMSS and PMCT was a decedent with a florid periosteal reaction of the right clavicle with no fracture line.

The time between the first image and the last image taken of each study was used to approximate the acquisition times of the scans. The acquisition time for the PMCT (median time 4.758 minutes; SD 1.486) was significantly faster than for the PMSS (median time 27.633 minutes; SD 11.944) ($p < 0.0001$).

Discussion:

The median age of the decedents in this study was 24 months which is in agreement with figures reported internationally and in South Africa (7,13,34). There were slightly more girls than boys, as described in international literature, however there was a male predominance in a similar local population previously (13,35). No statistically significant difference was found between these two groups.

The number of decedents with fractures present (35%) is lower than that found by Wessels *et al.* (45.2%) who studied the same population over a different period. Our study cohort showed a different fracture profile than previously found. Common fracture sites such as the ribs, cited as the most common bones fractured in the Wessels study, were not found in our cohort (13). It was also an unusual finding that there were more uncommon fractures in our study, such as the mandibular and pelvic fractures whereas in the Wessels study these fractures were not

encountered. This could be due to the comparatively smaller sample size in this study (20 vs. 73 decedents) (13). Alternatively this may indicate an evolving pattern of fractures since the earlier study or possibly a change in the type and level of violence of those perpetrating the NAI.

The two mandible fractures were not identified on PMSS but detected on PMCT. Due to the multiple overlapping structures on the lateral and AP skull views on the PMSS, these non-displaced fractures may have been obscured making them difficult to detect (Figure 3). Mandible fractures in NAI are uncommon possibly due to the morphologic characteristics of the paediatric face and when present, were found to involve the condyles more than other parts of the mandible in keeping with our findings (36).

Both pelvic fractures present on the one decedent were not detected on PMSS but were identified on PMCT (Figure 4). Pelvic fractures are uncommonly encountered on PMSS done in living patients and when present they are moderately specific for NAI and are associated with sexual abuse (13,25,37). PMCT makes the identification of these uncommon fractures easier with the added capability of MPR and 3D reconstructions as well as negating the problem of overlapping anatomy, bowel gas and gas secondary to putrefaction which may cause artefacts on radiographs.

PMCT and PMSS were equally effective in revealing cranial fractures. PMCT however demonstrated the fractures in greater detail, a finding corroborated by studies showing that CT is superior to radiography in evaluating cranial fractures (28–30). The ability of PMCT to show cranial fractures allows for increased reader confidence in evaluating the fractures. In a courtroom setting, an anticipated benefit of PMCT is that the radiologist providing testimony can exhibit both 2D images (Figure 5), 3D reconstructions and even 3D printed models of the decedents' injuries (38). This would allow for better understanding of such injuries by lay people and the legal fraternity who may not understand medical terminology.

A metaphyseal corner fracture of a tibia was detected on PMSS but not on PMCT (Figure 6). This was the only fracture present on this decedent and because metaphyseal corner fractures are so highly specific for NAI, the detection of these fractures is paramount. Shelmerdine *et al.* postulated that good quality radiographs may be more sensitive for these fractures than CT (3). Reader inexperience with PMCT in general and specifically the appearance of metaphyseal corner fractures on PMCT may also have been a factor here (1,13). MPR and 3D volumetric reconstruction around the larger joints of the upper and lower limbs can the aid detection of

these injuries on PMCT. The incidence of metaphyseal corner fractures in our population is low therefore larger scale studies, as advocated by us and other authors, are required to evaluate this (13,1).

When we compared the ability of each modality to classify fractures into either "low", "moderate" or "high" specificity fracture locations for NAI, we found no significant difference. This may be because of the small sample size and because certain low-specificity fractures were not detected on PMSS and that the only highly specific fracture (i.e., the metaphyseal corner fracture) was not identified on PMCT. Wessels *et al.* found that over a quarter of decedents studied had fractures that were highly specific for NAI whereas only one decedent in this smaller study population had such a fracture (13).

Although fracture dating has been described as an "inexact science" by Prosser *et al*., being able to classify a fracture as acute or chronic is very important since multiple fractures of varying ages are highly suggestive of NAI (12,39). The 3 upper limb fractures detected on both modalities were all dated according to presence or absence of periosteal reaction. Although there was no statistically significant difference in the dating of these fractures using either modality (Figure 7), the ability of PMCT to demonstrate bridging callus and periosteal reactions to aid in dating fractures has not been published previously and is a finding which needs to be further examined. PMCT may assist in improved fracture dating for cases with subtle non-displaced fractures of the cortex by clearly delineating any associated periosteal reaction, as in our case of an acute ulna diaphyseal fracture (Figure 8).

Our preliminary experience with PMCT in our resource constrained setting, highlights not only the above anticipated benefits but also the challenges of a fledgeling forensic imaging service, similar to those encountered internationally (1,40).

The radiographers interviewed by the authors reported that the process of PMCT scanning was preferable to PMSS in that there was far less time spent acquiring the images and there was minimal interaction with the decedent. The physical and emotional challenges associated with the meticulous positioning of the decedent necessary for a good quality PMSS were obviated. This resulted in increased radiographer willingness to performing the post-mortem imaging.

There are benefits for the reporting radiologist as well. PMCT may obviate the need for a consultant radiologist to approve the quality of each view on PMSS and the repeating of radiographic views when required in the case of initial inadequate views. Decedents may also be discreetly scanned at any time rather than waiting for a dedicated in-office- hours slot when

a radiology consultant is available to approve the PMSS views. The time taken to acquire the studies was also significantly shorter. These two advantages could increase the throughput of post-mortem imaging cases in the radiology department resulting in reduction of unnecessary delays in the performance of the forensic autopsies awaiting imaging prior to autopsy. The reporting radiologist would also be more confident in interpreting fractures of the cranium and other regions which would normally be obscured by overlapping structures – such as the mandible and the pelvis – as we have seen in this study. One major disadvantage reported by the study reader, however, was the increased time required for the radiologist to reconstruct and read large CT data sets compared to shorter times for reporting on PMSS which have much smaller data sets.

Despite these benefits, there appears to be a steep learning curve associated with PMCT interpretation in the absence of formal training as was also reported by Gould *et al.* (1). Internationally, PMCTs are usually read by experienced paediatric radiologists (1).There are very few paediatric radiologists in South Africa therefore practically these studies may have to be read by general radiologists, with the exception of a few subspecialist centres. This leads a lack of subspeciality expertise in paediatric and/or forensic imaging reporting. This can potentially be overcome by offering forensic imagining training to radiology trainees, specifically regarding the post-mortem changes that can mimic pathology (41). Multidisciplinary meetings with forensic pathologists, radiologists and radiographers may be beneficial (1). Collaboration with colleagues from around the world with more extensive paediatric forensic imaging experience would be invaluable as well.

Further challenges in implementing this study were encountered from institutional management, as corroborated by Gould *et al*. (1). The general argument put forward was that in a resource-poor setting such as South Africa, was it possible to justify performing additional expensive imaging at a state hospital on deceased patients when there are considerable waiting times for living patients awaiting scans? Moreover, in our setting there has been a longstanding challenge in attracting radiographers for funded forensic imaging posts. Gould *et al*. found similar issues with underfunding of forensic services but with the added problem of post-mortem imaging not being reimbursed by health insurers (1).

Study limitations:

Limitations of this study included a small sample size with a single reader. The reader is a paediatric radiologist who has experience reading skeletal surveys in living and deceased

patients but no prior PMCT experience. The decedents in this study were only suspected of being victims of fatal NAI and the causes of death as determined at autopsy were not included as part of the study. Furthermore, the time intervals from death to imaging were not available.

Conclusion:

We have described the first use of paediatric PMCT in South Africa in investigating suspected fatal NAI and compared it to PMSS findings. Whilst there was no statistically significant difference in the number of fractures detected in all regions, PMCT proved useful in detecting the complexity of skull fractures and uncommon fractures of the facial and pelvic bones, which may be harder to detect on PMSS. PMCT is acquired faster with increased radiographer satisfaction. Larger multicentre prospective studies are required in our resource-limited setting before PMCT can be routinely recommended.

Tables:

Table 1: Radiographic skeletal survey views (adapted from Red Cross War Memorial Children's Hospital Guidelines [1]):

Head	**AP and lateral skull**
Spine	Cervical spine (AP and lateral)
	Thoracic spine (lateral)
	Lumbosacral spine (lateral)
Chest	AP
	Bilateral oblique rib views
Abdomen	Pelvis (AP), to include mid lumbar spine
Upper and lower limbs	AP (centre on joints)
	Hands (AP)
	Feet (AP)
	Lateral views of knees, ankles, wrists and elbows [2]
[1] CT head is performed in living children according to these guidelines	
[2] Additional views are added at the discretion of the radiologist	

Figures:

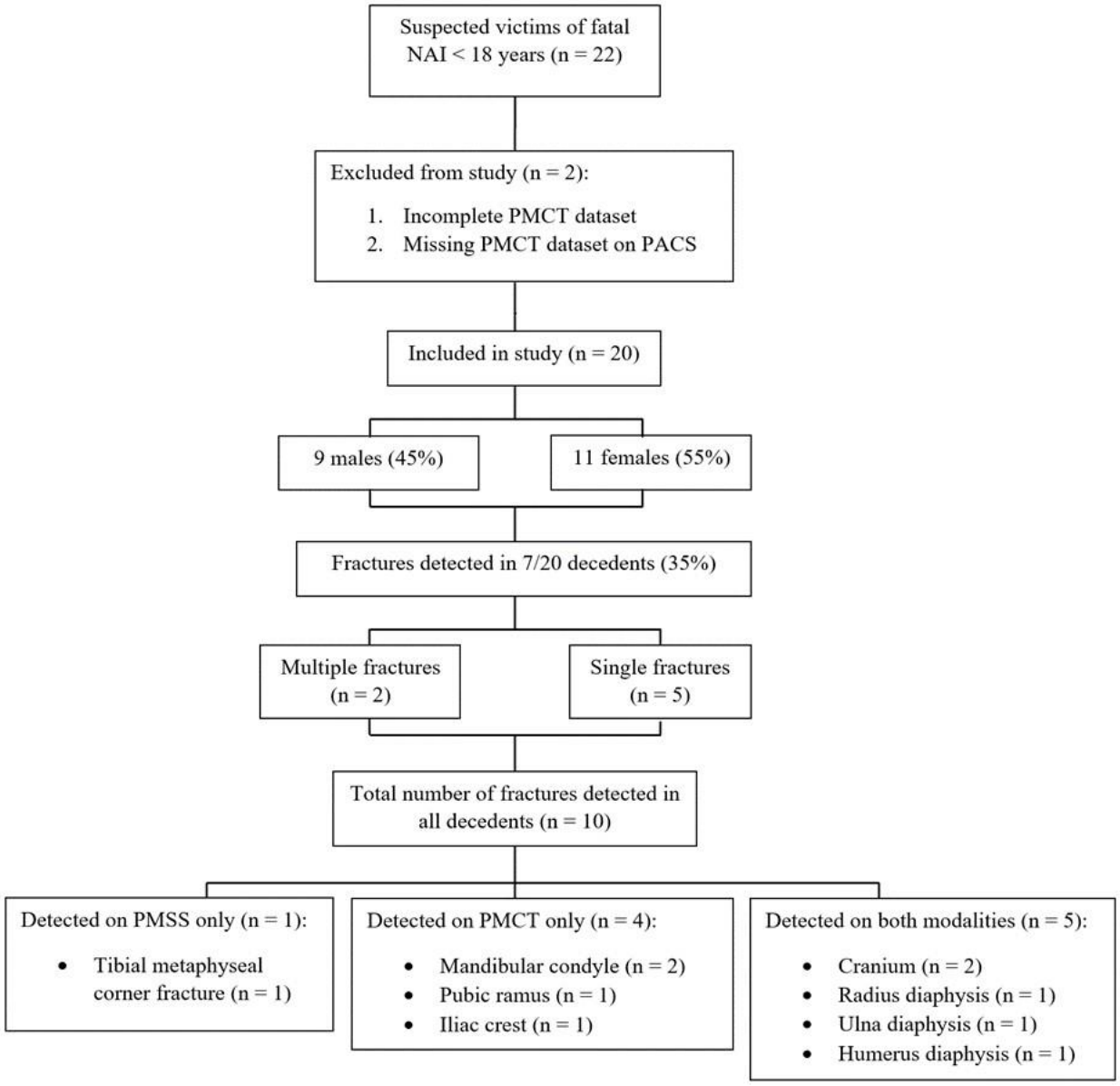

Figure 1

Flowchart of study population and fracture types per modality.

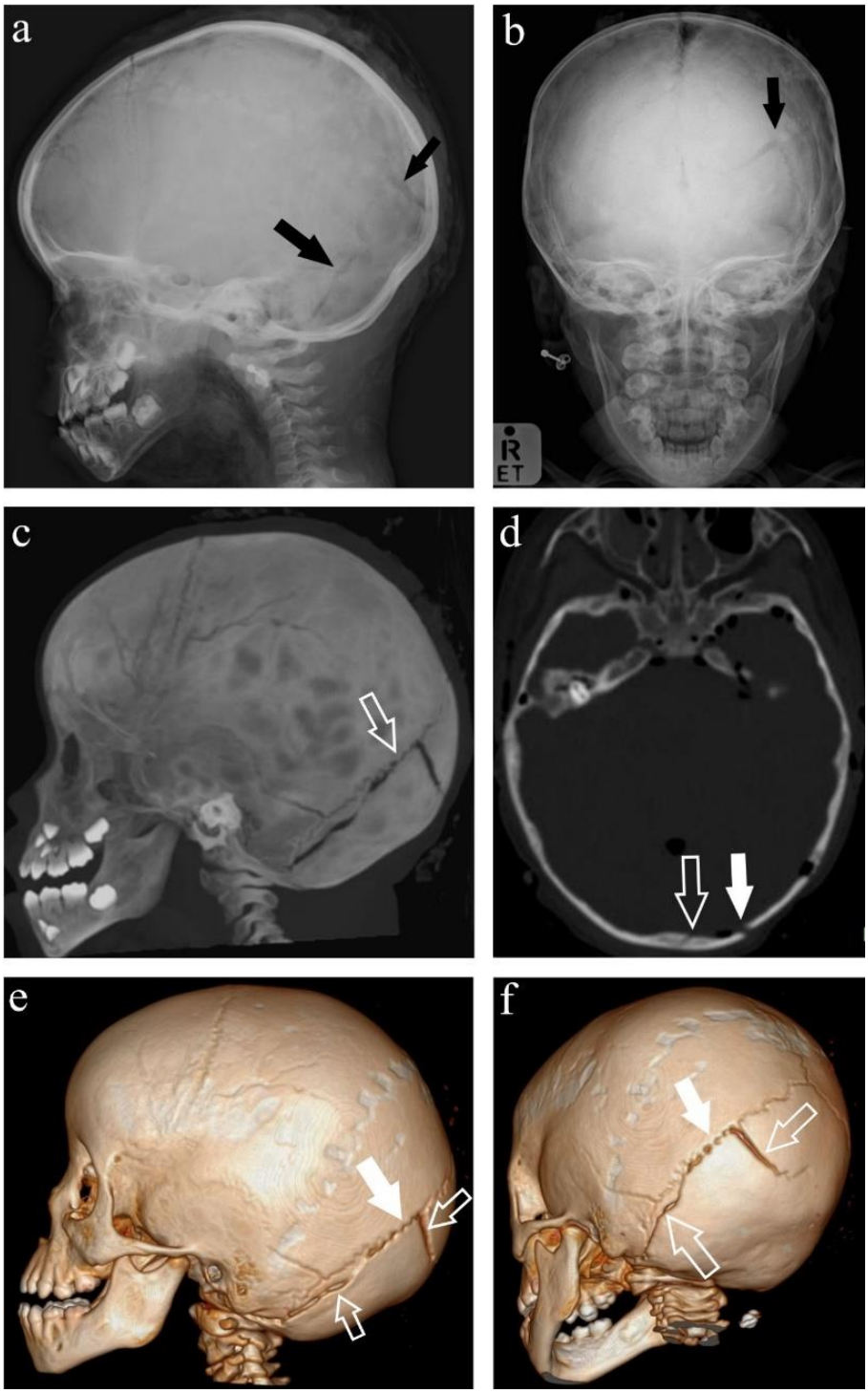

Figure 2

Cranial fractures in a 2-year-old female decedent. The black arrows demonstrate a linear fracture of the occipital bone. PMCT showing a complex fracture (open white arrows) with associated diastasis of the left lambdoid suture (solid white arrows). a and b = lateral and AP views of the skull from a PMSS; c = maximum intensity projection (MIP) of the head; d = axial bone reconstruction; e and f = 3D volume reconstructions.

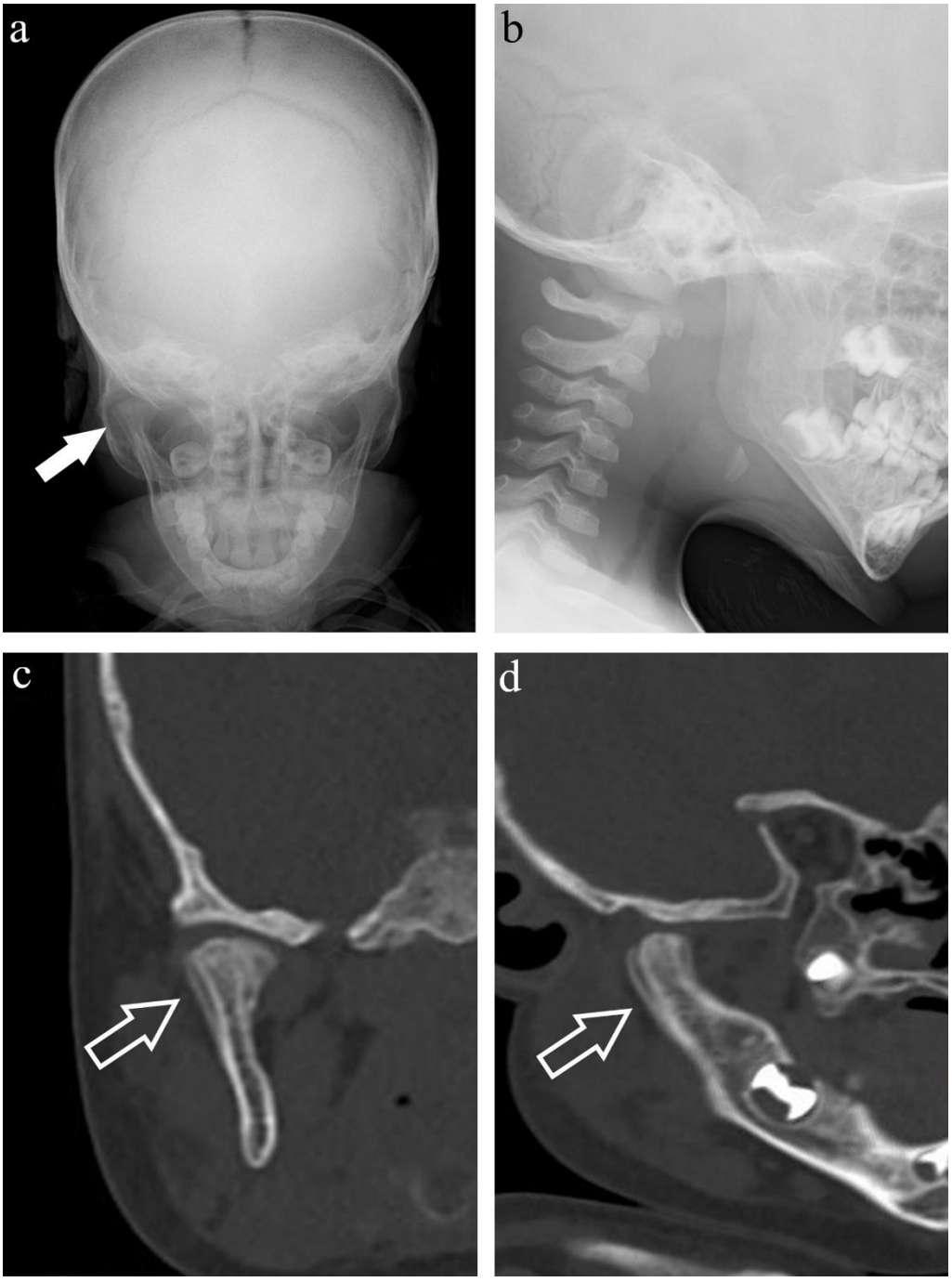

Figure 3

Right mandibular condyle fracture in a 10-year-old female decedent. The solid white arrow in figure a (AP skull radiograph) indicates a periosteal reaction which was not identified on PMSS. This fracture is not conspicuous on the lateral view from the PMSS (b). PMCT easily demonstrates the fracture and associated periosteal reaction (open white arrow). c = coronal single slice from PMCT; d = oblique single slice reconstruction.

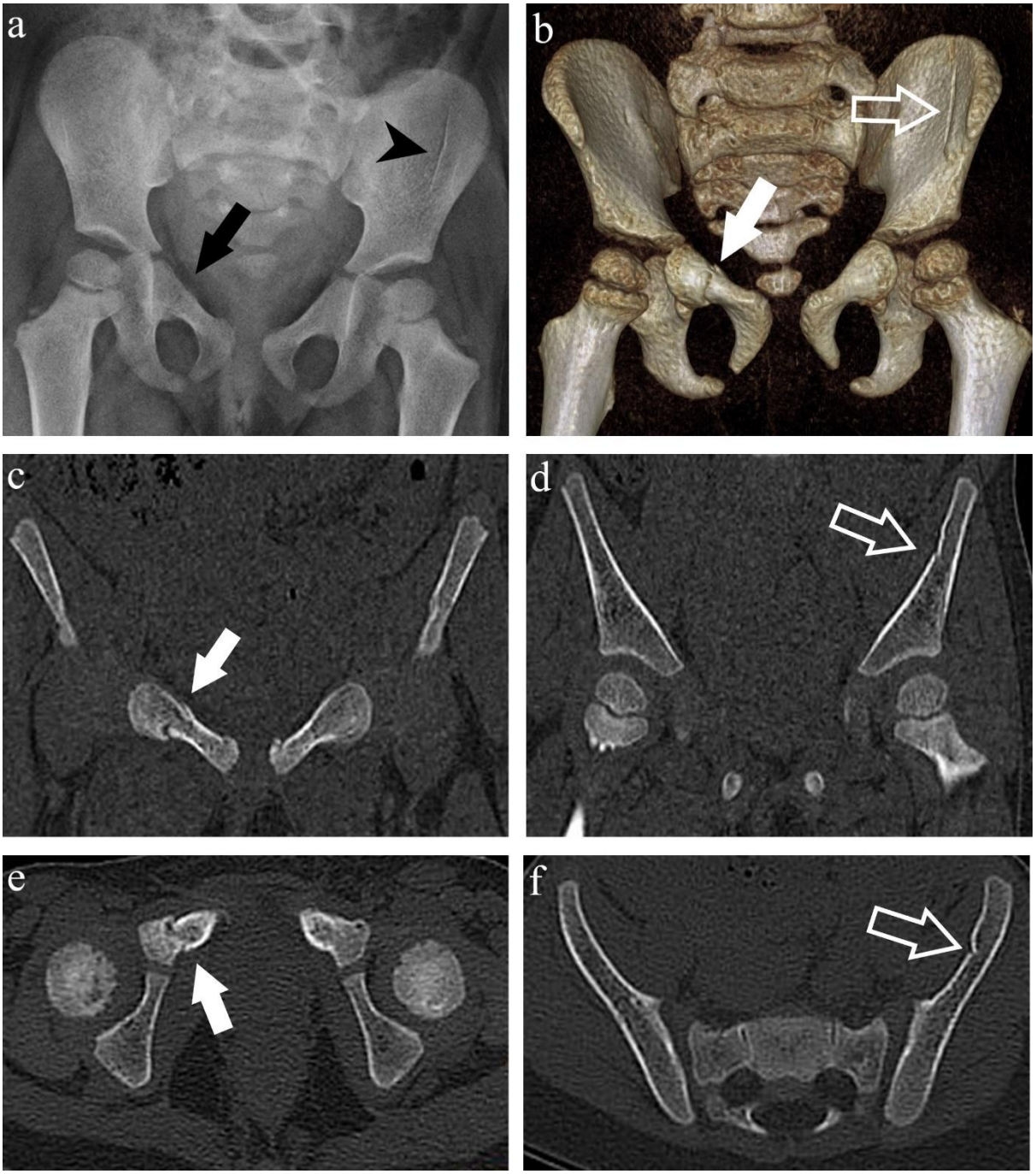

Figure 4

Pelvic fractures in a 3-year-old male decedent. The right superior pubic ramus fracture (solid black arrow) and the left iliac crest linear fracture (black arrowhead) were not identified on the PMSS (a). These fractures were detected on PMCT, likely due to their increased conspicuity on MPR (solid white arrows = right superior pubic ramus fracture; open white arrows = left iliac crest linear fracture). b = 3D volume reconstruction; c and d = single coronal slices through the pelvis; e and f = single axial slices through the pelvis.

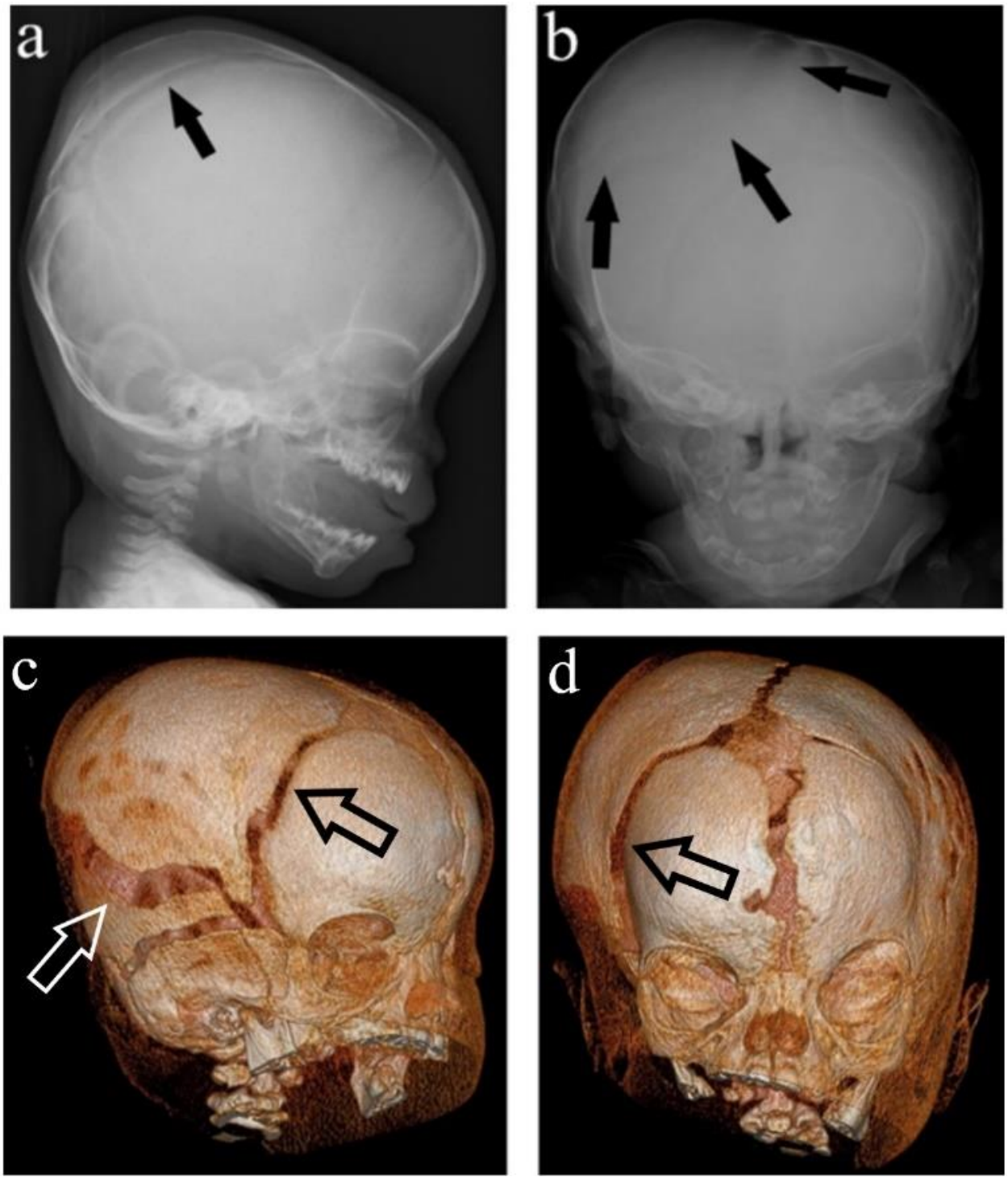

Figure 5

Cranial fractures in a 1-year-old female decedent. Lateral and AP skull radiographs (a and b) demonstrate a large complex right parietal and occipital bone fracture with associated diastatic fractures (solid black arrows). The same fracture is demonstrated on the PMCT (open white arrows) and the right coronal suture diastasis is easily demonstrated (open black arrow). c and d = 3D volume reconstructions of the PMCT.

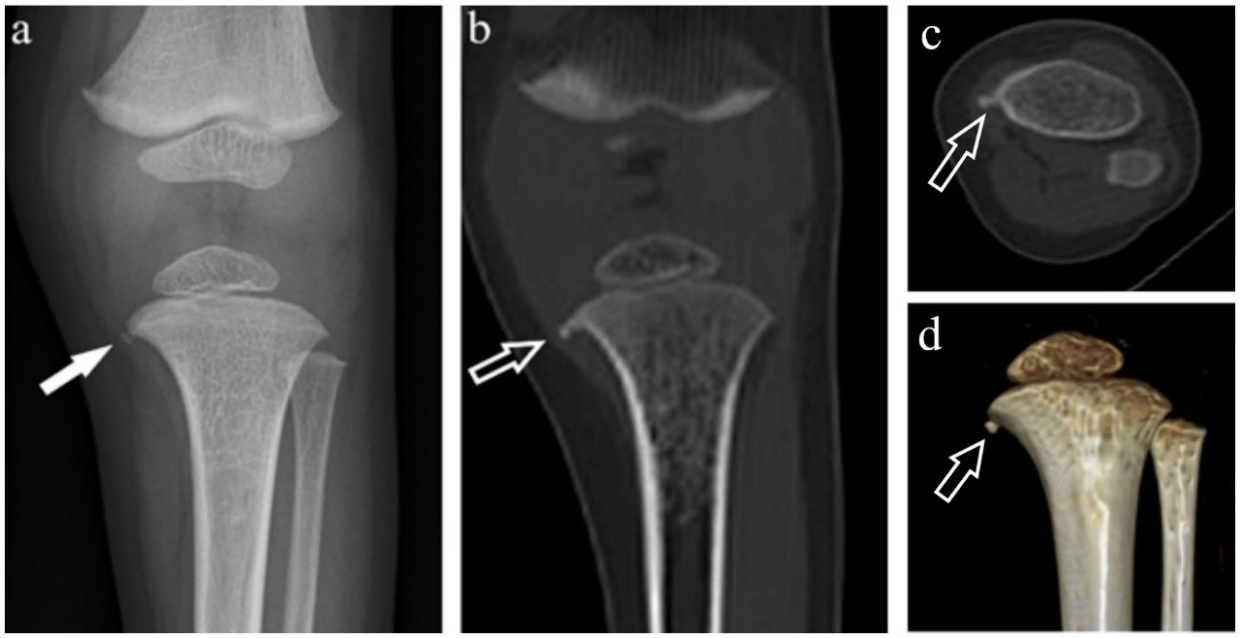

Figure 6

Metaphyseal corner fracture of the left proximal tibia in a 3-year-old male decedent. This fracture was detected on the PMSS (solid white arrow) but not on PMCT (open white arrows). a = cropped image from a PMSS; b = coronal single slice; c = axial single slice of PMCT d = PMCT 3D volume reconstruction.



Figure 7

Fracture dating: A right proximal humerus oblique fracture in a 2-year-old male decedent (images a – c; solid white arrows) This was detected on both PMSS and PMCT. Note lack of callus formation indicating that this fracture occurred less than 4 days before death. Compare these to images d – f which demonstrate a right distal radius fracture in a 10-year-old female decedent (open white arrows) which was detected on both modalities. The fracture line is more conspicuous on PMCT than on PMSS. The formation of bridging callus and periosteal reaction indicates that this fracture occurred between 14 and 21 days before death. Note also the periosteal reaction of the distal ulna (solid black arrow). a = cropped image from a PMSS; b = coronal single slice from PMCT; c = 3D volume reconstruction of PMCT; d = cropped image from a PMSS; e = coronal single slice from PMCT; f = 3D volume reconstruction of PMCT.

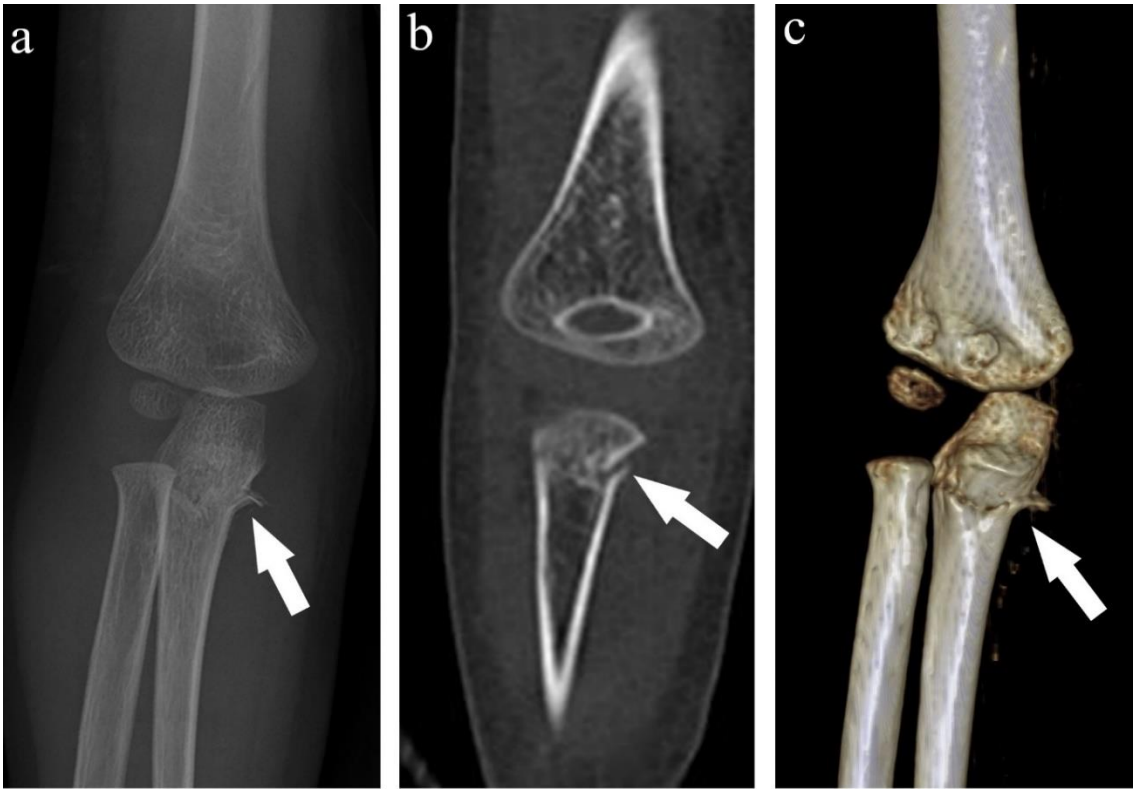

Figure 8

Right proximal ulna diaphyseal transverse fracture in a 3-year-old male decedent (solid white arrows) which was detected on both SS and PMCT. The lack of callus formation indicates that this fracture occurred less than 4 days before death. Compare this case to Figure 7 in which the callus could be confused on PMSS alone as a periosteal reaction rather than a fracture. a = cropped image from PMSS; b = coronal single slice from PMCT; c = 3D volume reconstruction of PMCT.

References:

1. Gould SW, Harty MP, Givler NE, Christensen TE, Curtin RN, Harcke HT. Pediatric postmortem computed tomography: initial experience at a children's hospital in the United States. Pediatr Radiol. 2019;49(9):1113–29.

2. Proisy M, Marchand AJ, Loget P, Bouvet R, Roussey M, Pelé F, et al. Whole-body post-mortem computed tomography compared with autopsy in the investigation of unexpected death in infants and children. Eur Radiol. 2013;23(6):1711–9.

3. Shelmerdine SC, Gerrard CY, Rao P, Lynch M, Kroll J, Martin D, et al. Joint European Society of Paediatric Radiology (ESPR) and International Society for Forensic Radiology and Imaging (ISFRI) guidelines: paediatric postmortem computed tomography imaging protocol. Pediatr Radiol. 2019;49(5):694–701.

4. Dirnhofer R, Jackowski C, Vock P, Potter K, Thali MJ. Virtopsy: Minimally invasive, imaging-guided virtual autopsy. Radiographics. 2006;26(5):1305–33.

5. van Rijn RR, Beek EJ, van de Putte EM, Teeuw AH, Nikkels PGJ, Duijst WLJM, et al. The value of postmortem computed tomography in paediatric natural cause of death: a Dutch observational study. Pediatr Radiol. 2017;47(11):1514–22.

6. Noda Y, Yoshimura K, Tsuji S, Ohashi A, Kawasaki H, Kaneko K, et al. Postmortem computed tomography imaging in the investigation of nontraumatic death in infants and children. Biomed Res Int. 2013;2013.

7. Mathews S, Abrahams N, Jewkes R, Martin LJ, Lombard C. The epidemiology of child homicides in South Africa. Bull World Health Organ. 2013;91(8):562–8.

8. Badoe E. A critical review of child abuse and its management in Africa. African J Emerg Med. 2017;7(January):S32–5.

9. South Africa. Inquests Act No. 58 of 1959.

10. O'Donnell C, Woodford N. Post-mortem radiology-a new sub-speciality? Clin Radiol. 2008;63(11):1189–94.

11. Makino Y, Yokota H, Nakatani E, Yajima D, Inokuchi G, Motomura A, et al. Differences between postmortem CT and autopsy in death investigation of cervical spine injuries. Forensic Sci Int. 2017;281(2017):44–51.

12. Prosser I, Maguire S, Harrison SK, Mann M, Sibert JR, Kemp AM. How old is this fracture? Radiologic dating of fractures in children: A systematic review. Am J Roentgenol. 2005;184(4):1282–6.

13. Wessels R, Moodley H. Fatal non-accidental injury in South Africa: A Gauteng hospital's perspective on the incidence and fracture types on post mortem skeletal surveys. 2021;

14. Cohen MC, Whitby E, Fink MA, Collett JM, Offiah AC. Running a postmortem service — a business case and clinical experience. Pediatr Radiol. 2015;45(4):501–8.

15. Doyle E, Hunter P, Viner MD, Kroll JJK, Pedersen CC, Gerrard CY. IAFR Guidelines for best practice: Principles for radiographers and imaging practitioners providing forensic imaging services. Forensic Imaging. 2020;22(August):200400.

16. Swinson S, Tapp M, Brindley R, Chapman S, Offiah A, Johnson K. An audit of skeletal surveys for suspected non-accidental injury following publication of the British Society of Paediatric Radiology guidelines. Clin Radiol. 2008;63(6):651–6.

17. Offiah AC, Hall CM. Observational study of skeletal surveys in suspected non-accidental injury. Clin Radiol. 2003;58(9):702–5.

18. van Rijn RR, Kieviet N, Hoekstra R, Nijs HGT, Bilo RAC. Radiology in suspected non-accidental injury: Theory and practice in the Netherlands. Eur J Radiol. 2009;71(1):147–51.

19. Flach PM, Gascho D, Schweitzer W, Ruder TD, Berger N, Ross SG, et al. Imaging in forensic radiology: an illustrated guide for postmortem computed tomography technique and protocols. Forensic Sci Med Pathol. 2014;10(4):583–606.

20. Arthurs OJ, Van Rijn RR, Sebire NJ. Current status of paediatric post-mortem imaging: An ESPR questionnaire-based survey. Pediatr Radiol. 2014;44(3):244–51.

21. Arthurs OJ, van Rijn RR, Whitby EH, Johnson K, Miller E, Stenzel M, et al. ESPR postmortem imaging task force: where we begin. Pediatr Radiol. 2016;46(9):1363–9.

22. Rutty GN, Brogdon G, Dedouit F, Grabherr S, Hatch GM, Jackowski C, et al. Terminology used in publications for post-mortem cross-sectional imaging. Int J Legal Med. 2013;127(2):465–6.

23. Hong TS, Reyes JA, Moineddin R, Chiasson DA, Berdon WE, Babyn PS. Value of postmortem thoracic CT over radiography in imaging of pediatric rib fractures. Pediatr Radiol. 2011;41(6):736–48.

24. Shelmerdine SC, Langan D, Hutchinson JC, Hickson M, Pawley K, Suich J, et al. Chest radiographs versus CT for the detection of rib fractures in children (DRIFT): a diagnostic accuracy observational study. Lancet Child Adolesc Heal. 2018;2(11):802–11.

25. Wootton-Gorges SL, Stein-Wexler R, Walton JW, Rosas AJ, Coulter KP, Rogers KK. Comparison of computed tomography and chest radiography in the detection of rib fractures in abused infants. Child Abus Negl. 2008;32(6):659–63.

26. Renton J, Kincaid S, Ehrlich PF. Should helical CT scanning of the thoracic cavity replace the conventional chest x-ray as a primary assessment tool in pediatric trauma? An efficacy and cost analysis. J Pediatr Surg. 2003;38(5):793–7.

27. Antúnez S, Grevent D, Boddaert N, Vergnaud E, Vecchione A, Ferrant-Azoulay O, et al. "Perimortem" total body CT-scan examination in severely injured children: an informative insight into the causes of death. Int J Legal Med. 2019;

28. Mulroy MH, Loyd AM, Frush DP, Verla TG, Myers BS, "Dale" Bass CR. Evaluation of pediatric skull fracture imaging techniques. Forensic Sci Int. 2012;214(1–3):167–72.

29. Chawla H, Malhotra R, Yadav RK, Griwan MS, Paliwal PK, Aggarwal AD. Diagnostic utility of conventional radiography in head injury. J Clin Diagnostic Res. 2015;9(6):TC13–5.

30. Merhar SL, Kline-Fath BM, Nathan AT, Melton KR, Bierbrauer KS. Identification and management of neonatal skull fractures. J Perinatol. 2016;36(8):640–2.

31. Combrinck N, Jansen van Vuuren S. The role of post-mortem computed tomography in assault victims with head trauma in central South Africa. South African J Radiol. 2017;21(1):6778.

32. No Title [Internet]. Available from: https://www.pedrad.org/Specialties/Post-Mortem-Imaging#46183060-opinions

33. Gilsanz V, Ratib O. Hand Bone Age: A Digital Atlas of Skeletal Maturity. New York, NY: Springer Science & Business Media; 2005.

34. Royal College of Paediatrics and Child Health. Child Protection Evidence Systematic review on Bruising. 2020;(April):1–67.

35. Lonergan GJ, Baker AM, Morey MK, Boos SC. Child Abuse: Radiologic-Pathologic Correlation. Radiographics. 2003;23(4):811–45.

36. Wasicek PJ, Gebran SG, Elegbede A, Ngaage LM, Rasko Y, Ottochian M, et al. Differences in Facial Fracture Patterns in Pediatric Nonaccidental Trauma. J Craniofac Surg. 2020;31(4):956–9.

37. Offiah A, Van Rijn RR, Perez-Rossello JM, Kleinman PK. Skeletal imaging of child abuse (non-accidental injury). Pediatr Radiol. 2009;39(5):461–70.

38. Ebert LC, Thali MJ, Ross S. Getting in touch-3D printing in Forensic Imaging. Forensic Sci Int. 2011;211(1–3):1–6.

39. Di Pietro MA, Brody AS, Cassady CI, Kleinman PK, Wyly JB, Applegate KE, et al. Diagnostic imaging of child abuse. Pediatrics. 2009;123(5):1430–5.

40. Chapman S. What are the greatest challenges and/or barriers to applying postmortem imaging in paediatric radiology? Pediatr Radiol. 2015;45(4):478.

41. Klein WM, Bosboom DGH, Koopmanschap DHJLM, Nievelstein RAJ, Nikkels PGJ, van Rijn RR. Normal pediatric postmortem CT appearances. Pediatr Radiol. 2015;45(4):517–26.

Highlights:

- PMCT is a novel tool in investigating fatal NAI
- We describe the first prospective comparison of PMCT with PMSS in South Africa
- PMCT proved useful in detecting and evaluating complex cranial, facial and pelvic fractures
- PMCT is faster and easier to perform than PMSS

Approved Research Protocol:

Whole body post-mortem computed tomography versus skeletal survey in the detection of fractures in suspected cases of fatal non-accidental injury

Daniel Nicholas Prince (investigator) * [a], Halvani Moodley (supervisor) [a], Jeanine Vellema (co-supervisor) [b]

[a] *Department of Diagnostic and Interventional Radiology, University of the Witwatersrand*

[b] *Department of Forensic Medicine and Pathology, University of the Witwatersrand*

**Correspondence to: dan.n.prince@gmail.com; cell phone: 083-624-2932*

List of abbreviations/glossary of terms:

CMJAH – Charlotte Maxeke Johannesburg Academic Hospital

Decedent – deceased person

FPS – Forensic Pathology Service

Lodox – Full-body digital x-ray scanner

MDCT – multidetector computed tomography

MPR – multiplanar reconstruction

NAI – non-accidental injury

PACS – picture archiving and communication system

PMCT – post-mortem computed tomography

SAPS – South African Police Service

SASPI – South African Society of Paediatric Imaging

SS – skeletal survey

1. Introduction:

Non-accidental injury (NAI) is defined as harm to a child via acts of commission or omission (1).

Child homicide rates in sub-Saharan Africa are estimated to be the highest in the world (over double that of the United States), and deaths due to NAI account for a substantial proportion of this. In one study, the rate of fatal NAI was found to be 6.6 per 100 000 using "a fairly conservative definition". Furthermore, they state that deaths due to NAI are frequently underreported or misclassified as natural or accidental deaths (2). The prevalence of fatal NAI could therefore potentially be higher. In South Africa, approximately half of all child murders are as a result of NAI, with the most at-risk group being those under 5 years old (3).

Radiological studies have been used in the forensic investigative process since the late 19th century and have now become routine (4).

At Charlotte Maxeke Johannesburg Academic Hospital, the current practice for radiographic evaluation of deceased infants and children in suspected cases of NAI is to perform a skeletal survey (SS) involving a standardised set of views based on the 2013 South African Society of Paediatric Imaging (SASPI) guidelines (see appendix 1). The decedents are referred to the radiology department at CMJAH from the various Southern Gauteng Cluster Forensic Medico-Legal Laboratories. The skeletal survey takes place either before or after the autopsy has been performed and is acquired by radiographers with experience in paediatric forensic imaging. These SSs are performed during normal working hours on digital units. All the views acquired in these studies need to be reviewed by a consultant radiologist before the decedent leaves the radiology department to ensure that all the necessary views have been performed, whether any additional views need to be taken and that they are of adequate diagnostic quality.

In the investigation of suspected cases of NAI, radiographic imaging is employed to assist the forensic investigators in diagnosing fractures (it has been shown that up to 52% of abused children will have sustained fractures) (5). It is then possible to characterise and document these injuries for later use in legal proceedings.

Certain fractures such as those involving the posterior ribs and the metaphyseal corners of long bones ("bucket handle" type fractures) are highly specific locations for non-

accidental injuries. Multiple fractures at varying stages of healing is a sign also considered highly specific for NAI (5). It is also known that certain fractures – particularly fractures of the anterior and posterior extremities of the ribs – may be missed on skeletal surveys, especially when there has not yet been time for callus to form (6). Radiography can also underestimate the extensiveness of metaphyseal corner fractures (7).

A thorough skeletal survey is time-consuming (~45 minutes to 1 hour to perform) and requires careful radiographic technique which has to be modified in the deceased (for example, positioning hands and feet to compensate for rigor mortis, which increases the study time). Further, the process of imaging a deceased infant or child is an unpleasant and upsetting task, according to the radiographers informally interviewed by the investigators.

Furthermore it has been shown internationally that skeletal surveys in both the living and the dead frequently do not comply with the standardised guidelines stipulated by the British Society of Paediatric Radiology (BSPR) and the American College of Radiology (ACR) in terms of adequate number of views and technical quality of the images taken (1,8,9). No studies have examined this in the South African setting. At CMJAH, we have a specialist paediatric radiologist who checks the adequacy of SSs – in less well-resourced hospitals, the SSs could potentially not comply with the SASPI guidelines.

Despite the growing importance of radiology in forensic investigation, a review of the literature reveals a paucity of published research in this field. Many of the studies are retrospective analyses and there are few prospective studies; in particular, studies involving cross-sectional imaging in the paediatric population are scarce.

Much of the literature on forensic radiology comes from Europe and the United States of America. There are concerted efforts overseas to formulate standardised post-mortem imaging protocols and guide the practice of post-mortem cross-sectional imaging, with the European Society of Paediatric Radiology (ESPR) recently forming a dedicated task-force to address these issues (10).

Hong *et al.* investigated the utility of post-mortem CT in rib fracture detection rate in deceased children by comparing plain radiography, PMCT and autopsy findings (which was considered the gold standard), and found that by using PMCT, significantly more

rib fractures were detected than when employing plain radiography. However, it also noted that the experience of the interpreting radiologist could affect the detection rates of these fractures on PMCT (11).

A small study by Sanchez *et al.* investigated the utility of low-dose CT scanning of the chest in living children (sample size of 4) with suspected NAI and found that several fractures that were not evident on plain radiographic studies were detected on CT (12).

Tsai *et al.* found that the findings of high-resolution CT scanning of long bone specimens taken from 5 infants who were fatally abused correlated well with histological findings in these same specimens (13).

Only one published study from South Africa on the topic of post-mortem radiology was found when reviewing the literature. It retrospectively compared autopsy findings with full-body digital radiography (Lodox) findings in 192 cases of sudden unexpected death in infancy (SUDI) and concluded that full-body radiography findings were consistent with autopsy findings and could potentially help in improving workflow in mortuaries by reducing the time taken to image the decedent (14).

One unpublished study presented at the Radiological Society of South Africa/SASPI Congress by Combrinck and Jansen van Vuuren in 2016 looked at the utility of PMCT in adult head trauma and found that PMCT is a useful adjunct to autopsy especially in diagnosing skull fractures (15).

To the best of our knowledge, no studies involving PMCT in paediatric patients have been carried out in South Africa, let alone in the context of NAI.

Only one study attempted to address the issue of the increased financial cost of PMCT to the healthcare system – conventional chest radiographs were found to be more cost effective than CT (16).

The literature has demonstrated that MDCT imaging is superior to conventional radiography in the detection of fractures in both living and deceased patients. It has also shown that the usual problems associated with paediatric MDCT imaging (motion artefact, minimising radiation dose) are near absent in post-mortem imaging. A whole body MDCT scan takes a fraction of the time to acquire compared to a skeletal survey, and with the anticipated benefits of improved fracture detection, shorter study times and limited handling of the decedent by the radiography staff (improving staff

compliance and satisfaction as well as guarding from potentially hazardous bodily fluids), the role of paediatric PMCT needs to be investigated in our local setting.

2. Study objectives:

The primary objective of this prospective double-blinded study is to ascertain whether whole body PMCT will result in improved detection of fractures compared to SS for fatal NAI.

Secondary objectives include:

- Incidence and fracture types on PMCT vs. SS.
- Sensitivity of PMCT vs. SS for high specificity fracture locations for fatal NAI.
- Average study time of PMCT vs. SS.
- Sensitivity of fracture dating on PMCT vs SS.

3. Methods:

This prospective double-blinded study will evaluate all deceased infants and children (< 18 years old) referred from the FPS Southern Gauteng Cluster to CMJAH for suspected NAI for radiological investigation.

Inclusion criteria:

Suspected NAI by the South African Police Service (SAPS) case officer/forensic pathologist.

All decedents under the age of 18 years old undergoing skeletal survey and PMCT at CMJAH.

Exclusion criteria:

Any cases that do not meet the above criteria.

Method:

Each case will first undergo a PMCT using either a 64 or 128 slice Philips CT scanner at CMJAH and then a SS will be performed as per the departmental protocol (SASPI 2013 guidelines).

The PMCT scanning protocols will be in-line with the Society of Pediatric Radiology guidelines (see appendix 2) and will be created for CMJAH radiology by a Phillips CT application specialist based on the above guidelines.

The entire decedent will be scanned supine from vertex to feet in two stages: head and neck only, then the rest of the body. The relatively small diameter of the head compared to the diameter of the chest, abdomen and pelvis necessitates two scanning protocols due to attenuation differences to ensure optimal image quality. Since the decedents will likely be small, out-of-scan-field artefacts aren't anticipated to be a problem.

The decedents will be scanned in the body bags to avoid soiling the CT gantry with bodily fluids and in the interests of preventing cross infection with the live patients also scanned on the same machines. The CT table will be disinfected after each study.

Dr Prince will assign a randomised study number to each case so that the reader is blinded to the decedents' identities other than sex and age (if age is not known, a bone age analysis will be performed using the standards of Gilsanz and Ratib to estimate the age).

The SS will be reported by the paediatric radiologist at CMJAH (Dr H Moodley) and the report will be stored on PACS (on the day of/day after the SS).

Several weeks to months later, the PMCT will be interpreted (using MPR and 3D reconstruction) images on PACS. A time delay will minimise bias.

A *Pro forma* diagnostic checklist will be provided to the reader. This will include adequacy of scan, presence, description, location and dating of fractures, time of first image acquisition, time of final image acquisition, and provision for recording any further information deemed relevant by the reader (see appendix 4).

At the time of the SS and PMCT interpretations, the reader will capture the data using Redcap.

Endpoint:

12 consecutive months to collect data prospectively.

4. Data analysis:

Data from the checklists will be captured electronically by the reader on Redcap and downloaded as a Microsoft Excel spreadsheet by the researcher. Analysis will be done by a statistician using SAS Version 9.2.

Descriptive statistics, namely frequencies and percentages, will be calculated for categorical data and means and standard deviations or medians and percentiles will be calculated for numerical data. The Shapiro-Wilk test will be used to investigate the normality of numerical data – if the data follows a normal distribution the mean and standard deviation will be reported, but if the data doesn't follow a normal distribution, the median and inter-quartile ranges will be reported.

Categorical variables will be summarised by calculating frequencies and percentages. In order to compare the findings of the PMCT and SS, the Fisher's Exact Test will be used to compare percentages of the two groups and the independent T-test (or Mann-Whitney U-test) will be used to compare mean (or median) values.

A significance level (α) of 0.05 will be used.

5. Ethics:

Ethics clearance is pending (HREC number M181132).

6. **Timing:**

	Aug 2018	**Sept 2018**	**Oct 2018**	**Dec 2018 to Dec 2019**	**Dec 2019**	**Jan 2020**	**Jan 2020**
Literature review							
Preparing protocol							
Protocol assessment							
Ethics application							
Collecting data							
Data analysis							
Write-up							

7. **Funding:**

Dr Prince will self-fund the research.

With assistance from Professor Vangu and Professor Vellema, scans will be charged for as follows:

As per the National Department of Health Uniform Patient Fee Schedule:

Decedents will be considered H1 level patients (R75) and the cost of the imaging (R75), to make a total of R150 for each study participant.

The total estimated cost is R 3000 for 20 patients.

8. **Problems:**

None anticipated.

9. References:

1. van Rijn RR, Kieviet N, Hoekstra R, Nijs HGT, Bilo RAC. Radiology in suspected non-accidental injury: Theory and practice in the Netherlands. Eur J Radiol. 2009;71(1):147–51.

2. Mathews S, Abrahams N, Jewkes R, Martin LJ, Lombard C. The epidemiology of child homicides in South Africa [Internet]. Vol. 91, Bulletin of the World Health Organization. 2013. p. 562–8. Available from: http://www.who.int/entity/bulletin/volumes/91/8/12-117036.pdf

3. Mathews S, Martin LJ, Bch MB, For D, Sa M, Forens MP, et al. Developing an understanding of fatal child abuse and neglect : Results from the South African child death review pilot study. 2016;106(12):2014–7.

4. Brogdon B. Forensic Radiology [Internet]. Boca Raton: CRC Press; 1998. Available from: http://www.crcnetbase.com/doi/book/10.1201/9781420048339

5. Prosser I, Maguire S, Harrison SK, Mann M, Sibert JR, Kemp AM. How Old Is This Fracture ? Radiologic Dating of Fractures in Children : A Systematic Review. 2005;(April):1282–6.

6. Offiah A, Van Rijn RR, Perez-Rossello JM, Kleinman PK. Skeletal imaging of child abuse (non-accidental injury). Pediatr Radiol. 2009;39(5):461–70.

7. Kleinman PK. Problems in the diagnosis of metaphyseal fractures. Pediatr Radiol. 2008;38(SUPPL. 3):388–94.

8. Swinson S, Tapp M, Brindley R, Chapman S, Offiah A, Johnson K. An audit of skeletal surveys for suspected non-accidental injury following publication of the British Society of Paediatric Radiology guidelines. Clin Radiol. 2008;63(6):651–6.

9. Offiah AC, Hall CM. Observational study of skeletal surveys in suspected non-accidental injury. Clin Radiol. 2003;58(9):702–5.

10. Arthurs OJ, van Rijn RR, Whitby EH, Johnson K, Miller E, Stenzel M, et al. ESPR postmortem imaging task force: where we begin. Pediatr Radiol [Internet]. Pediatric Radiology; 2016;46(9):1363–9. Available from: http://dx.doi.org/10.1007/s00247-016-3639-2

11. Hong TS, Reyes JA, Moineddin R, Chiasson DA, Berdon WE, Babyn PS. Value of postmortem thoracic CT over radiography in imaging of pediatric rib fractures. Pediatr Radiol. 2011;41(6):736–48.

12. Sanchez TR, Lee JS, Coulter KP, Seibert JA, Stein-Wexler R. CT of the chest in suspected child abuse using submillisievert radiation dose. Pediatr Radiol. 2015;45(7):1072–6.

13. Tsai A, McDonald AG, Rosenberg AE, Gupta R, Kleinman PK. High-resolution CT with histopathological correlates of the classic metaphyseal lesion of infant abuse. Pediatr Radiol. 2014;44(2):124–40.

14. Douglas TS, Kewana K, Chb MB, Ngema Y. Radiological findings at a South African forensic pathology laboratory in cases of sudden unexpected death in infants. SA Journal of Radiology. 2012. p. 4–6.

15. Combrinck N, Jansen van Vuuren S. The role of post-mortem computed tomography in assault victims with head trauma in central South Africa. SA J Radiol. 2016;21(1):6778.

16. Renton J, Kincaid S, Ehrlich PF. Should helical CT scanning of the thoracic cavity replace the conventional chest x-ray as a primary assessment tool in pediatric trauma? An efficacy and cost analysis. J Pediatr Surg. 2003;38(5):793–7.

17. pedrad. Post-Mortem Imaging [Internet]. [cited 2018 Oct 9]. Available from: https://www.pedrad.org/Specialties/Post-Mortem-Imaging#46173047-ct-protocols

[Protocol] Appendix 1:

Views in a complete skeletal survey (as per SASPI 2013 Guidelines):

- Axial skeleton
    - Thorax (AP, Lateral and bilateral Oblique ribs), to include ribs, thoracic and upper lumbar spine
    - Pelvis (AP), to include mid lumbar spine
    - Lumbosacral spine (Lateral)
    - Cervical spine (AP and Lateral)
    - Skull (Frontal and Lateral; additional views if necessary – Oblique or Towne's view)
- Appendicular skeleton
    - Humeri (AP)
    - Forearms (AP)
    - Hands (PA)
    - Femurs (AP)
    - Lower legs (AP)
    - Feet (PA or AP)
- Additional views if necessary (centred on joints or lateral views)

[Protocol] Appendix 2:

Scanning parameters for PMCT as per SPR Guidelines (17)**:**

Infant Head

Scan Type	**Slice Thickness**	**Pitch**	**Collimation**	**kV**	**Eff mAs**	**Algorithm**
Helical	5 mm	128X0.6	0.6	120	110	Standard

Older Head

Scan Type	**Slice Thickness**	**Pitch**	**Collimation**	**kV**	**Eff mAs**	**Algorithm**
Helical	5 mm	128X0.6	0.35	120	250	Standard

Body

Scan Type	**Slice Thickness**	**Pitch**	**Collimation**	**kV**	**Eff mAs**	**Algorithm**
Helical	5 mm	128X0.6	0.4	140	400	Standard

[Protocol] Appendix 3:

Checklist for reader:

Decedent study number: _____

Chronological age / bone age (please circle): _____

Sex: _____

Skeletal Survey / Post-mortem CT (please circle).

If SS: Are all the required images included in the study as per SASPI 2013 guidelines? (Y/N)

If PMCT: Is the entire body included in the scan? (Y/N)

Time of first image taken: _____

Time of last image taken: _____

Autopsy performed prior to radiological investigation (Y/N).

	Fracture (Y/N)	**Site**	**Description**	**Age of fracture[1]**
Skull				
Mandible				
Cervical spine				
Humeri				
Forearms				
Hands				
Thoracic spine				
Ribs				
Clavicles				

[1] See Appendix 4

Sternum				
Scapulae				
Lumbar spine				
Pelvis, sacrum and coccyx				
Femurs				
Lower legs				
Feet				

Other findings:

_____

_____

_____

_____

_____

[Protocol] Appendix 4:

Radiographic dating of fractures (5)**:**

Category	**Early**	**Peak**	**Late**
Resolution of soft tissues	2–5 days	4–10 days	10–21 days
SPNBF[2]	4–10 days	10–14 days	14–21 days
Loss of fracture line definition	10–14 days	14–21 days	
Soft callus	10–14 days	14–21 days	
Hard callus	14–21 days	21–42 days	42–90 days
Remodeling	3 month	1 years	2 years to physeal closure

[2] Sub-periosteal new bone formation

Appendices:

Appendix A: Ethics Clearance Certificate

UNIVERSITY OF THE WITWATERSRAND, JOHANNESBURG

R14/49 Dr Daniel Prince

HUMAN RESEARCH ETHICS COMMITTEE (MEDICAL)

CLEARANCE CERTIFICATE NO. M181132

NAME: (Principal Investigator)	Dr Daniel Prince
DEPARTMENT:	Diagnostic and Interventional Radiology Charlotte Maxeke Johannesburg Academic Hospital
PROJECT TITLE:	Whole body post-mortem computed tomography versus skeletal survey in the detection of fractures in suspected cases of fatal non-accidental injury
DATE CONSIDERED:	30/11/2018
DECISION:	Approved unconditionally
CONDITIONS:	
SUPERVISOR:	Dr H. Moodley and Prof J. Vellema
APPROVED BY:	Dr CB Penny, Chairperson, HREC (Medical)
DATE OF APPROVAL:	21/06/2019

This clearance certificate is valid for 5 years from date of approval. Extension may be applied for.

DECLARATION OF INVESTIGATORS

To be completed in duplicate and **ONE COPY** returned to the Research Office Secretary on the Third Floor, Faculty of Health Sciences, Phillip Tobias Building, 29 Princess of Wales Terrace, Parktown, 2193, University of the Witwatersrand. I/we fully understand the conditions under which I am/we are authorized to carry out the above-mentioned research and I/we undertake to ensure compliance with these conditions. Should any departure be contemplated, from the research protocol as approved, I/we undertake to resubmit the application to the Committee. **I agree to submit a yearly progress report**. The date for annual re-certification will be one year after the date of convened meeting where the study was initially reviewed. In this case, the study was initially reviewed in **November** and will therefore be due in the month of **November** each year. Unreported changes to the application may invalidate the clearance given by the HREC (Medical).

PLEASE QUOTE THE PROTOCOL NUMBER IN ALL ENQUIRIES

Appendix B: Plagiarism Declaration

UNIVERSITY OF THE WITWATERSRAND, JOHANNESBURG

FACULTY OF HEALTH SCIENCES

PLAGIARISM DECLARATION TO BE SIGNED BY ALL HIGHER DEGREE STUDENTS

SENATE PLAGIARISM POLICY: APPENDIX ONE

I Daniel Nicholas Prince (Student number: 0701897T) am a student registered for the degree of MMed (Diagnostic Radiology) in the academic year 2021.

I hereby declare the following:

- I am aware that plagiarism (the use of someone else's work without their permission and/or without acknowledging the original source) is wrong.
- I confirm that the work submitted for assessment for the above degree is my own unaided work except where I have explicitly indicated otherwise.
- I have followed the required conventions in referencing the thoughts and ideas of others.
- I understand that the University of the Witwatersrand may take disciplinary action against me if there is a belief that this is not my own unaided work or that I have failed to acknowledge the source of the ideas or words in my writing.
- I have included as an appendix a report from "Turnitin" (or other approved plagiarism detection) software indicating the level of plagiarism in my research document.

Signature:  Date: 05/05/2021

1

Appendix C: Turnitin Report Cover Page

0701897t:Final_Blinded_Manuscript_DN_Prince_.docx

ORIGINALITY REPORT

9%	5%	7%	1%
SIMILARITY INDEX	INTERNET SOURCES	PUBLICATIONS	STUDENT PAPERS

PRIMARY SOURCES

1	Jennifer C. Love, Sharon M. Derrick, Jason M. Wiersema. "Skeletal Atlas of Child Abuse", Springer Science and Business Media LLC, 2011 Publication	1%
2	pure.uva.nl Internet Source	1%
3	www.preprints.org Internet Source	1%
4	link.springer.com Internet Source	1%
5	www.scribd.com Internet Source	<1%
6	www.aafs.org Internet Source	<1%
7	idoc.pub Internet Source	<1%
8	Submitted to University of Wales, Bangor Student Paper	<1%

9	Pediatric Orthopedic Imaging, 2015. Publication	<1 %
10	Submitted to University of Witwatersrand Student Paper	<1 %
11	"Radiology in Forensic Medicine", Springer Science and Business Media LLC, 2020 Publication	<1 %
12	Andy Tsai, Jeannette Perez-Rossello, Susan A. Connolly, Kosuke Kawai, Paul K. Kleinman. "Temporal Pattern of Radiographic Findings of Costochondral Junction Rib Fractures on Serial Skeletal Surveys in Suspected Infant Abuse", American Journal of Roentgenology, 2021 Publication	<1 %
13	Submitted to University of Liverpool Student Paper	<1 %
14	hsag.co.za Internet Source	<1 %
15	Elspeth Whitby, Amaka C. Offiah, Susan C. Shelmerdine, Rick R. van Rijn et al. "Current state of perinatal postmortem magnetic resonance imaging: European Society of Paediatric Radiology questionnaire-based survey and recommendations", Pediatric Radiology, 2020 Publication	<1 %

16	connect.myesr.org Internet Source	<1 %
17	www.ncbi.nlm.nih.gov Internet Source	<1 %
18	"Postmortem and Forensic Magnetic Resonance Imaging", Imaging of the Pelvis Musculoskeletal System and Special Applications to CAD, 2016. Publication	<1 %
19	Abolfazl Najaf-Zadeh, Eric Nectoux, François Dubos, Laurent Happiette et al. "Prevalence and clinical significance of occult fractures in children with radiograph-negative acute ankle injury", Acta Orthopaedica, 2014 Publication	<1 %
20	Christina Jacobsen. "A comparative study of cranial, blunt trauma fractures as seen at medicolegal autopsy and by Computed Tomography", BMC Medical Imaging, 2009 Publication	<1 %
21	Mattias Kettner, Stefan Potente, Boris Schulz, Peter Knauff, Peter H. Schmidt, Frank Ramsthaler. "Analysis of laryngeal fractures in decomposed bodies using microfocus computed tomography (mfCT)", Forensic Science, Medicine, and Pathology, 2014 Publication	<1 %

22	doctorpenguin.com Internet Source	<1 %
23	sajp.org.za Internet Source	<1 %
24	silo.pub Internet Source	<1 %
25	Steffen G. Ross, Michael J. Thali, Stephan Bolliger, Tanja Germerott, Thomas D. Ruder, Patricia M. Flach. "Sudden Death after Chest Pain: Feasibility of Virtual Autopsy with Postmortem CT Angiography and Biopsy", Radiology, 2012 Publication	<1 %
26	Swinson, S.. "An audit of skeletal surveys for suspected non-accidental injury following publication of the British Society of Paediatric Radiology guidelines", Clinical Radiology, 200806 Publication	<1 %
27	www.scielo.org.za Internet Source	<1 %
28	Burke, . "Front Matter", Forensic Pathology of Fractures and Mechanisms of Injury Postmortem CT Scanning, 2011. Publication	<1 %
29	Evidence-Based Imaging in Pediatrics, 2010. Publication	

		<1 %
30	Beatriz V. Krentz, Leonor Alamo, Jochen Grimm, Fabrice Dédouit et al. "Performance of post-mortem CT compared to autopsy in children", International Journal of Legal Medicine, 2016 Publication	<1 %
31	Forensic Pathology of Infancy and Childhood, 2014. Publication	<1 %

Exclude quotes	On	Exclude matches	Off
Exclude bibliography	On		

Appendix D: Clinical Radiology Author Information Pack



CLINICAL RADIOLOGY

AUTHOR INFORMATION PACK

TABLE OF CONTENTS

- Description p.1
- Impact Factor p.1
- Abstracting and Indexing p.2
- Editorial Board p.2
- Guide for Authors p.5



ISSN: 0009-9260

DESCRIPTION

Clinical Radiology is published by Elsevier on behalf of The Royal College of Radiologists. *Clinical Radiology* is an International Journal bringing you original research, editorials and review articles on all aspects of **diagnostic imaging**, including:

- **Computed tomography**
- **Magnetic resonance imaging**
- **Ultrasonography**

- **Digital radiology**
- **Interventional radiology**
- **Radiography**
- **Nuclear medicine**

Papers on **radiological protection**, quality assurance, audit in **radiology** and matters relating to radiological training and education are also included. In addition, each issue contains correspondence, book reviews and notices of forthcoming events.

IMPACT FACTOR

2019: 2.118 © Clarivate Analytics Journal Citation Reports 2020

ABSTRACTING AND INDEXING

Scopus
Biological Abstracts
Chemical Abstracts
Elsevier BIOBASE
Current Contents - Clinical Medicine
Embase
Nuclear Science Abstracts
Research Alert
Science Citation Index
Social Sciences Citation Index
CINAHL
Sociedad Iberoamericana de Informacion Cientifica (SIIC) Data Bases
PubMed/Medline

EDITORIAL BOARD

Editor-in-Chief

M. Weston, Leeds, United Kingdom

Deputy Editors

J. Cox, Sunderland, UK

A. Rajesh, Leicester, United Kingdom

A. Shaw, Cambridge, United Kingdom

Advisory Editors: Breast

J. Cox, Sunderland, UK

R. Dobrashian, Blackburn, United Kingdom

J. Litherland, Glasgow, United Kingdom

S. Lowes, Gateshead, United Kingdom

I. Lyburn, Cheltenham, United Kingdom

A. Malhotra, London, United Kingdom

N. Sharma, Leeds, United Kingdom

Advisory Editors: Cardiac/Inc. interventional

M. Arzanauskaite, Liverpool, United Kingdom

A. Awwad, Nottingham, United Kingdom

R. Rajani, London, United Kingdom

G. Roditi, Glasgow, United Kingdom

C. Roobottom, Plymouth, United Kingdom

I. Vlahos, London, United Kingdom

D. Vummidi, Detroit, United States of America

M. Williams, Edinburgh, Scotland, UK

Advisory Editors: ENT/Maxillofacial

A. Ahuja, Shatin, Hong Kong

K. Bhatia, London, United Kingdom

C. Offiah, London, United Kingdom

S. Suresh Babu, Singapore, Singapore

S. Vaid, Pune, India

S. Vaidyanathan, Leeds, United Kingdom

A. Whyte, Perth, Australia

Advisory Editors: Gastrointestinal (inc. interventional)

J. Burn, London, United Kingdom

J. Franklin, Dorset, United Kingdom

A. Lim, London, United Kingdom

P. Mehrotra, South Shields, United Kingdom

J. Patel, London, United Kingdom

K. Planche, London, United Kingdom

R. Sinha, Warwick, United Kingdom

J. Stephenson, Leicester, UK

R. Verma, Leicester, United Kingdom

Advisory Editors: Guidelines, Educational and Manpower

Y. Graham, Sunderland, United Kingdom

R. Proctor, Lancaster, United Kingdom

S. Shamshuddin, Lancaster, United Kingdom

D. Vummidi, Detroit, Michigan, United States of America

Advisory Editors: Musculoskeletal

S. Babar, London, United Kingdom

W. Bhatti, Manchester, United Kingdom

R. Botchu, Birmingham, United Kingdom

R. Chowdhury, Oxford, United Kingdom

Y. Hughes-Roberts, , United Kingdom

R. Johnson, Oxford, United Kingdom

S. Shamshuddin, Lancaster, United Kingdom

P. Wilson, Belfast, United Kingdom

N. Winn, Oswestry, United Kingdom

Advisory Editors: Neurological

A. Agarwal, Cincinnati, United States of America

A. Chattopadhyay, Nottingham, United Kingdom

R. Gallagher, Leicester, United Kingdom

R. James, , United Kingdom

L. McGavin, Plymouth, United Kingdom

D. Minks, Newcastle Upon Tyne, United Kingdom

M. Radon, Sheffield, United Kingdom

S. Stivaros, Manchester, United Kingdom

Advisory Editors: Oncological Radiology (inc. interventional)

R. Balaji, Chennai, India

A. Lim, London, United Kingdom

A. Malhotra, London, United Kingdom

A. Rajesh, Leicester, United Kingdom

B. Taylor, Manchester, United Kingdom

Advisory Editors: Paediatric

O. Arthurs, London, United Kingdom

S. Shelmerdine, London, United Kingdom

Advisory Editors: Pancreatic/Hepato-biliary (inc. interventional)

A. Alsafi, London, United Kingdom

E.M. Anderson, Oxford, United Kingdom

J. Bell, Manchester, United Kingdom

J. Franklin, Dorset, United Kingdom

S. Khwaja, Cambridge, United Kingdom

M. Laugharne, Bristol, United Kingdom

P. Mehrotra, South Shields, United Kingdom

P. Najran, Manchester, United Kingdom

C. Smith, Leeds, United Kingdom

Advisory Editors: Radiology Systems/PACS

C. Cash, London, United Kingdom

S. Shamshuddin, Lancaster, United Kingdom

Advisory Editors: Radionuclide Radiology/PET

R. Graham, Bath, United Kingdom

V. Prakash, Ashford, United Kingdom

A. Scarsbrook, Leeds, United Kingdom

Advisory Editors: Thoracic

A. Awwad, Nottingham, United Kingdom

A. Barker, Cambridge, United Kingdom

C. Cash, London, United Kingdom

S. Copley, London, United Kingdom

S. Ganti, Singapore, Singapore

B. Hudson, Bath, United Kingdom

C. Johns, Sheffield, United Kingdom

A Nair, London, United Kingdom

G. Robinson, Bath, United Kingdom

N. Screaton, Cambridge, United Kingdom

A. Swift, Sheffield, United Kingdom

I. Vlahos, London, United Kingdom

D. Vummidi, Detroit, United States of America

Advisory Editors: Uro-Genital (inc. interventional)

M. Balogun, Birmingham, United Kingdom

T. Barrett, Cambridge, United Kingdom

J. Belfield, Liverpool, United Kingdom

V. Duddalwar, Los Angeles, United States of America

D. Maudgil, Slough, United Kingdom

M. Robinson, Cardiff, United Kingdom

B. Taylor, Manchester, United Kingdom

R. Wiles, Liverpool, United Kingdom

Advisory Editors: Vascular (inc. interventional)

A. Awwad, Nottingham, United Kingdom

S.B. Babu, Singapore, Singapore

S. Chandramohan, , Singapore

J. Cox, Sunderland, UK

R. Kasthuri, Glasgow, United Kingdom

G. Roditi, Glasgow, United Kingdom

N. Shaida, Cambridge, United Kingdom

R. Uberoi, Oxford, United Kingdom

Trainee AE

R. Frood, Leeds, United Kingdom

N. Parvizi, Oxford, United Kingdom

Editorial Office

Clinical Radiology Editorial Office, 21 Lion Close, Overton, Hampshire, RG25 3HL, , UK

GUIDE FOR AUTHORS

INTRODUCTION

Clinical Radiology is published under the auspices of The Royal College of Radiologists which appoints the Editor who selects all material for publication. No responsibility is accepted by The Royal College of Radiologists or the Editor for opinions expressed by the contributors.

The instructions below accord with the Uniform Requirements for Manuscripts Submitted to Biomedical Journals (http://www.icmje.org/). The journal supports the guidelines published by the Committee on Publication Ethics and the recommendations of the Standards for Reporting of Diagnostic Accuracy steering group and requires that authors do the same. The guidelines can be found at http://www.publicationethics.org.uk and http://www.stard-statement.org/ respectively.

The right is reserved to introduce any changes necessary to make contributions conform to the editorial standards and format of the journal. Original manuscripts will be accepted only on the understanding that they have been submitted exclusively to *Clinical Radiology*.

All papers accepted for publication in *Clinical Radiology* will appear on our online platforms. The Editor in Chief will decide which accepted papers will appear in the print version of the Journal.

Types of submission

Clinical Radiology invites submission of the following:

Original Papers should be no more than 3,500 words in length, and should contain no more than 10 illustrations (single frames), which will be printed at single column width.

Technical Reports should be no more than 2,000 words in length.

Review Articles* should not exceed 4,000 words and should include no more than 10 illustrations, which will be printed no larger than the width of a single column of text.

Pictorial Reviews* should not exceed 2,500 words and should include no more than 20 illustrations (single frame) which will be published at single column width.

Letters to the Editor concerning papers published in the journal, and other points of interest to readers, are welcomed by the Editor and are published at the Editor's discretion.

All text should be double-spaced.

* To avoid duplicating **review articles** and **pictorial reviews** please contact the editorial office (crad@editorial office.co.uk) if you are planning to write a review article for Clinical Radiology. Please include a short précis (100 words or less) describing the intended review and any novel aspects. Specify how many figures you will intend to include, referring to the instructions for authors for current requirements. Please note that a favourable response does not mean that the Journal has commissioned the review, simply that there is no clash with other papers in the pipeline. Submitted reviews are subject to peer review and publication is not guaranteed.

Additional illustrations : Illustrations in excess of the numbers specified above, including video

clips, may be included in the online version of the paper at the discretion of the Editor. This will only be considered if the additional material clearly adds value for readers of the paper, and the author will be responsible for identifying which key images he or she wishes to appear in the paper version. Despite the availability of this facility, the uncritical inclusion of large number of illustrations should be avoided, as it may reduce the likelihood of acceptance.

Contact Details

If you have any queries, contact Clinical Radiology, Editorial Office, 21 Lion Cose, Overton,Hampshire, RG25 3HL.

Tel: +44 (0)845 834 0370; Fax: 044 (0)1256 771303; Email: crad@editorialoffice.co.uk

Submission checklist

You can use this list to carry out a final check of your submission before you send it to the journal for review. Please check the relevant section in this Guide for Authors for more details.

Ensure that the following items are present:

One author has been designated as the corresponding author with contact details:

- E-mail address
- Full postal address

All necessary files have been uploaded:

Manuscript:

- Include keywords
- All figures (include relevant captions)
- All tables (including titles, description, footnotes)
- Ensure all figure and table citations in the text match the files provided
- Indicate clearly if color should be used for any figures in print

Graphical Abstracts / Highlights files (where applicable)

Supplemental files (where applicable)

Further considerations

- Manuscript has been 'spell checked' and 'grammar checked'
- All references mentioned in the Reference List are cited in the text, and vice versa
- Permission has been obtained for use of copyrighted material from other sources (including the Internet)
- A competing interests statement is provided, even if the authors have no competing interests todeclare
- Journal policies detailed in this guide have been reviewed
- Referee suggestions and contact details provided, based on journal requirements

For further information, visit our Support Center.

BEFORE YOU BEGIN

Ethics in publishing

Please see our information pages on Ethics in publishing and Ethical guidelines for journal publication.

Studies in humans and animals

If the work involves the use of human subjects, the author should ensure that the work described has been carried out in accordance with The Code of Ethics of the World Medical Association (Declaration of Helsinki) for experiments involving humans. The manuscript should be in line with theRecommendations for the Conduct, Reporting, Editing and Publication of Scholarly Work in Medical Journals and aim for the inclusion of representative human populations (sex, age and ethnicity) as per those recommendations. The terms sex and gender should be used correctly.

Authors should include a statement in the manuscript that informed consent was obtained for experimentation with human subjects. The privacy rights of human subjects must always be observed.

All animal experiments should comply with the ARRIVE guidelines and should be carried out in accordance with the U.K. Animals (Scientific Procedures) Act, 1986 and associated guidelines, EU Directive 2010/63/EU for animal experiments, or the National Institutes of Health guide for the careand use of Laboratory animals (NIH Publications No. 8023, revised 1978) and the authors should clearly indicate in the manuscript that such guidelines have been followed. The sex of animals must be indicated, and where appropriate, the influence (or association) of sex on the results of the study.

Informed consent and patient details

Studies on patients or volunteers require ethics committee approval and informed consent, which should be documented in the paper. Appropriate consents, permissions and releases must be obtained where an author wishes to include case details or other personal information or images of patients and any other individuals in an Elsevier publication. Written consents must be retained by the authorbut copies should not be provided to the journal. Only if specifically requested by the journal in exceptional circumstances (for example if a legal issue arises) the author must provide copies of the consents or evidence that such consents have been obtained. For more information, please review theElsevier Policy on the Use of Images or Personal Information of Patients or other Individuals. Unless you have written permission from the patient (or, where applicable, the next of kin), the personal details of any patient included in any part of the article and in any supplementary materials (including all illustrations and videos) must be removed before submission.

Declaration of competing interest

All authors must disclose any financial and personal relationships with other people or organizationsthat could inappropriately influence (bias) their work. Examples of potential conflicts of interest include employment, consultancies, stock ownership, honoraria, paid expert testimony, patent applications/

registrations, and grants or other funding. Authors should create a declaration of competing interestsstatement using this tool and upload to the submission system at the Attach Files step. **Note: Pleasedo not convert the .docx template to another file type. Author signatures are not required.**This statement will be published within the article if accepted.

Submission declaration

Submission of an article implies that the work described has not been published previously (except inthe form of an abstract, a published lecture or academic thesis, see 'Multiple, redundant or concurrent publication' for more information), that it is not under consideration for publication elsewhere, that its publication is approved by all authors and tacitly or explicitly by the responsible authorities where the work was carried out, and

that, if accepted, it will not be published elsewhere in the same form, inEnglish or in any other language, including electronically without the written consent of the copyright-holder.

Author Contributions

Authors are required to identify the contributions for which they are responsible. The author responsible for the integrity of the entire study should be identified. Please list the following phrasesand beside each indicate the name(s) of the author(s) to whom they apply:

1 guarantor of integrity of the
entire study2 study concepts
and design
3 literature research
4 clinical studies
5 experimental studies / data
analysis6 statistical analysis
7 manuscript preparation
8 manuscript editing

Items that do not apply should also be indicated with N/A. Where there is any uncertainty regardingauthorship the editor of the study reserves the right to contact the guarantor of the study for furtherinformation.

Use of inclusive language

Inclusive language acknowledges diversity, conveys respect to all people, is sensitive to differences,and promotes equal opportunities. Content should make no assumptions about the beliefs or commitments of any reader; contain nothing which might imply that one individual is superior to another on the grounds of age, gender, race, ethnicity, culture, sexual orientation, disability or health condition; and use inclusive language throughout. Authors should ensure that writing is free from bias, stereotypes, slang, reference to dominant culture and/or cultural assumptions. We advise to seek gender neutrality by using plural nouns ("clinicians, patients/clients") as default/wherever possible to avoid using "he, she," or "he/she." We recommend avoiding the use of descriptors that refer to personal attributes such as age, gender, race, ethnicity, culture, sexual orientation, disability or health condition unless they are relevant and valid. These guidelines are meant as a point of reference to help identify appropriate language but are by no means exhaustive or definitive.

Changes to authorship

Authors are expected to consider carefully the list and order of authors **before** submitting their manuscript and provide the definitive list of authors at the time of the

original submission. Any addition, deletion or rearrangement of author names in the authorship list should be made only **before** the manuscript has been accepted and only if approved by the journal Editor. To request sucha change, the Editor must receive the following from the **corresponding author**: (a) the reasonfor the change in author list and (b) written confirmation (e-mail, letter) from all authors that they agree with the addition, removal or rearrangement. In the case of addition or removal of authors, this includes confirmation from the author being added or removed.

Only in exceptional circumstances will the Editor consider the addition, deletion or rearrangement ofauthors **after** the manuscript has been accepted. While the Editor considers the request, publicationof the manuscript will be suspended. If the manuscript has already been published in an online issue,any requests approved by the Editor will result in a corrigendum.

Copyright

Upon acceptance of an article, authors will be asked to complete a 'Journal Publishing Agreement' (see more information on this). An e-mail will be sent to the corresponding author confirming receipt of the manuscript together with a 'Journal Publishing Agreement' form or a link to the online version of this agreement.

Subscribers may reproduce tables of contents or prepare lists of articles including abstracts for internal circulation within their institutions. Permission of the Publisher is required for resale or distribution outside the institution and for all other derivative works, including compilations and translations. If excerpts from other copyrighted works are included, the author(s) must obtain written permission from the copyright owners and credit the source(s) in the article. Elsevier has preprinted forms for use by authors in these cases.

Author rights

As an author you (or your employer or institution) have certain rights to reuse your work. Moreinformation.

Elsevier supports responsible sharing

Find out how you can share your research published in Elsevier journals.

Role of the funding source

You are requested to identify who provided financial support for the conduct of the research and/or preparation of the article and to briefly describe the role of the sponsor(s), if any, in study design; inthe collection, analysis and interpretation of data; in the writing of the report; and in the decision tosubmit the article for publication. If the funding source(s) had no such involvement then this shouldbe stated.

Open access

Please visit our Open Access page for more information.

Language (usage and editing services)

Please write your text in good English (American or British usage is accepted, but not a mixture of these). Authors who feel their English language manuscript may require editing to eliminate possible grammatical or spelling errors and to conform to correct scientific English may wish to use the English Language Editing service available from Elsevier's Author Services.

Submission

Our online submission system guides you stepwise through the process of entering your article details and uploading your files. The system converts your article files to a single PDF file used in the peer-review process. Editable files (e.g., Word, LaTeX) are required to typeset your article for final publication. All correspondence, including notification of the Editor's decision and requests for revision, is sent by e-mail.

Submit your article

Please submit your article via http://www.editorialmanager.com/crad/.

PREPARATION

Please add continuous line numbers to your main manuscript file.

Double anonymized review

This journal uses double anonymized review, which means the identities of the authors are concealed from the reviewers, and vice versa. More information is available on our website. To facilitate this, please include the following separately:
Title page (with author details): This should include the title, authors' names, affiliations, acknowledgements and any Declaration of Interest statement, and a complete address for the corresponding author including an e-mail address.
Anonymized manuscript (no author details): The main body of the paper (including the references, figures, tables and any acknowledgements) should not include any identifying information, such as the authors' names or affiliations.

Use of word processing software

It is important that the file be saved in the native format of the word processor used. The text should be in single-column format. Keep the layout of the text as simple as possible. Most formatting codes will be removed and replaced on processing the article. In particular, do not use the word processor's options to justify text or to hyphenate words. However, do use bold face, italics, subscripts, superscripts etc. When preparing tables, if

you are using a table grid, use only one grid for each individual table and not a grid for each row. If no grid is used, use tabs, not spaces, to align columns.The electronic text should be prepared in a way very similar to that of conventional manuscripts (see also the Guide to Publishing with Elsevier). Note that source files of figures, tables and text graphics will be required whether or not you embed your figures in the text. See also the section on Electronicartwork.

To avoid unnecessary errors you are strongly advised to use the 'spell-check' and 'grammar-check' functions of your word processor.

Article structure

Subdivision - unnumbered sections

Divide your article into clearly defined sections. Each subsection is given a brief heading. Each heading should appear on its own separate line. Subsections should be used as much as possible when cross-referencing text: refer to the subsection by heading as opposed to simply 'the text'.

Introduction

State the objectives of the work and provide an adequate background, avoiding a detailed literaturesurvey or a summary of the results.

Materials and Methods

Describe clearly the number and selection of the subjects studied (patients or experimental animals, including controls). For studies of the diagnostic accuracy of new imaging tests, authors should refer to the STARD recommendations (http://www.stard-statement.org). Identify the methods, instrumentation (manufacturer's name and address in parentheses), and procedures in sufficient detail to allow other workers to reproduce the results. Give references to established methods, including statistical methods that have been published but are not well known; describe new or substantially modified methods and give reasons for using these techniques. Detailed statistical analyses, mathematical derivations and similar should be presented in one or more appendices.

Results

Results should be clear and concise.

Discussion

This should explore the significance of the results of the work, not repeat them. A combined Resultsand Discussion section is often appropriate. Avoid extensive citations and discussion of published literature.

Essential title page information

- ***Title.*** Concise and informative. Titles are often used in information-retrieval systems. Avoid abbreviations and formulae where possible.
- ***Author names and affiliations.*** Please clearly indicate the given name(s) and family name(s)of each author and check that all names are accurately spelled. You can add your name between parentheses in your own script behind the English transliteration. Present the authors' affiliation addresses (where the actual work was done) below the names. Indicate all affiliations with a lower-case superscript letter immediately after the author's name and in front of the appropriate address.Provide the full postal address of each affiliation, including the country name and, if available, the e-mail address of each author.
- ***Corresponding author.*** Clearly indicate who will handle correspondence at all stages of refereeing and publication, also post-publication. This responsibility includes answering any future queries about Methodology and Materials. **Ensure that the e-mail address is given and that contact details are kept up to date by the corresponding author.**
- ***Present/permanent address.*** If an author has moved since the work described in the article wasdone, or was visiting at the time, a 'Present address' (or 'Permanent address') may be indicated as a footnote to that author's name. The address at which the author actually did the work must be retained as the main, affiliation address. Superscript Arabic numerals are used for such footnotes.

Please ensure that you include any acknowledgements in your Title Page. List here those individualswho provided help during the research (e.g., providing language help, writing assistance or proof reading the article, etc.).

Highlights

Highlights are mandatory for this journal as they help increase the discoverability of your article viasearch engines. They consist of a short collection of bullet points that capture the novel results of your research as well as new methods that were used during the study (if any). Please have a look at the examples here: example Highlights.

Highlights should be submitted in a separate editable file in the online submission system. Please use 'Highlights' in the file name and include 3 to 5 bullet points (maximum 85 characters, including spaces, per bullet point).

Abstract

A concise and factual abstract of no more than 250 words is required. The abstract should state brieflythe purpose of the research, the principal results and major conclusions. An abstract is often presentedseparately from the article, so it must be able to stand alone. For this reason, References shouldbe avoided, but if essential, then cite the author(s) and year(s). Also, non-standard or uncommon abbreviations should be avoided, but if essential they must be defined at their first mention in the abstract itself.

Units and Abbreviations

Radiation measurements and laboratory values should be given in the International System of Units(SI) (see: SI Units in Radiation Protection and Measurements. NCRP Report no. 82 [August 1985]).Abbreviations should be used sparingly and only when the term appears more than 10 times in thefollowing text. Abbreviations should be spelled out when first used in the text such as 'cerebrospinalfluid (CSF)'. Laboratory slang, clinical jargon, and uncommon abbreviations should be avoided.

Formatting of funding sources

List funding sources in this standard way to facilitate compliance to funder's requirements:

Funding: This work was supported by the National Institutes of Health [grant numbers xxxx, yyyy];the Bill & Melinda Gates Foundation, Seattle, WA [grant number zzzz]; and the United States Institutesof Peace [grant number aaaa].

It is not necessary to include detailed descriptions on the program or type of grants and awards. Whenfunding is from a block grant or other resources available to a university, college, or other researchinstitution, submit the name of the institute or organization that provided the funding.

If no funding has been provided for the research, please include the following sentence:

This research did not receive any specific grant from funding agencies in the public, commercial, ornot-for-profit sectors.

Artwork

Image manipulation

Whilst it is accepted that authors sometimes need to manipulate images for clarity, manipulation forpurposes of deception or fraud will be seen as scientific ethical abuse and will be dealt with accordingly. For graphical images, this journal is applying the following policy: no specific feature within an image may be enhanced, obscured, moved, removed, or introduced. Adjustments of brightness, contrast, or color balance are acceptable if and as long as they do not obscure or eliminate any information present in the original. Nonlinear adjustments (e.g. changes to gamma settings) must be disclosed in the figure legend.

Electronic artwork

General Points

- Make sure you use uniform lettering and sizing of your original artwork.

- Embed the used fonts if the application provides that option.
- Aim to use the following fonts in your illustrations: Arial, Courier, Times New Roman, Symbol, or use fonts that look similar.
- Number the illustrations according to their sequence in the text.
- Use a logical naming convention for your artwork files.
- Provide captions to illustrations separately.
- Size the illustrations close to the desired dimensions of the published version.
- Submit each illustration as a separate file.
- Ensure that color images are accessible to all, including those with impaired color vision.

A detailed guide on electronic artwork is available.

You are urged to visit this site; some excerpts from the detailed information are given here.

Formats

If your electronic artwork is created in a Microsoft Office application (Word, PowerPoint, Excel) thenplease supply 'as is' in the native document format. Regardless of the application used other than Microsoft Office, when your electronic artwork is finalized, please 'Save as' or convert the images to one of the following formats (note the resolutionrequirements for line drawings, halftones, and line/halftone combinations given below):
EPS (or PDF): Vector drawings, embed all used fonts.
TIFF (or JPEG): Color or grayscale photographs (halftones), keep to a minimum of 300 dpi.
TIFF (or JPEG): Bitmapped (pure black & white pixels) line drawings, keep to a minimum of 1000 dpi.TIFF (or JPEG): Combinations bitmapped line/half-tone (color or grayscale), keep to a minimum of 500 dpi.

Please do not:

- Supply files that are optimized for screen use (e.g., GIF, BMP, PICT, WPG); these typically have alow number of pixels and limited set of colors;
- Supply files that are too low in resolution;
- Submit graphics that are disproportionately large for the content.

Color artwork

Please make sure that artwork files are in an acceptable format (TIFF (or JPEG), EPS (or PDF) or MS Office files) and with the correct resolution. If, together with your accepted article, you submit usable color figures then Elsevier will ensure, at no additional charge, that these figures will appearin color online (e.g., ScienceDirect and

other sites) in addition to color reproduction in print. Further information on the preparation of electronic artwork.

Illustration services

Elsevier's Author Services offers Illustration Services to authors preparing to submit a manuscript butconcerned about the quality of the images accompanying their article. Elsevier's expert illustrators can produce scientific, technical and medical-style images, as well as a full range of charts, tables and graphs. Image 'polishing' is also available, where our illustrators take your image(s) and improvethem to a professional standard. Please visit the website to find out more.

Figure captions

Ensure that each illustration has a caption. Supply captions separately, not attached to the figure. Acaption should comprise a brief title (**not** on the figure itself) and a description of the illustration. Keep text in the illustrations themselves to a minimum but explain all symbols and abbreviations used.

Tables

Please submit tables as editable text and not as images. Tables can be placed either next to the relevant text in the article, or on separate page(s) at the end. Number tables consecutively in accordance with their appearance in the text and place any table notes below the table body. Be sparing in the use of tables and ensure that the data presented in them do not duplicate results described elsewhere in the article. Please avoid using vertical rules and shading in table cells.

References

Citation in text

Please ensure that every reference cited in the text is also present in the reference list (and vice versa). Any references cited in the abstract must be given in full. Unpublished results and personal communications are not recommended in the reference list, but may be mentioned in the text. If thesereferences are included in the reference list they should follow the standard reference style of the journal and should include a substitution of the publication date with either 'Unpublished results' or 'Personal communication'. Citation of a reference as 'in press' implies that the item has been accepted for publication.

Reference links

Increased discoverability of research and high quality peer review are ensured by online links tothe sources cited. In order to allow us to create links to abstracting and indexing services, such as Scopus, CrossRef and PubMed, please ensure that data provided in the references are correct. Pleasenote that incorrect surnames, journal/book

titles, publication year and pagination may prevent link creation. When copying references, please be careful as they may already contain errors. Use of theDOI is highly encouraged.

A DOI is guaranteed never to change, so you can use it as a permanent link to any electronic article.An example of a citation using DOI for an article not yet in an issue is: VanDecar J.C., Russo R.M., James D.E., Ambeh W.B., Franke M. (2003). Aseismic continuation of the Lesser Antilles slab beneath northeastern Venezuela. Journal of Geophysical Research, https://doi.org/10.1029/2001JB000884. Please note the format of such citations should be in the same style as all other references in the paper.

Web references

As a minimum, the full URL should be given and the date when the reference was last accessed. Anyfurther information, if known (DOI, author names, dates, reference to a source publication, etc.), should also be given. Web references can be listed separately (e.g., after the reference list) under adifferent heading if desired, or can be included in the reference list.

Data references

This journal encourages you to cite underlying or relevant datasets in your manuscript by citing themin your text and including a data reference in your Reference List. Data references should include thefollowing elements: author name(s), dataset title, data repository, version (where available), year, and global persistent identifier. Add [dataset] immediately before the reference so we can properly identify it as a data reference. The [dataset] identifier will not appear in your published article.

Reference style

Number references consecutively in the order in which they are first mentioned. Please limit references to no more than 30. The abbreviations used for periodicals cited in the references should follow thefollowing style:

For journal articles, list surnames and initials of all authors when six or less, such as:
1 Stuart MJ, Elrad H, Graeber JE, Hakanson DO, Sunderji SG, Barvinchak MK. Increased synthesis ofprostaglandin endoperoxides and platelet hyperfunction in infants of mothers with diabetes mellitus.J Lab Clin Med 1979;94:1226.
When seven or more authors are listed, only the first three names need to be identified, followedby 'et al'.

Abstracts, editorials and letters to the Editor should be noted as such. In the case of

books, the authors of a chapter, title of the chapter, editor(s), title of the book, edition, city, publisher, year, andspecific pages must be provided:
1 Brown M, Gray L. Indications for hematology. In: Wintrobe MM, ed. Clinical Hematology. 3rd ed. Philadelphia, USA: Lea & Febiger, 1975;1146-1167.

A reference to any website containing background information should list the authors and title (if appropriate), the date it was accessed and the DOI if possible. At the very least, the URL of the website and the date it was accessed should be given

Journal abbreviations source

Journal names should be abbreviated according to the List of Title Word Abbreviations.

Video

Elsevier accepts video material and animation sequences to support and enhance your scientific research. Authors who have video or animation files that they wish to submit with their article are strongly encouraged to include links to these within the body of the article. This can be done in the same way as a figure or table by referring to the video or animation content and noting in the bodytext where it should be placed. All submitted files should be properly labeled so that they directly relate to the video file's content. In order to ensure that your video or animation material is directlyusable, please provide the file in one of our recommended file formats with a preferred maximum size of 150 MB per file, 1 GB in total. Video and animation files supplied will be published online in the electronic version of your article in Elsevier Web products, including ScienceDirect. Please supply 'stills' with your files: you can choose any frame from the video or animation or make a separate image. These will be used instead of standard icons and will personalize the link to your video data. For more detailed instructions please visit our video instruction pages. Note: since video and animation cannot be embedded in the print version of the journal, please provide text for both the electronic and the print version for the portions of the article that refer to this content.

Supplementary material

Supplementary material such as applications, images and sound clips, can be published with your article to enhance it. Submitted supplementary items are published exactly as they are received (Excel or PowerPoint files will appear as such online). Please submit your material together with the articleand supply a concise, descriptive caption for each supplementary file. If you wish to make changes tosupplementary material during any stage of the process, please make sure to provide an updated file.Do not annotate any corrections on a previous version. Please switch off the 'Track Changes' option in Microsoft Office files as these will appear in the published version.

AFTER ACCEPTANCE

Proofs

One set of page proofs (as PDF files) will be sent by e-mail to the corresponding author (if we do nothave an e-mail address then paper proofs will be sent by post) or a link will be provided in the e- mail so that authors can download the files themselves. To ensure a fast publication process of the article, we kindly ask authors to provide us with their proof corrections within two days. Elsevier now provides authors with PDF proofs which can be annotated; for this you will need to download the freeAdobe Reader, version 9 (or higher). Instructions on how to annotate PDF files will accompany the proofs (also given online). The exact system requirements are given at the Adobe site.

If you do not wish to use the PDF annotations function, you may list the corrections (including repliesto the Query Form) and return them to Elsevier in an e-mail. Please list your corrections quoting linenumber. If, for any reason, this is not possible, then mark the corrections and any other comments(including replies to the Query Form) on a printout of your proof and scan the pages and return via e-mail. Please use this proof only for checking the typesetting, editing, completeness and correctnessof the text, tables and figures. Significant changes to the article as accepted for publication will onlybe considered at this stage with permission from the Editor. We will do everything possible to get yourarticle published quickly and accurately. It is important to ensure that all corrections are sent back to us in one communication: please check carefully before replying, as inclusion of any subsequent corrections cannot be guaranteed. Proofreading is solely your responsibility.

Offprints

The corresponding author will, at no cost, receive a customized Share Link providing 50 days free access to the final published version of the article on ScienceDirect. The Share Link can be used for sharing the article via any communication channel, including email and social media. For an extra charge, paper offprints can be ordered via the offprint order form which is sent once the article is accepted for publication. Both corresponding and co-authors may order offprints at any time via Elsevier's Author Services. Corresponding authors who have published their article gold open access do not receive a Share Link as their final published version of the article is available open access on ScienceDirect and can be shared through the article DOI link.

AUTHOR INQUIRIES

Visit the Elsevier Support Center to find the answers you need. Here you will find everything from Frequently Asked Questions to ways to get in touch.

You can also check the status of your submitted article or find out when your accepted article willbe published.