

https://dspace.org/

The spectrum of conjunctival squamous cell carcinoma at St John Eye Hospital

Dolland, Riana Sarita

2014-02-21
http://hdl.handle.net10539/13910

Downloaded from a DSpace repository. https://dspace.org/

THE SPECTRUM OF CONJUNCTIVAL SQUAMOUS CELL CARCINOMA AT ST JOHN EYE HOSPITAL

RIANA SARITA DOLLAND

A research report submitted to the faculty of Health Sciences, University of the Witwatersrand, in the fulfillment of the requirements for the degree of Master of Medicine in Ophthalmology. June 2013

DECLARATION

I hereby declare that this research report is my own unaided work. It is being submitted for the degree of Master of Medicine in the branch of Ophthalmology at the University of the Witwatersrand, Johannesburg. It has not been submitted before for any degree or examination in any other University.

Signed _____

This _____day of _____ 2013

The work reported in this research report was carried out in the Department of Ophthalmology, St John Eye Hospital (Chris Hani Baragwanath Hospital), Johannesburg, South Africa.

The project was approved by the Ethics Committee, University of the Witwatersrand.

DEDICATION

This research report is dedicated to my father Dr. Edward Thomas Clarke who has been a constant inspiration and motivation throughout my life. Dad you have always told me I can do anything if I put my mind to it…

Thank you for always believing in me and pushing me to do my best at every juncture in my life. Your constant encouragement has allowed me to be the person that I am today and I will pass these values on to my children.

ABSTRACT

Purpose: To determine the spectrum of ocular surface squamous cell neoplasia (OSSN) in young patients presenting at the St John Eye hospital. The objectives were: (1) documentation of the occurrence of OSSN in young patients at St John Eye hospital (2) to determine the possible role of HIV as a risk factor and the correlation of disease severity with CD4 count.

Method: A retrospective case series analysis of patient's histo-pathological and medical records between January 2007 and June 2011. Conjunctival biopsies had been submitted to the National Health Laboratory Services (NHLS) for histo-pathological analysis and patients within the inclusion criteria had the following information extracted: patient demographics, histo-pathological diagnosis, HIV status and CD4 count, where available.

Results: Of the 934 conjunctival biopsies retrieved from the NHLS, 185 had confirmed OSSN. Median age 32.9, 119 (65.0%) were female and 64 (35.0%) male.

Mild conjunctival intraepithelial neoplasia (CIN) was found in 26 (14.1%), moderate CIN in 54 (29.2%), carcinoma *in-situ* in 87 (47.0%) and squamous cell carcinoma (SCC) in 18 (9.7%).

HIV results were available only for 16 (12%) patients of whom all were positive and the remainder unknown. CD4 count was available in 14 patients with a mean of 244.

Conclusion: Young females in their 30's are most affected, and pre-invasive lesions are common. From limited data, HIV may be a risk factor but a prospective study with a larger cohort is recommended.

ACKNOWLEDGEMENTS

It is with deep appreciation that the following persons are acknowledged:

1. Prof. I. Mayet: for your advice, knowledge and expertise to complete this project successfully.
2. Prof. T.R. Carmichael: for your knowledge and expertise.
3. Prof. M.J. Hale: for your permission to access the data from the NHLS snowmed system, histopathology photographs and your advice throughout this project.
4. Dr P.Lingham: for permission to access patient medical records and files from the St. John Eye Hospital
5. Dr J. Fadah for the statistical analysis of the data.
6. Dr K.M. Koetsie for giving me the idea for my MMed topic and constantly pushing me to complete this report.
7. The St John Eye Hospital and NHLS staff for assisting me in accessing the patient records.

TABLE OF CONTENTS

DECLARATION II

DEDICATION III

ABSTRACT IV

ACKNOWLEDGEMENTS VI

TABLE OF CONTENTS VII

LIST OF FIGURES IX

LIST OF TABLES X

CHAPTER 1 1

1. INTRODUCTION 1

1.1. Problem statement 2

1.2. Justification for the study 2

1.3. Background 2

1.3.1. Anatomy and Physiology 2

1.3.2. Pathogenesis and clinical features 4

1.4. Literature review 10

1.4.1. Global Incidence 10

1.4.2. Epidemiology and Pathogenesis 10

1.4.3. Clinical presentation and Treatment 12

1.5. Research Aim 13

1.6. Research Objective 14

CHAPTER 2 15

2. METHODOLOGY 15

2.1. Study design 15

2.2. Inclusion criteria 15

2.3. Data Collection 16

2.4. Study population 16

2.5. Data management 17

2.6. Data analysis 17

2.7. Ethical considerations 17

CHAPTER 3 19

3. RESULTS 19

3.1. Patient Demographics 19

3.2. Lesion type 19

3.3. Dysplastic lesion analysis, including sex and age 20

3.3.1. Table 1 – Analysis of dysplastic lesions 20

3.3.2. Table 2 – Distribution of conjunctival biopsies with respect to males and females 21

3.3.3. Table 3 – Distribution of conjunctival biopsies with respect to patient age 21

3.4. HIV and CD4 results 22

3.4.1. Table 4 – Analysis of CD4 count 22

CHAPTER 4 23

DISCUSSION 23

CONCLUSION 27

REFERENCES.....28
APPENDIX A: DATA CAPTURING SHEET.....32
APPENDIX B: ETHICS CERTIFICATE.....33
APPENDIX C: APPROVAL TO ACCESS MEDICAL RECORDS..... 34

LIST OF FIGURES

FIGURE 1.1 CROSS SECTION OF THE GLOBE DEMONSTRATING THE THREE CONJUNCTIVAL AREAS (REPRODUCED FROM GK LANG, OPHTHALMOLOGY ATLAS 2ND EDITION, 2006 *)*……..…….3

FIGURE 1.2 NORMAL SQUAMOUS EPITHELIUM UNDERGOING SQUAMOUS METAPLASIA & PROGRESSING TO FULL THICKNESS DYSPLASIA (1) WITH INVASIVE SQUAMOUS CARCINOMA (2) (COURTESY OF PROFESSOR MJ HALE)……...5

Figure 1.3 FULL THICKNESS DYSPLASIA OF THE CONJUNCTIOVAL EPITHELIUM WITH SEVERE ACTINIC ELASTOSIS OF THE UNDERLYING SUBSTANTIA PROPRIA (COURTESY OF PROFESSOR MJ HALE)……..6

FIGURE 1.4 PIGMENTED PAPILLOMATOUS CONJUNCTIVAL INTRAEPITHELIAL NEOPLASIA (REPRODUCED WITH PATIENT PERMISSION)……...6

FIGURE 1.5 INFILTRATING SQUAMOUS CARCINOMA (1) WITH SEVERE, ADJACENT ACTINIC ELASTOSIS OF THE UNDERLYING SUBSTANTIA PROPRIA (2) (COURTESY OF PROFESSOR MJ HALE)……..……8

FIGURE 1.6 SQUAMOUS CELL CARCINOMA OF THE CONJUNCTIVA WITH NEARLY 360° LIMBAL LEUCOKPLAKIA AND FEEDER VESSELS (R*EPRODUCED WITH* PATIENT *PERMISSION)*……...9

FIGURE 1.7 SQUAMOUS CELL CARCINOMA OF THE CONJUNCTIVA AND CORNEA WITH ASSOCIATED FEEDER VESSELS AND LEUKOPLAKIA (R*EPRODUCED WITH PATIENT PERMISSION)*…..…….....9

LIST OF TABLES

TABLE 1 ANALYSIS OF DYSPLASTIC LESIONS ……..20

TABLE 2 DISTRIBUTION OF CONJUNCTIVAL BIOPSIES WITH RESPECT TO MALES AND FEMALES……21

TABLE 3 DISTRIBUTION OF CONJUNCTIVAL BIOPSIES WITH RESPECT TO PATIENT AGE……21

TABLE 4 ANALYSIS OF HIV AND CD4 COUNT…….....22

Chapter 1

This chapter describes the background, justification and overall research question of the study. The relevant literature related to the topic will be presented as well as the aims and objectives of the study.

1. Introduction

Squamous cell carcinoma of the conjunctiva is part of a spectrum of conditions called ocular surface squamous neoplasia (OSSN). The term OSSN was first described by Lee and Hirst in 1995[1] as an umbrella term that encompasses intraepithelial and invasive squamous cell carcinoma of the conjunctiva and cornea.

In the study previously cited, the clinical spectrum of this condition begins with simple dysplasia and ends with invasive conjunctival squamous cell carcinoma (CSCC). OSSN denotes neoplastic lesions of epithelial origin that can involve the conjunctiva or the cornea, but more commonly begins in the conjunctiva and extends across the limbus to involve the cornea. This condition is important because of its potential to cause ocular and even systemic morbidity and mortality.[1]

In the past two decade OSSN has increased in prevalence throughout sub-Saharan Africa due to a variety of aetiological factors. These include; human

immunodeficiency virus (HIV), human papillomavirus (HPV) and ultraviolet (UV)-light exposure, which are causing a growing epidemic throughout the continent.[2]

1.1. Problem statement

OSSN is a growing problem in sub-Saharan Africa with a rapid rise being noted in young black South Africans.

1.2. Justification for the study

The rising trend of CSCC in South Africa requires analysis to determine the most common type of lesion within the spectrum of OSSN. The impact of HIV and CD4 count on this trend also needs assessment to establish whether there is a significant relationship, among our patients, with this common risk factor.

1.3. Background

1.3.1. Anatomy and Physiology

The conjunctiva is a thin mucous membrane that lines the inner eyelids and is reflected at the superior and inferior fornices onto the anterior surface of the eyeball. It covers part of the sclera and its epithelium is continuous with that of the cornea (figure 1.1).

The conjunctiva can be divided into three regions:

The palpebral conjunctiva, the conjuctival fornices and the bulbar conjunctiva. The palpebral conjunctiva extends from the lid margin and lines the eyelids and is firmly adherent to the posterior surface of the tarsal plate. The conjunctival fornix is a transitional zone between the palpebral and bulbar conjunctiva and is loosely attached to the underlying fascial expansions.[3]

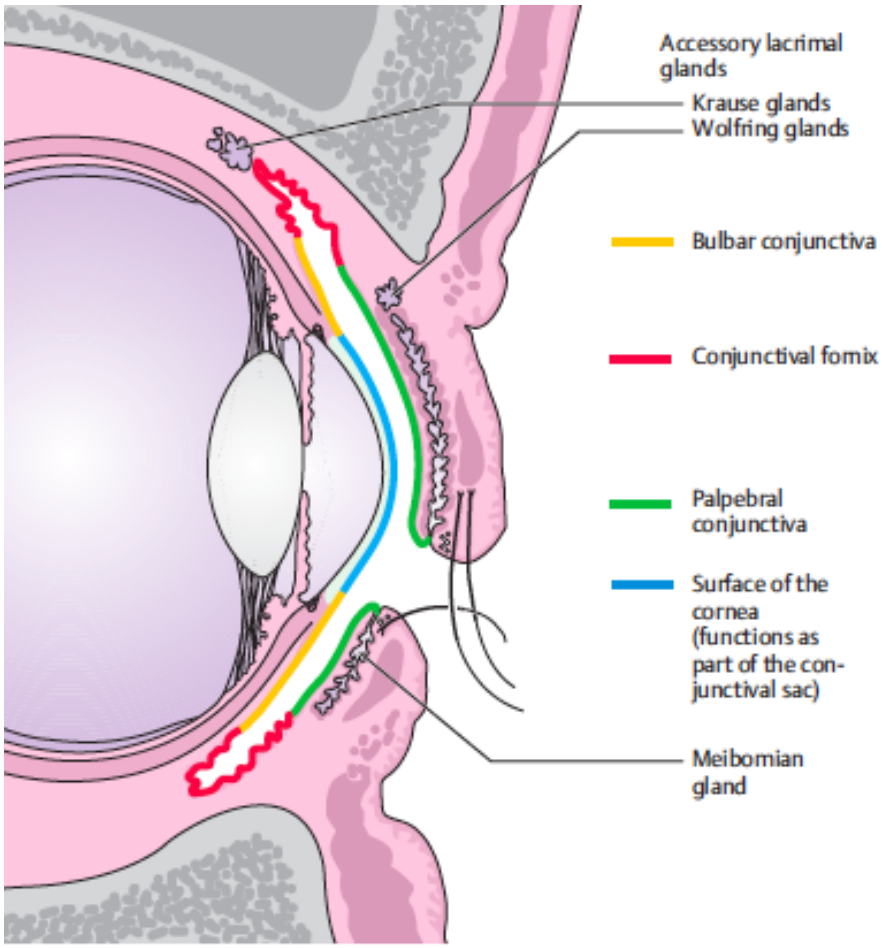

FIGURE 1.1: CROSS SECTION OF THE GLOBE DEMONSTRATING THE THREE CONJUNCTIVAL AREAS (REPRODUCED FROM LANG GK, OPHTHALMOLOGY ATLAS, 2ND EDITION, 2006)

The bulbar conjunctiva, which is the primary site of OSSN, consists of cuboidal stratified epithelium that rests on a thin basement membrane. The epithelium is two

to three cell layers thick and the cell membranes contain infoldings and microvilli. The conjunctival cells harbor many organelles, particularly mitochondria. The main functions of the conjunctiva are to provide mucus for the tear film and protect the ocular surface from pathogens, both as a physical barrier and as a source of inflammatory cells.[4]

1.3.2. Pathogenesis and clinical features

The term OSSN encompasses conjunctival intraepithelial (CIN) and invasive squamous cell carcinoma of the conjunctiva and cornea. This includes a disease spectrum characterized by replacement of the normal conjunctival epithelium by atypical squamous cells (figure 1.2).

In mild CIN less than 50% of the epithelial layer is involved and in severe dysplasia greater than 50% contains dysplastic cells (figure 1.3). Clinically, CIN usually presents as an ill-defined gelatinous lesions that blends with the surrounding normal conjunctiva. The surface usually shows keratinization (leukoplakia), which appears as focal thickening of the stratified squamous epithelium with a superficial plaque of opaque white hyperkeratosis. It can also appear as a sessile papillomatous lesion that appears as highly vascularized[5] (figure 1.4).

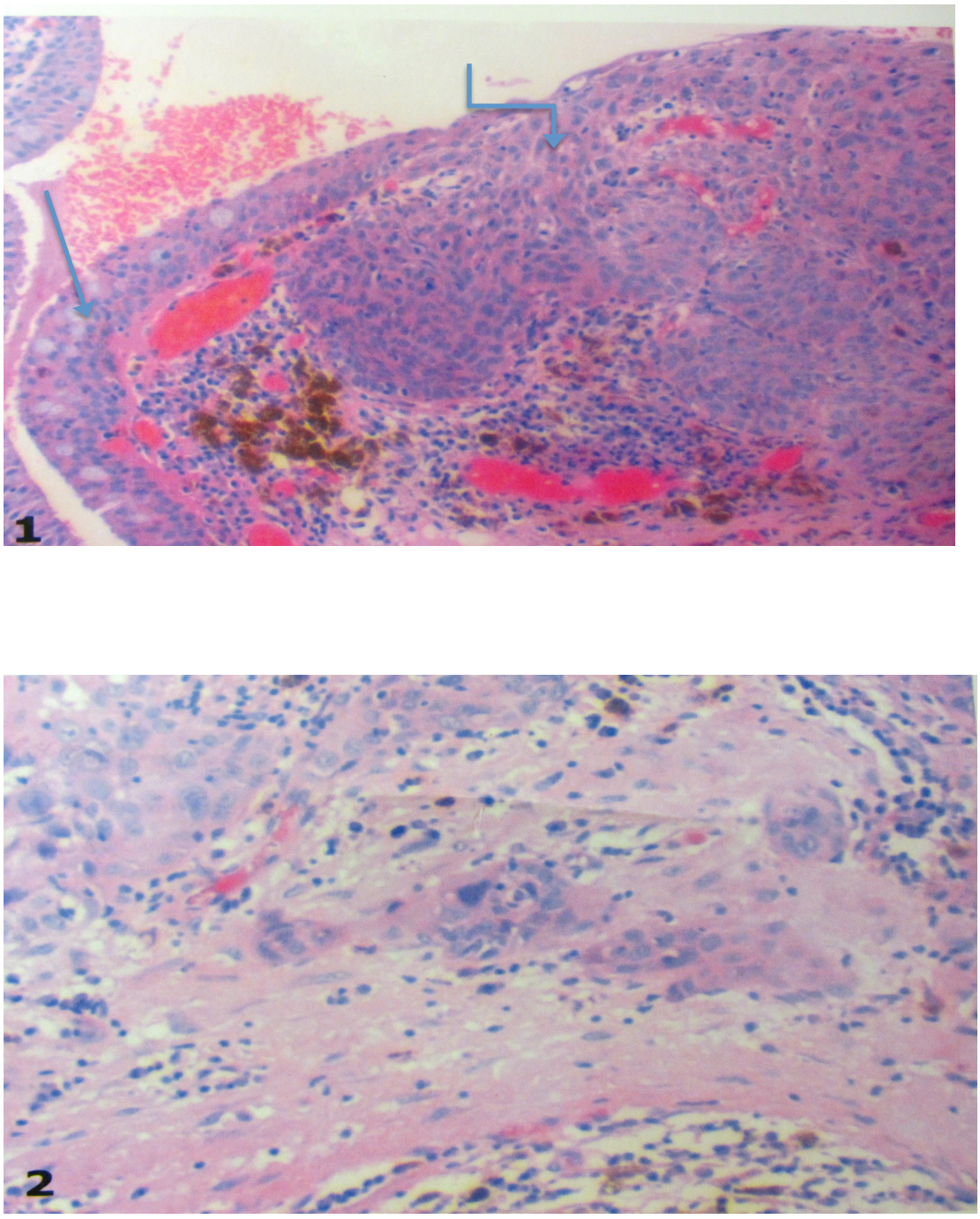

FIGURE 1.2: NORMAL SQUAMOUS EPITHELIUM (STRAIGHT ARROW) UNDERGOING SQUAMOUS METAPLASIA (BENT ARROW) & PROGRESSING TO FULL THICKNESS DYSPLASIA (1) WITH INVASIVE SQUAMOUS CARCINOMA (2) (COURTESY OF PROFESSOR MJ HALE)

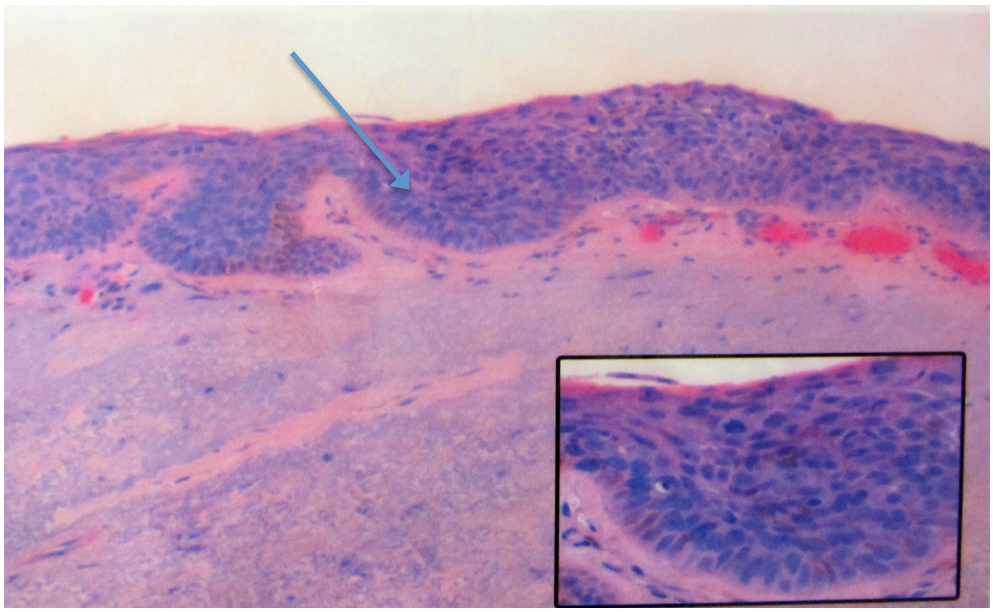

FIGURE 1.3: FULL THICKNESS DYSPLASIA OF THE CONJUNCTIOVAL EPITHELIUM (ARROW) WITH SEVERE ACTINIC ELASTOSIS OF THE UNDERLYING SUBSTANTIA PROPRIA (COURTESY OF PROFESSOR MJ HALE)



FIGURE 1.4: PIGMENTED PAPILLOMATOUS CONJUNCTIVAL INTRAEPITHELIAL NEOPLASIA (REPRODUCED WITH PATIENT PERMISSION)

Carcinoma in-situ represents full thickness replacement of the epithelium by frankly malignant cells but the epithelial basement membrane is intact with no invasion into the substantia propria. Clinically it presents as a papillary mass at the limbus with minimal leukoplakia.[5]

Squamous cell carcinoma is the final stage where malignant cells have broken through the basement membrane and invaded the substantia propria (figure 1.5). The patients present with a red eye associated with a raised gelatinous mass with leukoplakia and feeder vessels. The lesion is initially mobile but later becomes fixed to underlying structures of the globe (figure 1.6 & 1.7).

CSCC is locally very aggressive. Spread to regional lymph nodes and systemic metastases is not very common especially with appropriate excision and adjunctive therapy.[5]

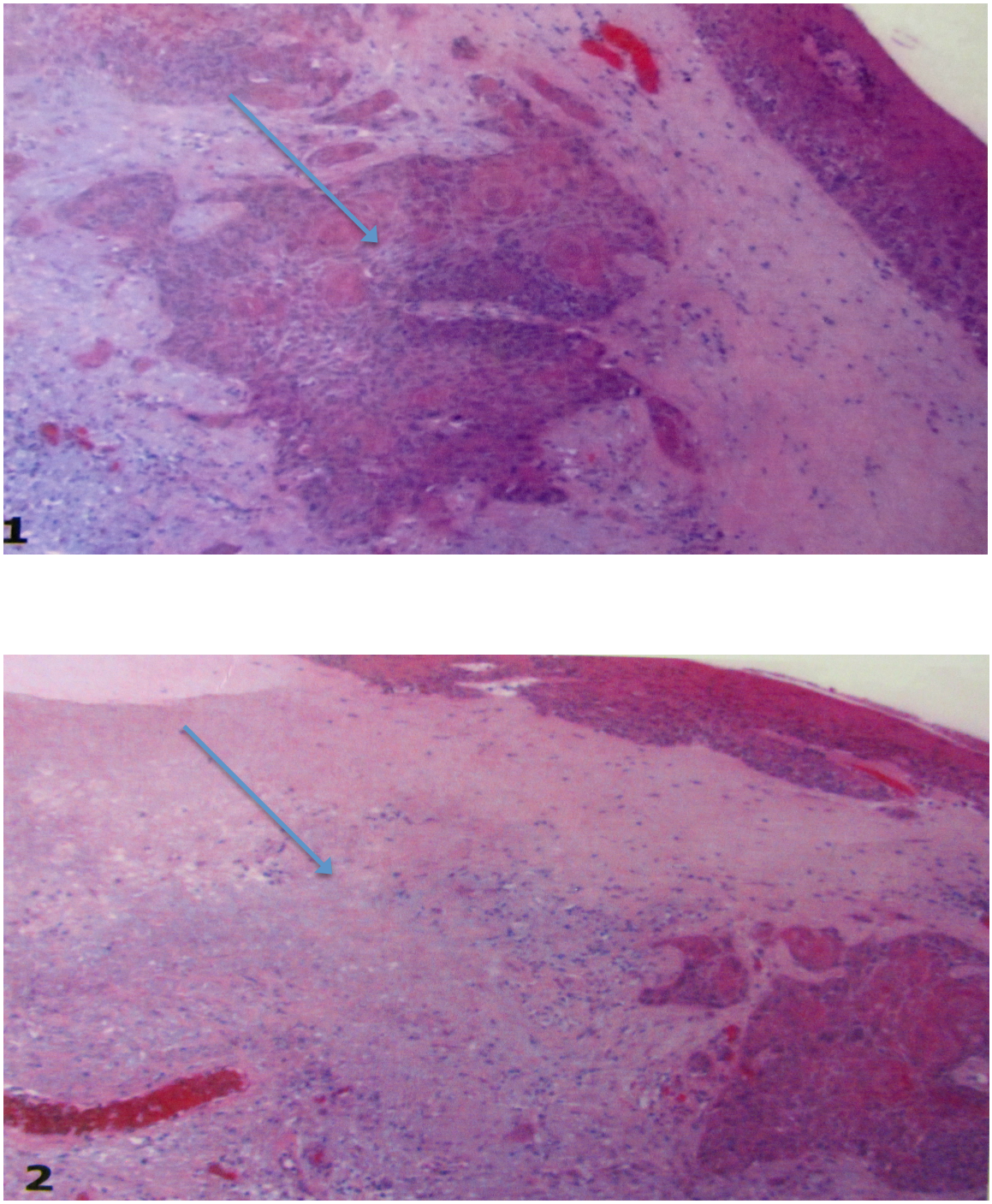

FIGURE 1.5: INFILTRATING SQUAMOUS CARCINOMA (ARROW) (1) WITH SEVERE, ADJACENT ACTINIC ELASTOSIS OF THE UNDERLYING SUBSTANTIA PROPRIA (ARROW) (2) (COURTESY OF PROFESSOR MJ HALE)



FIGURE 1.6: SQUAMOUS CELL CARCINOMA OF THE CONJUNCTIVA WITH NEARLY 360° LIMBAL LEUCOPLAKIA AND FEEDER VESSELS (*REPRODUCED WITH PATIENT PERMISSION)*

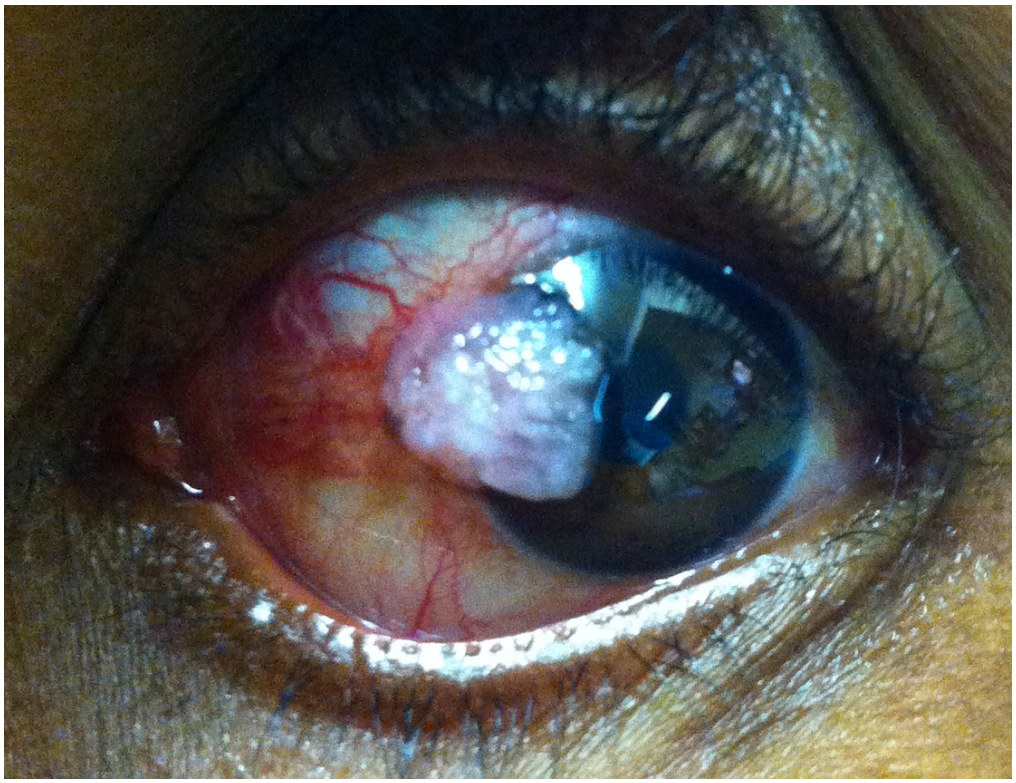

FIGURE 1.7: SQUAMOUS CELL CARCINOMA OF THE CONJUNCTIVA AND CORNEA WITH ASSOCIATED FEEDER VESSELS AND LEUKOPLAKIA (*REPRODUCED WITH PATIENT PERMISSION)*

1.4. Literature review

1.4.1. Global Incidence

The incidence of OSSN varies across the world. A study conducted in Brisbane, Australia[6] found the incidence to be 1.9/100 000 and another study in the United States by Sun and co-workers[7] found an incidence of 0.03/100 000 cases. The incidence is higher in sub-Saharan Africa, with countries such as Uganda, reporting an incidence of CSCC as six per million per year from 1970 until 1988, which increased to 35 per million per year by 1992. This trend has also been reported in other African countries such as Malawi, Tanzania and Zimbabwe[8-13].

1.4.2. Epidemiology and Pathogenesis

During the last two decades a strong correlation between CSCC and HIV infection has been noted. In Africa, the combined effects of UV irradiation, HPV and HIV infection has caused this condition, previously more common in elderly Caucasian males in Europe and North America, to increase in severity in young Africans.[14,15]

According to the World Health Organization, the AIDS epidemic is the main cause of death in young adults in Africa and in many other developing countries. Of the estimated 33.3 million people worldwide living with HIV by the end of 2009, 22.5 million were in sub-Saharan Africa.[16] Research in South Africa has shown that the

combined effects of UV irradiation, HPV and HIV have caused OSSN to increase among young African HIV positive female patients in their early 30s.[17,18]
In particular, exposure to ultraviolet irradiation causes DNA damage to cells and without adequate repair, mutations can occur which are likely to cause cancer.[19] This is supported by studies showing that the rate of OSSN declines by 49% for each 10-degree increase in latitude from the earths equator, and that there is a younger age of onset in countries less than 30 degrees from the equator.[20]

The exact role of HPV in the pathogenesis of OSSN is controversial. Varying results have been reported by centers all over the world. In 2010 Hale et al[21] from Wits University analyzed the conjunctival biopies from 2007 and 2008 for evidence of HPV. Of the 51 patients that had dysplasia or invasive carcinoma none showed any evidence of HPV following PCR amplification. These results correlate with a study in Germany which looked at 31 specimens and did not find any evidence of HPV infection.[22] Another study conducted in India did not detect any HPV in the 57 specimens analyzed by PCR[23].

These results are in contrast to a study by Scott et al[24] which found HPV 16 and 18 in all 10 patients with CIN. Other interesting studies conducted by Ateenyi-Agaba et al[19,25] found cutaneous HPV in nearly 45% of CSCC cases, 41% of dysplasia cases and 11% of controls. HPV 5 and 8 were the most common types of HPV found and most often occurred in combination with other types of HPV. In their study they

concluded that Epidermodysplasia verruciformis type of human papilloma virus (HPV 5, 8, 19-25 and 36-38) acts as a cofactor in the aetiology of OSSN.

1.4.3. Clinical presentation and Treatment

Patients with OSSN give typically a 3 to 4 month history of conjunctival mass growth and present with either small localized nasal tumors or large fungating lesions that require enucleation or exenteration, due to the severity of spread within the globe. There is conflicting evidence as to the speed at which conjunctival tumors grow. Although the tumor growth history given by patients is usually 3 to 4 months, a study by Mahomed et al[17] demonstrated that these are slow growing tumors (low proliferation index) even in the presence of HIV infection. Despite the varying severity of these lesions at presentation, surgical and/or non-surgical approaches can be used.

During surgical excision clear margins (4 to 5mm) are necessary to prevent recurrence, which can be as high as 40-53%. Other predictors of high recurrence rate are the grade/stage of the tumor and presence of corneal involvement.[14] These factors increase the chance of recurrence, but when managed correctly a good outcome in HIV positive patients is possible. In addition there is consensus that these tumors rarely have systemic involvement and are not a cause of mortality, unlike other aggressive AIDS-related malignancies.[14,15]

Crum-Cianflone N et al[26], have shown that the trend in the incidence of cancers among HIV infected people has changed dramatically since the emergence of HIV in the 1980s. AIDS-defining malignancies such as Kaposi's sarcoma and non-Hodgkin's lymphoma are not as prevalent among HIV patients as in the pre-HAART era (1984-1995), while non-AIDS-defining malignancies have increased in the post-HAART era (1996-current). Research has not shown a significant relationship between the use of HAART and non-AIDS defining malignancies, but have assumed that the cause of these cancers is due to the aging of the HIV population.

To assess the risk of developing AIDS-related illnesses, CD4 count has been shown to be a strong predictive factor for survival and progression of malignancies in HIV positive individuals.[27] In the management of AIDS-defining malignancies such as, Kaposi's sarcoma, CD4 count, severity of disease and the presence of other signs and symptoms of systemic HIV infection are used as prognostic factors for the classification of patients.[28,29]

1.5. Research Aim

The aim of this study was to determine the spectrum of OSSN in young patients presenting at the St John Eye Hospital.

1.6. Research Objective

To determine what the occurrence of conjunctival intraepithelial neoplasia and invasive squamous cell carcinoma was among young patients presenting with OSSN at the St John Eye Hospital, over the period (January 2007 to June 2011) by reviewing patient files and histo-pathological reports.

To determine if HIV is a possible risk factor for OSSN and whether CD4 count can be a predictor of severity of disease.

Chapter 2

This chapter gives a description of the research design and how it is organized in the study: Its sample procedure, population, data collection procedure and analysis of the data.

2. Methodology

2.1. Study design

This was a retrospective case series analysis of patient medical records and histo-pathological reports of patients who presented with OSSN at the St John Eye Hospital between January 2007 and June 2011.

2.2. Inclusion criteria

The inclusion criteria for patients at St John Eye Hospital - all adult black patients between the ages 15 – 40 years with the histo-pathological diagnosis of OSSN.

2.3. Data Collection

The data was collected in two stages.

Review of Histo-pathological reports

All patients' histo-pathological reports of conjunctival biopsies were retrieved from the National Health Laboratory Services (NHLS). The data was accessed off the snowmed database at the NHLS. The specified search code was DA – 75700 'conjunctival biopies', and the data was extracted. The raw data was analyzed, and all specimens having a report of OSSN, and within the inclusion criteria, were extracted and entered into a separate excel data spread sheet (Appendix A).

Review of patient medical records

The patient's laboratory medical records were checked for HIV and CD4 count blood results through the NHLS records. The patient's hospital number was entered and if no result was obtained, the patients surname and first name were used to access the required information. The data was entered into the excel spread sheet containing the biopsy results (Appendix A)

2.4. Study population

The study was conducted at St John Eye Hospital, which serves Soweto and the greater Johannesburg. The population of Soweto, consisting of a mixture of ethnic

groups (e.g. Zulu, Sotho, Tswana), is approximately 1.3 million. The study consisted of 185 conjunctival biopsies with OSSN. These specimens had been sent to the NHLS during January 2007 and June 2011 for histo-pathological analysis.

2.5. Data management

Each patient was assigned a unique number to ensure anonymity. The unique case numbers were correlated with their histo-pathological reports and laboratory medical records. All patient information collected during the course of the research was kept strictly confidential and only information directly relevant to the study was extracted.

The data was recorded in Microsoft excel 2008 for Macintosh.

2.6. Data analysis

The data was analyzed using STAT 10. Inferential and descriptive statistics were used, as well as Chi squared testing to analyze categorical variables.

2.7. Ethical considerations

Ethical approval was obtained from the Human Research Ethics Committee of the University of the Witwatersrand, Johannesburg. The ethics protocol number is M10114 (Appendix B).

Permission to extract data from the NHLS snowmed system was obtained from Professor MJ Hale, Anatomical pathology departmental head, University of the Witwatersrand (Appendix C).

Permission to review past medical records was obtained from Dr P Lingham, Superintendent St John Eye unit, Chris Hani Baragwanath Hospital, Soweto. Information was kept strictly confidential.

Chapter 3

Results of a four and a half year retrospective analysis (January 2007 to June 2011) on conjunctival biopsies retrieved from the NHLS.

3. Results

3.1. Patient Demographics

Of the 934 conjunctival biopsies, 185 were shown to have OSSN. Of these only 183 (98.9%) had sex recorded of which 119 (65.0%) were female and 64 (35.0%) were male.

The age was recorded in 148 (80%) of the 185 biopsies, with the median age being 32.9 (range 18-40; SD 4.7)

3.2. Lesion type

Of the 185 specimens with OSSN, 26 (14.05%) had CIN 1, 54 (29.19%) had CIN II, 87 (47.03%) had carcinoma in-situ and 18 (9.73%) squamous cell carcinoma (see table 3.3.1).

The total number of dysplastic lesions was 167 (90.27%) and represented the majority of the lesions analyzed.

3.3. Dysplastic lesion analysis, including sex and age

3.3.1. Table 1 – Analysis of dysplastic lesions

DYSPLASTIC LESION TYPE	NUMBER OF PATIENTS
CIN I	**26**
CIN II	**54**
CIN III (Carcinoma in-situ)	**87**

The majority of lesions were seen in females (65.0% for pre-invasive lesions and 61.1% for invasive lesions), and the most common age range was between 30-40 years (61.1% for pre-invasive lesions; 92.31% for invasive lesions).

The first table on the following page (3.3.2) demonstrates the distribution of the lesions with respect to gender and the second table (3.3.3) demonstrates the distribution of lesions with respect to age.

3.3.2. Table 2 – Distribution of conjunctival biopsies with respect to males and females

LESION TYPE	FREQ	PERCENT (%)	SEX	
			M	F
CIN I	26	14.05	10	16
CIN II	54	29.19	21	33
CIN III	87	47.03	26	59
SCCa	18	9.73	7	11
Total	185	100.00	64	119

3.3.3. Table 3 – Distribution of conjunctival biopsies with respect to patient age

AGE GROUPS	LESION TYPE				
	CIN I	CIN II	CIN III	SCCa	Total
<20 yrs.	0 (0.0)	1 (100.0)	0 (0.0)	0 (0.0)	1 (0.68)
20-24 yrs.	1 (25.0)	1 (25.0)	2 (50.0)	0 (0.0)	4 (2.70)
25-29 yrs.	4 (13.79)	11 (37.93)	13 (44.83)	1 (3.45)	29 (19.59)
30-34 yrs.	7 (12.96)	16 (29.63)	24 (44.44)	7 (12.96)	54 (36.49)
35-40 yrs.	9 (15.0)	18 (30.0)	28 (46.67)	5 (8.33)	60 (40.54)
Total	21 (14.19)	47 (31.76)	67 (45.27)	13 (8.78)	148 (100.0)

3.4. HIV and CD4 results

HIV results were retrieved for 16 (8.65%) patients. Of the 16 all were positive and 169 (91.35%) were unknown. From the HIV positive results CD4 count was available for 14 (87.50%) patients. The results are outlined in the table 3.4.1 below. There was no evidence of a relationship between CD4 count and severity of disease in the few CD4 results available.

3.4.1. Table 4 – Analysis of CD4 count

Variable	Obs	Mean	Std. Dev.	Min	Max
CD4 count	14	244.1	197.5	7	691

Chapter 4

DISCUSSION

The spectrum of OSSN comprises of dysplasia, carcinoma in-situ and squamous cell carcinoma of the conjunctiva and/or cornea. In our study that was conducted over a four and a half year period, we analyzed 185 conjunctival biopsies with OSSN.

Our study showed dysplasia in 90.27% (CIN I-14.05%, CIN II-29.19%, CIN III/CIS-47.03%) and CSCC in 9.73% of the sample. The majority of cases in the sample occurred in the age group 30-40 years, of these 61.1% were for dysplastic lesions and 92.31% for invasive lesions. Females were most commonly affected in both the dysplastic lesions (65.0%) and invasive lesions (61.1%).

Waddell KM et al[9] in Uganda and Malawi conducted a study comparing the association between HIV and CSCC. In the Ugandan group 38 patients (27 invasive CSCC and 11 CIN) were found. There were 14 males and 24 females with a mean age of 35 years. In the Malawian group 36 patients had excisional biopsies (20 invasive CSCC, 12 CIN, 4 pingueculae). There were 15 males and 17 female patients with a mean age of 31 years. In the Ugandan group 71% of the patients with carcinoma were HIV positive and 86% in the Malawian group.

In another study conducted in Malawi by Spitzer MS et al[11] in 2008, they looked at the prevalence of HIV in patients with OSSN. Of the 53 (23 invasive CSCC, 21 CIN, 9 with indeterminate OSSN due to poor excision) 22 were female and 31 male with a mean age of 33 years. Of the 38 patients tested 30 were found to be HIV positive and with invasive disease.

In Zimbabwe, a country that borders South Africa, a study was conducted by Porges Y et al[13] to evaluate the prevalence of HIV among patients with OSSN. The study was conducted between December 1993 and November 1995 and a group of 23 patients underwent excisional biopsy. Females were predominantly affected with a mean age of 36.9 years. Of the 23 biopsies, 12 had invasive CSCC, 6 CIN and 5 Kaposi's sarcoma (KS). All HIV positive patients had CSCC or KS, except one.

These results from Uganda, Malawi and Zimbabwe are similar to our study in that they show the same epidemiological profile, with respect to gender and age distribution. However, the majority of patients in our study had pre-invasive disease and not invasive disease as reported in the above studies. This could be related to earlier presentation by better educated patients, or a less aggressive nature of the disease due to a variability of other risk factors such as UV irradiation, HPV and HIV infection among young patients in South Africa.

In Durban, South Africa a study conducted by Mohamed et al[18] also found the majority of lesions to be pre-invasive (23 CIN and 18 invasive CSCC). Forty patients underwent excisional biopsy (20 male, 20 female) with a mean age of 37 years. Of the 17 patients tested for HIV, 12 were positive and 11 had CIS or invasive CSCC.

Of the 185 specimens in our study, HIV results were only available for 16 (8.65%) patients, all of whom were HIV positive. The remaining 169 results were unknown and this may be due to resistance from patients to test or lack of knowledge by medical doctor of the relationship between OSSN and HIV in sub-Saharan Africa. From the 16 HIV positive patients CD4 count results were available for 14 (87.05%) with the mean CD4 count being 244.1. Previous studies[30] have shown a trend of lower CD4 count in patients with squamous cell carcinoma compared to dysplasia, but our study was unable to demonstrate these findings due to the limited HIV results. No trend of lower CD4 count being associated with more severe dysplasia was noted. The lowest CD4 count was 7 in a patient with carcinoma in-situ and the highest was 691 in a patient with CIN II. This data does not show any relationship between CD4 count and severity of disease in OSSN.

Our study was unable to extrapolate adequate data on the effects of HIV on our patient population living in sub-Saharan Africa. This is most likely due to its retrospective nature and the lack of patient willingness or doctor knowledge on the importance of testing patients. Other limitations included poor access to medical files

to assess morphological features of the lesions, environmental effects, additional risk factors and patient follow-up.

CONCLUSION

In sub-Saharan Africa OSSN occurs among young African females in their 30's and pre-invasive lesions are more common at Chris Hani Baragwanath (St John Eye Hospital) in South Africa.

The rise in OSSN has been shown by several studies to be due to UV light exposure, HIV and HPV infection. This condition represents an important non-AIDS-defining malignancy in Africa, which needs to be monitored, especially in HIV patients.

A prospective study in South Africa is recommended to investigate whether there is an association between HIV positive patients immune status and severity of OSSN, due to the lack of HIV results in this study. To our knowledge there has been no study exclusively looking at the association between CD4 count and severity of disease in patients with OSSN.

REFERENCES

1. Lee GA, Hirst LW. Ocular surface squamous neoplasia. *Surv Ophthalmol* 1995;**39**:429-450
2. Nagaiah G, Stotler C, Orem J, et al. Ocular surface squamous neoplasia in patients with HIV infection in sub-Saharan Africa. *Curr Opin Oncol* 2010:**22**;437-442
3. Snell RS, Lemp MA. Clinical anatomy of the eye. 2nd ed. United Kingdom: Blackwell publishing Inc, 2006:108
4. Kaufman PL, Alm A. Adler's physiology of the eye – clinical application. 10th ed. Missouri: Mosby publishing, 2003:23
5. Othman IS. Ocular surface tumours. *Oman J Ophthalmol* 2009;**2**:3-14
6. Lee GA, Hirst LW. Incidence of ocular surface epithelial dysplasia in metropolitan Brisbane - A 10-year survery. *Arch Ophthalmol* 1992;**110**:525-527
7. Sun EC, Fears TR, Goedert JJ. Epidemiology of squamous cell conjunctival cancer. *Cancer Epidemiol Biomarkers Prev* 1997;**6**:73-77
8. Waddell KM, Kwehangana J, Johnson WT, et al. A case-control study of ocular surface squamous neoplasia (OSSN) in Uganda. *Int J Cancer* 2010;**127**:427-432
9. Waddell KM, Lewallen S, Lucas SB, et al. Carcinoma of the conjunctiva and HIV infection in Uganda and Malawi. *Br J Ophthalmol* 1996;**80**:503-508.
10. Ateenyi-Agaba C. Conjunctival squamous cell carcinoma associated with HIV infection in Kampala, Uganda. *Lancet* 1995;**345**:695-698.

11. Spitzer MS, Batumba NH, Chirambo T, et al. Ocular surface squamous neoplasia as the first apparent manifestation of HIV infection in Malawi. *Clin Experiment Ophthalmol* 2008;**36**:422-425.
12. Poole TRG. Conjunctival squamous cell carcinoma in Tanzania. *Br J Ophthalmol* 1999;**83**:177-179.
13. Porges Y, Groisman GM. Prevalence of HIV with conjunctival squamous cell neoplasia in an African provincial hospital. *Cornea* 2003;**22**:1-4
14. Basti S, Macsai MS. Ocular surface squamous neoplasia – a review. *Cornea* 2003;**22**:687-704
15. Gichuhi S, Irlam JJH. Interventions for squamous cell carcinoma of the conjunctiva in HIV-infected individuals. *Cochrane Database of Syst Rev* 2007;**18**:1-14.
16. UNAIDS. AIDS epidemic. <http://www.unaids.org/en/human immunodeficiency virus (HIV)_data/2007GlobalReport/ (accessed 10.12.2012).
17. Goedhals J, Beukes CA, Joubert G, et al. Conjunctival squamous cell neoplasia and HIV. *SA Ophthalmology Journal* winter 2007;21-24.
18. Mahomed A, Chetty R. Human immunodeficiency virus infection, Bcl-2, p53 protein, and Ki-67 analysis in ocular surface squamous neoplasia. *Arch Ophthalmol* 2002;**120**:554-558.
19. Ateenyi-Agaba C, Dai M, Le Calvez F, et al. TP53 mutations in squamous cell carcinoma of the conjunctiva: evidence for UV-induced mutagenesis. *Mutagenesis* 2004;**19**:399-401.

20. Newton R, Ferlay J, Reeves G, et al. Effect of ambient solar ultraviolet radiation on incidence of squamous cell carcinoma of the eye. *Lancet* 1996;**347**:1450-1451

21. Hale MJ, Naidoo S, Muthabeni SM. Human papillomavirus infection is not associated with dysplasia and squamous cell carcinoma of the conjunctiva in a cohort of young patients in South Africa. Division of Anatomical Pathology, School of Pathology, Faculty of Health Sciences, University of the Witwatersrand and NHLS South Africa. 2010

22. Guthoff R, Marx A, Stroebel P. No evidence for a pathogenic role of human papillomavirus infection in ocular surface squamous neoplasia in Germany. *Curr Eye Res* 2009;**3**:666-671

23. Manderwad GP, Kannabiran C, Honavar SG, et al. Lack of association of high-risk human papillomavirus in ocular surface squamous neoplasia in India. *Arch Pathol Lab Med* 2009;**133**:1246-1250

24. Scott IU, Karp CL, Nuovo GJ. Human papillomavirus 16 and 18 expression in conjunctival intraepithelial neoplasia. *Ophthalmology* 2002;**109**:542-547.

25. Ateenyi-Agaba C, Franceschi S, Wabwire-Mangen F, et al. Human papillomavirus infection and squamous cell carcinoma of the conjunctiva. *Br J Cancer* 2010;**102**:262-267.

26. Crum-Cianflone N, Hullsiek KH, Marconi V, et al. Trends in the incidence of caners among HIV-infected persons and the impact of antiretroviral therapy: A 20-year cohort study. *AIDS* 2009;**23**:41-50.

27. Jung AC, Paauw DS. Diagnosing HIV-related disease using the CD4 count as a guide. *J Gen Intern Med* 1998;**13**:131-136.

28. Robotin MC, Law MG, Milliken S, et al. Clinical features and predictors of survival of AIDS-related non-Hodgkin's lymphoma in a population-based case series in Sydney, Australia. *HIV medicine* 2004;**5**:377-384.

29. Krown SE, Testa MA, Huang J. AIDS-related Kaposi's sarcoma: Prospective validation of the AIDS clinical trials group staging classification. *J Clin Oncol* 1997;**15**:3085-3092.

30. Pola EC, Masanganise R, Rusakaniko S. The trend of ocular surface squamous neoplasia among ocular surface tumor biopsies submitted for histology from Sekuru Kaguvi Eye Unit, Harare between 1996 and 2000. *Cent Afr J Med* 2003;**49**:149-152.

Appendix A: Data Capturing Sheet

Table 1 – Data summary sheet

Patient no.	Age	Sex	HIV status	CD4 count	Lesion type (Preinvasive or Invasive)
e.g. GP08897654	35	M	Positive	239	Preinvasive – CIN II

Appendix B: Ethics Certificate

UNIVERSITY OF THE WITWATERSRAND, JOHANNESBURG
Division of the Deputy Registrar (Research)

HUMAN RESEARCH ETHICS COMMITTEE (MEDICAL)
R14/49 Dr Riana Sarita Dolland

CLEARANCE CERTIFICATE	**M10114**
PROJECT	The Spectrum of Conjuntival Squamous Cell Carcinoma at St John Eye Hospital
INVESTIGATORS	Dr Riana Sarita Dolland.
DEPARTMENT	Division of Opthalmology
DATE CONSIDERED	29/01/2010
DECISION OF THE COMMITTEE*	Approved unconditionally

Unless otherwise specified this ethical clearance is valid for 5 years and may be renewed upon application.

DATE 29/01/2010 **CHAIRPERSON** .....
(Professor PE Cleaton-Jones)

*Guidelines for written 'informed consent' attached where applicable
cc: Supervisor : Dr I Mayet

DECLARATION OF INVESTIGATOR(S)

To be completed in duplicate and **ONE COPY** returned to the Secretary at Room 10004, 10th Floor, Senate House, University.
I/We fully understand the conditions under which I am/we are authorized to carry out the abovementioned research and I/we guarantee to ensure compliance with these conditions. Should any departure to be contemplated from the research procedure as approved I/we undertake to resubmit the protocol to the Committee. **I agree to a completion of a yearly progress report.**

PLEASE QUOTE THE PROTOCOL NUMBER IN ALL ENQUIRIES...

Appendix C: Approval to access medical records

NATIONAL HEALTH LABORATORY SERVICE
UNIVERSITY OF THE WITWATERSRAND – JOHANNESBURG
Division of Anatomical Pathology

P.O. Box 1038, Johannesburg 2000
Tel : +27-11-489-8477
+27-11- 489-8479
Fax::+27-11-489-8512

Division of Anatomical Pathology
Faculty of Health Sciences
York Road
Parktown e-mail : martin.hale@nhls.ac.za

Professor MJ Hale MBChB (Rhodesia) FCPath (SA). LRCP, LRCS, LRCP&S (Edinburgh & Glasgow)
Professor & Head: Division of Anatomical Pathology,

10 March 2010

CONSENT FORM TO ACCESS MEDICAL RECORDS & BIOPSY REPORTS

I, Professor Martin Hale, hereby give Dr R S Dolland, a registrar in the Division of Ophthalmology, Department of Neurosciences, permission to access medical records and biopsy reports to facilitate her research on 'The spectrum of conjunctival squamous cell carcinoma at St John Eye Hospital' for her master degree in Ophthalmology.

Professor MJ Hale; Head of Department of Anatomical Pathology
Name and Title



Signature

16th March 2010.

Date