

https://dspace.org/

The value of F-18 FDG-PET in invasive cervical cancer

Mahomed, Faiza

2014-03-31
http://hdl.handle.net10539/14425

Downloaded from a DSpace repository. https://dspace.org/

THE VALUE OF F-18 FDG-PET IN INVASIVE CERVICAL CANCER



BY:

DR FAIZA MAHOMED
DEPARTMENT OF RADIATION ONCOLOGY AND DEPARTMENT OF NUCLEAR MEDICINE
CHARLOTTE MAXEKE JOHANNESBURG ACADEMIC HOSPITAL

JOHANNESBURG, 2012

SUPERVISORS: PROF M. D. T.VANGU
DR J. KOTZEN

COVER FIGURE : PARA-AORTIC LYMPHADENOPATHY
CHARLOTTE MAXEKE JHB ACADEMIC HOSPITAL



DECLARATION:

I, Dr Faiza Mahomed declare that this thesis is my own work. It is being submitted for the Degree of Masters of Medicine in Radiation Oncology, in the University of the Witwatersrand, Johannesburg. It has not been submitted before for any degree or examination at this, or any other University.

…… (Signature of Candidate)

This 21 day of January 2013.

This research was approved by the Committee for Research on Human Subjects, University of the Witwatersrand (protocol M10319) Human Research Ethics Committee.

DEDICATION

In Loving Memory of My Mother
Ayesha Suliman
1927 – 2010.

TABLE OF CONTENTS **Page**

TITLE PAGE -

COVER FIGURE : PARA-AORTIC LYMPHADENOPATHY 1

DECLARATION 2

DEDICATION 3

TABLE OF CONTENTS 4

CONTENTS OF CHAPTERS 5 - 7

PUBLICATION AND PRESENTATIONS 8
(ARISING FROM THIS STUDY)

ABSTRACT 9

ACKNOWLEDGEMENTS 10

LIST OF ABBREVIATIONS 11

LIST OF TABLES 12

LIST OF FIGURES 13 – 14

LIST OF ANNEXURES 15

BODY OF THESIS:

INTRODUCTION 16 – 32

LITERATURE REVIEW 33 - 50

OBJECTIVES 51

MATERIALS AND METHODS 51 – 54

RESULTS 55 – 72

DISCUSSION 73 – 81

CONCLUSION 82 – 86

REFERENCES 87 - 91

ANNEXURES 92 - 103

SPECIAL PERMISSIONS 104

CONTENTS OF CHAPTERS:

CHAPTER 1: INTRODUCTION 16

1.1 FIGO INTERNATIONAL STAGING 17
1.1.1 Significance of para-aortic lymph nodes 18
1.1.2 Early invasive cervical cancer 19

1.2 PET AS AN IMAGING MODALITY 20

1.3 IMAGING AND DETERMINING THE EXTENT OF CERVICAL CANCER. 23

1.4 IMAGING LYMPH NODES AND DISTANT METASTASES 23
1.4.1 Lymph nodes 23
1.4.2 Progression-free survival based on lymph node status on F-18 FDG-PET 26

1.5 IMAGING LOCAL DISEASE 27
1.5.1 Standard Uptake Value 28

1.6 POST THERAPY MONITORING 29

CHAPTER 2: LITERATURE REVIEW 33

2.1 LYMPH NODE STAGING BY F-18 FDG- PET/CT 34

2.2 DIAGNOSTIC VALUE OF F-18 FDG-PET/CT 36

2.3 TUMOUR UPTAKE BY F18-FDG-PET/CT AS A BIOMARKER FOR CERVICAL CANCER TO EVALUATE RESPONSE AND SURVIVAL 42

2.4 THE ROLE OF F-18 FDG-PET/CT IMAGING IN THE POST TREATMENT SETTING. 43

2.5 F-18 FDG-PET/CT SCANNING AND THE HUMAN IMMUNODEFICIENCY VIRUS / AIDS SYNDROME 44

2.6 TABULATED LITERATURE REVIEW 49

CHAPTER 3: STUDY 51

3.1 OBJECTIVES 51

3.2 METHODOLOGY 51

3.3 RESULTS 55
3.3.1 RESULTS 55

3.4 DEMOGRAPHICS 57
3.4.1 Age 57
3.4.2 Stage at Diagnosis 57
3.4.3 Histological Subtypes 57
3.4.4 HIV Status 59
3.4.5 CD4 59

3.5 METASTATIC DISEASE FOUND ON PRE – TREATMENT SCAN 59

3.5.1 Liver metastases 59
3.5.2 Lung metastases 59
3.5.3 Bone metastases 59
3.5.4 Para-aortic metastases 60
3.5.5 Supraclavicular lymph node metastases 60
3.5.6 Hilar lymph node metastases 60
3.5.7 Volume of the primary tumour. 61

3.6 PET STAGING PRE-TREATMENT. 61
3.6.1 PET STAGING PRE-TREATMENT 61
3.6.2 ASSOCIATION BETWEEN CLINICAL STAGES 62
3.6.3 SUV CERVIX ASSOCIATION WITH PARA-AOTIC LYMPHADENOPATHY 62

3.7 HIV DISEASE AND PRE-TREATMENT PET STAGINGS. 63
3.7.1 HIV negative vs PET stage. 63
3.7.2 HIV positive vs PET stage. 63
3.7.3 SIGNIFICANCE OF HIV ASSOCIATION WITH PET STAGE 63
3.7.4 CD4 and PET STAGE. 63

3.8 PARA-AORTIC LYMPH NODES PRE AND POST TREATMENT 64

3.8.1 Para-aortic lymph nodes ; pre-treatment size and distant metastases 64
3.8.2 Para-aortic lymph nodes; post-treatment size and distant metastases 65

3.9 PATIENT CHARACTERISTIC TABLE 66

3.10 Figures of patients who had F-18 FDG-PET/CT at Charlotte Maxeke Johannesburg Academic Hospital. 68

CHAPTER 4: DISCUSSION 73

4.1 METASTATIC DISEASE AND PARA-AORTIC LYMPH NODE IN PRE-TREATMENT SCAN 74

4.2 STATUS OF PARA-AORTIC LYMPH NODE 76

CHAPTER 5: CONCLUSION

5.1 RECOMMENDATIONS FOR A PRE-TREATMENT F18-FDG-PET SCAN 82

5.2 RECOMMENDATION FOR A POST- TREATMENT F18-FDG-PET SCAN 83

5.3 RECOMMENDATION FOR IMRT IN FUTURE 86

REFERENCES: 87-91

ANNEXURES: 92

SPECIAL PERMISSIONS:

PUBLICATION AND PRESENTATION ARISING FROM THIS STUDY

This Project / or Research findings will be submitted for publication in the following.

1. Journal of Nuclear Medicine.
2. SASCRO / SASCO National Congress in 2013 as a National paper.
3. Departmental Presentation as lecture: 2013
4. International poster presentation. 2013
5. Journal of Obstetrics and Gynaecology, local
6. Journal of Continuing Medical Education
7. Departmental protocol change –recommendation to University as well as Johannesburg Charlotte Maxeke Academic Hospital to include F-18 FDG PET/CT for locally advanced cancer of the cervix, for staging.

ABSTRACT: The Value of F-18 FDG – PET in Invasive Cervical Cancer.

Author: Mahomed. F
Supervisors: Prof MDT Vangu, Dr J. Kotzen
Affiliation: University of Witwatersrand (Department of Radiation Oncology)
Hospital: Charlotte Maxeke JHB Academic Hospital

Introduction**:** Uterine Cervical Cancer is one of the leading causes of morbidity amongst the female genital tract cancers. This study aims to identify the Value of Fluorine-18 - FluorinedeoxyGlucose – Positron emission tomography scan in cervical cancer. Currently, the International Federation of Gynaecology and Obstetrics (FIGO) staging is the routine method used internationally for staging of cervical cancer. This staging is based on clinical criteria and does not take into account para-aortic lymph nodes or pelvic lymph node involvement, which may affect the radiation target volumes. F-18-FDG-PET/CT scanning can identify metabolically active lymph nodes as well as distant metastases including para-aortic lymph nodes. This method aims to show that many patients in our setting have distant metastases; hence the current FIGO staging method may not be a very accurate method of staging in the Pre-treatment setting.
F-18 FDG-PET/CT was done post radiation therapy to assess response to treatment. Post treatment F-18 FDG PET/CT was correlated to clinical findings and responses after radiation. Radiation target volumes may be modified in future if para-aortic lymph nodes are found on pre-treatment F-18 FDG-PET/CT scan and extended field radiation will then be used. When a large primary tumour is found with no disease beyond the pelvis, patients may benefit from 3D Brachytherapy.

Methodology: This was a prospective randomised trial done at Charlotte Maxeke Johannesburg Academic Hospital, between May 2010 and Jan 2012 .After the routine tests were done and patients staged according to FIGO staging, patients had a Pre-Radiation F-18 FDG-PET/CT scan, followed by a post therapy F-18 FDG-PET/CT scan 3 months after treatment. Patients were stratified from clinical stages IBi to stage IIIB.All patients were biopsy confirmed with invasive cervical cancer.

Results: In future, the role of F-18 FDG-PET/CT will be an important modality in the initial staging as well as in the post therapy setting to assess the response of radiation in cervical cancer. The results showed that there was no association between FIGO clinical staging and findings in a pre-radiation F-18 FDG -PET/CT scan as para-aortic lymph nodes were not detected by FIGO staging.

Conclusion: The current staging used for cervical cancer does not correlate with pre -treatment PET findings. A large proportion of patients were upstaged by F-18 FDG-PET/CT scan. A proportion of patients were not identified prior to F-18 FDG- PET/CT scan, as having distant metastases. The value of F18 FDG-PET/CT scan may have an impact on the future management of patients with cervical cancer. PET in the post therapy setting is also a good surrogate endpoint for determining tumour control as well as residual and metastatic disease.

ACKNOWLEDGEMENTS:

I wish to thank the following people for their assistance towards the feasibility of the project.

1. Professor M. D. T Vangu.
2. Dr J. Kotzen.
3. Charlotte Maxeke Johannesburg Hospital : Dr Barney Selebano for allowing the research to be performed at this Hospital.
4. Prof V. Sharma.
5. Department of Radiation Oncology: Doctors, Radiographers, Physics, Sisters.
6. Department of Nuclear Medicine staff.
7. Research Assistant, Irma Mare.
8. Statistical Assistance: Prof E. Libhaber, Dr Tobias Chirwa.
9. Patients who agreed to participate in the research.

LIST OF ABBREVIATIONS:

1. F-18 FDG-PET: Fluorine-18-Fluorinedeoxyglucose–Positron Emission Tomography.
2. CT: Computed Tomography.
3. FIGO: Federation International de Gynecological Obstetrique also known as International Federation of Gynaecology and Obstetrics.
4. 3D: 3 Dimensional.
5. CTV : Clinical Target Volume.
6. MRI: Magnetic Resonance Imaging.
7. HIV: Human Immunodeficiency Virus.
8. AIDS: Acquired Immunodeficiency Syndrome.
9. TB: Tuberculosis
10. HPV: Human papilloma virus.
11. IMRT: Intensity Modulated Radiation Therapy.
12. PET: Positron Emission Tomography.
13. JHB: Johannesburg
14. CMJAH: Charlotte Maxeke Johannesburg Academic Hospital.
15. LN: Lymph nodes
16. TAH: Total abdominal hysterectomy
17. PFS: Progression free survival
18. OS: Overall survival
19. IVP: Intravenous Pyelography.
20. U/S: Ultrasonography.
21. SUV: Standard Uptake Value.
22. 2D: 2 Dimensional.
23. HAART: Highly Active Anti-Retroviral Treatment

LIST OF TABLES: **Page**

1.	Comparing sensitivity and specificity of imaging	24
2.	PET vs CT Scans and detection of lymph nodes	24
3.	Literature Review	49 – 50
4.	Stage at Diagnoses	57
5.	PET Staging: Pre -Treatment	61
6.	Results: Para-aortic lymph nodes, pre–treatment size and distant metastases	64
7.	Post Radiation: Para-aortic lymph node status with distant metastases	65
8.	Patient Characteristic table	66 - 67

LIST OF FIGURES / PHOTOGRAPHS **Page**

1. F-18 FDG-PET/CT image showing increased uptake in the supraclavicular lymph node 18
2. Early invasive cancer 19
3. Molecular structure of 2-deoxy-2-[^{18}F]fluoro-D-glucose (^{18}FDG) 21
4. F-18 FDG- PET/CT equipment used at Charlotte Maxeke Johannesburg Academic Hospital 21
5. PET/CT sequence acquisition 22
6. Progression-free survival based on FDG-PET lymph node status 26
7. Progression-free survival based on a negative versus a positive 3 month F-18 FDG-PET/CT scan 30
8. Overall Survival of a negative 3 month post therapy FDG-PET (a & b) 31
9. Overall Survival after isolated para-aortic recurrence 31
10. Regional lymph node spread in cervical cancer. 33
11. Common iliac lymph nodes demonstrating regional drainage 35
12. External iliac lymph nodes 35
13. Internal iliac lymph nodes drainage in cervical cancer: 36
14. Kaplan-Meier Progression Free Survival estimates based on pelvic lymph node status. 39
15. Kaplan Meier Progression Free Survival estimates based on para-aortic lymph node status. 40
16. Kaplan Meier Progression Free Survival estimates for patients with negative CT for para-aortic nodal involvement 40
17. Histology of well differentiated keratinizing squamous cell carcinoma 58

18. Well differentiated adenocarcinoma of the uterine cervix. 58
19a. Post Radiation scan of patient with multiple para-aortic lymph nodes and multiple liver lesions 69
19b. Post Radiation scan with a large liver lobe lesion in segment 2. 70
20a. Post Radiation scan of patient with multiple para-aortic lymph nodes and multiple bilateral pulmonary nodules. 71
20b. Post Radiation scan of patient with multiple para-aortic lymph nodes. 72
21. CTV Nodal for para-aortic lymph nodes 74
22. Para- aortic lymph nodes on a patient: Pre treatment scan 75
23. IMRT for cervical cancer 80
24. Brachytherapy tumour Optimisation for PET-defined volume (A &B) 84
25. Brachytherapy tumour Optimisation for PET-defined volume, with (A) optimisation and (B) with out Optimisation 85
26. IMRT for cervical cancer. 86

LIST OF ANNEXURES **Page**

1. Appendix 1. FIGO Staging 92

2. Ethics Clearance Certificate 93

3. Preparation for F-18 FDG-PET/CT Scan Department of Nuclear Medicine 94

4. Globocan Statistics: Incidence of new cervical cancers 2002 -2030 95

5. Comparison of AJCC and FIGO Staging 96

6. Worldwide Incidence and Mortality for cervical cancers 97

7. World-Age Standardised Incidence rates of cervical cancer 98

8. F-18 FDG-PET/CT scan showing cervical mass and internal iliac lymph nodes 99

9. F-18 FDG-PET/CT avid primary cervical disease and para-aortic lymph nodes 100

10. F-18 FDG-PET/CT scan showing local and distant nodal disease 101

11. F-18 FDG PET/CT in a patient with left external iliac lymph node and left internal iliac lymph node on a Pre-Treatment scan 102

12. Example of a Linear Accelerator at Charlotte Maxeke Johannesburg Academic Hospital 103

Special permissions 104

CHAPTER 1:

INTRODUCTION:

Worldwide, the commonest female gynaecological cancer from the uterus, is cervical cancer, with a yearly incidence of almost 493 100 and a mortality of 273 000.[1] It is the third most common cancer diagnosed after breast and colorectal cancer in the female population.

Cervical cancer is also the most common gynaecological cancer in South Africa. At the Charlotte Maxeke Johannesburg Academic Hospital, cervix cancer accounts for approximately 75% of gynaecological cancers. (departmental data). Radiation plays a pivotal role in the management of the majority of cervical cancers mainly stage IB to stage IVb, staged with the International Federation of Gynaecology and Obstetrics (FIGO) staging. (Annexure 1). The international FIGO staging is based on clinical criteria and does not take into account para-aortic lymphadenopathy or pelvic lymphadenopathy, which may affect radiation target volumes. The International Federation of Gynaecology and Obstetrics reported a 5 year recurrence rate and a 5 year overall mortality rate of cervical cancer as 28% and 27.5% respectively.[2] Early diagnosis of invasive cervical cancer is vital, as it impacts on patients survival.

In this study, F18-FDG PET/CT was used, to compare with current FIGO staging. Pre-treatment F-18 FDG PET/CT was done to determine the presence of para- aortic lymph nodes or distant metastatic disease. Literature currently contains limited data on the use of PET/CT in cervical cancer. A post-treatment scan was done after 3 months of radiation therapy to determine if therapeutic response correlated to clinical findings.

1.1 FIGO INTERNATIONAL STAGING:

Invasive cancer of the cervix is staged according to the FIGO staging system. This staging is based on physical examination. The status of pelvic, para-aortic and supraclavicular lymph nodes as determined by radiological studies, is not part of the staging system.[3]

The current FIGO system emphasises the local extent of cervical malignancy, however the involvement of pelvic or para-aortic disease does not change the FIGO clinical stage of the patient. Initial diagnosis and staging of most gynaecological malignancies are commonly achieved by history, physical examination and selected imaging modalities. Accurate staging of gynaecological cancers is important both for selecting appropriate therapy and prognosis.

Current Imaging modality used by FIGO, to stage cervical cancer, is a diagnostic ultrasound which is mainly used for detecting renal tract obstruction (hydronephrosis) or liver secondaries. However the test sensitivity of ultrasound is low compared to FDG – PET sensitivity.[3] Clinically, if the inguinal or supraclavicular lymph nodes are positive, then the clinical stage will be stage 1VB. Imaging studies such as magnetic resonance imaging (MRI) or positron emission tomography (PET), are not recommended by FIGO.

FIGO staging includes inspection, palpation, colposcopy, cystoscopy (bladder biopsy), proctoscopy (rectal mucosal biopsy) an intravenous pyelogram and a chest x-ray. Cystoscopy with bladder biopsy can be done if bladder involvement is suspected. Lymphangiogram, arteriogram, PET scans or laparoscopy/ laparotomy may not be used for clinical staging. FIGO has excluded PET and MRI scans so that uniformity in the staging of cervical cancer is achieved, especially in developing countries where resources are limited. [4]

1.1.1 Significance of para-aortic lymph nodes:

The significance of finding positive pelvic and para-aortic lymph nodes, is that the staging and method of therapy may change. The status of a patient in an early stage cancer or advanced cancer with metastatic disease, determines whether surgery, radiation of chemotherapy will be used as a treatment modality. [3]

The Radiotherapy treatment plan , irradiated volume and radiation dose may change depending on the presence of para-aortic lymph nodes and distant metastases.

The figure below shows an image of a patient with metastases to the supraclavicular, para-aortic and iliac regions in a patient with advanced cervical cancer. [5]

Figure 1:F-18 FDG-PET image showing increased uptake in the supraclavicular, para-aortic and iliac regions consistent with metastatic disease in a patient with advanced cervical cancer. [5]

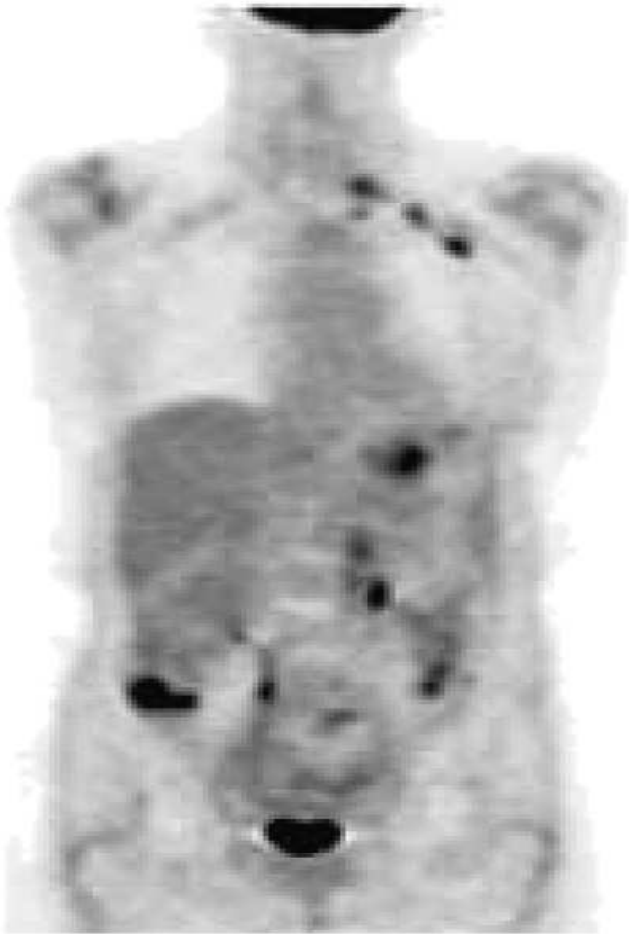

Reproduced with permission

1.1.2 Early invasive cancer:

Carcinoma of the cervix spreads in an orderly fashion. The uterine cervix tumour spreads from the primary tumour to the adjacent parametrial tissue in its early stages. Spread then occurs to the pelvic lymph nodes. From local pelvic lymph nodes the lymphatic spread then takes place to para-aortic lymph nodes and supraclavicular lymph nodes.

Non- nodal metastases also occur to sites such as lung, liver and bone.

Figure 2 below shows the early invasive appearance of carcinoma of the cervix with the colposcopic features . The diagnosis of early cervical cancer is done by history, examination and cervical biopsy. A colposcopic directed biopsy will confirm the diagnosis.

Figure 2: **Early invasive cancer: Note the raised irregular mosaics with umbilication (a), breaking mosaics (b), surface irregularity and the atypical vessels (c) after the application of 5% acetic acid**. [6]



Reproduced with permission

1.2 PET AS AN IMAGING MODALITY:

Positron emission tomography (PET) is an in-vivo, functional imaging modality that depends on the metabolic behaviour of viable cells. Malignant cells have a capability of increased glucose metabolism. This is the basis of using PET in cancer detection and prognostication. The radiolabeled glucose analogue, F-18 fluoro-2-deoxy-D-glucose (FDG), is the most commonly used radiotracer for PET. [1] F-18 FDG-PET utilises the fact that most cancers have increased glycolysis. This metabolic characteristic allows FDG-PET to detect metastases in normal-sized lymph nodes. This phenomenon allows detection of local as well as metastatic disease, using metabolic changes rather than anatomic changes in its imaging modality. Grigsby in a study in 2001, concluded that abnormal FDG uptake in lymph nodes is a robust predictor of disease progression. [3] Grigsby et al have shown that increased uptake in lymph node regions is associated with a worse prognosis and can alter therapeutic decisions. [3]

FDG is not utilised in the normal manner as physiological glucose. The presence of the tracer remains within the cell where it can be detected.

Metabolic trapping:

F-18 FDG radiotracer is produced by substituting a molecule of oxygen with a molecule of F-18 at position C-2. The radiotracer is introduced into the cells from the vascular compartments by glucose transport proteins in the plasma membrane which is then metabolised by hexokinase and phosphorylated by glucose-6-phosphate. However FDG is not synthesized in the manner of physiological glucose, rather it remains inside the cell.[7]

Figure 3, shows the molecular structure of F-18 radiotracer used in the FDG-PET machine, used in the management of cancer patients. [7]

Figure 3: Molecular structure of 2-deoxy-2-[^{18}F]fluoro-D-glucose (^{18}FDG). [7]

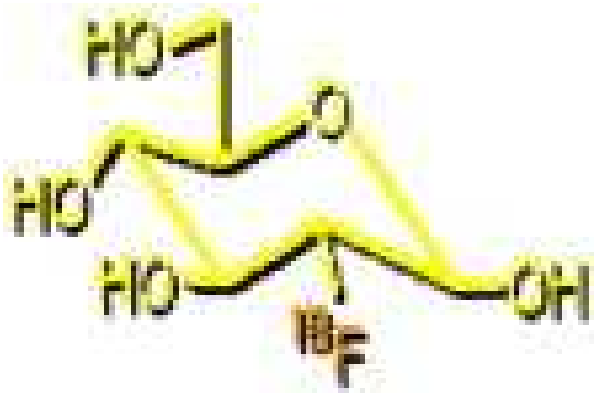

Reproduced with permission

Figure 4 a is an example of the F-18 FDG-PET/CT equipment which was utilised for the pre-treatment and post-treatment scans of our patients.

Figure 4 a : **F-18 FDG-PET/CT equipment used at Charlotte Maxeke Johannesburg Academic Hospital.**



Figure 5 demonstrates graphically how the low dose CT images are fused with the PET images to produce the transmission study.

Figure 5: PET/CT sequence acquisition: it will begin with a transmission scanning using available "low dose CT" during a minute. Emission PET scanning will extend until 20–30 min. In some cases, use of a "diagnostic CT" to acquire the transmission study[7]
Reproduced with permission

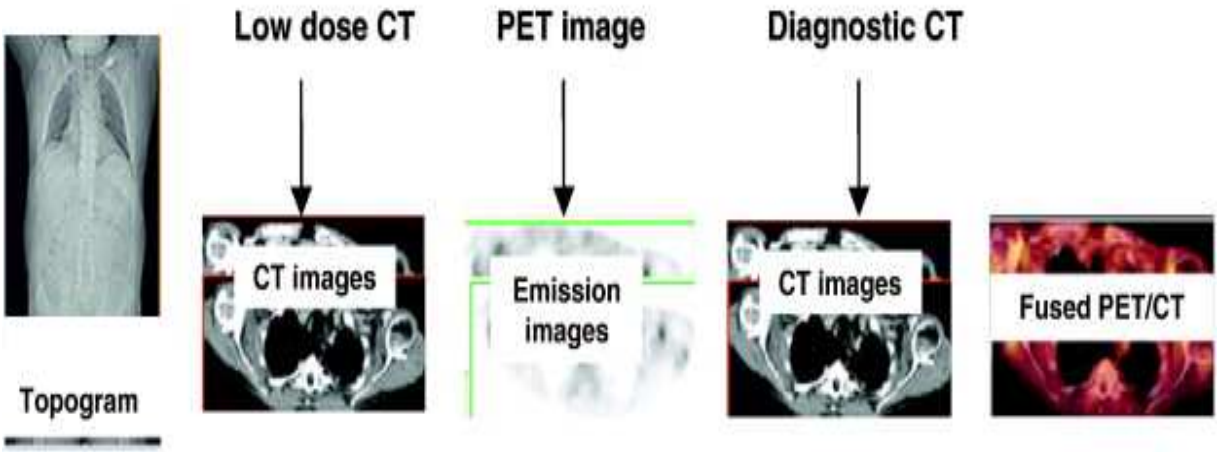

Reproduced with permission

1.3 IMAGING AND DETERMINING THE EXTENT OF CERVICAL CANCER.

Gynaecological malignancies are routinely diagnosed by history and physical examination. Some imaging modalities are used to supplement the diagnoses. The use of ultrasound and chest x-ray are utilised. Imaging modalities like computed tomography (CT) and magnetic resonance imaging (MRI) and positron emission tomography (PET) are not part of the FIGO system. In order to accurately stage cervix cancer one may utilise additional methods to improve diagnostic accuracy. The use of imaging like CT, MRI or FDG-PET/CT has been used, to improve on diagnostic stage so that metastatic disease can be detected earlier.

1.4 IMAGING LYMPH NODES AND DISTANT METASTASES:

1.4.1 Lymph nodes:

Lymph node metastases can be detected by imaging methods which detect the distortion of lymph node architecture . Lymphangiography was used in the past, which used the distortion of lymph node architecture to detect lymph node metastatic disease.[1]

Lymph nodes metastases may be also be diagnosed by several methods such as CT scans, MRI or ultrasonography. These methods have limited sensitivity. [3]

Lymphangiography has a specificity and sensitivity of 79% and 73% respectively. CT has a specificity and sensitivity of 34% and 96% respectively.

Ultrasonography a specificity and sensitivity of 19% and 99% respectively.

Perry Grigsby in the above study quoted Hellar et al in comparing the sensitivity and specificity of the respective imaging. The table below compares the respective findings above. [3]

Table 1. Comparing sensitivity and specificity of Imaging[3]

	SENSITIVITY %	SPECIFICITY %
LYMPHANGIOGRAPHY	79	73
CT SCAN	34	96
ULTRASONOGRAPHY	19	99

A conference report by Perry Grigsby, stated that FDG – PET is superior to conventional imaging methods for detecting metastatic disease, especially for lymph node metastases. [8] In fact, his study has shown that FDG-PET was found to be superior to CT and lymphangiography in suspected sites of metastases in pelvic lymphnodes, extra-pelvic lymph nodes, as well as visceral organs in patients with newly diagnosed advanced cervical cancer. [8]

The same conference report, showed that FDG-PET demonstrated abnormalities that were consistent with metastases more often than CT in pelvic lymph nodes (67% vs 21%) and in para-aortic lymph nodes (20% vs 7%) and PET also showed supraclavicular disease in 8%. [3]

The table below tabulated the above findings.

Table 2: PET vs CT Scans and detection of lymph nodes.

	Pelvic Lymph-nodes %	Para-Aortic Lymph-nodes %	Supraclavicular Lymph-nodes %
PET	67	21	8
CT Scan	20	7	

Limitation of F-18 FDG-PET for lymph node detection.

The use of F-18 FDG-PET has some limitation with regards normal physiologic activity in the genital tract and pelvis. Normal physiologic activity from the bladder or bowel can obscure disease in the pelvis. False positives may also be related to uptake of FDG tracer in hyperplastic nodes or normal physiologic activity can be misinterpreted as nodal metastases. [3]

The is also a pitfall in that the predictive value for negative F-18 FDG-PET findings in lymph nodes is unknown. However increased uptake is associated with a worse prognosis.

1.4.2 Progression-free survival based on lymph node status on FDG-PET:

It has been shown that progression free survival (PFS) based on FDG-PET lymph node status, is greater if metastases is present only in pelvic vs para-aortic vs supraclavicular lymph nodes. [8]

Figure 6 demonstrates that survival is better for no lymph nodes detected on FDG-PET, compared to findings when pelvic, para-aortic or supraclavicular lymph nodes are found.

Figure 6: Progression-free survival based on FDG-PET lymph node status: [8]

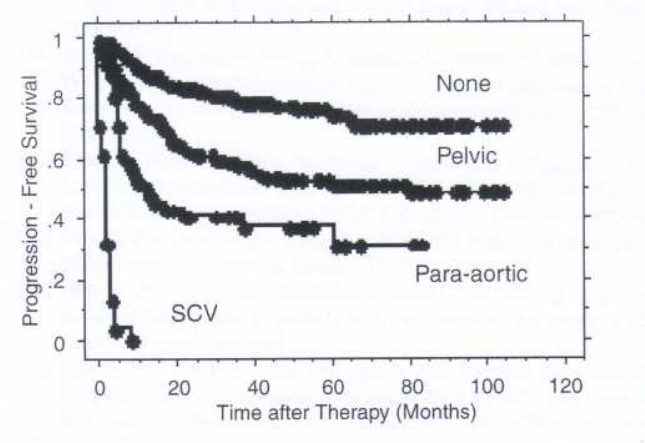

Reproduced with permission

In the United States of America , the Centre of Medicare and Medicaid Services has approved the use of FDG-PET in the initial staging in patients with cervix cancer. [8] This approval was based on the results by Perry Grigsby in his report in a Gynaecology Oncology Conference Report, demonstrating the use of FDG-PET in the initial staging in patients with cervical cancer. [8]

Assessment of para-aortic lymph nodes in advanced cervix cancer is also important. The stage as well as prognosis is prognostic ally important for progression-free survival. [9]

Neeta Pandit-Taskir quotes a study by Singh et al where the 3- year cause specific survival was 73% for those with no lymph node metastases, 58% with only pelvic lymph node metastases and 29% for those with pelvic and para-aortic lymph node metastases. [9] The 3- year cause specific survival was 0% for those with pelvic, para-aortic and supraclavicular metastases. [9]

F-18 FDG-PET imaging is therefore useful in obtaining information regarding lymph nodes in the pelvis, para-aortic lymph nodes and distant metastatic disease.

1.5 IMAGING LOCAL DISEASE:

CT of the abdomen and pelvis may be utilised to detect pelvic or local invasion by cervix cancer. However in terms of local disease or extent of cervix cancer, CT scans has not been shown to reliably detect parametrial invasion by the tumour.

MRI has been found to be accurate in localising the primary cervical tumour and evaluating parametrial extension. [8]

MRI may localise the primary cervical tumour and also evaluates myometrial and internal os evaluation. In contrast, CT is not a reliable method to detect parametrial invasion by tumour. MRI is good, but has a lower staging accuracy according to the Gynaecology Report (GOG) report. [8]

A prospective Danish Study, investigated the use of PET/CT as a supplement to clinical staging. [10] Results revealed that whole body FDG-PET for newly diagnosed cervical cancer, FIGO Stage $\geq$ 1B has a high sensitivity and specificity.

1.5.1 Standard Uptake Value:

Standard Uptake Value (SUV) is used in F-18 FDG-PET scans to evaluate the maximum metabolic activity by the cervical cancer. [11]

A PET scan creates images of cell activity, using SUV as a measurement. SUV describes the level of activity in a particular site compared to activity in the rest of the body. An SUV of 2.50 or greater can indicate metastatic disease.

Cancer treatment response is usually assessed with FDG PET by calculating the SUV on the highest pixel image in the tumour regions (SUV_{max}).

This SUV_{max} has been associated with treatment response and prognosis in patients with cervical cancer.

Kidd et al, have found that SUV_{max} of the cervical tumour at diagnosis was a sensitive biomarker of treatment response and prognosis for patients with cervical cancer. [11]

In cervix cancer, the primary tumour SUV_{max} which can be determined by PET scan, has been found to be at the time of diagnosis, a more significant predictor of outcome than FIGO stage, tumour volume, histology or lymph node involvement.

In essence SUV_{max}, assessed by FDG-PET at the time of diagnosis is a significant biomarker for disease progression, treatment response, as well as overall outcome in patients with cervical cancer. [11]

According to Kidd et al, SUV_{max} is a sensitive biomarker of treatment response and prognosis with cervical cancer.

It is an important tool for diagnosis and staging cancers. It correlates with the presence of lymph node at diagnosis, how well the primary tumour responds to treatment, the likelihood of disease recurrence and overall survival.

1.6 POST THERAPY MONITORING:

In cervical cancer, it has been stated that one-third of patients develop disease recurrence and that disease recurrences occur within the first 2 to 3 years after completion of therapy. [12] Predictors of disease recurrence include stage and pelvic lymph nodes at the time of initial diagnosis.

Current recommendations for the routine post therapy follow up of patients with cervical cancer include history and examination, followed by routine serial pelvic examination with pap smears beginning 3 months after completion of therapy. [12] This approach does not address early detection of disease recurrence in the pelvic lymph nodes and metastases to para-aortic lymph nodes. Additionally, pap smears in post therapy follow up may have a limited role due to radiation related pathologic effects. [12]

F-18 FDG-PET/CT in the post therapy setting is aimed to detect response to radical radiation therapy and to document any residual metabolically active disease. According to Grigsby, a 3 month post radiation FDG –PET is a good surrogate end-point for tumour control in cervical cancer. [12]

Grigsby in the study quoted above, studied 152 patients treated with radiotherapy, who underwent a 3 month post-treatment FDG-PET. Patients who were free of FDG-avid sites on a 3 month PET had a 5 year cause-specific and overall survival of 80% and 92% respectively. Abnormal uptake, in 20 patients had a cause specific survival of 32%. [12]

He also reported that the post treatment PET abnormalities, were found to be the most significant predictor of death from cervical cancer in this study. [12]

Perry Grigsby at the Mallinckrodt Institute in the U.S.A, now uses FDG-PET/CT in the routine follow up of all his patients with cervical cancer, to evaluate response as well as detect early recurrences post radiation treatment.

Progression –free survival curves are shown from his studies after a 3 month post-therapy FDG-PET. The survival for a negative FDG-PET vs a positive PET at 3 months are significant, see figure 7 below.

Figure 7: Progression-free survival based on a negative versus a positive 3 month FDG-PET.

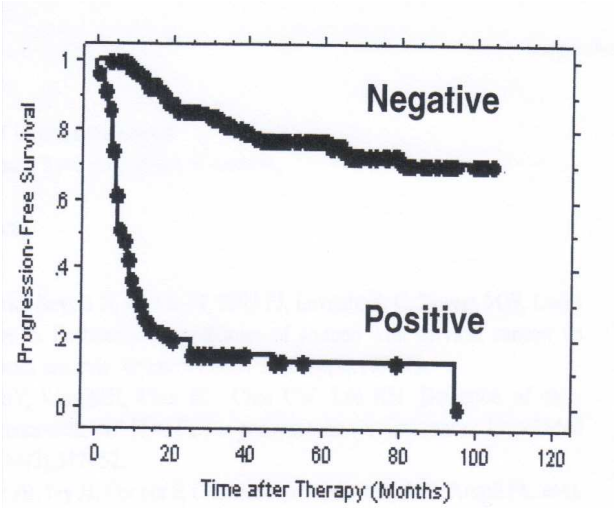

Reproduced with permission

The overall survival curves of patients who had a negative FDG-PET at 3 months, followed by FDG-PET at 12 months later are shown below in figures 8a and figure 8b. Figure 8a in Perry Grigsby studies show that survival is greater if patients are asymptomatic rather than symptomatic. Figure 8b demonstrates that of the asymptomatic patients that had a positive FDG-PET (with biopsy proven recurrence), salvage was possible and there were long term survivors. [12]

Figure 8:a and b: Overall Survival of a negative 3 month post therapy FDG-PET/CT. [12]

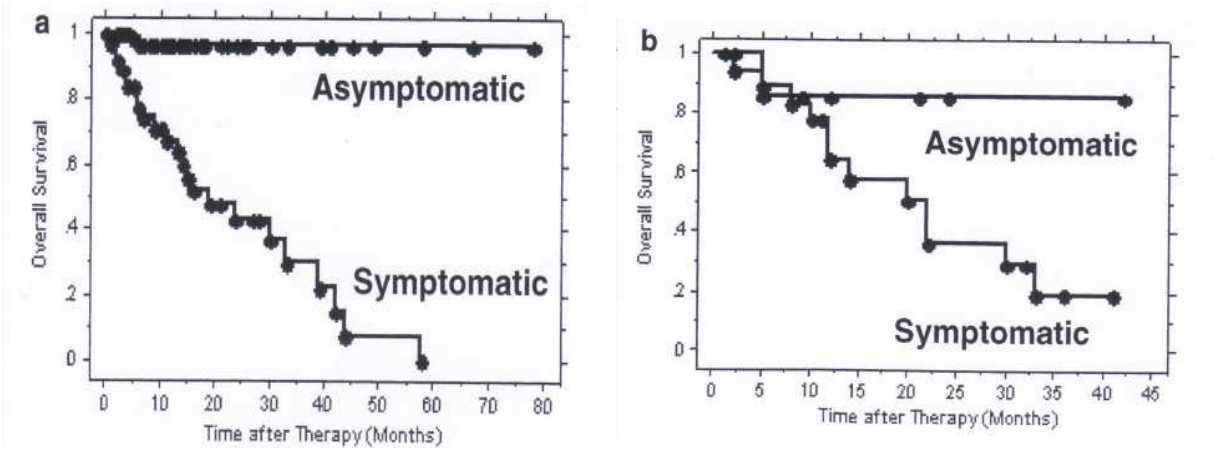

Figures reproduced with permission

Figure 9 below shows in his series, that on post-therapy monitoring, isolated para-aortic recurrences found on asymptomatic patients may be salvageable.[12]

Figure 9: Overall Survival after isolated para-aortic recurrence.

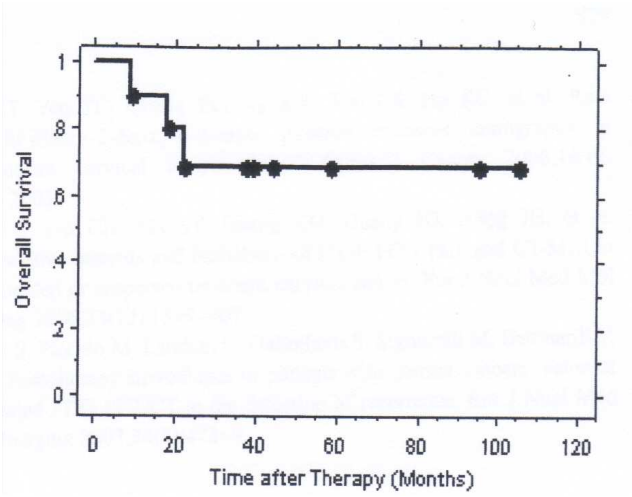

Figures reproduced with permission

These patients were found to have isolated para-aortic recurrence on FDG-PET/CT. [12]

The results clearly demonstrated that in post-therapy monitoring, F-18 FDG-PET/CT is both sensitive and specific in the post-treatment setting. Patients may be salvaged earlier with appropriate therapies on the detection of a recurrence.

CHAPTER 2:

LITERATURE REVIEW:

Initial diagnosis and staging of cervical cancer are usually achieved by history, physical examination and selected imaging.

Accurate staging is important for appropriate therapy and for prognosis.

Staging by FIGO does not require MRI, PET or PET/ CT. Hence a large number of pelvic and para-aortic lymph node metastases may be missed by conventional clinical staging.

Spread in Cervical Cancer:

Most gynaecological cancers spread from the primary organ, regionally and then through lymphatic spread, disseminating to distant sites.

Figure 10: Regional Lymph Node spread in Cervical Cancer. [13]

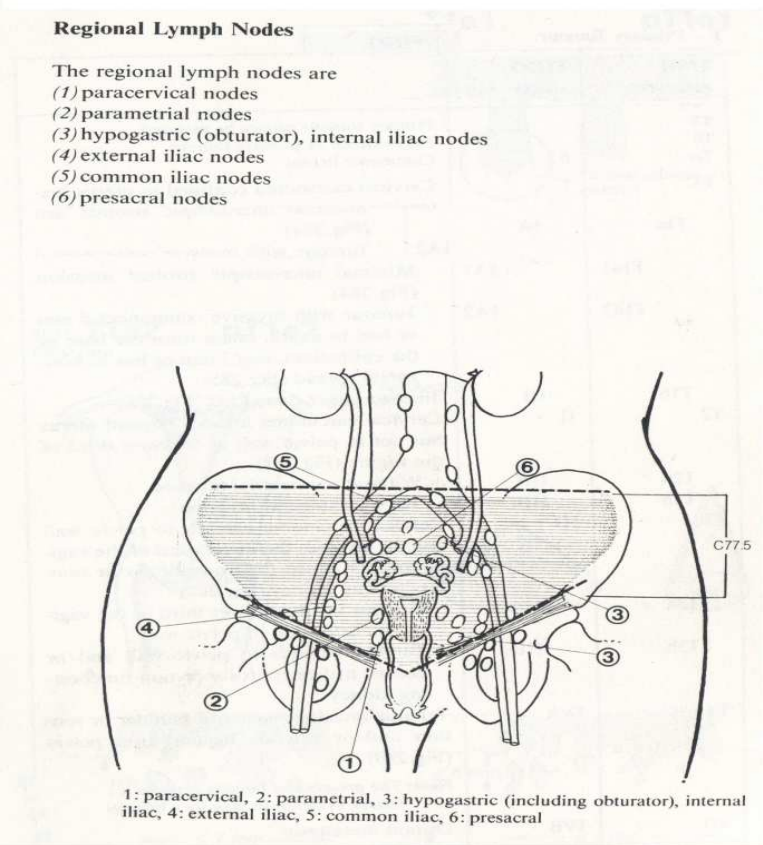

Literature reviewed will be discussed under the following headings, detailing the importance of FDG-PET in establishing a role in the management of cervical cancer.

2.1 LYMPH NODE STAGING BY PET.

2.2 DIAGNOSTIC VALUE OF FDG-PET.

2.3 TUMOUR UPTAKE BY F18-FDG-PET AS A BIOMARKER FOR CERVICAL CANCER TO EVALUATE RESPONSE AND SURVIVAL.

2.4 THE ROLE OF FDG-PET/CT IMAGING IN THE POST TREATMENT SETTING.

2.5 FDG-PET SCANNING AND THE HUMAN IMMUNODEFICIENCY VIRUS / AIDS SYNDROME.

2.1 LYMPH NODE STAGING BY PET:

Pelvic and para-aortic lymph node assessment is important to accurately stage cervical cancer. Cancer of the cervix spreads initially to local structures and local lymphatics. Later cancer spreads haematogenously to distant organs, e.g. lung, bone, brain and liver. Lymph node spread occurs from the primary cervix lesion, then to pelvic lymph nodes, para-aortic lymph nodes and supraclavicular lymph nodes.

Figure 11 represent metastases to the common iliac lymph nodes and figures 12 and 13 depict lymph node metastases to the external iliac and to the internal iliac lymph nodes respectively. [14] The primary drainage occurs in a progressive fashion from the internal and external iliac lymph nodes to the common iliac lymph nodes and then to para-aortic lymph nodes.

Diagrammatic representation of lymph node metastases in the pelvis:

Figure 11: Common iliac lymph nodes demonstrating regional drainage. [14]

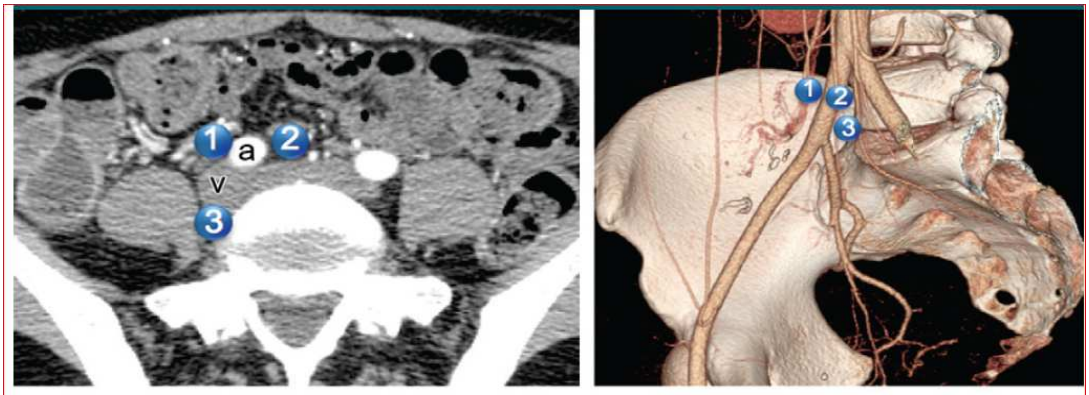

a. b.

Figure Common iliac lymph nodes. **(a)** Axial contrast material–enhanced computed tomographic (CT) image and **(b)** volume-rendered reformation of contrast-enhanced CT image show locations of named subgroups of common iliac lymph nodes: *1* = lateral, *2* = medial, *3* = middle. The relationship of these node locations to common iliac artery *(a)* and vein *(v)* can be seen.

Figure reproduced with permission

Figure 12: External iliac lymph nodes. [14]

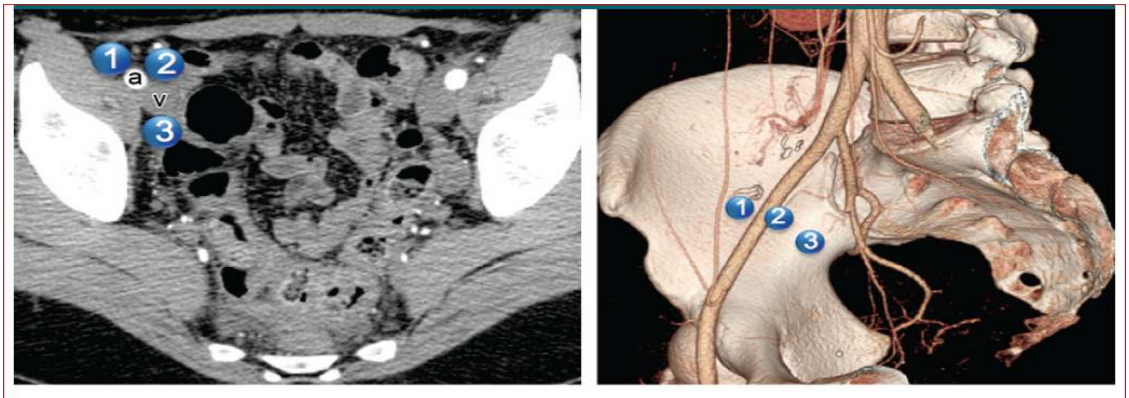

a. b.

Figure External iliac lymph nodes. **(a)** Axial contrast-enhanced CT image and **(b)** volume-rendered reformation of contrast-enhanced CT image show location of named subgroups of external iliac lymph nodes: *1* = lateral, *2* = middle, *3* = medial (including obturator). The relationship of these node locations to external iliac artery *(a)* and vein *(v)* can be seen.

Figures reproduced with permission:

Figure 13: Internal iliac lymph nodes drainage in cervical cancer: [14]

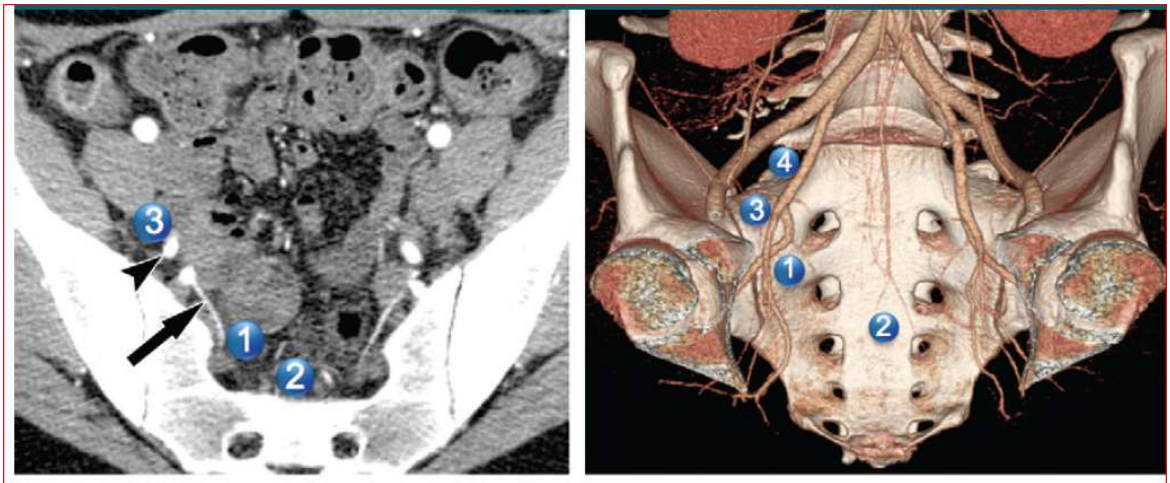

a. b.

Figure Internal iliac lymph nodes. **(a)** Axial contrast-enhanced CT image and **(b)** volume-rendered reformation of contrast-enhanced CT image show location of named subgroups of internal iliac lymph nodes: *1* = lateral sacral, which are adjacent to lateral sacral artery (arrow); *2* = presacral; *3* = anterior, which are anterior to anterior division of internal iliac artery (arrowhead); *4* = hypogastric.

Figure reproduced with permission

2.2 DIAGNOSTIC VALUE OF F-18 FDG-PET/CT:

Grigsby has shown that F-18 FDG-PET is superior to CT in unsuspected sites of metastases in pelvic lymph nodes and extra-pelvic lymph node metastases and visceral organs, in newly diagnosed advanced cervical cancer. [8]

The comparison of F-18 FDG-PET findings vs CT findings with regards to Perry Grigsby's findings are significant:

	PET	**vz**	**CT**
Pelvic	67 %		20 %
Para- aortic	21 %		7 %
Supraclavicular	8 %		-

This is an important study showing that FDG-PET showed abnormalities more often than CT did in the above findings. [8]

Whole body FDG-PET/CT scanning for newly diagnosed cervical cancer, FIGO stage ≥ 1B has a high sensitivity and specificity and can be a valuable supplement to the FIGO Staging procedure. [10]

This prospective study by Annika Loft et al , also looked at the value of PET/CT as a supplement to FIGO staging procedure in patients with newly diagnosed ≥ 1B cervical cancer. [10]

Patients in the study were divided into 2 groups, surgery and chemoradiation.

For nodal status in the pelvis for patients who had Total Abdominal Hysterectomy (TAH), FDG-PET showed the following:

PET/CT [TAH]	pelvic lymph nodes:
Sensitivity	75%
Specificity	96%
PET/CT [CHEMO-RADIATION]	Pelvic lymph nodes:
Sensitivity	75 %
Specificity	87 %

For para-aortic disease; PET- CT had the following in all patients:

[Surgery and non-surgical patients.]

	Sensitivity %	Specificity %
Para-Aortic	100	99
Distant	100	94

This study clearly demonstrated a high sensitivity of PET/CT for detecting para-aortic and distant metastases. [10]

Grigsby et al [3] have also shown that FDG-PET detects abnormal lymph node more often that does CT. Findings on PET are a better predictor of survival than those of CT in patients with carcinoma of cervix.

Perry Grigsby et al studied lymph node staging by PET in patients with carcinoma of the cervix. [3] Perry Grigsby compared CT and PET for lymph node staging.
The study compared results of PET/CT and FDG-PET alone for patients for lymph node staging in patients with carcinoma of the cervix and also the relationship of the findings to the prognoses of these patients. [3]
CT demonstrated abnormally enlarged pelvic lymph nodes in 20 (20%) and para-aortic lymph nodes in 7 (7%) of 101 patients.
FDG-PET demonstrated abnormal FDG uptake in pelvic lymph nodes in 67 (67%), in para-aortic in 21(21%) and supraclavicular in 8 (8%) of patients. [3]
The progression-free survival estimates based solely on pelvic lymph nodes in Perry Grigsby's studies showed the following: [3]
The 2 year Progression-free survival (PFS) rate was 73% for CT negative (-) patients and PET negative(-) patients.
The PFS decreased to 49% for CT (-) and PET (+) patients. (p= 0.001). [3]

Figure 14 below demonstrates the Kaplan-Meier progression-free survival curves based on pelvic lymph node status.

Figure 14: Kaplan-Meier Progression Free Survival estimates based on pelvic lymph lymph nodes.

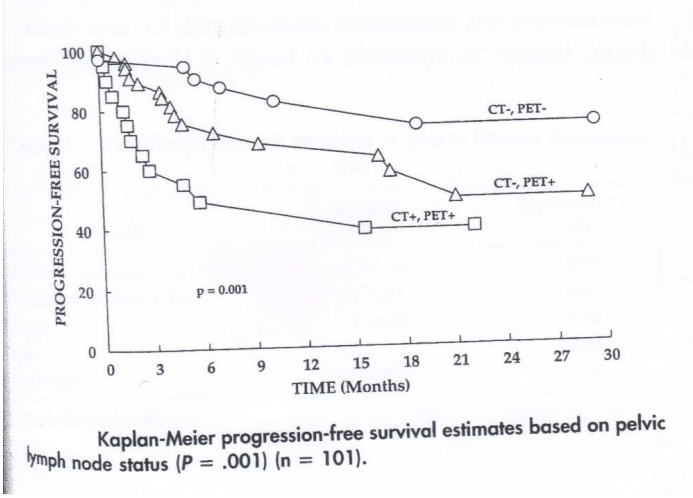

Kaplan-Meier progression-free survival estimates based on pelvic lymph node status ($P = .001$) ($n = 101$).

Figure reproduced with permission

The 2 year progression-free survival (PFS) based solely on para-aortic lymph node status, was 64% in CT negative and PET negative patients. The 2 year PFS was 18% in CT negative and PET positive patients and 14% in CT positive and PET positive patients. ($p<0.0001$). These findings showed that a positive PET affected greatly the PFS regardless of CT status.

The figure 15 shows the Kaplan-Meier survival curves based on lymph node status. This means that patients with a negative para-aortic lymph nodes had a 64 % 2 year PFS.

Figure 15: Kaplan Meier Progression Free Survival estimates based on para-aortic lymph node status. [3]

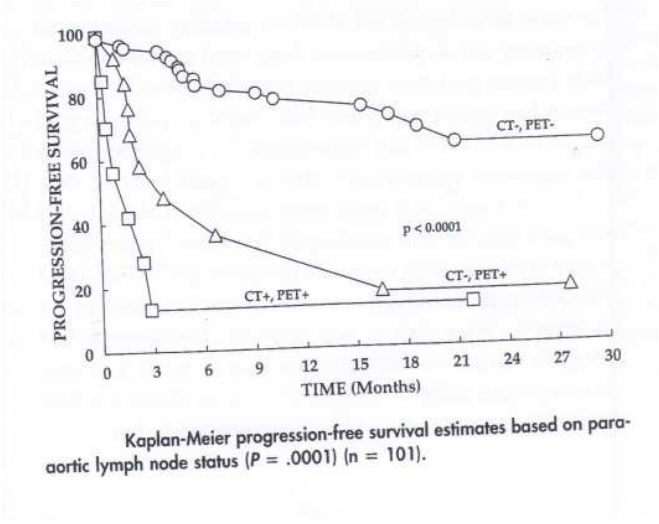

Kaplan-Meier progression-free survival estimates based on para-aortic lymph node status (P = .0001) (n = 101).

Figures reproduced with permission

Comparing PET negative (-) for PET positive (+), the 2 year PFS for –ve para-aortic nodes was found to be 64%, but if the para-aortic nodes was positive, the PFS decreased to 18%. (p, 0.0001)

Figure 16 demonstrates these results of the study quoted by P. Grigsby. [3]

Figure 16: Kaplan Meier Progression Free Survival estimates for patients with negative PET for para-aortic nodal involvement. [3]

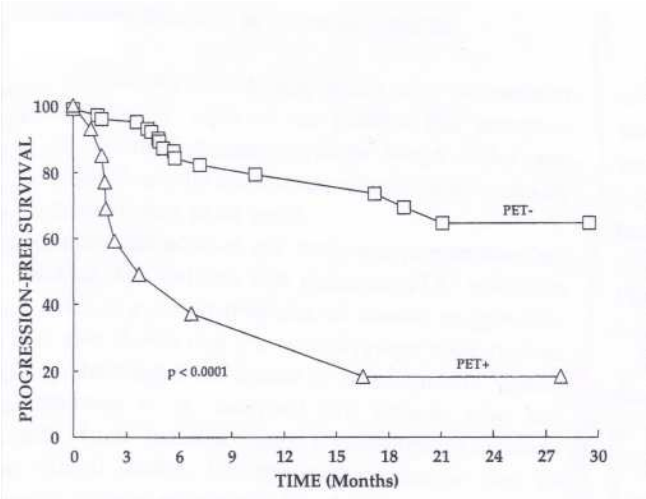

Kaplan-Meier progression-free survival estimates for patients with negative CT for para-aortic nodal involvement (n = 94), comparing those with positive PET (n = 14) and those with negative PET (n = 80); (P = .0001).

Their multivariate analysis showed that the most significant prognostic factor for progression – free survival was the presence of positive para-aortic lymph-nodes as detected by PET imaging. (P = 0, 025). [3]

Increased FDG uptake in lymph node regions is associated with a worse prognosis and can alter therapeutic management. In carcinoma of the cervix FDG – PET should be required because the therapeutic strategy (e.g. Surgery or Radiation and Chemotherapy) as well as outcome, will be changed if PET findings indicate positive para-aortic lymph nodes.

Conclusively, Perry Grigsby et al have shown in their data that abnormal FDG uptake in lymph nodes is a robust predictor of disease progression. In addition the site of lymph node exhibiting increased uptake is of prognostic significance. [3]

Kumar et al has reported in an editorial, [1] that FDG-PET has emerged as a useful tool for predicting survival and monitoring therapy in patients with cervical cancer. Kumar reports a study by Grigsby, Singh BA and Dehdasti et al who evaluated pre-treatment

-lymph node size

-irradiation dose

-failure patterns,

Using PET to score lymph nodes, positive or negative and using CT to determine lymph node size. Their results indicated that positive lymph nodes of any size at diagnosis were the most significant predictor for developing distant metastases. Distant metastases at diagnoses was the most common reason for treatment failure.[1]

2.3 TUMOUR UPTAKE BY F-18 FDG -PET AS A BIOMARKER FOR CERVICAL CANCER TO EVALUATE RESPONSE AND SURVIVAL:

The Standard Uptake Value (maximum) or SUVmax is measured by F-18 FDG-PET. This measurement has been done in a study by Kidd, Siegel, Dehdasti et al [11] to show that there is an association between the primary cervical tumour uptake (SUV)max and several factors namely; local control

risk of distant metastases

recurrence rate

overall survival.

The observations in this study showed that the primary tumour SUVmax was not related to the following factors:

patient-specific factors e.g.

histology

tumour stage

patient age or tumour volume

Rather primary tumour SUVmax was a predictive biomarker of the following:

Lymph node status

Persistent disease after treatment

Pelvic recurrence

Overall survival

The primary tumour SUVmax in this study [11] was a more significant predictor of survival than FIGO Stage, tumour volume, histology or lymph node involvement. This indicates that the primary SUVmax assessed by FDG-PET studies at the time of diagnoses is a significant biomarker for the following:

DISEASE PROGRESSION

TREATMENT RESPONSE

OVERALL OUTCOME IN PTS WITH CERVICAL CANCER. [11]

2.4 THE ROLE OF FDG-PET/CT IMAGING IN THE POST TREATMENT SETTING.

F-18 FDG-PET has been shown to have a role in the post treatment follow-up of patient with cervical cancer. [3] It is both sensitive and specific for the detection of persistent cervical cancer in the immediate post therapy setting (3 months) and in the long term follow-up of those patients.

Ryu and associates, in a GOG Conference Report in 2007, is quoted as having a sensitivity and specificity of F-18 FDG-PET for detection of recurrent disease as 90% and 70% respectively. [12] The majority of recurrences were detected within 6-18 months after diagnosis.

A retrospective analysis by Grigsby, in a 3 month post treatment F-18 FDG-PET, showed a 5 year cause-specific survival and overall survival of 80% and 92% respectively, for patients who were free of FDG-avid sites.

Persistent abnormal uptake in the cervix or lymph nodes was found to have a cause-specific survival of 32%. [12] By multivariate analysis, post-treatment PET abnormalities were found to be the most significant predictor of death from cervical cancer in this study.

A post treatment F-18 FDG-PET may pick up new sites of metastases. These patients may be enrolled onto novel treatment approaches and trials for new and persistent disease. [15]

In a study by Julie Schwartz et al, a prospective cohort validated the use of post-therapy FDG-PET as a predictor of clinical outcome in cervical cancer. [16]

Post Therapy FDG-PET:	percentage
Complete metabolic response	70
Persistent abnormal uptake	16
New sites of uptake (outside radiated area)	13

3 year cause-specific survival	percentage
Complete response	96
Persistent FDG uptake	43
New sites	14

In this study, cox proportional hazards showed that the 3 month post-therapy FDG-PET was the most significant predictive factor of progression free survival. ($p < 0.001$). HR OF 32.57. Confidence Interval 10.22 -103.82.

The rationale used in this post therapy study was 2 fold:

1. To obtain information on locally recurrent cervical cancer—to plan salvage treatment.
2. Most important rationale is to glean prognostic information, as early as 3 months after completion of treatment.

The significance of a 3 month post therapy FDG-PET, provides an immediate measure of response to therapy, acting as a robust predictor of outcome to the treatment of cervical cancer. [16]

2.5 FDG-PET SCANNING AND THE HUMAN IMMUNODEFICIENCY VIRUS / AIDS SYNDROME:

Acquired immunodeficiency syndrome (AIDS) is a disorder of cell-mediated immunity that causes characteristic malignancies and oppurtunistic infections, due to the Human immunodeficiency virus (HIV). [17]

Due to profound changes in the immunologic function, AIDS defining malignancies may occur due to the immunocompromised state. Cervical cancer is one of the AIDS defining malignancies. There is greater propensity for invasive cervical cancer to progress and metastasize in HIV disease.

There is limited data on the use of FDG-PET/CT regarding HIV infections and cervical cancer. However studies have shown that FDG-PET/CT is a valuable modality in the diagnoses, staging and restaging of malignancies associated with HIV infection. However the nuclear medicine specialist needs to keep in mind the differential diagnosis when reporting on patients with HIV infection. Infection and inflammation may also cause increased uptake on an FDG-PET scan. CD4 and viral load can aid in differentiating HIV nodes from cancerous nodes.

Limitations of FDG-PET and malignancies:

Both malignancy, as well as inflammatory cells utilise glucose as a source of energy. [18] The molecular basis of FDG-uptake in infection and inflammation is due to activated inflammatory cells e.g. neutrophils and macrophages , express high concentrations of glucose transporters that facilitate the movement of FDG through the cell membrane. This potential for FDG accummulation at sites of inflammation and infection, has resulted in false-positive results in the assessment of patients with cancer. [18] This false-positivity, has to be borne in mind particularly in the developing world, like South Africa, where there is a high incidence of Human Immunoviral disease and infection.

A study reported by Moodley et al, of Kwa-Zulu Natal in 2003, has reported a prevalence of HIV infection as high as 32.5% among antenatal attendees. [19]

Vernon et al (1999) demonstrated that HPV as well as HIV are independent risk factors for invasive cervical cancer.[19] It has been postulated that HIV virus may influence the pathogenesis of HPV associated cervical pathology by molecular interaction between HIV and HPV genes due to up regulation of E6/ E7 oncogenes by the HIV virus. Bearing this in mind, FDG-PET has been recognised as having a reduced specificity for cancer attributable to increased uptake with infection and inflammation. [20]

With the introduction of PET facilities in our developing countries, with a high incidence of HIV and tuberculosis (TB), a large number of possible false positives exist. [21]

It may prove difficult to differentiate between a malignancy, HIV infection and tuberculosis, [22] especially in countries where there is a high incidence of these infections.

However, studies have shown that FDG uptake increases over time in malignant lesions, wheras in inflammatory lesions uptake decreases or remains stable. [22]
TB may show increasing uptake with time.

FDG-PET data has shown that HIV-1 infections has distinct anatomical steps :
Involvement of the upper torso preceding involvement of the lower part of the body.
The degree of uptake is also related to viral load. [22]
O'Doherty reports that lymph nodes secondary to viraemia are typically slightly enlarged and display mild FDG-avid. There is also no cut off, of the size or standardized (SUV) uptake value which can be reliably used to differentiate a benign from a malignant lymphadenopathy. [17]
The sites of lymph nodes is also different between the two entities. The HIV related viral induced lymphadenopathy is more superficially distributed e.g. the neck, axilla or inguinal regions.

Invasive cancer of the cervix and metastatic lymph nodes:

Invasive cervix cancer spreads in a predictable fashion, initially spreading by local extension to local structures and regional lymphatics, and lymph nodes. The tumour spreads from the primary lesion sequentially to pelvic lymph nodes, para-aortic lymph nodes and supraclavicular lymphnodes. Later dissemination occurs haematogenously to distant organs e.g. lungs, liver, bone and brain. [8]

The role of FDG-PET in cervix cancer is well established. FDG-PET demonstrates abnormal cervical uptake in almost all invasive cervix cancers. It is highly sensitive in detecting metastatic lymph node deposits in the pelvis, para-aortic and supraclavicular regions.

Tuberculosis and FDG-PET:

Active pulmonary TB as well as extrapulmonary tuberculosis demonstrate increased FDG uptake. This increased uptake makes it difficult to differentiate between TB, malignancy and infection. Tuberculosis may need to be excluded with sputum culture, bronchial washings and correlation with FDG-PET pattern as well as CT scan information. Some studies recommend double-contrast phase FDG-PET to differentiate between inflammation and malignancy. [17]

Viral Load and FDG uptake:

O'Doherty reports a study evaluating FDG uptake in lymph nodes in patients with HIV infection: [20]

- Uptake of FDG in lymph nodes in patients with HIV was variable.
- This uptake could range from no uptake to high uptake. [20]

Scharka et al evaluated the pattern of lymph node involvement in different stages of infection: [20]

- Patients who recently sero-converted have uptake corresponding to response in nodes in response to viral infection.
- Nodes were situated in the head and neck, axilla and spleen.
- Later stages showed uptake in peripheral nodes and spleen.
- Advanced disease showed uptake in the ileocecal valve and mesenteric nodes –with lower uptake in the peripheral nodes.

Brust and co-workers: [20]

- Evaluation of uptake of FDG in different groups and viral loads.
- Control patients without HIV infection had no uptake in the lymph nodes.
- Early HIV infection with high viral loads > 84 000 copies/ml had uptake in cervical, axillary, hilar, para-aortic and inguinal lymph nodes.
- Patients on HAART anti-retroviral medication with negligible viral loads had no FDG uptake in lymph nodes.
- Patients who stopped HAART had nodal uptake again.
- Advanced HIV disease had uptake in variable lymph nodes.

Regarding the South African context:

The introduction of PET in developing countries is going to improve the healthcare of patients affected by cancer; however there may be false positive results. Sathekge feels that the use of F-18 FDG-PET can aid in the diagnosis and follow up of various infective diseases, as lymphocytes show increased glycolysis compared with resting cells which can be visualised with F-18 FDG-PET/CT. [21]

A major attribute of PET is the fact that it can quantitate the F-18 FDG uptake, which also allows monitoring the infectious or inflammatory process during the course of the disease. [21]

The presentation of TB is different than that observed in the HIV- negative patient, especially if the CD4 is less than 200: apical predominance is less pronounced, while consolidation, cavitation and haematogenous disseminations are less prevalent. F-18 FDG-PET/CT detects altered metabolic activity and demonstrates sensitivity for infection in the setting of lymphopenia and neutropenia.

FDG-PET is indeed relevant in discerning the location and extent of lymph node uptake. However, biopsy is required to identify whether the disease is infective e.g. due to HIV disease or it is indeed malignant in nature.

2.6 TABULATED LITERATURE REVIEW

TABLE 3: ADDITIONAL LITERATURE REVIEW

Author-review centre	Study	Period	Use of PET
1.Ahmed Salem Amman, Jordan	Review Pre Treatment	April 2011	- pre Treatment effective - use in RT planning
2.Chirag Patel.Leeds.UK	Article Pre Treatment	May 2011	- Role of FGD PET/CT in primary evaluation of Cervix cancer (evaluating lymph node status and distant mets) - PET also to determine prognosis, assess Treatment and evaluate Disease recurrence.
3.Haie-Meder C , Mazeron R et al	Pre Treatment	Aug 2010	- detection of lymph node in advanced cervical cancer, lymph node status in the pelvis and detection outside pelvis, esp. para-aortic area
4. Kidd. St. Louis	Prospective Randomized controlled trial	2009	PET>CT for lymph node staging, linked to PFS. - nodal involvement is linked to stage
5. Kidd, Siegel, Dehdasti, Grigs. St Louis.	Prospective	Oct 2008	- SUV(PLN) as a marker to predict Treatment response, pelvic recurrence risk DSS in Patients with cervical cancer
6.Ritu Salani, Floor J, et al. Society of Gynae oncologist	Review	March 2011	- surveillance for Gynae cancer recurrence in women who had a response to primary ca Treatment.
7.Julie Schwarz, Barry S	Prospective	Sept 2006	Post Treatment PET as a predictor of survival

LITERATURE REVIEW CONTINUED

Author-review centre	Study	Period	Use of PET
8.Sivas Austral Herschtal	Prospective	2007	Post Treatment PET usage to establish complete MR, partial MR or progression
9. Son H, USA Kosit. Mnt Sinai	Abstract	2010	Prognosis - based on stage, size Lymph node - (pre Treatment PET) - Post Treatment PET for disease recurrence
10.Kang et al. Korea	Prospective	2011	PET for detecting distant recurrence
11. Yilmaz M et al.Turkey	Prospective	2010	Pre Treatment FDG uptake of cervix and Lymph node
12. Schwarz. Washing. St Louis	Prospective	2008	PET pre -Treatment during, post Treatment for Brachytherapy Treatment planning
13.Schwarz	Prospective	2006	Post Treatment to validate Association between Metabolic response and long term survival.
14. Yildrim. Turkey	Prospective	2008	PET- Pre Treatment in planning management and EFRT (extended field radiation.)

CHAPTER 3: THE STUDY.

3.1 STUDY OBJECTIVES:

This study aims to introduce the utlisation of F-18 FDG-PET/CT as:

(1) A comparison with the current FIGO staging in the pre-treatment setting.

(2) F-18 FDG-PET/CT as a tool to assess response to radiation therapy. (Post treatment.)

(3) To determine if radiation target volumes as applied at Charlotte Maxeke Johannesburg Academic Hospital should be modified in future by pre-radiation PET findings, e.g. if positive para-aortic lymph nodes are detected.

- A para-aortic field should be included.
- If a large primary tumour is present, without disease beyond the pelvis, then 3-D planned brachytherapy may be used.
- Also if no lymph nodes found in the pelvis then concurrent chemo-therapy may be omitted.

3.2 METHODOLOGY: Design and Setting under the following:

Time frame

Setting: Charlotte Maxeke Johannesburg Academic Hospital

Ethics clearance

Stratification and selection

Patient consent

Procedure prior to radiation

Method of F-18 FDG-PET tracer administration.

Pre-treatment cohort patients.

Post-treatment cohort patients.

Time Frame:

This was a prospective randomised controlled trial, commenced in April 2010.

Setting: Trial site selection: Charlotte Maxeke Johannesburg Academic Hospital.

Date of commencement of trial: April 2010 and concluded in January 2012.

Number of patients enrolled into trial: 37

In total 67 FDG-PET studies were performed for both the pre-treatment and post-treatment scans.

Ethical clearance: obtained from Human Research Ethics Committee. Ethics no M10319

Stratification and Selection:

Patients were stratified from clinical stages Ibi to stage IIIb (FIGO).

Patient consent:

1. Patients were counselled about the proposed radiation treatment they were to receive (based on department protocols).
2. Written informed consent for trial.
3. Patients were advised on preparation for PET/CT scan. (Annexure 3)
4. Written consent for radiation was obtained.
5. A pre radiation F18 -FDG PET/CT scan was done.
6. A post treatment F-18 FDG PET/CT scan was done 3 months after radiation.

Procedure prior to radiation:

All patients had the routine pretreatment investigations, including the following:-

- Routine history
- Examination including Gynaecological examination
- Biopsy conclusive of invasive cervical cancer. The interval between biopsy and scan differed in patients depending on tracer availability and booking for scans.
- Hematological i.e. FBC, U-E, LFT
- HIV status after pretest counseling. Viral load was not done for economic reasons.
- Radiological: chest x-rays
- Ultrasound (Imaging modality acceptable for FIGO staging
- Ultrasound examination - with respect to liver metastases
  - kidney for hydronephrosis

Patients were clinically staged after the above investigations.

A pre treatment F-18 FDG PET/CT scan was done on all patients prior to radiation. Patients were then treated according to clinical stage Ibi to stage IIIb, as PET 'Stage' was not used to alter routine clinical management. Patients then had a post – treatment F-18 FDG-PET/CT scan after 12 weeks of radiation.

Method of F-18 FDG-PET/CT tracer administration.

- F-18 FDG PET/CT scan allows metabolic evaluation of malignancy using F-18 FDG tracer.
- In our centre the Siemens biograph 40 PET – CT was utilised.
- Between 10 – 15 (mCi) tracer was injected after pre hydration (Annexure 3) 10 (mCi) of tracer is ordered but depending on decay of the isotope, delivery of the isotope, as well as patient booking. 6 to 12 (mCi) of tracer is injected.
- Oral hydration was maintained.
- Haemoglucotesting was done prior to tracer injection to check glycemic control.
- After 60 min, PET – CT imaging was obtained using contrast if no contraindication to the use of contrast existed.
- Axial attenuation – corrected images were obtained; reformatted in coronal and sagittal planes.

PET images are displayed on a workstation computer and interpreted by a nuclear medicine physician, experienced in PET scanning in our department.
Correlation with anatomic imaging namely CT was utilised.
PET imaging defines the extent of the disease at diagnosis. It aids in selecting therapy, such as surgery, radiation, chemotherapy or combinations thereof. [12]

Pre-Treatment cohort patients:

As mentioned 37 patients were recruited onto the trial for the treatment of invasive cervical cancer. These patients were diagnosed and treated from April 2010 to the end of December 2011. 36 patients underwent a pre – treatment PET scan.
One patient did not have a pre-treatment PET scan.

Patients received radiation and/or chemo radiation based on departmental protocol. Radiotherapy was administered for all patients and consisted of external beam radiotherapy and intracavitary brachytherapy.

Concurrent chemotherapy was given to all candidates who were stable clinically and haematologically. Cisplatinum based chemotherapy was used.
Cisplatinum chemotherapy was administered at a dose for 80mg/m^2 3 weekly.

Post -Treatment cohort:

Patients who completed concurrent chemo-radiation presented for a post-treatment F-18 FDG PET/CT, 3 months after treatment. Repeat F-18 FDG-PET scan emulated the pre-treatment F-18 FDG PET scan. The dosage of F-18 tracer was the same as the pre treatment scan for individual patient for pre and post treatment.
67 F-18 FDG-PET/CT studies were performed for both the pre and post treatment scans.

3.3 RESULTS:

3.3.1 Thirty seven (37) participants entered this study after being enrolled onto the trial. Their ages ranged from 27 to 76 years. The mean age of the participants was 43 years.

The main histologic subtype was squamous cell carcinoma, 67.57% followed by adenocarcinoma at 27.03%. Adenoid basal and neuroendocrine each accounted for 2.70% respectively.

Regarding FIGO staging, the majority of patients were FIGO stage IIb (54%) followed by IIIb (35%), stage IIIa comprised of 5.4%.

Stages IIa and Iva both constituted 2.7%.

59.46% of the group were HIV positive.

HIV negative patients constituted 40.54 %.

Of the HIV positive group, the mean CD4 at the time of diagnoses was 385.

The lowest CD4 in the group was 119.

Metastatic disease diagnosed on pre-treatment FDG-PET scans, not clinically diagnosed on FIGO staging, showed that metastases occurred to the liver in 33%, lung 36% and to the bone in 27.78% of patients.

Of the para-aortic lymph nodes diagnosed on the pre-treatment PET scan, 47% had lymph node positive uptake. A mean standard uptake value (SUV) for the para-aortic disease was 7.6 with a maximum standard uptake value (SUV) of 22.49.

The percentage of patients with positive supraclavicular lymph nodes was 25%

The volume of the primary cervical tumour on the pre-treatment scan showed an SUV mean of 15.26 and with a maximum SUV of the primary tumour of 40.71.

Regarding FDG-PET staging, 50% of patients were upstaged to stage IVb due to metastatic disease. Table 6 shows the pre-treatment PET findings with respect to stage breakdown.
Of importance in the clinical staging and pre-treatment work-up, none of the patients on routine investigations showed any liver, lung, bone or para-aortic metastases. In contrast to FIGO staging, 18/36 patients (50%) showed distant metastatic disease as demonstrated by the pre-treatment scan.

The significance of HIV association is relevant to the stage, with the association between stage II and stage IV being statistically significant. (Fischer's exact test 0.002)
Although HIV showed this statistical significance between PET stage II and PET stage IV; CD4 did not show any significant association with PET staging. (rank sum analysis).

The standard uptake value (SUV) in the primary cervical tumour was shown to have an association with para-aortic lymph nodes, where the uptake was greater than 2.52 for the para-aortic lymph nodes, as compared to no uptake. A cervix volume of 18.35 had an association with positive para-aortic lymph Nodes. (Kruskal-Wallis test).
This statistical association was confirmed using the Post Hoc Scheffe test.

Of relevance in this study was the association between clinical stages and PET stages. There was poor agreement between clinical stage and PET stage. The SAS method of statistical analysis showed that the clinical FIGO staging and the PET staged patients had no association.
Kappa statistics value 0.0984. 95% Confidence interval (0.0157 – 0.1812)

3.4 DEMOGRAPHICS:

36 patients had pretreatment PET scans. Only 31 patients had a post treatment scan. In 37 patients the median age at diagnosis was 43 years, for invasive cervical cancer.

3.4.1 Age: The youngest diagnosed was 27 years,

The oldest patient in this cohort was 76 years.

3.4.2 Stage at diagnosis:

Table 4:

Stage at diagnosis: Stage Breakdown n=37

STAGE	COUNT	PERCENT
IIA	1	2,702
II b	20	54,054
III a	2	5,40
III b	13	35,135
IV a	1	2.702

3.4.3 Histological subtypes: (n =37) Percentage

Squamous cell	25	67, 57
Adenocarcinoma	10	27, 03
Adenoid basal	1	2, 70
Neuroendocrine	1	2, 70

The main histological subtypes of squamous cell carcinoma of the cervix is depicted by figure 17 and the histopathological type of adenocarcinoma in figure 18.

Figure17: Histology of well differentiated keratinising squamous cell carcinoma. [6]

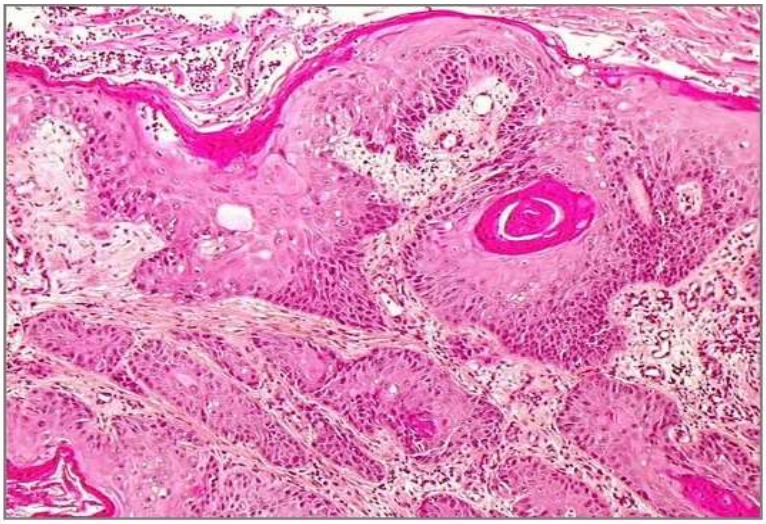

Figure reproduced with permission

Figure 18: Well differentiated adenocarcinoma of uterine cervix. [6]

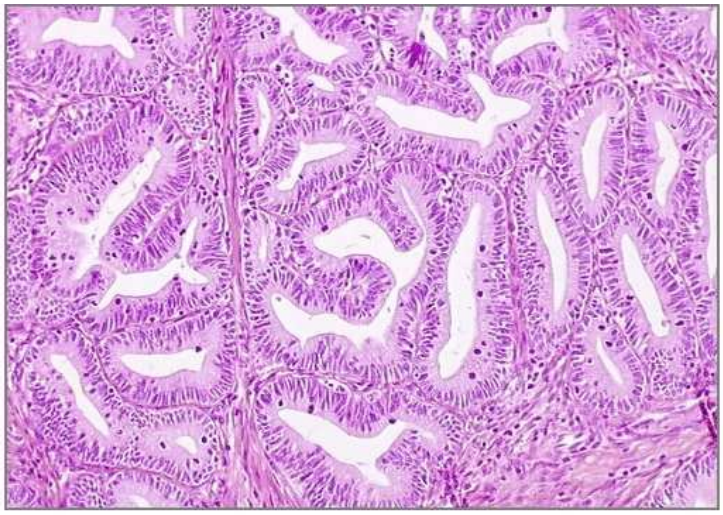

Figures reproduced with permission

3.4.4 HIV Status.

HIV status and positivity (n=37)		Percentage
HIV positive disease	22	59, 46
HIV negative	15	40, 54

3.4.5 CD 4 (HIV +VE DISEASE).

Valid n=22 At diagnosis.

Median	328, 5
Mean	385, 85
Min	119

Viral loads were not done due to economic factors.

3.5 METASTATIC DISEASE FOUND ON PRE TREATMENT PET SCAN:

NB. No liver or lung or bone metastases were found on clinical or FIGO stage.

3.5.1 Liver metastases	(n =36) PET Scan	
Positive PET	3	33%
Negative	33	8, 33

3.5.2 Lung metastases	(n=36)	
Positive on PET	11	36,56%
Negative	25	

3.5.3 Bone Metastases	(n=36)	
Positive	10	27,78%
Negative	26	

3.5.4 Para-aortic lymph nodes on PET pre-treatment:

Para-Aortic Lymph node positive (n-36)

22 patients with uptake positive on PET scan

5 with uptake < 2, 52 SUV

17 with uptake > 2, 52 = significant

Approximately 47% (17/36) patients had para-aortic LN positive.

Mean SUV of para-aortic lymph nodes on pre- treatment scans:

Mean SUV of the Para-aortic Lymph Node 7, 6

Max SUV of the Para-aortic Lymph Node 22, 49

3.5.5 Supraclavicular lymph node positive on pre-treatment

N=36

9 patients had positive uptake for supraclav LN on PET scan pre therapy = 25%

Mean	SUV	2, 77
Median	SUV	1, 68
Max	SUV	6, 93

3.5.6 Hilar lymph nodes on pre-treatment PET scan:

Mean	SUV	6, 34
Max	SUV	18, 32

Percentages of HIV POSITIVE patients were shown to be significant for stage 11 and stage 1V disease, noted in 3.7.3

3.5.7 Volume / SUV of the primary/cervix

Pre-treatment scan

Cervix SUV MEAN	15, 26
SUV MAX	40, 71

3.6 PET STAGING PRE-TREATMENT.

3.6.1 PET STAGING PRE-TREATMENT TABLE:

Table 5: PET STAGING [PRE TREATMENT] N=36

STAGE	COUNT	PERCENTAGE
Ibi	3	8,33
II a	3	8,33
II b	4	11,11
III	2	5, 55
IV A	6	16, 67
IV B	18	50, 00

3.6.2 ASSOCIATION BETWEEN CLINICAL STAGES:

The SAS statistical method was used for statistical analysis between clinical stage and PET stage. Using kappa statistics there was poor agreement between clinical stage and PET stage.

Value of kappa statistics = 0, 0984

95% confidence (0, 0157 – 0, 1812)

3.6.3 SUV CERVIX ASSOCIATION WITH PARA-AORTIC LYMPH NODES (PRE-TREATMENT)

Statistical analysis showed significance towards SUV uptake > 2, 52 for para-aortic lymph nodes as compared to no uptake (Cervix SUV mean 18, 34 for significant para-aortic uptake) [p = 0,04689]

A cervix primary tumour volume of 18, 35 (mean) had association with **positive** uptake for para-aortic lymph node. [Kruskal – Wallis test].

This statistical significance was also confirmed using the Post Hoc Scheffe test.

(p = 0, 02).

This may imply that a higher SUV in cervical primary tumour needs close follow-up because of a higher metastatic potential to e.g. para-aortic lymph nodes.

3.7 HIV DISEASE AND PRE-TREATMENT PET STAGING:

3.7.1 HIV negative vs PET stage (n=36).15 patients are negative on the trial.

Stage	no of Patients	percentage
IBi	3	8.33
III	2	55.55
IV a	4	11.11
IV B	6	16.66

3.7.2 HIV positive vs PET Stage

II a	3	8, 33
II b	4	11, 11
IV a	2	55, 55
IV b	12	33, 33

3.7.3 SIGNIFICANCE OF HIV ASSOCIATION WITH PET STAGE.

7/21 patients +VE in stage 2

14/21 patients +VE in stage 4

Fishers exact test = 0,002

This was significant.

This clearly shows an association between PET stage and HIV positive patients. The greatest was in stages II and stage IV.

3.7.4 CD4 and PET STAGE:

Although HIV showed statistical significance between PET stage 2 and PET stage 4, CD4 did not show any significant association with PET stage (Rank sum analysis)

3.8 PARA AORTIC LYMPH NODES ON PRE-TREATMENT SCAN.

3.8.1 PRE TREATMENT: PARA-AORTIC LYMPH NODE STATUS WITH DISTANT METASTASES:

Table 6: Para-Aortic lymph nodes – Pre- treatment and size, with distant Metastases

Total number of patients (n)	No Nodes (nil)	0-2cm	>2cm	0-2cm with distant metastases	>2cm with distant metastases	No nodes with distant metastases
36	15	12	9	10	8	1

Explanation: In the 0-2cm para-aortic lymph nodes from a total of 12 patients, 2 patients did not have distant metastases; with this size of lymph nodes. This is 2/36 patients which means 5, 56% potentially can be salvaged from extended field radiation in the pre-radiation group.

This means that if the para-aortic lymphnodes have disease and is biopsy positive, then we can extend our radiation fields to potentially cure patients if no other distant metastasis is present.

3.8.2 POST RADIATION: PARA-AORTIC LYMPH NODE STATUS WITH DISTANT METASTASES.

Table 7: Post Radiation: Para-aortic lymph node status with distant metastases

Total no of patients	No of Nodes	0-2cm	>2cm	0-2cm with distant metastases	>2cm with distant metastases	No nodes with distant metastases.
31	14	7	10	4	9	3
45,16%	45,16%	22,58%	32,36%	57,14%	29,03	96,77%

3/7 patients had no nodes, in the 0-2cm lymph node group. In the >2 cm group only 1/10 patients i.e. 10% had no distant mets.

Explanation/Significance

3/31 patients ~ 9,68 ~ 10% of patients will be potentially salvageable if a Post – radiation PET scan is done.

An extended field for para-aortic disease can be used, if biopsy positive for cancer.

3.9 Patient Characteristics Table:

Table: 8: **PATIENTS CHARACTERISTIC TABLE.**

CHARACTERISTIC	**VALUE**
AGE (YRS): RANGE	27 – 76
MEAN AGE	43
HISTOLOGY (NO OF PTS)	37
SQUAMOUS	25
ADENOCARCINOMA	10
ADENOIDBASAL	1
NEUROENDOCRINE	1
FIGO STAGE:	
1A1	-
1A2	-
IB1	-
IIA	1
IIB	20
IIIA	2
IIIB	13
IVA	1
IVB	-

HIV STATUS:			
HIV +VE			15
HIV –VE			22
CD4:			
CD4 (Mean)			385
CD4 (Max)			1021
Liver metastasis on PET scan : positive			3
	negative		33
Lung metastasis	positive		11
	negative		25
Bone Metastasis	positive		10
	negative		26
Para-aortic uptake	< 2.52		5
Para-aortic uptake	> 2.52		17
Supraclavicular lymph nodes	positive		9
Hilar lymph node	positive	mean SUV	6.34
Hilar lymph node	positive	max SUV	18.34
Cervix		mean SUV	15.26
Cervix		max SUV	40.71

3.10 Figures of patients who had FDG –PET/CT at Charlotte Maxeke Johannesburg Academic Hospital:

Figure 19a: shows a post radiation scan of a patient with multiple para-aortic lymph nodes and multiple liver lesions.

Figure 19b: A post radiation scan of the patient demonstrating a large liver lesion in Segment 2. The measured SUV in this lesion was 20.77.

Figure 20a : A post radiation scan of a patient showing multiple bilateral pulmonary nodules. These lung nodules were not diagnosed on the pre-radiation scan of this patient.

Figure 20b: A post radiation scan of a patient showing progression of disease in the abdominal lymph nodes.

Figure19 a : A Post Radiation Scan of a patient with multiple para-aortic lymph nodes and multiple liver lesions at Charlotte Maxeke Johannesburg Academic Hospital.

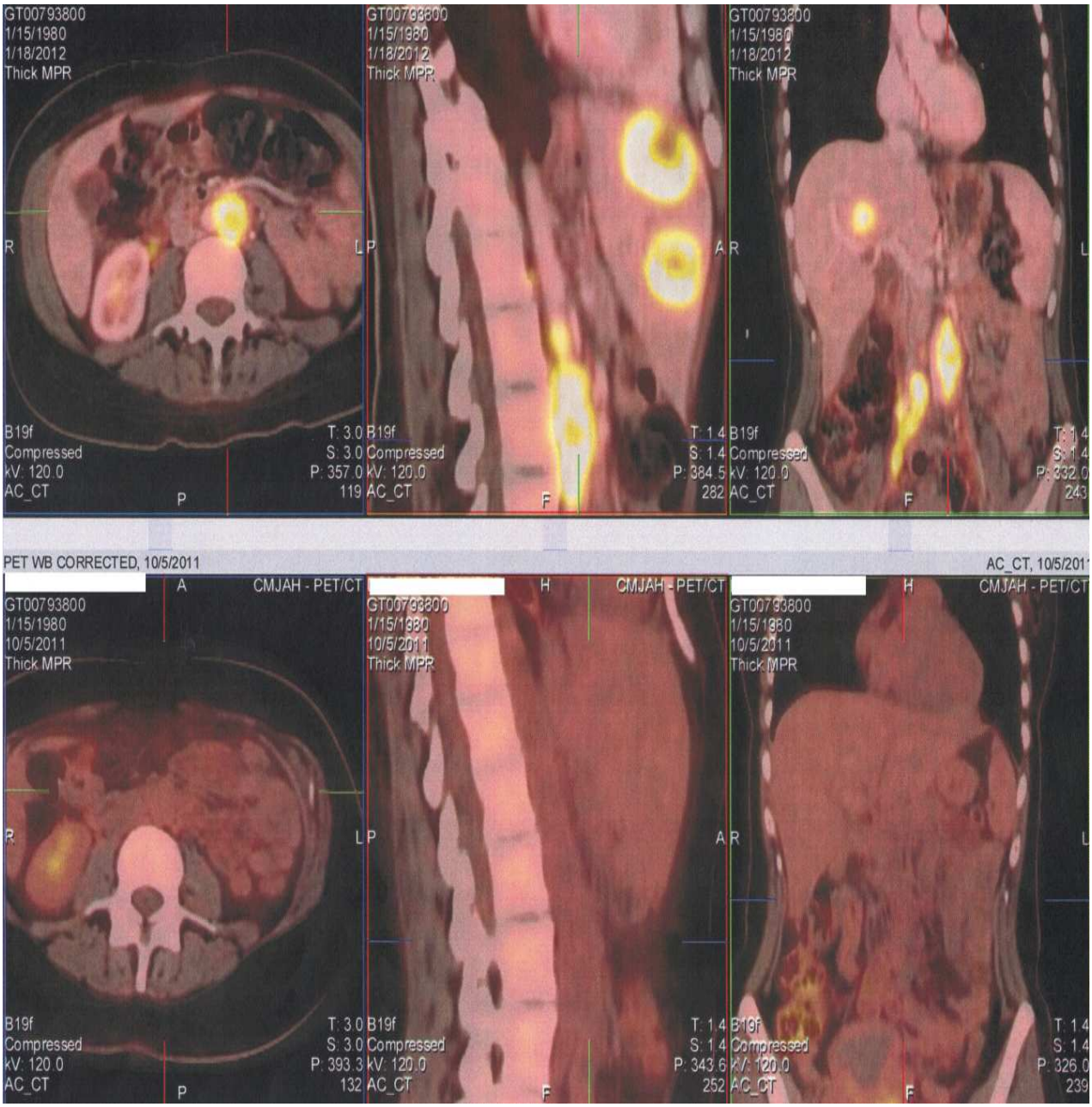

Figure 19 b: Same patient with a large liver lobe lesion in segment 2, SUV 20.77- Post Radiation F18-FDG-PET/CT scan at Charlotte Maxeke Johannesburg Academic Hospital.

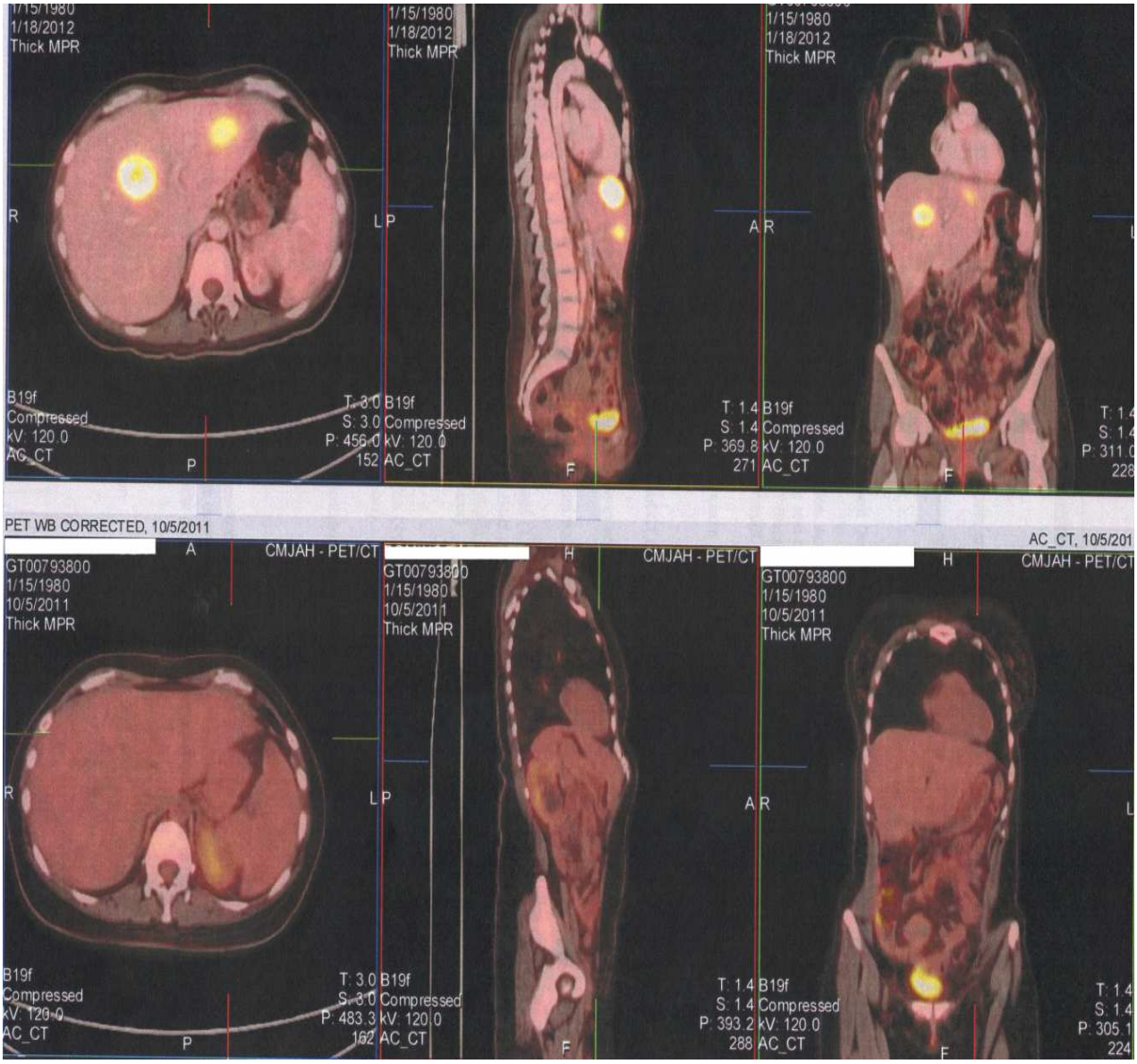

Figure 20a: Post Radiation Scan of a patient with multiple para-aortic lymph nodes and multiple bilateral pulmonary nodules. Lung nodules detected only on the post radiation scan.

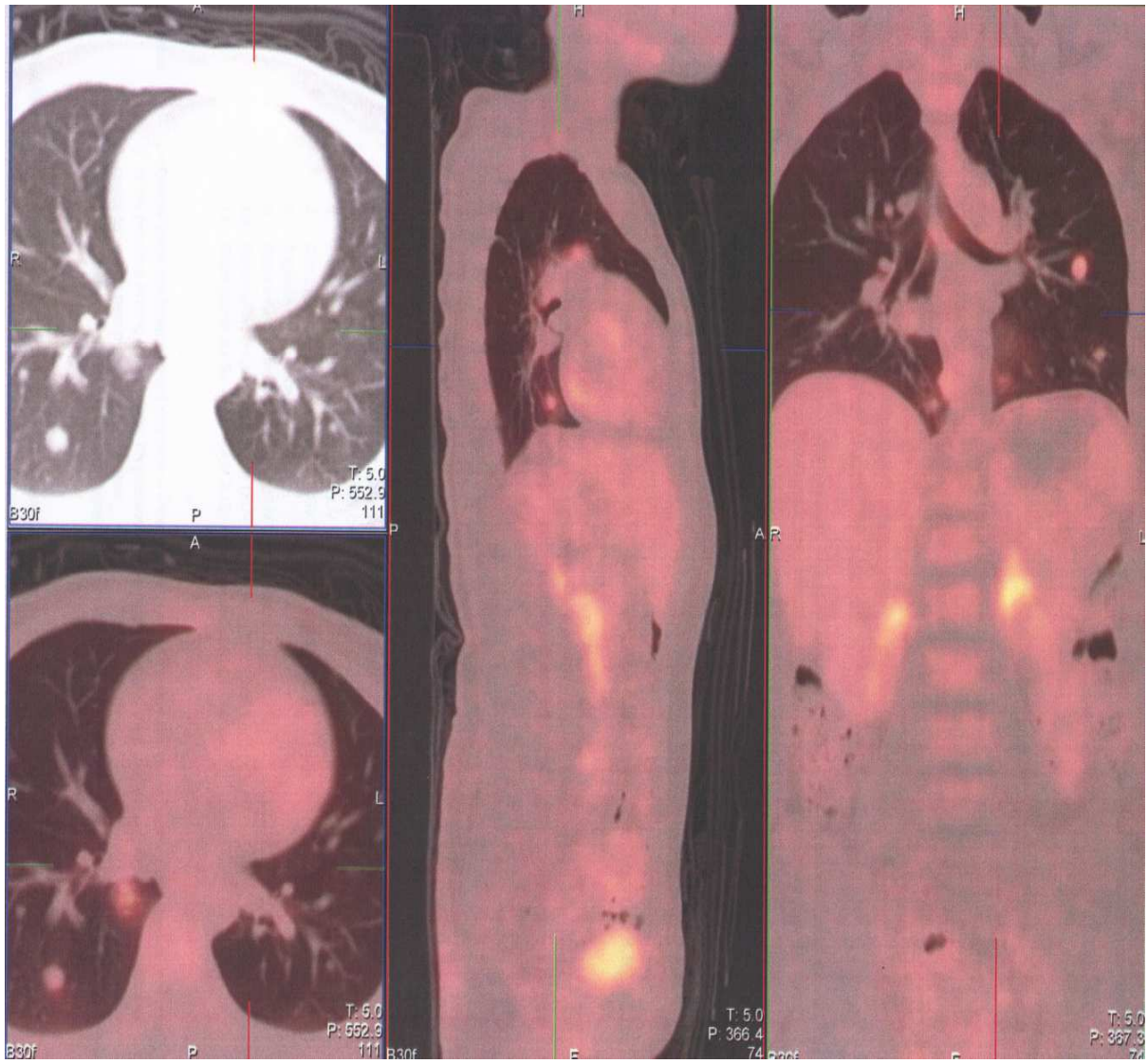

Figure 20b: Post Radiation Scan of the multiple para-aortic nodes. The post radiation scan showed progression of disease in the abdominal nodes as compared to the pre-treatment scan. The F-18-FDG-PET/CT was done at the Charlotte Maxeke Johannesburg Academic Hospital.

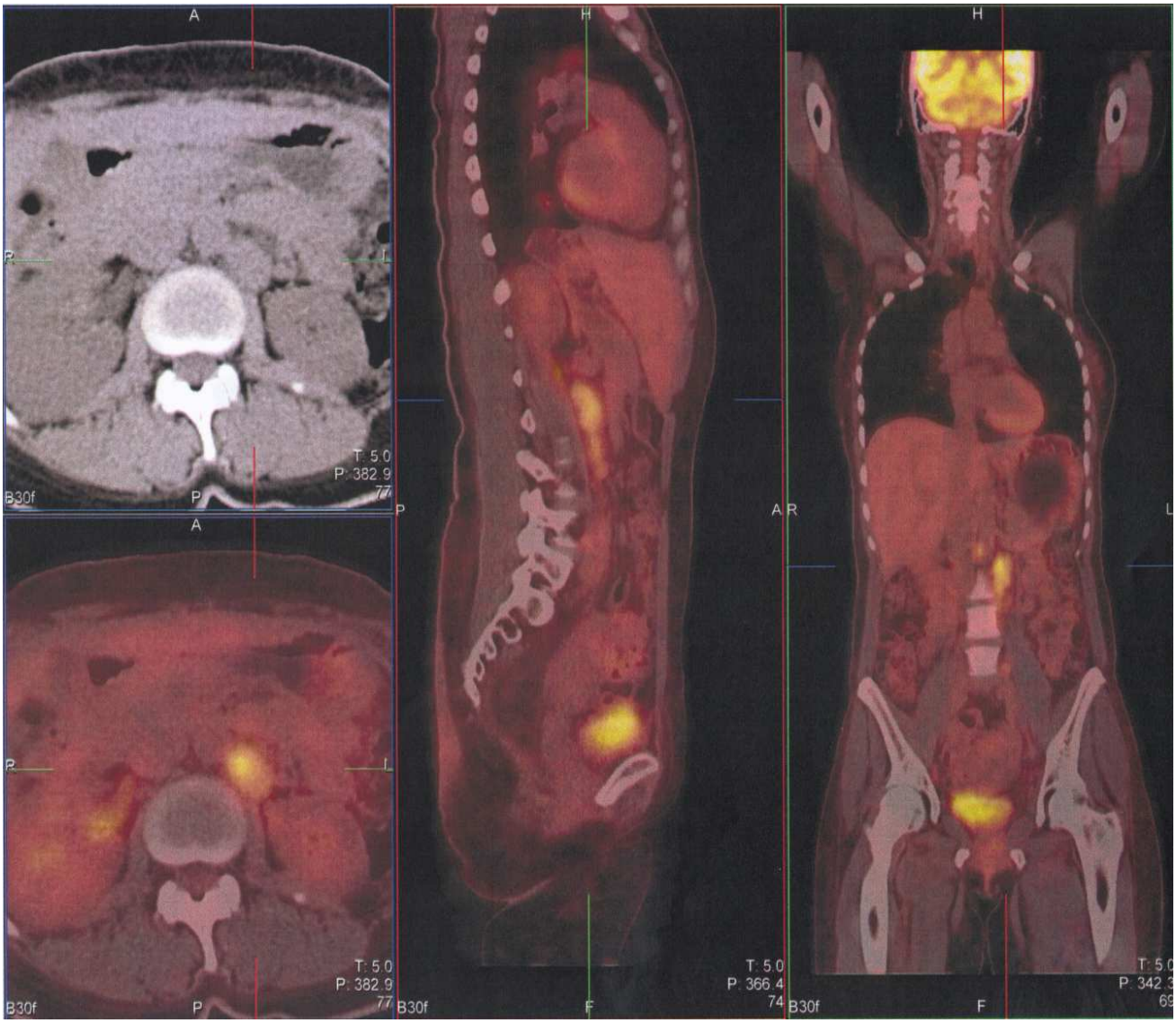

CHAPTER 4

DISCUSSION:

Internationally, the FIGO gynaecological staging system is used for the staging cervical cancer. The FIGO gynaecological staging does not take into account the pelvic lymph node status, nor does it take into account the para-aortic lymph node status. PET staging on the other hand uses the metabolic imaging modality and can access the uptake in the para-aortic and pelvic lymph nodes. As mentioned previously, PET has a high specificity and sensitivity than a diagnostic ultrasound, which is the current modality used by the FIGO staging method.

In our study the association between clinical staging and the PET stage showed Poor agreement. (SAS statistical method was used.) In essence this means that clinical staging did not agree with F18 FDG PET staging. Statistical value = 0,0984
95% confidence (0, 0157 – 0, 1812)

Clinical Stage Pre-Radiation

Stage	II a	Accounted for 2, 7% pts
	IIb	54, 05%
	IIIa	5, 4 %
	IIIb	35, 14%
	IV a	2, 7%

In contrast the **F18 – FDG PET** showed the following

Stage	IBi	8,33%
	IIa	8,33
	IIb	11,11
	III	5,55
	IVa	16,67%
	IVb	50%

By statistical combination and association there was **no association** between PET stage and clinical / FIGO staging.

4.1 METASTATIC DISEASE AND PARA-AORTIC LYMPH NODE IN PRE-TREATMENT SCAN:

47.22 % of patients on F18 FDG PET had para- aortic nodal uptake on PET scan, pretreatment. On the FIGO staging no para-aortic lymph nodes were diagnosed, once again showing the discrepancy of FIGO staging which is routinely used to stage cervical cancer before treatment.

Also 5.56% of patients had no distant metastatic disease. This shows that by extending our fields in 5.56% of patients, we can potentially cure patients if no distant is present, if the para-aortic nodes are biopsy positive.

Figure 21: CTV NODAL FOR PARA-AORTIC LYMPH NODES. [23]

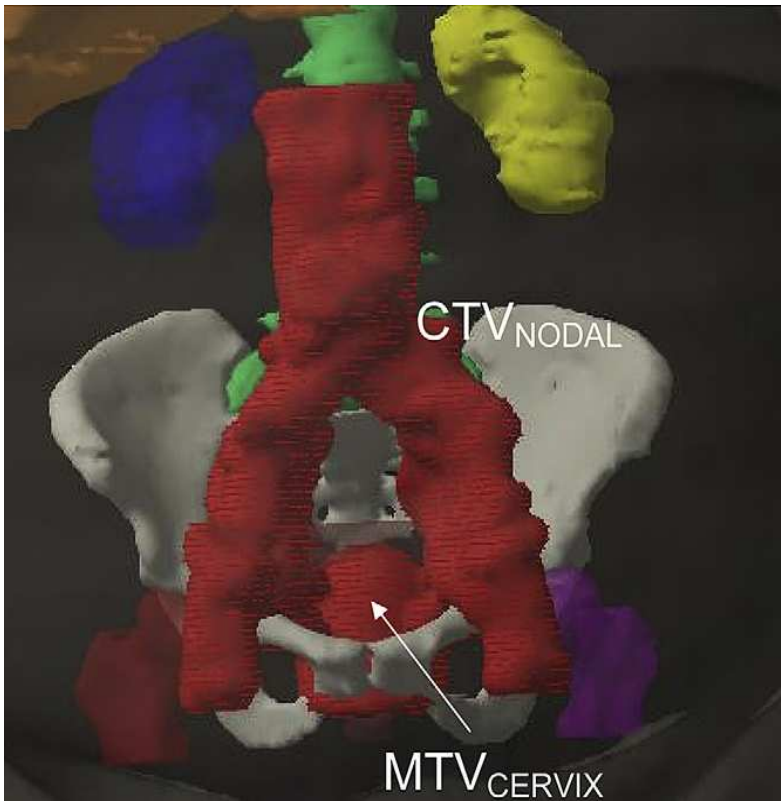

Figure reproduced with permission

Figure 22: Para- aortic lymph nodes on a patient: Pre treatment scan:



The average F18 FDG PET sensitivity and specificity across all applications are estimated at 84% -86% (based on 18 402 patients studies) and 88% - 93% based on 14 264 patient studies) respectively. (419 articles from 1993 – 2000). [3]

Accuracy of PET ranged from 87 – 90 %.

PET / CT is an effective tool for the diagnosis, staging and restaging of cancer patients.

4.2 STATUS OF PARA-AORTIC LYMPH NODE:

The status of para-aortic lymph node has been found to be the most important prognostic factor in invasive cervix cancer. [11]

FIGO staging has been shown, not to account for para-aortic lymph node. A prospective study in Denmark in 2007, investigated the utility PET/CT as a supplement to the normal FIGO staging. The study found that PET/CT had a sensitivity of 100% and a specificity of 99% for para-aortic nodal disease in all patients a sensitivity and specificity of 100% and 94% for distant metastases in all patients. [10]

According to Grigsby, Siegel and Dehdasti (JCO 2001). [3]

"Although not part of the staging system, the presence of pelvic and para-aortic lymph node metastases is an important finding, that does alter the method of therapy (i.e. Surgery, radiotherapy and chemotherapy) as well as the radiotherapy treatment plan (irradiated volume and dose).

In the study by Perry Grigsby, B A Siegel, Dehdasti, 7/101 patients were found to have para-aortic lymph node metastases on the basis of CT findings. An additional 14 patients had abnormal FDG uptake in para-aortic lymph node, therefore the irradiated volume could be modified on the basis of PET findings to include the para-aortic lymph node region in the 14% of patients studied. [3]

Stehman et al, analysed 626 patients enrolled onto Gynaecology Oncology Group clinical studies. [3] Patients underwent surgical para-aortic lymph node sampling. Patient's tumour's were staged I – IVa authors found the relative risk for progression of disease was 11,0 for para-aortic lymph nodes positive for disease and that positive para-aortic lymph nodes were " the most significant predictor of recurrence and death overwhelming all other risk factors."

STAGING AND PET IN CERVICAL CANCER

After its discovery in the mid 1970's PET became an important diagnostic modality in oncology in the early 90's and mid 1990's. The advent of PET/CT in the late 1990's further increased the visibility and acceptance of PET. [24]

Although the value of PET/CT over PET alone for treatment monitoring has yet to be determined, improvements in the staging and restaging accuracies of PET/CT over PET or CT alone for different cancers are now established. Restaging of cancers are statistically significant and average about 10 – 15%. These improvements have resulted in emergence of PET/CT as the most important cancer imaging modality. [24]

HIV +ve stage in cervical cancer;

Significantly stages II and stage IV showed an association between PET stage and HIV positive patients, in our study at Charlotte Maxeke Johannesburg Academic Hospital. Although HIV showed statistical significance between PET stage II and PET stage IV, CD4 did not show any association with the cervical cancer stage.

(Rank Sum analysis).

PARA-AORTIC LYMPH NODE POSITIVE ON PET-SCAN PRE-TREATMENT:

N.B in our study para-aortic lymph node positive (n=36)

22 patients (n = 36) patients had positive uptake on F18-FDG PET scan.

5 patients had an uptake < 2,52

17 patients had an uptake >2,52

Approximately 47% (17/36) had significant para-aortic lymph nodes. These were not detected on FIGO staging. In our country the effect of HIV/TB must be accounted for – the lymph nodes may be due to HIV/TB and false positives may occur.

Metastatic disease found on the pre-treatment PET scan.

Positive PET uptake for the following

1. Liver metastases 8,33%
2. Lung 36,56%
3. Bone 27,78%

On FIGO staging we did not find any liver metastases on sonar. There were no lung metastases commented on chest x-ray. Bone metastases are not usually investigated by the FIGO method, hence no bone metastases were found on the clinical staging.

Liver Metastases and Pre Treatment PET:

In addition 8, 3% of patients had liver metastases on pre treatment PET-CT which were not detected on FIGO stage.

Lung Metastases and Pre – Treatment PET:

Approximately 36, 5% patients had positive lung metastases not detected on pretreatment Chest X-ray.

SUV Cervix Association with Para-aortic Nodes (Pre Treatment)

In this study there was statistical significance for a mean SUV Cervix of 18,35 for association with positive para-aortic lymph node uptake. This means that a higher SUV in cervical cancer needs close follow up because of higher metastatic potential for para-aortic lymph nodes.

SUMMARY:

Finally, our study showed the following:-

- There is no association between the FIGO staging used internationally, with the findings on a pre-treatment PET scan.
- A large number of patients were upstaged by PET scan. Metastatic para-aortic lymph node were not detected by FIGO staging. [47% patients on pre –treatment PET scan.]
- More distant metastatic disease was detected on F18 FDG PET/CT scanning as compared to routine clinical staging methods used by FIGO.

  33% liver mets
  36% lung mets
  27% bone mets

- An extended para-aortic treatment field for radiation can be utilised for biopsy proven para-aortic lymph nodes, to potentially cure patients who have positive nodes on a pre-treatment scan. (5 – 6% in our study can potentially be salvaged from an extended field of Radiation.)
- For post therapy scans and para-aortic lymph nodes – some patients can be potentially salvaged with para-aortic radiation –approximately 10 % of patients can benefit with a post treatment FDG-PET scan. Biopsy should be obtained to confirm metastatic cancer.

Grigsby et al have shown that a three month post treatment FDG - PET was the most significant predictive factor of PFS.[15]

Of equal importance is that a post treatment PET scan gives information that impact on an approach to salvage treatment. Early detection of a recurrence has the potential of improving the outcome of salvage treatment.

2nd rationale: [25]

A post treatment scan provides long term prognostic information as early as 3 months after completing treatment: for a complete response – patients will require no additional treatment.

For partial responders - patients may be enrolled on a clinical trial. New metabolic sites within 3 months of completing treatment may be enrolled onto new strategies for refractory disease.

A post treatment scan is also a robust predictor of outcome, in the long term treatment of cervical cancer.

USE OF PET FOR RADIOTHERAPY PLANNING IN CERVICAL CANCER:

Over the years the improved outcome of treating cervical cancer, with concurrent chemoradiation, came at a cost of increased gastrointestinal, haematological and genitourinary side effects.[26]

Implementation of PET guided IMRT to improve therapy to pelvic and para-aortic lymph nodes, is set to improve treatment- related toxicity.

Kidd et al have shown a lower incidence of grade 3 gastrointestinal and genitourinary toxicity in patients treated with PET guided IMRT versus conventional radiation.

Figure 23: IMRT FOR CERVICAL CANCER . [27]

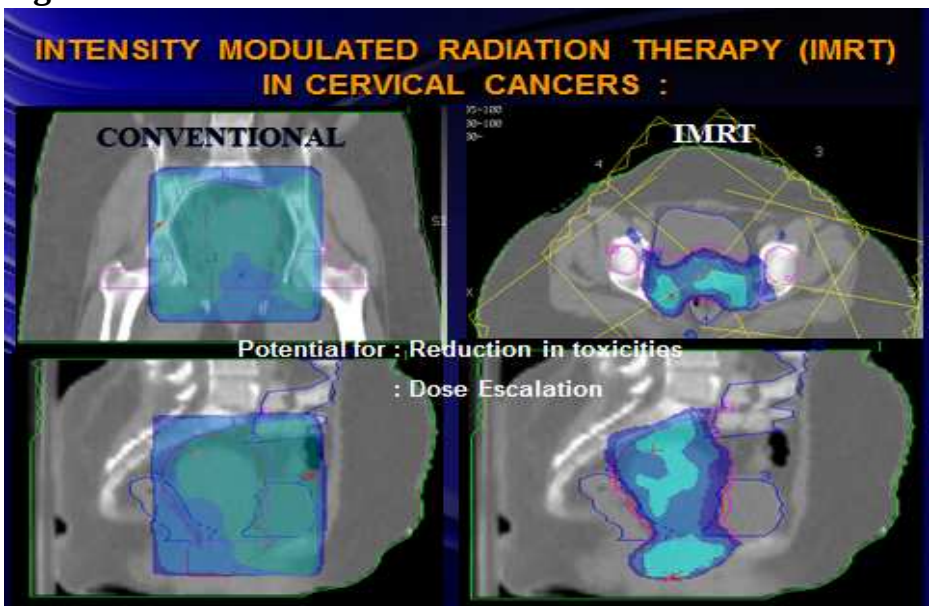

PET and Brachytherapy:

2 studies have demonstrated the role of PET in Brachytherapy optimization. [26]

Brachytherapy was delivered using traditional 2 D orthogonal planning. [26]

PET based optimization was conducted for the sole purpose of comparison. The studies by Lin et al demonstrated that PET based brachytherapy optimization has the potential of achieving improved tumour coverage over conventional techniques. [28]

Bladder and bowel radiation doses will be decreased if this type of "adaptive" brachytherapy is utilized. [26]

To quote Lin et al, "PET – CT based brachytherapy is feasible. It could provide 3D metabolic and dosimetric information about the tumour and critical structures. In future PET/CT guided brachytherapy may form the basis of new trials." [28]

PRE TREATMENT PET:

Pretreatment PET/ PET CT would likely impact in planning patients with a high risk of harbouring para-aortic lymph node metastases, as in our developing country. The high risk of enlarged pelvic and para-aortic lymph nodes, together with advanced clinical stage makes this an important imaging modality to determine the type of radiation to offer our patients. In the future PET/CT may integrate advanced techniques of dose painting, utilizing complex IMRT plans, guided by PET/CT imaging.

CHAPTER 5 CONCLUSION:

5.1 RECOMMENDATION FOR A PRE-TREATMENT F18-FDG-PET SCAN:

F18 FDG-PET scan may be used as an Imaging modality, in addition to the routine FIGO staging investigation; especially for locally advanced cervical disease.

A pre – treatment PET/CT provides important information regarding metastatic disease. Moreover, routine investigations do not provide important information e.g. Para- aortic lymph node status. Para-aortic disease will not be treated by conventional pelvic fields. As has been shown by our study that there is no Stage Association between FIGO Stage and FDG-PET findings –we are missing patients who have para-aortic disease and who could benefit with an extended para-aortic field.
[In our study 47% had para-aortic lymph nodes on FDG-PET scan.] 5-6% of these patients can be salvaged if they have an extended field of para-aortic radiation.
A Pre-Treatment scan will give us important information e.g. SUV which will prognosticate good vz bad prognostic features on a patient.
Initial failure of correct treatment is associated with a poor salvage rate. It also decreases long term survival in advanced cancer of the cervix. Therapy must therefore be effective.

Detection of very advanced disease, on PET/CT correlates with a poor prognoses – hence our treatment can be tailored to a less radical approach, palliation for Stage IVB disease if patients have multiple metastases e.g. liver, lung, and bone metastases. Patients upstaged on a pre-treatment F-18 FDG-PET scan, with extensive metastases may be offered given a hypofractionated course of radiation.
Our impression is that F-18 FDG-PET/CT scan, be done for staging of selected locally advanced high risk patients, because it will alter the treatment modality offered to patients if PET findings indicated PET positive lymph nodes and these are biopsy proven as cancer.

F-18 FDG-PET/CT studies should be done if the resources are adequate in a state setting. In the United States of America it is a recommended investigation by the F.D.A.

In Sub-Saharan Africa all positive lymph nodes or metastases seen on F-18 FDG-PET should be first be confirmed with a biopsy.

5.2 **RECOMMENDATIONS FOR A POST -TREATMENT FDG-PET SCAN:**

F-18 FDG-PET will detect persistent or recurrent disease as early as 3 months after definitive radiation treatment. A post treatment PET will provide information for patients who may be salvaged after radiation.

- Previously gross disease found on clinical examination, after radiation was associated with high mortality if a total pelvic exenteration was done.
- Early detection in our patients with a post treatment PET scan, may mean we can salvage patients from disease progression as well as death.
- Patients with complete metabolic response will require no further treatment.
- Patients with localised disease and recurrence may be referred earlier for surgical evaluation.
- Patients who did not have an extended radiation field may be salvaged if para-aortic lymph nodes are found on a post treatment FDG-PET.
- In our hospital 10% of patients can be salvaged with a post-treatment scan if extended field radiation is given to them.
- New metabolic sites can be enrolled onto trials in the department, e.g. patients with supraclavicular lymph node involvement, as an indication for more aggressive systemic therapies.

Brachytherapy in our Centre:

The FDG-PET defined tumour volume may be used in our centre in future – so that Brachytherapy insertions conform better to the tumour/cervical disease.

PET/PET-CT based brachytherapy optimisation can be utilised to improve dose distributions. Our patients have locally advanced disease and PET – based Brachytherapy insertions could improve local disease control to the cervix and parametrial disease. In addition, we may be able to decrease dose to the bladder and rectum if FDG-PET based brachytherapy is utilised.

Figure 24: Brachytherapy tumour Optimisation for PET-defined volume . [28]

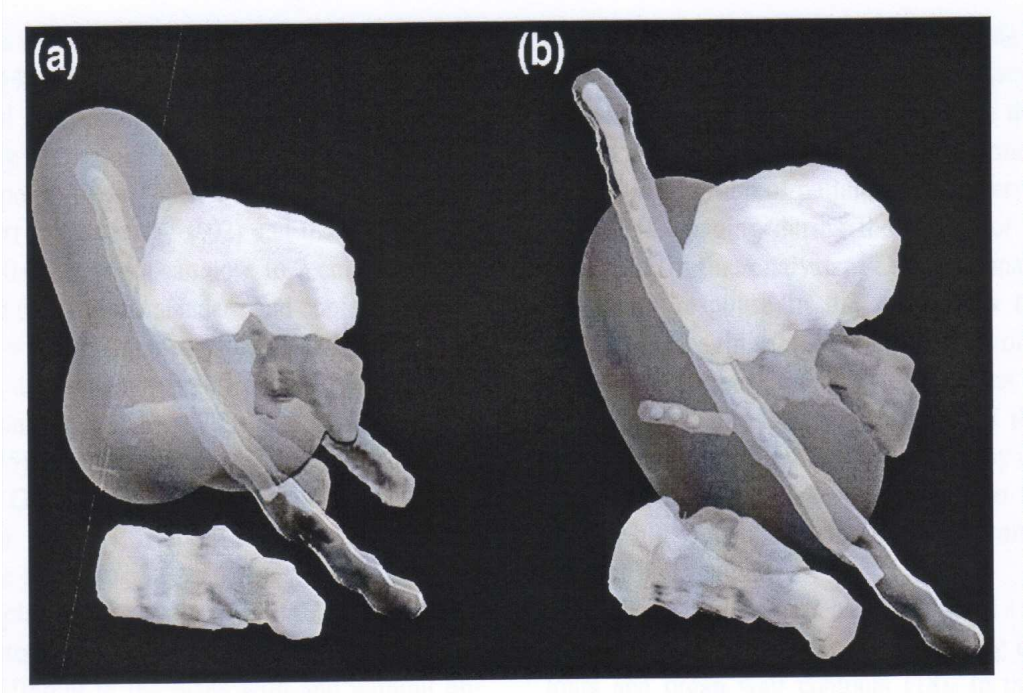

Figure reproduced with permission

Figure 25: Brachytherapy tumour Optimisation for PET-defined volume, with (a) optimisation and (b) with out Optimisation . [28]

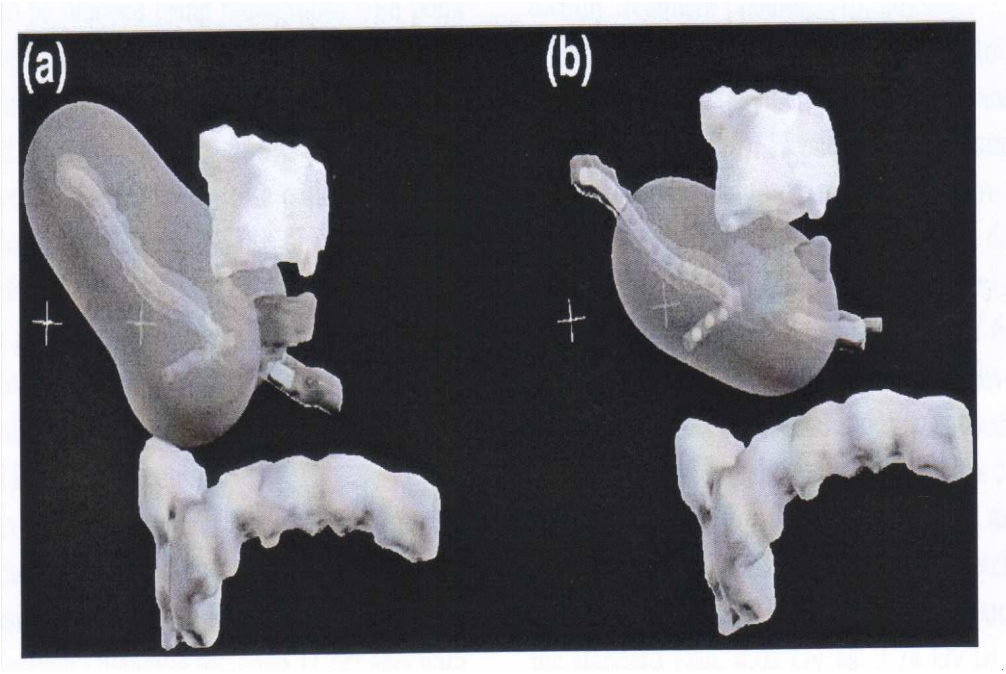

Figure reproduced with permission

5.3 RECOMMENDATIONS FOR IMRT IN OUR CENTRE IN FUTURE:

Should FDG-PET detect large pathologically positive nodal disease, then FDG-PET integrated IMRT (Intensity Modulated Radiation Therapy) may be utilised in our centre, in the future if resources permit. This technique may allow higher doses of radiation to be given to the cancer as well as to the lymph nodes. Gastrointestinal and genitourinary side effects may be decreased if PET/CT guided IMRT is utilised in future.

The potential for use of PET and radiotherapy treatment planning and IMRT in our hospital is feasible. Cervical cancer patients may have improved survival due to less treatment related toxicity.

Figure 26: IMRT FOR CERVICAL CANCER . [27]

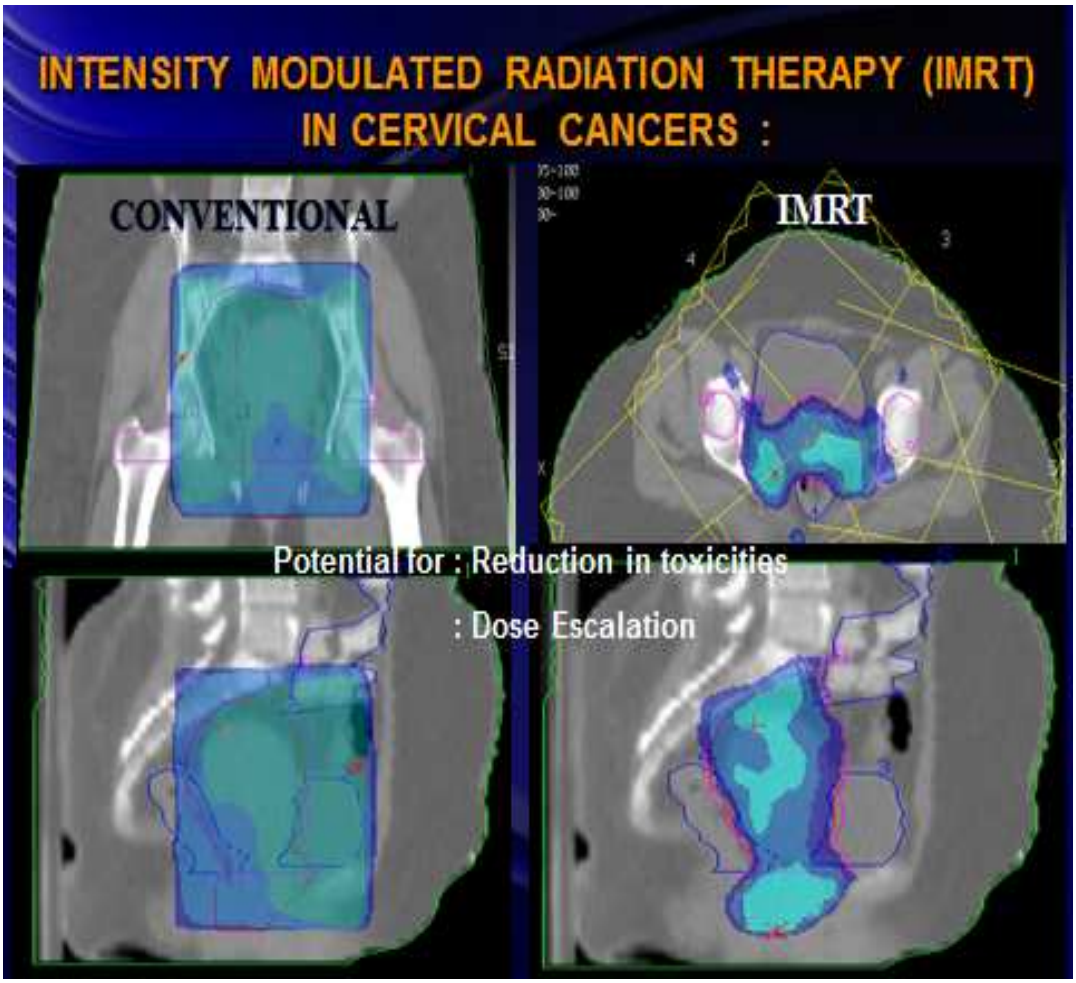

REFERENCES :

1. Kumar R, Dadparvar S. F-18-Fluoro-2-deoxy-D-glucose-PET/PET-CT in Carcinoma of the cervix. Cancer. 2007 Oct; Vol 110 (8): 1650-1653.

2. FIGO Committee on Gynecologic Oncology. Benedict J.L, Bender H, Jones III, Ngan H.Y.S, Pecorelli. Staging classifications and clinical practice guidelines of gynaecologic cancers. International Journal of Gynecology and Obstetrics 2000; (70): 207-312

3. Grigsby P.W, Siegel B, Dehdasti F. Lymph Node Staging by PET in patients with Carcinoma of Cervix. Journal of Clinical Oncology 2001; 19, suppl 17 : 3745 – 3749.

4. Hafty B.G, Wilson L.D. Handbook of Radiation Oncology. In Choi S, Eifel P. J. Cervical Cancer. Jones and Bartlett Publishers, 2009 (29): 583 – 603.

5. Harry Vanessa. Novel imaging Techniques as response biomarkers in cervical cancer. Gynaecologic Oncology 2010; (116): 253-261.

6. Sellors J.W. and Sankaranarayanan R. Colposcopy and Treatment of Cervical Intraepithelial Neoplasia. A Beginner's manual. Lyon, France, IARC Press, 2003, http://screening.iarc.fr/doc/colposcopymanual.pdf

7. Jover R, Lourido D, Gonzalez C, Rojo A et al. Role of PET/CT in the evaluation of cervical cancer. Gynaecologic Oncology. 2008 Sept; 110 iss 3 (suppl 2): S55-S59.

8. Grigsby P.W. The Contribution of new imaging techniques in staging cervical cancer. Gynaecologic Oncology 2007 July; 107: S 10 –S12.

9. Taskar N.P. Oncologic Imaging in Gynaecologic Malignancies. The Journal of Nuclear Medicine. 2005 Nov; Vol 46 (11): 1842 – 1850.

10. Loft A, Berthelsen A.K, Roed H, Ottosen C, Lundvall L, Knudson J, Nedergaard L, Hojgaard L et al. The diagnostic value of PET/CT Scanning in patients with cervical cancer: Gynaecologic Oncology 2007; 106: 29-34.

11. Kidd E. A, Siegel B, Dehdasti F, Grigsby P. The standard uptake value for F – 18 fluorodeoxyglucose is a sensitive predictive biomarker for cervical cancer treatment response and survival. Cancer 2007; 110 (8): 1738 – 1744.

12. Grigsby P. The Role of FDG-PET /CT Imaging after Radiation therapy. Gynaecologic Oncology. 2007 (107) : S27- S29.

13. Spiesssl B, Beahrs O.H, Hermanek P et al. UICC TNM Atlas. Illustrated Guide to the TNM /pTNM Classification of Malignant Tumours. New York: Springer, 1992: 211 – 212.

14. McMahon C. J, Rofsky N. M, Pedrosa I. Lymphatic Metastases from Pelvic Tumours: Anatomic Classification, Characterisation and Staging. Radiology: 2010 Jan; Vol 254 (1): 31-34.

15. Grigsby P.W, Siegel B, Dehdasti F, Rade J, Zoberi I. Post therapy F-18 FluorodeoxyGlucose PET in Carcinoma of the Cervix: Response and outcome. Journal of Clin Oncology. 2004 June; Vol 2 (11): 2167 – 2171.

16. Schwarz J, Siegel B, Dehdasti F, Grigsby P. Association of post therapy PET with tumour response and survival in cervical carcinoma. JAMA 2007 Nov; 298(19): 2289 – 2295

17. Liu Yiyan. Demonstrations of AIDS-associated malignancies and infections at FDG PET-CT. Ann Nucl Med 2011 May; 25: 536-546.

18. Basu S, Chryssikos T, Moghadam-Kia Siamak et al. Positron Emission Tomography as a Diagnostic Tool in Infection: Present Role and Future Possibilities. Seminars in Nuclear Medicine. 2009; 39: 36-51.

19. Moodley M, Mould S. Invasive cervical cancer and human immunodeficiency virus (HIV) infection in KwaZulu-Natal, South Africa. Journal of Obstetrics and Gynaecology 2005 Oct; 25 (7): 706-710.

20. O'Doherty M.J, Barrington S.F, Klein J.L. Oppurtunistic Infection and Nuclear Medicine. Seminars in Nuclear Medicine. 2009; 39: 88-102.

21. Sathekge M, Maes A, AL Nahhas A, et al. What impact can fluorine-18 fluorodeoxyglucose PET/CT tomography have on HIV/AIDS and tuberculosis pandemic? Nuclear Medicine Communications. 2009; 30: 255 -257.

22. Glaudemans A.W. J. M. Signore A. FDG-PET/CT in infections: the imaging method of choice? Euro J Nucl Med Mol Imaging. 2010; 37:1986-1991.

23. Kidd Elizabeth, Siegel Barry, Dehdasti Farrokh et al. Clinical Outcomes of definitive IMRT with FDG-PET simulation in patients with locally advanced cervical cancer. IJROBP. 2010; Vol 77 (4): 1085-1091.

24. Czernin J, Auerbach M.A, Schubert Heinrich R. Improvements in cancer staging with PET/CT: Literature –Based Evidence as of Sept 2006.The Journal of Nuclear Medicine. 2007 Jan; Vol 48(1): 78S – 88S.

25. Fletcher J.W, Djulbegovic B, Soares P. H, Siegel B et al. Recommendations on the use of 18 FDG-PET in Oncology. The Journal of Nuclear Medicine, March 2008; Vol 4 (3): 480 – 508.

26. Salem A, Salem Abdel - Fattah, Al-Ibraheem A et al. Evidence for the use of PET for radiation therapy planning in patients with cervical cancer: a systematic review. Hematol Oncol Stem Cell Ther 2011; 4(4): 173-181.

27. Tata Memorial Working Group. Improving Therapeutic ratio in Cervical Cancer. ESTRO International Symposium. ESTRO/TMH 2005.

28. Lin L, Mutic S, Miller T, Grigsby P. Adaptive Brachytherapy treatment planning for cervical cancer using FDG-PET. International Journal of Radiation Oncology Biol Phys. 2006. Vol 67 (1): 91 – 96.

29. American Joint Committee on Cancer. AJCC Cancer Staging Manual. Edge S, Byrd D, Compton C Cet al. Springer, 2010: 395 – 398.

30. Ferlay J, Shin HR, Bray F, Forman D, Mather's C and Parkin DM. Globocan 2008, Cancer and Incidence and Mortality Worldwide: IARC CancerBase No 10[Internet]. Lyon, France: International Agency for Research on Cancer; 2010

31. Chung Hyun H, Hoenil J, Kang Won J. et al. Clinical impact of integrated PET/CT on the management of suspected cervical cancer recurrence. Gynaecologic Oncology 2007; 104: 529-534.

32. Miller Tom R, Grigsby Perry W. Measurement of Tumor volume by PET to evaluate prognosis in patients with advanced cervical cancer treated by radiation therapy. Int J. Radiation Oncology Biol Physics. 2002; Vol. 53 No (2): 353 – 359.

33. Amitt Amnon, Beck D, Lowenstein L, Lavie O, Shalom Rachel B, Zohar Kedar, Ora Israel. The Role of HYBRID PET/CT in the evaluation of patients with Cervical cancer. Department of O and G, Rambam Medical Center, Carmel Medical Center, Haifa, Israel. Department of Nuclear Radiology, Rambam Medical Centre, Haifa, Israel. Available online 2 November 2005.

34. Selman Tara J, Mann Christopher, Zamora Javier, Appleyard Tracy Louise, Khan Khalid. Diagnostic Accuracy of tests for Lymph Node Status in primary Cervical cancer: A systemic review and meta-analyses. Canadian Medical Assoc Journal. 2008 March; 178 (7): 855 – 862

35. Bernd J Pichler, Hans F Wehrl, Martin S Judenhofer. Latest Advances in Molecular Imaging Instrumentation. Journal of Nuclear Medicine. 2008; 49: 5S – 23S.

36. Segal George M.A New paradigm to increase utilization of PET/CT. The Journal of Nuclear Medicine 2008 June; 49 (6): 53N – 56N.

37. Hilmar Kuehl,Patrick Veit, Sandra J Rosenbaum,Andreas Bockisch, Gerald Antoch. Can PET/CT replace separate diagnostic CT protocols for Cancer Imaging? Journal of Nuclear Medicine. Jan 2007; 48 (1): 45S – 57S.

38. Fletcher et al. Use of F18 – FDG PET in Oncology. Journal of Nuclear Medicine. 2008 March; Vol 49 (3):497 – 508.

39. Rose Peter G, Lee P. Adler, Rodrigues Michael, Faulhaber Peter, Karim Fadi W Abdul et al. Journal of Clinical Oncology. 1999 Jan; Vol 17 (1): 41 – 45.

40. Vincent Gregoire, Karin Haustermans, Xavier Geets, Sarah Roels Max Lonneux. PET based treatment planning in radiotherapy: A new Standard The Journal of Nuclear Medicine. 2007 Jan; Vol 48 (1): 68S – 77S.

41. Grigsby PW, Siegel BA, Dehdasti F.FDG-PET evaluation of carcinoma of the cervix. Clinical Positron Imaging.1999; 2 (2): S10-S12.

42. Heller PB, Malfetano JH et al.Clinical-pathologic study of Stage II B, III B and IVA carcinoma of the cervix: extended diagnostic evaluation for para-aortic mets. A GOG study. Gynaecologic Oncology.1990; (38): 425-430.

43. Belhocine Tarik, Thille Alain, Fridman Viviana, Albert Adelin et al. Contribution of Whole-Body F-18 FDG PET Imaging in the Management of Cervical Cancer. Gynaecologic Oncology. 2002; (87): 90-97.

44. Ichiya Y, Kuwabara Y, et al. FDG-PET in infectious lesions: The detection and assessment of lesion activity. Annals of Nuclear Medicine. 1996; Vol 10 (2): 185-191.

45. O'Doherty M.J, Barrington S.F, Campbell M, Lowe J, Bradbeer C.S.PET Scanning and Human Immunodeficiency Virus-Positive Patient. Journal of Nuclear Medicine. 1997; 38: 1575-1583.

46. Lucignani G, Orunesu E, Cesari M, Marzo K, et al. PFG-PET imaging in HIV-infected subjects: relation with therapy and immunovirological variables. Euro J Nucl Med Mol Imaging. 2009; 36: 640-647.

47. Davison J, Subramaniam R. M. Surasi D, Cooley T, Mercier G, Peller P. J. FDG-PET/CT in Patients with HIV. AJR. 2011 Aug; 197: 284-294.

Annexure 1: FIGO STAGING.[2]

Appendix 1 FIGO Staging

Stage	Characteristics
0	Carcinoma in situ, intraepithelial carcinoma; cases of stage 0 should not be included in any therapeutic statistics for invasive carcinoma
I	The carcinoma is strictly confined to the cervix (extension to the corpus should be disregarded)
IA	Invasive cancer identified only microscopically. All gross lesions, even with superficial invasion, are stage IB cancers. Invasion is limited to measured stromal invasion with a maximum depth of 5 mm taken from the base of the epithelium, either surface or glandular, from which it originates. Vascular space involvement, either venous or lymphatic, should not alter the staging)
IA1	Measured invasion of stroma no greater than 3 mm in depth and no wider than 7 mm
IA2	Measured invasion of stroma > 3 mm and no greater than 5 mm in depth and no wider than 7 mm
IB	Clinical lesions confined to the cervix or preclinical lesions > IA
IB1	Clinical lesions no greater than 4 cm in size
IB2	Clinical lesions > 4 cm in size
II	The carcinoma extends beyond the cervix, but has not extended onto the pelvic wall; the carcinoma involves the vagina, but not as far as the lower third
IIA	No obvious parametrial involvement
IIB	With parametrial involvement
III	The carcinoma has extended onto the pelvic wall; on rectal examination there is no cancer-free space between the tumour and the pelvic wall; the tumour involves the lower third of the vagina; all cases with a hydronephrosis or nonfunctioning kidney should be included, unless they are known to be due to other causes
IIIA	No extension onto the pelvic wall, but involvement of the lower third of the vagina
IIIB	Extension onto the pelvic wall or hydronephrosis or nonfunctioning kidney
IV	The carcinoma has extended beyond the true pelvis or has clinically involved the mucosa of the bladder or rectum
IVA	Spread of the growth to adjacent organs
IVB	Spread to distant organs

(1) FIGO staging is based on clinical data (clinical examination and colposcopy), chest x-rays, IVP, biopsy and D&C.
(2) Cystocopy and sigmoidoscopy may be used for clinical stage (bladder and/or rectal mucosal biopsy).
(3) Lymphangiogram, CT, MRI, laparotomy, laparoscopy cannot be used for clinical staging.
(4) Pathological IVP defines a cancer as stage IIIB.
(5) Paracervical, parametrial, hipogastric, obturator, internal, external and common iliac, presacral and sacral are the regional nodes.

ANNEXURE 2: ETHICS APPROVAL CERTIFICATE

UNIVERSITY OF THE WITWATERSRAND, JOHANNESBURG
Division of the Deputy Registrar (Research)

HUMAN RESEARCH ETHICS COMMITTEE (MEDICAL)
R14/49 Dr Faiza Mahomed

CLEARANCE CERTIFICATE	**M10319**
PROJECT	The Value of F-18 FDG-PET Scan in Invasive Cervical Cancer
INVESTIGATORS	Dr Faiza Mahomed .
DEPARTMENT	Department of Radiation Oncology
DATE CONSIDERED	26/03/2010
DECISION OF THE COMMITTEE*	Approved unconditionally

Unless otherwise specified this ethical clearance is valid for 5 years and may be renewed upon application.

DATE 24/05/2010 **CHAIRPERSON** .....
(Professor PE Cleaton-Jones)

*Guidelines for written 'informed consent' attached where applicable
cc: Supervisor : Prof MDT Vangu

DECLARATION OF INVESTIGATOR(S)

To be completed in duplicate and **ONE COPY** returned to the Secretary at Room 10004, 10th Floor, Senate House, University.
I/We fully understand the conditions under which I am/we are authorized to carry out the abovementioned research and I/we guarantee to ensure compliance with these conditions. Should any departure to be contemplated from the research procedure as approved I/we undertake to resubmit the protocol to the Committee. **I agree to a completion of a yearly progress report.**

PLEASE QUOTE THE PROTOCOL NUMBER IN ALL ENQUIRIES...

Annexure 3: Preparation for PET/CT Scan

JOHANNESBURG HOSPITAL
Nuclear Medicine and Molecular Imaging
Area 559
Private Bag X 39
Johannesburg 2000

Phone: 011-488-3590/3560/3559/3500
Fax: 011-488-3501

PREPARATION FOR PET/CT SCAN

You are booked for a PET/CT scan at our department. There are a few preparation steps that are required. Please adhere to these as closely as possible.

1. Drink at least 1500ml (1.5l) of water on the day before the scan
2. Drink at least 700ml of water on the day of the scan, and continue after the scan
3. Empty your bladder often
4. Avoid strenuous exercise on the day of the study, this includes arriving at the department early so as to rest prior to the injection of the radioactivity
5. Do not smoke on the day of the study
6. Do not consume alcohol on the day of the study
7. Your last meal should be the night before the study, however, bring along a sandwich with you to your appointment
8. Your usual medication may be taken with water on the morning of the study
9. If you are claustrophobic or extremely anxious, please inform the radiographer/nurse in the department
10. If you are diabetic please inform the radiographer/nurse in the department so that special arrangements can be made
11. Depending on the area of interest, you may be given a diuretic which helps to empty the kidneys/bladder and/or a urinary catheter may be inserted to ensure emptying of the bladder

Should have require any of the above points clarified, please do not hesitate to contact the department at one of the above numbers.

Annexure 4: GLOBOCAN 2008.

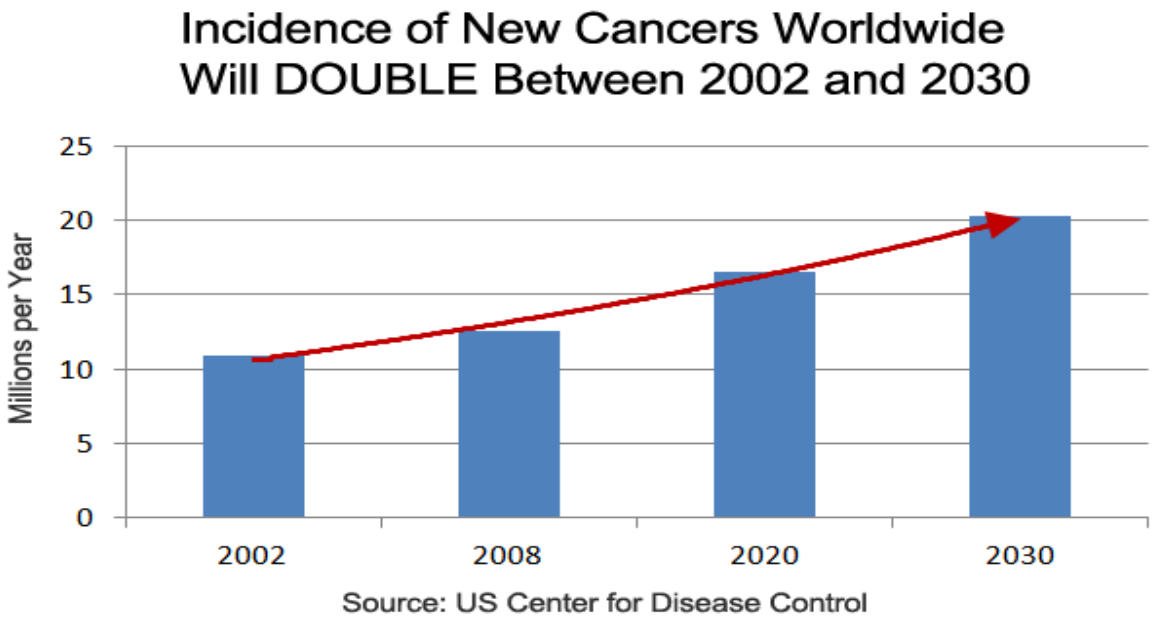

Annexure 5: Comparison of AJCC and FIGO Staging for Cervical Cancer[29]

Primary Tumor (T)

TNM Categories	*FIGO Stages*	
TX		Primary tumor cannot be assessed
T0		No evidence of primary tumor
Tis*		Carcinoma in situ (preinvasive carcinoma)
T1	I	Cervical carcinoma confined to uterus (extension to corpus should be disregarded)
T1a**	IA	Invasive carcinoma diagnosed only by microscopy. Stromal invasion with a maximum depth of 5.0 mm measured from the base of the epithelium and a horizontal spread of 7.0 mm or less. Vascular space involvement, venous or lymphatic, does not affect classification
T1a1	IA1	Measured stromal invasion 3.0 mm or less in depth and 7.0 mm or less in horizontal spread
T1a2	IA2	Measured stromal invasion more than 3.0 mm and not more than 5.0 mm with a horizontal spread 7.0 mm or less
T1b	IB	Clinically visible lesion confined to the cervix or microscopic lesion greater than T1a/IA2
T1b1	IB1	Clinically visible lesion 4.0 cm or less in greatest dimension
T1b2	IB2	Clinically visible lesion more than 4.0 cm in greatest dimension
T2	II	Cervical carcinoma invades beyond uterus but not to pelvic wall or to lower third of vagina
T2a	IIA	Tumor without parametrial invasion
T2a1	IIA1	Clinically visible lesion 4.0 cm or less in greatest dimension
T2a2	IIA2	Clinically visible lesion more than 4.0 cm in greatest dimension
T2b	IIB	Tumor with parametrial invasion
T3	III	Tumor extends to pelvic wall and/or involves lower third of vagina, and/or causes hydronephrosis or nonfunctioning kidney
T3a	IIIA	Tumor involves lower third of vagina, no extension to pelvic wall
T3b	IIIB	Tumor extends to pelvic wall and/or causes hydronephrosis or nonfunctioning kidney
T4	IVA	Tumor invades mucosa of bladder or rectum, and/or extends beyond true pelvis (bullous edema is not sufficient to classify a tumor as T4)

**Note*: FIGO no longer includes Stage 0 (Tis).

***Note*: All macroscopically visible lesions – even with superficial invasion – are T1b/IB.

Regional Lymph Nodes (N)

TNM Categories	*FIGO Stages*	
NX		Regional lymph nodes cannot be assessed
N0		No regional lymph node metastasis
N1	IIIB	Regional lymph node metastasis

Distant Metastasis (M)

TNM Categories	*FIGO Stages*	
M0		No distant metastasis
M1	IVB	Distant metastasis (including peritoneal spread, involvement of supraclavicular, mediastinal, or paraaortic lymph nodes, lung, liver, or bone)

ANATOMIC STAGE/PROGNOSTIC GROUPS (FIGO 2008)

Stage 0*	Tis	N0	M0
Stage I	T1	N0	M0
Stage IA	T1a	N0	M0
Stage IA1	T1a1	N0	M0
Stage IA2	T1a2	N0	M0
Stage IB	T1b	N0	M0
Stage IB1	T1b1	N0	M0
Stage IB2	T1b2	N0	M0
Stage II	T2	N0	M0
Stage IIA	T2a	N0	M0
Stage IIA1	T2a1	N0	M0
Stage IIA2	T2a2	N0	M0
Stage IIB	T2b	N0	M0
Stage III	T3	N0	M0
Stage IIIA	T3a	N0	M0
Stage IIIB	T3b	Any N	M0
	T1-3	N1	M0
Stage IVA	T4	Any N	M0
Stage IVB	Any T	Any N	M1

**Note*: FIGO no longer includes Stage 0 (Tis).

Annexure 6: GLOBOCAN 2008. World wide incidence and mortality for cervical cancer [30]

Estimated numbers (thousands)	Cases	Deaths
World	530	275
More developed regions	76	32
Less developed regions	453	242
WHO Africa region (AFRO)	75	50
WHO Americas region (PAHO)	80	36
WHO East Mediterranean region (EMRO)	18	11
WHO Europe region (EURO)	61	28
WHO South-East Asia region (SEARO)	188	102
WHO Western Pacific region (WPRO)	105	46
IARC membership (22 countries)	193	96
United States of America	11	3
China	75	33
India	134	72
European Union (EU-27)	31	13

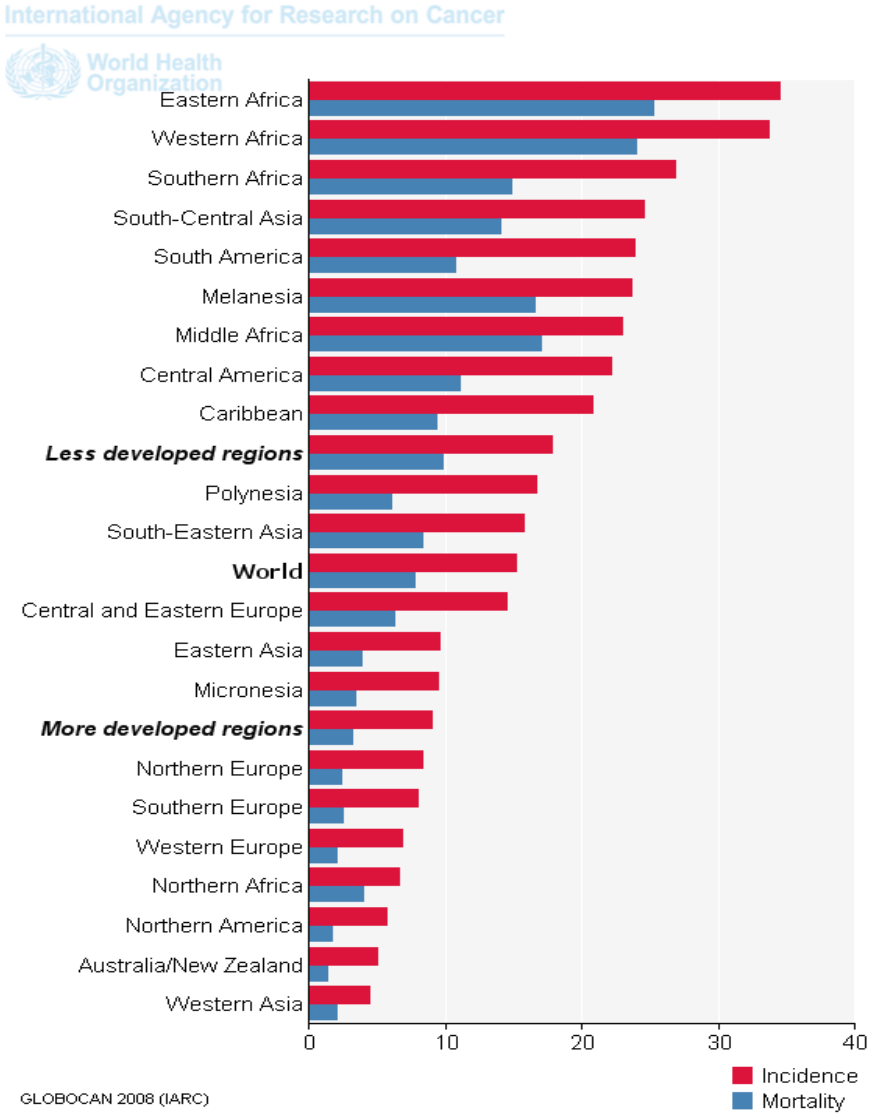

Figure reproduced with permission

Annexure 7: Globocan 2008. [30]

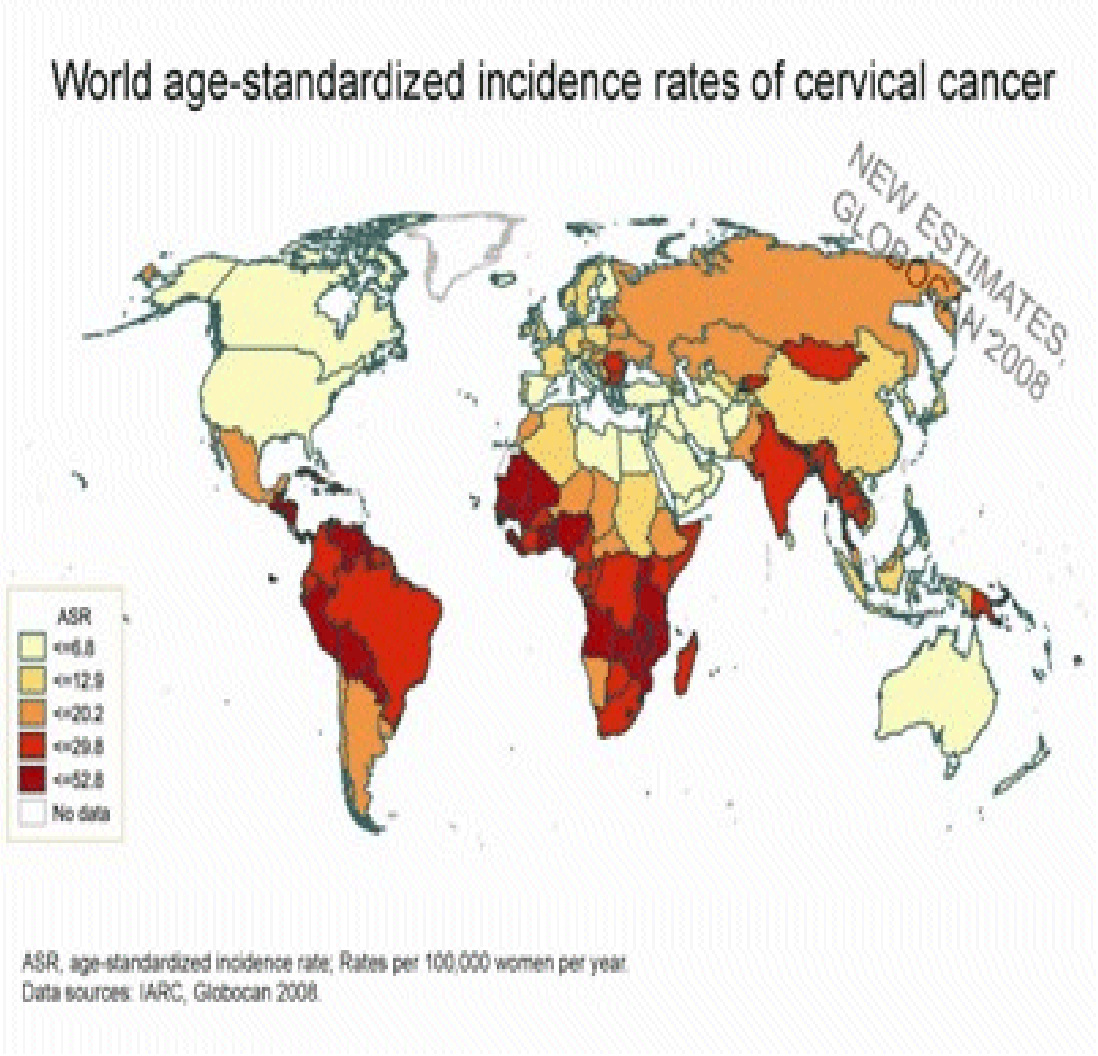

Reproduced with permission

Annexure 8:

F-18 FDG-PET/CT scan showing a cervical mass and internal iliac lymph nodes in a patient who had a FDG-PET scan at Charlotte Maxeke Johannesburg hospital.



Annexure 9:

FDG avid primary cervical disease and para-aortic lymph nodes in a patient who had a F-18 FDG-PET/CT scan at Charlotte Maxeke Johannesburg Hospital.

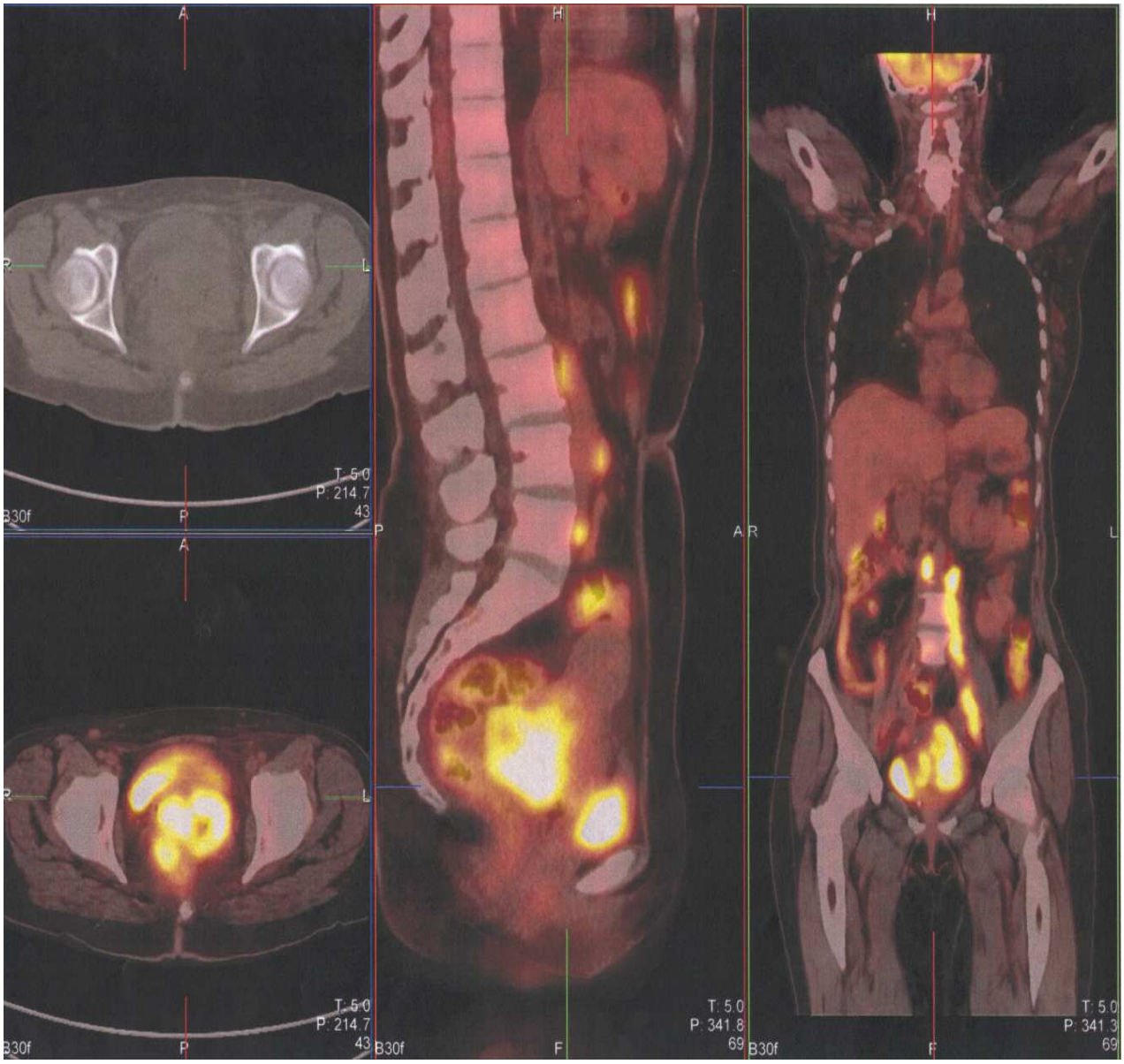

Annexure 10:
F-18 FDG-PET/CT scan showing local and distant nodal disease.

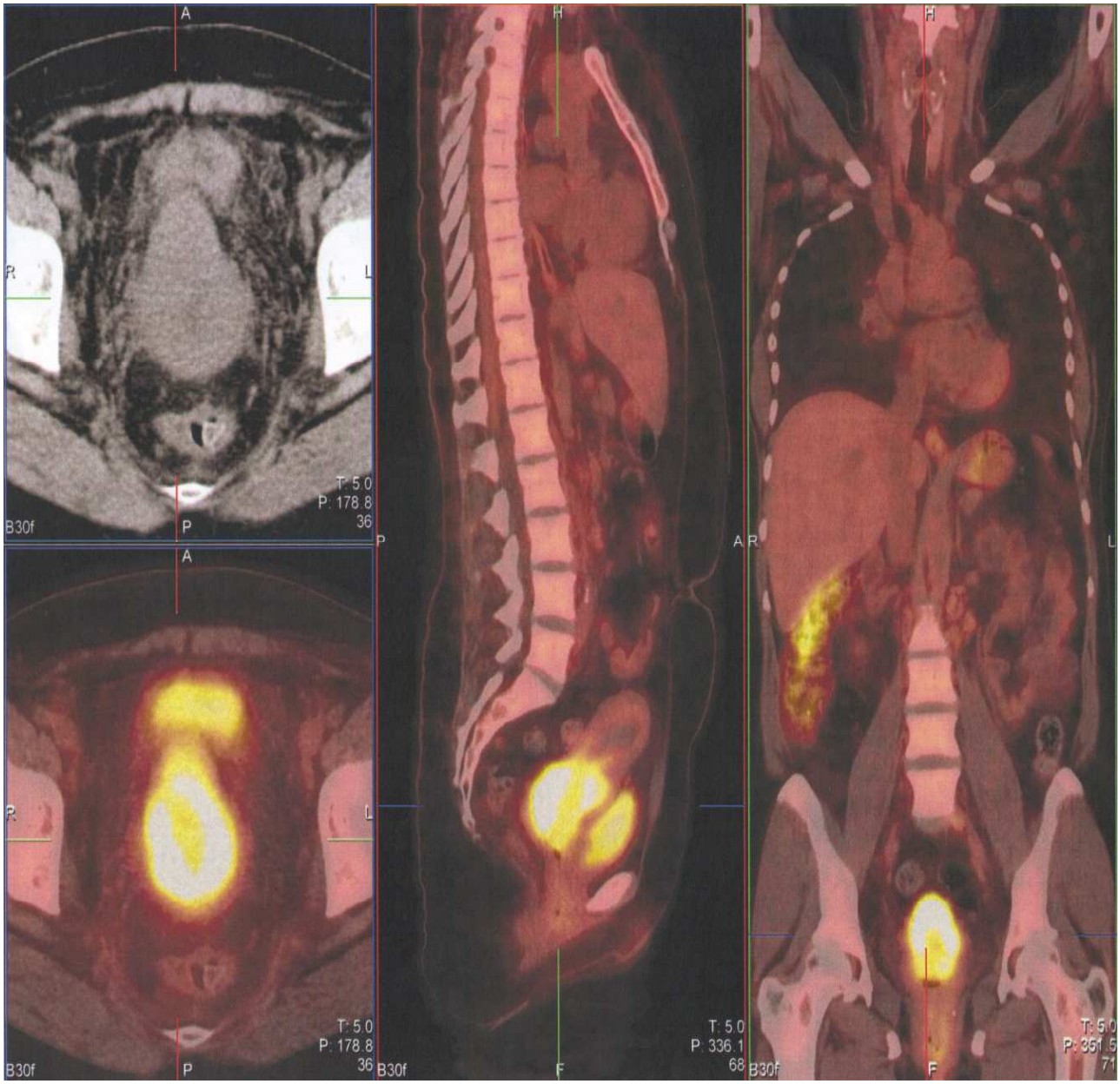

Annexure 11:

F-18 FDG PET/CT in a patient with left external iliac lymph node and left internal iliac lymph node on a Pre-Treatment scan

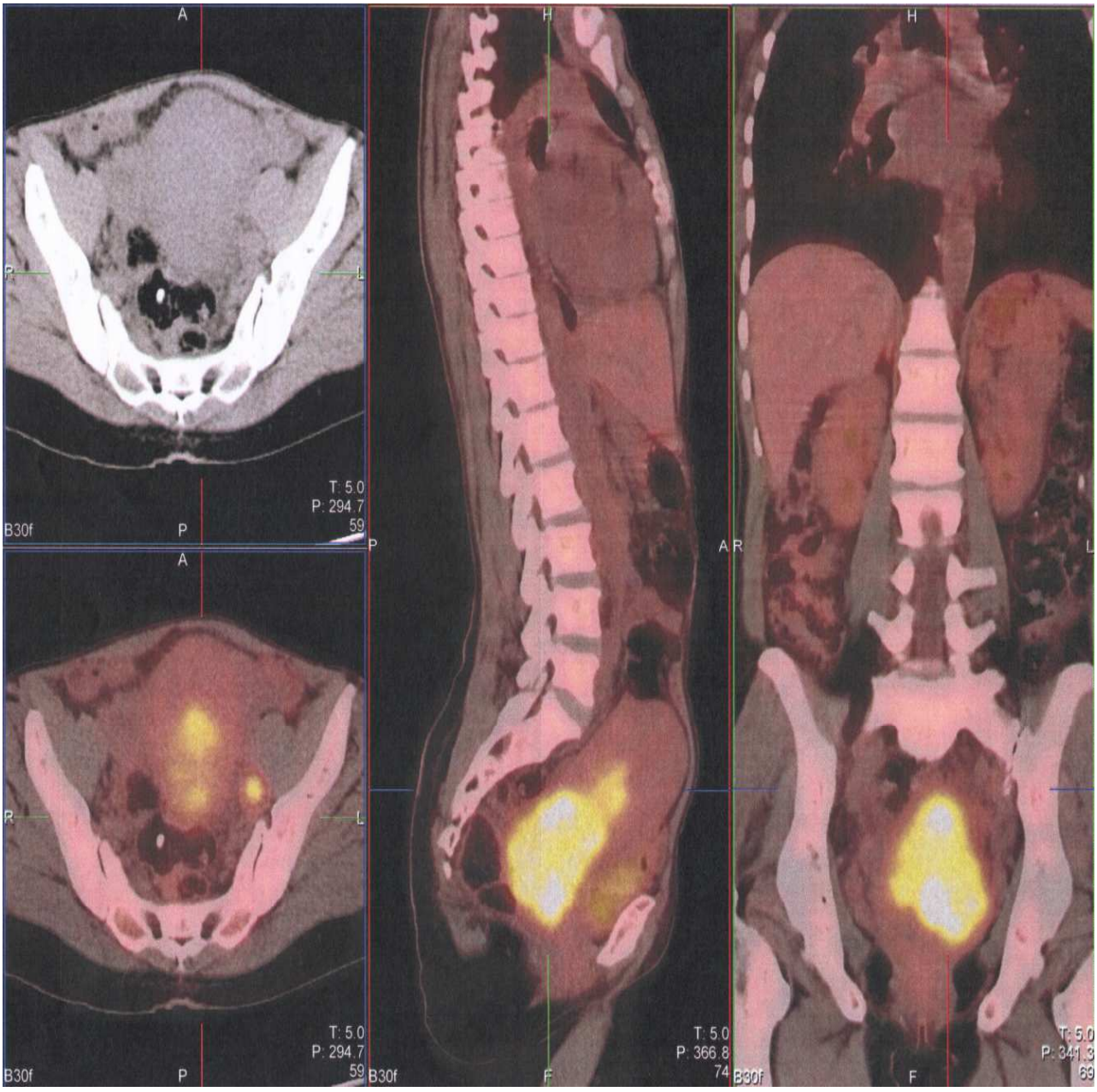

Annexure 12:

Example of linear accelerator/ siemens machine used at Charlotte Maxeke Johannesburg Academic Hospital.



SPECIAL PERMISSIONS OBTAINED:

The following annexures are a list of special permissions obtained for figures and tables which were used in the thesis. The listed annexures provide the authors/ organisations from whom these figures were requested special permissions from.

1. Annexure 13 — Perry Grigsby for figures 7
   figure 8a and 8b
   figure 9
2. Annexure 14 — International Agency for Research on Cancer for
   figure on annexure 6 : Globocan 2008. World wide incidence and mortality for cancer.

   Figure on annexure 7: World age-standardized rates for cervical cancer.
3. Annexure 15 — International Agency for Research on Cancer for the following figures:
   figure 2: early invasive carcinoma of the cervix.
   figure 17: keratinising well differentiated squamous cell carcinoma.
   figure 18: well differentiated adenocarcinoma
4. Annexure 16 — Dra. Raquel Jover- Diaz for figure 3 and figure 5
5. Annexure 17 — Vanessa Harry for figure 1.
6. Annexure 18 — Neil Rofsky for figures 11, 12 and 13.
7. Annexure 19 — Perry Grigsby for figure 21.
8. Annexure 20 — Perry Grigsby for figure 6, 14, 15, 16, 24, 25