

https://dspace.org/

Computed tomography demonstration of the complications and associations of lymphobronchial tuberculosis in children

Lucas, Susanna

2012-04-03
http://hdl.handle.net/10539/11450

Downloaded from a DSpace repository. https://dspace.org/

COMPUTED TOMOGRAPHY DEMONSTRATION OF THE COMPLICATIONS AND ASSOCIATIONS OF LYMPHOBRONCHIAL TUBERCULOSIS IN CHILDREN

Dr Susan Lucas

A research report submitted to the Faculty of Health Sciences, University of the Witwatersrand, Johannesburg, in partial fulfilment of the requirements for the degree of Master of Medicine in Radiology.

Johannesburg, 2011

Declaration

I, Susan Lucas, declare that this research report is my own work. It is being submitted for the degree of MMed (RadD) at the University of the Witwatersrand, Johannesburg. It has not been submitted before for any degree or examination at this or any other University.

DR S LUCAS

On this 22nd day of September 2011.

I dedicate this to Nic.

Thank you for being my constant amongst all the variables.

Publications and presentations

This work has never been published.

It was presented at the SORSA-RSSA 2011 Imaging Congress in Durban on 4 March 2011.

Abstract

Lymphobronchial tuberculosis (LBTB) is tuberculous lymphadenopathy involving the airways, which is particularly common in children.

AIM: To describe the CT findings of LBTB in children, the parenchymal complications and associated abnormalities.

METHOD: CT scans of 98 children with LBTB were retrospectively reviewed. Lymphadenopathy, bronchial narrowing, parenchymal complications and associations were documented.

RESULTS: Infants comprised 51% of patients. The commonest lymphadenopathy was subcarinal (97% of patients). Bronchial compressions (259 in total) were present in all patients, of which 23% were severe / complete stenoses and 28% affected bronchus intermedius. Parenchymal complications were present in 94% of patients, including consolidation (88%), breakdown (42%), air trapping (38%), expansile pneumonia (28%), collapse (17%) and bronchiectasis (9%), all predominantly right-sided (63%). Associations included oval focal bodies, miliary nodules, pleural disease and intracavitory bodies.

CONCLUSIONS: The most important CT finding of children with LBTB is visible airway compression as a result of lymphadenopathy. CT of children with LBTB showed that airway compressions were more severe in infants and most commonly involved bronchus intermedius. Numerous parenchymal complications were documented, all showing right-sided predominance. Several associations were identified.

Acknowledgements

I would like to acknowledge the following people - without their support, encouragement and guidance this study would have never been possible.

- My supervisor, Professor Savvas Andronikou. His experience as a researcher and special interest in paediatric radiology was invaluable.
- Prof Victor Mngomezulu for allowing dedicated time for research.
- Dr Pierre Goussard and Professor Robert Gie of the Department of Paediatrics, Stellenbosch University for the permission to use their database and for providing clinical input.
- Dr Peter King, dr Carol Hartmann and Professor Michael Mann for help with obtaining the normal values for the diameter of the proximal airways and the formula for calculating the diameters of the more distal airways.
- Prof Elaine Joseph and my other colleagues at Helen Joseph Hospital for their understanding and support.
- André Nieuwoudt and Dr Owen Terreblanche for help with IT related problems.
- Dr Alison Bentley, not only for the course in research writing, but for sound advice every step along the way.
- Dr Elena Liebhaber for help with the statistical analysis.
- Charné, Jacques, André and my other family and friends for believing in me.
- Nic, not only for proofreading the manuscript, but for your love, support and involvement.

Table of Contents

Declaration ii

Publications and presentations iv

Abstract v

Acknowledgements vi

Table of Contents vii

List of Figures ix

List of Tables x

1. Introduction 1

1.1 Methods to diagnose TB in children 2

1.2 What is lymphobronchial TB? 5

1.3 The appearance of LBTB on chest X-ray (CXR) 7

1.4 CT compared to CXR for imaging of LBTB 7

1.5 Types of CT acquisition – multi-detector, combiscan and high resolution 9

1.6 CT compared to bronchoscopy 10

1.7 Indications for CT in patients with LBTB 11

1.8 Study objectives 11

2. Materials and Methods 12

2.1 Components of the database utilised in the current study 12

2.2 Definitions 13

2.3 Inclusion and exclusion criteria for the current study 17

2.4 Collation of data for analysis 17

2.5 Determination of the degree of airway narrowing 17

2.5.1 Calculation of normal values for diameter of third and fourth order bronchi .. 18

2.6 Statistical analysis 19

3. Results 20

3.1 Study population 20

3.2 Lymphadenopathy: Sites and distribution 20

3.3 Compressions of the tracheobronchial tree 21

3.4 Parenchymal complications of LBTB 24

3.5 Associations of LBTB 26

4. Discussion 27

4.1 Results in context 27

4.2 Current applications of chest CT in children with LBTB 34

4.3 Limitations of the current study 34

4.4 Future applications of CT chest in children with LBTB 35

4.5 Areas of future research identified by the current study 38

5. Conclusion 40

Appendix A: Ethics Clearance Certificate 41

Appendix B: Calculated values for categorising severity of stenosis of the individual airways according to age. 42

6. References 44

List of Figures

Figure 1.1 Pathogenesis of LBTB..... 6

Figure 2.1 Examples of the documented complications of LBTB detected on CT 15

Figure 2.2 Examples of the documented associations of LBTB detected on CT 16

Figure 4.1 Unusual complications and associations of LBTB as seen on CT..... 33

Figure 4.2 MinIP and MIP coronal reformatting demonstrating airway compression, incriminating lymphadenopathy and parenchymal complications and associations of LBTB in children 37

List of Tables

Table 1.1 WHO criteria for the diagnosis of pulmonary TB in children 2

Table 2.1 Normal values (in mm) for airways in different age groups..... 19

Table 3.1 Distribution of lymphadenopathy detected by CT of children with LBTB..... 21

Table 3.2 Number of airway compressions by age and severity detected by CT of children with LBTB 22

Table 3.3 Number of airway compressions by site and severity detected by CT of children with LBTB 23

Table 3.4 Instances of specific parenchymal complications detected by CT of children with LBTB 24

Table 3.5 Number of patients with specific parenchymal complications detected by CT of children with LBTB 25

Table 3.6 Instances of associated findings of LBTB detected by CT of children with LBTB 26

Table 4.1 Comparison of three studies with regard to the prevalence of lymphadenopathy detected by CT of children with TB 28

Table 4.2 Average age-specific risk for disease development after primary TB infection* 29

1. Introduction

The incidence of tuberculosis (TB) is increasing globally and South Africa's incidence ranks third in the world with respect to both TB and multi-drug resistant (MDR) TB cases (1). Adding to the burden of disease, there are an estimated 5.3 million people living with HIV/AIDS in South Africa (2).

TB is one of the top ten causes of mortality in the paediatric age group, regardless of HIV status. HIV-positive young adults are increasingly infected with TB, which increases the exposure and infection risk of children (3). The WHO states that the source of infection of most children is an infectious adult in their close environment, usually within the household (4). If the children themselves are HIV positive, their risk of infection is further increased and they are also more likely to get more severe forms of TB. HIV-positive children with TB have a higher mortality rate, and both a lower cure rate for and higher recurrence rate of TB (3).

Primary TB results from the inhalation of droplets containing the causative organism, *Mycobacterium tuberculosis*. This initiates a localised pneumonic process, called the Ghon focus. From here, the bacilli spread to the regional lymph nodes via the lymphatics. This local infective focus with associated lymphangitis and lymphadenopathy is known as the primary complex or Ghon complex (5; 6). It is this regional lymphadenopathy that is considered the hallmark of the radiological diagnosis of TB in children (5).

1.1 Methods to diagnose TB in children

TB in children is notoriously difficult to diagnose clinically. Patients may be asymptomatic in 50% (7) to 90% (3) of cases, or may have non-specific symptoms such as cough, fever, wheezing, dyspnoea, weight loss or failure to thrive (7; 8). Clinical signs may be scanty, but include crepitations, bronchial breathing, wheezes or decreased breath sounds over the affected lung fields (8).

The WHO criteria (4) for the diagnosis of pulmonary TB in children are detailed in Table 1.1.

Table 1.1 WHO criteria for the diagnosis of pulmonary TB in children

A. Positive acid-fast stain of sputum or gastric aspirate
OR
B. Three or more of the following:
• History of contact with a known or suspected case of active TB

• Physical signs of TB
  ○ Cough lasting longer than 2 weeks
  ○ Fever > 38° for 2 weeks after common causes such as pneumonia and malaria have been excluded
  ○ Weight loss or failure to thrive
  ○ Signs of extrapulmonary TB such as gibbus or non-painful cervical lymphadenopathy with fistula formation

• A reactive tuberculin skin test
  ○ >5 mm in high risk children (HIV+, severely malnourished)
  ○ >10 mm in all other children, regardless of BCG vaccination

• Radiological findings compatible with TB
• Response to anti-TB therapy (increased body weight by 10% after 2 months, decrease in symptoms)

If TB is suspected in a child either on clinical grounds or on the basis of exposure, special investigations may aid or prove the diagnosis (7).

The Mantoux or tuberculin skin test is interpreted in the light of clinical information such as HIV status and exposure history. The gold standard for diagnosis is the culture of *M. tuberculosis.* However, the mycobacterial bacilli may be visualised in body fluids using special stains such as Ziehl Neelsen, auramine and rhodamine (7). Obtaining diagnostically positive sputum is difficult in children because of the paucibacillary nature of the disease and the fact that children produce less sputum (9). The material for direct stain and / or culture may be obtained from sputum, gastric lavage, cerebrospinal fluid or aspiration of lymph nodes, pleural effusions or soft tissue masses. Bronchoscopy may aid in obtaining the bacilli necessary for diagnosis, but this procedure is invasive and difficult to perform in children (10).

The polymerase chain reaction (PCR) is another diagnostic test which may be used to detect *M. tuberculosis* genetic material. This test is possibly too sensitive for routine use in the South African setting, as it may be positive in patients that have *M. tuberculosis* infection only, rather than those with active disease (11). PCR may also be positive in treated TB, as it cannot differentiate between genetic material derived from viable or non-viable bacilli (12). It is a relatively expensive investigation that requires sophisticated equipment and technical expertise which are not widely available in developing countries and PCR is thus not a routinely advised diagnostic modality for TB (12). However, very recent (April 2011) publications have shown that a new PCR-based test, the Xpert ®

MTB/RIF assay is rapid and cost-effective and could prove very useful in expediting the diagnosis of TB in adults and children (13; 14).

There are no pathognomonic radiological signs for the diagnosis of TB. However, on plain x-rays, the radiographic hallmark of primary TB in children is lymphadenopathy (5; 6; 15). This may be unilateral or bilateral (6), may cause airway compression and may show calcification (16). Other radiological changes include consolidation, hyperinflation, collapse, pleural effusions, miliary infiltrates or solitary masses (7; 10; 16; 17). Cavitation is rarely identified in young children, but is a more frequent finding in adolescents (4; 7).

Computed tomography (CT) of the chest with administration of contrast media may identify lymph nodes that are not visible on plain radiographs (10; 18-20). It is the modality of choice for lymph node detection (21). CT can also better demonstrate any parenchymal or pleural changes which may present (15). Parenchymal features of TB on CT include interstitial (linear, nodular or confluent), segmental or lobar pathology (22). Associated findings are necrosis, cavitation, pleural effusions, empyema and bronchiectasis (6; 21-24).

Magnetic resonance imaging (MRI) with gadolinium administration can also demonstrate nodal, parenchymal and pleural disease (24). However, this is a very costly investigation which is not widely available and may require anaesthesia or sedation as the procedure is lengthy.

1.2 What is lymphobronchial TB?

When primary tuberculous infection within the lymph nodes involves the airways, the result is lymphobronchial TB (LBTB). This term encompasses a whole spectrum of airway involvement and its associated complications (25). The lymph nodes enlarge and involve the airways by compression of the airway, infiltration of the airway or erosion into the airway (26).

The pathogenesis of LBTB is summarised in Figure 1.1. The pathological process starts with partial occlusion of the lumen, with a ball-valve effect that leads to air trapping in the affected segment or lobe, which may in turn undergo consolidation. In consolidated segments with completely occluded bronchi the lung may fill with fluid, resulting in the so-called “drowned lung” (27). These areas of consolidation still show perfusion on post contrast scan. If, however, a segment is necrosed or infarcted, it will show non-perfusion. Infarcted segments or lobes may break down or cavitate. Bronchiectasis may also develop in areas of longstanding or chronic consolidation.

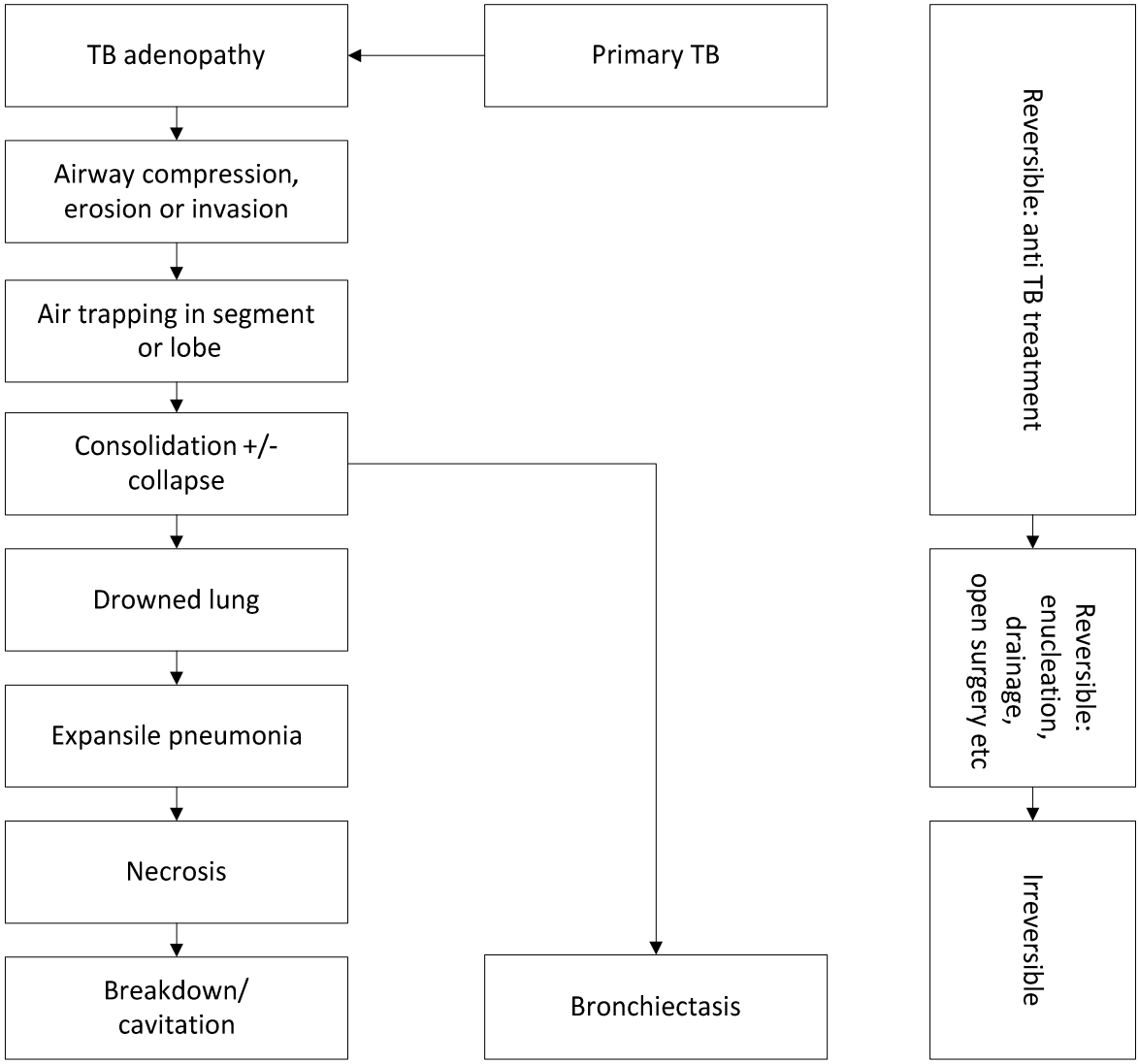

Figure 1.1 Pathogenesis of LBTB

Obstruction of the airway may result from external compression or intraluminal obstruction by inflammatory change in the bronchial wall or herniation of a caseating lymph node. (28). This usually affects the right main bronchus or bronchus intermedius (24). The resulting radiologically demonstrable parenchymal complications of obstruction include air trapping, collapse, consolidation, expansile pneumonia, necrotising pneumonia and liquefaction with or without cavitation (29). Erosion of tuberculous lymph

nodes into the airways can cause intrabronchial spread, resulting in distant alveolar or bronchopneumonic consolidation (23).

1.3 The appearance of LBTB on chest X-ray (CXR)

The parenchymal findings of LBTB on CXR vary and are determined by the nodal pathology. Enlarged hilar and mediastinal lymph nodes are invariably identified, together with narrowing of the adjacent airway. The paratracheal (22) and subcarinal (19; 21) nodal groups are most commonly affected, but multiple sites are usually involved (19; 22; 30). If airway obstruction is incomplete, a ball-valve effect can cause a hyperinflated lung or lobe (5; 26; 31), depending on the level of obstruction. Complete obstruction may result in collapse of the affected segment or lobe (31). Nodes eroding into the tracheobronchial tree will result in parenchymal disease as a result of endobronchial spread.

1.4 CT compared to CXR for imaging of LBTB

CT is the most sensitive way of imaging the lungs due to its high spatial resolution (15; 32). It is far superior to CXR for detecting nodal disease and for characterising parenchymal disease. The administration of intravenous contrast allows for good visualisation of the vascular tree (32), making differentiation of pathological nodes possible as nodes do not enhance to the same degree as the vessels. With the increased resolution comes increased radiation dose; the radiation dose of a CT chest is equivalent to approximately 150 CXRs (33). It is important when imaging children to only perform clinically indicated CT scans, to use the optimum exposure factors and to choose a

protocol that keeps the radiation to the child to a minimum, adhering to the ALARA principle. (As Low As Reasonably Achievable).

Clear practice principles have been laid out through the “Image Gently” campaign: (34)

- Reduce the amount of radiation used, tailored to the size of the child;
- Scan only when necessary;
- Scan only the indicated region;
- Scan only once.

LBTB is a complication of TB seen almost exclusively in children who are more at risk because of the small calibre and compressibility of their airways. Although regional lymphadenopathy is the radiological hallmark for the diagnosis of TB in children, compression of the airways by these enlarged nodes (i.e. LBTB) I seen in only 38% of patients on CT (35). Newborns and children up to 3 years old are more likely to have lymphadenopathy and are consequently more likely to develop LBTB (23). The radiological findings of LBTB on CXR are well established, but the findings on CT are not well documented and neither is the prevalence of parenchymal complications. Similarly, The CT findings of patients with TB are well documented, but there is a paucity of literature regarding CT of LBTB. Where mentioned, the findings include enlarged lymph nodes, hyperinflation, consolidation, drowned lung, necrosis, bulging fissures and eventual cavitation (24; 28).

1.5 Types of CT acquisition – multi-detector, combiscan and high resolution

Modern CT scanners offer multi-detector technology, which allows data to be obtained faster and in more detail than ever before. The faster acquisition time of the multi-detector CT (MDCT) scanners, especially those which are 16-slice and more, decreases the need for sedation, reducing costs and usage of resources (36; 37).

The standard MDCT scan allows the acquisition of a three-dimensional volume of data, making reconstruction of images possible in all three planes (axial, sagittal and coronal). The slice thickness of standard MDCT (usually 1.5mm) does not allow for true high-resolution reconstruction of the lung fields. Post-processing, however, not only allows two-dimensional reconstruction in all three planes (multi-planar reconstruction or MPR), but can also produce three-dimensional or volumetric images (32). Both multi-planar reconstruction (MPR) and three-dimensional volume rendering (3D VR) have been shown to improve diagnostic accuracy (36).

A true high-resolution CT of the chest is the acquisition of 1mm thick slices throughout the chest at 10mm intervals. This is not a volumetric scan and three-dimensional reconstruction is not possible as the dataset is not contiguous (32).

The “combiscan” method is also a volumetric data acquisition, but it differs from the standard method in that a thinner tube collimation is used (0.5 to 1mm versus 1.5 mm for the standard MDCT). This provides finer detail of the smaller airways and vessels as well as allowing for high-resolution reconstruction of the lung fields using a bony algorithm.

The radiation dose for a combiscan is slightly more than that for the standard method, but because high-resolution reconstruction of the data is possible, it is not necessary to scan the patient again to obtain this information. This minimises the radiation exposure of the patient according to the "scan only once" principle mentioned above. All the post-processing for the standard MDCT is also possible on the combiscan data (32). The administration of intravenous contrast allows differentiation of nodes from vessels and assists identification of any vascular abnormalities that may be present (32).

1.6 CT compared to bronchoscopy

A study comparing the accuracy of three-dimensional volume rendered CT (3D VRCT) with fibreoptic tracheobronchoscopy (FTB) (35) demonstrated definite advantages of 3D VRCT:

- It is not possible to pass a bronchoscope beyond severe and complete obstructions, but 3D VRCT can visualise these airways and identify further stenoses (35).
- 3D VRCT is able to identify the cause of stenoses which FTB may not be able to. In the abovementioned study 14% of stenoses were caused by structures other than lymphadenopathy (35).

Furthermore, other studies demonstrated that:

- CT is less invasive, does not require general anaesthesia and with faster scanning times requires less sedation than FTB (36).
- CT is able to provide additional information on the parenchymal complications and other associations present (24).

Although FTB is a more invasive procedure it has the advantage of being able to obtain tissue for diagnosis. It is also possible to do enucleation of obstructing nodes in the same procedure.

1.7 Indications for CT in patients with LBTB

Identifying the complications and associations of LBTB has clinical relevance. These patients may need surgical intervention in the form of enucleation of an obstructing node to decompress a bronchus, or removal of intraluminal obstructions via bronchoscopy (38-40). Recovering patency of the airway and allowing resolution of the parenchymal disease associated with the obstruction can thus be achieved. In such cases, the CT scan serves as a road map for the surgical approach (37), and follow-up CT scans may confirm resolution (41). Even though CT may not replace bronchoscopy, is proving to be very useful as a complementary study (42).

CT is thus a highly useful modality in this disease setting, allowing diagnosis of TB, detection of LBTB and its complications, providing multi-planar and three-dimensional surgical guidance (35) and allowing post surgical follow up for assessment of response and resolution (41).

1.8 Study objectives

This study aims to describe the imaging features on CT chest of LBTB in children, to document the parenchymal complications and to identify any associated abnormalities.

2. Materials and Methods

This study is a retrospective descriptive analysis of patient records, which were previously collated into an established database for use in a larger clinical project by the Department of Paediatrics at the University of Stellenbosch. Ethics approval for this study was obtained on 30/04/2010, the clearance certificate M10441 is attached as Appendix A.

2.1 Components of the database utilised in the current study

The database comprises children below 13 years of age with known TB, presenting to a paediatric pulmonologist between 1 March 2004 and 31 August 2010 with symptoms and signs of major airway compression. These included persistent coughing and wheezing, unilateral hyperinflation, expansile pneumonia, pneumonia not responding to treatment and lobar collapse. TB was previously confirmed either by culture or by demonstration of acid fast bacilli in gastric or bronchial aspirates. The HIV status of all the patients had been determined by PCR and was extracted from the available clinical data. The patients had been treated for 30 days with a quadruple anti-TB drug regimen, to which steroids were added. If they had persistent clinical or radiological evidence of major airway obstruction after 30 days of treatment, a diagnosis of LBTB was made. Fibreoptic tracheobronchoscopy (FTB) and CTs of the chest were performed to investigate the cause and level of airway obstruction, as part of the routine clinical management of these patients.

CT scans were performed on a four-slice multi-detector CT scanner (Aquilon, Toshiba) using the Tygerberg Hospital radiology department's routine chest CT protocol for children, with 120 kVp tube voltage and 50 mA tube current. Contrast was administered by hand injection

at a dose of 2ml/kg. Routine combiscanning provided mediastinal windows, lung windows and high resolution reconstructions on lung windows.

All CT scans were reviewed by the same paediatric radiologist with regards to:

- Airway stenosis: presence, distribution and diameter at the level of maximum stenosis in the axial plane.
- Lymphadenopathy: presence and distribution of lymphadenopathy was documented at six sites: trachea, left main bronchus (LMB), left upper lobe bronchus (LULB), left lower lobe bronchus (LLLB), right main bronchus (RMB), bronchus intermedius (BI) and right lower lobe bronchus (RLLB). The size of only the nodal group implicated in airway stenosis was measured.
- Parenchymal complications of LBTB with lateralisation: consolidation; breakdown; air trapping; expansile pneumonia; collapse and bronchiectasis.
- Associated findings related to TB: oval focal bodies; miliary nodules; pleural disease and intracavitory bodies.

2.2 Definitions

Consolidation was equivalent to any air-space disease and defined as any dense area of lung which enhanced and demonstrated air-bronchograms that was either filling a lobe or had ill defined edges.

Drowned lung was defined as fluid filled lung distal to a complete obstruction of an airway.

Expansile pneumonia was defined as an area of consolidation with bulging fissures, regardless of enhancement pattern.

Necrosis or necrotising pneumonia was recorded whenever a segment of lung did not show enhancement.

Liquefaction was recorded whenever the density of any non-enhancing lung (necrotic lung) was low, approximating water.

Breakdown and cavitation was defined as any areas of irregular air-filled pockets within the affected lung.

Intracavitory bodies were defined as any solid material within cavities.

Oval focal bodies were defined as small round, oval or flame-shaped nodules thought to represent the primary or Ghon focus.

Figure 2.1 shows examples of the documented complications, while figure 2.2 demonstrates examples of the documented associations of LBTB.

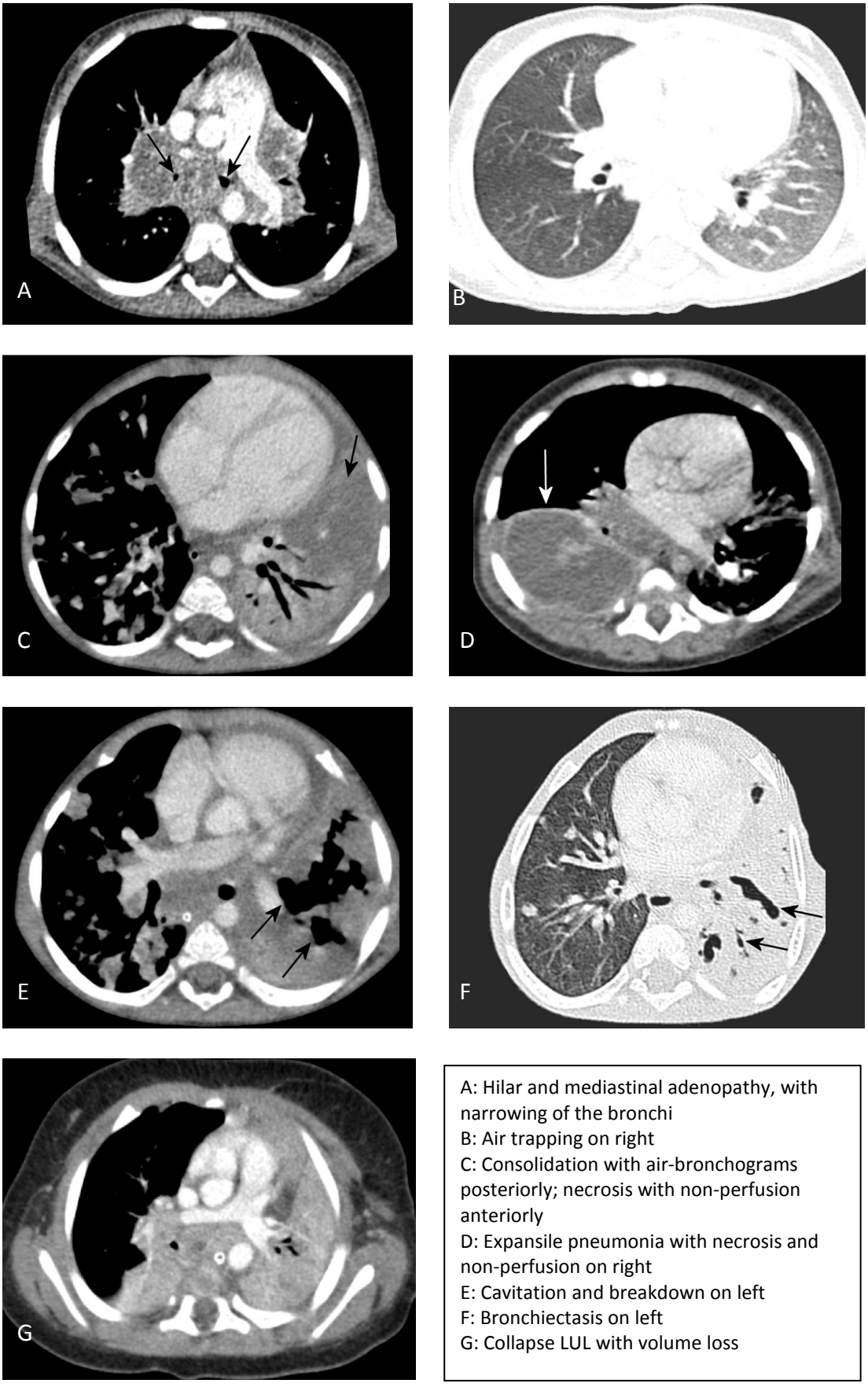

A: Hilar and mediastinal adenopathy, with narrowing of the bronchi
B: Air trapping on right
C: Consolidation with air-bronchograms posteriorly; necrosis with non-perfusion anteriorly
D: Expansile pneumonia with necrosis and non-perfusion on right
E: Cavitation and breakdown on left
F: Bronchiectasis on left
G: Collapse LUL with volume loss

Figure 2.1 Examples of the documented complications of LBTB detected on CT

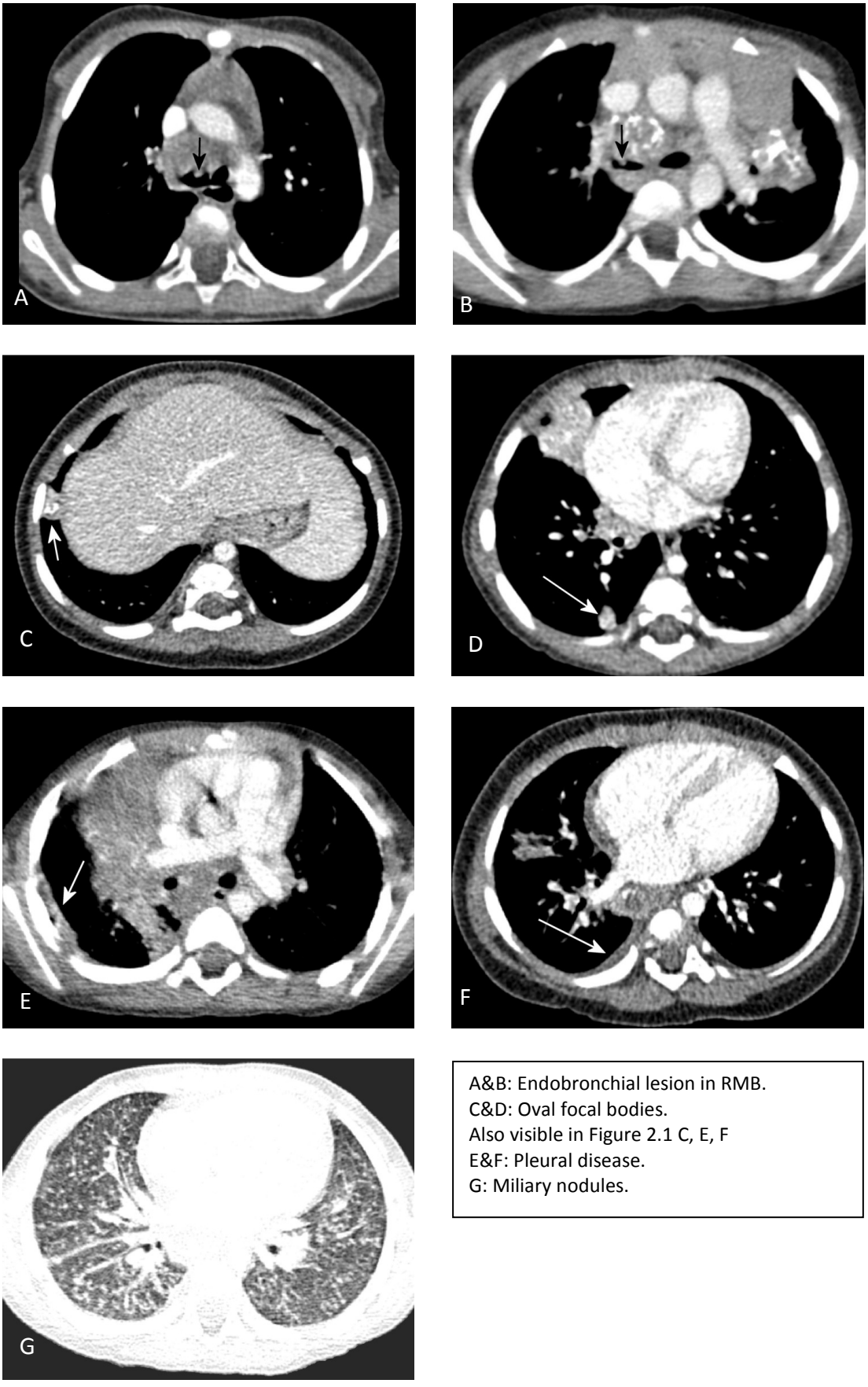

A&B: Endobronchial lesion in RMB.
C&D: Oval focal bodies.
Also visible in Figure 2.1 C, E, F
E&F: Pleural disease.
G: Miliary nodules.

Figure 2.2 Examples of the documented associations of LBTB detected on CT

2.3 Inclusion and exclusion criteria for the current study

Children below 13 years of age were included in the Tygerberg database. From this database patients who had undergone CT scanning were selected for consideration in the current study. The first 100 adequate CTs that were available for reading were included in this study. Cases were excluded if CT was deemed inadequate because of movement artefact or other technical factors affecting interpretation. Two cases were excluded because of insufficient data.

2.4 Collation of data for analysis

Ninety eight patients were included in the study. The spreadsheet of radiological findings from the CT scans of each of these patients was examined and sites of lymphadenopathy, diameter of the airway at the level of maximum stenosis, parenchymal complications and associated abnormalities were extracted and collated. The diameter of the airway at the level of maximum stenosis was utilised to determine the degree of airway narrowing as described below in section 2.5.

2.5 Determination of the degree of airway narrowing

The measured value of the airway diameter at the level of maximum stenosis was compared to the normal value of the airway diameter for the patient's age group and was expressed as a percentage of attenuation. This percentage was then stratified into a category of severity of compression as follows: mild (0-33%), moderate (34-66%), severe (67-99%) and complete (100%) for each airway in each age group.

Normal values for the sizes of the trachea (first order) as well as the left and right main bronchi (second order) according to age were obtained from the literature (43; 44). Normal values for the diameter of the bronchial tree distal to the main bronchi (third and fourth order) were not available in the literature and were calculated as described in section 2.5.1 below.

2.5.1 Calculation of normal values for diameter of third and fourth order bronchi

The normal values for the sizes of the left upper lobe bronchus, bronchus intermedius (third order bronchi), and right lower lobe bronchus (fourth order bronchus) were calculated according to the following formula (45; 46):

$$d(z) = d_0 . 2^{-z/3}$$

Where d = diameter of bronchus

z = generation of bronchus

d_0 = diameter of trachea

The calculated normal values for each age category were rounded off to the nearest mm to facilitate comparison with the calliper measurements obtained on CT. These values are detailed in Appendix B and summarised in Table 2.1 below.

Table 2.1 Normal values (in mm) for airways in different age groups

Age (years)	Age (months)	Trachea	RMB*	BI*	RLLB*	LMB*	LULB*	LLLB*
0-1	0-12	6	5	3	2	4	3	3
1-2	13-24	7	6	3	3	4	3	3
2-4	25-48	8	7	4	3	5	4	4
4-6	47-72	8	7	4	3	5	4	4
6-8	73-96	9	8	5	4	6	5	5
8-10	96-119	9	8	5	4	6	5	5
10-12	120-144	10	8	5	4	7	5	5

*RMB: right main bronchus; BI: bronchus intermedius; RLLB: right lower lobe bronchus;
LMB: left main bronchus; LULB: left upper lobe bronchus; LLLB: left lower lobe bronchus.

The normal values for the age group 2-4 yrs and 4-6 years are the same, and these patients were combined into a 2-6 year age group for the purpose of the data analysis. The 6-8 yr and 8-10 yr age groups were also combined into a 6-10 year age group for the same reasons.

2.6 Statistical analysis

The data was analysed using STATISTICA (data analysis software system), version 9.1; a statistical software package by StatSoft, Inc. with specific reference to the number of compressions by site, age and severity, as well as the number and type of parenchymal changes present including laterality.

Results were expressed as frequencies and percentages for categorical variables.

3. Results

3.1 Study population

The study included 98 children with confirmed LBTB. There were 55 males and 43 females, with ages ranging from 2 to 144 months (median age 12 months, interquartile range of 24 months). The infant group (0 – 12 months) constituted the largest number of patients (51%). The HIV status was positive for 17 patients (17.3%), negative for 80 patients (81.6%) and unknown for 1 (1%) patient.

3.2 Lymphadenopathy: Sites and distribution

Six lymph node sites had been assessed in the database, namely, subcarinal, right paratracheal, right hilar, right azygo-oesophageal, left hilar and right paracardiac. Lymphadenopathy was present in all 98 patients. Multiple sites were usually involved - only one patient had single-site involvement.

The distribution of lymphadenopathy is summarised in Table 3.1.

Table 3.1 Distribution of lymphadenopathy detected by CT of children with LBTB

Site with lymphadenopathy	Number of patients affected	% of patients affected
Subcarinal	95	96.9%
Right paratracheal	92	93.9%
Right hilar	84	85.7%
Right azygo-oesophageal	76	77.6%
Left Hilar	68	69.4%
Right paracardiac	17	17.3%
Total affected sites	432	73.5% of all possible sites
Total possible sites: 6 x 98	588	

The commonest site of lymphadenopathy was the subcarinal region, followed by the right paratracheal and right hilar regions. Of 588 possible lymph node sites (6 sites x 98 patients), lymphadenopathy was documented in 432 sites (432 / 588 = 73.5% of possible sites). The average number of affected sites was 4.41 sites per patient (432/98).

3.3 Compressions of the tracheobronchial tree

Airway compression was documented in the database at seven possible sites. CT scan revealed a total of 259 airway compressions out of a possible 686 sites (7 x 98), which equates to 37.75%. Severity of compression was graded as mild (0-33%), moderate (34-66%), severe (67-99%) or complete (100%).

The number and severity of airway compressions according to age group is summarised in Table 3.2.

Table 3.2 Number of airway compressions by age and severity detected by CT of children with LBTB

Age group	No. of patients	Mild	Moderate	Severe	Complete	Total	No. of compressions per patient
0-1 years	50	58	41	22	19	140	2.8
1-2 years	19	26	15	4	8	53	2.8
2-6 years	19	20	20	2	1	43	2.3
6-10 years	8	10	5	2	1	18	2.3
10-13 years	2	3	1	0	1	5	2.5
All Age Groups	98	117	82	30	30	259	2.6

The infant age group (0-12 months) constituted the largest number of patients and demonstrated the most compressions, 54.1% of total compressions (140 / 259). The number of compressions per patient is similar for each age group and varies from 2.3 to 2.8 compressions per patient. “Severe” and “complete” stenoses formed only 23.2% (30 + 30 / 259) of total stenoses. The infant group demonstrated the largest number of “severe” and “complete” compressions, 68.3% (22 + 19 / 30 + 30) and 82% (22 + 19 / 50) of the infants had “severe” or “complete” compression at some level. Only 6.7% (2+1+1/30+30) of all of the “severe” and “complete” compressions were in children over 6 years of age.

The site of compression was documented in the database at seven sites and is summarised according to severity in Table 3.3.

Table 3.3 Number of airway compressions by site and severity detected by CT of children with LBTB

Site	Degree of severity of compression				Total compressions
	Mild	Moderate	Severe	Complete	
Trachea	44	16	2	0	62
LMB*	22	25	7	9	63
LULB*	3	0	1	1	5
LLLB*	7	2	0	1	10
RMB*	10	9	1	0	20
BI*	15	24	18	16	73
RLLB	16	6	1	3	26
All sites	117	82	30	30	259

* LMB: left main bronchus; LULB: left upper lobe bronchus; LLLB: left lower lobe bronchus; RMB: right main bronchus; BI: bronchus intermedius; RLLB: right lower lobe bronchus.

The commonest site of compression was bronchus intermedius (BI), 28.2% of sites (73 / 259), followed by the left main bronchus (LMB), 24.3% (63/259) and trachea, 24% (62/259). Most of the significant compressions ("severe" and "complete") occurred at BI, 13.1% of total sites (18 + 16 / 259) and 56.67% of all severe and complete compressions (18+16/30+30). "Severe" and "complete" compressions made up almost half (46.6%) of the BI compressions (18 +16/73). Tracheal compression was most commonly (96.8%) "mild" or "moderate" (44 + 16/62).

Although they are not tracheobronchial compressions per se, endoluminal lesions were seen in 14 patients, ten right-sided and four left-sided. It was not possible to differentiate granulomatous tissue from debris.

3.4 Parenchymal complications of LBTB

A total of 262 instances of parenchymal complication were identified in the database in 92 of the 98 patients (93.9%). Table 3.4 shows the **instances** of specific parenchymal complications.

Table 3.4 Instances of specific parenchymal complications detected by CT of children with LBTB

Parenchymal complication	Total no. of instances	% of total number of complications (n=262)	Total right-sided	Total left-sided
Consolidation	117	44.7%	71	46
Breakdown	43	16.4%	28	15
Air trapping	41	15.6%	28	13
Expansile pneumonia	29	11.1%	19	10
Collapse	20	7.6%	11	9
Bronchiectasis	12	4.6%	7	5
Total	262		164	98

The commonest instance of complication was consolidation (44.7%), followed by breakdown (16.4%) and air trapping (15.6%).

In total, instances of parenchymal complication were more common on the right, 62.6% (164/262) compared to the left, 37.4% (98/262). Right-sided complications were also increased in each specific category compared to the left. The average number of complications per patient was 2.8 (262/92).

The number of **patients** in the database with specific parenchymal complications that can be ascribed to LBTB, together with laterality of the lesions, are summarised in Table 3.5.

Table 3.5 Number of patients with specific parenchymal complications detected by CT of children with LBTB

Parenchymal complication	Total no. of patients	% of total no. of patients (n=98)	Unilateral on right	Unilateral on left	Bilateral
Consolidation	86	87.7%	40	15	31
Breakdown	41	41.8%	26	13	2
Air trapping	37	37.8%	24	9	4
Expansile pneumonia	28	28.6%	18	9	1
Collapse	17	17.3%	8	6	3
Bronchiectasis	9	9.2%	4	2	3

The commonest complication per patient was consolidation (87.7%), followed by breakdown (41.8%) and air trapping (37.8%). Numerous patients (n=66) had multiple complications, either uni- or bilaterally.

3.5 Associations of LBTB

Other findings related to TB, but which are not complications of LBTB, were documented as associations in the database. A total of 81 associated findings were documented in 56 patients. These included oval focal bodies (Ghon focus - radiological sign of primary TB), pleural disease, miliary nodules and intracavitory bodies. These findings are summarised in Table 3.6.

Table 3.6 Instances of associated findings of LBTB detected by CT of children with LBTB

Associated finding	Instances of associated finding	% of total number of associated findings (n=81)
Oval focal bodies	33	40.1%
Miliary nodules	20	24.7%
Right pleural disease	16	19.8%
Left pleural disease	6	7.4%
Intracavitory body	6	7.4%

The commonest associated finding was oval focal bodies, 40.1%, followed by pleural disease, 27.2% (19.8% + 7.4%) and miliary nodules (24.7%).

Other unusual and rare CT findings were noted. These included extrathoracic lymphadenopathy with anterior chest wall involvement (one patient) and pericardial pathology (one patient). One patient showed extensive pneumomediastinum, likely due to erosion of a mass of necrotic nodes into an airway.

4. Discussion

4.1 Results in context

The incidence of TB is increasing worldwide, and children are at increasing risk of being exposed to the disease (47). The subsequent increase in the number of children with TB has led to an increase in the number of children with complications such as LBTB.

Lymphadenopathy is the hallmark of primary TB in children (5; 6; 15). This means that a high percentage of children with TB will have lymphadenopathy. All the patients in our study had lymphadenopathy, and 99% had more than one site involved. The commonest sites involved were subcarinal, right hilar and paratracheal. This compares well with other studies with regards to the distribution of lymphadenopathy on CXR (5; 6; 15). Table 4.1 compares the current study to two other studies that showed the prevalence in distribution of TB lymphadenopathy on CT. The overall incidence of lymphadenopathy is lower in the study by Andronikou et al (19) , as the patients in this study were only suspected of having TB, and did not have proven TB as in the study by Mukund and colleagues (48) and the current study.

When these pathological lymph nodes affect the airways, the resulting lesions define LBTB. This may take the form of external airway compression, erosion, ulceration, infiltration, intraluminal caseating material or granulation tissue (28).

Table 4.1 Comparison of three studies with regard to the prevalence of lymphadenopathy detected by CT of children with TB

	Andronikou et al 2004 (19)	Mukund 2011 (48)	Current study 2011
No. of patients in study	100	91	98
CT scanner	Single Slice CT	Multi-slice CT	MDCT
Population	Children with suspected TB	Children with proven TB	Proven TB, known LBTB
Median age	21.5 months	11 years	12 months
% of patients with any lymphadenopathy	92%	96.7%	100%
• Subcarinal	90%	76.1%	96.9%
• Right hilar	74%	52.3%	85.7%
• Left hilar	72%	36.4%	69.4%
• Right paratracheal	63%	84.1%	93.9%
% of patients with bronchial compression	35%	35.2% “airway disease”	100%
• Right main bronchus	14%	Not stated	20/98 = 20.4%
• Bronchus Intermedius	8%	Not stated	73/98 = 74.5%
• Left main bronchus	21%	Not stated	63/98 = 64.3%

Not all children with TB will develop LBTB. The incidence of airway narrowing by TB lymph nodes varies from 35% (19) to 40% (15). The patient population of the current study is a superselected population group of children with symptoms of airway compression. It is not known what percentage they represent of the paediatric TB patients at Tygerberg Hospital.

Younger children are more likely to develop disease, including lymphadenopathy, after infection with *M. tuberculosis*. Table 4.2 is reproduced from a review of the literature by Marais et al (5) and summarises the risk of developing disease after infection with TB according to age.

Table 4.2 Average age-specific risk for disease development after primary TB infection*

Dominant response to primary TB infection	Risk of disease by age group				
	< 1 yr	1 – 2 yr	2 – 5 yr	5 – 10 yr	> 10 yr
No disease	50%	70-80%	95%	98%	80-90%
Pulmonary disease (Ghon focus, lymphadenopathy, or bronchial pathology)	30-40%	10-15%	5%	2%	Nil
Pulmonary disease (effusion or adult-type)	Nil	Nil	Nil	Nil	10-20%
TB meningitis or miliary disease	10-20%	2-5%	<0.5%	<0.5%	<0.5%

*After Marais et al (5).

In addition, younger children are more likely to have pathological lymph nodes, probably because their immune systems are less mature (9), allowing organisms to proliferate within the reticulo-endothelial system. Younger children, by nature of their anatomical size, have narrower airways with less supportive cartilage, making them 'softer' and more likely to be compressed.

The above discussions of age specific disease risk and pathological lymphadenopathy resulting in airway compression offer plausible explanations why infants were more likely

to develop LBTB in our study. Although the ages of our patients ranged from 2 months to 12 years, the majority (51%) of our patients were under 1 year of age. This age group also demonstrated more severe compressions with 82% showing “severe” or “complete” compressions at least at one site.

The prevalence of HIV in our study population was 17%. This is in keeping with the prevalence of HIV in children with TB as found in other studies. Reported HIV prevalences in these studies vary from 11.2% in Ethiopia (49) and 18% in Zambia (50) in 2002, to 22.3% (51) and 21% (52) in more recent studies (2007, 2009) in South Africa. This similarity between the HIV prevalence of our study population with LBTB and other study populations with unspecified TB suggests that HIV infection is not a specific predisposing factor for the development of LBTB.

Our patients showed a high percentage of lymphadenopathy at documented sites (73.5% of all possible sites showed nodal enlargement) but compression of the tracheobronchial tree was present at only 38% of sites. Although any of the airways may show compression by lymph nodes, our study showed that BI is the airway most likely to be compressed (28% of all compressions). This is because the BI is a third order bronchus and therefore narrower than the left and right main bronchi. It is a longer, more vertical bronchus situated between the two nodal groups most likely to be enlarged (subcarinal and right hilar). A predominant form of documented BI compression was of a “nutcracker” nature, with compression from both medial and lateral (see Figure 4.2 C). In other cases, larger, more extensive lymphadenopathy “collared” the BI and compressed it in a circumferential manner. BI was not only more frequently compressed, but also more

severely. “Severe” and “complete” compressions made up almost half (47%) of the BI compressions in our study. Goussard and colleagues also found that BI was the most likely airway to be completely obstructed (28).

In contrast to bronchus intermedius, the right and left main bronchi abut the pulmonary arteries and because of this proximity to the arteries, they cannot be compressed by lymphadenopathy in a “nutcracker” fashion. When extensive lymphadenopathy does “collar” the RMB and LMB, their larger calibre appears to protect them initially, as compared to compression of the smaller calibre BI. The LMB showed 24% of total airway compressions compared to 8% for RMB. The narrower diameter and increased length of the LMB compared to the RMB across all age groups may account for this difference.

The trachea exhibited 24% of the total nodal compressions, however, these were mostly (97%) of the “mild” to “moderate” type. This is probably because the trachea is a larger, more rigid airway than the bronchi and because it is not usually circumferentially involved and therefore responds by displacement rather than compression.

Nodal compression of the airways leads to air trapping, consolidation, collapse, expansile pneumonia, necrosis and breakdown (28). The commonest complication documented in our study was consolidation, present in 88% of patients. Of note, however, is that it is not possible to differentiate consolidation secondary to LBTB from that of primary TB, as the radiological appearances are indistinguishable. Consequently, our results may overestimate the number of cases of LBTB complicated by consolidation.

Our patients showed a predominance of right-sided parenchymal complications, both overall and in each category of complication. This is to be expected, as lymphadenopathy was most commonly right-sided and the most frequent and severe bronchial occlusions were also right-sided. In addition, primary TB is reported to be more common on the right, thought to be related to the anatomy of the bronchial tree (30).

Other findings associated with TB which are not necessarily complications of LBTB were documented. These included pleural disease, oval focal bodies, miliary nodules and intracavitory bodies. All of these findings were also more common on the right.

The pathogenesis of TB is a progressively evolving, dynamic process and the imaging findings will subsequently depend on the stage at which the patient is imaged. Our patients showed a variety of synchronous imaging changes, including features of primary TB (oval focal bodies) together with advances LBTB changes (breakdown and cavitation). Other patients showed early LBTB changes (air trapping) together with chronic lung disease in the form of bronchiectasis. Interestingly, it has also been reported that treatment for TB can cause nodes to enlarge paradoxically (15), giving rise to more acute findings in patients with advanced (established) LBTB.

Other unusual and rare CT findings were noted. These included extrathoracic lymphadenopathy and pericardial pathology. One patient showed extensive pneumomediastinum, likely due to erosion of a mass of necrotic nodes into an airway. Figure 4.1 shows some of these unusual appearances of LBTB.

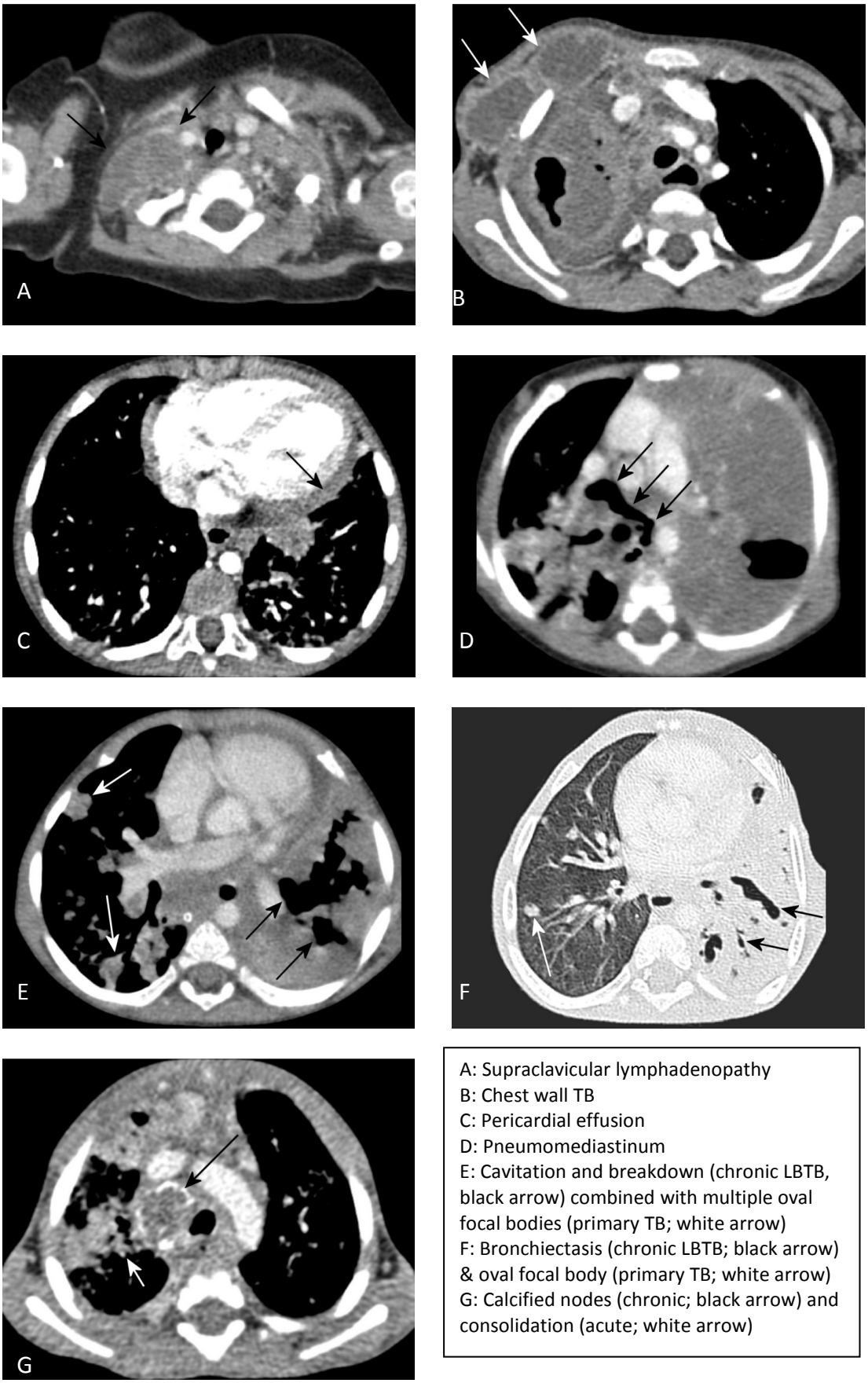

Figure 4.1 Unusual complications and associations of LBTB as seen on CT

4.2 Current applications of chest CT in children with LBTB

CT is a very useful tool for the visualisation of airways, surrounding structures and the parenchyma distal to an airway obstruction. This makes it possible to identify patients at risk for airway occlusion and patients who may be amenable to enucleation of pathological lymph nodes, which may potentially reverse parenchymal changes. CT can subsequently serve as a roadmap for surgery or bronchoscopy to enucleate nodes or to relieve airway symptoms (37). It can also be used for follow-up of LBTB patients, who may be either on anti-TB treatment or post surgery (41). CT should be considered in all patients with airway symptoms especially infants because of the severity of the obstruction we found.

4.3 Limitations of the current study

This study comprised a retrospective analysis of data from the CT imaging findings collected for a larger research study. In the retrospectively reviewed data, the sites of consolidation were not documented in detail by lobe, but only by laterality, and as a consequence, we could not draw any direct conclusions from comparison of the site of the compression and the site of the consolidation. However, we suspect that there is in fact a direct correlation between site of compression and site of consolidation.

The CTs were read by only one reviewer. This introduces bias, but the lack of paediatric radiology subspecialty expertise with experience in TB as well as a lack of resources precluded the use of more than one reviewer.

CT is unable to differentiate the consolidation of primary TB from consolidation which is a complication of bronchial occlusion in LBTB. The number of recorded instances of consolidation in our study may therefore also include primary TB consolidations.

Although information was available in the database which would allow determination of impact of nodal size on the degree of airway compression, this analysis was deemed beyond the scope of the objective of the current study to characterise parenchymal disease. This analysis was rather identified as an area for future study.

4.4 Future applications of CT chest in children with LBTB

Modern post-processing software including thick slab minimum intensity projection (MinIP), maximum intensity projection (MIP), three dimensional volume rendered (3D VR) reconstructions and virtual bronchoscopy represent the immediate future in the diagnosis of LBTB and prediction of complications. These functions are available commercially on most scanners and are relatively user-friendly.

Figure 4.2 shows MIP and MinIP reconstructions demonstrating the usefulness of this post-processing software in the diagnosis and management of patients with LBTB. MinIP is the projection of the lowest density of tissue present in a slab of tissue onto a single image. If a thick slab setting is selected, it can incorporate the entire airway, making stenoses clearly visible. A thinner slice may mimic a stenosis by cutting obliquely through an airway and is not used to assess the airways for narrowing. On the other hand, MIP is the projection of the maximum density of tissue present in a slab of tissue onto a single image, facilitating the visualisation of soft tissue and vascular structures.

The extent of the luminal narrowing as well as the airway distal to the stenosis can be visualised, as shown in Figure 4.2 A and E. Coronal reformatting shows the incriminating nodes in a more anatomical view and the nature of any parenchymal change is clearly visible (e.g. Fig 4.2B, C & D), making it possible for the referring clinician to plan intervention and further treatment, such as bronchoscopic or surgical enucleation.

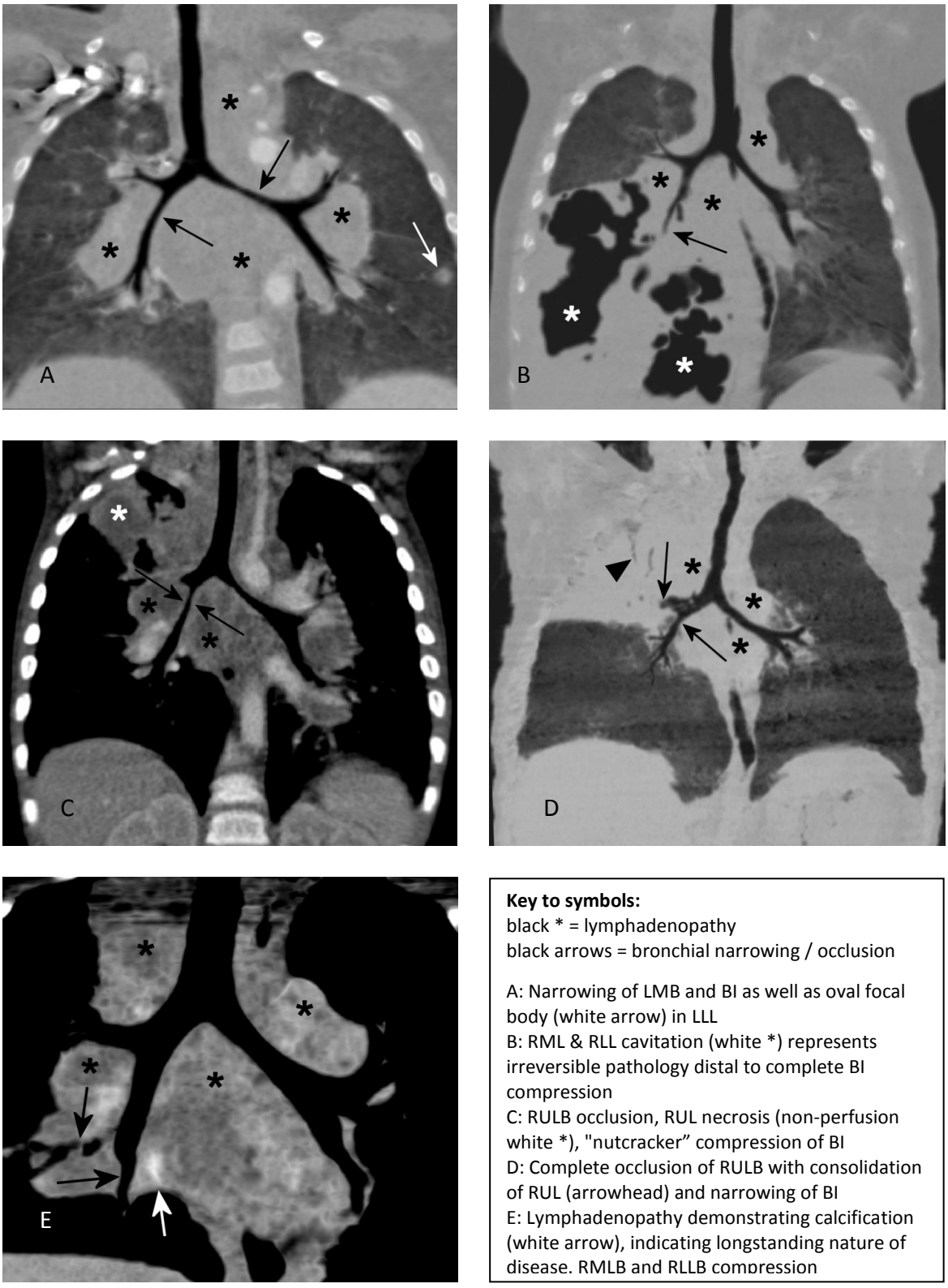

Figure 4.2 MinIP and MIP coronal reformatting demonstrating airway compression, incriminating lymphadenopathy and parenchymal complications and associations of LBTB in children

Virtual bronchoscopy (VB) is another useful post-processing software application (35), especially when traditional bronchoscopy is either unavailable or not possible, as it can be performed on the same CT data set as the other post-processing techniques. VB may be the desired airway visualisation technique for pulmonologists who are more accustomed to this type of view.

MRI for visualising the airways and lungs is as yet not equivalent in quality to CT, but has the advantage of not imparting a radiation dose. In comparison to CT, MRI is extremely useful for demonstrating lymphadenopathy, even without the need for contrast using the STIR imaging sequence. However, the need for anaesthesia during the longer MRI procedures must be weighed against the CT radiation risk in deciding on an imaging modality to image these patients.

4.5 Areas of future research identified by the current study

This study has identified a variety of future research topics. Information in the database could be used to correlate the degree of compression with nodal size. Our impressions from the current study indicate that larger nodes are more likely to cause more severe airway compression. We would be interested to know if there is a correlation between the consistency of lymphadenopathy identified at bronchoscopy and CT density or signal intensity on MRI. If a correlation does exist, further analysis may highlight a relationship between lymph node consistency and likelihood of compression.

The theory of pathogenetic evolution proposed in this study may be confirmed by serial follow-up imaging of children with LBTB, offering further insight into the disease process.

CT of children with LBTB has proved highly useful, both in terms of diagnosis and management. Development of protocols for scanning children with LBTB, in collaboration with referring pulmonologists and thoracic surgeons would be of multi-disciplinary benefit. With such a protocol, information relevant for surgical management decisions could be readily obtained in a consistent and reproducible manner. Furthermore, development of reporting templates for paediatric radiologists to meet the needs of the clinicians in this regard would be a useful adjunct to the scanning protocols.

5. Conclusion

The most important CT finding of children with LBTB is visible airway compression as a result of lymphadenopathy. This compression primarily involves the right-sided airways, most notably the bronchus intermedius. Parenchymal complications distal to an airway narrowing predominantly involve the right lung and include air trapping, consolidation/collapse, expansile pneumonia, breakdown and bronchiectasis. These complications are thought to be an evolving progression of severity imaged at a specific moment in time. Associated findings of TB include miliary nodules, pleural disease and parenchymal oval focal bodies and intracavitory bodies, which are seen in a variety of combinations with the parenchymal complications.

Recognition of LBTB as an entity and identification of the location of airway compression, as well as the presence of related parenchymal complications is highly relevant for paediatric radiologists, paediatric pulmonologists and thoracic surgeons and enables the planning of interventions aimed at salvaging residual vital lung parenchyma in children with pulmonary TB.

Appendix A: Ethics Clearance Certificate

UNIVERSITY OF THE WITWATERSRAND, JOHANNESBURG
Division of the Deputy Registrar (Research)

HUMAN RESEARCH ETHICS COMMITTEE (MEDICAL)
R14/49 Dr Su Lucas

CLEARANCE CERTIFICATE	**M10441**
PROJECT	Computed Tomography Demonstration of the Complications and Associations of Lymphobronchial Tuberculosis in Children
INVESTIGATORS	Dr Su Lucas.
DEPARTMENT	Department of Radiology
DATE CONSIDERED	30/04/2010
DECISION OF THE COMMITTEE*	Approved unconditionally

Unless otherwise specified this ethical clearance is valid for 5 years and may be renewed upon application.

DATE 03/05/2010 **CHAIRPERSON** .....
(Professor PE Cleaton-Jones)

*Guidelines for written 'informed consent' attached where applicable
cc: Supervisor : Prof S Andronikou

DECLARATION OF INVESTIGATOR(S)

To be completed in duplicate and **ONE COPY** returned to the Secretary at Room 10004, 10th Floor, Senate House, University.
I/We fully understand the conditions under which I am/we are authorized to carry out the abovementioned research and I/we guarantee to ensure compliance with these conditions. Should any departure to be contemplated from the research procedure as approved I/we undertake to resubmit the protocol to the Committee. **I agree to a completion of a yearly progress report.**

PLEASE QUOTE THE PROTOCOL NUMBER IN ALL ENQUIRIES...

Appendix B: Calculated values for categorising severity of stenosis of the individual airways according to age.

Calculated values for categorising severity of stenosis for the <u>trachea</u> according to age

Age (years)	Age (months)	Trachea	Mild	Moderate	Severe	Complete
0-1	0-12	6	5-6	3-4	1-2	0
1-2	13-24	7	5-7	3-4	1-2	0
2-6	25-72	8	6-8	4-5	1-3	0
6-10	73-120	9	7-9	4-6	1-3	0
10+	121-144	10	7-10	4-6	1-3	0

Calculated values for categorising severity of stenosis for the <u>LMB</u> according to age

Age (years)	Age (months)	LMB	Mild	Moderate	Severe	Complete
0-1	0-12	4	3-4	2	1	0
1-2	13-24	4	3-4	2	1	0
2-6	25-72	5	4-5	3	1-2	0
6-10	73-120	6	5-6	3-4	1-2	0
10+	121-144	7	5-7	3-4	1-2	0

Calculated values for categorising severity of stenosis for the <u>LUL and LLL bronchus</u> according to age

Age (years)	Age (months)	LUL, LLL	Mild	Moderate	Severe	Complete
0-1	0-12	3	3	2	1	0
1-2	13-24	3	3	2	1	0
2-6	25-72	4	3-4	2	1	0
6-10	73-120	5	4-5	3	1-2	0
10+	121-144	5	4-5	3	1-2	0

Calculated values for categorising severity of stenosis for the <u>RMB</u> according to age

Age (years)	Age (months)	RMB	Mild	Moderate	Severe	Complete
0-1	0-12	5	4-5	3	1-2	0
1-2	13-24	6	5-6	3-4	1-2	0
2-6	25-72	7	5-7	3-4	1-2	0
6-10	73-120	8	6-8	4-5	1-3	0
10+	121-144	8	6-8	4-5	1-3	0

Calculated values for categorising severity of stenosis for the <u>BI</u> according to age

Age (years)	Age (months)	BI	Mild	Moderate	Severe	Complete
0-1	0-12	3	3	2	1	0
1-2	13-24	3	3	2	1	0
2-6	25-72	4	3-4	2	1	0
6-10	73-120	5	4-5	3	1-2	0
10+	121-144	5	4-5	3	1-2	0

Calculated values for categorising severity of stenosis for the <u>LMB</u> according to age

Age (years)	Age (months)	RLL	Mild	Moderate	Severe	Complete
0-1	0-12	2	2		1	0
1-2	13-24	3	3	2	1	0
2-6	25-72	3	3	2	1	0
6-10	73-120	4	3-4	2	1	0
10+	121-144	4	3-4	2	1	0

6. References

(1) WHO; "Global Tuberculosis Control: A short update to the 2009 report." 2010. <http://www.who.int/tb/publications/global_report/2009/update/en/index.html> [Accessed on 22/3/2010].

(2) GeographyIQ; "HIV/AIDS - people living with HIV/AIDS." 2010. <http://www.geographyiq.com> [Accessed on 4/4/2010].

(3) Rekha B, Swaminathan S. Childhood tuberculosis - global epidemiology and the impact of HIV. Paediatr Respir Rev 2007; 8(2):99-106.

(4) WHO Stop TB Partnership Childhood TB Subgroup. Guidance for National Tuberculosis Programmes on the management of tuberculosis in children. Chapter 1: introduction and diagnosis of tuberculosis in children. Int J Tuberc Lung Dis 2006; 10(10):1091-1097.

(5) Marais BJ, Gie RP, Schaaf HS, Hesseling AC, Obihara CC, Starke JJ et al. The natural history of childhood intra-thoracic tuberculosis: a critical review of literature from the pre-chemotherapy era. Int J Tuberc Lung Dis 2004; 8(4):392-402.

(6) Parisi MT, Jensen MC, Wood BP. Pictorial review of the usual and unusual roentgen manifestations of childhood tuberculosis. Clin Imaging 1994; 18(2):149-154.

(7) Khan EA, Starke JR. Diagnosis of tuberculosis in children: increased need for better methods. Emerg Infect Dis 1995; 1(4):115-123.

(8) Cruz AT, Starke JR. Clinical manifestations of tuberculosis in children. Paediatr Respir Rev 2007; 8(2):107-117.

(9) Newton SM, Brent AJ, Anderson S, Whittaker E, Kampmann B. Paediatric tuberculosis. Lancet Infect Dis 2008; 8(8):498-510.

(10) de Charnace G, Delacourt C. Diagnostic techniques in paediatric tuberculosis. Paediatr Respir Rev 2001; 2(2):120-126.

(11) Lima JF, Montenegro LM, Montenegro RA, Cabral MM, Lima AS, Abath FG et al. Performance of nested PCR in the specific detection of Mycobacterium tuberculosis complex in blood samples of pediatric patients. J Bras Pneumol 2009; 35(7):690-697.

(12) Consensus statement on childhood tuberculosis. Indian Pediatr 2010; 47(1):41-55.

(13) Boehme CC, Nicol MP, Nabeta P, Michael JS, Gotuzzo E, Tahirli R et al. Feasibility, diagnostic accuracy, and effectiveness of decentralised use of the Xpert MTB/RIF test for diagnosis of tuberculosis and multidrug resistance: a multicentre implementation study. Lancet 2011.

(14) Cuevas LE. The urgent need for new diagnostics for symptomatic tuberculosis in children. Indian J Pediatr 2011; 78(4):449-455.

(15) Andreu J, Caceres J, Pallisa E, Martinez-Rodriguez M. Radiological manifestations of pulmonary tuberculosis. Eur J Radiol 2004; 51(2):139-149.

(16) Schaaf HS, Beyers N, Gie RP, Nel ED, Smuts NA, Scott FE et al. Respiratory tuberculosis in childhood: the diagnostic value of clinical features and special investigations. Pediatr Infect Dis J 1995; 14(3):189-194.

(17) Theart AC, Marais BJ, Gie RP, Hesseling AC, Beyers N. Criteria used for the diagnosis of childhood tuberculosis at primary health care level in a high-burden, urban setting. Int J Tuberc Lung Dis 2005; 9(11):1210-1214.

(18) Delacourt C, Mani TM, Bonnerot V, de Blic J, Sayeg N, Lallemand D et al. Computed tomography with normal chest radiograph in tuberculous infection. Arch Dis Child 1993; 69(4):430-432.

(19) Andronikou S, Joseph E, Lucas S, Brachmeyer S, Du Toit G, Zar H et al. CT scanning for the detection of tuberculous mediastinal and hilar lymphadenopathy in children. Pediatr Radiol 2004; 34(3):232-236.

(20) Venkateswaran RV, Barron DJ, Brawn WJ, Clarke JR, Desai M, Samuel M et al. A forgotten old disease: mediastinal tuberculous lymphadenitis in children. Eur J Cardiothorac Surg 2005; 27(3):401-404.

(21) Andronikou S, Wieselthaler N. Modern imaging of tuberculosis in children: thoracic, central nervous system and abdominal tuberculosis. Pediatr Radiol 2004; 34(11):861-875.

(22) Lamont AC, Cremin BJ, Pelteret RM. Radiological patterns of pulmonary tuberculosis in the paediatric age group. Pediatr Radiol 1986; 16(1):2-7.

(23) Griffith-Richards SB, Goussard P, Andronikou S, Gie RP, Przybojewski SJ, Strachan M et al. Cavitating pulmonary tuberculosis in children: correlating radiology with pathogenesis. Pediatr Radiol 2007; 37(8):798-804.

(24) Andronikou S, Vanhoenacker FM, De Backer AI. Advances in imaging chest tuberculosis: blurring of differences between children and adults. Clin Chest Med 2009; 30(4):717-744.

(25) Marais BJ, Gie RP, Schaaf HS, Starke JR, Hesseling AC, Donald PR et al. A proposed radiological classification of childhood intra-thoracic tuberculosis. Pediatr Radiol 2004; 34(11):886-894.

(26) Gie RP, Goussard P, Kling S, Schaaf HS, Beyers N. Unusual forms of intrathoracic tuberculosis in children and their management. Paediatr Respir Rev 2004; 5 Suppl A:S139-S141.

(27) Venta LA, Shapir J. Enhancement of pulmonary vasculature in pulmonary consolidation as seen by computed tomography. J Comput Tomogr 1985; 9(2):133-135.

(28) Goussard P, Gie R. Airway involvement in pulmonary tuberculosis. Paediatr Respir Rev 2007; 8(2):118-123.

(29) Andronikou S, Wieslthaler N. Imaging for tuberculosis in children. In: Schaaf HS, Zumla A, editors. Tuberculosis: a comprehensive clinical reference. Philadelphia: Saunders Elsevier, 2009: 261-295.

(30) Leung AN, Muller NL, Pineda PR, FitzGerald JM. Primary tuberculosis in childhood: radiographic manifestations. Radiology 1992; 182(1):87-91.

(31) Marais BJ, Gie RP, Schaaf HS, Beyers N, Donald PR, Starke JR. Childhood pulmonary tuberculosis: old wisdom and new challenges. Am J Respir Crit Care Med 2006; 173(10):1078-1090.

(32) Park KM, Owens CM. When should CT be performed in children with lung disease? Paediatrics and Child Health 2009; 19(6):282-290.

(33) Brody AS, Frush DP, Huda W, Brent RL. Radiation risk to children from computed tomography. Pediatrics 2007; 120(3):677-682.

(34) Goske MJ, Applegate KE, Boylan J, Butler PF, Callahan MJ, Coley BD et al. The Image Gently campaign: working together to change practice. AJR Am J Roentgenol 2008; 190(2):273-274.

(35) Du Plessis J, Goussard P, Andronikou S, Gie R, George R. Comparing three-dimensional volume-rendered CT images with fibreoptic tracheobronchoscopy in the evaluation of airway compression caused by tuberculous lymphadenopathy in children. Pediatr Radiol 2009; 39(7):694-702.

(36) Lee EY, Siegel MJ, Hildebolt CF, Gutierrez FR, Bhalla S, Fallah JH. MDCT evaluation of thoracic aortic anomalies in pediatric patients and young adults: comparison of axial, multiplanar, and 3D images. AJR Am J Roentgenol 2004; 182(3):777-784.

(37) Papaioannou G, Young C, Owens CM. Multidetector row CT for imaging the paediatric tracheobronchial tree. Pediatr Radiol 2007; 37(6):515-529.

(38) Papagiannopoulos KA, Linegar AG, Harris DG, Rossouw GJ. Surgical management of airway obstruction in primary tuberculosis in children. Ann Thorac Surg 1999; 68(4):1182-1186.

(39) Hewitson JP, Von Oppell UO. Role of thoracic surgery for childhood tuberculosis. World J Surg 1997; 21(5):468-474.

(40) Freixinet J, Varela A, Lopez RL, Caminero JA, Rodriguez DC, Serrano A. Surgical treatment of childhood mediastinal tuberculous lymphadenitis. Ann Thorac Surg 1995; 59(3):644-646.

(41) Maydell A, Goussard P, Andronikou S, Bezuidenhout F, Ackermann C, Gie R. Radiological changes post-lymph node enucleation for airway obstruction in children with pulmonary tuberculosis. Eur J Cardiothorac Surg 2010.

(42) Lawler LP, Corl FM, Haponik EF, Fishman EK. Multidetector row computed tomography and 3-dimensional volume rendering for adult airway imaging. Curr Probl Diagn Radiol 2002; 31(4):115-133.

(43) Hammer GB, Fitzmaurice BG, Brodsky JB. Methods for single-lung ventilation in pediatric patients. Anesth Analg 1999; 89(6):1426-1429.

(44) Respiration and Circulation (Biological Handbooks). Bethesda, MD: Federation of American Societies for Experimental Biology, 1971: 105-108.

(45) Weibel ER. Morphometry of the Human Lung. Berlin: Springer-Verlag, 1963: 123.

(46) The Lung: Scientific Foundations. Second ed. Philadelphia: Lippincot-Raven, 1997: 1064-1066.

(47) Middelkoop K, Bekker LG, Morrow C, Zwane E, Wood R. Childhood tuberculosis infection and disease: a spatial and temporal transmission analysis in a South African township. S Afr Med J 2009; 99(10):738-743.

(48) Mukund A, Khurana R, Bhalla AS, Gupta AK, Kabra SK. CT patterns of nodal disease in pediatric chest tuberculosis. World J Radiol 2011; 3(1):17-23.

(49) Palme IB, Gudetta B, Bruchfeld J, Muhe L, Giesecke J. Impact of human immunodeficiency virus 1 infection on clinical presentation, treatment outcome and survival in a cohort of Ethiopian children with tuberculosis. Pediatr Infect Dis J 2002; 21(11):1053-1061.

(50) Chintu C, Mudenda V, Lucas S, Nunn A, Lishimpi K, Maswahu D et al. Lung diseases at necropsy in African children dying from respiratory illnesses: a descriptive necropsy study. Lancet 2002; 360(9338):985-990.

(51) Schaaf HS, Marais BJ, Whitelaw A, Hesseling AC, Eley B, Hussey GD et al. Culture-confirmed childhood tuberculosis in Cape Town, South Africa: a review of 596 cases. BMC Infect Dis 2007; 7:140.

(52) Hesseling AC, Cotton MF, Jennings T, Whitelaw A, Johnson LF, Eley B et al. High incidence of tuberculosis among HIV-infected infants: evidence from a South African population-based study highlights the need for improved tuberculosis control strategies. Clin Infect Dis 2009; 48(1):108-114.