

https://dspace.org/

Primary orthodontic treatment for the cleft palate patient

Dreyer, C. J.; Gavron, G.

1962

http://hdl.handle.net/10539/20377

Dreyer, C. J., Gavron, G. 1962. Primary orthodontic treatment for the cleft palate patient. Journal of the dental association of South Africa; 17(4):113-119

Downloaded from a DSpace repository. https://dspace.org/

DIE TYDSKRIF VAN DIE T.V.S.A.

THE Journal OF THE D.A.S.A.

DIE Tydskrif VAN DIE T.V.S.A.

APRIL, 1962.
Vol. 17. No. 4.

PRIMARY ORTHODONTIC TREATMENT FOR THE CLEFT PALATE PATIENT

C. J. DREYER

Joint Dental Research Unit of the Council for Scientific and Industrial Research and the University of the Witwatersrand, Johannesburg

G. GAVRON

Orthodontic Department, University of the Witwatersrand, Johannesburg

AVAILABLE statistics indicate that the incidence of cleft palate is rising. The greatest increase is reported by Schlegel (1960) who compared the results of the incidence of cleft palate between 1937 and 1947 with the comparable data of the 1947 to 1957 period. In the former period the incidence per 100 births was 0·14 while the latter period showed an increase to 0·56 per 100 births. The magnitude of the cleft palate problem in South Africa is unknown but, calculated on a most conservative estimate of 0·1 per 100 births, one could expect 80 European infants to be born per year in South Africa with this congenital deformity. A comparable analysis of the non-White population is omitted as the results could be misleading. However, one can expect an increased percentage of non-White infants born with cleft palate to survive because of the improvement in the maternity services available to the non-European as well as the now more enlightened approach of the non-European population to all congenital deformities.

Congenital abnormalities are not necessarily confined to a specific tissue or organ, hence the individual with a cleft palate may also be inflicted with various other defects. Some of these associated abnormalities have been described by Moss (1957), Subtelny (1955) and Pruzansky (1960). Many of these defects must adversely affect the growth of the skull and jaws and thus the prognosis of a particular case. However, the authors believe that the primary aim in the majority of cases should be the restoration of maxillary arch form.

This paper will be confined to unilateral and bilateral clefts involving both the lip and the palate.

Relationship of the Arches at Birth

From the orthodontic point of view, the most striking feature to be seen in an infant born with a complete unilateral or bilateral cleft palate and lip is the malrelationship of the separated segments of the maxillary arch.

In unilateral clefts the larger segment of the upper arch is most prominent in the premaxillary area where it usually can be seen bulging through between the two sections of the cleft lip. The smaller segment on the other hand is usually placed posteriorly, and tilted towards the midline, so that the arch is narrower anteriorly (Fig. 1). However, in some cases this seg-

ment may be in good lateral position with a uniformly wide palatal cleft. This variation in arch width may be due to the position and activity of the tongue.

Similarly the position of the two lateral segments of the upper arch in bilateral clefts is not constant. Their anterior extremities may vary in position from wide separation to complete apposition in the mid-line (Fig. 1).

A detailed description and classification of both unilateral and bilateral cleft palates has been described by Pruzansky (1953) and Nordin (1960).

ORTHODONTIC TREATMENT

Orthodontic treatment of a patient with a cleft palate may be initiated either prior to the first lip repair McNeil (1954), Derichsweiler (1958) and Burston (1959), or at any age after the first surgical repair. The latter group which, with certain exceptions, requires routine orthodontic treatment, will not be discussed.

Essentially the early treatment which is based on the work of McNeil (1954) consists of fitting appliances of acrylic which partially close the defect between the nose and mouth. The appliance is held in position by stainless steel wires attached by means of elastic bands to a specially made headcap (Fig. 2). The pressure exerted on the appliance by the elastics and by the muscles during sucking and deglutition tends to mould the deformed maxillary segments into a more favourable anatomical relationship. The pressure utilized to mould one segment is derived from the other segment or segments, thus balancing the movements in opposite directions. These appliances are constructed on a series of modified plaster models of the infant's upper jaw.

Upper and lower impressions in composition are taken as soon as possible after birth. Standard small dental impression trays can be modified or special acrylic trays may be constructed. In addition to the composite upper impression a separate impression is taken of the premaxilla and prolabium in the case of the bilateral cleft. Careful moulding of the soft composition over the latter structures with the fingers usually suffices to produce an adequate impression. At the same time a careful note is made of the relationship of the lower arch to the upper, having in mind that in the first few weeks after birth the mandible is often distally placed. This will tend to make the upper arch appear wider than it actually is in relation to the lower arch.

The upper plaster model should be well trimmed with a flat base and sides.

UNILATERAL CLEFTS

The upper model of the unilateral cleft is divided by one or two cuts with a fine fret-saw (Fig. 3). These parts are then repositioned on a flat surface and plaster carefully cut away where necessary in order to allow for the estimated repositioning. The desired alterations usually include a reduction of the prominence of the premaxillary segment and rotation or antero-lateral movement of the lesser segment (Figs. 3 and 4). Occasionally in cases where the tongue is habitually placed in the cleft one may even find it necessary to constrict the arch. The actual amount of correction at any one time is a matter of clinical judgment. On the average about 2 to 3 mms. alteration in position is made.

FIG. 1.—These models of patients taken from different age groups illustrate a normal arch form, typical appearance of a complete unilateral cleft and two different examples of complete bilateral clefts.

FIG. 2.—Lateral view of four month old patient with a bilateral cleft demonstrating the attachment of the appliance to the head-cap.

FIG. 3.—A model of a unilateral cleft showing the y-shaped saw-cuts dividing it into three sections.

FIG. 4.—The same model as shown in Fig. 3 demonstrating the repositioning of the segments prior to the construction of the appliance.

FIG. 5.—The completed appliance for a unilateral cleft palate.

FIG. 6.—Appliance used to treat a bilateral cleft. The asymmetry of the position of the premaxillary cup in this instance is a reflection of the anterolateral displacement of the premaxilla in relation to the lateral segments of the maxilla.

FIG. 7.—The models of a unilateral cleft taken before, during and after active orthodontic treatment. Orthodontic treatment was completed in fifty days and the final model was taken twenty-two days after the first lip repair.

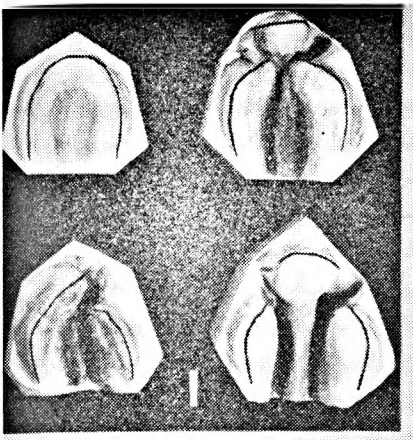



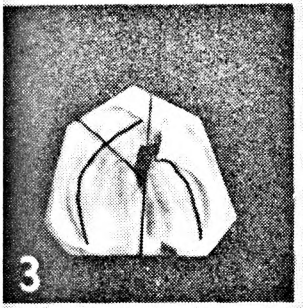



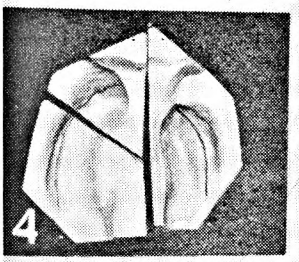

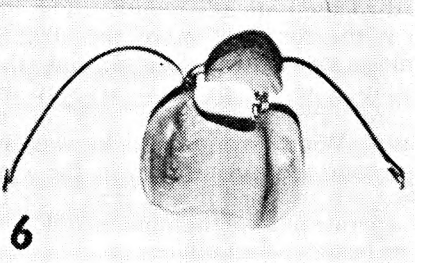

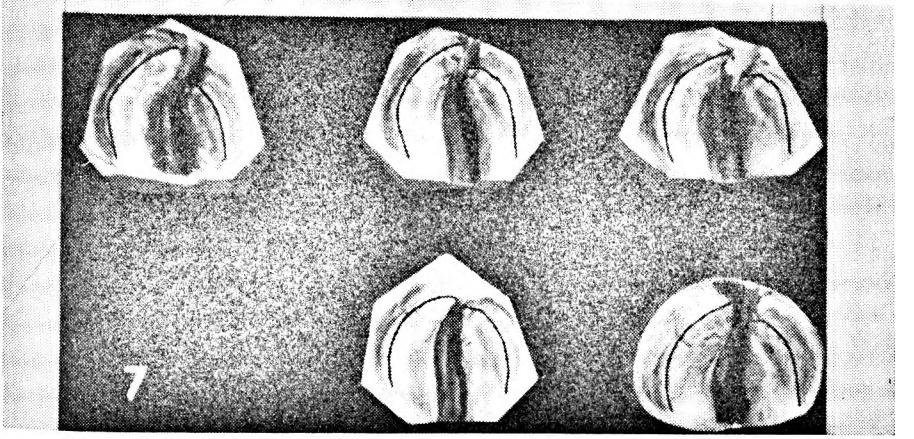

Wax is now poured into the slits to join the segments, to fill in the cleft area and any gross undercuts. It is an advantage to have a slight undercut in relation to the larger segment anteriorly in unilateral clefts which will improve the stability of the appliance. The two extra-oral arms, each about 6 in. long, are constructed of ·036 in. stainless steel wire. They are positioned on the model and the appliance is made of self curing acrylic. The appliance should not be bulky and any nodules or rough areas on the fitting surface must be carefully removed (Fig. 5).

BILATERAL CLEFTS

The preparation of the models and subsequent construction of the appliance for bilateral cleft patients is similar to that described for the unilateral cleft except where the premaxilla is markedly displaced. In such patients the posterior segments are still aligned and the appliance constructed as previously described, but a separate acrylic cup is made to cover the entire prolabium and as much of the premaxilla as possible without extension into undercut areas.

The still separate intraoral appliance and premaxillary cup are fitted and adjusted to the patient's mouth. The next step is the construction of the ·022 in. stainless steel clock springs and their adaptation to the premaxillary cup and intraoral appliance while still in the mouth. With the aid of sticky wax and subsequent self curing acrylic the clock springs are attached to and thus unite the two separate parts of the appliance (Fig. 6).

The headcap for unilateral and bilateral clefts is made either of tube gauze or preferably tape. The gauze is more readily adapted to the infant's head but it has the disadvantage of not retaining its shape. The hooks for the elastic bands are attached to the headcap just in front of the ears (Fig. 2). The retaining wires are cut to the appropriate length and the ends bent down to form a hook. Elastic bands of the correct size are fitted from the hooks on the wires to those on the headcap. Only slight tension is needed to hold the appliance in position. A denture powder may also be used as it aids retention of the appliance, and the jelly-like consistency also has a cushioning effect and thus helps to prevent irritation and ulceration. The latter, however, is not a common occurrence. To overcome the dryness of the lips and protruding premaxilla petroleum jelly should be used freely.

In the case of the bilateral cleft the clock springs are only activated after the infant has worn the appliance for twenty-four to forty-eight hours. To achieve optimum results new appliances are made every three to five weeks for unilateral clefts and less frequently for bilateral clefts. Apart from the co-operation of the parent and nursing staff, factors such as age at which treatment is started and health of the child will modify the end result.

The first phase of the orthodontic treatment which precedes the lip repair is usually completed by the third to fifth month. Some of the results obtained by this form of therapy can be seen in Figs. 7, 8.

DISCUSSION

The change to early orthodontic treatment has been prompted by a better understanding of the growth and rates of growth of the head, the relationship between function and growth, the aid to the plastic surgeon, simplification of the feeding problem and lastly the possible effects on speech.

GROWTH AND DEVELOPMENT

The importance of the cartilaginous nasal septum in the growth of the nasomaxillary complex has been stressed by Scott (1958).

In bilateral clefts the nasal septum with the premaxilla attached anteriorly is isolated from the restraining influence of the surrounding hard and soft tissues resulting in uninhibited growth and prominence of this structure. The lateral segments of the maxilla which would normally be carried forward in unison with the nasal septum are denied this stimulus and are thus left behind.

The nasal septum being attached to the larger segment in unilateral clefts explains the deformity resulting in these cases.

If the malrelationship of the arches is attributed to degrees of uninhibited growth of the nasal septum, then the earlier its

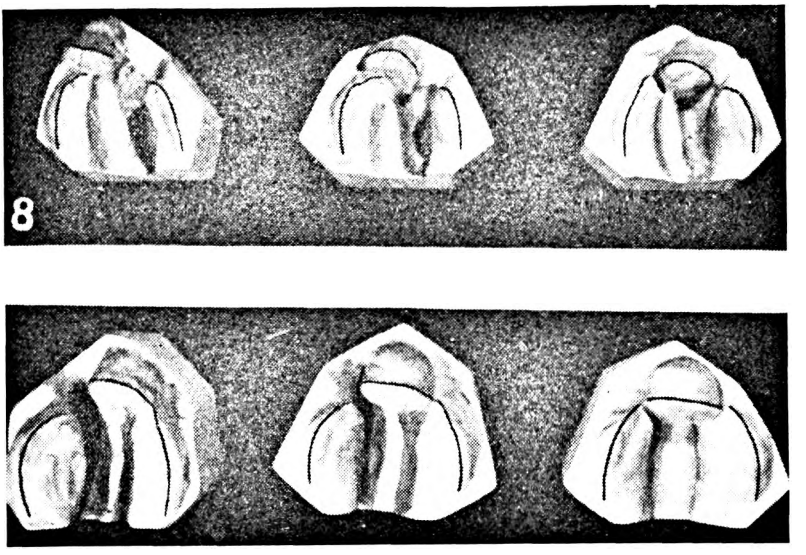

FIG. 8.—The original, progress and final models of two patients with bilateral cleft palates showing different types of displacement of the premaxilla. Treatment for the one patient (upper models) was completed in 90 days and the other in 56 days.

growth is made to influence the maxillary segments the better. It is obvious that a loosley fitting appliance cannot be used to transmit the antero-inferior force of the nasal septum to the maxillary segments. At present we only attempt to utilize the force exerted by the nasal septum in an anterior direction. Thus the appliance converts the anterior force with which the premaxillary segment is thrust forward by the nasal cartilage into a force which encourages a forward growth of the maxillary segments.

The rapid results achieved in some cases may be an indication of septal deviation rather than forward growth of the maxillary segments. The effects of such septal deviation on subsequent maxillary growth are debatable but the immediate and long-term advantages seem to outweigh any possible disadvantages.

The neo-natal pause is that period during which the infant does not show any gain in weight. This may be interpreted as a stage of temporary cessation of growth during which time no advantage could be gained by active treatment. Our observations do not support this hypothesis.

Definite changes are to be seen in the relationship of the separate segments of the maxillary arch during the neo-natal pause. Thus growth may play a part in the favourable response to treatment achieved during this phase of the infant's life.

FUNCTION AND GROWTH

Many authors have expressed their views on this subject. Much of the controversy seems to have arisen as a result of the nature of the relationship between function and growth. Thus Walkoff's statement (see Brash 1956) that function does influence bone growth may well be just as correct as Murray (1936) who is of the opinion that no relationship exists between function and the first production of form. Functional stimuli cannot alter the genetic pattern but may favourably affect the growth of the tissue bone and hence the gross morphological pattern of a bone which can vary widely within the limits of its inherited pattern. However, even if the alignment of the segments and consequent establishment of better function has no beneficial effects on the growth and development of the mid-face then in most cases early repositioning of the segments is still justified for another reason related to function. One or both maxillary segments often are so collapsed that they become contained within the lower arch during function, the maxillary arch therefore becoming progressively more

distorted with the added complication of lateral deviations of the mandible.

PLASTIC SURGERY

A close relationship exists between the soft and hard tissues of the face. The maxillary segments influence the position and thus the appearance of both the lips and nose; on the other hand maxillary arch form itself is affected by the orofacial musculature. This inter-relationship thus indicates that the final aesthetic result of the surgical treatment of the cleft lip and palate is in part dependent on arch form while arch form could in turn be affected by the surgical restoration of the continuity of the lips. The obvious question which follows is whether a repaired lip will not have the same or better effect than the mechanical treatment advocated.

There is no doubt that the restoration of the upper lip will have a restraining influence on the nasal septum and its attached premaxilla and in some selected cases may dispose of mechanical means of repositioning the premaxilla. The appliance therapy, however, has other advantages: First, as discussed under growth and development, it is important to institute treatment as early as possible and appliance therapy in contrast to surgery is more easily started within the first 24 hours after birth. Secondly, where the premaxilla with its attached prolabium is markedly displaced either anteriorly or laterally, extensive undermining may be needed to bring the lips into apposition with the prolabium. The resultant effects on the vascularity of the maxillary segments may be detrimental and the repair itself is often jeopardized by the tension on the lips.

Thirdly, the repair of the lip does not have any apparent corrective effect on collapsed maxillary buccal segments which often hinder or even prevent the repositioning of the premaxilla in spite of the posterior force exerted by the lips on the premaxilla.

Fourthly, a surgical repair of the soft tissues on a malaligned bony base may necessitate further operative procedures if and when the maxillary segments are corrected. It has been noted that a marked improvement in the alae of the nose often follows the establishment of good maxillary arch form.

THE FEEDING PROBLEM

The appliance which is used for repositioning of the maxillary segments also simplifies the feeding problem. It enables the infants to suck from a bottle with a normal teat with little milk finding its way into the nose. In some cases where the treatment is started later, with the baby having made little progress up to that time, the increase in the child's weight and improved general health is often marked. The incidence of upper respiratory disease is high in cleft palate patients and although no direct proof can be given, it seems as if these complications are reduced in those patients who have this form of appliance therapy.

SPEECH THERAPY

Recently it has been pointed out by McMahon (1961) that the abnormal swallowing pattern which the baby with a palatal cleft is forced to adopt may alter the nervous pathways to the muscles which are common to speech and deglutition. The resulting muscular patterns may play a part in the maintenance of the typical abnormal speech in some cases in spite of subsequent adequate surgical treatment.

Very early treatment which may assist deglutition could thus later also favourably affect the speech problem.

CONCLUSIONS

For the reasons enumerated, orthodontic treatment has been instituted as soon as an infant with a cleft palate has been referred to the orthodontic department. During 1961, 51 new patients were admitted to the cleft palate section of the orthodontic department, of which 21 were less than one year old.

This form of treatment has only been employed at this university during the past two years and it is therefore not yet possible to assess the long-term effects, but the advantages gained from the results achieved by early orthodontic treatment have been most encouraging and warrant continuation.

ACKNOWLEDGMENTS

We wish to thank Mr. J. B. Cuthbert and Mr. D. H. Walker of the Plastic Surgery Unit of the Johannesburg General Hospital for their co-operation which enabled us to undertake this treat-

ment; Professor J. Staz, the Director of the Oral and Dental Hospital, for allowing us the use of the hospital facilities; and Mrs. A. Vorster for the illustrations.

REFERENCES

BRASH, J. C., MCKEAG, H. T. A., and SCOTT, J. H. "The aetiology of irregularity and malocclusion of the teeth." Dental Board of the United Kingdom, London. 1956.

BURSTON, W. R. "The development of cleft lip and palate". Ann. Royal College of Surgeons, **25,** p. 225, 1959.

DERICHSWEILER, H. "Some observations on the early treatment of hare lip and cleft palate cases." Trans. of the European Orth. Soc., p. 237, 1958.

MCMAHON, E. M. "Speech patterns with special reference to cleft palates." Aus. Dent. J., **6,** No. 2, p. 101, 1961.

MCNEIL, C. K. "Oral and facial deformity." Pitman, London, 1954.

Moss, M. L. "Premature Synostosis of the frontal suture in cleft palate skull." Plast. and Reconstr. Surg., **20,** No. 3, p. 199, 1957.

MURRAY, P. D. F. "Bones". Cambridge University Press, 1936.

NORDIN, K. E. "Early jaw orthopaedics in the cleft palate programme as a new orthopaedic-surgical procedure." Trans. European Ortho. Soc., p. 150, 1960.

PRUZANSKY, S. Description, classification and analysis of unoperated clefts of lip and palate. Am. J. Orth., **39,** p. 590, 1953.

PRUZANSKY, S. "The contribution of roentgenographic cephalometry to the study of congenital and acquired malformations of the face." Dent. Clin. of North America, p. 395, July, 1960.

SCHLEGEL, D. "Surgical repair of facial clefts in Germany." Zbb. Chir., p. 489, 1960.

SCOTT, J. H. "The growth of the human skull." J. Dent. Ass. S.A., **13,** p. 133, 1958.

SUBTELNY, J. "Width of nasopharynx and related anatomic structures in normal and unoperated clefts of lip and palate. Am. J. Orth., **39,** p. 950, 1955.

ORAL MANIFESTATIONS OF SYSTEMIC DISEASES IN CHILDREN

(Being the substance of a lecture given to the Natal Branch of the Dental Association of South Africa)

CLIFFORD GLYNN WILLIAMS, M.R.C.S. (ENG.), L.R.C.P. (LOND.), M.R.C.P. (EDIN.) F.R.F.P.S. (GLAS.), D.C.H. (ENG.)

Senior Pediatrician, Edendale Hospital, Pietermaritzburg, in association with

JOSEPH RYAN, L.R.C.P. AND S. (EDIN.), L.R.F.P.S., H.D.D., L.D.S. (GLAS.)

THE object behind this lecture is two-fold: first, it is hoped that it will bring about a closer co-operation and liaison between our allied professions; and secondly that it will stimulate the dental profession to look upon the oral cavity as something more than an opening that contains the teeth. If looked for, many varied and interesting lesions which are manifestations of systemic diseases are to be found there; and we can be sure that any doctor (physician) who has the welfare of his child patient at heart would appreciate it if the dentist concerned were to contact him accordingly on discovering such lesions. A recent experience will serve to confirm this view:

A native child, aged five years, was seen by one of us (C.G.W.) because he was bleeding from the gums. On examination there was no local evidence of infection, and because malnutrition with its associated liver steatosis is so prevalent among these children the diagnosis of hypoprothrombinaemia was considered the most likely cause and Vitamin K was accordingly prescribed. Although scurvy must be extremely rare in the Bantu child the sponginess of the gums also suggested this possibility, but this was excluded on X-raying the long bones. The following morning he was brought back as he was still bleeding and anaemic, and so he was referred to the Dental Clinic for an opinion. Within a few minutes the dentist approached me and suggested that the