

https://dspace.org/

The behaviour and morphology of human oesophageal carcinoma cells in vivo and in vitro and a comparison with the normal.

Robinson, Kathleen Mary

2015
http://hdl.handle.net/10539/19215

Downloaded from a DSpace repository. https://dspace.org/

TABLE 20 (cont.)

Mouse Number	Cell line inoculated	Differentiation of human cell line	Sex of mouse	Age of mouse when inoculated	Latency period	Age of mouse when tumour removed	Differentiation of mouse tumour	Tumour information
M 13	B 5	poor	M	2 months	$2\frac{1}{2}$ months	6 months	well	+
M 14	13.M1	well	M	6 weeks	6 weeks	$4\frac{1}{2}$ months	moderate	+
M 15	Hcu 35	well	F	6 weeks	3 months	4 months	moderate	+
M 16	Hcu 35	well	M	1 month	2 months	4 months	moderate	+
M 17	13.M1	well	M	2 months	2 months	6 months	well	–
M 18	Hcu 35	well	M	1 month	2 months	4 months	well	–
M 19	13.M7	well	M	$1\frac{1}{2}$ months	3 weeks	3 months	well	–
M 20	13.M5	moderate	F	2 months	2 months	5 months	moderate	+
M 21	Hcu 33	well	F	2 months	2 months	6 months	well	–
M 22	13.M5	moderate	M	2 months	2 months	$7\frac{1}{2}$ months	well	+
M 23	Hcu 33	well	M	2 months	2 months	$5\frac{1}{2}$ months	well	–
M 24	Hcu 18	poor	F	$2\frac{1}{2}$ months	2 months	6 months	well	+
M 25	Hcu 18	poor	F	$2\frac{1}{2}$ months	2 months	6 months	well	–
M 26	Hcu 39	poor	F	2 months	3 months	$6\frac{1}{2}$ months	well	–
M 27	B 5	poor	M	2 months	$4\frac{1}{2}$ months	8 months	well	–

TABLE 28 (cont.)

Mouse Number	Cell line inoculated	Differentiation of human cell line	Sex of mouse	Age of mouse when inoculated	Latency period	Age of mouse when tumour removed	Differentiation of mouse tumour	Tumour infiltration
M 28	Hcu 33	well	F	2 months	$2\frac{1}{2}$ months	$8\frac{1}{2}$ months	moderate	-
M 29	Hcu 33	well	M	2 months	3 months	$8\frac{1}{2}$ months	well	-
M 30	B 17	moderate	F	6 weeks	$2\frac{1}{2}$ months	4 months	moderate	-
M 31	B 5	poor	F	2 months	$8\frac{1}{2}$ months	$11\frac{1}{2}$ months	well	-
M 32	Hcu 18	poor	F	$2\frac{1}{2}$ months	4 months	$7\frac{1}{2}$ months	well	+
M 33	Hcu 10	poor	M	6 weeks	2 months	$4\frac{1}{2}$ months	moderate	-
M 34	13.M5	moderate	F	2 months	5 months	9 months	well	-
M 35	B 17	moderate	M	4 weeks	4 months	8 months	poor	+
M 36	B 17	moderate	M	4 weeks	4 months	7 months	poor	-
M 37	B 17	moderate	M	4 weeks	4 months	7 months	poor	-
M 38	Hcu 10	poor	F	4 weeks	$6\frac{1}{2}$ months	9 months	poor	+
X 1	Hcu 18	poor	M	6 weeks	$4\frac{1}{2}$ months	6 months	poor	+ ✓

✓ metastatic tumour



Fig. 98 Large, lobulated suprascapular tumour infiltrating adjacent tissues in M 24 which was inoculated with Hcu 18 cells.

and bony tissue was noted, and, in several instances, movement of the upper limbs was impaired as a result of extensive tissue growth. In two animals [M 6 and M 7] inoculated with the cells of the line Hcu 13, the tumour invaded the spinal cord, causing compression and paralysis. Invasion of underlying tissues occurred more frequently than epidermal invasion and tumour infiltration into the skin was only detected in four animals. In M 11 both an encapsulated, mobile tumour and a fixed skin nodule developed, thus two different tumours developed in a single animal at very similar sites. There was no obvious correlation between any property of the cells inoculated or the human tumour of origin and invasion of the surrounding tissues.

Skin ulceration was never observed even in those tumours which infiltrated the epidermis. Ulceration was further prevented as all tumours were removed one to three months after their initial appearance, before they reached a diameter of three cm and so formed

which appeared to incapacitate the animal were removed earlier. Four tumours, resulting from the inoculation of cells from the lines 13.M5 and B 5 showed a rapid increase in size, accumulated fluid and stretched the overlying skin (Fig. 99). Such areas were inflamed and tender.



Fig. 99 Large cystic tumour stretching the overlying skin in M 11 which was inoculated with B 5 cells.

17. 4. 1 Bilateral tumours

In the three mice inoculated bilaterally the tumours resulting from the inoculation of Hcu 13 cells and Hcu 10 cells differed. In all three animals, the tumours on the right hand side, induced by the inoculation of cells from the line Hcu 13, grew more rapidly than those on the left side where cells from Hcu 10 had been injected. In M 3 the tumour initiated from Hcu 13 cells was fixed and infiltrating while the tumour on the left side was freely mobile (Fig. 100). The opposite occurred in M 4 where the tumour derived from the Hcu 13 cells was fully mobile.



Fig. 100 Bilateral tumours in M 3 which was inoculated with Hcu 13 and Hcu 10 cells in the right and left supra-scapular regions respectively. The tumour induced by the inoculation of Hcu 13 cells appeared sooner and grew more rapidly.

17. 5 METASTASIS

Although 124 mice were inoculated with malignant cells from continuous lines derived from tumours which metastasized in the human host, metastasis of the resulting mouse tumour was only observed in a single animal. This mouse, designated X 1, was inoculated with cells from the poorly differentiated line Hcu 13 at the age of six weeks. Four months later the animal rapidly lost weight and became hunched, shrivelled and emaciated (Fig. 11). During the next two weeks the lymph nodes in the axillary and inguinal regions enlarged (Fig. 101) and as the animal appeared weak and in pain it was then sacrificed. No primary tumour was present at the site of inoculation and none of the litter-mates inoculated at the same time with cells from the same line showed evidence of metastasis; in fact only one other mouse in the litter of six developed a tumour.



Fig. 101 Emaciated mouse X 1 with enlarged lymph nodes containing metastatic deposits of the line Hcu 18.

17.5 TUMOUR REMOVAL

Prior to tumour removal all animals were anaesthetised (Chapter 5). Although size variation from mouse to mouse was minimal, there was a variation in response to the injection of Sagatal. Some mice required a repeat injection of a further 0,2 ml Sagatal (diluted 1 : 10 with water) before succumbing to the anaesthetic, while others died upon the introduction of the first dose of Sagatal. The time required for the anaesthetic to assert its effect varied from three to fifteen minutes.

Removal of the mobile, well encapsulated tumours was easily performed. Most of these tumours were supplied by a single vascular trunk and severing these vessels resulted in minimal bleeding. Once the tumour was removed the incision was sutured and the mouse allowed to recover. The wound healed within three to five days and scarring was minimal (Fig. 102). Many mice survived for six months or more after tumour removal without showing any adverse effects or evidence of tumour recurrence.



Fig. 102 Mouse 21 five days after the removal of a large mobile tumour induced by the inoculation of HCu 33 cells. A small skin nodule resembling a wart (W.) was present anterior to the incision.

The lobulated invasive tumours were more difficult to remove and many animals were sacrificed because removal of the extensively invading tumours was a major procedure. Several tumours infiltrated through the dorsal musculature into the thoracic cavity and in two mice infiltration of the abdominal cavity also occurred. Where the tumours had infiltrated the spinal cord, death was unavoidable. Those tumours infiltrating into the skin only were more easily removed without too much damage to surrounding structures and several animals were saved.

Although several tumours were infiltrating, a capsule was present and well developed in those regions where it partially enveloped the tumour. There was no persistent correlation between the size of the tumour and tendency to infiltrate the surrounding tissues. Several rather small tumours infiltrated skin and muscle, while other larger structures remained mobile. The blood supply of the invasive tumours was more complex than that of the mobile tumours

and several vascular trunks were sometimes evident supplying the tumour tissue.

17. 7 TUMOUR RECURRENCE

Four mice from which infiltrating tumours had been removed were followed for up to six months after tumour removal, but no recurrence was noted. Scarring was minimal and the incisions healed rapidly. A further eight animals from which mobile tumours had been removed were also observed and a skin nodule which resembled a wart (Fig. 102) appeared in M 21, a mouse which had developed a tumour as a result of the inoculation of Hcu 33 cells. As this structure slowly increased in size it was removed and histopathological examination confirmed it to be a squamous carcinoma. There was no other evidence of tumour recurrence.

17. 8 HISTOPATHOLOGY OF CARCINOMAS IN THE NUDE MOUSE

All 42 tumours which developed in nude mice subsequent to the inoculation of human oesophageal carcinoma cell lines were classified as carcinomas, but varied in their degree of differentiation. Tumour differentiation ranged from poor to well and no single cell line produced tumours which were constant with respect to their degree of differentiation. There was poor correlation between differentiation of the cell lines inoculated and differentiation of the resulting tumours (Table 29), for example, of the nine tumours which resulted from the inoculation of cells from line Hcu 13, five were well differentiated, three moderately differentiated and one poorly differentiated. Lines Hcu 33 and Hcu 35 derived from well differentiated tumours, both gave rise to tumours which were moderately or well differentiated in the nude mouse, while line Hcu 18 derived from a poorly differentiated human tumour gave rise to equal numbers of poorly and well differentiated tumours (Table 29).

Inoculation of the cell lines 13.M1, 13.M5 and 13.M7 all derived from oesophageal carcinomas induced in the nude mouse presented a

TABLE 29 HISTOLOGICAL DIFFERENTIATION AND INFILTRATION OF EXPERIMENTALLY INDUCED TUMOURS IN THE NUDE MOUSE

Cell line inoculated	Number of tumours	Differentiation			Infiltration
		poor	moderate	well	
lines from poorly differentiated tumours					
Hcu 10	5	2	1	2	2
Hcu 19	4	1	0	3	2
B 5	3	0	0	3	1
lines from moderately differentiated human tumours					
Hcu 39	1	0	0	1	0
B 17	4	3	1	0	0
lines from well differentiated human tumours					
Hcu 13	9	1	3	5	5
Hcu 33	4	0	1	3	0
Hcu 35	3	0	2	1	2
lines from mouse tumours induced by inoculation of human cell lines					
13.M1	5	2	2	1	4
13.M5	3	0	1	2	3
13.M7	1	0	0	1	0

TABLE 29 HISTOLOGICAL DIFFERENTIATION AND INFILTRATION OF EXPERIMENTALLY INDUCED TUMOURS IN THE NUDE MOUSE

Cell line inoculated	Number of tumours	Differentiation			Infiltration
		poor	moderate	well	
lines from poorly differentiated tumours					
Hcu 10	5	2	1	2	2
Hcu 18	4	1	0	3	2
B 5	3	0	0	3	1
lines from moderately differentiated human tumours					
Hcu 39	1	0	0	1	0
B 17	4	3	1	0	0
lines from well differentiated human tumours					
Hcu 13	9	1	3	5	5
Hcu 33	4	0	1	3	0
Hcu 35	3	0	2	1	2
lines from mouse tumours induced by inoculation of human cell lines					
13.M1	5	2	2	1	4
13.M5	3	0	1	2	3
13.M.	1	0	0	1	0

more confusing picture with the resulting tumours showing all degrees of differentiation. In H 11, the main nodule tumour (Chapter 17. 4) was classified as poorly differentiated, the skin nodule was described as moderately differentiated, and the cells of the line of origin, 13.M1, were well differentiated.

There was no correlation between the degree of tumour differentiation and infiltration of the surrounding tissues and poorly differentiated tumours were less invasive than expected.

The large (three cm diameter) fluid containing tumours derived from lines B 5 and 13.M5 showed central areas of necrosis and cystic degeneration.

17. 8. 1 Histopathological studies on a metastatic tumour

Specimens of liver, lung, kidney, spleen and lymph nodes from the mouse X 1 were prepared for histological examination. Undifferentiated carcinoma cells were present in all of the organs examined with the exception of the lungs (Table 30).

Sections of these organs were removed from several other tumour bearing animals but no evidence of metastatic spread was noted.

17. 9 TISSUE CULTURE OF TUMOURS GROWN IN THE NUDE MOUSE

All experimentally induced carcinomas removed from nude mice and cultured using the explant technique grew well and rapidly in vitro. Outgrowths of sheets of adherent epithelial cells were evident within two to three days of culture initiation Giant cells were occasionally present at intervals between the small cells, but the overall incidence of giant cells was [illegible] cells passaged through nude mice. Fibroblast overgrowth was seldom a problem as, prior to culture initiation, every effort was made to strip the fibrous connective tissue capsules away from the tumours and the few mouse fibroblasts which grew in vitro were easily removed by trypsinisation. With the exception of Hcu 18 X 1 subculturing was always successfully performed after one to three weeks in vitro and all cell strains survived freezing and thawing

TABLE 30 TUMOUR METASTASIS IN MOUSE XI

Cell line inoculated	Age of mouse	Sex of mouse	Latency	Organ	Infiltration	Differentiation
Hcu 18	6 months	M	$4\frac{1}{2}$ months	liver	carcinoma throughout	undifferentiated
				lung	-	-
				kidney	carcinoma throughout involving capsule	undifferentiated
				spleen	carcinoma especially in subcapsular zone	undifferentiated
				lymph nodes	carcinoma involving all nodes	undifferentiated

after as little as one passage *in vitro* and performed as continuous lines. Cell cultures derived from tumours grown in athymic mice showed similar growth patterns and behaviour *in vitro* to one another and there were no striking or consistent differences between those derived from the different oesophageal carcinoma cell lines. *In vitro* growth properties of the tumours grown in the nude mice did not appear to correlate with differentiation or infiltration of the tumours.

ULTRASTRUCTURE OF HUMAN OESOPHAGEAL CARCINOMAS INDUCED IN NUDE MICE

Carcinomas induced in nude mice were examined in an attempt to elucidate the relationship between oesophageal carcinoma cells existing in the nude mouse, those in the human host and the cell lines derived from them.

TRANSMISSION ELECTRON MICROSCOPY

In vivo specimens of 34 of the 42 carcinomas induced in nude mice by the inoculation of human oesophageal carcinoma cell lines were examined by transmission electron microscopy, as were primary cultures of 25 mouse tumours. The results of these ultrastructural studies are summarised in Tables 31 to 34. All specimens growing in flasks were primary cultures, unless stated otherwise. Ultrastructural similarities and differences were noted both between tumours induced by the inoculation of the same and different oesophageal carcinoma cell lines.

Ultrastructural features indicative of tumour differentiation

All tumours consisted of epithelial cells of varying differentiation with prominent nuclei and nucleoli (Fig. 103). Cells in the well differentiated tumours contained many prominent desmosomes and abundant dense aggregates of tonofilaments, predominantly in a paranuclear position (Fig. 104) while cells in the poorly differentiated tumours generally displayed numerous profiles of rough endoplasmic reticulum and sparse tonofilaments. Although there was correlation between tumour differentiation as determined using light microscopy and tonofilament number, the tumours 18.X1 and 18.X1.M10 described histologically as poorly differentiated were exceptions and displayed abundant tonofilaments (Fig. 104).

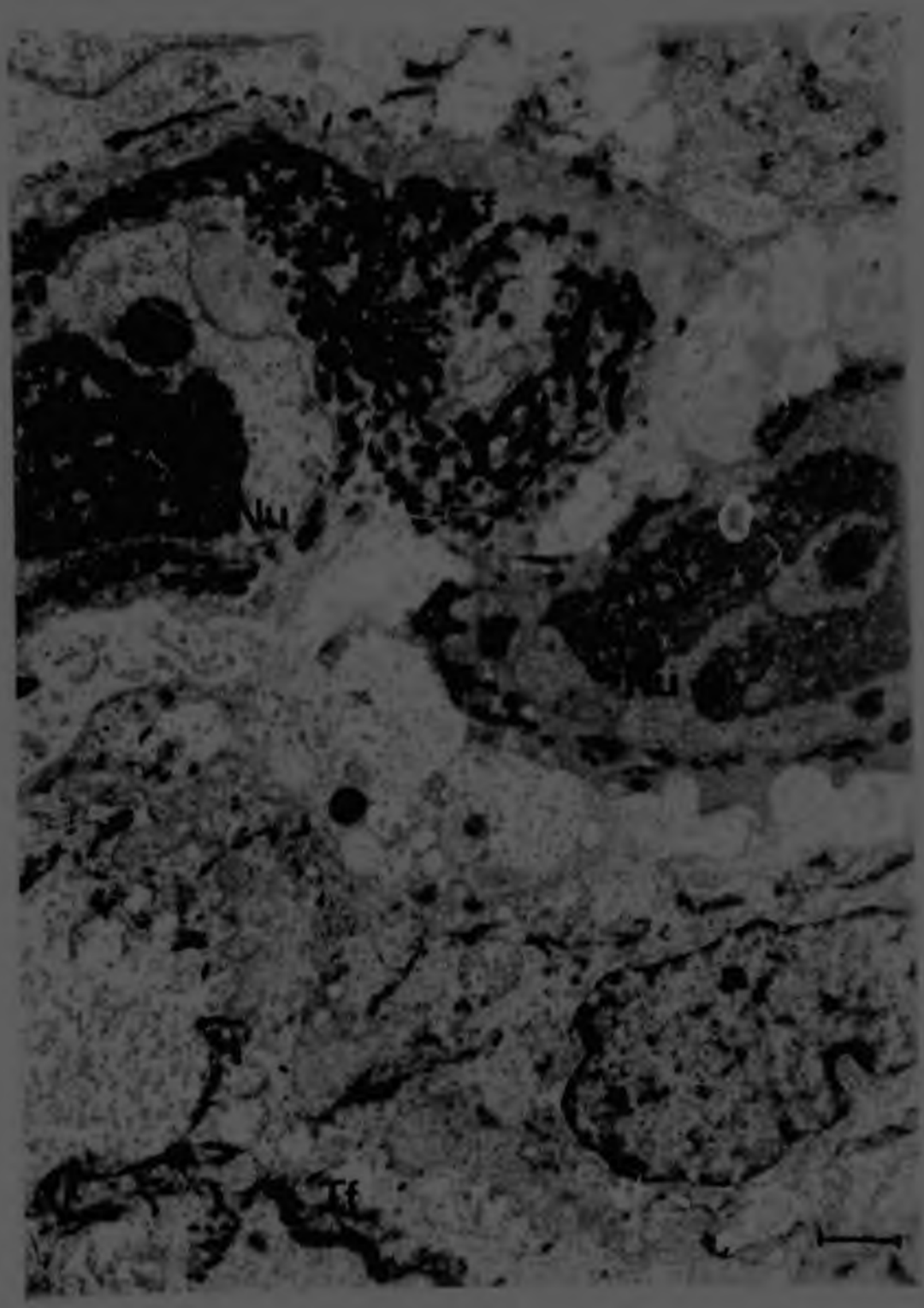

Fig. 103 Transmission electron micrograph showing light and dark carcinoma cells of the moderately differentiated tumour 13.W7. Enlarged dense nucleoli (Nu) and aggregates of paranuclear tonofilaments (Tf) are evident in the dark cells. Bar = 1 µm

TABLE II SUMMARY OF SOME OF THE ULTRASTRUCTURAL FEATURES OF NUDE MOUSE [illegible] ARISING AS A RESULT OF THE INOCULATION OF CELLS OF [illegible] DERIVED FROM POORLY DIFFERENTIATED HUMAN TUMOUR.

A INOCULATION OF [illegible] CELLS

Specimen number	Differentiation	Flask or Tumour	Tonofilaments	Desmosomes	Intranuclear particles (70-[illegible]nm)	Cytoplasmic particles (45nm)	Lipid	Glycogen	M[illegible]	Nucleoli	Other
10.M 2	poor	T	-	[illegible]	[illegible]	-	-	-	dense	not evident	few organelles
10.M [illegible]	poor	F	+	+	-	+	+	[illegible]	pale	particulate	few ribosomes
10.M 3	poor	T	+	+	-	+	-	-	dense	[illegible]	[illegible] cytoplasmic filaments, [illegible] [illegible] complex
10.M 3	poor	F	+	[illegible]	+	+	-	-	dense	dense	[illegible] abundant
10.M 4	well	T	**	**	-	-	+	+	pale	[illegible]	complex intercellular microvilli
10.M 4	well	F	no ultrastructural studies possible								
10.M 33	moderate	T	+	***	-	-	-	-	dense	dense	abundant [illegible] endoplasmic reticulum
10.M 33	moderate	F	no ultrastructural studies performed								

TABLE 31 SUMMARY OF SOME OF THE ULTRASTRUCTURAL FEATURES OF IN VITRO GROWN TUMOURS ARISING AS A RESULT OF THE INOCULATION OF CELLS OF LINES DERIVED FROM POORLY DIFFERENTIATED HUMAN TUMOURS

B INOCULATION OF NCO 10 CELLS

Specimen number	Differentiation	Flask or Tumour	Tonofilaments	Desmosomes	Intranuclear particles (20–40nm)	Cytoplasmic particles (45nm)	Lipid	Glycogen	Mitochondria	Nucleoli	Other
18.M 24	well	T	++	+	–	+	+	–	vacuolated	threadlike	dilated rough endoplasmic reticulum(RER)
18.M 24	well	F	+	+	–	–	–	+	sparse	particulate	abundant RER and annulate lamellae
18.M 25	well	T	++	++	–	–	+	–	pale	threadlike	prominent marginal bands
18.M 25	well	F	–	+	–	–	+	–	dense	dense	–
18.M 32	well	T	+++	++	–	–	+	–	dense	particulate	abundant RER
18.M 32	well	F	no ultrastructural studies performed								
18 X 1	poor	T	+++	++	–	+	+	–	dense	threadlike	–
18 X 1	poor	F	no ultrastructural studies possible								

C INOCULATION OF B 5 CELLS

Specimen number	Differentiation	Flask or Tumour	Tonofilaments	Desmosomes	Intranuclear particles (20–40nm)	Cytoplasmic particles (45nm)	Lipid	Glycogen	Mitochondria	Nucleoli	Other
85.M 13	well	T	+++	++	–	+	–	–	dense	threadlike	collagen
85.M 13	well	F	+	+	–	+	–	–	dense	particulate	annulate lamellae
85.M 31	well	T	+++	+	–	–	+	–	dense	threadlike	–
85.M 31	well	F	–	+	–	–	+	–	dense	particulate	abundant rough endoplasmic reticulum

TABLE 32 SUMMARY OF SOME OF THE ULTRASTRUCTURAL FEATURES OF [illegible] TUMOURS ARISING AS A RESULT OF THE INOCULATION OF CELLS OF LINES [illegible]

Specimen number	Differentiation	Flank or Tumour	Tonofilaments	Desmosome	Intranuclear particles (21-45nm)	Cytoplasmic particles (40-60nm)	Lipid	Glycogen	Mitochondria	Nucleoli	Other
Hcu 19 M/F	well	T	[illegible]	+	-	-		-	[illegible]	[illegible]	confronting cisternae, particulate aggregate
Hcu 19 M2F	well	F	no ultrastructural studies performed								
B 17 M 10	moderate	T	++	+	-	-	-	-	dense	thread-like	nuclear inclusions
B 17 M 10	moderate	F	++	++	-	-	-	-	dense	particulate	myelinoid figures

TABLE 33 SUMMARY OF SOME OF THE ULTRASTRUCTURAL FEATURES OF NUDE MOUSE GROWN TUMOURS ARISING AS A RESULT OF THE INOCULATION OF CELLS OF LINES DERIVED FROM WELL DIFFERENTIATED HUMAN TUMOURS.

A INOCULATION OF HCU 13 CELLS

Specimen number	Differentiation	Flask or Tumour	Tonofilaments	Desmosomes	Intranuclear particles (20–30nm)	Cytoplasmic particles (40–60nm)	Lipid	Glycogen	Mitochondria	Nucleoli	Other
13.M 1	well	T	++	++	+	+	+	+	pale swollen	threadlike	
13.M 1	well	F	++	++	+	+	–	–	dense	particulate	abundant rib[illegible]mes, well developed ++ Golgi
13.M 2	well	T	++	++	–	–	–	–	dense	dense	–
13.M 2	well	F	+	++	–	–	–	–	dense	particulate	–
13.M 3	well	T	++	+++	+	+	+	+	dense	dense	whorled RER, marginated chromatin, fine cytoplasmic filaments
13.M 3	well	F	+	+	–	+	–	–	dense	dense	well developed RER
13.M 4	well	T	++	++	–	+	–	+	pale	dense	dilated Golgi
13.M 4	well	F	+	+	+	+	–	–	dense		well developed RER
13.M 5	moderate	T	+++	+++	–	–	+	–	dense	dense	abundant RER and fine cytoplasmic filaments
13.M 5	moderate	F	+	+	–	–	–	+	dense	particulate	myelinoid bodies and fine cytoplasmic filaments

TABLE 33 SUMMARY OF SOME OF THE ULTRASTRUCTURAL FEATURES OF NUDE MOUSE GRAFT TUMOURS ARISING AS A RESULT OF THE INOCULATION OF CELLS OF LINES DERIVED FROM WELL DIFFERENTIATED HUMAN TUMOURS

A INOCULATION OF HCU 13 CELLS

Specimen number	Differentiation	Flask or Tumour	Tonofilaments	Desmosomes	Intranuclear particles (20–30nm)	Cytoplasmic particles (40–60nm)	Lipid	Glycogen	Mitochondria	Nucleoli	Other
13.M 1	well	T	++	++	+	+	+	+	pale swollen	threadlike	
13.M 1	well	F	++	++	+	+	–	–	dense	particulate	abundant ribosomes, well developed ++ Golgi
13.M 2	well	T	++	++	–	–	–	–	dense	dense	–
13.M 2	well	F	+	++	–	–	–	–	dense	particulate	–
13.M 3	well	T	++	+++	+	+	+	+	dense	dense	whorled RER, coarse-grained chromatin, fine cytoplasmic filaments
13.M 3	well	F	+	+	–	+	–	–	dense	dense	well developed RER
13.M 4	well	T	++	++	–	+	–	+	pale	dense	dilated Golgi
13.M 4	well	F	+	+	+	+	–	–	dense		well developed RER
13.M 5	moderate	T	+++	+++	–	–	+	–	dense	dense	abundant RER and fine cytoplasmic filaments
13.M 5	moderate	F	+	+	–	–	–	+	dense	particulate	myelinoid bodies and fine cytoplasmic filaments

TABLE 33 (cont.) A INOCULATION OF NEU II CELLS (cont.)

Specimen number	Differentiation	Flask or Tumour	Tonofilaments	Desmosomes	Intermediate particles (20–30nm)	Cytoplasmic particles (40–60nm)	Lipid	Glycogen	Mitochondria	Nucleoli	Other
13.M 6	well	T	++	++	+	+	–	–	pale	threadlike	–
13.M 6	well	F	++	++	+	+	–	+	pale	particulate	prominent marginal vacuole
13.M 7	moderate	T	+++	+++	+	+	–	–	vacuolated	dense	–
13.M 7	moderate	F	+	+	–	–	–	–	dense	dense	abundant RER and Golgi
13.M 8	moderate	T	+++	+++		–	+	+	vacuolated	threadlike	cytoplasmic filaments and abundant collagen
13.M 8	moderate	F	+	+	–	–	–	–	dense	dense	–
13.M 9	poor	T	+	++	–	–	+	+	vacuolated	particulate	abundant RER
13.M 9	poor	F	++	+++	–	–	+	–	dense	dense	myelinoid bodies

TABLE 33 SUMMARY OF SOME OF THE ULTRASTRUCTURAL FEATURES OF NUDE MOUSE HUMAN TUMOURS, AUTO-IN, AS A RESULT OF THE INOCULATION OF CELLS OF LINES DERIVED FROM WELL DIFFERENTIATED HUMAN TUMOURS

B INOCULATION OF HCU [illegible] CELLS

Specimen number	Differentiation	Flask or Tumour	Tonofilaments	Desmosomes	Intranuclear particles [35-[illegible]nm]	Cytoplasmic particles [[illegible]nm]	Lipid	Glycogen	Mitochondria	Nucleoli	Other
33.M 23	well	T	+++	+	-	+	+	-	pale	threadlike	nuclear inclusions
33.M 23	well	F	-	+	-	-	-	+	dense	undefined	irregular nuclei
33.M 28	moderate	T	++	++	-	-	-	-	sparse	threadlike	few organelles
33.M 28	moderate	F	-	+	-	-	-	-	sparse	particulate	autophagic vesicles
33.M 29	well	T	++	+	-	+	+	-	vacuolated	dense	nuclear inclusions
33.M 29	well	F	[illegible]	+	-	-	-	[illegible]	sparse	particulate	autophagic vesicles

C INOCULATION OF HCU [illegible] CELLS

Specimen number	Differentiation	Flask or Tumour	Tonofilaments	Desmosomes	Intranuclear particles (.[illegible]-[illegible]nm)	Cytoplasmic particles	Lipid	Glycogen	Mitochondria	Nucleoli	Other
35.M 19	moderate	T	+	+	-	-	-	-	vacuolated	threadlike	
35.M 19	moderate	F	no ultrastructural studies performed								
35.M 16	moderate	T	+	+	-	45nm	-	-	vacuolated	dense	
35.M 16	moderate	F	+	+	-	-	+	[illegible]	dense	particulate	

TABLE 34 SUMMARY OF SOME OF THE ULTRASTRUCTURAL FEATURES OF NUDE MOUSE GROWN TUMOURS ARISING AS A RESULT OF THE INOCULATION OF CELLS FROM LINES DEVELOPED FROM MOUSE TUMOURS INDUCED BY THE INOCULATION OF HUMAN OESOPHAGEAL CARCINOMA CELL LINES

A INOCULATION OF 13.M1 CELLS

Specimen number	Differentiation	Flask or Tumour	Tonofilaments	Desmosomes	Intranuclear particles (20-30nm)	Cytoplasmic particles (40-60nm)	Lipid	Glycogen	Mitochondria	Nucleoli	Other
13.M1.M10	poor	T	+++	+++	+	-	+	-	dense	threadlike	dilated RER, filamentous bodies
13.M1.M10	poor	F	++	+	+	-	-	-	dense	particulate	filamentous bodies, abundant Golgi
13.M1.M11	poor	T	+	+	+	+	+	-	dense	particulate	collagen and intracellular vesicles
13.M1.M11	poor	F	+	+	+	-	-	-	dense	particulate	myelinoid bodies
13.M1.M12	poor	T		+	-	-	-	-	dense	dense	
13.M1.M12	poor	F	-	+	-	+	-	-	dense	particulate	annulate lamellae
13.M1.M14	moderate	T	++	++	-	+	-	-	vacuolated	threadlike	-
13.M1.M14	moderate	F	++	+	+	-	-	-	dense	dense	abundant RER and Golgi

TABLE 34 SUMMARY OF SOME OF THE ULTRASTRUCTURAL FEATURES OF [illegible] TUMOURS ARISING AS A RESULT OF THE INOCULATION OF CELLS FROM LINES DEVELOPED FROM MOUSE [illegible] INDUCED BY THE [illegible] OF HUMAN CERVICOVAGINAL CARCINOMA CELL LINES

B INOCULATION OF 13.M5 AND 13.M7 CELLS

Specimen number	Differentiation	Flank or Tumour	Tonofilaments	Desmosomes	Intranuclear particles (20–30nm)	Cytoplasmic particles (40nm)	Lipid	Glycogen	Mitochondria	Nucleoli	Other
13.M5.M20	moderate	T	+++	+++	–	+	–	–	vacuolated	thread[illegible]e	
13.M5.M20	moderate	F	no ultrastructural studies performed								
13.M5.M22	well	T	+++	++	–	+	–	–	dense	threadlike	dense granules
13.M5.M22	well	F	no ultrastructural studies performed								
13.M7.M19	well	T	+	+	–	–	+	–	vacuolated	dense	dilated ER
13.M7.M19	well	F	no ultrastructural studies performed								

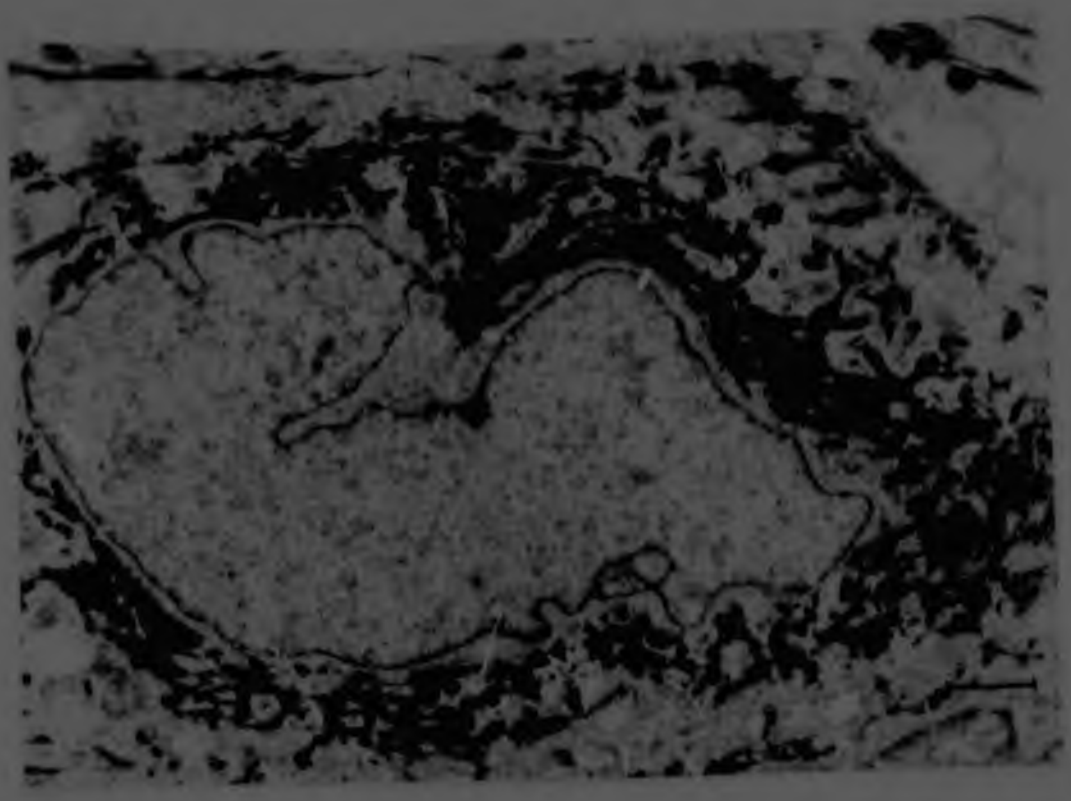

Fig. 104 Transmission electron micrograph showing a dense paranuclear aggregate of tonofilaments in a cell from the metastatic tumour 1 .X1. Bar = 1 µm

This may be related to regional differences in differentiation within the tumours. Many carcinoma cells in well differentiated nude mouse tumours were anucleate and filled with fine cytoplasmic filaments and it was often difficult to distinguish between cells which were in an advanced stage of keratinisation and those which were undergoing necrosis. Areas of necrosis were present in several of the larger and all of the cystic tumours grown in nude mice and necrotic cells were frequently observed by transmission electron microscopy (Fig. 105). Marginal band formation was not confined to necrotic cells and many cells in the well differentiated tumours were in the process of developing thickened plasma membranes (Fig. 10).

With the exception of 10.M2 and 13.M9 (Tables 31A and 33A) desmosomes were observed in all of the tumour specimens examined. Most of the observed desmosomes were in intercellular positions

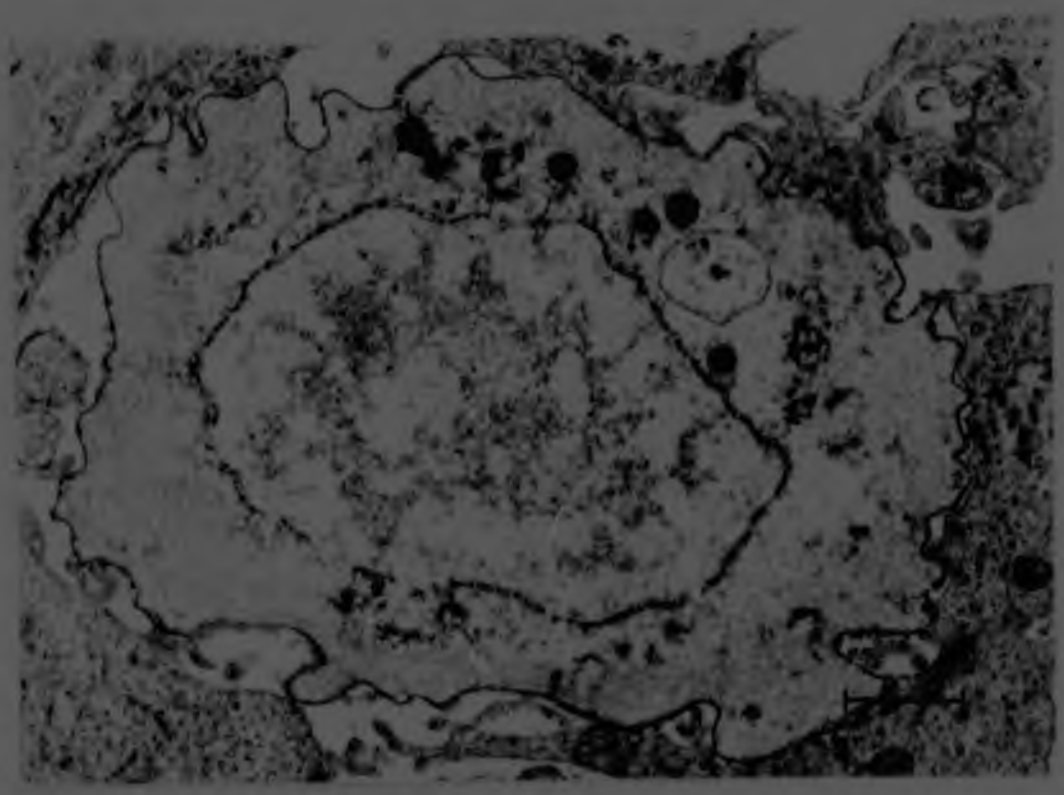

Fig. 105 Transmission electron micrograph showing portions of apparently healthy 85.M31 cells surrounding a necrotic cell which contains fine cytoplasmic filaments, a few dense bodies, but otherwise sparse organelles, and is bordered by a marginal band. Bar = 1 µm

and two internalised desmosomes were observed (Fig. 107).

When cells derived from the induced nude mouse tumours were grown in vitro some loss of differentiation was evident and desmosomes and tonofilaments were less abundant in tumour cells in vitro than in those in vivo (Tables 31 - 34). These structures did, however, persist in the cultured cells and provided some evidence of their epithelial nature.

16. 1. 8 Intranuclear particles

The distinctive 20 - 30 nm diameter intranuclear particles observed in Hcu 13 cells (Chapter 15. 2) persisted when these cells were inoculated into nude mice, this being confirmation of their association with the cell line Hcu 13. Intranuclear particles were observed in five of the tumours resulting from the



Fig. 108 Transmission electron micrograph of the thickened plasma membranes bordering well differentiated 18.M cells which are filled with filamentous material. Modified desmosomes of varying morphology are pr at intervals between the opposed membranes. Bar = 0,1 µm

inoculation of Hcu 13 cells and were present in three primar c.- tures derived from such tumours (Table 33 A). When present, intranuclear particles were prominent (Fig. 108) and the production of such particles was amplified by passage through the nude mouse as these particles were observed more frequently and in greater abundance in the nude mouse tumour cells than in Hcu 13, the line of origin. The intranuclear particles observed in primary cultures of the nude mouse tumour cells were not as numerous as th in the nude mouse tumours in vivo, though they were present in larger numbers than in the cell line Hcu 13. As well as being located within the nuclei, particles of similar size and morph were also observed lying free within the cytoplasm (Fig. 109) in some cells of 13.M s.



Fig. 107 Transmission electron micrograph showing bundles of tonofilaments in the cytoplasm of a 13.M1.M10 tumour cell which also displays both intercellular desmosomes (D) and internalised desmosomes (ID). Bar = 1 µm.

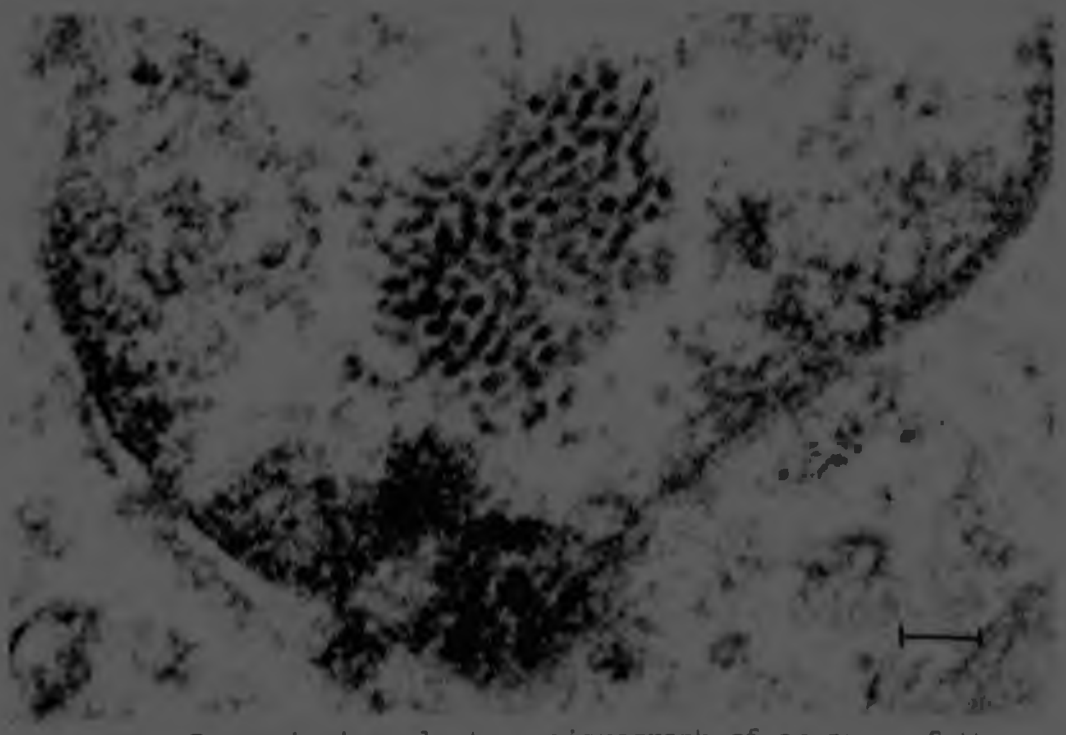

Fig. 108 Transmission electron micrograph of an area of the nucleus of a 13.M1 tumour cell which contains a cluster of 20 - 30 nm intranuclear particles. Bar = 0,1 µm

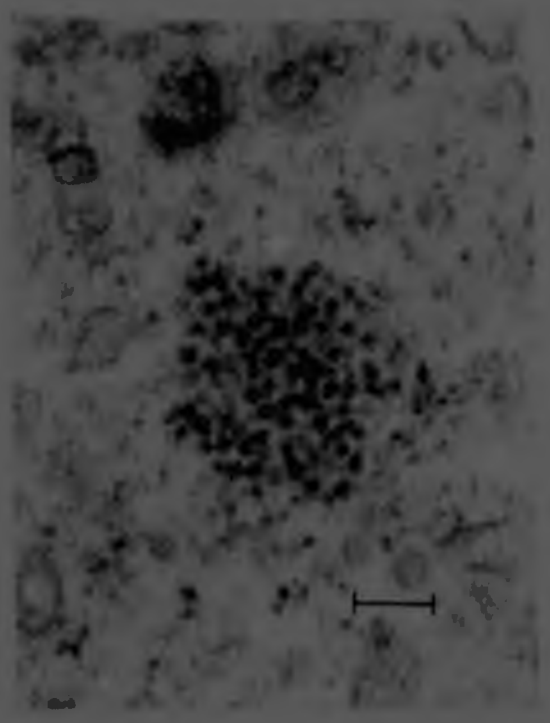

Fig. 109

Transmission electron micrograph of a cluster of 20 - 30 nm particles in the cytoplasm of a cultured 13.M3 cell. Bar = 0,1 µm

The presence of morphologically similar intranuclear particles in cells of 10.M2 in vivo and 10.M3 in vitro (Table 31A) was unexpected since such particles had not been observed in Hcu 10, the cell line of origin. However, the tumours 10.M2 and 10.M3 were grown in mice bearing tumours 13.M2 and 13.M3 and the intranuclear particles present in the Hcu 13 cells introduced into the mice may have been transmitted to the carcinoma cells forming the tumours which resulted from the inoculation of Hcu 10 cells.

18. 1. 3 Cytoplasmic particles

Cytoplasmic particles of varying size and morphology (Fig. 110) were observed in cells of many of the nude mouse tumours and in primary cultures derived from these tumours (Tables 31 - 34). Many of these particles were of diameter 40 - 60 nm and resembled membrane coating granules in possessing dense material surrounded by a clear halo and then a membrane. These particles were more prominent and better developed in tumours in vivo than in primary cultures.

Clearly defined 8 - 14 nm cytoplasmic rods were present in some



Fig. 110

Transmission electron micrograph showing granules (G) of varying size and density in the cytoplasm of a cultured 13.M5 cell. Bar = 1 μm

cells of 10.M3 (Table 31A) and resembled those described in Chapter 15.

Structures resembling mycoplasmas were also observed within the cytoplasm of some tumour cells from nude mice (Fig. 111). These structures were strikingly similar to those presumed to be ingested mycoplasmas in normal human oesophageal cells (Chapter 12. 2).

18. 1. 4 Other cytoplasmic organelles

The distribution of glycogen and lipid material varied in all of the nude mouse tumour specimens and their subcultures which were examined (Tables 31 - 34). No correlation between presence of lipid and glycogen was noted and the presence of aggregates of such material did not correlate with tumour differentiation, infiltration or cellular degeneration.

Many of the carcinoma cells in the nude mouse grown tumours possessed vacuolated mitochondria, while cells in primary cultures revealed small dense mitochondria (Tables 31 - 34). Such differences may reflect poor fixation of tumour specimens (Ghadially,

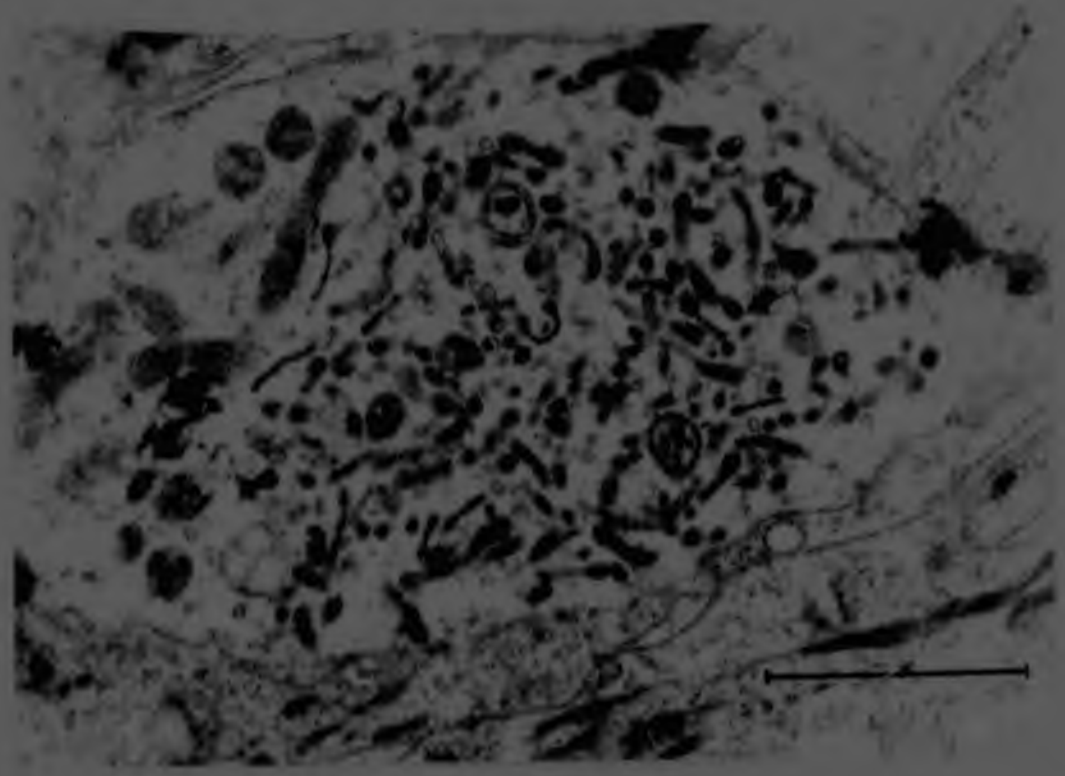

Fig. 111 Transmission electron micrograph revealing rod-like structures which resemble mycoplasmas in the cytoplasm of a 13.M7 cell *in vivo* in the nude mouse. Bar = 1 μm

1980) or be related to osmotic modifications and different metabolic requirements of the tumour cells *in vivo* and *in vitro*. The mitochondria in cells of the primary cultures resembled those in the cell lines of origin (Chapter 15) while those in the mouse tumours *in situ* resembled those in human tumours (Chapter 13. 2).

Dense aggregates of free ribosomes were present in many of the tumours and several cells displayed abundant well-developed endoplasmic reticulum which was frequently dilated (Tables 31 to 34). In the tumour 13.M3 the rough endoplasmic reticulum was arranged in whorls (Fig. 112) which bore some resemblance to the granular whorled bodies described in Chapter 13. 2. 5.

The golgi apparatus was active and well developed in many of the tumour cells (particularly those in poorly differentiated tumours) examined. Confronting cisternae, annulate lamellae and



Fig. 112 Transmission electron micrograph showing whorls (W) of endoplasmic reticulum with associated ribosomes in a 13.M3 cell *in vivo*. Such structures occurred typically in close proximity to lipid droplets (L).
Bar = 1 µm

a variety of myelinoid bodies and autophagic vesicles were also observed in many of the nude mouse tumour cells (Tables 31 to 34). Thus, most of the organelles observed in the oesophageal carcinoma cell lines and tumours of origin were also present in the tumours induced in the nude mice. With the exception of tonofilaments and desmosomes all cytoplasmic organelles were better developed in mouse tumour cells *in vivo* than in corresponding cells *in vitro*.

Fine filamentous aggregates were encountered in several tumours, particularly those which arose as a result of the inoculation of Hcu 13 cells (Table 33A). Such filamentous bundles which resembled those present in T22 (Chapter 13. 2. 4) frequently occupied large areas of cytoplasm (Fig. 113) and differed in density from tonofilaments.



Fig. 113 Transmission electron micrograph depicting the aggregates of fine filaments (F) which occupied large areas of the cytoplasm of 13.3 cells *in vivo*. Bar = 1 μm

18. 1. 5 Invasive tumours

Several of the carcinomas induced in the nude mouse were incompletely encapsulated and infiltrated other tissues (Chapter 17). Ultrastructural evidence for such invasion is given in Fig. 114 where the encroachment of a malignant cell on an area of striated muscle can be recognised.

Although some of the tumours examined were incompletely encapsulated, there was a close association between malignant cells and collagen fibres. Aggregates of collagen fibrils of mouse origin which may represent a host defence mechanism were frequently present in the intercellular spaces between carcinoma cells (Fig. 115.)

In summary tumours induced in nude mice by the inoculation of continuous human oesophageal carcinoma cell lines showed ultrastructural and some behavioural similarities to the cell lines

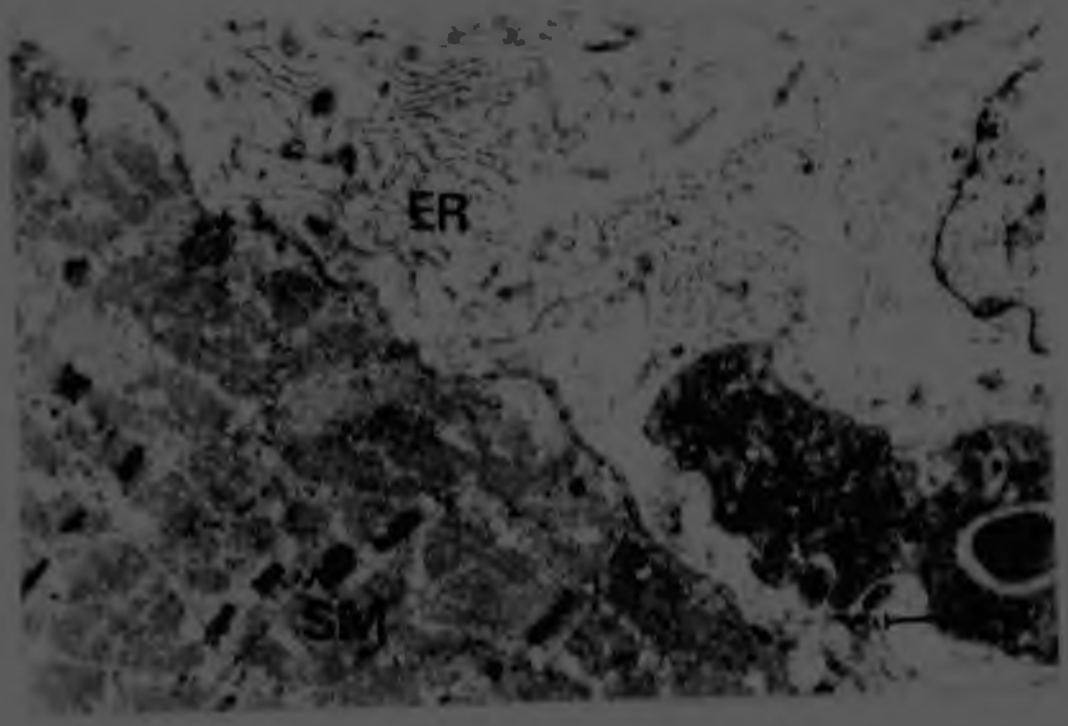

Fig. 114 Transmission electron micrograph of an area where an induced carcinoma is invading adjacent muscle in situ in the nude mouse. A poorly differentiated 13.M9 cell containing dilated rough endoplasmic reticulum (ER) lies adjacent to a striated muscle fibre (SM) with clearly defined myofilaments. Bar = 1 µm

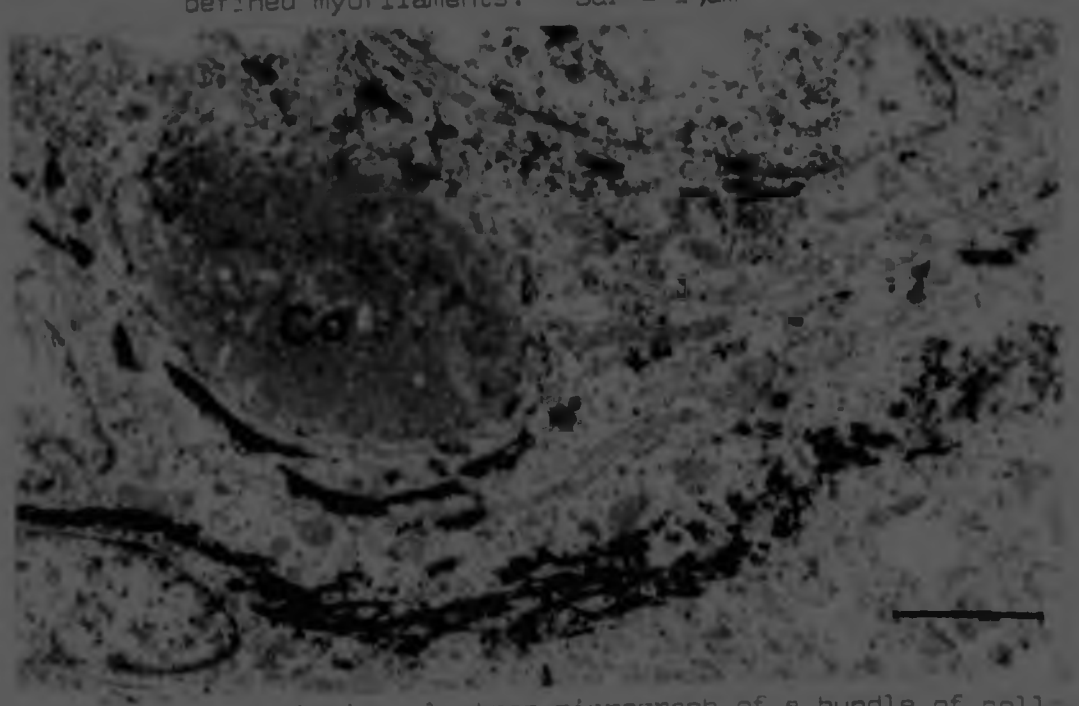

Fig. 115 Transmission electron micrograph of a bundle of collagen fibres (Co) which is surrounded by moderately differentiated 13.[illegible] cells in vivo. Bar = 1 µm

and oesophageal carcinomas from which they originated. Most tumours displayed differentiated epithelial features such as tonofilaments and desmosomes and features such as intranuclear particles which characterised certain cell lines persisted in the tumours in nude mice and in cultures derived from them.

18. 2 SCANNING ELECTRON MICROSCOPY

As cell surface changes may occur when cells are grown in an altered environment scanning electron microscopy can yield information about changes which occur when cells of cell lines derived from human oesophageal carcinomas are inoculated into nude mice.

18. 2. 1 Nude mouse tumours in vivo

As the surfaces of oesophageal carcinomas induced in nude mice were enveloped by a well developed branching network of collagen and reticular fibres (Fig. 116) no natural cancer cell surfaces



Fig. 116 Scanning electron micrograph showing the collagen (Co) and branching reticular fibres which comprise the capsule around a mobile carcinoma in a nude mouse.
Bar = 10 μm

were evident and little ultrastructural detail could be resolved. Surface studies on sectioned tumour material provided little useful information as artifact was rife and few natural surfaces were evident. Thus the surface features of human oesophageal carcinoma cells growing in the nude mouse could not be compared with those of malignant cells reaching the oesophageal lumen in the human host.

18. 2. 2 Nude mouse tumour cell in vitro

Cells of tumours induced in nude mice as a result of the inoculation of cells of line Hcu 13 and primary and later subcultures of cells of these tumours were examined by light microscopy and by scanning and transmission electron microscopy (Table 33A) and compared with cells of the human line of origin. The ultrastructural and surface features of Hcu 13 cells at the various stages of this investigation have been reported (Robinson et al., 1980b) and are summarised in Table 35. Although the human cell line of origin, the tumours in nine nude mice and primary cultures and subcultures of the tumours in the nude mice showed many similarities, differences were evident when surface features were compared.

The adherent overlapping cells of the continuous cell line Hcu 13 appeared irregular or pleoform with some surface microvilli and well developed complex intercellular connections (Figs. 94 and 95). By scanning electron microscopy the mouse passaged carcinoma cells in primary culture were regular in shape with few surface microvilli (Fig. 117) and showed similarities to early cultures of normal oesophageal cells (Chapter 14. 3), though the cells displayed slightly more surface activity (Table 35). In this way, nude mouse passaged cells in primary culture differed markedly from those in the line of origin which displayed microvilli, lateral processes and interdigitations. The epithelial cells of human oesophageal carcinoma origin grew in continuous bands around the explants of nude mouse grown tumours and only slight stratification of the carcinoma cells in primary cultures was evident.

TABLE 35 SUMMARY OF [illegible] AND [illegible] OF NINE NUDE MOUSE TUMOURS, [illegible] AND THE CELL LINE, [illegible] FROM WHICH THEY ORIGINATED

Characteristics	Hcu 13 cell line	Tumours in the nude mouse	Primary cultures of tumours grown in the nude mouse	Primary cell lines (1-5 passages) from tumours grown in the nude mouse
Type of cell	epithelial	epithelial and fibroblasts	epithelial and fibroblasts	epithelial
Growth pattern	adherent sheet	solid tumour	adherent sheet	adherent cell clusters
Cell shape	pleoform	oval	polygonal epithelial cells	pleoform
Stratification	evident	(solid tumour)	evident	evident
Giant cells	present	present	present	present
Nucleus	marginated chromatin	marginated chromatin	marginated and dispersed chromatin	marginated and dispersed chromatin
Nucleoli	small, dense	dense	dense or threadlike	threadlike
No. of (20-30nm) nuclear particles	moderate	abundant - but variable	moderate - varies in different specimens	moderate - sparse depending on the tumour sample
Microvilli	abundant	few	few	moderate
Surface blebs	moderate	absent	few	moderate
Lateral processes	numerous, well developed	not evident	numerous, well developed	numerous, well developed
Tonofilaments	sparse	abundant in most tumours	abundant in many cultures	sparse

TABLE 35 (cont.)

Characteristic	Hcu 13 cell line	Tumours in the nude mouse	Primary cultures of tumours grown in the nude mouse	Primary cell line (1st subculture) from tumours grown in the nude mouse
Desmosomes	few, well developed	abundant, well developed	abundant - moderate, well developed	few, well developed
Mitochondria	electron dense well preserved cristae	both electron dense and vacuolated forms	electron dense, well preserved cristae	electron dense, well preserved cristae
Ribosomes	associated with endoplasmic reticulum	many free	free	associated with endoplasmic reticulum
Golgi apparatus	abundant	abundant	abundant	abundant
Glycogen	present in some cells	present in several tumours	absent from most cultures	present in few cultures, absent from most
Lipid	occasional droplets	abundant in some cells of some tumours	occasional droplets	occasional droplets



Fig. 117 Scanning electron micrograph showing nude mouse passaged Hcu 13 cells in primary culture. The malignant epithelial cells (E) which are regular in shape and possess few surface projections are bordered by elongated overlapping fibroblasts (F) of mouse origin. Bar = 10 µm

After several subcultures the nude mouse passaged Hcu 13 cells assumed a form which more closely resembled that of the line of origin. The cultured cells acquired microvilli, lateral processes and interdigitations. Initially the lateral processes were longer and thicker than those of the original cell line, while cell contacts and interdigitations were not as well developed (Fig. 118), but after several passages, the cells derived from tumours grown in the nude mouse more closely resembled those of the line Hcu 13.

Thus, morphological changes did occur when human tumour cells were passaged through nude mice and then cultured. The changes were environmental and largely reversible as, after several subcultures, the cells cultured from all nine of the tumours induced by the inoculation of Hcu 13 cells assumed a form resembling that of the cells of the line of origin.



Fig. 118 Scanning electron micrograph of subcultured 13.M1 cells some of which show well developed surface projections while others are relatively denuded of superficial processes. Bar = 10 μm

19 DISCUSSION

BEHAVIOUR AND MORPHOLOGY OF CELLS DERIVED FROM HUMAN OESOPHAGEAL CARCINOMAS IN NUDE MICE

Tumour cells in a human or animal host grow in close proximity to one another in a three dimensional environment. Therefore, in theory, tumour growth and some of the properties of human malignant cells in the nude mouse should more closely approximate the behaviour of malignant cells in the human patient than do malignant cells growing in tissue culture. However, human tumours in nude mice do not invade and metastasize as extensively in this animal as they do in the human host. Nevertheless, the nude mouse provides a useful model system in which aspects of malignancy can be studied and the advantages of both the *in vitro* and nude mouse *in vivo* situations can be interchangeably exploited (Fogh *et al.*, 1979) as many human tumours and cell lines derived from tumours can be grown *in vivo* in the nude mouse and then again *in vitro*.

19.1 TUMOUR "TAKE" RATES IN ATHYMIC NUDE MICE

In this study, eight of the nine oesophageal carcinoma cell lines investigated formed tumours in nude mice, thus proving their tumorigenicity. Although some of the lines (Hcu 13) had "take" rates of 90 per cent, the overall "take" rate recorded in this study for inoculated oesophageal carcinoma cell lines was 31,4 per cent, which is low. Fogh *et al.* (1977) recorded that 100 per cent of 127 malignant cell lines established from a wide range of tumours produced tumours after inoculation into the nude mouse; 90 per cent of such tumours being produced in the first month and the remaining ten per cent within two months of inoculation of the cell lines though some cell lines produced tumours only after repeated testing. Freedman and Shin (1974) also reported "takes" for all heterploid cell lines inoculated into

nude mice. There are, however, a number of other cell lines which, according to present tests, with similar cell inocula and periods of observation have not produced tumours in nude mice (Hajdu and Fogh, 1978) and the ability or lack of ability of some neoplastic cell lines to grow in nude mice is not always a reliable criterion for malignancy (Nilsson et al., 1977). Most researchers who have tried to transplant tumours have found only 50 per cent or less of all attempts to be successful (Rygaard, 1978; Sharkey et al., 1978) as there appear to be certain biological groups of tumours that cannot be propagated in the nude mouse (Rygaard, 1979).

Oesophageal tumours may not grow as well in nude mice as tumours from other sites. Sharkey et al., 1978 reported a 72 per cent "take" rate for tumours derived from the colon, but less success was noted with tumours from other sites of the gastrointestinal tract. While Ikeuchi et al. (1980) have published the only report of oesophageal carcinoma tumour specimens successfully xenografted into nude mice (50 per cent "take"), cells from several other oesophageal carcinoma cell lines (Table 23) have been shown to retain malignant potential in vitro and be tumorigenic upon inoculation into nude mice (SNO, TE-1 and TE-2) or other irradiated rodents (Eca 109, CaES - 17) but no "take" rates have been reported.

Factors such as age, health, strain and immunocompetence of the mice used may be related to the varying "take" rates. Animals in different litters differed genetically and as regards immunocompetence (Stanbridge and Perkins, 1977) and thus varied in their susceptibility to tumour formation. The formation of anti-human antibodies in tumour bearing mice has been reported (Yuspa et al., 1979). For this reason when tumours did not appear after inoculation of a particular cell line, another litter was inoculated with the same cell line in order to test mice of slightly different genetic background against that cell line. The number and type of viable cells inoculated further influenced the "take" rates. Even though several animals were inoculated with 2×10^6 cells of a particular line, the animals may not all have received equivalent cells as a cell line usually consists of clones of cells of

varying tumorigenicity (Uzello and Sordat, 1980).

In this study cell lines showing differentiated features were most tumorigenic, an observation which contradicts that of Grant et al. (1979) who reported that the degree of differentiation did not appear to markedly affect the formation of xenografts. Some of the low "take" rates reported in this study may be related to mycoplasma orale contamination of the cell lines inoculated. Ultrastructural studies revealed the presence of intracellular structures resembling mycoplasmas (Fig. 111) in mouse carcinoma cells and this may be an adaptional response to the environment in the nude mouse. Mycoplasmas may assume an intracellular position when normal or malignant cells are growing in vivo in the human host or in the nude mouse and rapidly become extracellular again when the cells are placed in an in vitro environment. Though the mechanism is not understood the nude mouse responds in some way to mycoplasmas and passage of contaminated cells through nude mice has been reported to eliminate these micro-organisms (Van Diggelen et al., 1977a).

The presence of other micro-organisms may also affect "take" rates and Reid et al (1978) reported that persistently virus- infected cell lines did not form tumours in nude mice. However, the cell line Hcu 13 which possessed virus-like particles was one of the most tumorigenic in this study.

Several tumours in the nude mice may have failed to grow because of inadequate vascularisation and the areas of necrosis present in many of the tumours examined may reflect this (Stanbridge and Perkins, 1977). The inoculated cells may produce some angiogenic factor which influences the development of their blood supply and failure to produce such a factor may result in failure of such cells to form a tumour as may have occurred in the case of the inoculated Hcu 37 cells. The location of the vascular supply may also influence the extent of tumour infiltration into surrounding areas and the rate of growth, as tumours do not always grow consistently after inoculation into nude mice (Jaffrey et al., 1979).

19. 1. 1 Bilateral inoculation

The effect of bilateral inoculation of malignant cell lines on tumour "take" rate is uncertain. The cell line Hcu 13 which was more tumorigenic and had a higher "take" rate than the line Hcu 10 produced tumours which appeared earlier and grew more rapidly than those induced by Hcu 10 cells although similar numbers of cells were inoculated. Bilateral inoculation of cells may have facilitated tumour production, as the formation of a tumour by Hcu 13 cells may have altered the residual immunocompetence of the mouse host and made the animal in some way more receptive to tumour formation by the Hcu 10 cells. Stiles et al. (1976a) noted that the nude mice that had previously failed to grow tumours as a result of the inoculation of human cells, produced tumours when subsequently challenged with other human cells of neoplastic origin.

19. 2 LATENCY PERIODS

The range of latency periods recorded corresponded to those of other workers who reported latency periods of one to three weeks (Stiles et al., 1976a; Stanbridge and Perkins, 1977; Kyriazis et al., 1978), eight weeks (Shin et al., 1975) and up to 33 weeks (Sharkey et al., 1978).

In this study the lengthy latency periods and low tumour "take" rates were not related to poor health of the mice as the animals were healthy and many survived for 12 - 18 months in the environment in which they were maintained. Factors such as mycoplasma contamination (Van Diggelen et al., 1977), failure of a large proportion of the injected cells to adapt to conditions within the nude mouse or rejection of large numbers of cells by some immune mechanism related to residual thymic influence (Stutman, 1979) or involving macrophages may be related to the long latency periods before some of the cell lines inoculated produced tumours.

19. 1. 1 Bilateral inoculation

The effect of bilateral inoculation of malignant cell lines on tumour "take" rate is uncertain. The cell line Hcu 13 which was more tumorigenic and had a higher "take" rate than the line Hcu 10 produced tumours which appeared earlier and grew more rapidly than those induced by Hcu 10 cells although similar numbers of cells were inoculated. Bilateral inoculation of cells may have facilitated tumour production, as the formation of a tumour by Hcu 13 cells may have altered the residual immunocompetence of the mouse host and made the animal in some way more receptive to tumour formation by the Hcu 10 cells. Stiles et al. (1976a) noted that the nude mice that had previously failed to grow tumours as a result of the inoculation of human cells, produced tumours when subsequently challenged with other human cells of neoplastic origin.

19. 2 LATENCY PERIODS

The range of latency periods recorded corresponded to those of other workers who reported latency periods of one to three weeks (Stiles et al., 1976a; Stanbridge and Perkins, 1977; Kyriazis et al., 1978), eight weeks (Shin et al., 1975) and up to 33 weeks (Sharkey et al., 1978).

In this study the lengthy latency periods and low tumour "take" rates were not related to poor health of the mice as the animals were healthy and many survived for 12 - 18 months in the environment in which they were maintained. Factors such as mycoplasma contamination (Van Diggelen et al., 1977), failure of a large proportion of the injected cells to adapt to conditions within the nude mouse or rejection of large numbers of cells by some immune mechanism related to residual thymic influence (Stutman, 1979) or involving macrophages may be related to the long latency periods before some of the cell lines inoculated produced tumours.

19. 3 SEX DIFFERENCES

No marked sex difference was evident in this study and the development of oesophageal carcinomas was independent of the sex of the animals, a finding which was contrary to the observation of Pettengill et al. 1980). There was no evidence for hormonal dependence of this tumour since tumours grew equally well in pregnant females, lactating mothers and sexually active males.

19. 4 TUMOUR INFILTRATION INTO SURROUNDING TISSUES

Oesophageal tumours may be particularly malignant since cells derived from them displayed invasive properties in the nude mice and just under half of all the tumours grown in the nude mouse and examined during this investigation were infiltrating surrounding tissues. However, other cell lines also derived from invasive human tumours have formed sharply delineated tumours in the nude mouse (Freedman and Shin, 1978) and these tumours have grown as single, well defined encapsulated masses (Freedman and Shin, 1974; Stanbridge and Perkins, 1977; Kyriazis et al., 1978; Sharkey et al., 1978; Freedman and Shin, 1978). Local spread and invasion into striated muscle have only occasionally been noted (Stanbridge et al., 1 3; Ozello and Sordat, 1980) and tumours grown in the nude mouse infrequently showed invasion of deep muscular or bony structures, no matter how large they became (Sharkey et al., 1978).

In spite of infiltrating tumour cells coming into close proximity to mouse cells it is unlikely that cells injected into nude mice produced tumours by transformation of the host cells (Billelo et al., 1977; Freedman and Shin, 1978), and the only obvious involvement of the host with the tumour cells was the formation of a fibrous connective tissue capsule around the growing tumour mass and the organisation of a blood supply to the tumour.

19. 5 METASTASIS

In this study all tumours were inoculated subcutaneously and the

extensive metastases without an obvious primary tumour observed in mouse X1 were an unexpected finding. The absence of gross macroscopic metastasis after the inoculation of many tumour cell lines has been reported by several laboratories (Freedman and Shin, 1974; Stiles et al., 1976a), the absence of tumour metastasis being especially remarkable for tumours derived from those known to metastasize in the human host (Giovanella et al., 1973). However, the absence of tumour metastasis in nude mice is not the invariable rule. Giovanella et al. (1974) reported the production of metastatic tumours in nude mice following the inoculation of cells derived from a human malignant melanoma. Sharkey and Fogh (1979) noted metastasis in 1,3 per cent of human tumour lines studied and Shimosato et al. (1979) found evidence for limited metastasis with one human tumour in a series involving 91 human tumours. Reid et al. (1978) have also reported two cases of metastasis; one an epidermoid carcinoma of the lung and one a prostatic carcinoma, and Ozello and Sordat (1980) reported metastasis of a mammary tumour in the nude mouse.

There may be an association between tumorigenicity of the cell line inoculated and metastasis in the nude mouse. The line Hcu 18 was derived from an anaplastic carcinoma which was invasive in the human host. The cells of this line grew rapidly in vitro and showed marked surface activity - an indication of malignant potential (Chapter 16). However, other poorly differentiated lines such as Hcu 10 failed to induce metastasizing tumours, and only a single mouse inoculated with Hcu 18 cells developed tumour metastases.

The metastatic involvement of kidney, spleen and liver was unusual, particularly as the lungs (a frequent site of implantation of other metastatic tumours (Ozello and Sordat, 1980))were free of metastases. The involved axillary and inguinal lymph nodes may be related to the routes of lymphatic drainage of the suprascapular area where the cells were inoculated; but other nodes, such as the submandibular nodes also contained tumour deposits. A significant association between metastasis and

and body wall invasion and size of tumours has also been noted (Sharkey and Fogh, 1979). In this study many tumours infiltrated the body wall, yet metastasis was observed in only one mouse. Several mice were screened for metastasis and sections of kidney, lung, liver and spleen examined but there was no evidence of tumour cell infiltration of any of these areas. Metastasis in the nude mouse may be a strain specific phenomenon independent of the nu/nu genotype as Reid and Shin, 1978, observed no metastases when malignant cells were inoculated into BALB/c nude mice; yet the same cells produced metastasizing tumours in C57BL/6 mice.

The failure of most tumour cells to metastasize in the nude mouse may be related to the development of connective tissue capsules around the tumours which may interfere with growth of the tumours (Kyriazis et al., 1978). Alternatively, the occurrence of metastasis may be related to the site of inoculation (Sharkey and Fogh, 1979) as tumours transplanted intraperitoneally imitate more closely the biological characteristics of malignant growths in man, spread over wide areas, infiltrate and give distant metastases (Kyriazis et al., 1978), with the lungs and mediastinal lymph nodes being the sites where metastases were most frequently encountered. The inability of malignant cells to metastasize in the nude mouse may also be related to the observed surface changes which occur when malignant cells are grown in the nude mouse (Robinson et al., 1980b). The cells lose a number of malignant features such as extensive surface activity and may consequently function in a similar way to benign cells.

19.6 TUMOUR RECURRENCE

Several mice were observed for periods of up to six months following tumour removal and recurrence noted in a single animal which had developed a mobile encapsulated, non-infiltrating, well differentiated, squamous carcinoma. This recurrence was unexpected since the initial tumour was fully mobile. The skin nodule developed anterior to where the tumour had been situated on the ipsolateral side; this suggesting some form of local spread.

Although nude mice have a low incidence of spontaneous neoplasms (Ioachim,1976) and those which do occur generally involve the lymphoreticular system (Reid et al., 1978; Sharkey et al., 1978), the skin nodule may have developed independently as a spontaneous neoplasm. It is more likely, though, that the skin nodule was related to the original tumour. Other animals may also have developed recurrent tumours if the period of observation was increased. There have been no other reports of tumour recurrence in nude mice but this may be attributed to the fact that most animals have been sacrificed upon tumour removal.

19. 7 DIFFERENTIATION OF OESOPHAGEAL CARCINOMAS INDUCED IN NUDE MICE

In this study tumours grown in nude mice consisted sometimes of cells which were better differentiated than those in the line of origin and sometimes of cells which became less well developed. Single cell lines were capable of giving rise to tumours of varying differentiation and showing different degrees of differentiation in different animals. This finding differs from the observations of other workers who have claimed that tumour cells in the nude mouse host are similar to those in the human host (Povlsen and Rygaard, 1971; Visfeldt et al., 1972 ; Povlsen, 1976) or that tumours in nude mice exhibit a higher degree of differentiation than that shown by the tumour of origin (Giovanella et al., 1978; Sharkey et al., 1978).

The degree of differentiation expressed by tumour cells may be dependent on the environment. Loss or reduction of differentiated features such as tonofilaments was a common observation when primary cultures of nude mouse tumours were compared with those in the mouse host (Robinson et al., 1980b) and cells *in vitro* infrequently showed all of the differentiated functions observed *in vivo*. Since *in vitro* conditions can alter differentiation, so too, *in vivo* conditions such as blood supply or stromal infiltration could also influence the degree of differentiation expressed by human oesophageal carcinoma cells in the nude mouse.

[illegible] l., cell [illegible] rly differentiated may have [illegible]ntial [illegible] m well differentiated in a more suitable [illegible]ment.

[illegible] between tumorigenicity or latency [illegible] between loss of [illegible] by Barendsen [illegible] was not observed. For instance, in M1 both [illegible] developed and grew [illegible] differentiated tu- [illegible] ed been inoculated.

[illegible] INTRANUCLEAR PARTICLES

[illegible] nuclear particles present in some of the cells of nude [illegible] s induced by the inoculation of Hcu 13 cells and nude [illegible] passaged Hcu 13 cells ma be related to viral activity or [illegible] metabolism. Their persistence in Hcu 13 cells grown in [illegible]erent environments and passed through the nude mouse emphasizes [illegible] association with cells of this line. The apparent [illegible]ification of the production of these particles may be an en- [illegible]onmental effect as the nude mouse may provide a suitable milieu [illegible] their production. Such particles may be present in several [illegible] in the mouse and intranuclear particles were evident in [illegible] cells which were grown in the same animals as Hcu 13 [illegible]. These particles may have been transferred from Hcu 13 [illegible] the Hcu 10 cells may have retained the latent ability to [illegible] intranuclear particles and become activated within the [illegible] mouse. The degree of differentiation of malignant cells [illegible] play a role in viral replication (Zur Hausen, 1979), and the [illegible] in differentiation of the Hcu 10 cells in the nude mouse [illegible] have resulted in the production of intranuclear particles. [illegible] expression which is repressed in the host of origin can [illegible] appear when the tumour tissue (or cell line derive from it) [illegible] transplanted in nudes where such repression does not [illegible] (Giovanelli and [illegible], 1978).

19. 9 SURFACE DIFFERENCES IN CELLS OF LINE HCU 13 BEFORE AND AFTER PASSAGE THROUGH THE NUDE MOUSE

The marked surface differences observed in cells of line Hcu 13 before and immediately after passage through the nude mouse may be related to environmental effects since, after several subcultures, the nude mouse passaged cells once again closely resembled cells of the line Hcu 13 (Robinson et al., 1980b). Cell form in culture is dynamic (Westbrook et al., 1975) and interaction with an underlying substrate can cause profound changes as the cells settle and become established in culture (Cooper and Fischer, 1968; Witkowski and Brighton, 1971; Netzel et al., 1976). Therefore it is not surprising that cells in the nude mouse differed somewhat from those in tissue culture. Although the nude mouse tumour cells, their subcultures and the line Hcu 13 differed in a number of features, such as degree of differentiation, presence of intranuclear particles and surface activity, in this investigation the nude mouse grown tumour cells still possessed some distinctive features which illustrated their genetic relationship to the cell line of origin. Thus the genetic composition obviously influenced cell form and surface change subject to the effects of the environment (Westbrook et al., 1975). This was clearly demonstrated by the fact that the various nude mouse tumours and the lines arising from them showed striking resemblance to one another. Cells of the primary cultures of the nude mouse tumours grew in continuous sheets, were tightly adherent both to one another and the substrate and displayed little surface activity and in this way were similar to early cultures of normal human oesophageal cells (Chapter 14. 3). Subcultured cells grew in smaller clusters, were less adherent and showed far more surface detail.

Surface features such as microvilli and lateral processes may be an expression of malignant potential (Boyden and Reith, 1980; Reith et al., 1980) though it is unlikely that there would be marked alterations in the tumorigenicity of early and later subcultures of the same cells. The increased number of micro-

villi after several subcultures may be nothing more significant than a response to exposure to trypsin as an increase in the number of cell surface projections following trypsinisation of both normal and malignant cell lines has been reported (Dalen and Scheie, 1969; Follett and Goldman, 1970). Such an increase in the number of microvilli must, however, be under genetic control as the eventual cell form (morphology) reached was similar in all cultures derived from the nine nude mouse tumours originating from cells of the line Hcu 13.

19. 10 SUMMARY

The nude mouse experimental system provided information about the tumorigenicity of all the human oesophageal carcinoma lines tested. With the exception of line Hcu 37, all of the lines tested produced carcinomas of varying differentiation in the nude mouse. There was little correlation between "taks" rates, latency periods and tumour differentiation. Although tumour infiltration of surrounding tissues was frequently observed, metastatic spread only occurred in a single animal and tumour recurrence after removal was only noted in one instance.

Amplification of the production of 20 - 30nm intranuclear particles took place in the nude mouse model and a cell line (Hcu 10) not previously seen to contain virus-like particles, after growth in the nude mouse revealed numerous intranuclear particles.

The investigations performed allowed comparisons to be made between the cells comprising carcinomas in nude mice, the cell lines from which they originated and cell lines arising from them.

20 GENERAL DISCUSSION AND CONCLUSIONS

MAJOR RESULTS AND THEIR RELEVANCE

Although the bulk of the investigations performed involved laboratory work, all tissue culture, transmission and scanning electron microscopy and nude mouse studies revolved around the patient with carcinoma of the oesophagus. Every endeavour was made to find correlations which would be of clinical relevance, so that the patient who is the crux of the problem might ultimately benefit from the research.

20.1 DISTINCTION BETWEEN NORMAL AND MALIGNANT OESOPHAGEAL CELLS

Several conspicuous differences between normal and malignant oesophageal cells were obvious in both the *in vivo* and *in vitro* studies.

1 Cell surface morphology - Superficial surfaces of normal oesophageal cells *in vivo* were covered with regular arrays of microplicae, but these processes were sparse and irregular on carcinoma cells which reached the lumen of the oesophagus. *In vitro*, malignant oesophageal cells displayed more surface activity (microvilli and lateral processes) while normal oesophageal cells were characterised by sparse surface microvilli.

2 Differentiation - malignant oesophageal cells showed a range of differentiation both *in vivo* and *in vitro* with areas of keratinisation being frequently encountered. Normal oesophageal cells, although highly differentiated, did not keratinise and were more uniform in appearance.

3 Giant cells - while both mono- and multinucleated giant cells were associated with specimens of malig-

nant oesophagus *in vivo* and in culture, these large cells were not observed in association with normal oesophageal mucosa.

4 Growth rate - normal oesophageal cells generally grew more rapidly after culture initiation than did oesophageal carcinoma cells.

5 Growth potential - all specimens of normal oesophageal mucosa studied had a finite *in vitro* lifespan, while the cells from several oesophageal carcinoma specimens formed continuous cell lines.

20. 1. 1 Significance of morphological and behavioural differences between normal and malignant oesophageal cells

Accurate morphological distinction between normal and malignant cells is important when diagnosing malignancy, and when checking that a tumour has been removed in its entirety. The conclusions from this study are that:

(a) Scanning electron microscopy is a more sensitive measure of cell surface features than conventional histological techniques and may be of use when diagnosis is uncertain.

(b) *In vitro* growth patterns may aid in cases of difficult diagnosis as cultured normal cells can be easily distinguished from malignant cells *in vitro*.

(c) The successful culturing of normal oesophageal cells is significant as little is known about these and other normal adult cells *in vitro*.

(d) A supply of cultured normal oesophageal cells will be of value in the investigation of suspected carcinogenic agents as *in vitro* effects of these agents may be extrapolated to the *in vivo* situation.

(e) The morphological characterisation of normal and

malignant oesophageal cells *in vivo* provides further information regarding the changes which occur in neoplastic cells and which have not previously been described.

20. 2 ESTABLISHMENT OF TEN CONTINUOUS HUMAN OESOPHAGEAL CARCINOMA CELL LINES

Existing tissue culture techniques were adjusted to suit local conditions and ten continuous oesophageal carcinoma cell lines established from tumours of varying differentiation. Lines from poorly differentiated tumours showed some similarities to one another, as did those derived from some of the well differentiated tumours. The lines established in this study resembled those described in the literature.

20. 2. 1 Significance of human oesophageal carcinoma cell lines

The ten lines established in this study increase the total number of reported lines to 17. These lines provide an invaluable source of material for a wide range of investigations. The cell lines can be used for ultrastructural and biochemical studies, *in vitro* testing of anti-cancer drugs, immunological investigations such as the production of antibodies, in particular, monoclonal antibodies, the growth of human oesophageal carcinomas in experimental animals, chromosome studies, and cell kinetics.

20. 3 SOME IN VITRO FEATURES CORRELATE WITH IN VIVO BEHAVIOUR

On the basis of their growth rate, growth pattern and potential *in vitro*, resected and biopsied oesophageal carcinoma specimens were placed in Categories. The Categories into which a specimen fell on the basis of *in vitro* behaviour correlated with certain *in vivo* properties of the tumour. In this way, information of clinical value was obtained from those specimens which did not develop into continuously growing cell lines.

20. 3. 1 Growth in vitro and clinical prognosis

The correlation between ability of a tumour specimen to grow in vitro and invasive properties of an oesophageal carcinoma in vivo is important as it allows invasive tumour behaviour in vivo to be predicted on the basis of laboratory results. Information obtained from tissue culture can influence the treatment modality selected.

Although a close association between lymph node and organ invasion and tissue culture category was noted, features such as differentiation and lymphocyte infiltration of the tumours had no obvious correlations in vitro. There was, however, a tendency for specimens derived from poorly differentiated tumours to survive longer in vitro.

Thus, tissue culture ties up closely with the clinical situation and provides information which is not made available using other techniques.

20. 4 BIOPSY SPECIMENS IN VITRO ARE REPRESENTATIVE OF THEIR TUMOURS OF ORIGIN IN VIVO

No differences in growth pattern, rate or cell morphology were noted when superficial biopsy specimens and deep resected specimens from the same tumours were compared. On the basis of in vitro growth, biopsy specimens could be classified into similar tissue culture categories to those used for resected specimens. As the emphasis was on rapid results, the slightly different categories used for biopsy specimens allowed clinically relevant results to be obtained.

20. 4. 1 Clinical simplicity

As biopsy specimens behave in vitro in a manner representative of certain properties of the tumour of origin in vivo the culture of biopsy specimens can be used as an aid in diagnosis and an indication of clinical staging. Specimens from invasive or metastasizing

tumours grow more rapidly *in vitro* and the tissue culture information can thus be of importance in selecting patients for surgery and other forms of treatment. A further advantage is that biopsies can be easily obtained. A fuller utilisation of biopsy specimens and the information they can yield would benefit the patient with carcinoma of the oesophagus.

20. 5 NORMAL AND MALIGNANT CELLS UNDERGO ALTERATIONS DURING ADAPTATION TO *IN VITRO* CONDITIONS

While emphasis is placed on the clinical significance of tissue culture results, the fact that cells become altered during adaptation to the *in vitro* environment must be taken into account. The recognition and understanding of such adaptational changes may increase the value of continuous cell lines and allow for a realisation of their limitations.

Primary cultures most closely resembled the tumours of origin and several changes became evident with increasing time *in vitro*. These included:

1 Growth rate - the cells in primary cultures were slow-growing and later replaced by more rapidly multiplying populations.

2 Surface changes - with the exception of cultured normal oesophageal cells, all cells acquired a greater number of surface projections, up to a genetically or environmentally determined limit, with increasing time *in vitro*.

3 Differentiation - cells *in vitro* showed a progressive decrease in differentiation as exemplified by a reduction in the numbers of desmosomes and tonofilaments. However, the potential to differentiate remained and many cells became highly differentiated upon inoculation into the nude mouse.

4 Myelinoid bodies - these structures were more abundant in cultured cells than those *in vivo*. Their presence in the more basally situated cells may be related to

altered nutritional supply to these cells and the fact that nourishment is by diffusion.

5 Organelles - cultured cells displayed more numerous and regular cytoplasmic organelles than those present in malignant cells *in vivo*.

20. 6 CONTINUOUS HUMAN OESOPHAGEAL CARCINOMA CELL LINES ARE TUMORIGENIC IN NUDE MICE

As changes occurred during adaptation of oesophageal carcinoma cells to *in vitro* conditions it was necessary to confirm that the continuous cell lines did consist of malignant cells. Tumour formation in nude mice provided proof of the authentic malignant nature of cells of eight of the nine lines tested. All tumours resulting from the inoculation of cells of the continuous lines were carcinomas and possessed varying numbers of tonofilaments and desmosomes.

Tumorigenicity testing in nude mice is a useful method of screening cell lines for malignant potential. The nude mouse also provides a model in which tumour growth and behaviour can be studied.

20. 7 ALL OESOPHAGEAL CARCINOMAS INDUCED IN NUDE MICE BY THE INOCULATION OF CELLS OF CONTINUOUS HUMAN OESOPHAGEAL CARCINOMA CELL LINES RESEMBLE ONE ANOTHER

Although differences were noted in tumour "take" rates, latency periods, histological differentiation, size and infiltration in many of the mouse carcinomas displayed similar features. In fact, there was just as much variation when cells from the same line were inoculated into different mice as when cells from different lines were inoculated. This is of significance as it implies that all of the cell lines tested are capable of producing similar tumours which are related to the human tumours from which the cell lines arose.

20. 8 CARCINOMAS INDUCED IN NUDE MICE SHOW MANY SIMILARITIES TO THEIR HUMAN TUMOURS OF ORIGIN

Many morphological similarities were noted between nude mouse tumours and human oesophageal carcinomas *in vivo*, though some of the mouse tumours showed more differentiated features than their human tumours of origin. Some behavioural similarities were also noted, as the tumours in nude mice grew indefinitely, as did those in the human host. Although all of the cell lines were established from invasive human tumours, most of the mouse carcinomas behaved like benign tumours and metastasis was only observed in one animal. However, with the exception of tumours induced by HCu 33 cells, some tumours resulting from inoculation of each of the lines, infiltrated surrounding tissues. The mouse tumours may not appear as invasive as those in the human host because of some residual immune response occurring in the nude mouse or there may be an interaction between the mouse connective tissue and human carcinoma cells.

In spite of these behavioural differences, the nude mouse provides a valid model system for the investigation of oesophageal carcinomas and associated studies such as screening of anti-cancer agents.

20. 9 OESOPHAGEAL CARCINOMAS GROWN IN NUDE MICE CAN BE SUCCESSFULLY CULTURED

With a single exception, all mouse carcinomas adapted rapidly to *in vitro* conditions and formed cell lines, thus substantiating their malignant origin. The ease with which cell lines were derived may be explained by the fact that the carcinoma cells inoculated into nude mice were already adapted for *in vitro* conditions. After culture, the nude mouse passaged cells remained tumorigenic and several tumours induced by mouse passaged cells were successfully cultured.

Similarities were evident between human and mouse grown carcinomas and the cell lines derived from both. After several subcultures

the mouse passaged cells closely resembled those of the human cell line of origin. Thus, the cells were subject to genetic constraints which were dependent on the environment. The nude mouse can justifiably be used when investigating human tumour cells as such cells are not irreversibly altered by passage through the nude mouse.

20. 10 THE PRESENCE OF INTRANUCLEAR AND CYTOPLASMIC PARTICLES IN SOME OESOPHAGEAL CARCINOMA CELLS SUGGESTS THE POSSIBILITY OF VIRAL INVOLVEMENT WITH CARCINOMA OF THE OESOPHAGUS

While the morphological features listed in Chapter 16. 3 may be indicative of viral activity in some oesophageal carcinoma cells, this association has not been proved. Several other features such as amplification of intranuclear particles by passage through the nude mouse support the theory but the viral hypothesis is still speculation.

20. 11 SUMMARY OF CONTRIBUTIONS TO EXISTING KNOWLEDGE

Both *in vivo* (nude mouse) and *in vitro* model systems for investigations on oesophageal carcinomas were established. Normal and malignant human oesophageal cells were characterised *in vivo* and *in vitro* and previously unreported correlations between *in vivo* and *in vitro* behaviour were described.

REFERENCES

ABERCROMBIE, M. and AMBROSE, E.J. (1962). The surface properties of cancer cells: a review. Cancer Research 22, 525 - 548.

ACKERMAN, L., PIROS, J., DE CARLE, D. and CHRISTENSEN, J. (1976). A scanning electron microscopic study of esophageal mucosa. Scanning Electron Microscopy / 1976 / V Proceedings of the Workshop on advances in Biomedical applications of the SEM. pp 247 - 252. Chicago: Illinois Institute of Technology.

AIRD, I., LEE, D.A. and ROBERTS, J.A.F. (1960). ABO blood groups and cancer of the oesophagus, cancer of the pancreas, and pituitary adenoma. British Medical Journal 1, 1163 - 1166.

ALBOT, P.M.G. and JEZEQUEL, A.M. (1962). Ultrastructure du foie et pathogenie de l'ictere au cours des hepatites virales. Archives des Maladies de l'Appareil Digestif et des Maladies de la Nutrition 5, 505 - 528.

ALEXANDER, J., BEY, E., WHITCUTT, J.M. and GEAR, J.H.S. (1976). Adaptation of cells derived from human malignant tumours to growth in vitro. South African Journal of Medical Sciences 41, 89 - 98.

ALEXANDROVA, N.M., KOLYCHEVA, N.I. and ADILGIREEVA, S.X. (1980). On morphological and some cytophotometric features of oesophageal dysplasia and cancer in situ. Voprosi Onkologii 26, 41 - 46.

AL YASSIN, T.M. and TONER, P.G. (1977). Fine structure of squamous epithelium and submucosal glands of human oesophagus. Journal of Anatomy 123, 705 - 721.

ARNOLD, W. and HUTH, F. (1979). Light and electron microscopic investigations of nasopharyngeal carcinomas with regard to the viral etiology of these tumors. Journal of Cancer Research and Clinical Oncology 94, 97 - 107.

REFERENCES

[illegible], [illegible] and [illegible], [illegible] ([illegible]). The surface properties of cancer cells: a review. Cancer Research 22, 525 - 548.

[illegible], [illegible], [illegible], [illegible] CARLE, D. and CHRISTENSEN, J. (1976). A scanning electron microscopic study of esophageal mucosa. Scanning Electron Microscopy / 1976 / V Proceedings the [illegible] on Advances in Biomedical applications of the SEM. [illegible] - [illegible]. Chicago: Illinois Institute of Technology.

[illegible], [illegible], [illegible], D.[illegible] and ROBERTS, J.A.F. (1960). 'BO blood [illegible] and cancer of the oesophagus, cancer of the pancreas, and pituitary adenoma. British Medical Journal 1, 1163 - 1166.

[illegible], [illegible] and JEZEQUEL, A.M. (1962). Ultrastructure du foie et pathogenie de l'ictere au cours des hepatites virales. Archives des Maladies de l'Appareil Digestif et des Maladies de la Nutrition 5, 505 - 528.

[illegible], [illegible], BEY, E., WHITCUTT, J.M. and GEAR, J.H.S. (1976). Adaptation of cells derived from human malignant tumours to growth in vitro. South African Journal of Medical Sciences 41, 89 - 98.

[illegible]OVA, [illegible], KOLYCHEVA, N.I. and ADILGIREEVA, S.X. (1980). [illegible] morphological and some cytophotometric features of oesophageal [illegible] and cancer in situ. Voprosi Onkologii 26, [illegible] - 46.

[illegible], [illegible] and [illegible], P.G. (1977). Fine structure of squamous [illegible] and submucosal glands of human oesophagus. Journal of Anatomy 123, 705 - 721.

[illegible], W. [illegible], [illegible] (1979). Light and electron microscopic investigations of oesopharyngeal carcinomas with regard to the viral etiology of these tumors. Journal of Cancer Research and Clinical Oncology 94, 87 - 107.

ANGHILERI, L.J. and DERMIETZEL, A. (1976). Cell coat in tumour cells - effects of trypsin and EDTA. A biochemical and morphological study. Oncology 33, 17 - 23.

AUBERT, C., ROUGE, F. and GALINDO, J.R. (1980). Tumorigenicity of human malignant melanocytes in nude mice in relation to their differentiation in vitro. Journal of the National Cancer Institute 64, 1029 - 1040.

AUERSPERG, N. and FINNEGAN, C.V. (1974). The differentiation and organisation of tumours in vitro. In Neoplasia and cell differentiation (ed G.V. Sharbert), pp 279 - 318. Basel: Karger.

BALCH, C. , MURAD, T.M., SOONG, S.J., INGALLS, A.L., HALPERN, N.B. and MADDOX, W.A. (1978). A multifactorial analysis of melanoma. Annals of Surgery 188, 732 - 742.

BARENDSEN, G.N., JANSE, H.C., DEYS, B.F. and HOLLANDER, G.F. (1977). Comparison of growth characteristics of experimental tumours and derived cell cultures. Cell and Tissue Kinetics 10, 469 - 475.

BEASLEY, M.H. (1964). The ABO blood groups of carcinoma of the oesophagus and benign prostatic hyperplasia. Journal of Clinical Pathology 17, 42 - 44.

BERNHARD, W. (1969). Ultrastructure of the cancer cell. In Handbook of Molecular Cytology (ed. A. Lima-de-Faria), pp 687 - 715. Amsterdam: Elsevier / North Holland.

BERTOLINI, L. and DIAMOND, L. (1976). Preservation of cells in monolayer culture by freezing in situ. Tissue Culture Association Manual 2, 487 - 488.

BEY, E., ALEXANDER, J., WHITCUTT, J.M., HUNT, J.A. and GEAR, J.H.S. (1976). Carcinoma of the oesophagus in Africans: establishment of a continuously growing cell line from a tumor specimen. In Vitro 12, 107 - 110.

BILELLO, J.A., FREEDMAN, V.H. and SHIN, S-I. (1977). Growth of murine sarcoma virus transformed rat kidney cells in nude

mice: absence of induction of host endogenous viruses. Journal of the National Cancer Institute 58, 1691 - 1694.

BIRBECK, M.S.C. (1976). Ultrastructure of tumour cells. In Scientific Foundations of Oncology (ed. T. Symington and R.L. Carter), pp 8 - 15. London: Heinemann Medical.

BLACK, M.M., BARCLAY, T.H. and HANKEY, B.F. (1975). Prognosis in breast carcinoma utilising histr ical characteristics of the primary tumor. Cancer . 48 - 2055.

BLOOM, E.T. (1972). Further definition by cytotoxicity tests of cell surface antigens of human sarcomas in culture. Cancer Research 32, 960 - 967.

BLOOM, W. and FAWCETT, D.W. (1975). A Text book of Histolog 10th ed. Philadelphia: W.B. Saunders Company.

BOGOVSKI, P. and WALKER, E.A. (1973). N-nitroso compounds in the environment. Lyon: IARC Scientific Publications, No. 9.

BOTHA, J.B.C., BOWEN, R.M. and UYS, C.J. (1978). The pathology of carcinoma of the oesophagus. A survey of 1632 cases in Cape Town. In Carcinoma of the Oesophagus (ed. W. Silber), pp 117 - 131. Cape Town: Balkema.

BOYSEN, M. and REITH, A. (1980). Surface structures in normal, metaplastic and dysplastic nasal mucosa of nickel workers. A SEM and post-SEM histopathological study. Scanning Electron Microscopy/1980 / III, 35 - 42.

BRADSHAW, E. and SHOPLAND, M. (1969). Oesophageal and lung cancers in Natal African males in relation to certain socio-economic factors. British Journal of Cancer 23, 275 - 284.

BREATHNACH, A.S. (1971). An Atlas of the Ultrastructure of Human Skin. London: Churchill.

BRIGHTMAN, M.W. and REESE, T.S. (19). Junctions between intimately opposed cell membrances in the vertebrate brain. Journal of Cell Biology 40, 648 - 677.

BRINTON, F.A. (1973). The cytological diagnosis of oesophageal

malignancy. In Carcinoma of the Oesophagus (ed. M. Silber), pp 193 - 199. Cape Town: Balkema.

BRODSKY, W.Y. and URYVAEVA, I.V. (1977). Cell Polyploidy: its relation to tissue growth and function. International Review of Cytology 70, 275 - 332.

BUSCH, H. and SMETANA, K. (1974). The nucleus of the cancer cell. In The Cell Nucleus (ed. H. Busch), pp 41 - 80. New York: Academic Press.

BUSCH, H. (1974). The Cell Nucleus. New York: Academic Press.

CARR, K.E., DUNN, J. and TONER, P.G. (1974). Scanning electron microscopy of the alimentary tract. Scottish Medical Journal 19, 211 - 220.

CARRINGTON, G. and WILSON, N.H. (1980). A tridimensional view of keratoacanthomas. Scanning Electron Microscopy / 1980 / III, 495 - 504.

CASE, R.A.M. (1961). Mortality from cancer of the oesophagus in England and Wales. In Neoplastic Disease at various sites (ed. M.C. Tanner and D.W. Smithers), pp 16 - 28. Edinburgh: Livingstone.

CHOPRA, D.P. and FLAXMAN, B.A. (1975). The effect of vitamin A on growth and differentiation of human keratinocytes in vitro. Journal of Investigative Dermatology 64, 17 - 22.

COOK, P. (1971). Cancer of the oesophagus in Africa. A summary and evaluation of the evidence for the frequency of occurrence, and a preliminary indication of the possible association with the consumption of alcoholic drinks made from maize. British Journal of Cancer 25, 853 - 880.

COOK, P. and BURKITT, D.P. (1971). Cancer in Africa. British Medical Bulletin 27, 14 - 20.

COOK - MOZAFFARI, P.J., AZORDEGAN, F., DAY, N.E., RESSICAUD, A., SABAI, C. and ARAMESH, B. (1979). Oesophageal cancer studies in the Caspian littoral of Iran: results of a case-control study. British Journal of Cancer 39, 293 - 309.

COOPER, T.W. and FISHER, H.W. (1968). Electron microscopic survey of the presence of microvilli on cultured mammalian cells. Journal of the National Cancer Institute 41, 789 - 794.

COPELAND, D.D., CLOYD, M.W., NESCHLEN, W., INGRAM, P. and BIGNER, D.D. (1976). Surface morphology of avian sarcoma virus and ethyl-nitrosourea transformed rat neuroectodermal cells and human glioblastoma cells in organ and monolayer culture. Scanning Electron Microscop. / 1976 / V Proceedings of the Workshop on advances in Biomedical applications of the SEM. pp 93 - 100. Chicago: Illinois Institute of Technology.

COPENHAVER, W.M., KELLY, D.E. and WOOD, R.L. (1978). Bailey's Textbook of Histology 17th ed. Baltimore: Williams and Wilkins Company.

CORVAJA, N., MAGHERINI, P.C. and POMPELAND, O. (1971). Ultrastructure of glycogen-membrane complexes in sensory nerve fibres of cat muscle spindles. Zeitschrift für Zellforschung und mikroskopische Anatomie 121, 191 - 217.

CUMMINGS, J.H. (1978). Dietary factors in the aetiology of gastrointestinal cancer. Journal of Human Nutrition 32, 455 - 465.

CUTLER, S.J. and YOUNG, J.L. Jr. (1975). Third National Cancer Survey: Incidence Data. Bethesda: National Cancer Institute, Monogram No. 41.

DALEN, N. and SCHEIE, P. (1969). Microextentions on Chang's liver cells throughout their division cycle. Experimental Cell Research 57, 351 - 358.

DE HARVEN, E. (1970). Identification of tissue culture contaminants by electron microscopy. In Contamination in Tissue Culture (ed. J Fogh), pp 205 - 231. New York: Academic Press.

DEKKER, W. and TYTGAT, G.N. (1977). Diagnostic accuracy of fiberendoscopy in the detection of upper intestinal malignancy: a follow up. Gastroenterology 73, 710 - 714.

DEMBITZER, H.M., HERZ, F., SCHERMER, A., MOLLEY, R.C. and KOSS, L.G.

(1980). Desmosome development in an in vitro model. Journal of Cell Biology 85, 695 - 702.

DENDY, P.P., BOZMAN, G. and WHEELER, T.K. (1970). In vitro screening test for human malignant tumours before chemotherapy. Lancet 2, 68 - 72.

ARTMENT OF CELL BIOLOGY OF CICAMS (1976). Establishment of an epithelial cell line from human esophageal carcinoma. Chinese Medical Journal 56, 412 - 415.

DESMET, V.J. and TYTGAT, G.N. (1974). Histology and electron microscopy. In Handbook der inneren Medizin 3/1. Diseases of the Esophagus (ed. G. Vantrappen and J. Hellemans), pp 17 - 39. Berlin: Springer-Verlag.

DREYER, L. (1980). The incidence of dysplasia and associated epithelial lesions in the oesophageal mucosa of South African Blacks. South African Medical Journal 10, 406 - 408.

EAGLE, H. (1959). Minimum Essential Medium. Science 130, 432.

ECCLES, S.A. and ALEXANDER, P. (1974). Macrophage content of tumours in relation to metastatic spread and host immune reaction. Nature 250, 667 - 669.

EDISER, R. and GIOVANELLA, B.C. (1978). Current knowledge of breeding and mass production of the nude mouse. In The nude mouse in experimental and clinical research (eds. J. Fogh and B.C. Giovanella), pp 16 - [illegible]. New York: Academic Press.

ENOMOTO, M. and SAITO, M. (1972). Carcinogens produced by fungi. Annual Review of Microbiology [illegible] - 312.

ESOPHAGEAL CANCER RESEARCH GROUP, CHINESE ACADEMY OF MEDICAL SCIENCES, PEKING (1977). Pathology of early esophageal squamous cell carcinoma. Chinese Medical Journal [illegible] - 192.

EVERS, P., ROBINSON, K.M., MAISTRY, L. and HIBBINSON, E. (1980). Description of a coverslip holder for, and observations on, the critical point drying of cell cultures. Journal of Microscopy [illegible].

FAGELMAN, K.M., JAGER, R. and POLK, H. (1979). Esophageal carcinoma: Trends in incidence, treatment methods and prognosis. Journal of the Kentucky Medical Association 77, 637 - 642.

FOA, C. and AUBERT, C. (1977). Ultrastructural comparison between cultured and tumor cells of human malignant melanoma. Cancer Research 37, 3957 - 3963.

FOGH, J. and HAJDU, S.I. (1975). The nude mouse as a diagnostic tool in human tumor cell research. Journal of Cell Biology 67, 117a.

FOGH, J., FOGH, J.M. and ORFEO, T. (1977). One hundred and twenty-seven cultured human tumor cell lines producing tumors in nude mice. Journal of the National Cancer Institute 59, 221 - 225.

FOGH, J., ORFEO, T., TISO, J. and SHARKEY, F.E. (1979). Establishment of human colon carcinoma lines in nude mice. Experimental Cell Biology 47, 136 - 144.

FOLLETT, E.A.C. and GOLDMAN, R.D. (1970). The occurrence of microvilli during spreading and growth of BHK 21 / C13 fibroblasts. Experimental Cell Research 59, 124 - 136.

FREEDMAN, V.H. and SHIN, S. (1974). Cellular tumorigenicity in nude mice: correlation with cell growth in semi-solid medium. Cell 3, 355 - 359.

_____ (1978). Use of nude mice for studies on the tumorigenicity of animal cells. In The nude mouse in experimental and clinical research (eds. J. Fogh and B.C. Giovanella), pp 353 - 384. New York: Academic Press.

FRITHIOF, L. (1972). Ultrastructural changes at the epithelial-stromal junction in human oral preinvasive and invasive carcinoma. In Tissue interactions in carcinogenesis (ed. D. Tarin), pp 161 - 189. New York: Academic Press.

FUCHS, E. and GREEN, H. (1978). The expression of keratin genes in epidermis and cultured epidermal cells. Cell 15, 887 - 897.

GARDNER, D.L. and DODDS, T.C. (1970). Human Histology. 3rd ed. New York: Churchill Livingstone.

GATEI, D.G., ODHIAMBO. P.A., ORINDA, D.A.O., MURUKA, F.J. and WASUNNA, A. (1978). Retrospective study of carcinoma of the esophagus in Kenya. Cancer Research 38, 303 - 307.

GEISINGER, K.R., LEIGHTON, J. and ZEALBERG, J. (1978). Appearance of giant cells as a morphological response of rat bladder carcinoma cell line (Nara bladder tumor No. 2) to a continuous thermal gradient in tissue culture. Cancer Research 38, 1223 - 1230.

GELDERBLOM, H., BAUER, H., OGURA, H., WIGAND, R. and FISCHER, A.B. (1974). Detection of oncornavirus-like particles in Hela cells - fine structure and comparative morphological classification. International Journal of Cancer 13, 246 - 253.

GERSHMAN, H., KATZIN, W. and COOK, R.T. (1978). Mobility of cells from solid tumors. International Journal of Cancer 21, 309 - 319.

GHADIALLY, F.N. (1975). Ultrastructural pathology of the cell. London: Butterworth.

_____, (1980). Diagnostic electron microscopy of tumours. London: Butterworth.

GIARD, D.J., AARONSON, S.A., TODARO, G.J., ARNSTEIN, P., KERSEY, J.H., DOSIK, H and PARKS, W.P. (1973). In vitro cultivation of human tumors: establishment of cell lines derived from a series of solid tumors. Journal of the National Cancer Institute 1, 1417 - 1423.

GILLIS, C.R. (1970). Aetiological hypotheses. In Carcinoma of the Oesophagus (ed. N. Silber), pp 83 - 90. Cape Town: Balkema.

GILLIS, C.R. and CARTER, R.L. (1970). Epidemiology of some human tumours: (2) Oesophagus. In Scientific Foundations of Oncology (ed. T. Symington and R.L. Carter), pp 213 - 223. London: Heinemann Medical.

GILULA, N.B. (1974). Junctions between cells. In Cell Communication (ed. R.P. Cox), pp 1 - 29. New York: John Wiley and Sons.

GIOVANELLA, B.C., YIM, S.O., MORGAN, A.C., STEHLIN, J.S. and WILLIAMS, L.J. Jr. (1973). Metastases of human melanomas transplanted in "nude' mice. Journal of the National Cancer Institute 50, 1051 - 1053.

GIOVANELLA, B.C., STEHLIN, J.S. and WILLIAMS, L.J. (1974). Heterotransplantation of human malignant tumors in "nude" thymusless mice. II. Malignant tumors induced by injection of cell cultures derived from human solid tumors. Journal of the National Cancer Institute 52, 921 - 930.

GIOVANELLA, B.C. and FOGH, J. (1978). Present and future trends in investigations with the nude mouse as a recipient of human tumor transplants. In The nude mouse in experimental and clinical research (ed. J. Fogh and B.G. Giovannella), pp 282 - 312. New York: Academic Press.

GIOVANELLA, B.C., STEHLIN, J.S., WILLIAMS, L.J., LEE, S.S. and SHEPARD, R.C. (1978). Heterotransplantation of human cancers into nude mice: a model system for human cancer chemotherapy. Cancer 42, 2269 - 2281.

GONDA, M.A., AARONSON, S.A., ELLMORE, N., ZEVEY, V.H. and NAGASHIMA, K. (1976). Ultrastructural studies of surface features of human normal and tumor cells in tissue culture by scanning and transmission electron microscopy. Journal of the National Cancer Institute 56, 245 - 263.

GONDOS, B., LAI, C.E. and KING, E.B. (1979). Distinction between atypical mesothelial cells and malignant cells by scanning electron microscopy. Acta Cytologica 23, 321 - 326.

GORDON, G.B., BARCZA, M.A. and BUSH, M.E. (1977). Lipid accumulation in hypoxic tissue culture cells. American Journal of Pathology 88, 663 - 678.

GRANBOULAN, N., TOURNIER, P., WICKER, R. and BERNHARD, W. (1963). An electron microscopic study of the development of SV40 virus. Journal of Cell Biology 17, 403 - 411.

GRANT, A.G., DUKE, D. and HERMON-TAYLOR, J. (1979). Establish-

ment and characterisation of primary human pancreatic carcinomas in continuous cell culture and in nude mice. British Journal of Cancer 39, 143 - 151.

GREEN, H. (1972). Terminal differentiation of cultured human epidermal cells. Cell 11, 405 - 416.

_____. (1976). Cell culture for the study of epithelial cells. National Cancer Institute Monogram 48, 259 - 262.

GREEN, H., RHEINWALD, J.G. and SIEN, T.T. (1977). Properties of an epithelial cell type in culture: the epidermal keratinocyte and its dependence on products of the fibroblast. In Cell shape and surface architecture (ed. J.P. Revel, V. Henning and C.F. Fox), pp 493 - 500. New York: Alan R. Liss Inc.

GREEN, M. (1972). RNA and DNA tumor viruses-mechanism of cell transformation and role in human cancer. In Membranes and Viruses in Immunopathology (ed. S.B. Day and R.A. Good), pp 193 - 216. New York: Academic Press.

HAAG, J.F. and SCOTTENFELD, D. (1978). Epidemiology of esophageal cancer. In Gastrointentinal tract cancer (ed. M. Lipkin and R.A. Good), pp 145 - 169. New York: Plenum Press.

HAFFEJEE, A.A. and ANGORN, I.B. (1979). Nutritional status and the non-specific cellular and humoral immune response in oesophageal carcinoma. Annals of Surgery 189, 475 - 479.

HAJDU, S.I. and FOGH, J. (1978). The nude mouse as a diagnostic tool in human tumor cell research. In The nude mouse in experimental and clinical research (ed. J. Fogh and B.C. Giovanella), pp 235 - 260. New York: Academic Press.

HALLAUER, C. and KRONAUER, G. (1962). Nachweis eines nicht identifizierten Haemag-glutinins in menschliche zellstämmen. Archiv für gesamte Virus forschung 11, [illegible] - 756.

HAM, A.W. (1974). Histology 7th ed. Philadelphia: J.B. Lippincott Company.

HARINGTON, J.S. and BRADSHAW, E. (1978). Cancer of the oesophagus with special reference to goldminers from the Transkei, and to

the Coloured male. In Carcinoma of the oesophagus (ed. W. Silber), pp 43 - 51. Cape Town: Balkema.

HARTMAN, C. and STAVEN, . (1964). ABO blood groups and cancer. Lancet 1, 1305 - 1306.

HASSELL, J. and ENGELHARDT, D.L. (1977). Factors regulating the multiplication of animal cells in culture. Experimental Cell Research 107, 159 - 167.

HAYFLICK, L. (1965). The limited in vitro lifetime of human diploid cell strains. Experimental Cell Research 37, 614 - 636.

_____. (1973). Fetal human diploid cells. In Tissue culture - methods and applications (ed. P.F. Kruse and M.K. Patterson) pp 43 - 50. New York: Academic Press.

HEATFIELD, B.M., SANEFUJI, H. EL-GERZAWI, S., URSO, B. and TRUMP, B.F. (1980). Surface alterations in urothelium of normal human bladder during long-term explant culture. Scanning Electron Microscopy / 1980 / III, 61 - 70.

HIGGINSON, J. and OETTLE A.G. (1960). Cancer incidence in the Bantu and "Cape Coloured" races of S.A.: report of a cancer survey in the Transvaal. Journal of the National Cancer Institute 24, 589 - 671.

HOGAN, B. (1979). Epithelial cancer, differentiation and vitamin A. Nature 277, 261 - 262.

HOPWOOD, D., LOGAN, K.R., COGHILL, G. and BOUCHIER, I.A.D. (1977). Histochemical studies of mucosubstances and lipids in normal human oesophageal epithelium. Histochemical Journal 9, 153 - 161.

HOPWOOD, D., LOGAN, K.R. and BOUCHIER, I.A.D. (1978). The electron microscopy of normal human oesophageal epithelium. Virchows Archiv B. Cell Pathology 26, 345 - 358.

HOPWOOD, D., MILNE, G. and LOGAN, K.R. (1979). Electron microscopic changes in human oesophageal epithelium in oesophagitis. Journal of Pathology 129, 161 - 167.

HUGICK, H.L. (1976). Spontaneous cell loss during growth of post-confluent primary cultures from mammary adenocarcinomas. Cancer Research 36, 3126 - 3130.

HOWARD, B.V. and HOWARD, W.J. (1975). Lipids in normal and tumor cells in culture. Progress in Biochemical Pharmacology 10, 135 - 166.

HOWELL-EVANS, W., MC CONNELL, R.P., CLARK, C.A. and SHEPHERD, P.M. (1958). Carcinoma of the oesophagus with keratosis palmaris et plantaris (tylosis). Quarterly Journal of Medicine 27, 413 - 429.

HULL, R.N., WEAVER, G. and CHERRY, W.R. (1973). Monkey kidney cells. In Tissue culture - methods and applications (ed. P.F. Kruse and M.K. Patterson), pp 97 - 101. New York: Academic Press.

HUMASON, G. (1972). Animal Tissue Techniques 3rd ed. San Francisco: W.H. Freeman and Company.

IKEUCHI, S., SHIMOSATO, Y., KAMEYA, T., WATANABE, S., KAKEGAWA, T. and ABE, O. (1980). Cell kinetic study of human cancers transplanted to nude mice. Experimental Cell Biology 48, 213 - 228.

IOACHIM, H.L. (1978). The stromal reaction of tumors: an expression of immune surveillance. Journal of the National Cancer Institute 57, 465 - 475.

JAFFREY, B.J., LAIR, V.S., HUDSON, J.W., LOZZIO, B.B., MACHADO, E.A. and CHASE, D.C. (1979). Heterotransplantation of human neoplasms. Journal of Oral Surgery 37, 16 - 20.

JARRETT, W.F. (1973). Oesophageal and stomach cancer in cattle: a candidate viral and carcinogen model system and its possible relevance to man. British Journal of Cancer 28, 93.

JEREB, B., TOURNADE, M.F., LEMERLE, J., VOUTE, P.A., DELEMARRE, J.F., AHSTROM, L., FLAMANT, R., LEMERLE-MARCHANT, R. and SANDSTEDT, B. (1980). Lymph node invasion and prognosis in nephroblastoma. Cancer 45, 1632 - 1636.

JESSEN, H. (1970). Two types of keratohyalin granules. Journal of Ultrastructure Research 33, 95 - 115.

JOINT IRAN NATIONAL AGENCY FOR RESEARCH ON CANCER STUDY GROUP (1977). Esophageal cancer studies in the Caspian littoral of Iran: results of population studies - a prodrome. Journal of the National Cancer Institute 59, 1127 - 1138.

JUNQUEIRA, L.L., CARNEIRO, J. and CONTOPOULOS, A.N. (1977). Basic Histology 2nd ed. Los Altos: Lange.

KADIN, M.E. and BENSCH, K.G. (1971). On the origin of Ewing's tumour. Cancer 27, 237 - 253.

KAIGHN, E.M. (1973). Human liver cells. In Tissue culture - methods and applications (ed. P.F. Kruse and M.K. Patterson), pp 54 - 57. New York: Academic Press.

KAIRAKBAEV, M.K. and NASIROV, S.N. (1980). Esophageal cancer morbidity among the population of Gur'vesk province. Voprosi Oncologii 26, 84 - 87.

KARNOVSKY, M.J. (1965). A formaldehyde-glutaraldehyde fixative of high osmolarity for use in electron microscopy. Journal of Cell Biology 27, 137.

KATSUOKA, Y., BABA, S. and HATA, M. (1976). Transplantation of human renal cell sarcoma to nude mice: an intermediate of in vivo and in vitro studies. Journal of Urology 115, 373 - 376.

KEEN, P. (1970). The changing pattern of cancer in South Africa. In Carcinoma of the oesophagus (ed. W. Silber), pp 52 - 59. Cape Town: Balkema.

KEEN, L.N., WHITTLE, W.L. and KRUSE, P.F. (1973). Vertical sectioning B cells in plastic flasks. In Tissue culture - methods and applications (ed. P.F. Kruse and M.K. Patterson), pp 448 - 451. New York: Academic Press.

KESSEL, R.G. and KARDON, R.D. (1979). Tissues and organs: A text atlas of scanning electron microscopy. San Francisco: W.H. Freeman and Company.

KIRKLAND, W.L., YANG, N-S., JORGENSEN, T., LONGLEY, C. and FURMANSKI, P. (1979). Growth of normal and malignant human mammary epithelial cells in culture. Journal of the National Cancer Institute 63, 29 - 41.

KLEIN, J.C. (1976). Behaviour of tumour cells in monolayer culture. In Human tumours in short term culture (ed. P.P. Dendy), pp 85 - 87. London: Academic Press.

KNOWLES, M.A. and FRANKS, L.M. (1978). Ultrastructure and biological markers of neoplastic change in adult mouse epithelial cells transformed in vitro. British Journal of Cancer 37, 603 - 611.

KRISHAN, A. (1971). Fine structure of cytochalasin- induced multinucleated cells. Journal of Ultrastructure Research 36, 191 - 204.

KUMEGAWA, M., CATTONI, M. and ROSE, G.G. (1968). Electron microscopy of oral cells in vitro. II Subsurface and intracytoplasmic confronting cisternae in strain KB cells. Journal of Cell Biology 36, 443 - 452.

KYRIAZIS, A.[illegible]., DIPERSIO, L., MICHAEL[illegible]G.J., PESCE, A.J. and STINNETT, J.D. (1978). Growth patterns and metastatic behaviour of human tumors growing in athymic mice. Cancer Researcr 38, 3186 - 3190.

LABORATORY SECTION, DEPARTMENT OF SURGERY, PEKING MEDICAL COLLEGE, PEKING (1976). Establishment of a cell line from human esophageal carcinoma. Chinese Medical Journal 2, 357 - 364.

LANMAN, M.J.S. (1971). Epidemiology of cancer of the oesophagus and stomach. British Journal of Surgery 58, 792 - 793.

LAUDER, I., AHERNE, W. and STEWART, J. (1977). Macrophage infiltration of breast tumours: a prospective study. Journal of Clinical Pathology 30, [illegible] - [illegible].

LAZARIDES, E. (1980). Intermediate filaments as mechanical integrators of cellular space. Nature 1[illegible], 283 (5744), 249 - 256.

LEAK, L.V., CAULFIELD, J.B., BURKE, J.F. and MCKHANN, C.F. (1967). Electron microscopic studies on a human fibromyxosarcoma. Cancer Research 27, 261 - 285.

LE BEUX, J.Y. (1969). An unusual ultrastructural association of smooth membranes and glycogen particles: the glycogen body. Zeitschrift für Zellforschung und mikroskopische Anatomie 101, 433 - 447.

LEESON, T.S. and LEESON, C.R. (1970). Histology. 2nd ed. Philadelphia: W.B. Saunders Company.

LEVINSON, D.A., HOPWOOD, D., MORGAN, R.G.H., COGHILL, G., MILNE, G.A. and WORMSLEY, K.G. (1979). Oesophageal neoplasia in male Wistar rats due to parenteral Di (2 - hydroxypropyl)-Nitrosamine (DHPN): a combined histopathological, histochemical and electron microscopic study. Journal of Pathology 129, 31 - 36.

LIMBURG, H. (1964). Die zuchtung von menschem krebsgewebe in der gewebe kultur und seine sensibilitats-testung gegan newere zytostatika. Deutsche Medizinische Wochenschrift 89, 1938 - 1946.

LIMBURG, H. and HECKMAN, U.J. (1968). Chemotherapy in the treatment of advanced pelvic malignant disease with special reference to ovarian cancer. Journal of Obstetrics and Gynaecology of the British Commonwealth 75, 1246 - 1255.

LITTLEFIELD, L.G. and MAILHES, J.B. (1975). Observations of de novo clones of cytogenetically aberrant cells in primary fibroblast cell strains from phenotypically normal women. American Journal of Human Genetics 27, 190 - 197.

LOGAN, K.R., HOPWOOD, D. and MILNE, G. (1977). Ultrastructural demonstration of cell coat on the surfaces of normal human oesophageal epithelium. Histochemical Journal 9, 495 - 504.

_____,(1978). Cellular junctions in human oesophageal epithelium. Journal of Pathology 126, 153 - 167.

LOWENFELS, A.B. and ANDERSON, M.E. (1977). Diet and cancer.

Cancer 39, 1808 - 1814.

LUTZNER, M.A. (1967). Virus diseases. In Ultrastructure of normal and abnormal skin (ed. A.S. Zelickson), pp 365 - 387. Philadelphia: Lea and Febiger.

MAGEE, P.N. and BARNES, J.M. (1956). The production of malignant primary hepatic tumours in the rat by feeding dimethynitrosamine. British Journal of Cancer 10, 114 - 122.

_____. (1967). Carcinogenic nitroso compounds. Advances in Cancer Research 10, 163 - 246.

MAISTRY, L. (1980). Detection, isolation and attempted elimination of mycoplasmas from human cell cultures. B.Sc. (Hons.) project, University of Natal, Durban.

MAISTRY, L. and ROBINSON, K.M. (1980). Scanning and transmission electron microscopy of mycoplasma orale in human cell cultures. Proceedings of the Electron Microscopy Society of Southern Africa 10, 119 - 120.

MAISTRY, L., ROBINSON, K.M., EVERS, P., MUNDER, P.G. and ANDREESEN, R. (1980). Morphological effects of an antitumor agent on esophageal carcinoma cells in vitro. Scanning Electron Microscopy / 1980 / III, 109 - 114.

MARCELO, C.L., KIM, Y.G., KAINE, J.L. and VOORHEES, J.J. (1978). Stratification, specialisation and proliferation of primary keratinocyte cultures. Journal of Cell Biology 77, 356 - 370.

MAREEL, M.M.K. (1979). Is invasiveness in vitro characteristic of maligrant cells? Cell Biology International Reports 3, 627 - 640.

MARTIN, G.M. (1973). Human skin fibroblasts. In Tissue culture - methods and applications (ed. P.F. Kruse and M.K. Patterson), pp 39 - 43. New York: Academic Press.

MAUL, G.G. (1977). Annulate lamellae and single pore complexes in normal, SV 40 transformed and tumor cells in vitro. Experimental Cell Research 104, 233 - 245.

MC GLASHAN, N.D. (1977). The oesophageal carcinoma problem in Transkei: a geographical reappraisal. South African Journal of Science 73, 294 - 299.

MC GARRITY, G.J., MURPHY, D.G. and NICHOLS, W.W. (1978). Mycoplasma infection of cell cultures. New York: Plenum Press.

MC NULTY, M.S., CURRAN, W.L., ALLAN, G.M. and MC FERRAN, J.B. (1978). Synthesis of careless, probably defective virus particles in cell cultures infected with rotaviruses. Archives of Virology 58, 193 - 202.

MEISSNER, W.A. and WARREN, S. (1971). Neoplasia. In Pathology 6th ed. (ed. W.A.D. Anderson and J.M. Kissane), pp 539 - 561. St. Louis: C.V. Mosby Company.

MERKOW, L.P., SLIFKIN, M., PARDO, M. and RAPOZA, N.P., (1970). Pathogenesis of oncogenic simian adenoviruses. VII The origin of annulate lamella in LLC-MK2 cells infected with SV 30. Journal of Ultrastructure Research 30, 344 - 353.

MILLER, R.W. (1978). Cancer epidemics in the Peoples' Republic of China. Journal of the National Cancer Institute 60, 1195 - 1203.

MINGXIN, L., SHIXIN, L. CHAUN, J., MINGYAO, W., SHUJUN, L. and CHANGLIAN, J. (1979). Formation of carcinogenic N-nitroso compounds in corn-bread inoculated with fungi. Scientia Sinica 22, 471 - 477.

MINGXIN, L., PING, L. and BARONG, L. (1980). Recent progress in research on esophageal cancer in China. Advances in Cancer Research 33, 173 - 248.

MIYAI, K., SLUSSER, R.J. and RUEBNER, B.H. (1963). Viral hepatitis in mice: electron microscopic study. Experimental and Molecular Pathology 2, 464 - 480.

MORASCA, L., BALCONI, G. and ERBA, E. (1976). Advances in morphological identification of cell types in primary culture. In Human tumours in short term culture (ed. P.P. Dendy), pp 79 - 84. London: Academic Press.

NICHOLSON, G.L., ROBBINS, J.C. and WINKELHAKE, J.L. (1975). Tumor cell surfaces and metastasis: dynamic changes in neoplastic membrane structure and their relation to tumor spread. In Cellular Membranes and tumor cell behaviour (Anderson Symposium No. 28), pp 81 - 127. Baltimore: Williams and Wilkins Company.

NILSSON, K., GIOVANELLA, B.C., STEHLIN, J.S. and KLEIN, G. (1977). Tumorigenicity of human hematopoietic cell lines in athymic nude mice. International Journal of Cancer 19, 337 - 344.

NISHIHIRA, T., KASAI, M., MORI, S., WATANABE, T., KURIYA, Y., SUDA, M., KITAMURA, M., HIRAYAMA, K., AKAISHI, T. and SASAKI, T. (1979). Characteristics of two cell lines (TE - 1 and TE - 2) derived from human squamous cell carcinoma of the oesophagus. Gann 70, 575 - 584.

NUNN, A.J., NUNN, J.R. and ROACH, W.A. (1978). Nitrosamines in relation to carcinoma of the oesophagus. In Carcinoma of the Oesophagus (ed. W. Silber), pp 99 - 104. Cape Town: Balkema.

OBERLING, C.H. and BERNHARD, W. (1961). The morphology of the cancer cells. In The Cell (ed. J. Brachet and A.E. Mirsky), pp 405 - 496. New York: Academic Press.

OVERTON, J. (1968). The fate of desmosomes in trypsinised tissue. Journal of Experimental Zoology 168, 203 - 214.

OWENS, R.B. (1976). Selective cultivation of mammalian epithelial cells. In Methods in Cell Biology XIV (ed. D.M. Prescott), pp 341 - 355. New York: Academic Press.

OWENS, R.B., SMITH, H.S. and NELSON-REES, W.A. (1977). Epithelial cell cultures from normal and cancerous human tissues. Journal of the National Cancer Institute 56, 834 - 839.

OZZELLO, L. and SORDAT, M. (1980). Behaviour of tumors produced by transplantation of human mammary cell lines in athymic nude mice. European Journal of Cancer 16, 553 - 559.

PANTELOURIS, E.M. (1968). Absence of thymus in a mouse mutant. Nature 217, 370 - 371.

PARKIN, J.L. and BRUNNING, R.D. (1978). Unusual configuration of endoplasmic reticulum in cells of acute promyelocytic leukemia. Journal of the National Cancer Institute 61, 341 - 347.

PARSHAD, R. and SANFORD, K.K. (1968). Effect of horse serum, fetal calf serum, calf serum, bovine serum and fetuin on neoplastic conversion and chromosomes of mouse embryo cells in vitro. Journal of the National Cancer Institute 41, 767 - 779.

PATRIZI, G. and MIDDELKAMP, J.N. (1969). In vivo and in vitro demonstration of nuclear bodies in vaccinia infected cells. Journal of Ultrastructure Research 28, 275 - 287.

PAUL, J. (1975). Cell and Tissue Culture 5th ed. Edinburgh: Churchill Livingstone.

PAULI, B.U., SAMUEL COHEN, M., ALROY, J. and WEINSTEIN, R.S. (1978). Desmosome ultrastructure and the biological behaviour of chemical carcinogen-induced urinary bladder carcinomas. Cancer Research 38, 3276 - 3285.

PEARSON, J.G. and LE ROUX, B.J. (1974). Malignant tumors of the esophagus. In Handbuck der inneren Medizin 3/1. Diseases of the Esophagus (ed. G. Vantrappen and J. Hellemans), pp 447 - 492. Berlin: Springer-Verlag.

PERRE, J. and FONCIN, J.F. (1977). Embedding method for monolayer cell cultures for light and electron microscopy. Stain Technology 52, 240 - 242.

PETTENGILL, O.S., CURPHEY, T.J., CATE, C.C., FLINT, O.F., MAURER, L.H. and SORENSON, G.D. (1980). Animal model for small cell carcinoma of the lung. Effect of immunosuppression and sex of mouse on tumor growth in nude athymic mice. Experimental Cell Biology 48, 279 - 297.

PLOWRIGHT, W., LINSELL, C.A. and PETERS, F.G. (1971). A focus of

rumenal cancer in Kenyan cattle. British Journal of Cancer 25, 72 - 80.

POVLSEN, C.O. and RYGAARD, J. (1971). Heterotransplantation of human adenocarcinomas of the colon and rectum to the mouse mutant nude. A study of consecutive transplantation. Acta Pathologica et Microbiologica Scandinavica A 79, 139 - 158.

POVLSEN, C.O. (1976). Heterotransplantation of human malignant melanomas to the mouse mutant nude. Acta Pathologica et Microbiologica Scandinavica A 84, 9 - 16.

PRIEST, J.H. (1977). Medical Cytogenics and Cell Culture 2nd ed. Philadelphia: Lea and Febiger.

PRITCHARD, H. and MICKLEM, H.S. (1974). The nude (nu/nu) mouse as a model of thymus and T-lymphocyte deficiency. In Proceedings of the first international workshop on nude mice (ed. J. Rygaard and C.O. Povlsen), pp 127 - 139. Stuttgart: Springer-Verlag.

QIZILBASH, A. and STEVENSON, G.W. (1979). Early gastric cancer. Pathology Annual 14, 317 - 351.

QIZILBASH, A.H., CASTELLI, M., KOWALSKI, M.A. and CHURLY, A. (1980). Endoscopic brush cytology and biopsy in the diagnosis of cancer of the upper gastrointestinal tract. Acta Cytologica 24, 313 - 318.

RABIN, H., NEUBAUER, R.H., GONDA, M.A., NELSON-REES, W.A., CHARMAN, H.P. and VALERIO, M.G. (1978). Spontaneous esophageal carcinoma and epithelial cell line of an adult Rhesus monkey. Cancer Research 38, 3310 - 3314.

RABIN, H., BENTON, C.V., TAINSKY, M.A., RICE, N.R. and GILDEN, R.V. (1979). Isolation and characterisation of an endogenous type C virus of Rhesus monkeys. Science 204, 841 - 842.

RABIN, H., GONDA, M.A., BENTON, C.V. and ROBINSON, K.M. (1981). Cell culture studies of simian and human esophageal carcinoma. In Carcinoma of the Esophagus - an international review (ed. C. Pfeiffer) in press. Boca Raton: CRC Press.

REID, L.M., HOLLAND, J., JONES, C., WOLF, B., NIWAYAMA, G., WILLIAMS, R., KAPLAN, N.O. and SATO, G. (1978). Some of the variables affecting the success of transplantation of human tumors into the athymic nude mouse. In Proceedings of the symposium on the use of athymic (nude) mice in cancer research (ed. D.P. Houchens and A.A. Ovejera), pp 107 - 121. New York: Gustav Fischer.

REID, L. and SHIN, S. (1978). Transplantation of heterologous endocrine tumor cells in nude mice. In The nude mouse in experimental and clinical research (ed. J. Fogh and B.C. Giovanella), pp 313 - 351. New York: Academic Press.

REITH, A., PUNTERVOLD, R. and SAXHOLM, H.J.K. (1980). A quantitative SEM study of microvilli in interphase and mitosis of carcinogen-transformed fibroblasts. Scanning Electron Microscopy / 1980 / III, 23 - 28.

REYNOLDS, E. (1963). The use of lead citrate of high pH as an electron opaque stain in electron microscopy. Journal of Cell Biology 17, 208 - 212.

RHEINWALD, J.G. and GREEN, H. (1975). Serial cultivation of strains of human epidermal keratinocytes: the formation of keratinising colonies from single cells. Cell 6, 331 - 344.

RHEINWALD, J.G. (1979). The role of terminal differentiation in the finite culture lifetime of the human epidermal keratinocyte. International Review of Cytology 10, 25 - 33.

RHODIN, J.A.G. (1963). An atlas of ultrastructure. Phildelphia: W.B. Saunders Company.

_____. (1974). Histology: a text and atlas. New York: Oxford University Press.

RIBET, A. (1980). Cancer of the esophagus: role of dietetic factors. Gazette Médicale de France 87, 2937 - 2939.

RICARD, M.A. and HAY, R.J. (1976) Proliferation and agglutinability of primary and transformed human epithelial cells in culture. Journal of Cell Science 21, 553 - 561.

ROBBINS, S.L. (1974). Pathologic basis of disease. Philadelphia: W.B. Saunders Company.

ROBINSON, K.M. and GREGORY, M.A. (1977). Ultrastructural features of cultured carcinoma of the oesophagus cells. Proceedings of the Electron Microscopy Society of Southern Africa 7, 125 - 126.

_____, (1978). Ultrastructural features of oesophageal tumours. Proceedings of the Electron Microscopy Society of Southern Africa 8, 47 - 48.

_____. (1981). Transmission electron microscopy of human oesophageal carcinomas. Journal of Pathology, in press.

ROBINSON, K.M., GREGORY, M.A., NUSS, D. and KASVALU, K.M. (1980)a. Growth patterns, ultrastructure and chromosomal constitution of normal kidney and nephroblastoma cells in short-term culture. Journal of Pediatric Surgery 15, 297 - 302.

ROBINSON, K.M., MAISTRY, L., EVERS, P. and BUX, S. (1980)b. Morphology of an esophageal carcinoma cell line before and after transplantation into nude mice. Scanning Electron Microscopy / 1980 / II, 231 - 238.

ROBINSON, K.M., HAFFEJEE, A.A. and ANGORN, I.B. (1980)c. Tissue culture and prognosis in carcinoma of the oesophagus. Clinical Oncology 6, 125 - 136.

ROBINSON, K.M. and MAISTRY, L. (1981). Scanning and transmission electron microscopy of continuous human esophageal carcinoma cell lines. In Cancer of the Esophagus - an international review (ed. C. Pfeiffer), in press. Boca Raton: CRC Press.

ROHL, L. (1959). Prostatic hyperplasia and carcinome studied with tissue culture technique. Acta Chirurgica Scandinavica, Supplement, 240 - 247.

ROSE, E.F. (1973). Oesophageal cancer in the Transkei 1955 - 1967. Journal of the National Cancer Institute 51, 7 - 15.

_____. (1978). Patterns of occurrence of oesophageal cancer with particular reference to the Transkei. In

Carcinoma of the Oesophagus (ed. W. Silber) pp 35 - 42. Cape Town: Balkema.

ROSE, E.F. and MC GLASHAN, N.D. (1975). The spatial distribution of oesophageal cancer in the Transkei, South Africa. British Journal of Cancer 31, 197 - 206.

ROUNDS, D.E. (1970). A growth modifying factor from cell lines of human malignant origin. Cancer Research 30, 2847 - 2851.

ROUSSEAU, M.F., NABARRA, B. and NEZELOF, C. (1974). Behaviour of Wilms tumour and normal metanephros in organ culture. European Journal of Cancer 10, 461 - 466.

RUBEN, R.L. and RAFFERTY, K.A. (1978). Colony formation by simian virus 40-transformed human parapharyngeal cells cultured in semi solid agar. Journal of the National Cancer Institute 61, 993 - 1000.

RUBIN, P. (1973). Cancer of the gastrointestinal tract. Journal of the American Medical Association 226, 24 - 31.

RYBICKA, K. (1978). Ultrastructural study on the extrusion of multivesicular bodies from cardiac cells. Virchows Archiv B. Cell Pathology 28, 119 - 133.

RYGAARD, J. and POVLSEN, C.O. (1969). Heterotransplantation of a human malignant tumour to nude mice. Acta Pathologica et Microbiologica Scandinavica A 77, 758 - 760.

RYGAARD, J. (1978). The nude mouse - background, some achievements and implications. In The nude mouse in experimental and clinical research (ed. J. Fogh and B.C. Giovanella), pp 75 - 109. New York: Academic Press.

SADEGHI, A., BEHMARD, S., GHAFIEPOOR, H. and ZEIGHMANI, E. (1977). Cancer of the oesophagus in southern Iran. Cancer 40, 841 - 845.

SALSBURY, A.J. (1975). The significance of the circulating cancer cell. Cancer Treatment Reviews 2, 55 - 72.

SATTLER, C.A., MICHALOPOULOS, G., SATTLER, G.L. and PITOT, H.C.

(1978). Ultrastructure of adult rat hepatocytes cultured on floating collagen membranes. Cancer Research 38, 1539 - 1549.

SCHAEFFER, W.I. (1969). Proposed useage of animal tissue culture terms (revised 1978). Usage of vertebrate cell, tissue and organ culture terminology. In Vitro 15, 64[illegible] - 653.

SCHLESINGER, H.R., GERSON, J.M., MOORHEAD, P.S., MAGUIRE, H. and HUMMELER, K. (1976). Establishment and characterisation of human neuroblastoma cell lines. Cancer Research 36, 3094 - 3100.

SCHOENTAL, R. (1980). Cancer of the digestive tract and mycotoxins of Fusarium species. Lancet 2 (8194), 593.

SCHOTTENFELD, D. (1975). Cancer epidemiology and prevention (Current concepts). Springfield: Charles C. Thomas.

SEIJI, M. and MIZUNO, F. (1969). Electron microscopic study of Bowen's disease. Archives of Dermatology 99, 3 - 16.

SETHI, J., HIRSHAUT, Y., HAJDU, S. and CLEMENTS, L.G. (1977). Growing human sarcomas in culture. Cancer 40, 744 - 755.

SHARKEY, F.E., FOGH, J.M. and HAJDU, S. (1978). Experience in surgical pathology with human tumor growth in the nude mouse. In The nude mouse in experimental and clinical research (ed. J. Fogh and B.C. Giovanella), pp 188 - 214. New York: Academic Press.

SHARKEY, F.E. and FOGH, J. (1979). Incidence and pathological features of spontaneous tumors in athymic nude mice. Cancer Research 39, 833 - 839.

SHIMOSATO, Y., KAMEYA, T. and HIROHASHI, S. (1979). Growth, morphology and function of xenotransplanted human tumors. Pathology Annual 14, 215 - 2[illegible].

SHIN, S-L., FREEDMAN, V.H., RISSER, R. and POLLACK, R. (1975). Tumorigenicity of virus-transformed cells in nude mice is correlated specifically with anchorage independent growth in vitro. Proceedings of the National Academy of Sciences of

the U.S.A. 72, 4435 - 4439.

SHIN, S. (1979). Use of nude mice for tumorigenicity testing and mass propagation. Methods in Enzymology 58, 371 - 376.

SHONLAND, M. and BRADSHAW, E. (1968). Cancer in the Natal African and Indian 1964 - 1966. International Journal of Cancer 3, 304 - 316.

SILBER, W. (1978). History of carcinoma of the oesophagus. In Carcinoma of the Oesophagus (ed. W. Silber), pp 1 - 3. Cape Town: Balkema.

SMITH, H.S. (1978). In vitro properties of epithelial cell lines established from human carcinomas and non-malignant tissue. Journal of the National Cancer Institute 62, 225 - 230.

SOBEL, H.J. and MARQUET, E. (1980). Usefulness of electron microscopy in the diagnosis of tumors. Pathology, Research and Practice 167, 22 - 44.

SOBEL, J.D., TCHAO, R., BOZZOLA, J., LEVISON, M.E. and KAYE, D. (1979). Human vaginal epithelial multilayer tissue culture. In Vitro 15, 993 - 1000.

SPIE, J.C. and O'BRIEN, J.S. (1979). Ultrastructure of skin biopsy specimens in lysosomal storage diseases: common sources of error in diagnosis. Clinical Genetics 15, 115 - 125.

STANBRIDGE, E.J. and PERKINS, F.T. (1977). Tumorigenicity testing in immunosuppressed mice: advantages and disadvantages. Development in Biological Standardisation 37, 211 - 217.

STANBRIDGE, E.J., PERKINS, F.T. and HAYFLICK, L. (1973). Cell tumorigenicity detected by heterotransplantation into mice immunosuppressed with anti-lymphocyte serum. Progress in Immunobiology 3, 243 - 251.

STILES, C.D., DESMOND, W., CHUMAN, L.M., SATO, G. and SAIER, M.H.Jr. (1976)a. Growth control of heterologous tissue culture cells in the congenitally athymic nude mouse. Cancer Research 36, 1353 - 1360.

_____. (1976)b. Relationship of cell growth and behaviour in vitro to tumorigenicity in athymic nude mice. Cancer Research 36, 3300 - 3305.

STUTMAN, O. (1979). Chemical carcinogenesis in nude mice: comparison between nude mice from hetetozygous matings and homozygous matings and the effect of age and carcinogen dose. Journal of the National Cancer Institute 62, 353 - 358.

SUGAR, J. (1972). Ultrastructural and histochemical changes during the development of cancer in various human organs. In Tissue interactions in carcinogenesis (ed. D. Tarin), pp 127 - 159. New York: Academic Press.

SUN, C.N. and WHITE, H.J. (1979). Annulate lamellae in human tumor cells Tissue and Cell 11, 139 - 146.

SUN, T-T. and GREEN, H. (1976). Differentiation of the epidermal keratinocyte in cell culture: formation of the cornified envelope. Cell 9, 511 - 521.

_____. (1978). Immunofluorescent staining of keratin fibres in cultured cells. Cell 14, 469 - 476.

SVENNEVIG, J.L. and SVAAR, H. (1979). Content and distribution of macrophages and lymphocytes in solid malignant human tumors. International Journal of Cancer 24, 754 - 759.

SYVERTON, J.T. and MC LAREN, L.C. (1957). Human cells in continuous culture I. Derivation of cell strains from esophagus, palate, liver and lung. Cancer Research 17, 923 - 926.

TAKITA, H., VINCENT, R.G., CAICEDO, J. and GUTIERREZ, A.C. (1977). Squamous cell carcinoma of the esophagus: a study of 152 cases. Journal of Surgical Oncology 9, 247 - 254.

TARIN, D. (1972). Morphological studies on the mechanism of carcinogenesis. In Tissue interactions in carcinogenesis (ed. D. Tarin), pp 225 - 269. New York: Academic Press.

TICKLE, C., CRAWLEY, A. and GOODMAN, M. (1979). Mechanisms of invasiveness of epithelial tumors. Ultrastructure of the interactions of carcinoma cells with embryonic mesenchyme and

_____. (1976)b. Relationship of cell growth and behaviour in vitro to tumorigenicity in athymic nude mice. Cancer Research 36, 3300 - 3305.

STUTMAN, O. (1979). Chemical carcinogenesis in nude mice: comparison between nude mice from hetetozygous matings and homozygous matings and the effect of age and carcinogen dose. Journal of the National Cancer Institute 62, 353 - 358.

SUGAR, J. (1972). Ultrastructural and histochemical changes during the development of cancer in various human organs. In Tissue interactions in carcinogenesis (ed. D. Tarin), pp 127 - 159. New York: Academic Press.

SUN, C.N. and WHITE, H.J. (1979). Annulate lamellae in human tumor cells. Tissue and Cell 11, 139 - 146.

SUN, T-T. and GREEN, H. (1976). Differentiation of the epidermal keratinocyte in cell culture: formation of the cornified envelope. Cell 9, 511 - 521.

_____. (1978). Immunofluorescent staining of keratin fibres in cultured cells. Cell 14, 469 - 476.

SVENNEVIG, J.L. and SVAAR, H. (1979). Content and distribution of macrophages and lymphocytes in solid malignant human tumors. International Journal of Cancer 24, 754 - 758.

SYVERTON, J.T. and MC LAREN, L.C. (1957). Human cells in continuous culture I. Derivation of cell strains from esophagus, palate, liver and lung. Cancer Research 17, 923 - 926.

TAKITA, H., VINCENT, R.G., CAICEDO, V. and GUTIERREZ, A.C. (1977). Squamous cell carcinoma of the esophagus: a study of 153 cases. Journal of Surgical Oncology 9, 547 - 564.

TARIN, D. (1972). Morphological studies on the mechanism of carcinogenesis. In Tissue interactions in carcinogenesis (ed. D. Tarin), pp 227 - 289. New York: Academic Press.

TICKLE, C., CRAWLEY, A. and GOODMAN, M. (1977). Mechanisms of invasiveness of epithelial tumors. Ultrastructure of the interactions of carcinoma cells with embryonic mesenchyme and

epithelium. Journal of Cell Science 33, 133 - 155.

TOBIAS, P.V. (1956). Chromosomes, sex cells and evolution in a mammal. London: Lund Humphries and Company.

TRUMP, B.F., HEATFIELD, B.M., PHELPS, P.C., SANEFUJI, H. and SHAMSUDDIN, A.K. (1980). Cell surface changes in pre-neoplastic and neoplastic epithelium. Scanning Electron Microscopy / 1980/ III, 43 - 60.

TUYNS, A.J., PEQUIGNOT, G. and ABBATUCCI, J.S. (1979). Oesophageal cancer and alcohol consumption; importance of type of beverage. International Journal of Cancer 23, 443 - 447.

VAN REENSBURG, S.J. (1978). The effect of food, beer and snuff used by high oesophageal carcinoma incidence populations on the rat oesophagus. In Carcinoma of the oesophagus (ed. W. Silber), pp 105 - 111. Cape Town: Balkema.

VAN DIGGELEN, O.P., SHIN, S. and PHILLIPS, D.M. (1977a). Reduction in cellular tumorigenicity after mycoplasma infection and elimination of mycoplasma from infected cultures by passage in nude mice. Cancer Research 37, 2680 - 2687.

VAN DIGGELEN, O.P., PHILLIPS, D.M. and SHIN, S-I. (1977b). Endogenous HPRT activity in a cryptic strain of mycoplasma and its effect on cellular resistance to selective media in infected cell lines. Experimental Cell Research 106, 191 - 203.

VASILIEV, J.M. and GELFAND, I.M. (1977). Mechanisms of morphogenesis in cell cultures. International Review of Cytology 50, 159 - 274.

VILARDELL, F. (1974). Exfoliative cytology of the esophagus. In Handbuch der inneren Medizin 3/1. Diseases of the Esophagus (ed. G. Vantrappen and J. Hellemans), pp 213 - 234. Berlin: Springer-Verlag.

VISFELDT, J., HOVLSEN, C.O. and RYGAARD, J. (1972). Chromosome analyses of human tumors following hetero-transplantation to the mouse mutant nude. Acta Pathologica et Microbiologica

epithelium. Journal of Cell Science 33, 133 - 155.

TOBIAS, P.V. (1956). Chromosomes, sex cells and evolution in mammal. London: Lund Humphries and Company.

TRUMP, B.F. BEATFIELD, B.M., PHELPS, P.C., SANEFUJI, H. and SHAMSUDDIN, A.K. (1980). Cell surface changes in preneoplastic and neoplastic epithelium. Scanning Electron Microscopy / 1980/ III, 43 - 50.

TUYNS, A.J., PEQUIGNOT, G. and ABBATUCCI, J.S. (1979). Oesophageal cancer and alcohol consumption; importance of type of beverage. International Journal of Cancer 23, 443 - 447.

VAN RENSBURG, S.J. (1978). The effect of food, beer and snuff used by high oesophageal carcinoma incidence populations on the rat oesophagus. In Carcinoma of the Oesophagus (ed. W. Silber), pp 105 - 111. Cape Town: Balkema.

VAN DIGGELEN, O.P., SHIN, S. and PHILLIPS, D.M. (1977a). Reduction in cellular tumorigenicity after mycoplasma infection and elimination of mycoplasma from infected cultures by passage in nude mice. Cancer Research 37, 2680 - 2687.

VAN DIGGELEN, O.P., PHILLIPS, D.M. and SHIN, S-I. (1977b). Endogenous HPRT activity in a cryptic strain of mycoplasma and its effect on cellular resistance to selective media in infected cell lines. Experimental Cell Research 106, 191 - 203.

VASILIEV, J.M. and GELFAND, I.M. (1977). Mechanisms of morphogenesis in cell cultures. International Review of Cytology 50, 159 - 274.

VILARDELL, F. (1974). Exfoliative cytology of the esophagus. In Handbuch der Inneren Medizin 3/1. Diseases of the Esophagus (ed. G. Vantrappen and J. Hellemans), pp 218 - 234. Berlin: Springer-Verlag.

WISFELDT, J., POVLSEN, C.O. and MYGAARD, J. (1978). Chromosome analyses of human tumors following hetero-transplantation to the mouse mutant nude. Acta Pathologica et Microbiologica

Scandinavica 80, 169 - 17[illegible]

VOIGT, W.H. and FUSENIG N.E. (1979). Organotypic differentiation of mouse keratinocytes in cell culture: a light and electron microscopic study. Biologie Cellulaire 34, 111 - 118.

WANSON, J.C., PENASSE, W., BERNAERT, D. and MAY, C. (1980). SEM study of adult rat hepatocytes from preneoplastic and hyperplastic foci induced in the liver by diethylnitrosamine. Scanning Electron Microscopy / 1980 / III, 29 - 34.

WARWICK, G.P. and HARINGTON, J.S. (1979). Some aspects of the epidemiology and etiology of esophageal cancer with particular emphasis on the Transkei, South Africa. Advances in Cancer Research 17, 82 - 229.

WEISS, L. and GREEP, R.O. (1977). Histology 4th ed. New York: McGraw-Hill.

WESTBROOK, E., WETZEL, B., CANNON, G.B. and BERARD, D. (1975). The impact of culture conditions on the surface morphology of cells in vitro. In Scanning Electron Microscopy / 1975/ I, pp 393 - 359. Chicago: Illinois Institute of Technology.

WETZEL, B., CANNON, G. and ERICKSON, B. (1974). A critical approach to the scanning electron microscopy of cells in suspension. In Scanning Electron Microscopy / 1974/ II, pp 581 - 588. Chicago: Illinois Institute of Technology.

WHITAKER, A. (1972). Tissue and Cell Culture. London: Baillière Tindall.

WHITEHEAD, R.H. (1976). The culture of tumour cells from human tumour biopsies. Clinical Oncology 2, 131 - 140.

WIER, K.A., FUKUYAMA, K. and [illegible]STEIN, W.L. (1971). Nuclear changes during keratinization of normal human epidermis. Journal of Ultrastructure Research 37, 138 - 145.

WILLIS, R.A. (1967). Pathology of Tumours 5th ed. Redhill: Butterworth.

WITKOWSKI, [illegible] and [illegible], W. (1971). Stages of spreading of

Scandinavica 80, 165 - 175

VOIGT, W.H. and FUSENIG N.E. (1979). Organotypic differentiation of mouse keratinocytes in cell culture: a light and electron microscopic study. Biologie Cellulaire 34, 111 - 118.

WANSON, J.C., PENASSE, M., BERNAERT, D. and MAY, E. (1980). SEM study of adult rat hepatocytes from preneoplastic and hyperplastic foci induced in the liver by diethylnitrosamine. Scanning Electron Microscopy / 1980 / III, 29 - 34.

WARWICK, G.P. and HARINGTON, J.S. (1973). Some aspects of the epidemiology and etiology of esophageal cancer with particular emphasis on the Transkei, South Africa. Advances in Cancer Research 17, 82 - 229.

WEISS, L. and GREEP, R.O. (1977). Histology, 4th ed. New York: McGraw-Hill.

WESTBROOK, E., WETZEL, B., CANNON, G.B. and BERARD, D. (1975). The impact of culture conditions on the surface morphology of cells in vitro. In Scanning Electron Microscopy / 1975/ I, pp 393 - 359. Chicago: Illinois Institute of Technology.

WETZEL, B., CANNON, G. and ERICKSON, B. (1974). A critical approach to the scanning electron microscopy of cells in suspension. In Scanning Electron Microscopy / 1974/ II, pp 581 - 588. Chicago: Illinois Institute of Technology.

WHITAKER, A. (1982). Tissue and Cell Culture. London: Bailliere Tindall.

WHITEHEAD, R.H. (1976). The culture of tumour cells from human tumour biopsies. Clinical Oncology 2, 131 - 140.

WIER, K.A., FUKUYAMA, K. and EPSTEIN, W.L. (1981). Nuclear changes during keratinization of normal human epidermis. Journal of Ultrastructure Research 77, 138 - 145.

WILLIS, R.A. (1967). Pathology of Tumours 4th ed. Arcadia: Butterworth.

WITKOWSKI, J. and ORIMOTO, W. (1971). Stages of spreading of

human diploid cells on glass surfaces. Experimental Cell Research 68, 373 - 380.

WOOD, G.W. and GILLESPIE, G.Y. (1975). Studies on the role of macrophages in regulation of growth and metastasis of murine chemically induced fibrosarcomas. International Journal of Cancer 16, 1022 - 1030.

WYNDER, E.L. and BROGS, I.J. (1961). A study of etiological factors in cancer of the esophagus. Cancer 14, 389 - 413.

WYNDER, E.L., MABUCHI, K. and HOFFMAN, D. (1975). Tobacco. In Cancer Epidemiology and Prevention (ed. D. Schottenfeld), pp 102 - 125. Springfield: Charles C. Thomas.

XIA, Q.J. and ZHAN, Y. (19). Fungal invasion of esophageal tissue and its possible relation to esophageal carcinoma. Chinese Medical Journal 90, 392 - 396.

YANG, C.S. (1980). Esophageal cancer in China: A review. Cancer Research 40, 2633 - 2644.

YOUNGHUSBAND, J.D. and ALDWINCARE, A.P.R. (1970). Carcinoma of the oesophagus: factors influencing survival. British Journal of Surgery 57, 422 - 430.

YUSPA, S.Y., VIGUERA, C. and NIMS, R. (1979). Maintenance of human skin on nude mice for studies of chemical carcinogenesis. Cancer Letters 6, 301 - 310.

ZELICKSON, A.F. and HARTROFT, J.F. (1962). An electron microscope study of normal human non-keratinizing oral mucosa. Journal of Investigative Dermatology 38, 95 - 107.

ZUR HAUSEN, H. (1975). Oncogenic herpes viruses. Biochimica et Biophysica Acta 417, 25 - 58.

_____. (1980). The virus-cancer problem and the possible therapeutic consequences. Therapiewoche 29, 7421 - 7422.

_____, (1982). The role of viruses in human cancers. Advances in Cancer Research 33, 1 - 107.

APPENDIX



```
106 FORMAT(/1X,'MAX SIMILARITY COEFF IF NO. EXECUTION [illegible]')
    IF(NOP.[illegible].1) GO TO 20
    GO TO 1
  6 SL=FLOAT(MAX)/1.0.0
C
C   BEGIN CLUSTER ANALYSIS
    WRITE(3,1,7)
  107 FORMAT(/1X,'CLUSTER ANALYSIS')
    DO 7 I=1,N
    NAT(I)=0.0
  7 CONTINUE
  8 CALL CLIGNKS,N,FL,[illegible],NCL,NO)
    DO [illegible] I=1,N
    IF(NAT(I).NE.NAT(I)) GO TO 10
  9 CONTINUE
    GO TO 15
C
C   PRINT OUTPUT WHENEVER CLUSTER PATTERN CHANGES
  10 WRITE(3,1,8) SL,NCL
  108 FORMAT(/1X,'SIMILARITY LEVEL=',F5.2,5X,'NUMBER OF CLUSTERS=',I3)
    DO 12 I=1,N
    NCL
    DO 11 J=1,N
    IF(NAT(J).[illegible].I) GO TO 11
    NCL=1
    NWK(K)=J
  11 CONTINUE
  12 WRITE(3,1,9) I,NWK(J),J=1,K)
  109 FORMAT(/1X,'CLUSTER',I3,4X,(20I5))
    IF(NO.[illegible].1) GO TO 14
    NCL
    DO 13 I=1,N
    IF(NAT(I).NE.0) GO TO 13
    NCL=1
    NWK(K)=I
  13 CONTINUE
    WRITE(3,1,10) NWK(I),I=1,K)
  110 FORMAT(/1X,'CLUSTERED',4X,(20I5))
  110 WRITE(3,1,11)
  111 FORMAT(/1X,'CLUSTERING WHEN ALL UNITS ARE IN SAME CLUSTER
  15 DO 17 I=1,N
    IF(NAT(I).[illegible].1) GO TO 17
    NCL=1
    DO 16 J=1,N
  16 NAT(J)=NAT(J)
    GO TO 8
  17 CONTINUE
    IF(NOP.EQ.1.AND.NOP11.EQ.1) GO TO 20
    GO TO 1
  20 NOP11=2
    GO TO 3
    END
```





Author Robinson K M
Name of thesis The behaviour and morphology of Human Oesophageal Carcinoma cells in In Vivo and In Vitro and a comparison with the normal 1981

PUBLISHER:
University of the Witwatersrand, Johannesburg
©2013

LEGAL NOTICES:

Copyright Notice: All materials on the University of the Witwatersrand, Johannesburg Library website are protected by South African copyright law and may not be distributed, transmitted, displayed, or otherwise published in any format, without the prior written permission of the copyright owner.

Disclaimer and Terms of Use: Provided that you maintain all copyright and other notices contained therein, you may download material (one machine readable copy and one print copy per page) for your personal and/or educational non-commercial use only.

The University of the Witwatersrand, Johannesburg, is not responsible for any errors or omissions and excludes any and all liability for any errors in or omissions from the information on the Library website.

Author Robinson K M
Name of thesis The behaviour and morphology of Human Oesophageal Carcinoma cells in In Vivo and In Vitro and a comparison with the normal 1981

PUBLISHER:
University of the Witwatersrand, Johannesburg
©2013

LEGAL NOTICES:

Copyright Notice: All materials on the University of the Witwatersrand, Johannesburg Library website are protected by South African copyright law and may not be distributed, transmitted, displayed, or otherwise published in any format, without the prior written permission of the copyright owner.

Disclaimer and Terms of Use: Provided that you maintain all copyright and other notices contained therein, you may download material (one machine readable copy and one print copy per page) for your personal and/or educational non-commercial use only.

The University of the Witwatersrand, Johannesburg, is not responsible for any errors or omissions and excludes any and all liability for any errors in or omissions from the information on the Library website.