

https://dspace.org/

Analysis of the thickness of the cortices along the course of the inferior alveolar nerve

Seleke, Kgothatso Morake

2023

University of the Witwatersrand, Johannesburg

https://hdl.handle.net/10539/37536

Seleke, Kgothatso Morake. (2023). Analysis of the thickness of the cortices along the course of the inferior alveolar nerve. [Masters dissertation, University of the Witwatersrand, Johannesburg]. https://hdl.handle.net/10539/37536

Downloaded from a DSpace repository. https://dspace.org/

Analysis of the thickness of the cortices along the course of the inferior alveolar nerve



Kgothatso Morake Seleke

2114489

A research report submitted to the Faculty of Health Sciences, University of the Witwatersrand, Johannesburg, in partial fulfilment of the requirements for the degree of Master of Dentistry

Johannesburg 2023

Declaration

I, Kgothatso Morake Seleke declare that this research report is my own, unaided work. It is being submitted for the Masters in Dentistry at the University of the Witwatersrand, Johannesburg. It has not been submitted before for any degree or examination at any other University.

_____

(Signature of candidate)

21 day of June 2023 in Pietermaritzburg

Dedication

I dedicate this piece of work to the late Dr TKE Kgomo, to my parents (Frans and Cathrine Seleke), siblings (Obakeng and Tshepiso Seleke) and lovely wife (Mammone Selolo) and my wonderful children (Kemisetso and Tshedimosetso Seleke).

ABSTRACT

Introduction

Surgical procedures performed around the course of the inferior alveolar nerve (IAN) accounts for 63% of neuropathy reported[2]. These surgical procedures include dental implant placement, surgical extractions around the lower molar area, internal fixation, mandibular ramus graft and bilateral sagittal split osteotomy. Failure to pay attention to detail while performing these surgical procedures may result in inferior alveolar nerve injuries, developing in neurological deficit which are characterized by either paraesthesia or anaesthesia.

Aim

The aim of this study was to analyse the buccal and lingual cortical bone thickness along the course of the inferior alveolar nerve.

Objectives

To analyse the thickness of the buccal-lingual cortical bone along the inferior alveolar canal (IAC). To determine whether there is association between position of the IAC and thickness of the cortices. To determine the factors (age and gender) associated with buccal-lingual position of the nerve.

Materials and Methods

This was a retrospective study based on analysing radiographic records of patients who took CBCT at Wits Oral Health Centre (W.O.H.C) from January 2015 up to December 2018. The estimated sample size was 132 quadrants of CBCT images which was determined with 95% confidence level, 5% margin of error, 50% population proportion and 200 population size. CBCT images were taken using SIDEXIS next Generation software. The IAN was identified and highlighted along its course to the mental foramen.

Results

The male and female buccal-lingual cortical measurements at all points were approximately the same. The lingual right cortical thickness increased with an increase in age, and the buccal right cortical thickness decreased with an increase in age. There was no association between gender and IAC position. The width of the buccal cortex was greater on the left than the right side and the lingual cortical thickness was also greater than the right. In the present study it was found that the males had a thicker buccal cortex posteriorly and a thinner cortex anteriorly compared to females. Females had thicker buccal cortex on the right side at point posteriorly whereas anteriorly it was thicker on the left. The left and right buccal cortices show the median increase in all age groups. The IAC was close to the lingual cortex at the molar region and buccal cortex at the premolar region. The position of the IAC whether buccal, lingual or inferior can be attributed to the type of the IAC as; straight projection, catenary-like projection and progressive descent. It was also determined by the type and depth of impaction, position of the roots of the third molar and the width or thickness of the buccal-lingual cortices.

Conclusion

CBCT play an integral role in diagnostic imaging due to details of the images. The position of the IAC that houses IAN is influenced by various factors including but not limited to gender and age as well as the surrounding anatomy. By understanding the surrounding anatomical influences on the position of the IAN, any surgery to the area would minimize complications associated with the IAN especially with the use of detailed imaging such as CBCT.

Acknowledgments

To Prof Nemuntandani, Prof Rikhotso Head of Department (Maxillo-Facial and oral Surgery) at University of the Witswatersrand and Dr. A Singh Head of Department (Maxillo-Facial and Oral Surgery) at Greys Hospital thank you for giving me this opportunity to realise my dream.

To my supervisors, Prof M Mabongo and Dr D Kotsane there are no words to express my gratitude to you and thanks for your patience and support.

To my lovely wife, parents, daughter, and my extended family thank you for words of encouragement and patience, and to my siblings' thank you for your support, encouragement and prayers.

Table of contents

Declaration ii
Dedication iii
Abstract iv
Introduction iv
Aim iv
Objectives iv
Materials and Methods iv
Results v
Conclusion v
Acknowledgments vi
LIST OF FIGURES ix
LIST OF TABLES x
LIST OF ABBREVIATIONS xi
LIST OF ANNEXURES xii
Chapter 1 1
1.1 Introduction 1
1.2 Literature review 2
Chapter 2: Research design 6
2.1. Aim 6
2.2. Objectives 6
2.3. Materials and Methods 6
2.3.1. Study Design 6
2.3.2. Methodology 7
2.3.3. Inclusion criteria 11
2.3.4. Exclusion criteria 11
2.3.5. Sample size 12
2.4. Statistical analyses 12
2.5. Ethical Considerations 13
Chapter 3: Results 14
Chapter 4: Discussion 32
4.1. The thickness of the buccal-lingual cortical bone from the mandibular canal to mental foramen 32
4.1.1. Association of gender and thickness of the cortices 33
4.1.2. Association of age and thickness of the cortices 33

4.2. To determine whether there is association between position of the IAC and thickness of the cortices 34
4.3. To determine the factors associated with buccal-lingual position of the nerve..... 35
4.4. Limitations..... 35
4.5. Conclusion 35
4.6. Recommendation..... 36
4.7. Declaration of interest 36
4.8. Funding..... 36
Reference 37

LIST OF FIGURES

Figure 1.1: Embryonic development of the mandible 3

Figure 2.1: Fiducial anatomical landmarks 8

Figure 2.2: Recorded measurements on cross-sectional image recorded from the outer cortex of the lingual and buccal cortices 9

Figure 2.3: Panoramic view with highlighted 9

Figure 2.4: Axial and coronal or cross-sectional view with measurements 10

Figure 2.5: Overall views of CBCT images 11

Figure 3.1: Showing different age groups at point A 19

Figure 3.2: Showing different age groups at point B 21

Figure 3.3: Showing different age groups at point A 23

Figure 3.4: Showing different age groups at point B 25

Figure 3.5: QQ-Plots for buccal-lingual cortices at point A 28

LIST OF TABLES

Table 3.1 Analysis of the thickness of the bucco-lingual cortical bone at all points 14

Table 3.2 Gender-wise comparison of the thickness of the bucco-lingual Cortical bone at point A 15

Table 3.3 Gender-wise comparison of the thickness of the bucco-lingual cortical bone at point B 16

Table 3.4 Gender-wise comparison of the thickness of the bucco-lingual cortical bone at point C 17

Table 3.5 Gender-wise comparison of the thickness of the bucco-lingual cortical bone at point D 18

Table 3.6 Different age groups at point A 20

Table 3.7 Different age groups at point B 22

Table 3.8 Different age groups at point A 24

Table3.9 Different age groups values at point D 26

Table 3.10 Summary statistics of the position of the IAC 27

Table 3.11 Association of the position of IAN on the left side 29

Table 3.12 Association of the position of IAN on the right side 30

Table 3.13 Association between gender and IAC position 31

Table 3.12 Association between age and IAC 31

LIST OF ABBREVIATIONS

IAC - Inferior Alveolar Canal

IAN - Inferior Alveolar Nerve

3D - Three Dimension

CBCT - Cone-beam Computed Tomography

HOD - Head of Department

W.O.H.C - Wits Oral Health Centre (W.O.H.C)

WITS - University of the Witwatersrand

HREC - Human Research and Ethics Committee

LIST OF ANNEXURES

Annexure A:	**Data Collection Sheet**	41
Annexure B:	**Approval from Wits School of Oral Health**	42
Annexure C:	**Ethical clearance Certificate**	43
Annexure D:	**Turnit in report**	44

Chapter 1

1.1 Introduction

The inferior alveolar nerve is reported to be housed in the inferior alveolar canal (IAC), which starts at the mandibular foramen and ends at the mental foramen usually opening near the apex of the second premolar or between the two premolars[1]. Surgical procedures performed around the course of the inferior alveolar nerve (IAN) accounts for 63% of neuropathy reported[2]. These surgical procedures include dental implant placement, surgical extractions around the lower molar area, internal fixation, mandibular ramus graft and bilateral sagittal split osteotomy. Failure to pay attention to detail while performing these surgical procedures, inferior alveolar nerve injuries may occur, resulting in neurological deficit which are characterized by either paraesthesia or anesthesia[3].

Some studies have reported neurological deficit to be a known risk when there is a direct contact or close relationship between the nerve and the roots of the lower third molar which can be viewed in a panoramic x-ray[3, 4], which is the most common radiograph that is used to assess the relationship of lower third molars to the inferior alveolar nerve[4].

Rood and Shebab reported several radiological signs that are suggestive of close relationship between the IAC and lower third molars[5]. These include darkening of roots, deflection of roots, narrowing of roots, bifid root apex, narrowing of canal, deflection of canal and interruption of white line of canal[5] and these features were significantly associated with inferior alveolar nerve exposure following lower third molar removal[5]. However, some studies have reported darkening of roots, interruption of white lines of canal and deflection of canal to be significantly associated with nerve injury[6]. In a study conducted by Miller et al it was reported that panoramic radiograph does not show a true reflection of the IAC in close relation to the impacted tooth. They reported that the IAC was in close relation to the buccal and lingual cortices although it showed signs of proximity to the impacted tooth on a panelipse[7].

Cone-beam Computed Tomography (CBCT) is useful as it can provide a 3D view of the nature of relationship between the canal and the roots. Unfortunately, CBCT's are not readily available due to the cost factor. Therefore, the oral surgeon should be familiar with the anatomical

landmarks before performing surgical procedures around the course of the inferior alveolar nerve since the accurate 3D view provided by the CBCT is not readily available[8].

1.2 Literature review

The inferior alveolar nerve runs within the IAC of the mandible, which is the strongest and largest bone of the face. It is made up of a curved, horizontal part known as the body and two vertical parts known as the rami. The rami join the ends of the body almost at right angles[9]. Pre-natal development of the mandible occurs at about the fourth week of intrauterine life. It develops from the first brachial arch, also known as the mandibular arch or first pharyngeal arch[10]**.** The mandible develops from the mandibular arch along the mandibular nerve, which is a branch of the trigeminal nerve and is the first structure that develops in the dawning of the lower jaw [9,10].

The cartilage of the first pharyngeal arch is known as Meckel's cartilage and has a close relationship with the developing mandible[11]. The two cartilages at the proximal ends are connected to the ear capsules and distally they join one another at the symphysis. At the seventh week, ossification starts whereas the condensation of mesenchyme occurred during the sixth week where the branches of inferior alveolar nerve are formed at right angles known as the centre of ossification[9-12].

Bone formation occurs at this centre where it spreads anteriorly to the midline and posteriorly into the lingual and inferior alveolar nerves. The new bone which is laid lateral to the Meckel's cartilage forms a trough with lateral and medial bone joined underneath the inferior alveolar nerve[12]. This trough is later converted into the inferior canal as the bone forms on top of the nerve[10, 12]. The ramus of the mandible develops by a rapid spread of ossification backwards, diverging away from Meckel's cartilage where it is defined by the lingula which is the opening of the inferior alveolar canal. At ten weeks of development, the primitive mandible is formed almost entirely by intramembranous ossification[9-11].

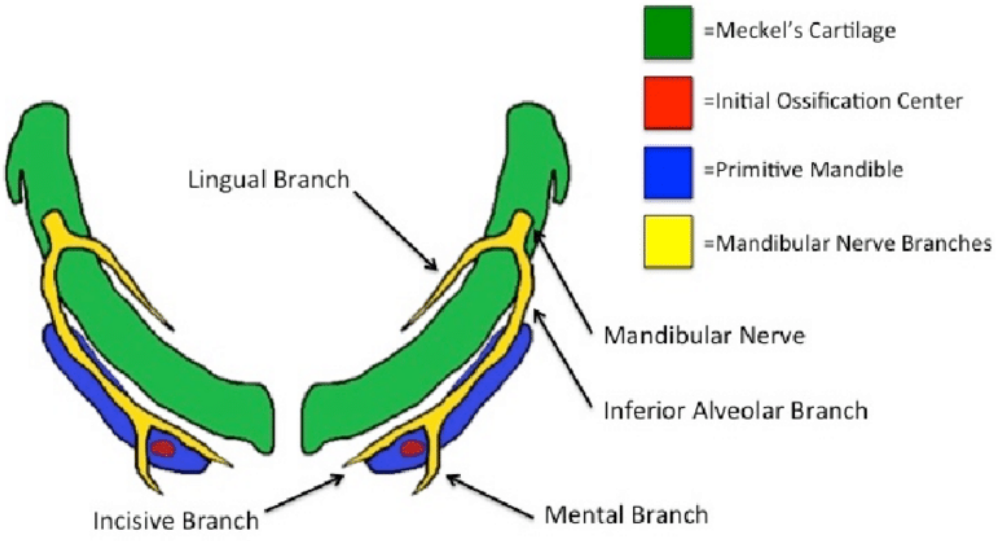

Figure 1.1 Embryonic development of the mandible (Nanci A[9])

The Meckel's cartilage degenerates at the lingula up to the division of inferior alveolar nerve and the proximal part forms the two bones of the inner ear (malleus and incus) and the sphenomalleolar ligament and sphenomandibular ligament[10,11]. The further development of the mandible is influenced by the secondary cartilages which are condylar, coronoid and symphyseal cartilages at twelve weeks of development where the carrot shaped condylar cartilage appears[9,12,13]. It gives rise to the condyle and posterior half of the ramus of the mandibular foramen by endochondral ossification and the coronoid cartilage, which forms the coronoid process and anterior half of the ramus[14]. The symphyseal cartilages are two in number and appear between the two ends of the Meckel's cartilage and are obliterated within the first year of life[13].

Lingula appears in different shapes (truncated shape = 38.8%, triangular = 30.8%, nodular = 21.4% and assimilated = 8.9%) and position. The average position of the lingual was 20.15mm, 16.77mm and 16.3mm to the anterior border, posterior border, and sigmoid notch respectively. The distance from the second molar was 33.3mm and the higher position may be expected in both class II and class III malocclusions[15]. Tshite found that the mandibular foramen was more likely to be in a superoposterior position on the ramus in males as compared to females on South African population without distinguishing between races[16]. A South African study that analysed

the position, shape, and number of mental nerves found that mental foramen had different positions which are as follows: -

1) Position I – between the canine and first premolar
2) Position II – at the apex of the first premolar
3) Position III – between first and second premolar
4) Position IV – at the second premolar
5) Position V – between second premolar and first molar
6) Position VI – at the level of first molar
7) Position VII – directly below the canine

It was found that the position III and IV were common in males and females respectively. Position II of mental foramen was seen in male European descent and position III in African males and female European descents and mixed descents in heterogeneous South Africans[17]. In other studies it was reported the location of the mental foramen was mostly found at position III, IV, II, and respectively in occurrence[18,19]. The course of the IAC in a vertical plane was analysed and classified into three types: 1) straight projection, 2) catenary-like projection (curled as hanging between two points) and 3) progressive descent[20,21]. The catenary-like projection (61.17%) is the most common type followed by progressive descent (28.19%) and straight projection (9.64%) [22, 23].

While the location of IAC was described to be buccal, lingual and inferior in relation to the root apices and it was not statistically significant in gender and age groups which were divided into less or greater than 40 yrs[6,24]. Another study that analysed the relationship of impacted third molars and position of IAC using traditional radiographs (panelipse, sub-mento-vertex and periapical) found IAC to lie in a buccal, inferobuccal lingual, inferolingual and inferior positions[24].

While other researchers described the course of the IAC in the horizontal plane as usually crossing from the lingual to the buccal aspect of the body of the mandible, at a point that is midway between the buccal and lingual cortices and in most cases is around the first molar region[24,25,26]. These studies suggest that IAC in most instances is close to the lingual cortical

plate rather than the buccal cortical plate in the molar region contrariwise to the premolars where the IAC is more buccal or direct inferior region. The distance from the inferior border of the mandible to the IAC has been reported to be at an average of one centimetre[25].

The study performed by Padayachee et al in South Africa reported that the buccal cortical thickness was farthest from IAC around the second and first molar region with an average of 6.525mm and 6.214mm respectively[24]. These results concurred with other studies that were performed in other parts of the world although the average values were different[18,19,23,25,26,29,30,31]. Lingual cortical thickness was reported to be thickest at the second premolar region and thinnest at the second molar region with an average of 3.8mm and 1.7mm respectively in a study conducted in America with slight difference from other studies by Balaji et al, Shokry et al, Khorshidi et al, Safee et al, Nagadia et al and de Oliveira Júnior et al[18,19,25,28,29,31].

A study conducted on Korean patients with skeletal class III malocclusion where the patients were divided into group I (no cancellous bone and the nerve was in contact with cortical bone) and group II (cancellous bone between the IAC and the cortical bone). Statistically significant difference was reported between the two groups on the distance from the IAC to the buccal cortex[32].The difference in the thickness of the cortices between the right and a left side was reported and it was found that the left side was slightly thicker than the right side.[26,33]. In the studies performed by Balaji et al and de Oliveira Júnior et al, it was reported that the left and right sides were contrariwise to the South African study by Padayachee et al[28,30].

Mallick et al found that the average distance from the root apex to the lingual cortical bone was 3.31mm on the right and 2.96mm on the left for males and for females was 3.98mm on the right and 3.56mm on the left in the third molar region[34]. In the studies conducted by Balaji et al, Simonton et al, de Oliveira Júnior et al and Mousa et al, it was reported that the males had thicker buccal and lingual cortices. The difference in the thickness was contributed to the factors that influence bone growth such as sex hormones and musculature[29,30,35,36]. In other studies that were conducted in different countries it was reported that females had thicker buccal cortices as compared to males[18,31,37]. Shokry et al and Kawashima et al also found that in females the left side was the thickest compared to the right side[18,33].

Levine et al reported that older patients showed to have less distance between the buccal cortex and the inferior alveolar nerve regardless of gender[38].When comparing 36-45yrs and 46-61yrs age groups Shokry et al found that the buccal cortical distance increased with age on the second molar region (distal root). The lingual distance increased with age between the ages of 15-25 years and 36-45 years[18]. Simonton et al reported that there was a decrease in mandibular width in third to sixth decade of life[35].

A study conducted in America reported that the non-Caucasians had thick buccal cortex compared to Caucasians[37]. Malaysian Chinese had highest values compared to Malaysian Indian where there was statistically significant at the lingual cortex on the right second molar, left second molar and the first molar. Native Malaysian had the highest values compared to the Malaysian Indian on the left second and first molar[32].

Chapter 2: Research design

2.1. Aim

The aim of this study was to analyse the buccal and lingual cortical bone thickness along the course of the inferior alveolar nerve.

2.2. Objectives

- To analyse the thickness of the buccal-lingual cortical bone along the inferior alveolar canal (IAC).

-To determine whether there is an association between position of the IAC and thickness of the cortices

- To determine the association between age and gender with buccal-lingual position of the nerve

2.3. Materials and Methods

2.3.1. Study Design

This was a retrospective descriptive study based on analysing radiographic records of patients exposed to CBCT scan at Wits Oral Health Centre (W.O.H.C) from January 2015 to December 2018.

2.3.2. Data collection

Files of patients exposed to CBCT scans from January 2015 to December 2018, and that have met the inclusion criteria were used and variables that were extracted included age and gender. CBCT images were taken using SIDEXIS next Generation software®. The images were imported to GALILEOS Viewer®, orientated and aligned to a vertical plane using the anterior nasal spine and the Frankfort horizontal plane for standardization of the analysis. The IAN was identified and highlighted along its course to the mental foramen. Four fiducial landmarks were identified as:

Point A - apical most part on the long axis of the distal root of the third molar

Point B - apical most part on the long axis of the distal root of the second molar

Point C - apical most part on the long axis of the distal root of the first molar

Point D - apical most part on the long axis of the root of the second premolar, see figure 3.

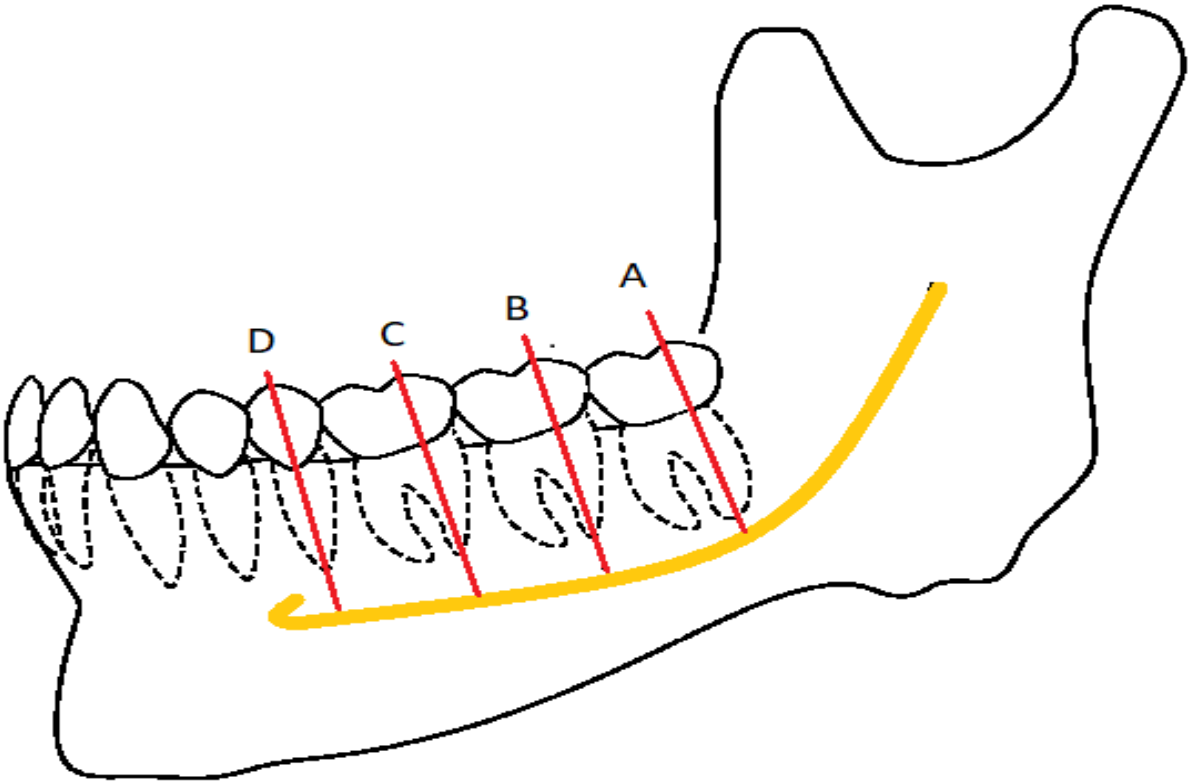

Figure 2.1 Fiducial anatomical landmarks

The anatomical position of the IAC was recorded as inferior, buccal, or lingual in relation to the fiducial points. The centre of the IAC was identified and used to determine the most buccal and lingual point on the circumference of the canal. A horizontal line bisecting these points in the centre was used to measure the cortical width. Thereafter, measurements were taken from the buccal aspect of the IAC to the outer buccal cortex and from the lingual aspect of the IAC to the outer lingual cortex to determine the thickness of the buccal and lingual cortices respectively, see figure 2.4.

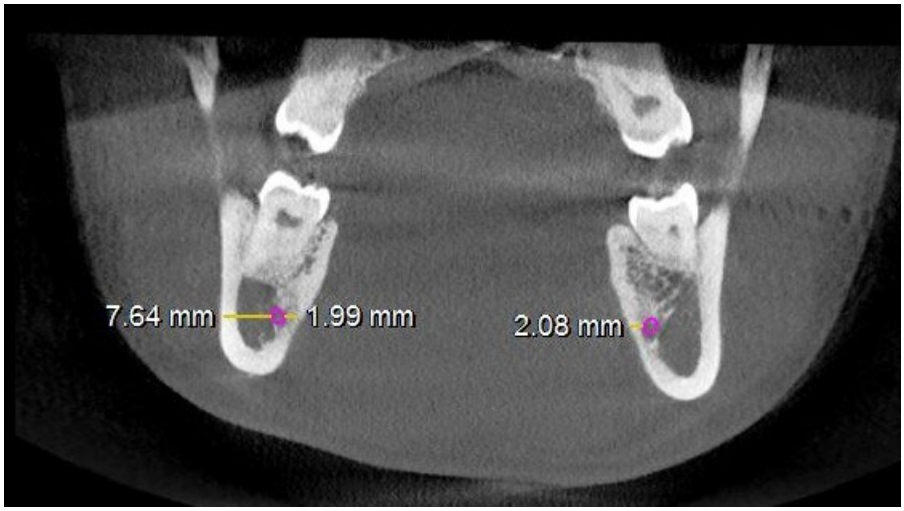

Figure 2.2 Recorded measurements on cross-sectional image recorded from the outer cortex of the lingual and buccal cortices

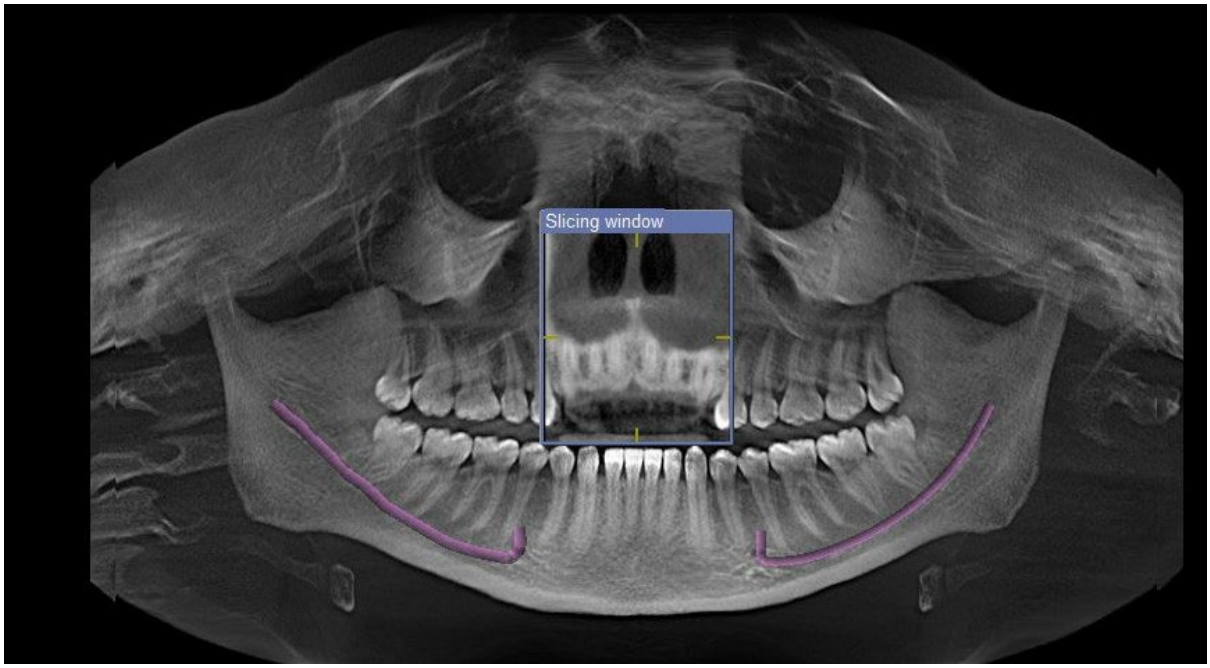

Figure 2.3 Reconstructed panoramic view with highlighted IAN

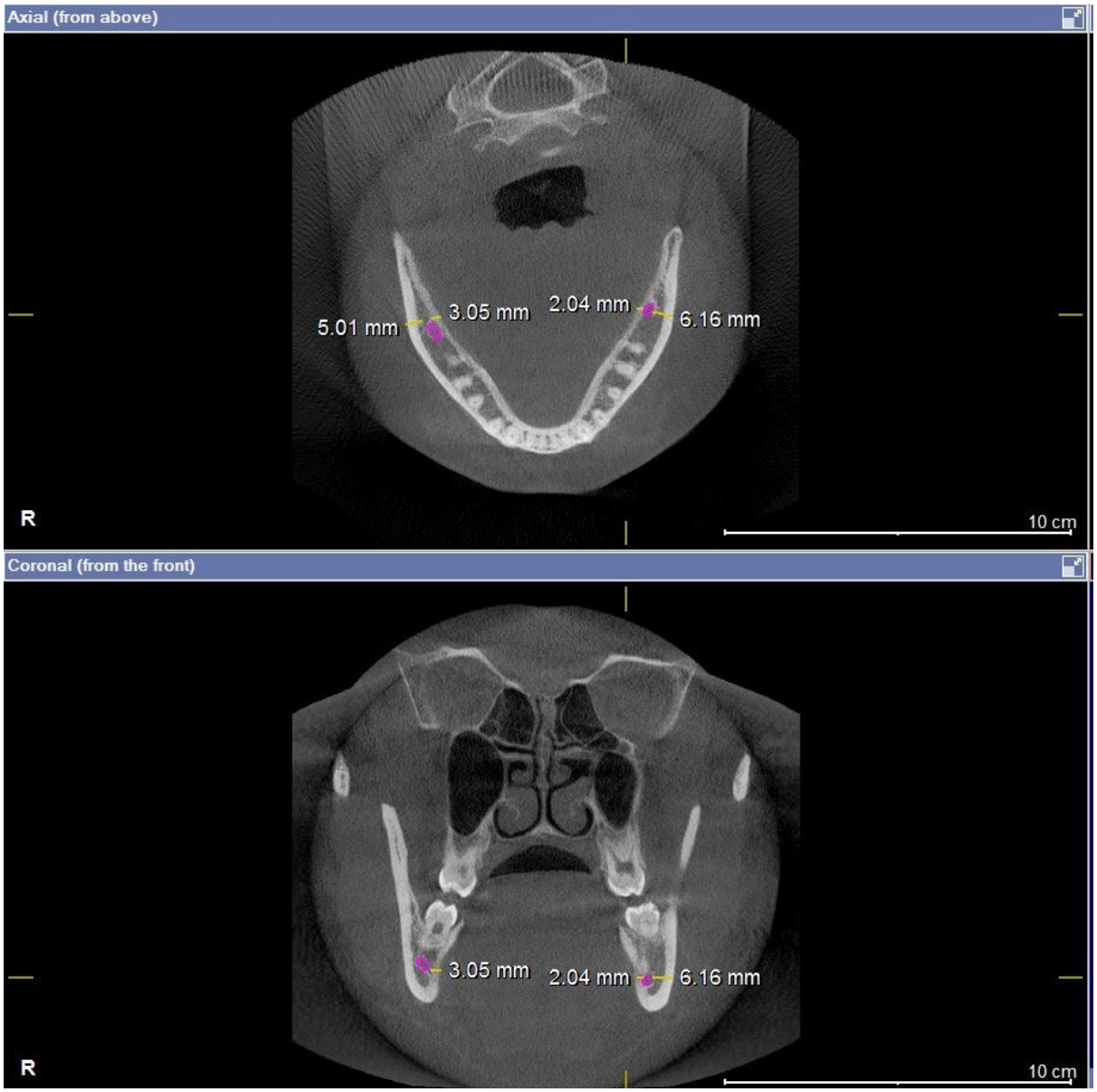

Figure 2.4 Axial and coronal or cross-sectional view with measurements

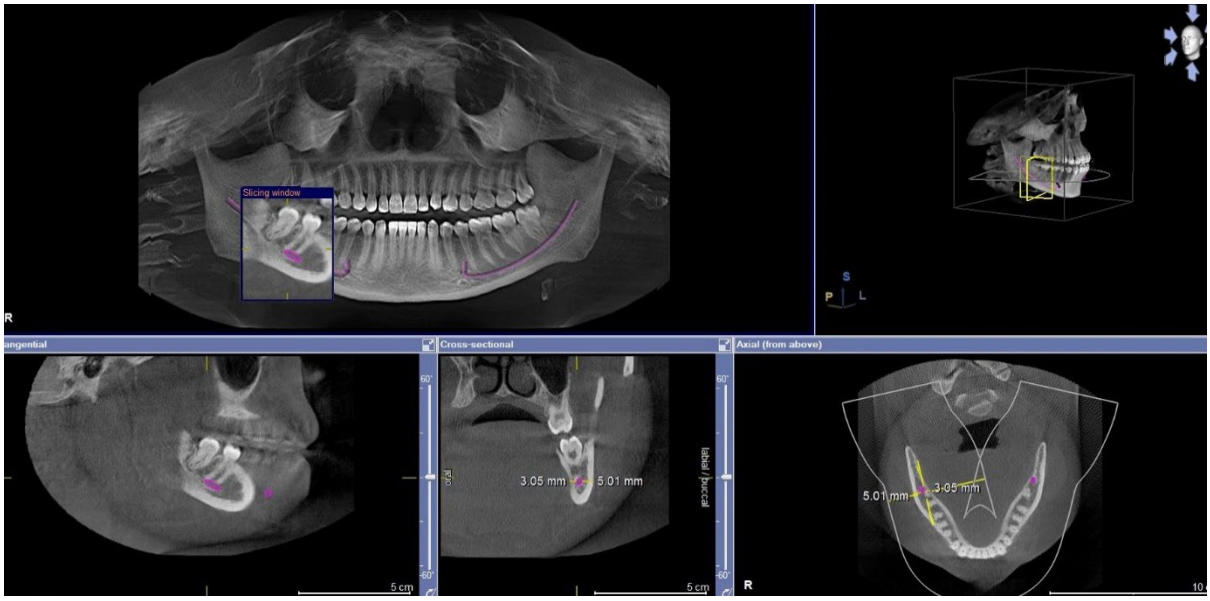

Figure 2.5 Overall views of CBCT images

The measurements were recorded on a data collection sheet and captured using Microsoft Excel®. The measurements of cortices were rechecked or retaken for accuracy by an independent radiographer with an experience in maxillofacial and oral radiology and mutual agreement was reached between her and me.

2.3.3. Inclusion criteria

- Patients exposed to CBCT scan from January 2015 to December 2018
- Patients of the age of 18 years and above
- Dentate patients with teeth of interest per quadrant

2.3.4. Exclusion criteria

- CBCT images of poor quality where inferior alveolar nerve canal could not be traced.
- CBCT Images of patients who have been treated for fractures, mandibular resections, and those with pathologic lesions in all quadrants.
- CBCT images of patients who have went for bilateral sagittal split osteotomy.
- Patients with missing teeth of interest per quadrant
- Horizontal impacted lower molars

2.3.5. Sample size

CBCT images of patients from January 2015 up to December 2018 were analysed. The estimated sample size was 132 quadrants (66 patients) of CBCT images which was determined with 95% confidence level, 5% margin of error, 50% population proportion and 200 population size. The sample size was reduced to 94 quadrants (47 patients). The maxilla and mandible are divided into the left and right quadrants.

Infinite sample size formula

$$n = [z^2 \times p \times (1 - p) / e^2] / [1 + (z^2 \times p \times (1 - p) / (e^2 \times N))]$$

Where:

n is the sample size,

z is the z-score associated with a level of confidence,

p is the sample proportion, expressed as a decimal,

e is the margin of error, expressed as a decimal,

N is the population size

2.4. Statistical analyses

Descriptive statistics (graphs and tables) was used to summarise the results. Nonparametric tests were used to test for associations; Mann-Whitney test was used to determine the association between gender and the buccal-lingual thickness. Kruskal-wallis test was used to determine associations between the age groups, IAC position against the buccal-lingual thickness. Lastly, an exact fisher's test was also run to determine the association of the IAC position against gender and age.

2.5. Ethical Considerations

Ethical clearance was obtained from Human Research and Ethics Committee (HREC) of Witwatersrand University whereby HREC clearance certificate was issued with reference no: M190266 MED19-02-071; see Annexure C. Permission for using hospital records was granted by CEO of the School of Oral Health Science and Wits Dental School with reference no. HRRC/JULY/05/2019; see Annexure D and Head of the Department of Diagnostics. Confidentiality was adhered by allocating codes to the data images of the patients on data collection form; see Annexure B. Identifiers of the patients were only accessed by the researcher.

Chapter 3: Results

Objective 1) Analyse the thickness of the buccal-lingual cortical bone

Table 3.1 Analysis of the thickness of the bucco-lingual cortical bone at all points

Point A					
	Mean	**Standard deviation**	**Confidence Interval**	**Median**	**Interquartile range**
Buccal left	5.781	1.978	5.200 – 6.362	5.66	2.57
Lingual left	1.989	1.456	1.561 – 2.416	1.39	1.65
Buccal Right	5.717	1.757	5.201 – 6.233	5.65	2.06
Lingual Right	1.953	1.261	1.583 – 2.324	1.5	1.47
Point B					
Buccal Left	7.346	1.620	6.870 – 7.821	7.49	2.35
Lingual Left	2.325	1.250	1.958 – 2.692	2.08	1.66
Buccal Right	7.371	1.528	6.922 – 7.820	7.62	2.17
Lingual Right	2.285	1.062	1.973 – 2.597	1.9	1.46
Point C					
Buccal Left	6.840	1.427	6.421 – 7.259	6.59	2.4
Lingual Left	2.684	1.343	2.290 – 3.078	2.35	1.58
Buccal Right	6.780	1.479	6.346 – 7.215	6.96	1.7
Lingual Right	2.733	1.172	2.389 – 3.077	2.44	1.29
Point D					
Buccal Left	3.769	1.756	3.253 – 4.284	3.99	2.26
Lingual Left	4.962	2.043	4.363 – 5.562	4.74	2.85
Buccal Right	3.322	1.984	2.739 – 3.905	3.91	2.66
Lingual Right	4.505	2.560	3.753 – 5.257	2.66	3.29

The buccal thickness increased from point A to point B and decreased from point B up to point D whereas the lingual cortical thickness increased from Point A through all points up to point D.

A non-parametric test**:** Mann-Whitney test was run to compare both genders as the lingual cortical thickness measurement is not normally distributed. An exact p-value is reported because n is small.

Table 3.2 Gender-wise comparison of the thickness of the bucco-lingual cortical bone at point A

Point A						
		n	**Mean**	**Standard deviation**	**Median**	**P-value**
Buccal Left	**Male**	25	5.976	1.883	5.83	0.669
	Female	22	5.559	2.102	5.595	
Lingual Left	**Male**	25	2.210	1.750	1.38	0.716
	Female	22	1.737	1.009	1.55	
Buccal Right	**Male**	25	5.743	1.813	5.4	0.763
	Female	22	5.688	1.734	5.925	
Lingual Right	**Male**	25	2.236	1.456	1.59	0.209
	Female	22	1.633	0.927	1.385	

Table 3.3 Gender wise comparison of the thickness of the bucco-lingual cortical bone at point B

Point B						
		n	**Mean**	**Standard deviation**	**Median**	**P-value**
Buccal Left	**Male**	25	7.735	1.484	7.92	0.119
	Female	22	6.903	1.687	6.69	
Lingual Left	**Male**	25	2.274	1.251	2.08	0.8451
	Female	22	2.383	1.275	2.06	
Buccal Right	**Male**	25	7.645	1.470	7.76	0.312
	Female	22	7.059	1.566	7.615	
Lingual Right	**Male**	25	2.291	1.184	1.9	0.845
	Female	22	2.279	0.933	1.895	

Table 3.4 Gender-wise comparison of the thickness of the bucco-lingual cortical bone at point C

Point C						
		n	**Mean**	**Standard deviation**		**P-value**
Buccal Left	**Male**	25	7.050	1.40	7.27	0.172
	Female	22	6.602	1.453	6.145	
Lingual Left	**Male**	25	2.748	1.592	2.33	0.724
	Female	22	2.612	1.023	2.495	
Buccal Right	**Male**	25	7.084	1.600	7.18	0.104
	Female	22	6.435	1.277	6.42	
Lingual Right	**Male**	25	2.619	1.217	2.27	0.277
	Female	22	2.864	1.132	2.885	

Table 3.5 Gender-wise comparison of the thickness of the bucco-lingual cortical bone at point D

Point D						
		n	**Mean**	**Standard deviation**		**P-value**
Buccal Left	**Male**	25	3.577	1.752	3.92	0.360
	Female	22	3.986	1.776	4.1	
Lingual Left	**Male**	25	4.913	2.049	5.37	0.804
	Female	22	5.018	2.083	4.55	
Buccal Right	**Male**	25	3.228	1.950	3.91	0.614
	Female	22	3.429	2.063	4.065	
Lingual Right	**Male**	25	4.456	2.684	4.15	0.8532
	Female	22	4.56	2.473	5.095	

From the P-values (> 0.05), there is insufficient evidence to reject the null hypothesis. Therefore, we can conclude that the male and female buccal-lingual cortical measurements at all points are approximately the same.

Age comparison of the thickness of the buccal-lingual cortical bone

Point A

Box Plots showing age comparison against thickness of the buccal-lingual cortical bone.

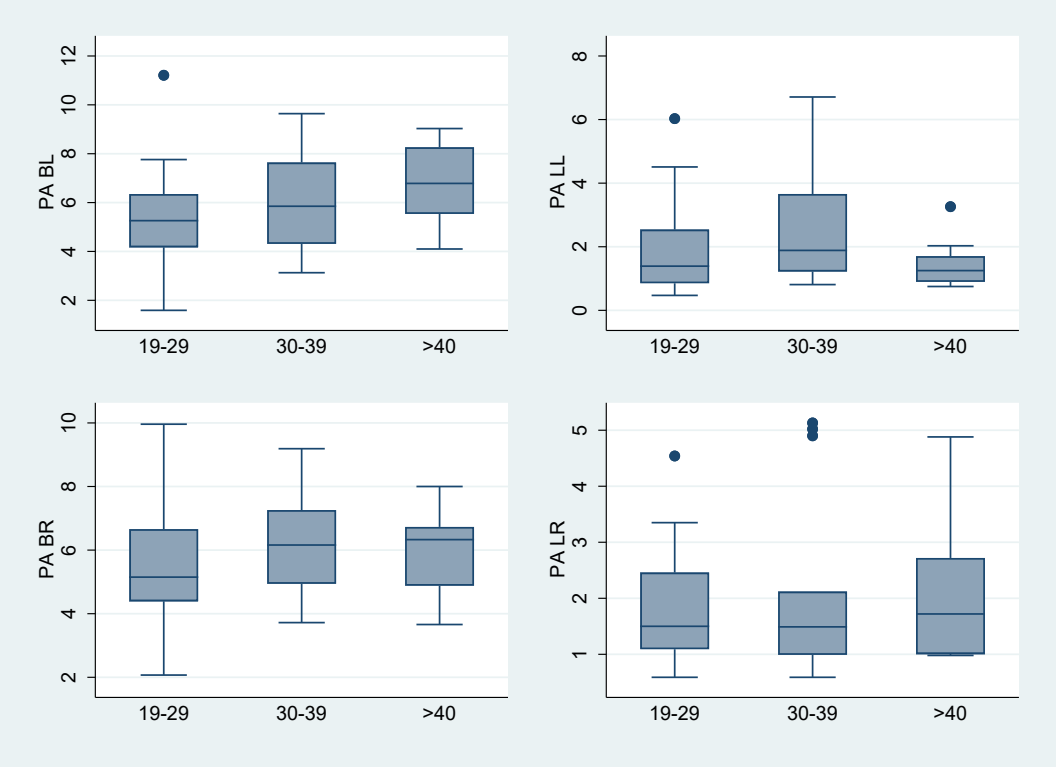

PA BL = Point A buccal left, PA LL = Point A lingual left, PA BR = Point A buccal right and PA LR = Point A lingual right

Figure 3.1 Showing different age groups at point A

Considering the box plot, we observe a median trend increase in both left buccal cortical and right buccal with an increase in age groups.

A non-parametric test: **Kruskal-Wallis** test was ran to compare both age groups as the lingual cortical thickness measurement was not normally distributed. An exact p-value was reported.

Table 3.6 Different age groups at point A

Point A					
Buccal Left	**n**	**Mean**	**Standard deviation**	**Median**	**P-value**
19-29	25	5.33	2.014	5.26	0.117
30-39	14	6.011	1.900	5.85	
40>	8	6.788	1.761	6.785	
Lingual Left					
19-29	25	1.912	1.449	1.39	0.303
30-39	14	2.426	1.695	1.885	
40>	8	1.464	0.828	1.25	
Buccal Right					
19-29	25	5.363	1.906	5.15	0.312
30-39	14	6.221	1.622	6.16	
40>	8	5.943	1.387	6.33	
Lingual Right					
19-29	25	1.807	1.003	1.5	0.927
30-39	14	2.2135	1.628	1.49	
40>	8	2.094	1.385	1.72	

P-value > 0.05. Do not reject the null hypothesis.

There is insufficient evidence that the thickness of the buccal-lingual cortical bone statistically differs at different age groups.

Point B

Box Plots showing age comparison against thickness of the buccal-lingual cortical bone.

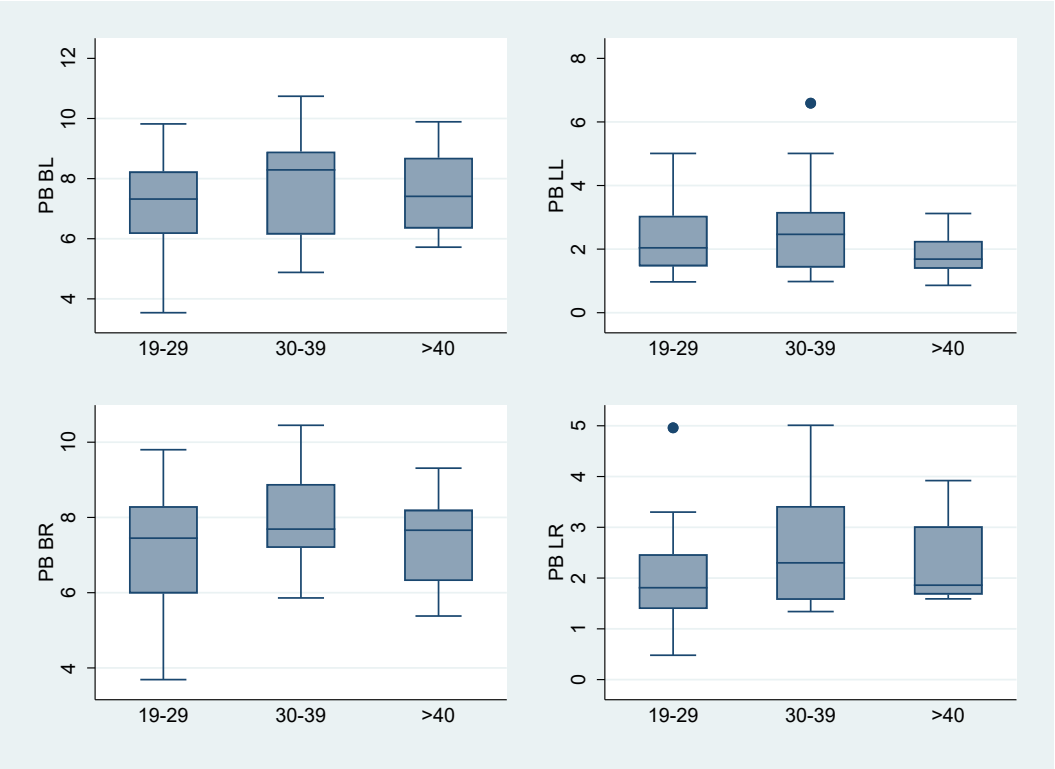

PB BL = Point B buccal left, PB LL = Point B lingual left, PB BR = Point B buccal right and PB LR = Point B lingual right

Figure 3.2 Showing different age groups at point B

A non-parametric test; **Kruskal Wallis** test is run to compare both age groups as the lingual cortical thickness measurement is not normally distributed. An exact *p*-value is reported.

Table 3.7 Age groups values at point B

Point B					
Buccal Left	**n**	**Mean**	**Standard deviation**	**Median**	**P-Value**
19 - 29	25	7.071	1.574	7.32	0.583
30 – 39	14	7.713	1.781	8.29	
> 40	8	7.563	1.504	7.41	
Lingual Left					
19-29	25	2.296	1.173	2.04	0.496
30-39	14	2.66	1.564	1.251	
40>	8	1.829	0.706	1.685	
Buccal Right					
19-29	25	7.076	1.686	7.45	0.4530
30-39	14	7.892	1.251	7.69	
40>	8	7.38	1.355	7.66	
Lingual Right					
19-29	25	2.049	0.966	1.81	0.2960
30-39	14	2.684	1.247	2.3	
40>	8	2.328	0.901	1.86	

P-value > 0.05. Do not reject the null hypothesis.

There is insufficient evidence that the thickness of the buccal-lingual cortical bone statistically differs at different age groups.

Point C

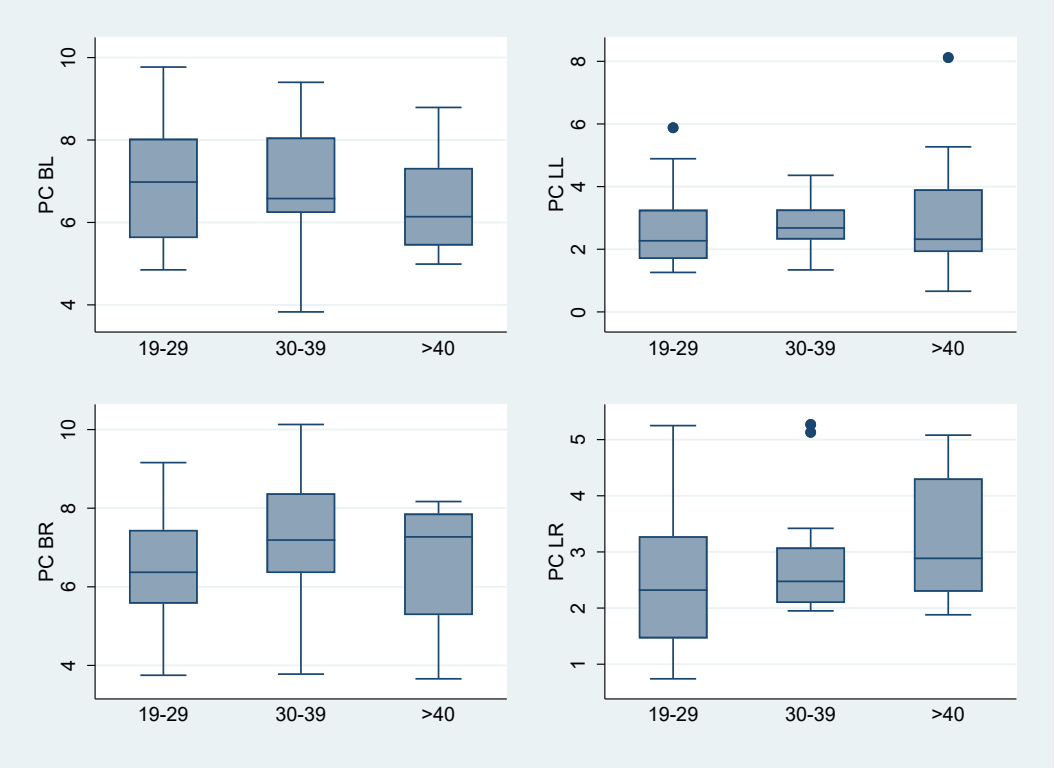

PC BL = Point C buccal left, PC LL = Point C lingual left, PC BR = Point C buccal right and PC LR = Point C lingual right

Figure 3.3 Showing different age groups at point C

Table 3.8 Age groups values at point C

Point C					
Buccal Left	**n**	**Mean**	**Standard deviation**	**Median**	**P-Value**
19 – 29	25	6.934	1.471	6.98	0.842
30 – 39	14	6.896	1.479	6.58	
> 40	8	6.449	1.301	6.14	
Lingual Left					0.7290
19-29	25	2.542	1.118	2.27	
30-39	14	2.681	0.894	2.68	
40>	8	3.134	2.406	2.32	
Buccal Right					
19-29	25	6.57	1.317	6.37	0.3311
30-39	14	7.269	1.585	7.19	
40>	8	6.583	1.754	7.27	
Lingual Right					
19-29	25	2.509	1.202	2.32	0.3466
30-39	14	2.844	1.082	2.475	
40>	8	3.241	1.182	2.885	

P-value > 0.05. Do not reject the null hypothesis.

There is insufficient evidence that the thickness of the buccal-lingual cortical bone statistically differs at different age groups.

Point D

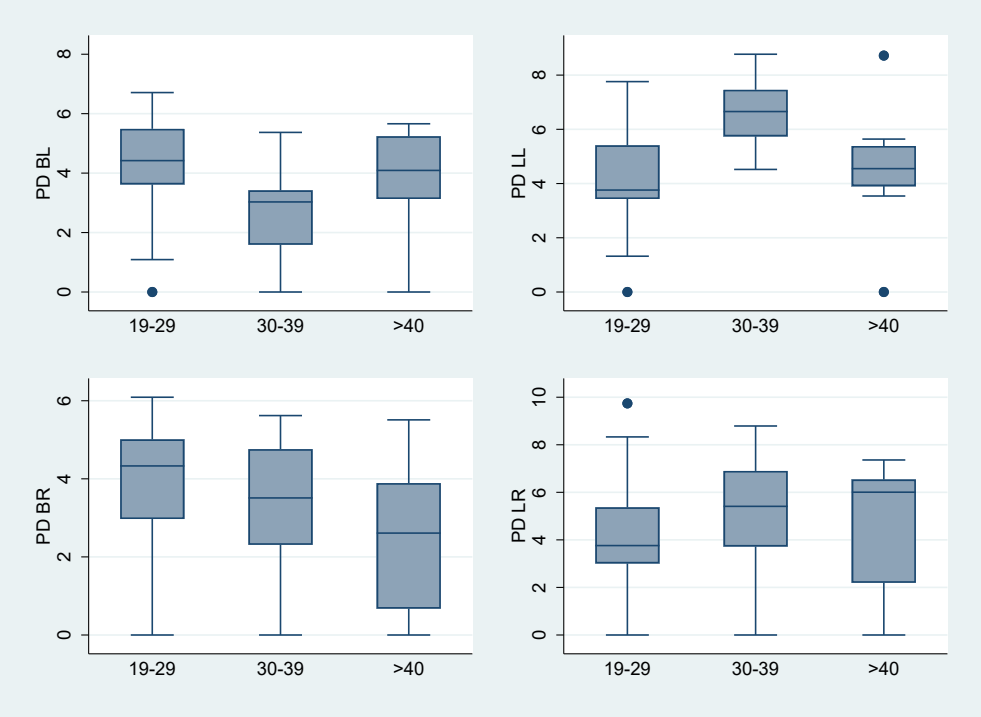

PD BL = Point D buccal left, PD LL = Point D lingual left, PD BR = Point D buccal right and PD LR = Point D lingual right

Figure 3.4 Different age groups at point D

Considering the box plot, we observe a difference in medians across all buccal-lingual cortices; with the lingual right cortical thickness increasing with an increase in age, and buccal right cortical thickness decreasing with an increase in age.

Table 3.9 Age groups values at point D

Point D					
Buccal Left	**n**	**Mean**	**Standard deviation**	**Median**	**P-Value**
19-29	25	4.370	1.593	4.42	0.0077
30-39	14	2.663	1.551	3.03	
40>	8	3.823	1.833	4.09	
Lingual Left					
19-29	25	4.150	1.767	1.958	0.0004
30-39	14	6.649	1.193	6.655	
40>	8	4.55	2.41	4.55	
Buccal Right					
19-29	25	3.691	1.958	4.33	0.2175
30-39	14	3.144	2.010	3.51	
40>	8	2.483	1.968	2.61	
Lingual Right					
19-29	25	4.136	2.390	3.76	0.2938
30-39	14	5.107	2.693	5.41	
40>	8	4.605	2.964	6.005	

P-Values > 0.05. There is insufficient evidence to reject the null hypothesis on the right side.

Objective 2) Association between buccal-lingual and position of IAC

Table 3.10 Summary statistics of the position of the IAC

	IAC Position	Frequency	Proportion
Point A left	Buccal	5	10.64
	Inferior	18	38.30
	Lingual	24	51.06
Point A right	Buccal	4	8.51
	Inferior	23	48.94
	Lingual	20	42.55
Point B left	Buccal	2	4.26
	Inferior	39	82.98
	Lingual	6	12.77
Point B right	Inferior	38	80.85
	Lingual	9	19.15
Point C left	Inferior	45	95.74
	Lingual	2	4.26
Point C right	Inferior	45	95.74
	Lingual	2	4.26
Point D left	Inferior	45	95.74
	.	2	4.26
Point D right	Buccal	1	2.13
	Inferior	39	82.98
	.	7	14.89

The position of the IAC such as Inferior, buccal, and lingual was reported. The measurements taken from Point A and left of point B have all three positions of IAC recorded.
Therefore, to test for whether there was an association between the thicknesses of the buccal-lingual cortices point A was only considered. The values of the buccal and lingual cortices of both sides were used to determine the position of the IAC on both left and right sides.

The Lingual measurements are not normally distributed (could not use ANOVA); therefore, **non-parametric test was used** to test for whether there is equality of thickness between the three positions. See QQ-Plot below.

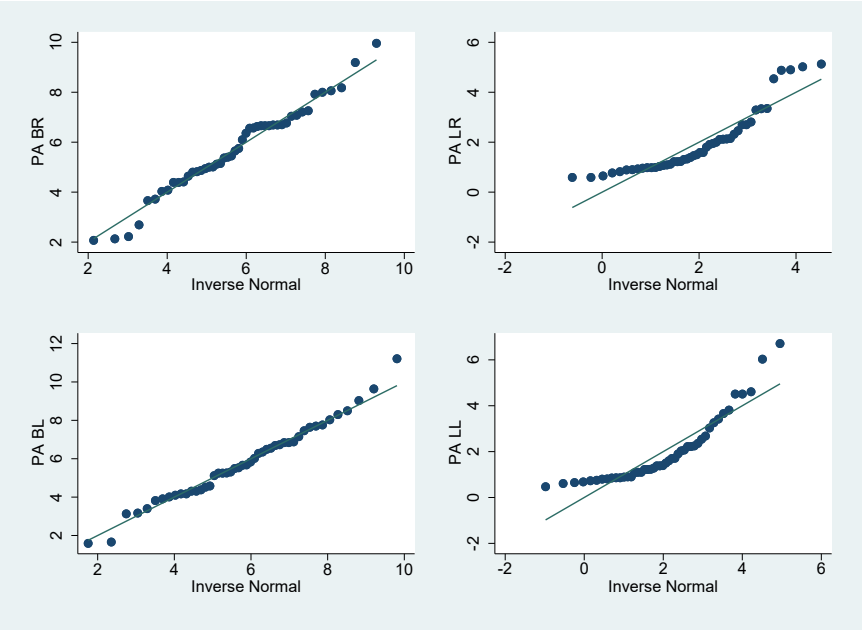

Figure 3.5 QQ-Plots for buccal-lingual cortices at Point A

Kruskal-Wallis test was used to determine if there is an association between position of the IAC and the buccal-lingual thickness.

Ho: The population medians of all positions are the same.
Ha: At least one population median of the sample (position) was different from the population median of another position.

Table 3.11 Association of the position of IAN on the left side

		n	Mean	Median	IQR	P-value
Buccal Left	B	5	4.684	4.38	1.43	0.0001
	I	18	4.412	4.24	1.4	
	L	24	7.035	6.785	2.14	
Lingual Left	B	5	4.478	4.61	2.22	0.0001
	I	18	2.368	2.235	1.88	
	L	24	1.185	0.9	0.775	
Buccal right	B	5	4.742	4.41	0.72	0.0003
	I	18	4.672	4.97	1.06	
	L	24	6.704	6.675	1.36	
Lingual right	B	5	3.086	2.46	2.78	0.0576
	I	18	2.094	1.93	1.47	
	L	24	1.612	1.22	0.93	

The P-values < 0.05, therefore, the null hypothesis is rejected. Therefore, the buccal-lingual thickness differs at the IAC positions Inferior, Buccal and Lingual. However, Lingual right P-value = 0.0576 was only marginally significant.

Table 3.12 Association of the position of IAN on the right side

		n	Mean	Median	IQR	P-value
Buccal Left	B	4	4.865	4.345	2.43	0.0039
	I	23	4.964	4.58	2.48	
	L	20	6.903	6.62	2.225	
Lingual Left	B	4	3.108	3.11	2.905	0.0187
	I	23	2.332	1.7	2.16	
	L	20	1.371	0.99	1.205	
Buccal right	B	4	4.643	4.4	2.205	0.0001
	I	23	4.775	4.87	1.72	
	L	20	7.016	6.69	1.36	
Lingual right	B	4	4.508	4.78	1.135	0.0001
	I	23	2.220	2.11	1.37	
	L	20	1.137	1.01	0.485	

The P-values < 0.05, therefore, the null hypothesis was rejected. It was statistically significant that the buccal-lingual thickness differs at the IAC positions Inferior, Buccal and Lingual.

Objective 3) Factors associated with IAC Position.

Association between gender, age, and IAC Position

Fisher's exact test was run to test for association between gender, age, and IAC Position.

Ho: There is no association between gender and IAC position

Ha: There is an association between gender and IAC position

Table 3.13 Association between gender and IAC position

Gender	B	I	L	P-Value
Female	1	18	3	1.000
Male	1	21	3	

P-value > 0.05. Do not reject null hypothesis. There is no association between gender and IAC position.

Ho: There is no association between age and IAC position

Ha: There is an association between age and IAC position

Table 3.14 Association between age and IAC position

Age	B	I	L	P-Value
19-29	1	21	3	0.588
30-39	1	10	3	
>40	0	8	0	

P-value > 0.05. Do not reject the null hypothesis. There is no association between age and IAC Position.

Chapter 4: Discussion

It is fundamental to have a broader knowledge on the position of the IAC that house the IAN and the amount of bone around it. This can be easily provided by a CBCT which is not routinely used in our dental institutions despite its low radiation exposure relative to routine imaging devices. Neurological deficits that mostly occur on the IAN are mostly due to the surgical procedures that are performed along the course of the IAN. These surgical procedures include dental implant placement, surgical extractions around the lower molar area, internal fixations using plates, mandibular ramus graft and bilateral surgical split osteotomy[3].

The IAC on the traditional radiographs such as panoramic and intra-oral periapical shows the vertical relationship to the teeth whereas CBCT provide both vertical and transverse relationship. The measurements on CBCT can be produced accurately and the structures can be clearly identified under magnification.

4.1. The thickness of the buccal-lingual cortical bone from the IAC to mental foramen

In this study it was found that the buccal cortex increased from point A to point B, it also decreased from point B through point C and point D. The lingual side increased throughout from point A to point D on both sides of the mandible (as depicted on table 3.1). The buccal cortex width is greater on the left than the right side and the lingual cortical thickness is also greater than the right with an exception at point C. Khorshidi et al, Padayachee et al, de Oliveira Júnior et al showed a similar pattern using different fiducial landmarks on the mandible[26,27,30].

Padayachee et al reported that the buccal thickness on the left side was greater than the right side and it was statistically significant in a study sample of 100 [27]. Balaji et al and de Oliveira Júnior et al were in contrast with the findings of this study as they have reported the right side to be greater than the left side and their findings were not statistically significant. The sample size of de Oliveira Júnior et al was 100 (50 males and 50 females) and Balaji's et al was 20 (10 males and 10 females) [29,30].

4.1.1. Association of gender and thickness of the cortices

In the present study it was found that the males had a thicker buccal cortex at point A, B, C and a thinner cortex at point D compared to females. The buccal cortical thickness was different when compared between male and females, at point A, B and D male right side was thicker than the left side with an exception on point C. Females had thicker buccal cortex on the right side at point A and B whereas at point C and D was thicker on the left. The lingual cortex values were not normally distributed on all points. The values are not statistically significant on both cortices and sides (as depicted on tables 3.2 to 3.5).

These findings were in contrast to the earlier studies that were conducted. Levine et al, Balaji et al and Shokry et al reported that females had greater buccal thickness compared to males on the first molar, and also Chua et al reported it on the second molar where their findings were found to be statistically significant[18,29,31,37]. Shokry et al also reported that there was a difference between left and right sides in females[18]. Kawashima et al reported that the lingual and buccal cortex was thicker in females than males despite the fact that buccal cortex was not statistically significant[33].

In this study it was found that the mean and median values had minor differences for all points A to D between males and females however they were not statistically significant and concurred with the study conducted by Simonton where measurements were taken from both mesial and distal roots of first and second molar[35], as well as the study conducted by Mousa et al where measurements were taken from the bifurcation of the first molar[36].

4.1.2. Association of age and thickness of the cortices

In the present study point A and D were considered as they had shown differences in the buccal-lingual thickness of the cortices. At point A both left and right buccal cortices shows the median increase in all age groups. The lingual cortex on the left showed an increase between age group 19-29 and 30-39 and a decrease between 30-39 and greater than 39. The right side showed an increase in all age groups. The findings were not statistically significant. At point D there was a difference in medians across buccal-lingual cortices with the right lingual cortical thickness increasing with increase in age and right buccal cortical thickness decreasing with increase in age(as depicted on figure 3.2). In both left buccal and lingual cortices it was statistically

significant that there was a difference in the thickness with age (as depicted on table 3.7). In the age groups 19-29 and 30-39 there was an increase of the left lingual cortex with an increase in age, between 30-39 and greater than 39 there was a decrease whereas the left buccal was contrariwise to it. This finding was in contrast with the findings of a study that was conducted in America where it was reported that there was a decrease of the buccal thickness with an increase in age of 40 years and greater[37].

In the study conducted by Shokry et al it was reported that there was a significant difference between age groups. This study concluded that with age there was an increase in buccal thickness in the second molar region between the age group, 36 to 45 and 46 to 61 years. There was an increase in lingual cortex in the age group of 15 to 25 years[18].

Simonton et al reported that the comprehensive mandibular thickness decreased with an increase in age (30-60yrs) in both male and female at the mesial and distal root of the first molar[35]. Nagadia et al tested the buccal and lingual cortices on the first molar area, the lingual cortical thickness increased with an increase in age and the buccal cortex decreased with increase in age[29]. de Oliveira Junior compared the thickness of the buccal and lingual cortices between the age groups of 25-50yrs and 51-75yrs and found a decrease in thickness with increase in age[30]. Nagadia et al and de Oliveira et al concurred with the findings of this study.

4.2. To determine whether there is association between position of the IAC and thickness of the cortices

In the present study the IAC was found to be in a buccal, lingual and inferior to the fiducial landmarks on both left and right sides. The position of the IAC on point A and B left was found in all three positions. Two positions at point B right and C whereas at point D it was only inferiorly positioned (as depicted on table 3.8). Tables 3.9 and 3.10 shows that there was an association of the position of the IAC at point A with buccal-lingual thickness on both sides which was statistically significant and on the lingual right was not. The lingual position was high at point A. This finding concurred with the previous investigators where the IAC was close to the lingual cortex at the molar region and buccal cortex at the premolar region. The different investigators reported that the IAC courses close to the lingual cortical cortex at the posterior (molar) region and crosses at the first molar region to be buccally at the premolar region[24,25,27].

4.3. To determine the factors associated with buccal-lingual position of the nerve

In the present study three different positions of IAC was found at point A and they were not associated with gender and age. This finding concurs with a study conducted by Obradovic who reported that age and gender were not statistically significant factors associated with the position of the IAC[6]. The position of the IAC whether buccal, lingual or inferior can be attributed to the type of the IAC as; straight projection, catenary-like projection and progressive descent[20,21]. It was also determined by the type and depth of impaction, position of the roots of the third molar and the width or thickness of the buccal-lingual cortices[6,14,15].

4.4. Limitations

There were many limitations that were encountered in this study. The first was the limited sample size as each patient does not get a routine CBCT like a panoramic radiograph. CBCT in our institution was taken mostly for pathology such as cysts and tumours, implant planning and if there was a sign of the IAC being near the third molar teeth. Secondly patients who were consulted for therapeutic reasons, who went for CBCT images could not meet inclusion criteria.

4.5. Conclusion

CBCT play an integral role in diagnostic imaging due to details of the images. The position of the IAC that houses IAN is influenced by various factors including but not limited to gender and age as well as the surrounding anatomy. By understanding the surrounding anatomical influences on the position of the IAN, any surgery to the area would minimize complications associated with the IAN especially with the use of detailed imaging such as CBCT.

This study will be able to give guidance on the depth of penetration of the buccal cortex during the surgical procedures around the IAN including bilateral surgical split osteotomy, surgical extraction around the lower molar teeth area, internal fixation, mandibular ramus graft and dental implant placement. Based on the findings of this study we recommend a depth of 6mm from the outer buccal cortex when performing these surgical procedures around the IAN. Litigations in respect to IAN injury will decrease as CBCT imaging would show three-dimensional view of the IAN.

4.6. Recommendation

A study on a South African population with a large sample size and different ethnic groups should be conducted.

4.7. Declaration of interest

None

4.8. Funding

None

Reference

1. Von Arx T, Friedli M, Sendi P, Lozanoff S, Bornstein MM. Location and dimensions of the mental foramen: a radiographic analysis by using cone-beam computed tomography. J Endod. 2013; 39(12) :1522-1528.

2. Kalladka M, Proter N, Benoliel R, Czerninski R, Eliav E. Mental nerve neuropathy: patient characteristics and neurosensory changes. Oral Surg Oral Med Oral Pathol Oral Radiol. 2008;106(3):364-70.

3. Kipp DP, Goldstein BH, Weiss WW Jr. Dysesthesia after mandibular third molar surgery: a retrospective study and analysis of 1,377 surgical procedures. J Am Dent Assoc. 1980;100(2):185-92.

4. Monaco G, Montevecchi M, Bonett GA, Gatto MRA, Checchi L. Reliability of panoramic radiography in evaluating the topographic relationship between the mandibular canal and impacted third molars. J Am Dent Assoc, 2004; 135(3):312-318.

5. Rood JP, Shehab BN. The radiological prediction of inferior alveolar nerve injury during third molar surgery. Br J Oral Maxillofac Surg. 1990 ; 28(1):20-5.

6. Obradovic O, Todorovic L, Vitanovic V. Anatomical considerations relevant to implant procedures in the mandible. Bull Group Int Rech Sci Stomatol Odontol. 1995; 38(1-2):39-44.

7. Miller CS, Nummikoski PV, Barnett DA. Langlais RP. Cross-sectional tomography: A diagnostic technique for determining the buccolingual relationship of impacted mandibular third molars and the inferior alveolar neurovascular bundle. Oral Surg Oral Med Oral Pathol Oral Radiol. 1990; 70(6): 791-797.

8. Kumar M, Shanavas M, Sidappa A, Kiran M. Cone beam computed tomography-know its secrets. J Int Oral Health. 2015; 7(2):64.

9. Nanci A. Ten Cate's oral histology: development, structure, and function. Philadelphia: Elsevier; 2017.

10. Moore KL, Persaud TVN, Torchia MG. The developing human: clinically oriented embryology. Philadelphia, Pa: Saunders/Elsevier; 2007

11. Lee SK, Kim YS, Oh HS, Yang KH, Kim EC, Chi JG. Prenatal development of the human mandible. Anat. Rec. 2001;263(3):314-25.

12. Sadler TW, Langman J. Langman's essential medical embryology. Philadelphia, Pa. ; London: Lippincott Williams & Wilkins; 2005.

13. Szabo-Rogers HL, et al. New directions in craniofacial morphogenesis. Dev Biol. 2010;341:84–94.

14. Depew MJ, Compagnucci C. Tweaking the hinge and caps: testing a model of the organization of jaws. J. Exp. Zool B: Mol. 2008;310(4):315-35.

15. Rikhotso RE, Munsamy C. A morphological study of the lingula in South Africans in relation to sagittal split osteotomy. S. Afr. Dent J. 2017;72(9):408-12.

16. Tshite K. Location of mandibular foramen on mandibles of adult black South African population: a morphometric analysis and investigation into possible radiographic correlation [unpublished Masters of Science in Dentistry thesis on the Internet]. Johannesburg: University of the Witwatersrand; 2017 [cited 2018 October 21]. Available from: https://wiredspace.wits.ac.za/server/api/core/bitstreams/8ee0e2f4-5d8d-4067-b78f-9b6384f4883e/content

17. McKay C, Tchokonte-Nana V, Mbajiorgu EF. The Mental Foramen in Dry Human Mandibles of Adult South Africans: An Anatomical Study. Int J Morphol. 2018;36(4).

18. Shokry SM, Alshaib SA, Al Mohaimeed ZZ, Ghanimah F, Altyebe MM, Alenezi MA, Shadd F, Aldali SZ, Alotaibi MM. Assessment of the inferior alveolar nerve canal course among Saudis by cone beam computed tomography (pilot study). J Maxillofac Oral Surg. 2019 Sep;18(3):452-8.

19. Safaee A, Mirbeigi S, Ezoddini F, Khojastepour L, Navab-Azam A. Buccolingual course of the inferior alveolar canal in different mental foramen locations: a cone beam computed tomography study of an Iranian population. Int. J.Appl. Basic Med. Res. 2016;6(4):262.

20. Worthington P. Injury to the inferior alveolar nerve during implant placement: a formula for protection of the patient and clinician. Int J Oral Maxillofac Implants. 2004;19(5).

21. Ozturk A, Potluri A, Vieira AR. Position and course of the mandibular canal in skulls. Oral Surg Oral Med Oral Pathol Oral Radiol. 2012;113(4):453-8.

22. Liu, T., Xia, B. and Gu, Z. Inferior alveolar canal course: a radiographic study. Clin Oral Implants Res. 2009;20(11):1212-1218.

23. Abdallah Edrees MF, Moustafa Attia A, Abd Elsattar MF, Fahmy Gobran HG, Ismail Ahmed A. Course and topographic relationships of mandibular canal: A cone beam computed tomography study. Int J Dentistry Oral Sci. 2017;4(3):444-9.

24. Davis, H. Mobilization of the Alveolar Nerve to Allow Placement of Osseointegratible Fixtures. Advanced Osseointegration Surgery: Application in the Maxillofacial Region. Chicago: Quintessence Publishing Co, 2000.129-141.

25. Khorshidi H, Raoofi S, Ghapanchi J, Shahidi S, Paknahad M. Cone beam computed tomographic analysis of the course and position of mandibular canal. J Maxillofac Oral Surg. 2017;16(3):306-11.

26. Padayachee S, Holmes H, Parker ME. Determining an average distance from the external mandibular cortex to the inferior alveolar canal using cone beam computed tomography (CBCT) imaging: an aid to harvesting mandibular ramus autogenous grafts. S. Afri. Dent. J. 2016;71(9):390-4.

27. Koivisto T, Chiona D, Milroy LL, McClanahan SB, Ahmad M, Bowles WR. Mandibular canal location: cone-beam computed tomography examination. J. Endod.2016;42(7):1018-21.

28. Balaji SM, Krishnaswamy NR, Kumar SM, Rooban T. Inferior alveolar nerve canal position among South Indians: A cone beam computed tomographic pilot study. Ann. Maxillofac. Surg. 2012;2(1):51.

29. Nagadia R, Tay AB, Chan LL, Chan EY. The spatial location of the mandibular canal in Chinese: a CT study. Int J Oral Maxillofac Surg. 2011;40(12):1401-5.

30. de Oliveira Júnior MR, Saud AL, Fonseca DR, De-Ary-Pires B, Pires-Neto MA, de Ary-Pires R. Morphometrical analysis of the human mandibular canal: a CT investigation. Surg Radiol Anat. 2011;33(4):345-52.

31. Chua MK, Koh WJ, Nimbalkar S, Patil PG. CBCT Evaluation of Buccolingual Orientation of Inferior Alveolar Canal in Mandibular Posterior Region for Implant Planning. Int J Dent. 2022;2022.

32. Lee HE, Han SJ. Anatomical position of the mandibular canal in relation to the buccal cortical bone: relevance to sagittal split osteotomy. J Korean Assoc Oral Maxillofac Surg. 2018;44(4):167-73.

33. Kawashima Y, Sakai O, Shosho D, Kaneda T, Gohel A. Proximity of the mandibular canal to teeth and cortical bone. J Endod. 2016;42(2):221-4.

34. Mallick A, Vidya KC, Waran A, Rout SK. Measurement of lingual cortical plate thickness and lingual position of lower third molar roots using cone beam computed tomography. J Int Soc Prev Communit Dent. 2017; S8-12.

35. Simonton JD, Azevedo B, Schindler WG, Hargreaves KM. Age-and gender-related differences in the position of the inferior alveolar nerve by using cone beam computed tomography. J Endo. 2009;35(7):944-9.

36. Mousa A, El Dessouky S, El Beshlawy D. Sex determination by radiographic localization of the inferior alveolar canal using cone-beam computed tomography in an Egyptian population. Imaging Sci Dent. 2020;50(2):117.

37. Levine MH, Goddard AL, Dodson TB. Inferior alveolar nerve canal position: a clinical and radiographic study. J. Oral and Maxillofac. Surg. 2007;65(3):470-4.

ANNEXURE A

DATA COLLECTION FORM

Patient's Age:

Patient's gender:

Research code:

Points	Buccal left	Lingual Left	Position of IAC	Buccal right	Lingual right	Position of IAC
Point A						
Point B						
Point C						
Point D						

ANNEXURE B

UNIVERSITY OF THE WITWATERSRAND, JOHANNESBURG

FACULTY OF HEALTH SCIENCES

School of Oral Health Science

Department of Oral Biological Sciences, 7 York Road, Parktown, 2193. Tel: 011 717 2045 Fax: 086 553 3890 Email: Juliths.Molepo@wits.ac.za

11 July 2019

Dr K. Seleke
Maxillo-facial and Oral Surgery
Faculty of Health Sciences
University of the Witwatersrand
Johannesburg

RE: PERMISSION TO CONDUCT RESEARCH

REFERENCE: HRRC/JULY/05/2019

It is my pleasure to grant final approval to conduct your research at Wits Oral Health Centre titled "Analysis of the thickness of the cortices along the course of inferior alveolar nerve".

The Hospital Research and Risk Committee allocated a unique reference number to this application – Kindly quote this reference number in all future correspondence regarding this research.

Please note that the Hospital Research and Risk Committee should be informed of the estimated date the research will commence, as well as regular status reports until the research has been concluded. Within a month after conclusion of the research project, a written report must be submitted to the Head of School/CEO, summarizing the final result/outcome as well as the recommendations made based on the research concluded.

Regards,

Prof M. S Nemutandani
CEO/Head of School
Date: 12/07/2019

ANNEXURE B

UNIVERSITY OF THE WITWATERSRAND JOHANNESBURG

R14/49 Dr Kgothatso Morake Seleke

HUMAN RESEARCH ETHICS COMMITTEE (MEDICAL)

CLEARANCE CERTIFICATE NO. M190266

NAME: (Principal Investigator)	Dr Kgothatso Morake Seleke
DEPARTMENT:	Maxillofacial and Oral Surgery Wits Oral Health Sciences General Dental Practice - Radiology Section
PROJECT TITLE:	Analysis of the thickness of the cortices along the course of inferior alveolar nerve
DATE CONSIDERED:	22/02/2019
DECISION:	Approved unconditionally
CONDITIONS:	
SUPERVISOR:	Dr Mzubanzi Mabongo and Dr Daisy.F Kotsane
APPROVED BY:	Dr CB Penny, Chairperson, HREC (Medical)
DATE OF APPROVAL:	08/07/2019

This clearance certificate is valid for 5 years from date of approval. Extension may be applied for.

DECLARATION OF INVESTIGATORS

To be completed in duplicate and **ONE COPY** returned to the Research Office Secretary on the Third Floor, Faculty of Health Sciences, Phillip Tobias Building, 29 Princess of Wales Terrace, Parktown, 2193, University of the Witwatersrand. I/we fully understand the conditions under which I am/we are authorized to carry out the above-mentioned research and I/we undertake to ensure compliance with these conditions. Should any departure be contemplated, from the research protocol as approved, I/we undertake to resubmit the application to the Committee. **I agree to submit a yearly progress report**. The date for annual re-certification will be one year after the date of convened meeting where the study was initially reviewed. In this case, the study was initially reviewed in **February** and will therefore be due in the month of **February** each year. Unreported changes to the application may invalidate the clearance given by the HREC (Medical).

Principal Investigator Signature Date

PLEASE QUOTE THE PROTOCOL NUMBER IN ALL ENQUIRIES

ANNEXURE C

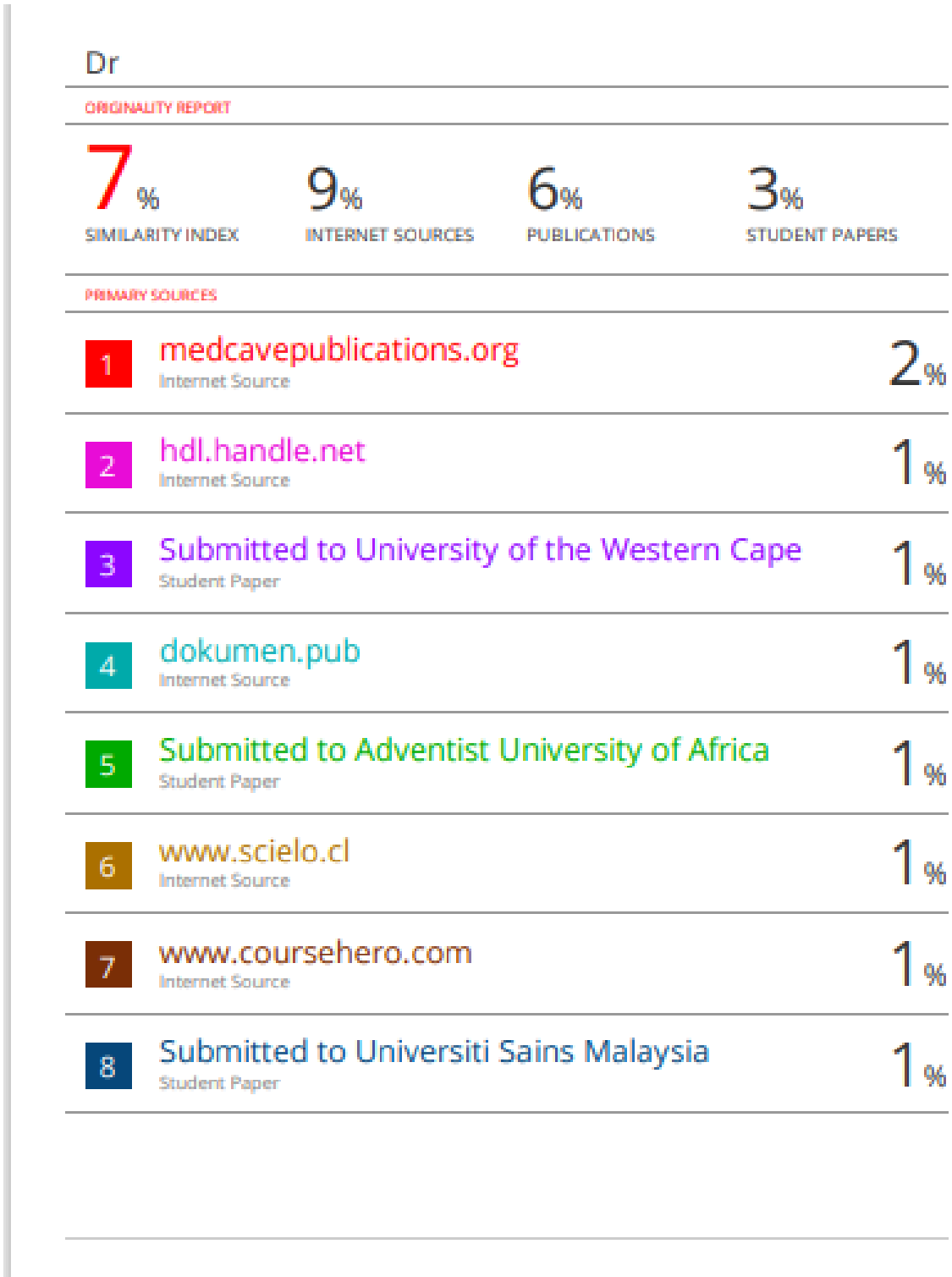

Dr

ORIGINALITY REPORT

7%	9%	6%	3%
SIMILARITY INDEX	INTERNET SOURCES	PUBLICATIONS	STUDENT PAPERS

PRIMARY SOURCES

1	medcavepublications.org Internet Source	2%
2	hdl.handle.net Internet Source	1%
3	Submitted to University of the Western Cape Student Paper	1%
4	dokumen.pub Internet Source	1%
5	Submitted to Adventist University of Africa Student Paper	1%
6	www.scielo.cl Internet Source	1%
7	www.coursehero.com Internet Source	1%
8	Submitted to Universiti Sains Malaysia Student Paper	1%

Exclude quotes	On	Exclude matches	< 1%
Exclude bibliography	On		

Dr

GRADEMARK REPORT

FINAL GRADE

/0

GENERAL COMMENTS

Instructor

PAGE 1

PAGE 2

PAGE 3

PAGE 4

PAGE 5

PAGE 6

PAGE 7

PAGE 8

PAGE 9

PAGE 10

PAGE 11

PAGE 12

PAGE 13

PAGE 14

PAGE 15

PAGE 16

PAGE 17

PAGE 18

PAGE 19