

https://dspace.org/

Treatment of giant cell arteritis

Miguel Gonzalez-Gay; T Pina; D Prieto-Pena; M Calderon-Goercke; Oreste Gualillo ...

https://hdl.handle.net/10539/35077
ISI

Downloaded from a DSpace repository. https://dspace.org/

Biochemical Pharmacology 165 (2019) 230–239

Contents lists available at ScienceDirect

Biochemical Pharmacology

journal homepage: www.elsevier.com/locate/biochempharm

Review

Treatment of giant cell arteritis

Miguel Á. González-Gay[a,b,c,*], Trinitario Pina[a], Diana Prieto-Peña[a], Mónica Calderon-Goercke[a], Oreste Gualillo[d,e], Santos Castañeda[f]

[a] Division of Rheumatology and Epidemiology, Genetics and Atherosclerosis Research Group on Systemic Inflammatory Diseases, Hospital Universitario Marqués de Valdecilla, Instituto de Investigación Marqués de Valdecilla (IDIVAL), Spain
[b] University of Cantabria, Santander, Spain
[c] Cardiovascular Pathophysiology and Genomics Research Unit, School of Physiology, Faculty of Health Sciences, University of the Witwatersrand, Johannesburg, South Africa
[d] The NEIRID Group (Neuroendocrine Interactions in Rheumatology and Inflammatory Diseases), Servizo Galego de Saude, Santiago de Compostela, Spain
[e] Instituto de Investigación Sanitaria de Santiago de Compostela (IDIS), Santiago University Clinical Hospital, Santiago de Compostela, Spain
[f] Rheumatology Division, Hospital de La Princesa, IIS-Princesa, Cátedra UAM-Roche (EPID-Future), Universidad Autónoma de Madrid (UAM), Madrid, Spain

ARTICLE INFO

Keywords:
Anti-IL6-receptor tocilizumab
Biologic agents
Giant cell (temporal) arteritis
Methotrexate
Polymyalgia rheumatica
Prednisone
Relapses

ABSTRACT

Giant cell arteritis (GCA) is the most common form of vasculitis in adults. Cranial manifestations are typical clinical features of this vasculitis. Sometimes the presenting symptoms are nonspecific and, in some cases, large-vessel involvement may prevail. Polymyalgia rheumatica is a frequent manifestation that in some cases may be the presenting symptom of GCA. Visual complications, in particular the risk of blindness, constitute the most feared manifestations of GCA. Prompt recognition of this vasculitis is required to avoid irreversible complications. Prednisone/prednisolone at a dose of 40–60 mg/day is the cornerstone therapy in GCA. Glucocorticoids lead to rapid improvement of symptoms and may reduce the risk of irreversible visual loss. However, relapses are common when the prednisone dose is tapered. Therefore, additional therapies are required in relapsing GCA or when a rapid reduction of glucocorticoids is needed. The most widely used conventional immunosuppressive drug is methotrexate Adjunctive treatment with methotrexate may decrease the risk of relapses and reduce glucocorticoid exposure. However, comprehensive reviews indicate that the efficacy of methotrexate in GCA is modest. The experience with other conventional immunosuppressive drugs in GCA patients is scarce. In some cases, the new biologic agents are required. Among them, the most frequently used is the recombinant humanized anti-IL-6 receptor antibody tocilizumab. It improves clinical symptoms, reduce the cumulative prednisone dose and the frequency of relapses in GCA patients. However, anti-tumor necrosis factor-α therapy is not useful in GCA. Promising results on other biologic agents, such as abatacept, ustekinumab or anakinra, require further confirmatory studies.

1. Introduction

Giant cell arteritis (GCA), also called temporal arteritis, is a granulomatous vasculitis affecting mainly large and middle-sized arteries, in particular the branches of the proximal aorta [1]. GCA is the most common form of vasculitis in adults, in particular in Western countries [2]. It almost exclusively affects patients aged 50 years or older [2,3]. The incidence increases in the older age groups being more common in the eighth decade of life [4].

Cranial manifestations are common, being the result of the arteritic involvement of branches derived of the external carotid artery [5]. They include new onset headache, generally bitemporal, scalp tenderness, facial pain, jaw and more rarely tongue claudication, and non-productive cough [5]. However, the most feared manifestation is the development of blindness, which in most cases is the result of the vasculitis involvement of arteries derived from the ophthalmic artery that, in turn, is a branch of the internal carotid artery [6–8]. Strokes, mainly due to the vasculitis involvement of the vertebrobasilar territory, are not exceptional complications [6,9]. Polymyalgia rheumatica, a condition that is also more frequents in individuals older than

Abbreviations: GCA, giant cell arteritis; PET/CT, positron emission tomography/computed tomography-scan

* Corresponding author at: Division of Rheumatology and Epidemiology, Genetics and Atherosclerosis Research Group on Systemic Inflammatory Diseases, Hospital Universitario Marqués de Valdecilla, Instituto de Investigación Marqués de Valdecilla, University of Cantabria, Santander 39011, Spain.
E-mail addresses: miguelaggay@hotmail.com (M.Á. González-Gay), trinitario.pina@scsalud.es (T. Pina), diana.prieto@scsalud.es (D. Prieto-Peña), monica.calderon@scsalud.es (M. Calderon-Goercke), Oreste.Gualillo@sergas.es (O. Gualillo).

https://doi.org/10.1016/j.bcp.2019.04.027
Received 30 January 2019; Accepted 25 April 2019
Available online 26 April 2019
0006-2952/ © 2019 Elsevier Inc. All rights reserved.

50 years [1,10,11], may be the presenting manifestation of GCA [11,12,13]. Polymyalgia rheumatica features are observed in up to 50% of the patients with GCA [5,11]. The musculoskeletal manifestations in patients with isolated polymyalgia are similar to those observed in patients with polymyalgia rheumatica associated with the typical cranial pattern of GCA [14]. However, patients with isolated polymyalgia rheumatica often have less severe inflammatory response than those with polymyalgia rheumatica associated with GCA [14].

Although cranial ischemic manifestations are the hallmark features of GCA, recent studies have shown a growing number of patients with predominant extracranial large-vessel vasculitis involvement, often not associated with the classic cranial manifestations [15,16]. Imaging techniques, such as the fluorine-18-fluorodeoxyglucose (18F-FDG) positron emission tomography/computed tomography (FDG-PET/CT)-scan, have confirmed that extra-cranial large-vessel vasculitis is not uncommon in GCA [17].

The physical examination often shows abnormalities of the temporal arteries, such as thickening, tenderness, beading or reduced pulsation [5,18]. Pulse deficits due to peripheral arterial vasculitis may also be observed [18]. Patients with GCA have a higher risk of aneurysms and dissection over the course of the disease, especially in the thoracic segment [19,20].

High erythrocyte sedimentation rate (ESR) and/or C reactive protein (CRP) are observed in the majority of patients [21]. In some cases, non-specific features, unexplained anemia or fever of unknown origin may be the only features of a silent "occult GCA" [22,23].

Table 1 summarizes the main clinical features that may alert the clinicians on the presence of GCA.

In patients with the classic cranial pattern of the disease a positive temporal artery biopsy is considered the gold-standard for diagnosis [24]. It shows an inflammatory infiltrate with the presence of multinucleated giant cells between the media and intima layers in 50% of the cases and disruption of the internal elastic lamina, ultimately leading to partial or complete obstruction of local arterial blood flow. A temporal artery ultrasound may be a good alternative to the temporal artery biopsy in these patients [25].

Imaging techniques, such as MRI or computed tomography-angiography or PET/CT-scan, can help to diagnose patients with predominant extracranial features [25]. Experts in the field consider that in some cases imaging techniques may also be used to monitor response to treatment [26]. *Graphical abstract* shows the main clinical differences between the classical (cranial) and the extracranial phenotypes of GCA.

Table 1
Symptoms, clinical features and alarm signs of GCA.

A) Typical cranial ischemic manifestations
New onset headache (mainly bitemporal)
Scalp tenderness
Jaw claudication
Facial pain
Tongue claudication
Unexplained dry cough
Temporal artery abnormalities on physical examination
Acute visual deficits
Anterior ischemic optic neuropathy or central retinal artery occlusion on ophthalmologic examination
B) Associated constitutional symptoms
C) Associated polymyalgia rheumatica symptoms*
D) Associated anemia and/or elevated C reactive protein/erythrocyte sedimentation rate
E) Extra-cranial disease
Ischemic signs and symptoms of extremities, especially in the absence of other cardiovascular risk factors or emboligenic cardiopathy:
Limb claudication
Pulse asymmetry
Arterial pressure asymmetry
Peripheral arterial bruits
Distal necrosis or gangrene
F) Non-specific manifestations without evidence of infectious o neoplastic disease:
Fever
Weight loss
Fatigue/malaise
Unexplained anemia
G Detection of aneurysm or dissection of aorta and main branches along with raised inflammatory markers

*Polymyalgia rheumatica that relapses or responds poorly to standard glucocorticoid therapy.
*Polymyalgia rheumatica with associated ischemic manifestations.

2. Pathogenesis of GCA

The precise etiology and pathogenesis of GCA are not well known. Experts in the field consider that GCA is the results of unknown environmental factors in individuals genetically predisposed. GCA affects mainly large- and medium-sized vessels leading to vascular inflammation and granuloma formation, leading in the long run to intimal hyperplasia and occlusion of the arterial lumen along with destruction of the vessel wall. The vascular damage is responsible of the development of vascular complications such as ischemic events and aneurysms [27].

There are a number of studies emphasizing the role of the genetic background in the susceptibility to GCA. The particular relevance is the strong association between GCA and the human leukocyte antigen (HLA) region [28,29]. A recent immunochip approach study assessing 1651 GCA patients from six different countries of European ancestry, and 15306 unrelated controls confirmed that class II HLA was the genomic region with the strongest association with GCA [30]. Outside the major histocompatibility complex (MHC) region, variants in PTPN22 locus [30] and other genes related to vascular response to inflammation and vascular remodeling, such as plasminogen and prolyl 4-hydroxylase subunit alpha 2, are also interestingly associated with GCA risk [31]. Other gene polymorphisms have been associated with increased risk of severe ischemic complications, including blindness [32,33]. Besides a genetic component, environmental factors and epigenetic modifications are thought to be involved in the pathogenesis of GCA (Fig. 1). In this regard, several studies have suggested the potential influence of different bacterial strains (such as Chlamydia pneumonia and Burkholderia), and viruses (cytomegalovirus, parvovirus B19, herpes simplex virus and human parainfluenzae 1) in the induction of GCA [34–36]. Unfortunately, these studies often yielded contradictory results and the role of infectious agents has not been confirmed in larger cohort studies, raising concern about the strong implication of infectious agents in the pathogenesis of GCA.

It is plausible to think that aging itself may be implicated in the pathogenesis of the disease, probably as a result of the influence of environmental effects and epigenetic modifications that occur throughout the life of the patient [37]. Because of that, differences in the DNA methylation level of several genes have been reported in temporal arteries from GCA patients when compared with non-GCA patients [38]. Besides, aging induces structural changes and biochemical modifications of matrix proteins into the arterial walls, which could activate immunization against arterial auto-antigens leading to GCA development [37].

Regardless of the trigger factors, it is known that inflammation in GCA starts in the adventitia and later spreads into the inner layers of the vessel wall. The adventitia is abundant in resident macrophages and dendritic cells (DCs) expressing Toll-like receptors, which are abnormally activated in this vasculitis via pathogen-associated molecular patterns (PAMPs) or microorganism-associated molecular patterns (MAMPs), leading to the production of pro-inflammatory cytokines such as interleukin (IL)-1 and IL-6 as well as the activation of T cells [27]. Furthermore, DCs express high levels of class-II MHC and co-stimulatory molecules (CD80 and CD86), making them able to activate CD4 + T lymphocytes [39,40].

The importance of CD4 + T cells in the pathogenesis of GCA is suggested by the fact that their depletion in the model of SCID mice engrafted with GCA arteries strongly decreases vasculitis lesions [41].

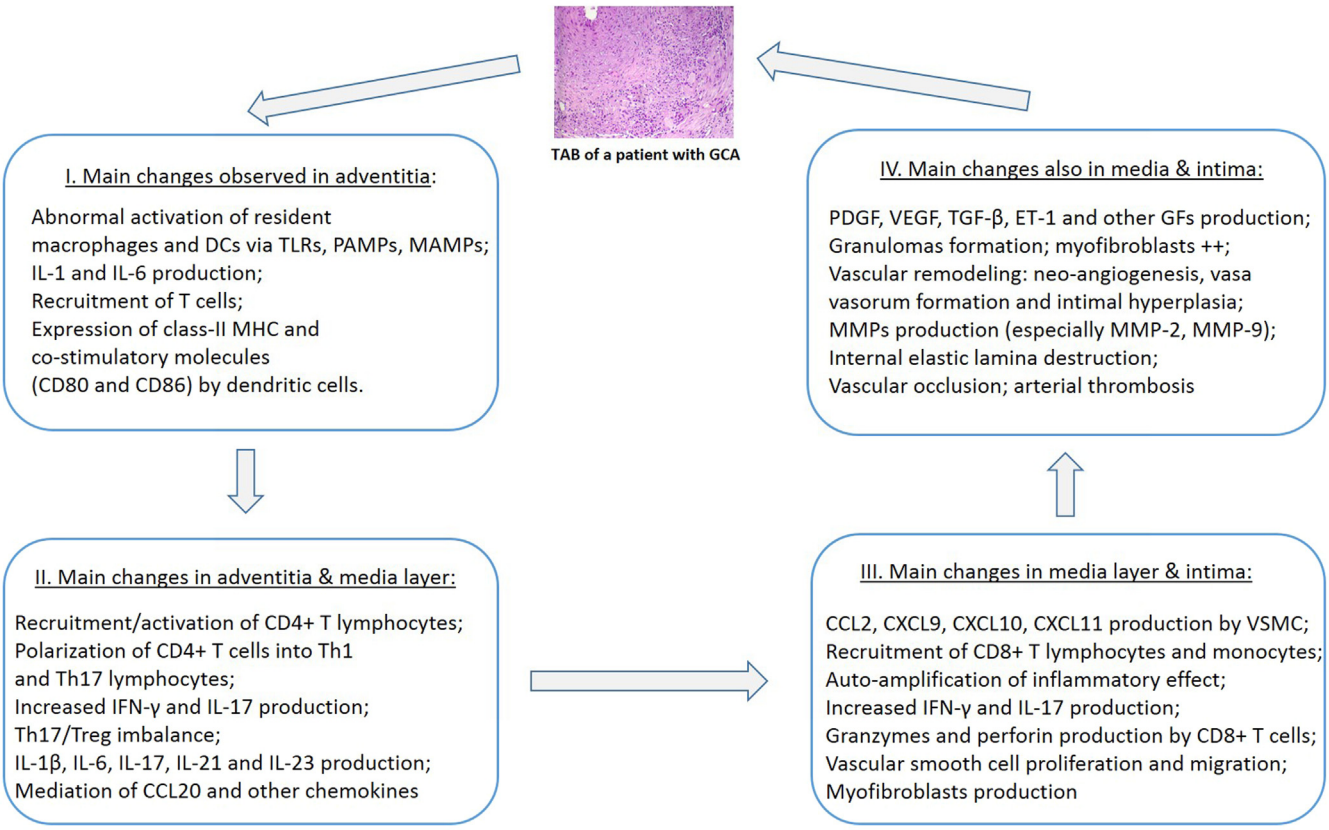

Fig. 1. Immunopathogenesis of giant cell arteritis. Main molecular and cellular lines implicated in the pathogenesis of GCA. *Abbreviations*: CCL: chemokines (CC family); CD: cluster of differentiation; CXCL: chemokines (CXC family); DCs: dendritic cells; ET-1: endothelin 1; GCA: giant cell arteritis; GFs: growth factors; IL: interleukin; IFN-ϒ: interferon gamma; TLRs: toll like receptors; MAMPs: microorganism-associated molecular patterns; MHC: major histocompatibility complex; MMPs: matrix metalloproteinases; PAMPs: pathogen associated molecular patterns; PDGF: platelet-derived growth factor; TAB: temporal artery biopsy; TGF-β: transforming growth factor beta; Th: T helper lymphocytes; Treg: T regulators lymphocytes; VEGF: vascular endothelial growth factor; VSMC: vascular smooth muscle cells.

Once recruited in the arterial wall, CD4 + T cells are activated by DCs and then, they are polarized toward Th1 and Th17 cells, depending on the predominant pro-inflammatory microenvironment (IL-12, IL-18, IL-23, IL-6 and IL-1β cytokine profiles). Th1 cells are generated in the presence of IL-12 and IL-18 and produce IFN-γ, whereas Th17 cells are generated in the presence of IL-6, IL-1β and IL-23 producing IL-17 [42]. The strong infiltration of Th1 and Th17 cells into the arterial wall is responsible for the production of large amounts of IFN-γ and IL-17, respectively. Interestingly, IFN-γ induces the production of several chemokines (CCL2, CXCL9, CXCL10 and CXCL11) by vascular smooth muscle cells (VSMC) [43]. CCL2 leads to the recruitment of monocytes, which express its receptor (CCR2) and then merge to form multinucleated giant cells, the hallmark of GCA [43]. CXCL9, CXCL10 and CXCL11 trigger the recruitment of more immune cells, particularly Th1 and CD8 + T cells, auto-amplifying its inflammatory effect, leading to the production of more IL-17 and IFN-γ, as well as other cytotoxic molecules such as granzymes and perforin [44].

Once recruited in the arterial wall, IFN-γ-stimulated monocytes differentiate into macrophages. Macrophages produce more IL-6, IL-1β and TNF-α, which intensify the local inflammatory response and are responsible for the constitutional syndrome and general signs of GCA. In the media, IFN-γ-activated macrophages produce mediators which are toxic for the arterial tissue. Reactive oxygen species cause lipid peroxidation of phospholipids, nitric oxide (NO) produced by the induced NO-synthase (iNOS) triggers nitration of endothelial proteins, and matrix metalloproteinase-2 (MMP-2) and MMP-9 produced by VSMC and macrophages destroy cellular matrix proteins, causing the destruction of the media and digestion of the internal elastic lamina [45].

Macrophages, giant cells or injured VSMC also produce growth factors and other mediators, essentially platelet-derived growth factor (PDGF) and vascular endothelial growth factor (VEGF), contributing to intimal hyperplasia, vascular occlusion and remodeling. VEGF is responsible for endothelial cell growth, neo-angiogenesis and "*vasa vasorum*" formation [46]. In addition, IL-33, an alarmin belonging to the IL-1 family, is overexpressed in GCA arteries and is probably involved in the pathogenesis of angiogenesis-dependent inflammation in GCA [47]. In addition, PDGF is implicated in the proliferation and migration of VSMC toward the intima, also resulting in intimal hyperplasia. Finally, endothelins may also contribute to the pathogenesis of GCA by promoting inflammation, increasing the sensitivity of the lesion to vasoconstriction, increasing VSMC proliferation and stimulating the migration of VSMC towards the intimal layer, all of them contributing to intimal hyperplasia and vascular occlusion [48,49].

Furthermore, VSMCs accumulate in the media of arteries of patients with GCA acquiring pro-inflammatory properties. Indeed, activated macrophages and VSMCs themselves produce several growth factors (PDGF, TGF-β, endothelin-1, nerve growth factor, brain-derived neurotrophic factor and the neurotrophin co-receptor sortilin), inducing the migration of VSMC into the intima and their differentiation into myofibroblasts, which synthetize matrix proteins. This process finally leads to intimal hyperplasia and vascular occlusion. VSMC also produce MMPs such as MMP-9 and especially MMP-2, which allow them to destroy the media and the internal elastic lamina [50,51]. Fig. 1 shows the main molecular and cellular findings in the pathogenesis of GCA.

Other kinds of immune deregulation in T-cells may also explain the

immune activation observed in GCA. Programmed death-1 (PD-1) expressed by activated T cells and its ligation to PD-L1 or PD-L2, which are expressed by antigen presenting cells, induces T-cell apoptosis, T-cell anergy and the production of IL-10 by T cells or their polarization into Treg lymphocytes. In this line, a defect in the immunoprotective PD-1/PD-L1 immune checkpoint has recently been reported in GCA patients [52]. The implication of immune checkpoints in GCA pathogenesis is also emphasized by the recently proved efficacy of abatacept for the treatment of GCA [53].

3. Treatment of giant cell arteritis

The probability of visual recovery is low when blindness is established [7,54]. Therefore, treatment should not be delayed if GCA is suspected. Glucocorticoids are the cornerstone of the therapy in GCA treatment [55–57].

Conventional immunosuppressive drugs, mainly methotrexate (MTX), can be used as glucocorticoid-sparing agents, thus reducing their adverse effects. However, different studies yielded conflicting results in terms of safety and clinical benefit of conventional immunosuppressive drugs in GCA [57,58]. Low-dose aspirin has been recommended to reduce the risk of associated cardiovascular events [19,59,60]. Open-label studies and clinical trials have shown that biologic agents, in particular the anti-interleukin (IL)-6 receptor, tocilizumab, a humanized monoclonal antibody, may lead to maintained glucocorticoid-independent remissions [61–64]. Table 2 shows the main drugs used for the management of GCA, while Fig. 2 shows the therapeutic escalation in this disease, with the different options currently available.

In the next sections, we have conducted a comprehensive and critical review on the classic management as well as the new therapies used in patients with GCA.

3.1. Glucocorticoids: the drugs of choice

Glucocorticoids are the gold-standard therapy to improve symptoms and reduce the risk of severe ischemic complication in patients with GCA [55]. Unlike patients with isolated PMR, in whom the initial dose of prednisone/prednisolone recommended to achieve rapid improvement of symptoms ranges between 12.5 and 25 mg/day [11,65], high-dose glucocorticoid therapy is needed to improve symptoms and accomplish disease remission in patients with GCA [66]. The initial dose of prednisone/prednisolone in GCA ranges between 40 and 60 mg/day for 3–4 weeks [55,57]. Clinical practice indicates that prednisone doses lower than 20 mg/day given at the time of GCA diagnosis do not prevent the development of visual ischemic complications [67].

Most patients experience improvement of cranial symptoms, such as headache, facial pain, jaw claudication or scalp tenderness, within the first 24 to 72 h after the onset of glucocorticoid therapy. It is also the case for polymyalgia rheumatica features.

We and others recommend using an initial prednisone dose of 40 mg/day in GCA patients without severe ischemic complications [57,68,69]. Experts from the EULAR suggested using an initial dose of prednisolone of 1 mg/kg/day (maximum 60 mg/day) [66]. Most clinicians agree on the use of an initial prednisone/prednisone dose of 60 mg/ day or the initial administration of intravenous methylprednisolone pulse therapy (1 g daily for 3 consecutive days) if patients present with severe ischemic manifestations, in particular if they have visual impairment [8,26]. However, few patients experience visual recovery if they present with visual loss lasting more than 24–48 h [7,70]. Therefore, intensive glucocorticoid therapy must be started as soon the diagnosis of GCA is suspected to reduce the risk of blindness.

Table 2
Main drugs used in the management of giant cell arteritis.

Glucocorticoids (gold standard therapy)
Most commonly prednisone/prednisolone: Initial dose: 40–60 mg/day
Methylprednisolone pulses (in patients with visual ischemic complications)
Methotrexate as glucocorticoid-sparing agent (moderate efficacy)
Anti-IL-6R-tocilizumab (first drug approved to treat giant cell arteritis)
In newly diagnosed patients
In relapsing patients

A study showed a beneficial effect of high-dose intravenous methylprednisolone as induction therapy for GCA [71]. It included 27 patients with GCA confirmed by a positive temporal artery biopsy. Patients were randomized to receive induction therapy with intravenous methylprednisolone (15 mg/kg ideal body weight/day) (n = 14) or intravenous saline for 3 consecutive days (n = 13). All patients started on an initial prednisone dose of 40 mg/day. The median total cumulative oral prednisone dose received by the group of intravenously glucocorticoid-treated patients at week 78 was 5636 mg whereas the median total cumulative oral prednisone dose received by the placebo-treated group at week 78 was 7860 mg. The difference was statistically significant. The subgroup of GCA patients initially treated with intravenous methylprednisolone had faster tapering of oral prednisone and higher rate of patients who achieved sustained remission of the disease after discontinuation of prednisone therapy. Therefore, the authors of the study concluded that induction therapy with high-dose pulse intravenous methylprednisolone may yield long-term benefit allowing a lower total oral prednisone dose. However, there were some limitations in this study. The most important was that the initial high-dose intravenous methylprednisolone received by the 14 patients was not included in the latter calculation. It clearly underestimated the cumulative glucocorticoid dose received by the subgroup of intravenously treated GCA patients. In addition, the small sample size could have affected the final outcomes. Moreover, the mean CRP protein level at baseline was lower in the methylprednisolone-treated group (3.43 mg/dl versus 5.16 mg/dl), and fewer patients in this group had weight loss, fever, or scalp tenderness. Although these clinical and laboratory differences were not statistically significant, they may represent a difference in terms of disease severity [71]. In this regard, data from another study did not support the long-term glucocorticoid -sparing effect of intravenous methylprednisolone in the management of non-complicated patients with GCA. It included 164 patients treated with pulse methylprednisolone at a dosage lower than that used in the former study [72].

In general, acute phase reactants (ESR and CRP) become normal in most patients within 2 to 4 weeks after the onset of the glucocorticoid therapy [55,57,68]. Then, the glucocorticoid dose can be gradually tapered [66]. As previously reported [57], we usually taper 5 mg of prednisone every 2–4 weeks up to 25 mg/day, generally every 2 weeks. Then, we perform prednisone reduction more slowly by 2.5 mg every 2–4 weeks until a prednisone dose of 10 mg/day is reached. Afterwards, we taper prednisone dose by approximately 2.5 mg every 2 months [57,73]. This way of prednisone tapering, which was based on our experience with 287 patients with GCA confirmed by a positive temporal artery biopsy [9], does not correspond with the EULAR recommendations [66]. EULAR experts recommended a faster reduction of the prednisone dose, reaching 10–15 mg/day of prednisone at week 12 if the patients have not suffered relapses of the disease [66]. This recommendation was based on the high number of side effects, such as such as diabetes mellitus, fractures, gastrointestinal bleeding, hypertension, cataracts and infections, reported in some studies on GCA patients undergoing prolonged use of glucocorticoids [74,75].

Close monitorization of GCA patients during the follow-up, searching for relapses of the disease and assessing routine laboratory markers of inflammation, is required [57].

In general, clinicians gradually taper the glucocorticoids in the follow-up if patients have no symptoms of GCA and the acute phase proteins ESR and CRP are normal [73,76]. At the time of tapering prednisone, it is important to keep in mind that alternate day

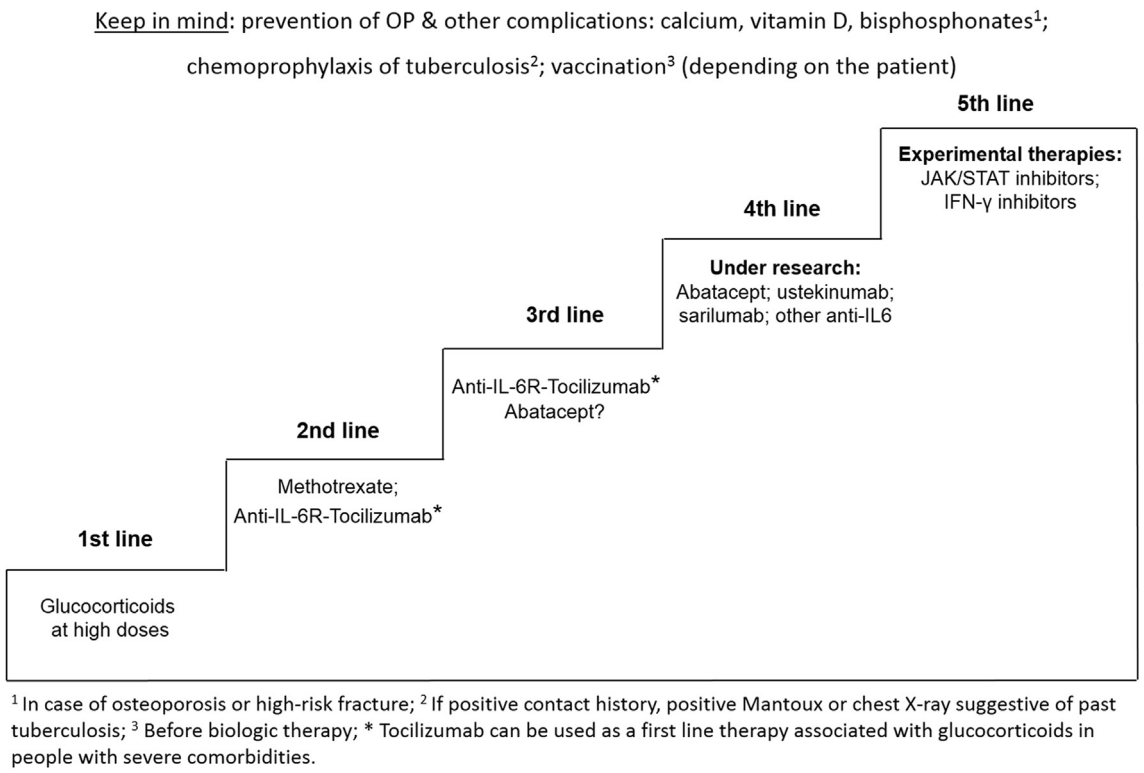

Fig. 2. Stepped therapeutical proposal for the treatment of giant cell arteritis. *Abbreviations*: IFN- ϒ: interferon gamma; IL-6R: interleukin-6 receptor; JAK: Janus kinase; STAT: signal transducers and activators of transcription.

glucocorticoid use should not be performed because it often leads to a relapse of the disease [26,66].

Typical relapses of GCA, in patients who undergo glucocorticoid therapy or who have discontinued the treatment, occur with an important rise of ESR (≥ 40 mm/1st hour) and they are associated with disease-related manifestations such as headache or other cranial manifestations, polymyalgia rheumatica, fever or constitutional symptoms. However, relapses of the disease are often associated with only mild elevation of ESR. Therefore, in practical terms relapses can be considered to be present in patients receiving glucocorticoids or in those who have discontinued this therapy when clear and worsening symptoms occurred with an ESR equal to or greater than 20 mm/1st hour [77]. A population-based study disclosed that 71 (41%) of 174 biopsy-proven GCA patients experienced relapses of the disease. The total duration of glucocorticoid therapy was significantly longer in those patients who had relapses [77]. In keeping with these results, 57 (45.6%) of 125 patients from Olmsted County (Minnesota, USA) diagnosed with GCA between 1950 and 1991 had relapses [75]. One hundred and three (86%) of them suffered adverse events associated with glucocorticoid use. A higher cumulative dose of glucocorticoids was associated with the development of adverse glucocorticoid side effects [75].

3.2. Glucocorticoid-sparing agents

Patients with GCA often have a chronic-relapsing course and may require glucocorticoids for several years. The high frequency of relapses and side effects related to glucocorticoids justify the use of glucocorticoid-sparing agents in some patients with GCA. Another situation that may require the use of glucocorticoid-sparing agents is in glucocorticoid resistant polymyalgia rheumatica patients, in whom a large vessel vasculitis is disclosed by imaging techniques, such as PET/CT scan [17].

A glucocorticoid-sparing agent is considered to be effective if it allows the clinician to shorten the duration of the glucocorticoid therapy and decrease the side effects related to prolonged use of glucocorticoids.

3.2.1. Conventional immunosuppressive drugs

Conventional immunosuppressive drugs have been used in relapsing patients or in those severe glucocorticoid-related side effects [57,66]. MTX is the conventional immunosuppressive drug most commonly used for the management of refractory GCA [66] (Fig. 2). However, the efficacy of this drug in GCA is modest [34]. There are three randomized controlled trials on MTX as adjunctive therapy to glucocorticoids [58–60]. The first included 21 patients with GCA treated with high-dose glucocorticoids along with MTX (n = 12) or placebo (n = 9) [78]. Results were negative since there were not significant differences between the MTX and the placebo groups in the cumulative glucocorticoid dose, number of weeks to achieve glucocorticoid discontinuation, weeks required to taper prednisone to less than 10 mg/day and bone mineral density in lumbar spine or hip at one year [78].

A second trial conducted in a single center included 50 patients with GCA confirmed by a positive temporal artery biopsy. Patients had received a dose equal to or higher than 10 mg/prednisone/day for less than 2 weeks prior to the onset of the study. A single dose of 10 mg/week of oral MTX or placebo was started and maintained throughout the period of study. Discontinuation of MTX and placebo was allowed after 24 months of follow-up if the patient was in clinical remission. In this study, the initial dose of prednisone was 60 mg/day, which was gradually tapered [79]. MTX use was associated with a significant decrease in the frequency of relapses of GCA [79]. This was the first trial showing that treatment with MTX and glucocorticoids is safer and more effective than glucocorticoid therapy alone to reduce the frequency of relapses of GCA.

The third randomized clinical trial on MTX in GCA was a multicenter study that enrolled 98 patients from different centers [80]. The initial dose of prednisone was 1 mg/kg/day (maximum 60 mg/day)

administered along with 0.15 mg/kg/week MTX (increased to 0.25 mg/kg/week, for a maximum weekly dose of 15 mg) or placebo. The median dose of MTX was 15 mg/week. Unlike the former study [79], the use of MTX along with glucocorticoids did not yield benefits in GCA patients [80]. The frequency of treatment failure after 12 months was similar in both groups [80]. No differences between MTX and placebo groups in the cumulative glucocorticoid dose were observed [80].

A *meta*-analysis of these three-randomized placebo-controlled trials yielded a modest role of MTX (10–15 mg/week) to reduce the frequency of relapses and decrease the cumulative prednisone dose [81].

The experience with other conventional immunosuppressive drugs in GCA patients is small and of limited relevance [57]. With respect to this, a double-blind randomized placebo-controlled study in patients with GCA or polymyalgia rheumatica suggested that azathioprine might be useful to reduce glucocorticoid requirement [82]. However, the number of patients included in this study (n = 31) was small to draw strong conclusions. Another study that included 12 patients with polymyalgia rheumatica and 11 with GCA highlighted the potential efficacy of leflunomide as a glucocorticoid-sparing agent [83]. However, the experience with leflunomide in GCA is limited. Other drugs such as cyclosporine A, hydroxychloroquine or dapsone did not show beneficial effects as glucocorticoid-sparing agents in patients with GCA [58]. Yates et al. conducted an elegant study that included a meta-analysis that analyzed the efficacy of different conventional immunosuppressive drugs. They concluded that the efficacy and safety of prednisone/prednisolone alone is in most cases similar to that derived from the use of glucocorticoids with adjunctive immunosuppression in patients with GCA [58].

3.2.2. Biologic agents and other new therapies for GCA

3.2.2.1. Anti-tumor necrosis factor (TNF) agents. Classic studies emphasized the role of proinflammatory cytokines in the pathogenesis of GCA [84,85]. Tumor necrosis factor (TNF)-alpha was found in the temporal artery biopsies of patients with GCA [84–86] and different studies emphasized the efficacy of anti-TNF therapy in patients with inflammatory arthritis. However, anti-TNF therapy was not found to be effective to achieve remission in patients with GCA.

The most relevant study on anti-TNF agents in GCA was a phase 2 study, randomized, double-blind, placebo-controlled trial to assess the efficacy of the chimeric monoclonal antibody-infliximab in newly diagnosed GCA patients [87]. Forty-four patients that achieved resolution of symptoms and normalization of ESR following treatment with 40–60 mg/day of prednisone/prednisolone were recruited in this study. Patients had to be in remission of the disease for at least 1 week before randomization. They received an initial dose of 40–60 mg/prednisone/day and were randomized to receive either placebo (n = 16) or infliximab 5 mg/kg/infusion (n = 28) at baseline (week 0) and at weeks 2, 6, 14, 22, 30, 38 and 46. Infliximab did not yield significant reduction in the cumulative doses of prednisone or in the number of patients free of relapses after 22 weeks of follow-up [87].

Experience with other TNF-antagonists has been scarce and the outcome in terms of efficacy disappointing. With respect to this, a study using the human anti-TNF monoclonal antibody adalimumab administered for 10 weeks did not show efficacy to reach remission with a dose of less than 0.1 mg/kg of prednisone at 6 months. Adalimumab-treated patients had more infections [88]. Information on etanercept a fully soluble, human dimeric fusion protein, which functions as a TNF inhibitor by competitively binding to TNF and preventing its activation of the inflammatory cascade, is also limited to a pilot study that did not confirm efficacy in patients with GCA [89].

3.2.2.2. Interleukin (IL)-6 inhibitors. IL-6 is a pivotal proinflammatory cytokine that promotes the synthesis of acute phase proteins. It also promotes the transition from acute to chronic inflammation. IL-6 is produced in the inflamed arteries of patients with GCA [90]. It is also expressed in the monocytes of these patients [91]. GCA patients have increased IL-6 serum levels [85,92]. IL-6 concentration is closely related to disease activity and the CRP level. Persistence of high serum IL-6 levels suggests the presence of disease activity in glucocorticoid-treated patients with GCA [92]. In this regard, IL-6 serum levels correlate with disease activity better than ESR.

The first data on the relevance of IL-6 in GCA were reported by Dasgupta and Panayi [93]. They showed that the use of glucocorticoids led to a rapid reduction of the levels of IL-6 in patients with GCA [93]. Since the decrease of IL-6 in serum was associated with a reduction in disease activity, the blockade of IL-6 was considered to be a good therapeutic option in GCA [94].

Single cases and small series showed that the anti-IL-6 receptor (anti-IL-6R) tocilizumab was effective in both newly diagnosed and relapsing patients with GCA [95,96]. Tocilizumab is a monoclonal antibody that competitively inhibits the binding of IL-6 to its receptor. The inhibition of the entire receptor complex prevents IL-6 signal transduction to inflammatory mediators that summon B and T cells [97]. This biologic agent has a nonlinear pharmacokinetic profile.

A retrospective, open-label, study that included 22 patients also showed that tocilizumab was useful in GCA patients with refractory and relapsing disease [61]. Patients from this study had previously been treated with high dose prednisone and in most cases (n = 19) with conventional immunosuppressive drugs and/or biologic agents. They were treated with intravenous tocilizumab (8 mg/kg/month) [61]. Nineteen of the 22 patients achieved rapid and maintained clinical response that correlated with a statistically significant reduction of CRP and ESR [61]. Significant reduction in the prednisone dose was obtained [61]. Prednisone was successfully tapered in 20 of the 22 patients. In keeping with these positive findings, another retrospective multicenter study showed beneficial effect of tocilizumab in 28 of 34 patients with GCA [98].

Two placebo-controlled trials fully confirmed that the anti-IL-6R tocilizumab is a useful therapy in patients with GCA [62,63]. The first of them was a phase 2 study in which the assessor judging clinical response was not blinded to the laboratory findings, being allowed to make changes in the treatment during the follow-up based on laboratory alterations [62]. The study included 23 newly diagnosed and 7 with relapsing patients with GCA who were randomized to receive intravenous tocilizumab at a dose of 8 mg/kg every 4 weeks plus prednisolone (n = 20 patients) or placebo infusion every 4 weeks plus prednisolone (n = 10). The primary endpoint was the percentage of patients who achieved complete remission at a prednisolone dose of 0.1 mg/kg/day at week 12. Seventeen of the 20 patients treated with intravenous tocilizumab achieved complete remission whereas it only occurred in 4 of the 10 placebo-treated patients [62]. Rapid glucocorticoid tapering followed by discontinuation after 36 weeks from the onset of therapy was achieved in tocilizumab-treated patients. The cumulative prednisolone dose at 52 weeks was also significantly lower in the tocilizumab group (43 mg/kg) than in the placebo group (110 mg/kg). Relapse-free survival at 52 weeks was significantly higher in the tocilizumab-treated patients (85%) than in those treated with placebo (20%) [62]. Nevertheless, relapses were reported once that tocilizumab was discontinued [62]. Seven (35%) patients from the tocilizumab-treated group and 5 (50%) from the placebo group had serious adverse events [62]. Although this study confirmed the efficacy of tocilizumab to induce remission, prevent relapses, and decrease the cumulative glucocorticoid dose, the use of CRP along with the clinical response as a combined final endpoint could have overestimated the actual number of remissions, because tocilizumab is very effective to decrease the levels of CRP [62].

The use of the anti-IL-6R monoclonal antibody-tocilizumab in GCA was fully supported by data from a randomized, double-blind, placebo-controlled, phase 3 trial, the Giant-Cell Arteritis Actemra (GiACTA) trial [63]. This study was designed to assess if tocilizumab led to higher rates of sustained glucocorticoid-free remission of GCA than placebo through a period of 52 weeks [63]. The GiACTA trial included 251 patients from

14 countries and 76 centers, 61 of them from Europe and 15 from North America. Newly diagnosed (n = 119) and relapsing (n = 132) GCA patients were included in the study if they had histological findings of GCA in the temporal artery biopsy or had imaging techniques showing large-vessel vasculitis and disease activity (cranial symptoms or polymyalgia rheumatica with increased acute-phase reactants). Patients recruited in this trial were included in one of the four groups: a weekly dose of 162 mg of subcutaneous tocilizumab plus a 26-week prednisone taper (n = 100), a dose of 162 mg of subcutaneous tocilizumab given every other week along with a 26-week prednisone taper (n = 50), a third group of weekly placebo-treated patients along with a 26-week prednisone taper (n = 50), and a fourth group of weekly placebo-treated plus a 52-week prednisone taper (n = 51).

Tocilizumab-treated patients experienced sustained remission more commonly than those placebo-treated at 52-week. Whereas 56% of the patients receiving subcutaneous tocilizumab every week and 53% of those treated with subcutaneous tocilizumab every other week achieved remission, only 14% and 18% of the patients treated with placebo plus 26-week prednisone taper or 52-week prednisone taper reached sustained remission [63]. The difference was statistical significance. Also, tocilizumab-treated patients had lower frequency of relapses of the disease (23% and 26% in those treated with tocilizumab every week or every other week) than those included in the 26 and 52-week placebo arms (68% and 49%, respectively). Patients undergoing tocilizumab therapy had longer duration of remission free of relapses than those treated with placebo. Tocilizumab use was associated with a powerful glucocorticoid-sparing effect [63]. This effect was stronger in the patients who had suffered relapses before randomization. Tocilizumab-treated patients had less serious adverse events than those treated with placebo [63].

Due to the positive results obtained in the GiACTA trial, the United States FDA and the European Commission have approved the weekly use of subcutaneous tocilizumab for the management of GCA (Fig. 2). Nevertheless, the GiACTA trial has several limitations [57,64]. With respect to this, half of the patients from this trial had short disease duration as the inclusion in the study for newly diagnosed patients was made within the first six weeks after the disease diagnosis. Another potential point of concern was the definition of remission, which was considered as the absence of relapse (flare) plus normalization of the CRP. Since tocilizumab yields a marked reduction of acute phase reactants, it is difficult to determine whether the effect mediated by this agent leads to a true remission of this vasculitis without having histopathology or imaging exams supporting such an improvement [57,64]. In this regard, we and others have observed persistent FDG uptake in large blood vessels from patients with GCA who are clinically asymptomatic with normal ESR and CRP [99]. Another potential limitation of the GiACTA trial was the scarce information on the effect of tocilizumab on visual loss, due to the small number of patients with unilateral or bilateral blindness at the time of inclusion.

Several open-label studies indicate that tocilizumab may also be useful for the management of refractory patients with other types of large vessel vasculitis. Tocilizumab yielded beneficial effects in patients with isolated aortitis and Takayasús arteritis, who were refractory to glucocorticoids and in many cases to other immunosuppressive agents [100,101].

We have recently conducted an observational, open-label multicenter study that included 134 GCA patients from 40 Spanish referral centers. All of them were treated with tocilizumab due to inefficacy or adverse events of previous therapies [102]. Tocilizumab yielded rapid and maintained clinical and laboratory improvement, regardless of GCA time course (less than 6 months or more than 6 months), administration route (intravenous of subcutaneously) or prednisone dose at the onset of tocilizumab ($\leq$15 mg/day or > 15 mg/day). The results from this large series of real-world patients were in agreement with data from the randomized control trials. According to our results, tocilizumab seems to be an excellent therapeutic option in patients with refractory GCA, regardless of the administration route and GCA duration, helping to minimize the glucocorticoid exposure over time [102]. However, we observed a higher frequency of serious infections than in the GiACTA clinical trial and in patients with rheumatoid arthritis, especially in those GCA patients on higher doses of prednisone during the first three months of tocilizumab treatment [102]. We think that the older age as well as the higher prednisone dose used in our series of GCA patients at the time of tocilizumab onset may explain the increased frequency of serious infections when compared with rheumatoid arthritis [102]. We feel that the age of the patients, the cumulative dose of glucocorticoids and the presence of comorbidities that predispose to infections should be considered before using tocilizumab in the clinical practice [102].

There are other anti-IL-6 monoclonal antibodies, different from tocilizumab, currently under investigation in GCA. A phase-3 randomized, controlled, double-blind study using sirukumab, a fully human anti-IL-6 IgG1 antibody that blocks the IL-6 pathway (ClinicalTrials.gov Identifier: NCT02531633) was initiated but it was cancelled. Also, sarilumab, another anti-IL-6R agent, is under study for its potential use and safety in GCA (ClinicalTrials.gov Identifier: NCT03600805).

3.2.2.3. Cytotoxic T lymphocyte antigen 4-immunoglobulin-Abatacept. Following T cell activation, T cells express a molecule called cytotoxic T lymphocyte antigen 4 (CTLA-4) that competes with CD28 for the binding to CD80 and CD86, playing a role as a T cell co-stimulus inhibitor [103]. Since affinity of the CD80/CD86 receptors is higher for CTLA-4 than for CD28, impairment of T cell activation can be achieved by using a soluble CTLA-4 engineered molecule. In this regard, the recombinantIg-CTLA-4 molecule abatacept, a dimeric fusion protein composed of the crystallizable fragment of a human IgG1 and the extracellular domain of CTLA-4, creates a soluble receptor able to bind with high-affinity CD80/CD86 molecules blocking its interaction with CD28, leading to a decrease of T cell activation [104]. Interestingly, some reports described patients treated with the biologic agent ipilimumab for malignant melanoma that developed GCA [105]. Ipilimumab is a monoclonal antibody directed against the CTLA-4 expressed on the surface of activated T cells [105]. Taken together these findings, it was plausible to think that abatacept might be useful in the management of patients with GCA, Because of that, to determine safety and efficacy of abatacept to maintain remission of GCA, patients with newly-diagnosed or relapsing GCA were treated with 10 mg/kg intravenously of abatacept on days 1, 15, 29, and at week 8, together with prednisone [106]. At week 12, 41 patients who had achieved remission were blindly randomized to receive either monthly placebo intravenous infusions (n = 21) or monthly intravenous abatacept (n = 20). Patients included in both study arms performed a standardized tapering prednisone dose until discontinuation at week 28. Interestingly, the median duration of remission was significantly longer in abatacept-treated patients (9.9 months versus 3.9 months in those who received intravenous placebo). The primary outcome of the study, relapse-free survival at 12 months, was also significantly more common in patients treated with intravenous abatacept (48%) than in those treated with placebo (31%) [106]. There were no differences in side effects between abatacept and placebo-treated groups [106]. However, some investigators have pointed out that due to the nonstandard design, in particular on glucocorticoid management, this study cannot be compared with the standard of care [107]. Moreover, another point that limits our ability to generalize the results of this study is the small number of patients assessed (n = 41). Therefore, further studies encompassing larger number of patients are needed to confirm whether abatacept is useful as adjunctive treatment to reduce relapses or as a glucocorticoid-sparing agent in patients with GCA.

3.2.2.4. Selective target of interleukin-12 (IL-12) and interleukin 23-Ustekinumab. IL-12 and IL-23 are two key cytokines involved in the anomalous Th1 and Th17 response implicated in the pathogenesis of GCA. Ustekinumab is a monoclonal antibody that acts targeting both IL-

12 and IL-23 pathways. It leads to a disruption of the Th1 (IL-12) and Th17 (IL-23) immune responses. The administration of three injections of 45 mg of ustekinumab given at weeks 0, 4 and 16 led to a significant reduction of Th1 and Th17 cells and cytotoxic T lymphocytes at peripheral blood when compared to baseline in patients with refractory GCA [106]. A significant increase of Tregs was also observed [108].

Ustekinumab was given to 14 GCA patients with long disease duration (median 30 months). These patients had been unable to taper glucocorticoids due to active GCA with a minimum of two relapses. In this open-label study, ustekinumab was prescribed at 90 mg subcutaneously at weeks 0, 4 and then every 12 weeks (median 8 months) [109]. Ustekinumab use allowed to reduce the glucocorticoid dose [109]. Also, glucocorticoids were successfully discontinued in 3 patients and in 8 patients ustekinumab allowed the discontinuation of the baseline immunosuppressive agents. Although there were not relapses while the patients were undergoing ustekinumab therapy, relapses were common following ustekinumab discontinuation.

An open label study to test the safety and efficacy of ustekinumab in patients with GCA is underway (estimated study completion date March 2020).

3.2.2.5. Anti-IL-1β agents. Increased of IL-1β mRNA expression was also observed in the temporal arteries of patients with biopsy-proven GCA. Because of that, IL-1β antagonists have been proposed as potential agents to be used in the management of GCA.

A recombinant and slightly modified version of the human IL-1 receptor antagonist protein- anakinra was used at a dose of 100 mg/day in three patients with refractory GCA [110]. Since it yielded favorable results, a phase-3 study is intended to be performed to assess its efficacy in GCA (NCT02902731).

Gevokizumab, a recombinant humanized anti-IL-1β antibody, is also under investigation for the management of GCA (European Clinical Trials Database Identifier 2013–002778–38).

3.2.2.6. Janus kinase (JAK) inhibitors. JAK inhibitors act inhibiting the activity of one or more of the Janus kinase family of enzymes (JAK1, JAK2, JAK3, TYK2). A great number of cytokines that are immune relevant mediators use the Janus kinase/signal transducers and activators of transcription (JAK/STAT) pathway to transduce intracellular signals [111]. Ligand binding of these immune mediators to their cell surface receptors leads to activation of associated JAKs. The activated JAKs increase their kinase activity, recruit, bind and activate STAT. The STAT molecules constitute hetero- or homo-dimers which translocate to the nucleus, inducing transcription and expression of target genes. Polymorphisms of JAK and STAT genes have been associated with autoimmune diseases [111]. STAT-1 signaling regulates the activity of vascular dendritic cells, controlling T cell trafficking and retention of inflammatory T cells in the vascular lesions [112,113]. IFN-γ is the major inducer of STAT-1. In an experimental model in immunodeficient mice, in which animals were engrafted with human medium-sized arteries and then reconstituted with peripheral blood mononuclear cells from patients with biopsy-proven GCA, dexamethasone suppressed the innate immunity with inhibition of dendritic cell activation, IL-6 and IL-1β expression in the vascular lesions. However, dexamethasone spared adaptive immunity and left IFN-γ-producing Th1 unaffected [112]. The JAK/STAT-inhibitor tofacitinib, a kinase inhibitor for JAK1 and JAK3, prevented T cell accumulation in the vessel wall and suppressed IFN-γ production and signaling in a model of vascular inflammation in human arteries engrafted into immunodeficient mice that were reconstituted with T cells and monocytes from patients with GCA [112,113].

Baricitinib is an orally bioavailable inhibitor of JAK1 and JAK2 that inhibits Th17 (IL-6, IL23) and Th1 (IL-12, IFN-γ) pathways. A phase-II open-label pilot study with baricitinib is currently recruiting patients with relapsing GCA (NCT03026504) whose estimated primary completion results will be presented by June 2020.

4. Conclusions

GCA is the most common vasculitis in elderly people from Western countries. It may lead to serious and irreversible complications, including permanent visual loss.

Glucocorticoids represent the cornerstone therapy for GCA. They yield excellent response in most patients if they are given soon before the onset of visual complications. However, relapses are frequent when glucocorticoids are tapered and the prolonged used of glucocorticoids is associated with increased risk of complications, such as diabetes, osteoporosis, hypertension or infection. This has been the reason for the search for alternative therapies that may shorten the duration of glucocorticoids and may help clinicians to taper prednisone, in particular in patients with refractory or relapsing disease.

MTX is the conventional immunosuppressive agent most commonly used in patients with refractory GCA. However, comprehensive reviews indicate that the benefits associated with the use of MTX are modest. Novel biologic therapies that were previously used in rheumatoid arthritis and other autoimmune diseases have also been used in GCA. Unlike anti-TNF-α agents that yielded negative results, the anti-IL-6R-tocilizumab has proved to be effective in newly diagnosed and also in relapsing patients with GCA. Daily clinical practice reports support the claim that tocilizumab is especially useful in patients with refractory disease. The use of this biologic agent leads to reduction of the cumulative glucocorticoid dose and the frequency of relapses of the disease. Because of that, tocilizumab has been approved for the management of GCA. Nevertheless, autopsy results have shown persistent vascular inflammation in patients who were apparently in clinical remission following tocilizumab therapy [114].

Other monoclonal antibodies, such as abatacept and ustekinumab, have shown promising preliminary results that need to be confirmed in clinical trials. The efficacy of JAK/STAT inhibitors in the management of GCA is currently under investigation.

Graphical abstract shows the main clinical features and therapeutic options of both classical (cranial) and extracranial phenotypes of GCA.

Disclosure interest

Prof. MA González-Gay has received consultation fees/participation in company sponsored speakeŕs bureau from Abbvie, MSD, Janssen, Pfizer, Lilly, Roche, Sanofi, Sobi, Novartis and Celgene. S. Castañeda is sponsorized in academic tasks by a “cathedra” promoted by Universidad Autónoma de Madrid (UAM)-ROCHE, Madrid.

References

[1] C. Salvarani, F. Cantini, L. Boiardi, G.G. Hunder, Polymyalgia rheumatica and giant-cell arteritis, N. Engl. J. Med. 347 (2002) 261–271.
[2] M.A. González-Gay, C. García-Porrúa, Epidemiology of the vasculitides, Rheum. Dis. Clin. North Am. 27 (2001) 729–749.
[3] M.A. Gonzalez-Gay, T.R. Vazquez-Rodriguez, M.J. Lopez-Diaz, J.A. Miranda-Filloy, C.C. Gonzalez-Juanatey, J. Martin, et al., Epidemiology of giant cell arteritis and polymyalgia rheumatica, Arthritis Rheum. 61 (2009) 1454–1461.
[4] M.A. Gonzalez-Gay, J.A. Miranda-Filloy, M.J. Lopez-Diaz, R. Perez-Alvarez, C. Gonzalez-Juanatey, A. Sanchez-Andrade, et al., Giant cell arteritis in northwestern Spain: a 25-year epidemiologic study, Medicine (Baltimore) 86 (2007) 61–68.
[5] M.A. Gonzalez-Gay, S. Barros, M.J. Lopez-Diaz, C. Garcia-Porrua, A. Sanchez-Andrade, J. Llorca, Giant cell arteritis: disease patterns of clinical presentation in a series of 240 patients, Medicine (Baltimore) 84 (2005) 269–276.
[6] A. Soriano, F. Muratore, N. Pipitone, L. Boiardi, L. Cimino, C. Salvarani, Visual loss and other cranial ischaemic complications in giant cell arteritis, Nat. Rev. Rheumatol. 13 (2017) 476–484.
[7] M.A. González-Gay, R. Blanco, V. Rodríguez-Valverde, V.M. Martínez-Taboada, M. Delgado-Rodriguez, M. Figueroa, et al., Permanent visual loss and cerebrovascular accidents in giant cell arteritis: predictors and response to treatment, Arthritis Rheum. 41 (1998) 1497–1504.
[8] M.A. González-Gay, C. García-Porrúa, J. Llorca, A.H. Hajeer, F. Brañas, A. Dababneh, et al., Visual manifestations of giant cell arteritis. Trends and clinical

spectrum in 161 patients, Medicine (Baltimore) 79 (2000) 283–892.
[9] M.A. Gonzalez-Gay, T.R. Vazquez-Rodriguez, I. Gomez-Acebo, R. Pego-Reigosa, M.J. Lopez-Diaz, M.C. Vazquez-Triñanes, et al., Strokes at time of disease diagnosis in a series of 287 patients with biopsy-proven giant cell arteritis, Medicine (Baltimore) 88 (2009) 227–235.
[10] M.A. González-Gay, C. García-Porrúa, M. Vázquez-Caruncho, A. Dababneh, A. Hajeer, W.E. Ollier, The spectrum of polymyalgia rheumatica in northwestern Spain: incidence and analysis of variables associated with relapse in a 10 year study, J. Rheumatol. 26 (1999) 1326–1332.
[11] M.A. González-Gay, E.L. Matteson, S. Castañeda, Polymyalgia rheumatica, Lancet 390 (2017) 1700–1712.
[12] M.A. Gonzalez-Gay, Giant cell arteritis and polymyalgia rheumatica: two different but often overlapping conditions, Semin. Arthritis Rheum. 33 (2004) 289–293.
[13] J. Narvaez, P. Estrada, L. López-Vives, M. Ricse, A. Zacarías, S. Heredia, et al., Prevalence of ischemic complications in patients with giant cell arteritis presenting with apparently isolated polymyalgia rheumatica, Semin. Arthritis Rheum. 45 (2015) 328–333.
[14] M.A. González-Gay, C. García-Porrúa, M. Vázquez-Caruncho, Polymyalgia rheumatica in biopsy proven giant cell arteritis does not constitute a different subset but differs from isolated polymyalgia rheumatica, J. Rheumatol. 25 (1998) 1750–1755.
[15] A. Brack, V.M. Martinez-Taboada, A. Stanson, J.J. Goronzy, C.M. Weyand, Disease pattern in cranial and large-vessel giant cell arteritis, Arthritis Rheum. 42 (1999) 311–317.
[16] J. Loricera, R. Blanco, J.L. Hernández, J.M. Carril, I. Martínez-Rodríguez, A. Canga, et al., Non-infectious aortitis: a report of 32 cases from a single tertiary centre in a 4-year period and literature review, Clin. Exp. Rheumatol. 33 (2 Suppl 89) (2015) S-19-31.
[17] D. Prieto-Peña, I. Martínez-Rodríguez, J. Loricera, I. Banzo, M. Calderón-Goercke, V. Calvo-Río, et al., Predictors of positive (18)F-FDG PET/CT-scan for large vessel vasculitis in patients with persistent polymyalgia rheumatica, Semin. Arthritis Rheum. (2018), https://doi.org/10.1016/j.semarthrit.2018.05.007 pii: S0049-0172(18)30215-4 [Epub ahead of print].
[18] B. Dasgupta, F.A. Borg, N. Hassan, L. Alexander, K. Barraclough, B. Bourke, et al., BSR and BHPR guidelines for the management of giant cell arteritis, Rheumatology (Oxford) 49 (2010) 1594–1597.
[19] D.M. Nuenninghoff, G.G. Hunder, T.J. Christianson, R.L. McClelland, E.L. Matteson, Incidence and predictors of large-artery complication (aortic aneurysm, aortic dissection, and/or large-artery stenosis) in patients with giant cell arteritis: a population-based study over 50 years, Arthritis Rheum. 48 (2003) 3522–3531.
[20] M.A. Gonzalez-Gay, C. Garcia-Porrua, A. Piñeiro, R. Pego-Reigosa, J. Llorca, G.G. Hunder, Aortic aneurysm and dissection in patients with biopsy-proven giant cell arteritis from northwestern Spain: a population-based study, Medicine (Baltimore) 83 (2004) 335–341.
[21] M.A. Gonzalez-Gay, M.J. Lopez-Diaz, S. Barros, C. Garcia-Porrua, A. Sanchez-Andrade, J. Paz-Carreira, et al., Giant cell arteritis: laboratory tests at the time of diagnosis in a series of 240 patients, Medicine (Baltimore) 84 (2005) 277–290.
[22] M.A. Gonzalez-Gay, C. Garcia-Porrua, J.C. Amor-Dorado, J. Llorca, Fever in biopsy-proven giant cell arteritis: clinical implications in a defined population, Arthritis Rheum. 51 (2004) 652–655.
[23] M.A. Gonzalez-Gay, C. Garcia-Porrua, J.C. Amor-Dorado, J. Llorca, Giant cell arteritis without clinically evident vascular involvement in a defined population, Arthritis Rheum. 51 (2004) 274–277.
[24] M.A. Gonzalez-Gay, The diagnosis and management of patients with giant cell arteritis, J. Rheumatol. 32 (2005) 1186–1188.
[25] C. Dejaco, S. Ramiro, C. Duftner, F.L. Besson, T.A. Bley, D. Blockmans, et al., EULAR recommendations for the use of imaging in large vessel vasculitis in clinical practice, Ann. Rheum. Dis. 77 (2018) 636–643.
[26] I. Martínez-Rodríguez, M. Jiménez-Alonso, R. Quirce, J. Jiménez-Bonilla, N. Martínez-Amador, M. de Arcocha-Torres, et al., (18)F-FDG PET/CT in the follow-up of large-vessel vasculitis: a study of 37 consecutive patients, Semin. Arthritis Rheum. 47 (2018) 530–537.
[27] C. Dejaco, E. Brouwer, J.C. Mason, F. Buttgereit, E.L. Matteson, B. Dasgupta, Giant cell arteritis and polymyalgia rheumatica: current challenges and opportunities, Nat. Rev. Rheumatol. 13 (2017) 578–592.
[28] M.A. González-Gay, M.M. Amoli, C. Garcia-Porrua, W.E. Ollier, Genetic markers of disease susceptibility and severity in giant cell arteritis and polymyalgia rheumatica, Semin. Arthritis Rheum. 33 (2003) 38–48.
[29] M.M. Amoli, M.A. Gonzalez-Gay, E. Zeggini, F. Salway, C. Garcia-Porrua, W.E. Ollier, Epistatic interactions between HLA-DRB1 and interleukin 4, but not interferon-gamma, increase susceptibility to giant cell arteritis, J. Rheumatol. 31 (2004) 2413–2417.
[30] F.D. Carmona, S.L. Mackie, J.E. Martin, J.C. Taylor, A. Vaglio, S. Eyre, et al., A large-scale genetic analysis reveals a strong contribution of the HLA class II region to giant cell arteritis susceptibility, Am. J. Hum. Genet. 96 (2015) 565–580.
[31] F.D. Carmona, A. Vaglio, S.L. Mackie, J. Hernandez-Rodriguez, P.A. Monach, S. Castañeda, et al., A genome-wide association study identifies risk alleles in plasminogen and P4HA2 associated with giant cell arteritis, Am. J. Hum. Genet. 100 (2017) 64–74.
[32] M.A. Gonzalez-Gay, A.H. Hajeer, A. Dababneh, C. Garcia-Porrua, M.M. Amoli, J. Llorca, W.E. Ollier, Interferon-gamma gene microsatellite polymorphisms in patients with biopsy-proven giant cell arteritis and isolated polymyalgia rheumatica, Clin. Exp. Rheumatol. 22 (6 Suppl 36) (2004) S18–S20.
[33] B. Rueda, M.A. Lopez-Nevot, M.J. Lopez-Diaz, C. Garcia-Porrua, J. Martín, M.A. Gonzalez-Gay, A functional variant of vascular endothelial growth factor is associated with severe ischemic complications in giant cell arteritis, J. Rheumatol. 32 (2005) 1737–1741.
[34] M.M. van Timmeren, P. Heeringa, C.G. Kallenberg, Infectious triggers for vasculitis, Curr. Opin. Rheumatol. 26 (2014) 416–423.
[35] M.A. Nagel, T. White, N. Khmeleva, A. Rempel, P.J. Boyer, J.L. Bennett, et al., Analysis of varicella zoster virus in temporal arteries biopsy positive and negative for giant cell arteritis, JAMA Neurol. 72 (2015) 1281–1287.
[36] A.S. Bhatt, V.E. Manzo, C.S. Pedamallu, F. Duke, D. Cai, D.C. Bienfang, et al., In search of a candidate pathogen for giant cell arteritis: sequencing based characterization of the giant cell arteritis microbiome, Arthritis Rheumatol. 66 (2014) 1939–1944.
[37] S.V. Mohan, Y.J. Liao, J.W. Kim, J.J. Goronzy, C.M. Weyand, Giant cell arteritis: immune and vascular aging as disease risk factors, Arthritis Res. Ther. 13 (2011) 231.
[38] P. Coit, L.B. De Lott, B. Nan, V.M. Elner, A.H. Sawalha, DNA methylation analysis of the temporal artery microenvironment in giant cell arteritis, Ann. Rheum. Dis. 75 (2016) 1196–1202.
[39] M. Samson, M. Corbera-Bellalta, S. Audia, E. Planas-Rigol, L. Martin, M.C. Cid, et al., Recent advances in our understanding of giant cell arteritis pathogenesis, Autoimmun. Rev. 16 (2017) 833–844.
[40] N. Terrades-Garcia, M.C. Cid, Pathogenesis of giant-cell arteritis: how targeted therapies are influencing our understanding of the mechanisms involved, Rheumatology (Oxford) 57 (suppl 2) (2018) ii51–ii62.
[41] A. Brack, A. Geisler, V.M. Martinez-Taboada, B.R. Younge, J.J. Goronzy, C.M. Weyand, Giant cell vasculitis is a T cell-dependent disease, Mol. Med. 3 (1997) 530–543.
[42] M. Samson, D. Lakomy, S. Audia, B. Bonnotte, T(H)17 lymphocytes: induction, phenotype, functions, and implications in human disease and therapy, Rev. Med. Intern. 32 (2011) 292–301.
[43] M. Corbera-Bellalta, E. Planas-Rigol, E. Lozano, N. Terrades-Garcia, M.A. Alba, S. Prieto-Gonzalez, et al., Blocking interferon gamma reduces expression of chemokines CXCL9, CXCL10 and CXCL11 and decreases macrophage infiltration in ex vivo cultured arteries from patients with giant cell arteritis, Ann. Rheum. Dis. 75 (2016) 1177–1186.
[44] M. Samson, K.H. Ly, B. Tournier, N. Janikashvili, M. Trad, M. Ciudad, et al., Involvement and prognosis value of CD8(+) T cells in giant cell arteritis, J. Autoimmun. 72 (2016) 73–83.
[45] K.H. Ly, A. Regent, M.C. Tamby, L. Mouthon, Pathogenesis of giant cell arteritis: more than just an inflammatory condition? Autoimmun. Rev. 9 (2010) 635–645.
[46] M. Kaiser, B. Younge, J. Bjornsson, J.J. Goronzy, C.M. Weyand, Formation of new vasa vasorum in vasculitis. Production of angiogenic cytokines by multinucleated giant cells, Am. J. Pathol. 155 (1999) 765–774.
[47] F. Ciccia, R. Alessandro, A. Rizzo, S. Raimondo, A. Giardina, F. Raiata, et al., IL-33 is overexpressed in the inflamed arteries of patients with giant cell arteritis, Ann. Rheum. Dis. 72 (2013) 258–264.
[48] T. Kida, H. Chuma, T. Murata, H. Yamawaki, S. Matsumoto, M. Hori, et al., Chronic treatment with PDGF-BB and endothelin-1 synergistically induces vascular hyperplasia and loss of contractility in organ-cultured rat tail artery, Atherosclerosis 214 (2011) 288–294.
[49] E. Planas-Rigol, N. Terrades-Garcia, M. Corbera-Bellalta, E. Lozano, M.A. Alba, M. Segarra, et al., Endothelin-1 promotes vascular smooth muscle cell migration across the artery wall: a mechanism contributing to vascular remodelling and intimal hyperplasia in giant-cell arteritis, Ann. Rheum. Dis. 76 (2017) 1624–1634.
[50] Z.S. Galis, J.J. Khatri, Matrix metalloproteinases in vascular remodeling and atherogenesis: the good, the bad, and the ugly, Circ. Res. 90 (2002) 251–262.
[51] K. Piggott, V. Biousse, N.J. Newman, J.J. Goronzy, C.M. Weyand, Vascular damage in giant cell arteritis, Autoimmunity 42 (2009) 596–604.
[52] H. Zhang, R. Watanabe, G.J. Berry, A. Vaglio, Y.J. Liao, K.J. Warrington, et al., Immunoinhibitory checkpoint deficiency in medium and large vessel vasculitis, Proc. Natl. Acad. Sci. U.S.A 114 (2017) E970–E979.
[53] C.A. Langford, D. Cuthbertson, S.R. Ytterberg, N. Khalidi, P.A. Monach, S. Carette, et al., A randomized, double-blind trial of abatacept (CTLA4-IG) for the treatment of giant cell arteritis, Arthritis Rheumatol. 69 (2017) 837–845.
[54] M.A. Gonzalez-Gay, S. Castañeda, J. Llorca, Giant cell arteritis: Visual loss Is our major concern, J. Rheumatol. 43 (2016) 1458–1461.
[55] M.A. González-Gay, T. Pina, Giant cell arteritis and polymyalgia rheumatica: an update, Curr. Rheumatol. Rep. 17 (2015) 64–67.
[56] F. Buttgereit, C. Dejaco, E.L. Matteson, B. Dasgupta, Polymyalgia rheumatica and giant cell arteritis: a systematic review, J. Am. Med. Assoc. 315 (2016) 2442–2458.
[57] M.A. González-Gay, T. Pina, D. Prieto-Peña, M. Calderon-Goercke, R. Blanco, S. Castañeda, Current and emerging diagnosis tools and therapeutics for giant cell arteritis, Expert Rev. Clin. Immunol. 14 (2018) 593–605.
[58] M. Yates, Y.K. Loke, R.A. Watts, A.J. MacGregor, Prednisolone combined with adjunctive immunosuppression is not superior to prednisolone alone in terms of efficacy and safety in giant cell arteritis: meta-analysis, Clin. Rheumatol. 33 (2014) 227–236.
[59] G. Nesher, Y. Berkun, M. Mates, M. Baras, A. Rubinow, M. Sonnenblick, Low-dose aspirin and prevention of cranial ischemic complications in giant cell arteritis, Arthritis Rheum. 50 (2004) 1332–1337.
[60] M.S. Lee, S.D. Smith, A. Galor, G.S. Hoffman, Antiplatelet and anticoagulant therapy in patients with giant cell arteritis, Arthritis Rheum. 54 (2006) 3306–3309.
[61] J. Loricera, R. Blanco, J.L. Hernández, S. Castañeda, M.A. González-Gay, A. Mera, et al., Tocilizumab in giant cell arteritis: multicenter open-label study of 22 patients, Semin Arthritis Rheum. 44 (2015) 717–723.

[62] P.M. Villiger, S. Adler, S. Kuchen, et al., Tocilizumab for induction and maintenance of remission in giant cell arteritis: a phase 2, randomised, double-blind, placebo-controlled trial, Lancet 387 (2016) 1921–1927.

[63] J.H. Stone, K. Tuckwell, S. Dimonaco, M. Klearman, M. Aringer, D. Blockmans, et al., Trial of tocilizumab in giant-cell arteritis, N. Engl. J. Med. 377 (2017) 317–328.

[64] M.A. González-Gay, T. Pina, D. Prieto-Peña, M. Calderon-Goercke, R. Blanco, S. Castañeda, The role of biologics in the treatment of giant cell arteritis, Expert Opin. Biol. Ther. (2018), https://doi.org/10.1080/14712598.2019.1556256 [Epub ahead of print].

[65] M.A. González-Gay, T. Pina, D. Prieto-Peña, M. Calderon-Goercke, R. Blanco, S. Castañeda, Drug therapies for polymyalgia rheumatica: a pharmacotherapeutic update, Expert Opin. Pharmacother. 19 (2018) 1235–1244.

[66] C. Mukhtyar, L. Guillevin, M.C. Cid, B. Dasgupta, K. de Groot, W. Gross, et al., European Vasculitis Study Group. EULAR recommendations for the management of large vessel vasculitis, Ann. Rheum. Dis. 68 (2009) 318–323.

[67] M.A. González-Gay, J. Santiago, R. Monte, R. Blanco, Low-dose corticosteroids and blindness in giant cell arteritis, Br. J. Rheumatol. 35 (1996) 702–703.

[68] M.A. Gonzalez-Gay, C. Martinez-Dubois, M. Agudo, O. Pompei, R. Blanco, J. Llorca, Giant cell arteritis: epidemiology, diagnosis, and management, Curr. Rheumatol. Rep. 12 (2010) 436–442.

[69] M.A. González-Gay, S. Castañeda, Managing of giant cell arteritis and polymyalgia rheumatica, Expert Opin. Orphan. Drugs. 4 (2016) 1133–1144.

[70] S.S. Hayreh, B. Zimmerman, R.H. Kardon, Visual improvement with corticosteroid therapy in giant cell arteritis. Report of a large study and review of literature, Acta Ophthalmol. Scand. 80 (2002) 355–367.

[71] M. Mazlumzadeh, G.G. Hunder, K.A. Easley, K.T. Calamia, E.L. Matteson, W.L. Griffin, et al., Treatment of giant cell arteritis using induction therapy with high-dose glucocorticoids: a double-blind, placebo-controlled, randomized prospective clinical trial, Arthritis Rheum. 54 (2006) 3310–3318.

[72] P. Chevalet, J.H. Barrier, P. Pottier, G. Magadur-Joly, M.A. Pottier, M. Hamidou, et al., A randomized, multicenter, controlled trial using intravenous pulses of methylprednisolone in the initial treatment of simple forms of giant cell arteritis: a one year follow-up study of 164 patients, J. Rheumatol. 27 (2000) 1484–1491.

[73] M.A. Gonzalez-Gay, C. Garcia-Porrua, J.A. Miranda-Filloy, J. Martin, Giant cell arteritis and polymyalgia rheumatica: pathophysiology and management, Drugs Aging 23 (2006) 627–649.

[74] M.A. González-Gay, M.D. Alonso, J.J. Agüero, M. Bal, B. Fernández-Camblor, A. Sánchez-Andrade, Temporal arteritis in a northwestern area of Spain: study of 57 biopsy proven patients, J. Rheumatol. 19 (1992) 277–280.

[75] A. Proven, S.E. Gabriel, C. Orces, W.M. O'Fallon, G.G. Hunder, Glucocorticoid therapy in giant cell arteritis: duration and adverse outcomes, Arthritis Rheum. 49 (2003) 703–708.

[76] S.S. Hayreh, B. Zimmerman, Management of giant cell arteritis. Our 27-year clinical study: new light on old controversies, Ophthalmologica 217 (2003) 239–259.

[77] L. Martinez-Lado, C. Calviño-Díaz, A. Piñeiro, T. Dierssen, T.R. Vazquez-Rodriguez, J.A. Miranda-Filloy, et al., Relapses and recurrences in giant cell arteritis: a population-based study of patients with biopsy-proven disease from northwestern Spain, Medicine (Baltimore) 90 (2011) 186–193.

[78] R.F. Spiera, H.J. Mitnick, M. Kupersmith, M. Richmond, H. Spiera, M.G. Peterson, et al., A prospective, double-blind, randomized, placebo controlled trial of methotrexate in the treatment of giant cell arteritis (GCA), Clin. Exp. Rheumatol. 19 (2001) 495–501.

[79] J.A. Jover, C. Hernandez-Garcia, I.C. Morado, E. Vargas, A. Bañares, B. Fernández-Gutiérrez, Combined treatment of giant-cell arteritis with methotrexate and prednisone. A randomized, double-blind, placebo-controlled trial, Ann. Intern. Med. 134 (2001) 106–114.

[80] G.S. Hoffman, M.C. Cid, D.B. Hellmann, L. Guillevin, J.H. Stone, J. Schousboe, et al., A multicenter, randomized, double-blind, placebo-controlled trial of adjuvant methotrexate treatment for giant cell arteritis, Arthritis Rheum. 46 (2002) 1309–1318.

[81] A.D. Mahr, J.A. Jover, R.F. Spiera, C. Hernandez-García, B. Fernández-Gutiérrez, M.P. Lavalley, et al., Adjunctive methotrexate for treatment of giant cell arteritis: an individual patient data meta-analysis, Arthritis Rheum. 56 (2007) 2789–2797.

[82] M. De Silva, B.L. Hazleman, Azathioprine in giant cell arteritis/polymyalgia rheumatica: a double-blind study, Ann. Rheum. Dis. 45 (1986) 136–138.

[83] A.P. Diamantopoulos, H. Hetland, G. Myklebust, Leflunomide as a corticosteroid-sparing agent in giant cell arteritis and polymyalgia rheumatica: a case series, Biomed. Res. Int. 2013 (2013) 120638.

[84] J. Hernandez-Rodriguez, M. Segarra, C. Vilardell, M. Sanchez, A. Garcia-Martinez, M.J. Esteban, et al., Tissue production of pro-inflammatory cytokines (IL-1beta, TNFalpha and IL-6) correlates with the intensity of the systemic inflammatory response and with corticosteroid requirements in giant-cell arteritis, Rheumatology (Oxford) 43 (2004) 294–301.

[85] C.M. Weyand, K.C. Hicok, G.G. Hunder, J.J. Goronzy, Tissue cytokine patterns in patients with polymyalgia rheumatica and giant cell arteritis, Ann. Intern. Med. 121 (1994) 484–491.

[86] M. Field, A. Cook, G. Gallagher, Immuno-localisation of tumour necrosis factor and its receptors in temporal arteritis, Rheumatol. Int. 17 (1997) 113–118.

[87] G.S. Hoffman, M.C. Cid, K.E. Rendt-Zagar, P.A. Merkel, C.M. Weyand, J.H. Stone, et al., Infliximab for maintenance of glucocorticosteroid-induced remission of giant cell arteritis: a randomized trial, Ann. Intern. Med. 146 (2007) 621–630.

[88] R. Seror, G. Baron, E. Hachulla, M. Debandt, C. Larroche, X. Puéchal, et al., Adalimumab for steroid sparing in patients with giant-cell arteritis: results of a multicentre randomized controlled trial, Ann. Rheum. Dis. 73 (2014) 2074–2081.

[89] V.M. Martínez-Taboada, V. Rodríguez-Valverde, L. Carreño, J. López-Longo, M. Figueroa, J. Belzunegui, et al., A double-blind placebo controlled trial of etanercept in patients with giant cell arteritis and corticosteroid side effects, Ann. Rheum. Dis. 67 (2008) 625–630.

[90] C.M. Weyand, J. Schonberger, U. Oppitz, N.N. Hunder, K.C. Hicok, J.J. Goronzy, Distinct vascular lesions in giant cell arteritis share identical T cell clonotypes, J. Exp. Med. 179 (1994) 951–960.

[91] A.D. Wagner, J.J. Goronzy, C.M. Weyand, Functional profile of tissue-infiltrating and circulating CD68+ cells in giant cell arteritis. Evidence for two components of the disease, J. Clin. Invest. 94 (1994) 1134–1140.

[92] A. Garcia-Martinez, J. Hernandez-Rodriguez, G. Espigol-Frigole, S. Prieto-González, M. Butjosa, M. Segarra, et al., Clinical relevance of persistently elevated circulating cytokines (tumor necrosis factor alpha and interleukin-6) in the long-term followup of patients with giant cell arteritis, Arthritis Care Res. 62 (2010) 835–841.

[93] B. Dasgupta, G.S. Panayi, Interleukin-6 in serum of patients with polymyalgia rheumatica and giant cell arteritis, Br. J. Rheumatol. 29 (1990) 456–458.

[94] S. Unizony, J.H. Stone, J.R. Stone, New treatment strategies in large-vessel vasculitis, Curr. Opin. Rheumatol. 25 (2013) 3–9.

[95] M. Seitz, S. Reichenbach, H.M. Bonel, S. Adler, F. Wermelinger, P.M. Villiger, Rapid induction of remission in large vessel vasculitis by IL-6 blockade. A case series, Swiss Med. Wkly. 141 (2011) 13156.

[96] C. Salvarani, L. Magnani, M. Catanoso, N. Pipitone, A. Versari, L. Dardani, et al., Tocilizumab: a novel therapy for patients with large-vessel vasculitis, Rheumatology (Oxford) 51 (2012) 151–156.

[97] A. Sebba, Tocilizumab: the first interleukin-6-receptor inhibitor, Am. J. Health Syst. Pharm. 65 (2008) 1413–1418.

[98] A. Régent, S. Redeker, A. Deroux, P. Kieffer, K.H. Ly, M. Dougados, et al., Tocilizumab in giant cell arteritis: a multicenter retrospective study of 34 patients, J. Rheumatol. 43 (2016) 1547–1552.

[99] D. Prieto-Peña, J. Loricera, M. Calderón-Goercke, I. Martínez-Rodríguez, J. Banzo, B. Atienza, et al., Giant Cell Arteritis in Treatment with Tocilizumab. Evolution of Vascular FDG Uptake on PET/CT. Abstract Supplement 2018 ACR/ARHP Annual Meeting. Arthritis Rheumatol. 70 (2018) Abstract Number 2748.

[100] J. Loricera, R. Blanco, S. Castañeda, A. Humbría, N. Ortego Centeno, J. Narvaez, et al., Tocilizumab in refractory aortitis: study on 16 patients and literature review, Clin. Exp. Rheumatol. 32 (2014) 79–89.

[101] J. Loricera, R. Blanco, J.L. Hernández, S. Castañeda, A. Humbría, N. Ortego, et al., Tocilizumab in patients with Takayasu arteritis: a retrospective study and literature review, Clin. Exp. Rheumatol. 34 (3 Suppl 97) (2016) S44–S53.

[102] M. Calderón-Goercke, J. Loricera, V. Aldasoro, S. Castañeda, I. Villa, A. Humbría, et al., Tocilizumab in giant cell arteritis. Observational, open-label multicenter study of 134 patients in clinical practice, Semin. Arthritis Rheum. (2019), https://doi.org/10.1016/j.semarthrit.2019.01.003 pii: S0049 0172(18)30571-7 [Epub ahead of print].

[103] L.S. Walker, D.M. Sansom, The emerging role of CTLA4 as a cell-extrinsic regulator of T cell responses, Nat. Rev. Immunol. 11 (12) (2011) 852–863.

[104] L. Moreland, G. Bate, P. Kirkpatrick, Abatacept, Nat. Rev. Drug Discov. 5 (2006) 185–186.

[105] B.L. Goldstein, L. Gedmintas, D.J. Todd, Drug-associated polymyalgia rheumatica/giant cell arteritis occurring in two patients after treatment with ipilimumab, an antagonist of CTLA-4, Arthritis Rheumatol. 66 (2014) 768–769.

[106] C.A. Langford, D. Cuthbertson, S.R. Ytterberg, N. Khalidi, P.A. Monach, S. Carette, et al., A randomized, double blind trial of Abatacept (CTLA-4Ig) for the treatment of Giant Cell Arteritis, Arthritis Rheumatol. 69 (2017) 837–845.

[107] H. De Boysson, A. Aouba, Abatacept as adjunctive therapy for the treatment of giant cell arteritis: comment on the article by Langford et al, Arthritis Rheumatol. 69 (2017) 1504.

[108] M. Samson, T. Ghesquière, S. Berthier, B. Bonnotte, Ustekinumab inhibits Th1 and Th17 polarisation in a patient with giant cell arteritis, Ann. Rheum. Dis. 77 (2018) e6, , https://doi.org/10.1136/annrheumdis-2017-211622.

[109] R. Conway, L. O'Neill, P. Gallagher, G.M. McCarthy, C.C. Murphy, D.J. Veale, et al., Ustekinumab for the treatment of refractory giant cell arteritis, Ann. Rheum. Dis. 75 (2016) 1578–1579.

[110] K.H. Ly, J. Stirnemann, E. Liozon, M. Michel, O. Fain, A.L. Fauchais, Interleukin-1 blockade in refractory giant cell arteritis, Joint Bone Spine 81 (2014) 76–78.

[111] S. Banerjee, A. Biehl, M. Gadina, S. Hasni, D.M. Schwartz, JAK-STAT signaling as a target for inflammatory and autoimmune diseases: current and future prospects, Drugs 77 (2017) 521–546.

[112] B. Hartmann, J. Liao, M.H. Weisman, K.J. Warrington, J.J. Goronzy, C.M. Weyand, The STAT1 Signaling Pathway In Giant Cell Arteritis. Meeting: 2013 ACR/ARHP Annual Meeting. (2013) Abstract Number: 1691.

[113] H. Zhang, R. Watanabe, G.J. Berry, L. Tian, J.J. Goronzy, C.M. Weyand, Inhibition of JAK-STAT signaling suppresses pathogenic immune responses in medium and large vessel vasculitis, Circulation 137 (2018) 1934–1948.

[114] S. Unizony, L. Arias-Urdaneta, E. Miloslavsky, S. Arvikar, A. Khosroshahi, B. Keroack, et al., Tocilizumab for the treatment of large-vessel vasculitis (giant cell arteritis, Takayasu arteritis) and polymyalgia rheumatica, Arthritis Care Res. 64 (2012) 1720–1729.