

https://dspace.org/

# Metopism in adult South Africans and its relationship to frontal sinus size

**F Grine; V Greening; Emily Hernandez; Brendon Billings; V Mngomezulu ...**

SAGE PUBLICATIONS INC
https://hdl.handle.net/10539/42543
WOS

Downloaded from a DSpace repository. https://dspace.org/

Check for updates

Received: 5 September 2023 | Revised: 21 October 2023 | Accepted: 26 October 2023

DOI: 10.1002/ar.25350

RESEARCH ARTICLE

The Anatomical Record WILEY

# Metopism in adult South Africans and its relationship to frontal sinus size

**Frederick E. Grine**[1,2] | **Victoria A. Greening**[1] | **Emily Hernandez**[1] | **Brendon K. Billings**[3] | **Victor Mngomezulu**[4] | **Carrie S. Mongle**[1,5]

[1]Department of Anthropology, Stony Brook University, Stony Brook, New York, USA

[2]Department of Anatomical Sciences, School of Medicine, Stony Brook University, Stony Brook, New York, USA

[3]Human Variation and Identification Research Unit, School of Anatomical Sciences, Faculty of Health Sciences, University of the Witwatersrand, Johannesburg, South Africa

[4]Department of Diagnostic Radiology, Charlotte Maxeke Johannesburg Academic Hospital, Johannesburg, South Africa

[5]Turkana Basin Institute, Stony Brook University, Stony Brook, New York, USA

**Correspondence**
Frederick E. Grine, Department of Anthropology, Stony Brook University, Stony Brook, NY 11794-4364, USA.
Email: frederick.grine@stonybrook.edu

**Abstract**

This study documents the incidences of complete and partial metopism and their possible relationship to frontal sinus volume (FSV) in a sample of modern adult black South Africans with a view to evaluating the hypothesis that metopism affects frontal sinus hypoplasia. FSV was measured from CT scans and the incidence of metopism was recorded from direct observations of dried cadaveric crania. The sex of each individual was known. Four linear cranial dimensions were used to compute a geometric mean by which to scale FSV. The incidence of partial metopism (38%) is comparable to that reported for other population samples, although there is considerable variation among these global sample frequencies. It is significantly more common in male than female South Africans. FSV in individuals with complete metopism is smaller than average but not inordinately so. On the other hand, FSV is significantly larger in individuals with partial metopism than in those that do not present with this sutural remnant. The data on FSV in individuals with and without partial metopism contradict the hypothesis that there is a relationship between partial metopism and frontal sinus hypoplasia. As such, the metopic remnant evinced by the Late Pleistocene cranium from Hofmeyr, South Africa is unlikely to be related to its very small FSV.

**KEYWORDS**

Hofmeyr skull, metopic eminence, metopic suture

## 1 | INTRODUCTION

The human neurocranium is characterized by the presence of prominent fibrous synarthrotic sutures that separate the two parietal bones (sagittal suture), the parietals and occipital (lambdoid), the parietals and the squamous temporal (squamosal), and the parietals and frontal (coronal). These four sutures persist into adulthood and, as a result of mechanotransductional and related molecular mechanisms that affect osteoblastic activity (Beederman et al., 2014; Katsianou et al., 2021), generally begin to undergo fusion in the third decade of life, although there is considerable variation in both sequence and timing (Calandrelli et al., 2021; Ruengdit et al., 2020). A fifth neurocranial suture (interfrontal, or metopic) separates the left and right frontal bones in the fetus and neonate. The metopic suture, unlike the others, is usually fused by the second year of life (Bajwa et al., 2013; Manzanares et al., 1988; Teager et al., 2019), with some studies reporting fusion between 3 and 9 months (Pindrik et al., 2016; Vu et al., 2001; Weinzweig et al., 2003).

 © 2023 American Association for Anatomy. 

Failure of the metopic suture to fuse soon after infancy may result in its persistence into adulthood as a suture that extends from nasion to bregma, a condition that is referred to as metopism. Failure of complete fusion may also result in partial or incomplete metopism; its patency may run anteriorly for some distance from bregma, it may be localized to the middle of the frontal or, most commonly, it extends superiorly for some distance from nasion. Beyond the observation that either complete or partial metopism may possibly be confused radiologically with a frontal bone fracture in living individuals (Bademci et al., 2007; del Sol et al., 1989; Keats, 1996), their presence appear to have no manifest clinical relevance. At the same time, however, a number of studies have argued that full, or complete metopism can affect the presence and/or size of the frontal sinus (e.g., Rochlin & Rubaschewa, 1934; Torgersen, 1950). Thus, Guerram et al. (2014) recorded small frontal sinus size to be more frequently encountered in individuals with metopism, Nikolova and Toneva (2019) described a significant relationship between the presence of a small sinus together with metopism, Atalay and Eser (2021) found metopic individuals to exhibit a 5× higher incidence of sinus hypoplasia, and Kumar et al. (2016) reported a relationship between metopism and sinus aplasia. On the other hand, an almost equal number of studies have observed there to be no relationship whatsoever between metopism and frontal sinus size and/or aplasia (e.g., Bilgin et al., 2013; Hunt & Everest, 2001; Marciniak & Nizankowski, 1959; Pondé et al., 2008; Sandre et al., 2017).

It is rather difficult to reconcile these conflicting results, as there is no consistent methodological difference between the two sets of studies. For example, those that posit a relationship between metopism and sinus size include the use of dried crania and a visual assessment of metopism (e.g., Guerram et al., 2014; Kumar et al., 2016; Nikolova & Toneva, 2019) with frontal sinus size gauged by either flat plane radiographs (Guerram et al., 2014) or CT scanning (Kumar et al., 2016; Nikolova & Toneva, 2019). This group of studies includes those that employed living patients with the assessment of both metopism and sinus size by radiographic means—either through flat plane X-rays (Rochlin & Rubaschewa, 1934; Torgersen, 1950) or via CT scanning (Atalay & Eser, 2021). Similarly, studies that found no relationship between metopism and frontal sinus size include ones that employed dried crania and a visual assessment of metopism (Hunt & Everest, 2001; Pondé et al., 2008; Sandre et al., 2017) with frontal sinus size assessed either by flat plane radiographs (Sandre et al., 2017) or from CT scans (Hunt & Everest, 2001). This group of studies also include those that employed living patients with the identification of metopism and the assessment of sinus size through CT scans (Bilgin et al., 2013), or used dried crania with identification of metopism and the assessment of sinus size through flat plane radiographs (Marciniak & Nizankowski, 1959). In a word, methodological differences do not account for the differences in the results of these two sets of studies.

Despite the claim by Bilgin et al. (2013) that no explanation has been provided for such an association, it is perhaps a reasonable expectation insofar as a suture extending from nasion to bregma will result in a wide separation of the left and right pneumatic spaces. While the presence of the suture itself should theoretically not affect the superior expansion of the sinus, the mechanisms that result in the failure of its closure may also affect sinus development in the frontal bones (Nikolova et al., 2019).

As such, it has also been surmised that remnant (incomplete) metopism may also be related to frontal sinus development (e.g., Balzeau et al., 2022; Butaric et al., 2022). In particular, these authors have suggested that the presence of this sutural remnant may be related to the small frontal sinuses in the Late Pleistocene human skull from Hofmeyr, South Africa (Balzeau et al., 2022; Butaric et al., 2022). In this specimen (Figure 1), the frontal sinus presents as two small, widely separated cavities that are restricted to the medial portion of each supraorbital torus. Together they measure only 2.0 mL in absolute volume (Butaric et al., 2022). The anteroinferior surface of the glabellar prominence of this cranium has a short (ca. 3–4 mm long) remnant of the metopic suture in the midline that extends from about 3 mm above nasion to the anterior face of the of the prominence (Grine, 2022).

Inasmuch as a number of penecontemporaneous (Late Pleistocene–Early Holocene) human crania from North Africa and Europe also possess similarly diminutive frontal sinuses (Butaric et al., 2022), the possibility of such a relationship is worthy of exploration as it may bear on the interpretation of human evolution in the Late Pleistocene and Holocene of Eurasia and Africa. At present, we are unaware of any study that has assessed the relationship between partial metopism and frontal sinus development.

## 1.1 | Purpose of this study

The present study was undertaken to ascertain the incidences of complete and partial metopism in a sample of modern human crania. In addition, the form and length of the sutural remnant in cases of partial metopism are investigated. The relationships between full and partial

19328494, 2024, 6, Downloaded from https://anatomypubs.onlinelibrary.wiley.com/doi/10.1002/ar.25350 by South African Medical Research, Wiley Online Library on [31/07/2024]. See the Terms and Conditions (https://onlinelibrary.wiley.com/terms-and-conditions) on Wiley Online Library for rules of use; OA articles are governed by the applicable Creative Commons License

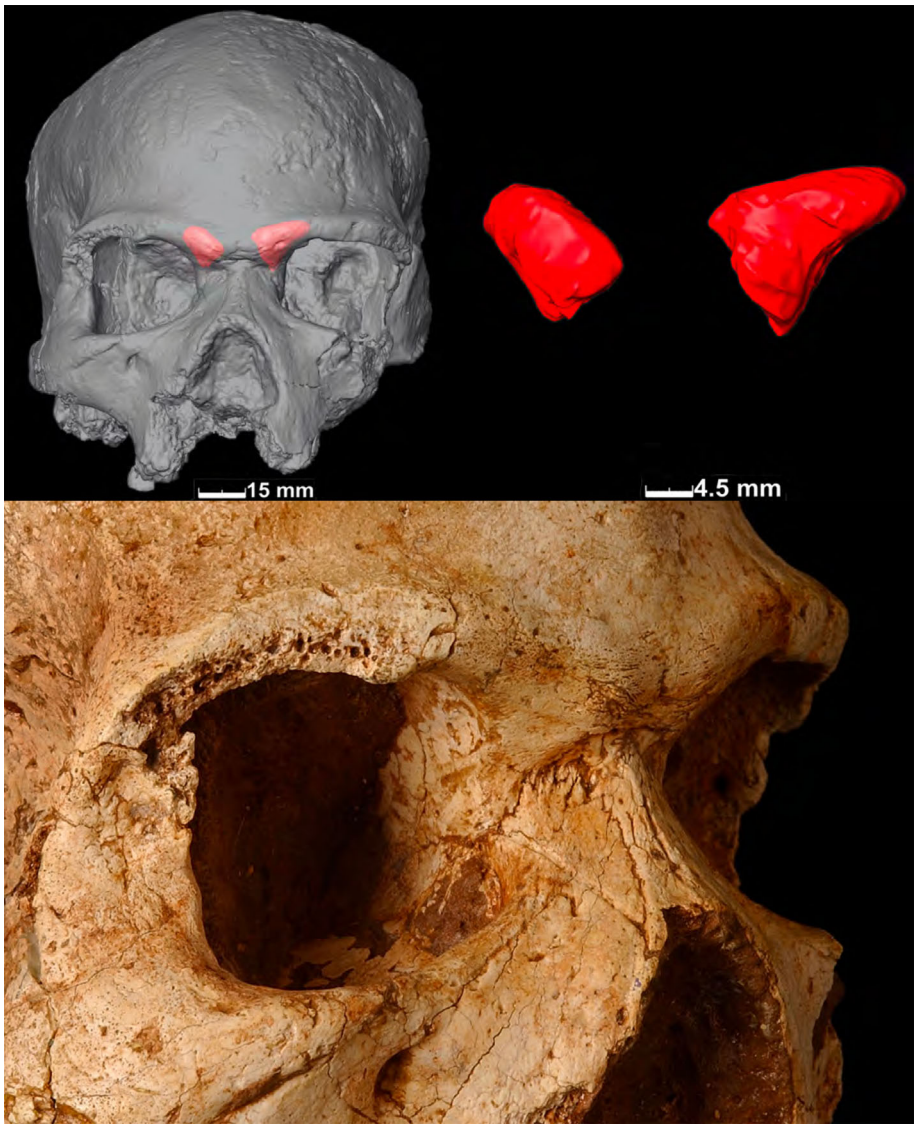


**FIGURE 1** Top: segmentation and isolation of the left and right frontal sinuses of the Hofmeyr cranium. Bottom: inferior remnant of the metopic suture on the anterior and inferior aspects of the glabellar prominence of the Hofmeyr cranium. The vertical extent of the sutural remnant is about 3 mm.

metopism and frontal sinus size in this sample is investigated. Specifically, we test the hypothesis that a remnant of the metopic suture will be associated with hypoplasia of the frontal sinus.

## 2 | MATERIAL

### 2.1 | The South African population sample

The present study is based on a sample of 152 crania from cadaveric skeletons in the Raymond A. Dart Collection, School of Anatomical Sciences, University of the Witwatersrand Medical School, Johannesburg, South Africa. The sex and age are known for every individual comprising this sample, which is roughly evenly divided between male ($n = 82$) and female ($n = 70$) individuals. All crania were from adult individuals (i.e., ≥18 years) and free of any obvious pathology.

This sample is the same as that employed by Greening et al. (In press) in their analysis of frontal sinus volume (FSV). The individuals comprising it are speakers of the "S" group Bantu languages, and closely related genetically (Choudhury et al., 2017; González-Santos et al., 2015; Henn et al., 2011; Schuster et al., 2010).

## 3 | METHODS

In order to determine FSV, each skeleton was CT scanned in a Philips Brilliance 16P in the Department of Diagnostic Radiology, Charlotte Maxeke Johannesburg Academic Hospital, Johannesburg. The cranium was

19328494, 2024, 6, Downloaded from https://anatomypubs.onlinelibrary.wiley.com/doi/10.1002/ar.25350 by South African Medical Research, Wiley Online Library on [31/07/2024]. See the Terms and Conditions (https://onlinelibrary.wiley.com/terms-and-conditions) on Wiley Online Library for rules of use; OA articles are governed by the applicable Creative Commons License

**TABLE 1** Categories describing the form of incomplete metopism employed by different workers.

| Study | 1 | 2 | 3 | 4 | 5 | 6 | 7 | 8 | 9 | 10 | 11 | 12 | 13 | 14 | 15 |
|---|---|---|---|---|---|---|---|---|---|---|---|---|---|---|---|
| Form | | | | | | | | | | | | | | | |
| Linear | x | x | x | x | | x | x | x | x | x | x | x | x | x | x |
| U-shaped | x | | x | x | x | x | | x | x | x | x | x | x | x | x |
| V-shaped | x | x | | x | x | x | x | x | x | x | x | x | | x | x |
| H-shaped | x | | | | | x | | x | | | x | x | x | | |
| Double | | | | | | | x | x | | | | | | | |
| Double U | | x | | | | | | | | | | | | | |
| Double zig-zag | | | x | | | | | | | | | | | | |
| Wide side to side | | | x | | | | | | | | | x | | | |
| Inverted U | | | | | | x | | | | | x | | | | |
| Y-shaped | | | | | | x | | | | | x | | | | x |
| T-shaped | | | x | | | | | | | | | | | | |

*Note*: Studies: 1, Ajmani et al. (1983); 2, Castilho et al. (2006); 3, Mangalgiri et al. (2010); 4, Chandrasekaran and Shastri (2011); 5, Maneenin et al. (2013); 6, Pilli and Sunder (2013); 7, Aksu et al. (2014); 8, Kumar and Rajshekar (2015); 9, Saikia (2014); 10, Santhosh et al. (2014); 11, Vinoth et al. (2014); 12, Burrell et al. (2016); 13, Surekha et al. (2016); 14, Zanaty (2017); 15, Andrade et al. (2019).

positioned in the horizontal plane on a Styrofoam block and scanned coronally from occipital to frontal. Scanner settings employed were 140 kVp, with a tube current of 30 mA. Slice thickness was 0.8 mm with a reconstruction increment of 0.5 mm. Images were reconstructed using the "Sharp" kernel algorithm.

## 3.1 | FSV determination

As described by Greening et al. (In press), the stacked CT scan images of the crania were manually segmented by two of us (VAG and EH) in Avizo 2021.1 to measure the absolute volume of the frontal sinus ($A_{FSV}$). As in that study, the inferior border of the frontal sinus was defined as the horizontal plane coincident with the top of the cribriform plate of the ethmoid as defined by the crista galli. This landmark is anatomically relevant, as it is coincident with the superior margin of the ethmoidal air cells, and it is easily identified on medical grade CT scans. Four linear measurements—(1) maximum cranial length [MCL] between glabella and opisthocranion, (2) maximum cranial breadth [MCB] between the two euyria, (3) frontal chord length [FCL] between glabella and bregma, and (4) minimum frontal breadth [MFB] between the two frontotemporalia—were recorded for each cranium to compute the geometric mean (GM) (Jungers et al., 1995) of cranial size according to the formula:

$$GM = \sqrt[4]{MFB \times MCL \times FCL \times MCB}.$$

The GM was used to scale the absolute FSV ($A_{FSV}$) by dividing the $A_{FSV}$ by the cube root of the GM according to the formula:

$$S_{FSV} = \frac{\sqrt[3]{Volume}}{GM}.$$

All of the crania included in this study presented with some degree of frontal sinus development (i.e., none exhibited bilateral sinus aplasia). Thus, for each cranium we obtained an absolute FSV ($A_{FSV}$) as well as a scaled FSV ($S_{FSV}$). The low rate of bilateral aplasia observed in the present sample is consistent with the findings of Trant and Christensen (2018), who reported a complete sinus agenesis rate of only 4.7% across a survey of 14 published global population samples. In this context, it is noteworthy that identifying the frontal sinus on the basis of the infundibulum that separates it from ethmoidal air cells results in lower aplasia rates than using an arbitrary horizontal line coincident with the supraorbital margins to demarcate the inferior border of the sinus (Butaric et al., 2020). Employing the infundibulum to demarcate the frontal sinus, Butaric et al. (2020) reported a global incidence of bilateral aplasia of some 6.4%, and an African rate of only 2.1%.

## 3.2 | Evaluation of metopism

Because metopism can be difficult to ascertain from CT volumetric renderings, each cranium in the sample was

19328494, 2024, 6, Downloaded from https://anatomypubs.onlinelibrary.wiley.com/doi/10.1002/ar.25350 by South African Medical Research, Wiley Online Library on [31/07/2024]. See the Terms and Conditions (https://onlinelibrary.wiley.com/terms-and-conditions) on Wiley Online Library for rules of use; OA articles are governed by the applicable Creative Commons License

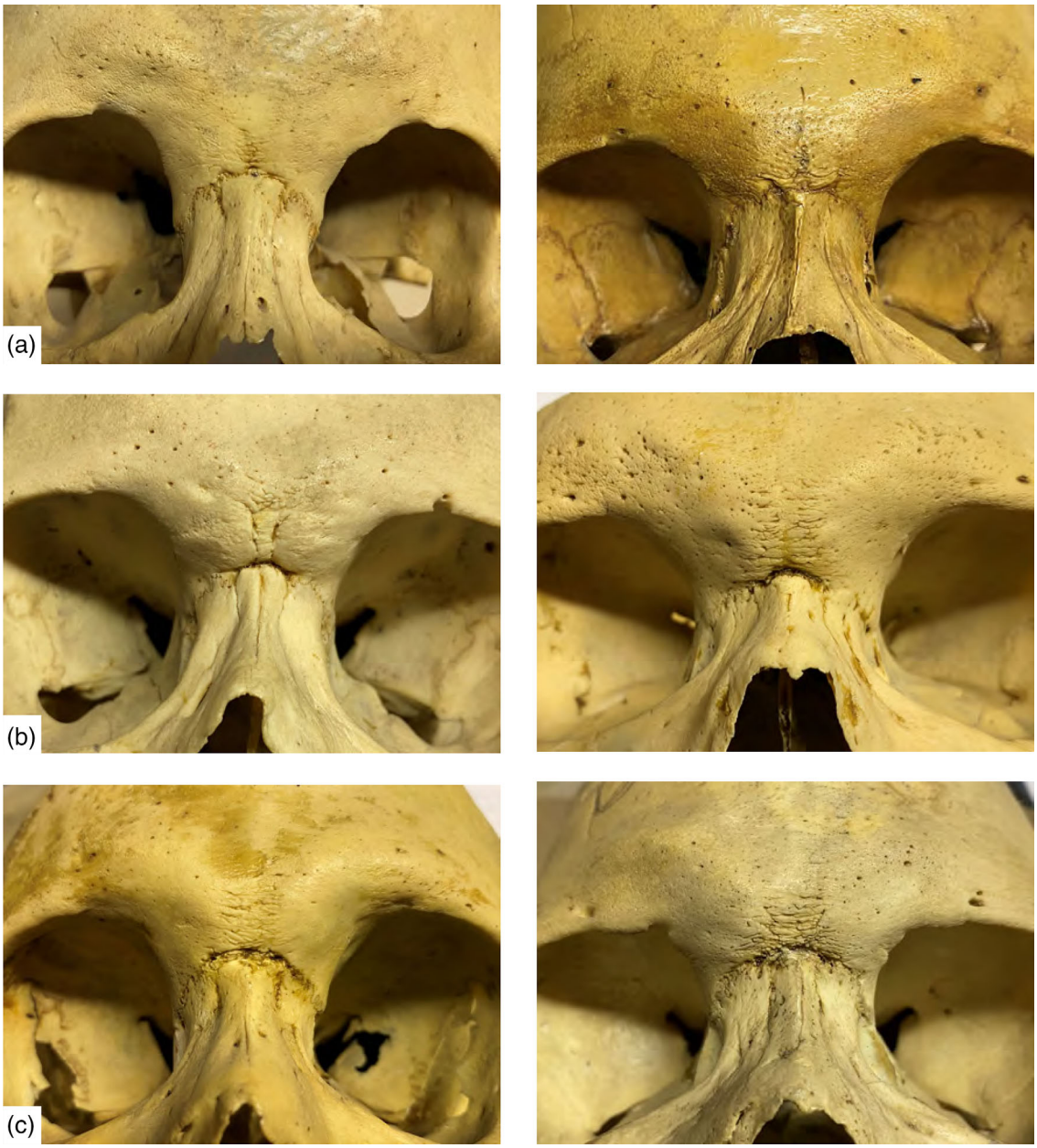


**FIGURE 2** Examples of the three forms of the incomplete metopic suture recognized in this study: (a) linear, (b) double, and (c) diffuse.

visually inspected by one of us (FEG) under strong incident light to determine whether it showed any evidence of a metopic suture. Metopism was recorded as complete, when the suture was patent from nasion to bregma, or incomplete, when the suture extended for some distance from nasion. The length of the incomplete metopic suture was measured by FEG using a dial-equipped vernier caliper and recorded to the nearest tenth of a millimeter.

In no instance was an incomplete metopic suture that extended anteroinferiorly from bregma observed. This is in keeping with the vast majority of studies that have recorded observations on incomplete metopism in recent human crania. Thus, Agarwal et al. (1979) noted that it was situated "almost exclusively" in the lower part of the frontal above nasion and Yadav et al. (2010) reported it to be just above nasion in 95.95% (142/148) of specimens examined by them. In all other studies in which the incomplete suture has been documented, it is clearly located immediately superior to nasion in all cases (Ajmani et al., 1983; Aksu et al., 2014; Andrade et al., 2019; Burrell et al., 2016; Castilho et al., 2006; Chandrasekaran & Shastri, 2011; del Sol et al., 1989; Kumar & Rajshekar, 2015; Maneenin et al., 2013; Mangalgiri et al., 2010; Pilli & Sunder, 2013; Saikia, 2014; Santhosh et al., 2014; Surekha et al., 2016; Vinoth et al., 2014; Zanaty, 2017).

19328494, 2024, 6, Downloaded from https://anatomypubs.onlinelibrary.wiley.com/doi/10.1002/ar.25350 by South African Medical Research, Wiley Online Library on [31/07/2024]. See the Terms and Conditions (https://onlinelibrary.wiley.com/terms-and-conditions) on Wiley Online Library for rules of use; OA articles are governed by the applicable Creative Commons License

A variety of terms have been employed by various workers to describe the configuration of an incomplete metopic suture that extends upwards from nasion (Table 1). Although 11 different forms have been illustrated and employed, the vast majority of studies (ca. 93%) recognize a single linear form, and all recognize some type of "doubled" configuration, variously defined as being U-shaped, V-shaped, Double, or Inverted U-shaped (Table 1). Some 40% of studies recognize a "diffuse" version in which the suture manifests as a variable number of stacked horizontal fissures that may or may not be bounded at their lateral ends by vertical fissures (e.g., H-shaped, Double Zig-Zag, Wide Side to Side). In the present study, the configuration of the incomplete metopic suture was recorded as conforming to one of these three general categories: linear, double, or diffuse (Figure 2). Although there have been numerous studies in which the incidence and form of the incomplete metopic suture has been reported, the study by Pilli and Sunder (2013) represents the only one to have recorded its length.

# 4 | RESULTS

## 4.1 | Incidence of full metopism

A complete metopic suture was encountered in only two crania (both female) in the present sample, representing 2.9% of the female sample and 1.3% of the total (combined sex) sample (Table 2). One of the two crania has a moderate sinus on the right and a slightly smaller sinus on the left; these are separated by relatively thick columns of cortical bone on either side of the suture (Figure 3 left). The other cranium possesses a moderately extensive sinus on the left side, whereas it is virtually aplastic on the right (Figure 3 right).

**TABLE 2** Incidence of complete metopism in the South African sample.

| | Metopic | Absent | Total | % metopic |
|---|---|---|---|---|
| Male | 0 | 82 | 82 | 0.00 |
| Female | 2 | 68 | 70 | 2.86 |
| Combined sex | 2 | 150 | 152 | 1.32 |

## 4.2 | Complete metopic suture and FSV

The absolute ($A_{FSV}$) and scaled ($S_{FSV}$) FSVs for the two female crania that evinced complete metopism are compared with those values for the other individuals who did not present with a complete metopic suture in Table 3. The absolute ($A_{FSV}$) as well as the scaled ($S_{FSV}$) values of the two individuals with complete metopism fall just over 2 SE below the mean of the female sample comprising individuals that lack full metopism. However, neither of these individuals evince values that are among the smallest in this sample. Similarly, the absolute ($A_{FSV}$) and scaled ($S_{FSV}$) values of the two individuals with full metopism fall just over 3 SE below the mean of the combined sex sample of individuals without complete metopism. Here, too, neither of the individuals with full metopism have values that are among the smallest in this sample (Figure 4).

## 4.3 | Incidence of incomplete metopism

The frequencies of incomplete remnants of the metopic suture in the current sample are recorded in Table 4. Interestingly, whereas only females displayed complete metopism, the incomplete suture is evident in a higher proportion of males (i.e., 49% vs. 33%). The difference is statistically significant ($\chi^2 = 8.92$; $p = 0.003$).

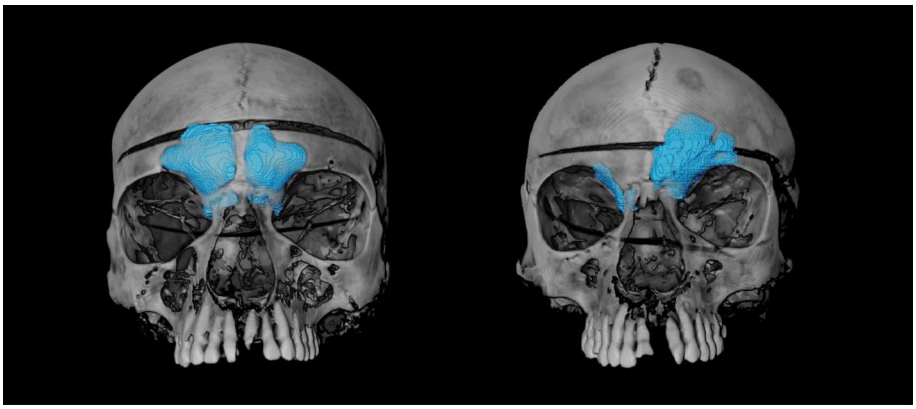

**FIGURE 3** The segmented frontal sinuses (blue) in "ghosted" renderings of the two crania that exhibit full metopism in the current sample. Note the wide separation of the left and right sinus cavities in the cranium on the left and the virtual absence of the right sinus in the cranium on the right. Portions of the metopic sutures are clearly visible.

19328494, 2024, 6, Downloaded from https://anatomypubs.onlinelibrary.wiley.com/doi/10.1002/ar.25350 by South African Medical Research, Wiley Online Library on [31/07/2024]. See the Terms and Conditions (https://onlinelibrary.wiley.com/terms-and-conditions) on Wiley Online Library for rules of use; OA articles are governed by the applicable Creative Commons License

**TABLE 3** Frontal sinus volumes (mL) of South African crania with and without a complete (full) patent metopic suture.

| | *N* | Mean | SD | SE | Obs. range |
|---|---|---|---|---|---|
| Absolute volume ($A_{FSV}$) | | | | | |
| Full metopism | | | | | |
| Females | 2 | 5.71 | – | – | 4.64–6.77 |
| Lacking full metopism | | | | | |
| Females | 68 | 7.73 | 7.79 | 0.94 | 0.67–49.33 |
| Males | 82 | 9.29 | 6.83 | 0.76 | 0.42–34.47 |
| Combined sex | 150 | 8.58 | 7.40 | 0.83 | 0.42–49.33 |
| Scaled volumes ($S_{FSV}$) | | | | | |
| Full metopism | | | | | |
| Females | 2 | 0.15 | – | – | 0.14–0.16 |
| Lacking full metopism | | | | | |
| Females | 68 | 0.14 | 0.04 | 0.01 | 0.08–0.28 |
| Males | 82 | 0.15 | 0.04 | 0.004 | 0.06–0.24 |
| Combined sex | 150 | 0.15 | 0.04 | 0.004 | 0.06–0.28 |

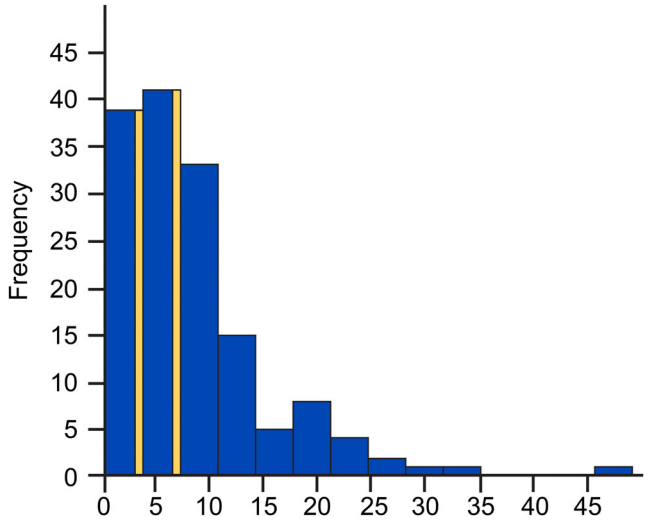


**FIGURE 4** Histogram of absolute frontal sinus volume ($A_{FSV}$) in the combined sex South African sample. The two yellow columns indicate the values of the two crania that exhibit complete metopic sutures. The *X*-axis represents the volumetric measurement in mL.

## 4.4 | Length of the remnant metopic suture

The length of the incomplete remnants of the metopic suture in the current sample is recorded in Table 5. The suture tends to be somewhat longer in males (mean = 8.48 mm) than in females (mean = 7.79 mm), but the difference is not statistically significant ($t = -1.03$; $p = 0.31$).

**TABLE 4** Incidence of crania exhibiting remnants of the metopic suture in the South African sample.

| | Metopic | Absent | Total | % metopic |
|---|---|---|---|---|
| Male | 40 | 42 | 82 | 48.8 |
| Female | 17 | 51 | 68 | 33.3 |
| Combined sex | 57 | 93 | 150 | 38.0 |

**TABLE 5** Length (mm) of the remnant metopic suture in the South African sample.

| | *N* | Mean | SD | SE | Obs. range |
|---|---|---|---|---|---|
| Males | 40 | 8.48 | 2.29 | 0.36 | 4.3–15.1 |
| Females | 17 | 7.79 | 2.30 | 0.56 | 3.5–11.6 |
| Combined sex | 57 | 8.27 | 2.30 | 0.30 | 3.5–15.1 |

**TABLE 6** Incidences of incomplete metopic sutural forms in the South African sample.

| | Males | | Females | | Total | |
|---|---|---|---|---|---|---|
| | *n* | % | *n* | % | *n* | % |
| Linear | 11 | 27.5 | 8 | 47.1 | 19 | 33.3 |
| Double | 15 | 37.5 | 2 | 11.8 | 17 | 29.8 |
| Diffuse | 14 | 35.0 | 7 | 41.2 | 21 | 36.8 |

## 4.5 | Form of the remnant metopic suture

The incidences of the three forms of incomplete metopism recognized here are recorded in Table 6. Nearly half of the

19328494, 2024, 6, Downloaded from https://anatomypubs.onlinelibrary.wiley.com/doi/10.1002/ar.25350 by South African Medical Research, Wiley Online Library on [31/07/2024]. See the Terms and Conditions (https://onlinelibrary.wiley.com/terms-and-conditions) on Wiley Online Library for rules of use; OA articles are governed by the applicable Creative Commons License

**TABLE 7** Frontal sinus volumes (mL) of South African crania with and without an incomplete (remnant) metopic suture.

| | *N* | Mean | SD | SE | Obs. range |
|---|---|---|---|---|---|
| Absolute volume ($A_{FSV}$) | | | | | |
| Partial metopism | | | | | |
| Males | 40 | 11.60 | 7.66 | 1.21 | 1.54–34.47 |
| Females | 17 | 7.42 | 7.08 | 1.71 | 1.05–27.49 |
| Combined sex | 57 | 10.35 | 7.68 | 1.01 | 1.05–34.47 |
| Lacking metopism | | | | | |
| Males | 42 | 7.10 | 5.13 | 0.79 | 0.42–22.92 |
| Females | 51 | 7.83 | 8.07 | 1.13 | 0.67–49.33 |
| Combined sex | 93 | 7.50 | 6.87 | 0.71 | 0.42–49.33 |
| Scaled volumes ($S_{FSV}$) | | | | | |
| Partial metopism | | | | | |
| Males | 40 | 0.17 | 0.04 | 0.006 | 0.09–0.24 |
| Females | 17 | 0.14 | 0.04 | 0.010 | 0.08–0.23 |
| Combined sex | 57 | 0.16 | 0.04 | 0.005 | 0.08–0.24 |
| Lacking metopism | | | | | |
| Males | 42 | 0.14 | 0.04 | 0.006 | 0.06–0.21 |
| Females | 51 | 0.15 | 0.04 | 0.006 | 0.07–0.28 |
| Combined sex | 93 | 0.14 | 0.04 | 0.004 | 0.06–0.28 |

females exhibit a single linear sutural remnant, whereas just over a quarter of the males show this form. In males, the double and diffuse forms occur with nearly equal frequency. In females, the linear and diffuse forms occur with nearly equal frequency. Overall, the three forms are just about equally represented, and the difference in frequencies between males and females is not statistically significant ($\chi^2 = 4.14$; $p = 0.126$).

### 4.6 | Remnant metopic suture and FSV

The absolute ($A_{FSV}$) and scaled ($S_{FSV}$) FSVs for males and females who evinced incomplete metopism are compared with those values for individuals who presented with no evidence of metopism in Table 7.

With reference to the $A_{FSV}$ values, males with a metopic remnant possess significantly larger frontal sinuses than those who do not ($t = 3.14$; $p < 0.003$). On the other hand, females with a metopic remnant tend to possess slightly smaller frontal sinuses than those who do not, but the difference is not significant ($t = -0.18$; $p = 0.85$). In the combined sex sample, the mean $A_{FSV}$ value is significantly higher in the metopic group ($t = 2.36$; $p = 0.024$).

With regard to the $S_{FSV}$ values, males with a metopic remnant again possess significantly larger frontal sinuses than those who do not ($t = 3.48$; $p < 0.001$). In this instance, females with a metopic remnant tend to possess slightly smaller frontal sinuses than those who do not, and here too the difference is not significant ($t = -0.27$; $p = 0.79$). In the combined sex sample, the mean $S_{FSV}$ value is again significantly higher in the metopic group ($t = 2.61$; $p < 0.001$).

## 5 | DISCUSSION

### 5.1 | Incidence of full metopism

The incidence of complete metopism in the combined sex South African sample (1.32%) is compared to the frequencies reported for some 50 other population samples in Table 8 and Figure 5. The South African incidence is among the lowest recorded, although the frequency that has been reported for another sub-Saharan sample (Malawi = 0.12%) is even lower. Six samples exhibit values that are similar to or lower than the South African sample. Reported global sample values range from 0.0% (Myanmarese) to 17.2% (Israeli Bedouin).

### 5.2 | Incidence of incomplete metopism

The frequency of incomplete metopism in the combined sex South African sample (38.0%) is compared to the frequencies reported for other global population samples in

19328494, 2024, 6, Downloaded from https://anatomypubs.onlinelibrary.wiley.com/doi/10.1002/ar.25350 by South African Medical Research, Wiley Online Library on [31/07/2024]. See the Terms and Conditions (https://onlinelibrary.wiley.com/terms-and-conditions) on Wiley Online Library for rules of use; OA articles are governed by the applicable Creative Commons License

**TABLE 8** Percentage incidences of persistent complete and incomplete metopism recorded for combined sex recent human population samples.

| Population | *n* | Complete | Incomplete | Reference |
|---|---|---|---|---|
| Sub-Saharan African | | | | |
| South African black | 152 | 1.32 | 38.00 | This study |
| Nigerian | 206 | 3.40 | 31.57 | Ajmani et al. (1983) |
| Malawian | 839 | 0.12 | 0.00 | Odokuma and Igbigbi (2008) |
| North African | | | | |
| Egyptian | 147 | 8.16 | 34.69 | Zanaty (2017) |
| Middle Eastern | | | | |
| Turkish | 631 | 9.70 | –[a] | Bilgin et al. (2013) |
| Turkish | 1603 | 4.60 | – | Atalay and Eser (2021) |
| Turkish (West Anatolia) | 160 | 7.50 | 67.50 | Aksu et al. (2014) |
| Israeli Bedouin | 145 | 17.20 | 3.40 | Arensburg et al. (1977) |
| Lebanese | 968 | 0.82 | 0.93 | Baaten et al. (2003) |
| European | | | | |
| Bulgarian[b] | 1373 | 6.85 | – | Nikolova et al. (2016) |
| British | 182 | 3.30 | – | Berry (1975) |
| English | 234 | 11.10 | 43.20 | Burrell et al. (2016) |
| Australian | 1034 | 4.8 | – | Chaisrisawadisuk et al. (2021) |
| Norwegian (Oslo) | 1012 | 12.80 | – | Torgersen (1951) |
| Norwegian (East) | 339 | 10.00 | – | Torgersen (1951) |
| Norwegian West | 370 | 11.10 | – | Torgersen (1951) |
| Sami | 648 | 3.20 | – | Torgersen (1951) |
| South Asian | | | | |
| Indian | 367 | 1.63 | 0.54 | Sheshgiri and Shisirkumar (2014) |
| Indian (Assam) NE | 126 | 3.17 | 33.33 | Saikia (2014) |
| Indian (Kanpur) N | 1276 | 2.66 | 38.17 | Agarwal et al. (1979) |
| Indian (Uttar Pradesh) N | 150 | 4.52 | 8.38 | Gupta et al. (2022) |
| Indian (North) N | 1020 | 3.50 | 14.60 | Yadav et al. (2010) |
| Indian (North) N | 100 | 2.59 | – | Verma et al. (2014) |
| Indian (Pradesh) N | 40 | 2.50 | 7.50 | Surekha et al. (2016) |
| Indian (Rajasthan) NW | 130 | 3.08 | – | Masih et al. (2013) |
| Indian (Mumbai) W | 100 | 2.00 | 44.00 | Kumar and Rajshekar (2015) |
| Indian (Karnataka) SW | 125 | 3.20 | 26.40 | Hussain et al. (2010) |
| Indian (Karnataka) SW | 100 | 6.00 | 7.00 | Santhosh et al. (2014) |
| Indian (Karnataka) SW | 100 | 3.00 | – | Pujari et al. (2015) |
| Indian (Karnataka) SW | 70 | 1.43 | 42.86 | Andrade et al. (2019) |
| Indian SE & SW | 80 | 6.25 | 38.75 | Chakravarthi and Venumadhav (2012) |
| Indian (South) | 120 | 3.33 | – | Nallathamby et al. (2013) |
| Indian (South) | 100 | 1.00 | 1.00 | Basha and Sugavasi (2015) |
| Indian (South) | 500 | 2.20 | 21.60 | Nayakanati et al. (2016) |
| Indian (Tamil Nadu) SE | 160 | 5.00 | 40.00 | Chandrasekaran and Shastri (2011) |
| Indian (Andhra Pradesh)SE | 180 | 5.00 | 37.80 | Pilli and Sunder (2013) |
| Indian (North Karnataka) | 140 | 2.14 | – | Kumar and Rajshekar (2015) |

19328494, 2024, 6, Downloaded from https://anatomypubs.onlinelibrary.wiley.com/doi/10.1002/ar.25350 by South African Medical Research, Wiley Online Library on [31/07/2024]. See the Terms and Conditions (https://onlinelibrary.wiley.com/terms-and-conditions) on Wiley Online Library for rules of use; OA articles are governed by the applicable Creative Commons License

TABLE 8 (Continued)

| Population | *n* | Complete | Incomplete | Reference |
|---|---|---|---|---|
| Indian (Central) | 253 | 3.95 | 52.96 | Mangalgiri et al. (2010) |
| Indian (Tamil Nadu) SE | 100 | 2.00 | 88.00 | Vinoth et al. (2014) |
| East Asian | | | | |
| Myanmarese (Burmese) | 51 | 0.00 | – | Berry (1975) |
| Thai | 706 | 2.83 | 4.67 | Khamanarong et al. (2015) |
| Thai | 149 | 1.30 | 6.00 | Pakdeewong and Tohno (2019) |
| Thai (Northeast) | 79 | 10.12 | 10.12 | Maneenin et al. (2013) |
| Chinese | 285 | 9.47 | – | Li et al. (2023) |
| South & Central American | | | | |
| Brazilian | 400 | 2.75 | 28.75 | del Sol et al. (1989) |
| Brazilian (South) | 71 | 7.00 | 32.40 | Castilho et al. (2006) |
| Brazilian | 134 | 4.48 | 5.22 | da Silva et al. (2013) |
| Brazilian | 245 | 6.94 | – | Sandre et al. (2017) |
| Mexican | 62 | 3.22 | – | Berry (1975) |
| Native North American | | | | |
| American (Northwest Coast) | 286 | 2.80 | – | Berry (1975) |

[a]Dashed line (–) denotes that no data were reported for incomplete metopism.
[b]This sample comprised only male crania.

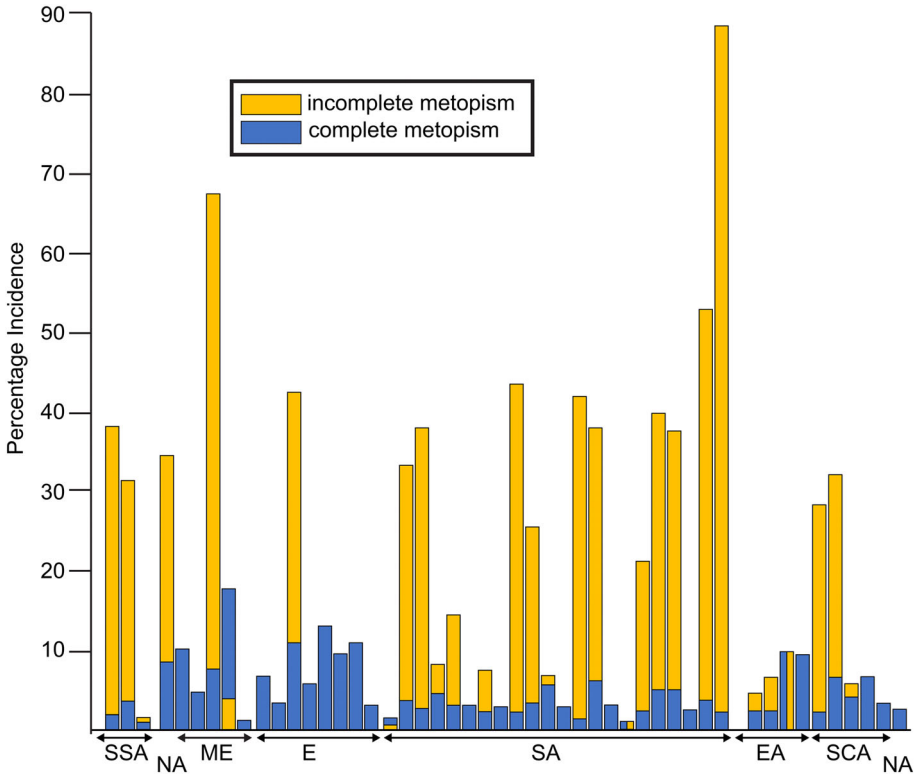


FIGURE 5 Histograms of the frequencies of complete and incomplete metopism recorded for global population samples. SSA = sub-Saharan African; NA = North African; ME = Middle Eastern; E = European; SA = South Asian; EA = East Asian; SCA = South-Central American; NA = Native North American. The first column to the far left is the current South African sample. The sample columns follow the same sequence as listed in Table 8.

Table 8 and Figure 5. This incidence is comparable to that recorded for another sub-Saharan sample (Nigeria = 31.6%) and another 10 samples from around the world. There is considerably more variation among these samples in the incidence of incomplete metopism than in the frequencies of complete metopism (Figure 5). The values reported for two or three population samples are seemingly inordinately high, with the Turkish sample studied by Aksu et al. (2014),

19328494, 2024, 6, Downloaded from https://anatomypubs.onlinelibrary.wiley.com/doi/10.1002/ar.25350 by South African Medical Research, Wiley Online Library on [31/07/2024]. See the Terms and Conditions (https://onlinelibrary.wiley.com/terms-and-conditions) on Wiley Online Library for rules of use; OA articles are governed by the applicable Creative Commons License

**TABLE 9** Length (mm) of remnant metopic sutures in the combined sex South African and the combined sex Indian sample of Pilli and Sunder (2013).

| | *N* | Mean | SD | SE | CV | Obs. range |
|---|---|---|---|---|---|---|
| South African | 57 | 8.27 | 2.30 | 0.30 | 27.8 | 3.5–15.1 |
| Indian | 68 | 11.94 | 5.09 | 0.62 | 42.6 | 5.0–22.0 |

that from Tamil Nadu reported by Vinoth et al. (2014), and the Central Indian sample examined by Mangalgiri et al. (2010) exhibiting incidences of 68%, 88%, and 53%, respectively. While the use of standard flat plane radiographs of living patients or dried crania might be expected to provide somewhat questionable values (but one would expect them to result in comparatively low values!), the three studies in question were conducted by physical examination of dry cadaverically or archeologically derived crania. Nevertheless, the variation in frequencies that have been recorded for numerous independent samples from India (Table 8) suggests that the identification of incomplete metopism differs quite widely among researchers using the same type of material (e.g., dried crania). Thus, for example, incidences of 7.0% and 42.9% have been reported for samples of dry crania from Karnataka State in southwestern India by Santhosh et al. (2014) and Andrade et al. (2019), respectively. Similarly, a complete absence of remnant metopism in a cranial sample from Malawi (Odokuma & Igbigbi, 2008) is quite unexpected given the incidence reported here for South Africa, which is just over some 1800 km distant.

In this context, it is perhaps worthy to consider examining incomplete metopism using micro-CT scans of crania in order to examine not only the exocranial aspect but also the endocranial aspect of the frontal bone. While the suture is barely perceptible in medical grade CT scan images, it should be easily identified in micro-CT images. We suggest that this may be a valuable future undertaking in the investigation of the incidence of metopism and its relationship to the frontal sinus.

The incidence of incomplete metopism in the South African sample is 28.8 times higher than its frequency of complete metopism. This difference is exceeded by only two other samples: the Karnataka Indian sample of Andrade et al. (2019) at 30×, and the Tamil Nadu sample of Vinoth et al. (2014) at 44×. At the same time, however, the incidence of incomplete metopism is lower than that for complete metopism in only three samples reported to date—those for Malawi (Odokuma & Igbigbi, 2008), the Bedouin (Arensburg et al., 1977), and India (Sheshgiri & Shisirkumar, 2014). Excluding the Malawian sample, for which there is a 0% incidence of incomplete metopism, the difference between complete and incomplete incidences averages 8.83× for the other 29 population samples listed in Table 7 (SE = 1.96×, SD = 10.57×, observed range = −5.06 to 44.00×).

## 5.3 | Length of the remnant metopic suture

As noted above, only one other study of which we are aware has recorded the length of the remnant metopic suture. Pilli and Sunder (2013: tables 3–8) recorded the raw data for suture length in five separate tables according to the form of the suture (e.g., linear, V-shaped). The whole sample statistic calculated from these data is compared to that for the South African sample in Table 9. The average length of the suture in the Indian sample is significantly greater ($t = 5.33$; $p < 0.001$), although the incidences of incomplete metopism in these two samples are nearly identical (37.8% vs. 38.0%). There is also considerably greater variation in suture length in the Indian than the South African sample to judge from their CVs, although both are comparatively high (but see Pélabon et al., 2020 for a discussion of the appropriateness of the CV to inform the degree of phenotypic plasticity of quantitative traits).

## 5.4 | Form of the remnant metopic suture

Given the variety of remnant sutural forms that have been recognized by different workers (Table 1), it is difficult to translate some of these categories into the two nonlinear forms (i.e., double and diffuse) employed in the present study. This seems to be especially the case with reference to the forms that have been recognized as being "Y-shaped" and "T-shaped" (Andrade et al., 2019; Mangalgiri et al., 2010; Pilli & Sunder, 2013). Nevertheless, if one assumes that the currently recognized double form includes the categories "U-shaped," "V-shaped," "Double," "Double U-shaped," and "Inverted U," and that the currently recognized diffuse form includes the categories "H-shaped," "Double Zig-Zag," and "Wide Side to Side" it is possible to perhaps gain some kind of idea as to the comparability of the frequencies in the three

19328494, 2024, 6, Downloaded from https://anatomypubs.onlinelibrary.wiley.com/doi/10.1002/ar.25350 by South African Medical Research, Wiley Online Library on [31/07/2024]. See the Terms and Conditions (https://onlinelibrary.wiley.com/terms-and-conditions) on Wiley Online Library for rules of use; OA articles are governed by the applicable Creative Commons License

**TABLE 10** Percentage incidences of the three forms of remnant metopism recorded for different combined sex population samples.

| Population | *n* | Linear | Double | Diffuse | Reference |
|---|---|---|---|---|---|
| South African | 57 | 33.3 | 29.8 | 36.8 | This study |
| Nigerian | 62 | 80.6 | 4.8 | 14.5 | Ajmani et al. (1983) |
| Egyptian | 51 | 70.6 | 29.4 | –[a] | Zanaty (2017) |
| Turkish | 108 | 58.3 | 41.7 | – | Aksu et al. (2014) |
| English | 101 | 10.9 | 28.7 | 60.4 | Burrell et al. (2016) |
| Indian (Assam) | 42 | 50.0 | 50.0 | – | Saikia (2014) |
| Indian (Mumbai) | 22 | 40.9 | 59.1 | – | Kumar and Rajshekar (2015) |
| Indian (Karnataka) | 7 | 71.4 | 28.6 | – | Santhosh et al. (2014) |
| Indian (Karnataka) | 30[b] | 36.7 | 46.7 | – | Andrade et al. (2019) |
| Indian (Tamil Nadu) | 64 | 43.8 | 56.3 | – | Chandrasekaran and Shastri (2011) |
| Indian (Tamil Nadu) | 88[b] | 38.6 | 42.8 | 11.1 | Vinoth et al. (2014) |
| Indian (Andhra Pradesh) | 68[b] | 23.5 | 45.6 | 20.6 | Pilli and Sunder (2013) |
| Indian (Central) | 134[b] | 61.2 | 1.5 | 36.6 | Mangalgiri et al. (2010) |
| Thai | 8 | 0.0 | 100.0 | – | Maneenin et al. (2013) |
| Brazilian | 23 | 69.6 | 30.4 | – | Castilho et al. (2006) |
| Brazilian | 115 | 64.4 | – | – | del Sol et al. (1989) |

Abbreviation: *n*, number of crania with remnant metopism.
[a]Dashed lines indicate that no category under this form was recognized in the study.
[b]Percentages do not equal 100% because of inclusion of other categories, such as T-shaped and Y-shaped.

forms among these different samples. At the very least, the commonly employed "linear" category frequencies should be directly comparable among studies.

The frequencies of the three remnant sutural forms that we have tabulated from the incidences for different categories that have been reported by various studies are compared to the South African sample values in Table 10. There is considerable variation in the frequencies expressed by different population samples but in about half, the linear form is evinced by ≥50% of individuals. Linear remnant sutures have been recorded as being present from 0.0% (Thai) to 80.6% (Nigerian) of individuals. There does not appear to be any relationship between the form assumed by the remnant suture and the geographic origin of the population.

## 5.5 | Relationship between a metopic suture and FSV

As noted above, the absolute ($A_{FSV}$) and scaled ($S_{FSV}$) FSVs for the two female crania that evinced complete metopism are compared with those values for the other individuals who did not present with a complete metopic suture in Table 3. The absolute ($A_{FSV}$) as well as the scaled ($S_{FSV}$) values of the two individuals with complete metopism fall just over 2 SE below the mean of the female sample comprising individuals that lack full metopism. However, neither of these individuals evince FSVs that are among the smallest in this sample.

This observation is consistent with those studies that have argued that complete metopism can affect the presence and/or size of the frontal sinus. As noted above, Guerram et al. (2014), Nikolova and Toneva (2019), and Atalay and Eser (2021) recorded small sinuses to be more frequently encountered in individuals with metopism. Kumar et al. (2016) reported a relationship between metopism and sinus aplasia, although none of the aplastic crania in the South African sample exhibited metopism. At the same time, however, a number of studies have observed no relationship between metopism and frontal sinus size and/or aplasia (e.g., Bilgin et al., 2013; Hunt & Everest, 2001; Marciniak & Nizankowski, 1959; Pondé et al., 2008; Sandre et al., 2017). As such, the results of the current study cannot be considered in any way conclusive.

The absolute ($A_{FSV}$) as well as the scaled ($S_{FSV}$) FSVs of the South African sample of males with a partial metopic remnant are significantly larger than in males who do not exhibit any metopism, whereas in females there is no significant difference between those with and without a metopic remnant. In the combined sex sample, both the $A_{FSV}$ and $S_{FSV}$ values are significantly larger in the metopic group.

19328494, 2024, 6, Downloaded from https://anatomypubs.onlinelibrary.wiley.com/doi/10.1002/ar.25350 by South African Medical Research, Wiley Online Library on [31/07/2024]. See the Terms and Conditions (https://onlinelibrary.wiley.com/terms-and-conditions) on Wiley Online Library for rules of use; OA articles are governed by the applicable Creative Commons License

This result certainly contradicts the notion that there is a relationship between partial metopism and frontal sinus hypoplasia (e.g., Balzeau et al., 2022; Butaric et al., 2022). Indeed, it is difficult to envision the means by which a persistent partial metopic suture could affect frontal sinus size, since the suture fuses in a "zipper-like" fashion, progressing from nasion to bregma (Weinzweig et al., 2003), with initiation of fusion as early as 3 months postnatal and complete fusion attained by 8–9 months in nonsynostotic individuals (Vu et al., 2001; Weinzweig et al., 2003). The frontal sinus, on the other hand, may form in individuals as young as 2 years of age, although it is commonly not visible radiographically until the age of 4–7 when it reaches the level of the orbital roof prior to pneumatizing the squama of the frontal bone (Adibelli et al., 2011; Barghouth et al., 2002; Fatu et al., 2006; Moore & Ross, 2017; Sardi et al., 2018; Yun et al., 2011). The mechanism(s) by which a suture that has all but fused in infancy could influence a sinus that only begins to form considerably later is (are) unclear.

## 5.6 | Metopism and frontal sinus size in the Hofmeyr cranium

As noted in Section 1, it has been surmised that the metopic remnant exhibited by the Late Pleistocene cranium from Hofmeyr, South Africa may be a factor behind its very small frontal sinuses (Balzeau et al., 2022; Butaric et al., 2022). In light of the current evidence, it would appear that the small volume of the frontal sinus in this fossil cannot be simply related to the presence of this sutural remnant. Given the size and robust nature of this fossil, and its possession of a prominent glabella and relatively large and continuous supraorbital tori, the small sizes of its frontal sinuses is quite unexpected. Indeed, as noted by Butaric et al. (2022), the area of the frontal bone that could potentially be pneumatized in the Hofmeyr cranium is very nearly 20 mL. Given that the combined volume of the left and right sinuses is only 2.0 mL, only about 11% of the potential space has been pneumatized in this individual.

In this respect, however it is perhaps noteworthy that Butaric et al. (2022) also drew attention to similarly small frontal sinuses in a number of penecontemporaneous (Late Pleistocene–Early Holocene) crania from North Africa and Europe. Thus, for example, the North African crania from Afalou Bou Rummel that date to between about 15–12 ka (Afalou 2, Afalou 12) and those from Taforalt that date to ca. 18–11 ka (Taforalt XI C1, Taforalt XV C4) have frontal sinuses that measure 3.10 mL, 1.97 mL, 0.70 mL, and 0.43 mL, respectively (Butaric et al., 2022: table 11.4). Similarly, the Upper Paleolithic crania from Cro-Magnon that date to about 28 ka (Cro-Magnon 2, Cro-Magnon 3) and the Abri-Pataud cranium that dates to some 21 ka exhibit small frontal sinuses (1.22 mL, 1.95 mL, and 1.23 mL, respectively). At the same time, other crania from Afalou (Afalou 13, Afalou 28), Taforalt (Taforalt XVII C1), and from the European Upper Paleolithic sites of Peştera Cioclovina and Mladeč (Mladeč 1) have frontal sinus aplasia (Butaric et al., 2022). We are unaware of any study that has documented the incidence of partial metopism in this fossil sample.

However, other crania from some of these sites exhibit notably larger sinuses (e.g., Afalou 30 is 9.45 mL, Afalou 34 is 8.41 mL, Cro-Magnon 1 is 11.55 mL, and Taforalt XV C5 is 9.85 mL). Thus, while small to absent frontal sinuses characterize the majority of these penecontemporaneous North African and European fossils, these conditions are not ubiquitous. Indeed, the sinus volumes of the Afalou 30, Afalou 34, Cro-Magnon 1, and Taforalt XV C5 crania (8.41–11.55 mL) fall comfortably within the ranges exhibited by recent human crania from Europe, sub-Saharan Africa, Asia, and the Americas (see Butaric et al., 2022: table 11.4).

Interestingly, the Hofmeyr cranium exhibits a prominent midline frontal keel (metopic eminence) with a breadth of ca. 13 mm that extends for about 40 mm from glabella (Figure 6). Benington and Pearson (1912), de Villiers (1968), and Grine (2022) have reported incidences of a metopic ridge in crania from Congo, Gabon, and South Africa. Although it is unclear whether the metopic elevation that Benington and Pearson (1912) and de Villiers (1968) observed is equivalent in development to that on the Hofmeyr frontal, the incidences that they reported are rather low (Table 11). The highest incidence of frontal keeling is shown by the Later Stone Age (LSA) South African Khoesan sample, with nearly a third of individuals displaying some degree of elevation. Here, a slight degree of development is the most common expression (26.3%), with only 1% displaying a marked keel that is comparable to that seen in Hofmeyr (Grine, 2022) (Figure 6). By comparison, some 25% of Eurasian Upper Paleolithic (UP) crania that are roughly penecontemporaneous with Hofmeyr display a frontal keel, although only one (Mladeč 6) exhibits a rather marked eminence (Grine, 2022).

It is perhaps noteworthy that early (premature) closure of the metopic suture (metopic craniosynostosis) in young children often results in a prominent midline ridge on the forehead, although neither the Hofmeyr cranium nor any of the South African LSA and Eurasian UP crania with a metopic eminence displays the frontal narrowing with biparietal widening (trigonocephaly) and orbital hypotelorism that constitute the "classic triad" of

19328494, 2024, 6, Downloaded from https://anatomypubs.onlinelibrary.wiley.com/doi/10.1002/ar.25350 by South African Medical Research, Wiley Online Library on [31/07/2024]. See the Terms and Conditions (https://onlinelibrary.wiley.com/terms-and-conditions) on Wiley Online Library for rules of use; OA articles are governed by the applicable Creative Commons License



**FIGURE 6** Midline metopic eminence in the Hofmeyr cranium (left) and its marked expression in a Holocene Later Stone Age cranium from the site of Peers Cave (= Skildergat or Fish Hoek Cave), Western Cape Province, South Africa. Scale bar = 50 mm.

**TABLE 11** Incidence of a metopic eminence in combined sex sub-Saharan African cranial samples.

| | | Presence | | |
|---|---|---|---|---|
| **Sample** | ***n*** | ***n*** | **%** | **Reference** |
| Gabon | 131 | 11 | 8.4 | Benington and Pearson (1912) |
| Congo | 77 | 8 | 10.4 | Benington and Pearson (1912) |
| South Africa | 720 | 51 | 7.1 | de Villiers (1968) |
| South Africa LSA Khoesan | 209 | 64 | 30.6 | Grine (2022) |

Abbreviation: LSA, Later Stone Age.

pathological metopic craniosynostosis (Birgfeld et al., 2013; Chandler et al., 2021; Pindrik et al., 2016; van der Meulen, 2012). While the Hofmeyr, the UP skulls, and the LSA crania that display metopic eminences do not appear to exhibit the clinical manifestations of pathological craniosynostosis, it is reasonable to conclude that all had early closure of the interfrontal suture. As such, there is little reason to suspect that a short remnant of the metopic suture should in any way signify disruption of frontal sinus development. Certainly, it does not in the South African sample investigated here.

## 6 | CONCLUSIONS

This study assessed the incidences of complete and partial metopism in a sample of black South Africans. The form and size of the remnant suture was investigated, together with the relationship between metopism and frontal sinus size. These data were used to test the hypothesis that a remnant of the metopic suture is expected to be associated with frontal sinus hypoplasia.

The incidence of full metopism in the South African sample (1.32%) is among the lowest recorded, although the frequency for another sub-Saharan sample is even lower. The frequency of incomplete metopism (38.0%) is comparable to that recorded for another sub-Saharan sample and is among the higher incidences that have been reported for globally distributed populations. There is considerably more variation in the incidence of incomplete than for complete metopism in these samples. Remnant metopism is nearly 30 times more common than full metopism in the South African sample, and this difference is exceeded by only two out of 29 global samples in which the difference averages about 9×. The incomplete suture in the South African sample is, on average, significantly shorter than in the only other population sample for which this has been recorded, although the incidences of remnant metopism in the two are nearly identical. Remnant sutural form in the South African sample is distributed nearly equally among linear, double, and diffuse categories, whereas the linear form is evinced by ≥50% of individuals in about half of the global population samples.

In the South African male and combined sex samples, both the absolute ($A_{FSV}$) and scaled ($S_{FSV}$) FSVs for individuals with a metopic sutural remnant are significantly larger than in the groups without a metopic remnant. This result contradicts the hypothesis that there is a relationship between partial metopism and frontal sinus hypoplasia. In light of this evidence, it would appear that the small frontal sinuses of the Late Pleistocene cranium from Hofmeyr, South Africa are unlikely to be related to its short metopic sutural remnant. Rather, it seems likely

19328494, 2024, 6, Downloaded from https://anatomypubs.onlinelibrary.wiley.com/doi/10.1002/ar.25350 by South African Medical Research, Wiley Online Library on [31/07/2024]. See the Terms and Conditions (https://onlinelibrary.wiley.com/terms-and-conditions) on Wiley Online Library for rules of use; OA articles are governed by the applicable Creative Commons License

that a small (or absent) frontal sinus was relatively common among other Late Pleistocene and early Holocene crania from North Africa and Europe.

## AUTHOR CONTRIBUTIONS

**Frederick E. Grine:** Conceptualization; writing – original draft; investigation; writing – review and editing; methodology. **Victoria A. Greening:** Investigation; methodology; data curation; writing – original draft; writing – review and editing. **Emily Hernandez:** Investigation; data curation. **Brendon K. Billings:** Writing – review and editing. **Victor Mngomezulu:** Writing – review and editing; investigation. **Carrie S. Mongle:** Conceptualization; investigation; data curation; methodology; writing – original draft; writing – review and editing.

## ACKNOWLEDGMENTS

We thank James Rossie for comments on an early draft of the manuscript and discussions related to paranasal sinuses. We thank Dr. Katharine Thompson for her assistance with the illustrations. We would like to acknowledge the donors for the generous gift of their remains that made this research possible. We thank the editor, Professor Hearther Smith and the two anonymous reviewers for providing us with cogent comments and suggestions that have served to improve this contribution.

## CONFLICT OF INTEREST STATEMENT

The authors declare no conflicts of interest.

## DATA AVAILABILITY STATEMENT

The data that support the findings of this study are available from the corresponding author upon reasonable request. The CT scans can be accessed through a request to the Raymond A. Dart Collection of Modern Human Skeletons, School of Anatomical Sciences, Faculty of Health Sciences, University of the Witwatersrand (brendon.billings@wits.ac.za).

## ORCID

*Frederick E. Grine* https://orcid.org/0000-0002-5310-9005

*Carrie S. Mongle* https://orcid.org/0000-0002-5474-0501

## REFERENCES

Adibelli, Z. H., Songu, M., & Adibelli, H. (2011). Paranasal sinus development in children: A magnetic resonance imaging analysis. *American Journal of Rhinology & Allergy*, *25*, 30–35.

Agarwal, S. K., Malhotra, V. K., & Tewari, S. P. (1979). Incidence of the metopic suture in adult Indian crania. *Acta Anatomica*, *105*, 469–474.

Ajmani, M. L., Mittal, R. K., & Jain, S. P. (1983). Incidence of the metopic suture in adult Nigerian skulls. *Journal of Anatomy*, *137*, 177–183.

Aksu, F., Cirpan, S., Mas, N. G., Karabekir, S., & Magden, A. O. (2014). Anatomic features of metopic suture in adult dry skulls. *The Journal of Craniofacial Surgery*, *25*, 1044–1046.

Andrade, L. S., Gupta, C., & Kalthur, S. G. (2019). Persistent metopic suture in adult cadaveric dry skulls of coastal Karnataka. *Journal of the Punjab Academy of Forensic Medicine and Toxicology*, *19*, 32–35.

Arensburg, B., Goldstein, M. S., & Nathan, H. (1977). Metopism in Bedouin crania from the Negev of Israel. *Zeitschrift für Morphologie und Anthropologie*, *68*, 293–297.

Atalay, B., & Eser, M. B. (2021). The relation between the metopic suture persistence and frontal sinus volume and olfactory fossa depth: A reliability study with semiautomatic volume measurement. *Medeniyet Medical Journal*, *36*, 287–293.

Baaten, P. J. J., Haddad, M., Abi-Nader, K., Abi-Ghosn, A., Al-Kutoubi, A., & Jurjus, A. R. (2003). Incidence of metopism in the Lebanese population. *Clinical Anatomy*, *16*, 148–152.

Bademci, G., Kendi, T., & Agalar, F. (2007). Persistent metopic suture can mimic the skull fractures in the emergency setting? *Neurocirugia*, *18*, 238–240.

Bajwa, M., Srinivasan, D., Nishikawa, H., Rodrigues, D., Solanki, G., & White, N. (2013). Normal fusion of the metopic suture. *The Journal of Craniofacial Surgery*, *24*, 1201–1205.

Balzeau, A., Albessard-Ball, L., Kubicka, A. M., Beaudet, A., Santos, E., Bienvenu, T., Arsuaga, J. L., Asfaw, B., Berger, L., Bermúdez de Castro, J. M., Carlson, K., Clarke, R. J., Daura, J., Filippo, A., Gorgoulis, V. G., Grine, F. E., Harvati, K., Hawks, J., Herries, A., … Buck, L. (2022). Frontal sinuses and human evolution. *Science Advances*, *8*, eabp9767. https://doi.org/10.1126/sciadv.abp9767

Barghouth, G., Prior, J. O., Lepori, D., Duvoisin, B., Schnyder, P., & Gudinchet, F. (2002). Paranasal sinuses in children: Size evaluation of maxillary, sphenoid, and frontal sinuses by magnetic resonance imaging and proposal of volume index percentile curves. *European Radiology*, *12*, 1451–1458.

Basha, M. P. A., & Sugavasi, R. (2015). Study of metopic suture in South Indian skulls. *International Journal of Research in Medical Sciences*, *3*, 2237–2239.

Beederman, M., Farina, E. M., & Reid, R. R. (2014). Molecular basis of cranial suture biology and disease: Osteoblastic and osteoclastic perspectives. *Genes & Diseases*, *1*, 120–125.

Benington, C. R., & Pearson, K. (1912). A study of the negro skull with special reference to The Congo and Gaboon crania. *Biometrika*, *81*, 292–339.

Berry, A. C. (1975). Factors affecting the incidence of non-metrical skeletal variants. *Journal of Anatomy*, *120*, 519–535.

Bilgin, S., Kantarcı, U. H., Duymus, M., Yildirim, C. H., Ercakmak, B., Orman, G., Gunenc Beser, C., Kaya, M., Gok, M., & Akbasak, A. (2013). Association between frontal sinus development and persistent metopic suture. *Folia Morphologica*, *72*, 306–310.

Birgfeld, C. B., Saltzman, B. S., Hing, A. V., Heike, C. L., Khanna, P. C., Gruss, J. S., & Hopper, R. A. (2013). Making the diagnosis: Metopic ridge versus metopic craniosynostosis. *The Journal of Craniofacial Surgery*, *24*, 78–185.

19328494, 2024, 6, Downloaded from https://anatomypubs.onlinelibrary.wiley.com/doi/10.1002/ar.25350 by South African Medical Research, Wiley Online Library on [31/07/2024]. See the Terms and Conditions (https://onlinelibrary.wiley.com/terms-and-conditions) on Wiley Online Library for rules of use; OA articles are governed by the applicable Creative Commons License

Burrell, C. L., Emery, M. M., Gonzalez, S., & Irish, J. D. (2016). Incidence and variance of the metopic suture. *Proceedings of the 18th Annual Conference British Association of Biological Anthropology and Osteoarchaeology*, 66–67.

Butaric, L., Buck, L., Balzeau, A., du Plessis, A., & Grine, F. E. (2022). The paranasal sinuses of the Hofmeyr cranium. In F. E. Grine (Ed.), *Hofmeyr: A late Pleistocene human skull from South Africa* (pp. 179–211). Springer.

Butaric, L. N., Jones, G. C., & Garvin, H. M. (2020). Revisiting global patterns of frontal sinus aplasia utilizing computed tomography. *Forensic Science International*, *315*, 110458.

Calandrelli, R., Pilato, F., D'Apolito, G., Panfili, M., & Colosimo, C. (2021). Normal growth of the sutures of the skull. In M. Turgut, R. S. Tubbs, A. T. Turgut, & A. S. Dumonts (Eds.), *The sutures of the skull* (pp. 77–96). Springer.

Castilho, M. A. S., Oda, J. Y., & Sant'Ana, D. M. G. (2006). Metopism in adult skulls from southern Brazil. *International Journal of Morphology*, *24*, 61–66.

Chaisrisawadisuk, S., Constantine, S., Lottering, N., Moore, M. H., & Anderson, P. J. (2021). Incidence of persistent metopic suture in Australia: Findings from 1034 three-dimensional computed tomography scans. *Child's Nervous System*, *37*, 3871–3879.

Chakravarthi, K. K., & Venumadhav, N. (2012). Morphological study of metopic suture in adult South Indian skulls. *International Journal of Medical and Health Sciences*, *1*, 23–28.

Chandler, L., Park, K. E., Allam, O., Mozaffari, M. A., Khetpal, S., Smetona, J., Pourtaheri, N., Lu, X., Persing, J. A., & Alperovich, M. (2021). Distinguishing craniomorphometric characteristics and severity in metopic synostosis patients. *International Journal of Oral and Maxillofacial Surgery*, *50*, 1040–1046.

Chandrasekaran, S., & Shastri, D. (2011). A study on metopic suture in adult South Indian skulls. *International Journal of Basic Medical Science*, *1*, 379–382.

Choudhury, A., Ramsay, M., Hazelhurst, S., Bardien, S., Botha, G., Chiusa, E. R., Christoffels, A., Gamieldien, J., Sefid-Dashti, M. J., Joubert, F., Meintjes, A., Mulder, N., Ramesar, R., Rees, J., Scholtz, K., Sengupta, D., Soodyall, H., Venter, P., Warnich, L., & Pepper, M. S. (2017). Whole-genome sequencing for an enhanced understanding of genetic variation among South Africans. *Nature Communications*, *8*, 2062.

da Silva, I., Fernandes, K., Ramalho, A., Bispo, R., Rodrigues, C., & Aragao, J. (2013). Occurrence of metopism in dry crania of adult Brazilians. *ISRN Anatomy*, *2013*, 158341.

de Villiers, H. (1968). *The skull of the south African negro*. University of the Witwatersrand Press.

del Sol, M., Binvignat, O., Bolini, P. D., & Prates, J. C. (1989). Metopism in Brazilians. *Revista Paulista de Medicina*, *107*, 105–107.

Fatu, C., Puisoru, M., Rotaru, M., & Truta, A. M. (2006). Morphometric evaluation of the frontal sinus in relation to age. *Annals of Anatomy – Anatomischer Anzeiger*, *188*, 275–280.

González-Santos, M., Montinaro, F., Oosthuizen, O., Oosthuizen, E., Busby, G. B. J., Anagnostou, P., Destro-Bisol, G., Pascali, V., & Capelli, C. (2015). Genome-wide SNP analysis of southern African populations provides new insights into the dispersal of Bantu-speaking groups. *Genome Biology and Evolution*, *7*, 2560–2568.

Greening, V. A., Hernandez, E., Mongle, C. S., Billings, B. S., Mngomezulu, V., Wallace, I. J., & Grine, F. E. (In press). Frontal sinus volume variation in a sample of black South Africans. *American Journal of Biological Anthropology*.

Grine, F. E. (2022). Description and comparative morphology of the Hofmeyr skull. In F. E. Grine (Ed.), *Hofmeyr. A late Pleistocene human skull from South Africa* (pp. 71–118). Springer.

Guerram, A., Le Minor, J., Renger, S., & Bierry, G. (2014). The size of the human frontal sinuses in adults presenting complete persistence of the metopic suture. *American Journal of Physical Anthropology*, *154*, 621–627.

Gupta, N., Singh, D., Malik, A., Arshad, M., Kumar, V., Beg, M. R. U., & Singh, S. P. (2022). Incidence of metopic suture in adult human crania in Uttar Pradesh. *Acta Medica International*, *9*, 137–140.

Henn, B. M., Gignoux, C. R., Jobin, M., Granka, J. M., Macpherson, J. M., Kidd, J. M., Rodriguez-Botigue, L., Ramachandran, S., Hon, L., Brisbin, A., Lin, A. A., Underhill, P. A., Comas, D., Kidd, K. K., Norman, P. J., Parham, P., Bustamante, C. D., Mountain, J. L., & Feldman, M. W. (2011). Hunter-gatherer genomic diversity suggests a southern African origin for modern humans. *Proceedings of the National Academy of Sciences of the United States of America*, *13*, 5154–5162.

Hunt, D. R., & Everest, K. (2001). Frontal sinus size: Sex, population and metopism affinities. *American Journal of Physical Anthropology*, *114*, 82–83.

Hussain, S. S., Mavishetter, G. F., Thomas, S. T., & Prasanna, L. C. (2010). Incidence of metopic suture in adult South Indian skulls. *Journal of Biomedical Science and Research*, *2*, 223–226.

Jungers, W. L., Falsetti, A. B., & Wall, C. E. (1995). Shape, relative size, and size-adjustments in Morphometrics. *Yearbook of Physical Anthropology*, *38*, 137–161.

Katsianou, M., Papavassiliou, K. A., Zoi, I., Gargalionis, A. N., Panagopoulos, D., Themistocleous, M. S., Piperi, C., Papavassiliou, A. G., & Basdra, E. K. (2021). Polycystin-1 modulates RUNX2 activation and osteocalcin gene expression via ERK signalling in a human craniosynostosis cell model. *Journal of Cellular and Molecular Medicine*, *25*, 3216–3225.

Keats, T. E. (1996). *Atlas of normal roentgen variants that may simulate disease* (6th ed.). Mosby.

Khamanarong, K., Tuamsuk, P., Woraputtaporn, W., Namking, M., Sawatpanich, T., Toomsan, Y., & Iamsaard, S. (2015). Incidence of metopism in adult Thai skulls. *International Journal of Morphology*, *33*, 51–54.

Kumar, N. V., Vijayashanmugam, U., Gugapriya, T. S., Nalinakumari, S. D., & Kumar, N. V. (2016). A roentgen-anatomic study of association between persistent inter-frontal suture with varied presence of frontal sinus. *Indian Journal of Clinical Anatomy and Physiology*, *3*, 510–513.

Kumar, T. H. D., & Rajshekar, S. S. (2015). Study of incidence of metopism in human dry skulls of North Karnataka region. *Journal of Research in Human Anatomy and Embryology*, *1*, 6–8.

Li, J. H., Chen, Z. J., Zhong, W. X., Yang, H., Liu, D., & Li, Y. K. (2023). Anatomical characteristics and significance of the metopism and Wormian bones in dry adult-Chinese skulls. *Folia Morphologica*, *82*, 166–175.

Maneenin, C., Tungsrithong, N., Toomsan, Y., Chaiciwamongkol, K., & Sripanidkulchai, K. (2013). Incidence

19328494, 2024, 6, Downloaded from https://anatomypubs.onlinelibrary.wiley.com/doi/10.1002/ar.25350 by South African Medical Research, Wiley Online Library on [31/07/2024]. See the Terms and Conditions (https://onlinelibrary.wiley.com/terms-and-conditions) on Wiley Online Library for rules of use; OA articles are governed by the applicable Creative Commons License

of metopic suture in skulls of Northeastern Thai adults. *Chiang Mai Medical Journal*, *52*, 11–16.

Mangalgiri, A. S., Satpathi, D. K., Razvi, R., & Naik, D. C. (2010). Study of metopism in skulls of Central India. *Indian Journal of Forensic Medicine and Toxicology*, *4*, 74–77.

Manzanares, M. C., Goret-Nicaise, M., & Dhem, A. (1988). Metopic sutural closure in the human skull. *Journal of Anatomy*, *161*, 203–215.

Marciniak, R., & Nizankowski, C. (1959). Metopism and its correlation with the development of the frontal sinuses: A roentgen anatomic study. *Acta Radiologica*, *51*, 343–352.

Masih, W. F., Gupta, S., Saraswat, P. K., & Aggarwal, S. K. (2013). Autopsy study of metopic suture incidence in human skulls in western Rajasthan. *National Journal of Medical Research*, *3*, 63–65.

Moore, K., & Ross, A. (2017). Frontal sinus development and juvenile age estimation. *The Anatomical Record*, *300*, 1609–1617.

Nallathamby, R., Avadhani, R., Sivarama, C. H., Babu, B., & Jacob, M. (2013). Study on metopic sutures in South Indian skulls. *International Journal of Bioassays*, *2*, 1087–1090. https://doi.org/10.21746/ijbio.2013.08.006

Nayakanati, A. R. J., Bannur, B. M., Rao, M. V. R., Srinivasan, K. R., & Saheb, S. H. (2016). A study on incidence of metopic suture in adult human dry skulls. *International Journal of Anatomy and Research*, *4*, 2235–2237.

Nikolova, S., & Toneva, D. (2019). Frontal sinus dimensions in the presence of persistent metopic suture. *Acta Morphologica et Anthropologica*, *26*, 90–96.

Nikolova, S., Toneva, D., & Georgiev, I. (2016). A persistent metopic suture – Incidence and influence on the frontal sinus development (preliminary data). *Acta Morphologica et Anthropologica*, *23*, 85–92.

Nikolova, S., Toneva, D., Georgiev, I., & Lazarov, N. (2019). Relation between metopic suture persistence and frontal sinus development. In T. C. Wang (Ed.), *Challenging issues on paranasal sinuses* (pp. 3–23). IntertechOpen. https://doi.org/10.5772/intechopen.79376

Odokuma, I. E., & Igbigbi, P. S. (2008). Incidence of metopism in adult Malawian population. *Journal of Experimental and Clinical Anatomy*, *7*, 48–49. https://doi.org/10.4314/jeca.v7i1.48024

Pakdeewong, N., & Tohno, Y. (2019). Coexistence of complete metopic suture and Inca bone in Thai skulls: Incidence, morphology and clinical applications. *Chiang Mai University Journal of Natural Sciences*, *18*, 1–13.

Pélabon, C., Hilde, C. H., Einum, S., & Gamelon, M. (2020). On the use of the coefficient of variation to quantify and compare trait evolution. *Evolution Letters*, *4*, 180–188.

Pilli, N., & Sunder, R. R. (2013). Persistent metopic suture in various forms in south Indian adult skulls – A study. *International Journal of Scientific and Research Publications*, *3*, 1–4.

Pindrik, J., Molenda, J., Uribe-Cardenas, R., Dorafshar, A. H., & Ahn, E. S. (2016). Normative ranges of anthropometric cranial indices and metopic suture closure during infancy. *Journal of Neurosurgery: Pediatrics*, *18*, 667–673.

Pondé, J. M., Andrade, R. N., Via, J. M., Metzger, P., & Teles, A. C. (2008). Anatomical variations of the frontal sinus. *International Journal of Morphology*, *26*, 803–808.

Pujari, R., Naveen, N., Shankar, R. G., & Roopa, C. R. (2015). A study of metopic suture in adult human skull. *Journal of Evolution of Medical and Dental Sciences*, *4*, 5452–5454.

Rochlin, D. G., & Rubaschewa, A. (1934). Zum problem des metopismus. *Zeitschrift für Menschliche Vererbungs-Und Konstitutionslehre*, *18*, 339–348.

Ruengdit, S., Case, D. T., & Mahakkanukrauh, P. (2020). Cranial suture closure as an age indicator: A review. *Forensic Science International*, *307*, 110111. https://doi.org/10.1016/j.forsciint.2019.110111

Saikia, R. A. (2014). A study on metopic suture in cadaveric skulls of Assamese people. *Journal of Evolution of Medical and Dental Sciences*, *3*, 10910+–10914.

Sandre, L. B., Mundim-Picoli, M. B. V., Picoli, F. F., Rodrigues, L. G., Bueno, J. M., & da Silva, R. F. (2017). Prevalence of agenesis of frontal sinus in human skulls with metopism. *The Journal of Forensic Odonto-Stomatology*, *35*, 20.

Santhosh, C. S., Vishwanathan, K. G., Gupta, A., & Siddesh, R. C. (2014). Metopic suture – Incidence and morphology in South Indian human adult skulls. *International Journal of Medical Toxicology and Forensic Medicine*, *4*, 6–10.

Sardi, M. L., Joosten, G. G., Pandiani, C. D., Gould, M. M., Anzelmo, M., & Ventrice, F. (2018). Frontal sinus ontogeny and covariation with bone structures in a modern human population. *Journal of Morphology*, *279*, 871–882.

Schuster, S. C., Miller, W., Ratan, A., Tomsho, L. P., Giardine, B., Kasson, L. R., Harris, R. S., Petersen, D. C., Zhao, F., & Qi, J. (2010). Complete Khoisan and Bantu genomes from southern Africa. *Nature*, *463*, 943–948.

Sheshgiri, C., & Shisirkumar, S. (2014). Study of incidence of metopism in adult South Indian skulls. *International Journal of Science and Research*, *3*, 735–736.

Surekha, T., Himabindu, A., & Viswasanthi, S. (2016). Metopic sutures in adult skulls of north coastal Andhra Pradesh. *International Journal of Health Research in Modern Integrated Medical Sciences*, *3*, 26–28.

Teager, S. J., Constantine, S., Lottering, N., & Anderson, P. J. (2019). Physiologic closure time of the metopic suture in south Australian infants from 3D CT scans. *Child's Nervous System*, *35*, 329–335.

Torgersen, J. (1951). The developmental genetics and evolutionary meaning of the metopic suture. *American Journal of Physical Anthropology*, *9*, 193–205.

Torgersen, J. A. (1950). A roentgenological study of the metopic suture. *Acta Radiologica*, *33*, 1–11.

Trant, M., & Christensen, A. M. (2018). Frontal sinus absence rates in various populations: Implications for forensic identification. *Forensic Anthropology*, *1*, 99–104.

van der Meulen, J. (2012). Metopic synostosis. *Child's Nervous System*, *28*, 1359–1367.

Verma, J. K., Gupta, P., Hussein, M., & Bezbaruah, N. (2014). Morphometrics study of metopic suture in adult North Indian skulls. *Innovative Journal of Medical and Health Science*, *4*, 150–154.

Vinoth, S., Shreekrishna, H. K., Vijaykumari, H., & Singi, Y. (2014). Study of metopic sutures in south Chennai region of Tamilnadu. *Medio-Legal Update*, *14*, 27–30.

Vu, H. L., Panchal, J., Parker, E. E., Levine, N. S., & Francel, P. (2001). The timing of physiologic closure of the metopic suture:

19328494, 2024, 6, Downloaded from https://anatomypubs.onlinelibrary.wiley.com/doi/10.1002/ar.25350 by South African Medical Research, Wiley Online Library on [31/07/2024]. See the Terms and Conditions (https://onlinelibrary.wiley.com/terms-and-conditions) on Wiley Online Library for rules of use; OA articles are governed by the applicable Creative Commons License

A review of 159 patients using reconstructed 3D CT scans of the craniofacial region. *The Journal of Craniofacial Surgery*, *12*, 527–532.

Weinzweig, J., Kirschner, R. E., Farley, A., Reiss, P., Hunter, J., Whitaker, L. A., & Bartlett, S. P. (2003). Metopic synostosis: Defining the temporal sequence of normal suture fusion and differentiating it from synostosis on the basis of computed tomography images. *Plastic and Reconstructive Surgery*, *112*, 1211–1218.

Yadav, A., Kumar, V., & Srivastava, R. K. (2010). Study of metopic suture in the adult human skulls of North India. *Journal of the Anatomical Society of India*, *59*, 232–236.

Yun, L. S., Kim, Y. O., Lee, S. K., & Rah, D. K. (2011). Three-dimensional computed tomographic analysis of frontal sinus in Asians. *The Journal of Craniofacial Surgery*, *22*, 462–467.

Zanaty, A. W. (2017). Forensic study for determination of the incidence of persistent metopic (frontal) suture and its relation to age and sex among sample of Egyptian skulls. *Egyptian Journal of Forensic Sciences and Applied Toxicology*, *17*, 261–273.

**How to cite this article:** Grine, F. E., Greening, V. A., Hernandez, E., Billings, B. K., Mngomezulu, V., & Mongle, C. S. (2024). Metopism in adult South Africans and its relationship to frontal sinus size. *The Anatomical Record*, *307*(6), 2018–2035. https://doi.org/10.1002/ar.25350

19328494, 2024, 6, Downloaded from https://anatomypubs.onlinelibrary.wiley.com/doi/10.1002/ar.25350 by South African Medical Research, Wiley Online Library on [31/07/2024]. See the Terms and Conditions (https://onlinelibrary.wiley.com/terms-and-conditions) on Wiley Online Library for rules of use; OA articles are governed by the applicable Creative Commons License