

https://dspace.org/

Resection of Symptomatic Pineal Cysts Provides Durable Clinical Improvement A Breakdown of Presenting Symptoms and Lessons Learned

Jacky T Yeung; I Young; Christos Profyris; Konstantinos Katsos; M Sughrue ...

https://hdl.handle.net/10539/35161
WOS

Downloaded from a DSpace repository. https://dspace.org/

Check for updates

Resection of Symptomatic Pineal Cysts Provides Durable Clinical Improvement: A Breakdown of Presenting Symptoms and Lessons Learned

Jacky T. Yeung[1], Isabella M. Young[2], Christos Profyris[1,3], Konstantinos Katsos[1], Michael E. Sughrue[1], Charles Teo[1]

BACKGROUND: **Surgical resection of symptomatic pineal cysts without hydrocephalus remains controversial because patients can present with variable symptoms. Hesitancies in surgical decision-making include determining surgical candidacy and whether results would be durable.**

METHODS: **We performed a retrospective analysis on patients who underwent resection of their pineal cysts in our practice. We examined the presenting symptomology and investigated the radiographic changes to the morphology of the cerebral aqueduct found on follow-up imaging. We examined the clinical outcomes and complications following surgical resection of symptomatic pineal cysts.**

RESULTS: **A total of 97 patients underwent resection of pineal cysts, with 84 patients who had adequate follow-up (mean: 30.5 months). The patient population were predominantly female (76%) presenting at a mean of 24 years of age. Almost half of the patients had headaches that were positional, with 82% being bilateral; 39% and 19% of patients presented with photophobia and sonophobia, respectively, concurrent with their headaches. Many patients presented with visual disturbance (73%) along with other non-headache symptoms. Surgery resulted in 89% of patients with clinical improvements of their headaches.**

CONCLUSIONS: **Pineal cysts can present with variable headache symptomatology. Surgical resection of pineal cysts in carefully selected symptomatic patients after exhaustive conservative management can be performed safely and result in durable symptomatic relief.**

INTRODUCTION

Pineal cysts are traditionally thought be asymptomatic entities in neurosurgical dictum. Their incidence ranges from 10% to 54% of the population and are usually incidental radiographic findings.[1] Although they are anatomically situated above the tectum and the aqueduct of Sylvius, they rarely cause obstructive hydrocephalus.[2-5] As they are mostly incidental findings, the treatment of patients with headache syndromes who are found to have pineal cysts without hydrocephalus is often conservative in nature.[1,5,6] In recent years, there have been multiple reports that detail the symptom improvement following resection of these symptomatic pineal cysts.[7-12]

We were among the first to report on a large surgical series of pineal cyst resections.[8] Following that, other authors have reported similar positive results with surgical resection of pineal cysts in carefully selected patients.[7,10,13] In our original experience, we selected patients who had headache syndromes and who had undergone extensive evaluation by headache specialists. Additionally, their symptomology must have included characteristics of raised intracranial pressure (ICP).[8,14] Since that time, the authors have observed that many patients have symptoms that are beyond positional headaches, such as sensory and memory disturbances.[7,10] These symptoms, in our early experience, improve after surgery to remove the pineal cysts.

In the current paper, we performed a retrospective analysis on patients who presented to our practice with headache syndromes

Key words
- Clinical outcomes
- Pineal cyst
- Resection
- Symptomatic pineal cyst

Abbreviations and Acronyms
CSF: Cerebrospinal fluid
ETV: Endoscopic third ventriculostomy
ICP: Intracranial pressure
MRI: Magnetic resonance imaging

From the [1]Centre for Minimally Invasive Neurosurgery, Prince of Wales Private Hospital, Sydney, Australia; [2]Cingulum Health, Sydney, Australia; and [3]Department of Neurosurgery, Helen Joseph Hospital, University of the Witwatersrand, Auckland Park, Johannesburg, South Africa

To whom correspondence should be addressed: Jacky T. Yeung, M.D. [E-mail: jacky.yeung@yale.edu]

Citation: World Neurosurg. (2021) 150:e668-e674. https://doi.org/10.1016/j.wneu.2021.03.087

Journal homepage: www.journals.elsevier.com/world-neurosurgery

Available online: www.sciencedirect.com

1878-8750/$ - see front matter © 2021 Elsevier Inc. All rights reserved.

and had undergone resection of their pineal cysts. We hypothesized that the clinical improvements were durable beyond the immediate perioperative period. We also examined the presenting symptomology and investigated the radiographic changes to the morphology of the cerebral aqueduct found on follow-up imaging. Finally, we present the lessons learned from the surgical management of this disease entity.

METHODS

Patient Selection

The study was conducted under ethics approval by South Eastern Sydney Local Health District (2021/ETH00193). All patients with symptomatic pineal cysts operated at the Centre for Minimally Invasive Neurosurgery (Sydney, Australia) from 2000 to 2020, inclusive, were reviewed. All patients needed to have undergone previous assessment by a headache specialist/neurologist to exclude other causes and exhausted all conservative management before being considered for surgery. Furthermore, each patient must have demonstrated some, no matter how small, stenosis of the cerebral aqueduct. Data were collected on the patient demographics including: details of headache characteristics (whether their position influenced the headache severity or character, and whether the headache was associated with either photophobia or sonophobia); preoperative largest diameter of the pineal cysts; and neurologic symptoms including tinnitus, vertigo/dizziness, memory disturbance, sensory disturbance, and preoperative sleep disturbance. Because sensory-related symptoms were largely variable, we grouped together all symptoms that related to dorsal-column dysfunction into the same category, including abnormal sensations and poor balance. All patients must have histologically proven pineal cysts to be included. Patients were followed up with regular clinical examination and imaging at 6-week post-surgery and with a telephone encounter at the time of data collection. Those lost to follow-up or did not return for a postoperative visit were excluded from further analyses.

Radiographic Analysis

The size of each pineal cyst was measured in its largest diameter by J.Y. and C.T using sagittal T1- and T2-weighted sequences in magnetic resonance imaging (MRI). Changes in the diameter in the cerebral aqueduct were evaluated using postoperative MRI images in the same manner, if available. The change in the aqueductal caliber was dichotomized into either same or improved (widened).

Surgical Strategy

The primary author (C.T.) initially removed pineal cysts using a para-median keyhole supra-cerebellar, infratentorial approach in the prone position. This surgical practice eventually moved towards a supine, keyhole para-median supra-cerebellar, infratentorial approach with the patient's head maximally turned towards the left. Briefly, a 2-cm craniotomy was made below the transverse sinus at 2-finger width from the midline. The dura was opened and reflected upwards. Cerebrospinal fluid (CSF) was gradually released accompanied by arachnoid dissection until the pineal region is reached. Only occasionally in patients with a low-lying torcula, and in whom the long-axis of the cyst pointed to a supratentorial approach, did we perform an inter-hemispheric, retro-splenial, trans-tentorial approach. Frameless stereotaxis was utilized to plan the keyhole craniotomy underneath the transverse sinus. In all cases the cyst was completely resected along with much of the pineal gland. Leaving part of the normal gland intact was felt to reduce the incidence of postoperative sleep disturbance without increasing the risk of cyst recurrence.

Statistical Analysis

Data when appropriate are presented as mean ± standard error of the mean. When parameters were missing from the medical records, such as certain symptoms or postoperative imaging, that variable from the patient was omitted from the denominator as to not influence the true representation of that variable. Comparisons between 2 variables were made using the χ^2 test (categorical variable) or Mann-Whitney test (continuous variable). A P value < 0.05 was considered as significant.

RESULTS

Patient Demographics

Ninety-seven patients underwent resections of pineal cysts (Figure 1). The patient population were predominantly female (76%) (Figure 2A). There was no difference in the age of surgery for both sexes ($P = 0.90$) (Figure 2B). Most patients presented at 24.0 ± 8.4 months of symptom duration before seeking surgical consultation (Figure 2C). Only 1 patient had radiographic mild ventriculomegaly. The mean largest diameter of the pineal cysts was 13.2 ± 0.6 mm (range: 5.0–47.0 mm). There was no correlation between the cyst diameter and age or sex. Mean follow-up was 30.5 ± 3.5 months (range: 0.2–120 months).

Headache Symptomatology

Ninety-four of 97 patients presented with headache as a chief complaint. Figure 3 illustrates the proportion of patients presenting with various headache-related characteristics. Slightly less than half of those patients with information available had headaches that were positional, such that recumbency worsened the headache, akin to ICP-related headaches. None had symptoms of abnormal tearing or rhinorrhea that were akin to cluster headaches. There were 39% and 19% of patients who presented

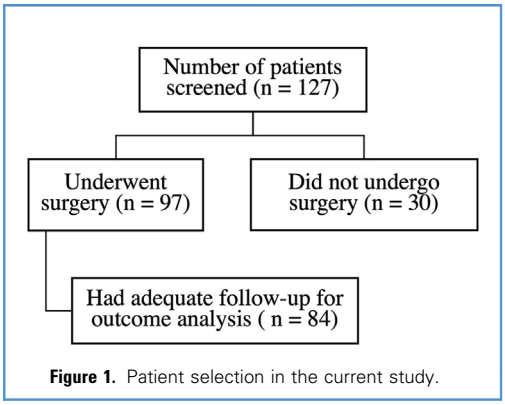

Figure 1. Patient selection in the current study.

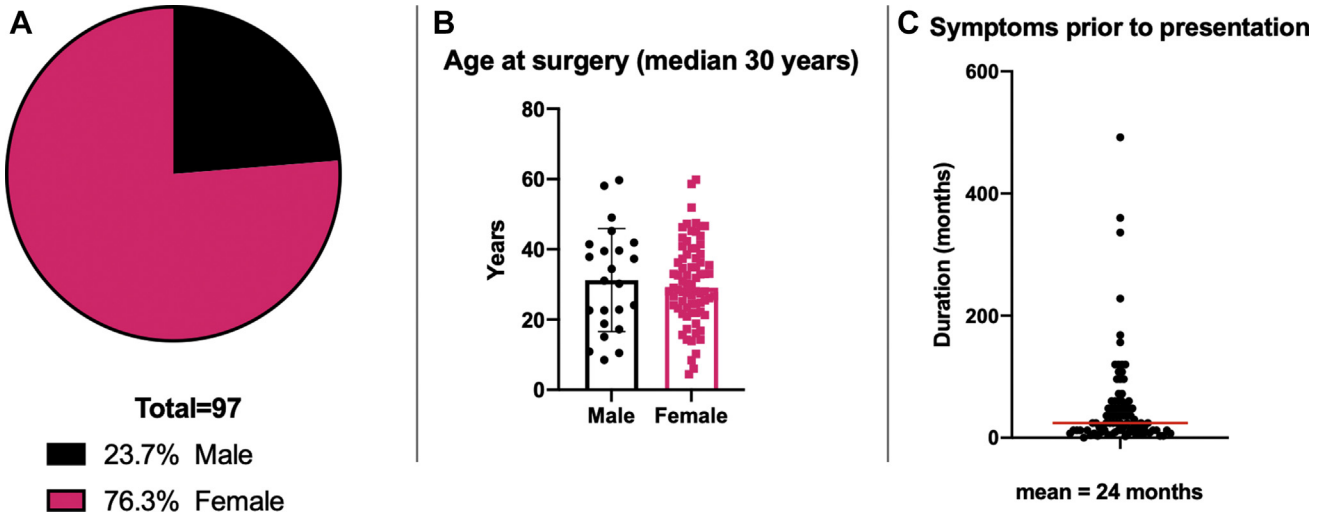

Figure 2. Patient demographics. (**A**) Sex distribution of patients who underwent surgical resection of pineal cysts. (**B**) Age at presentation segregated by sex. (**C**) Duration of symptoms prior to presentation.

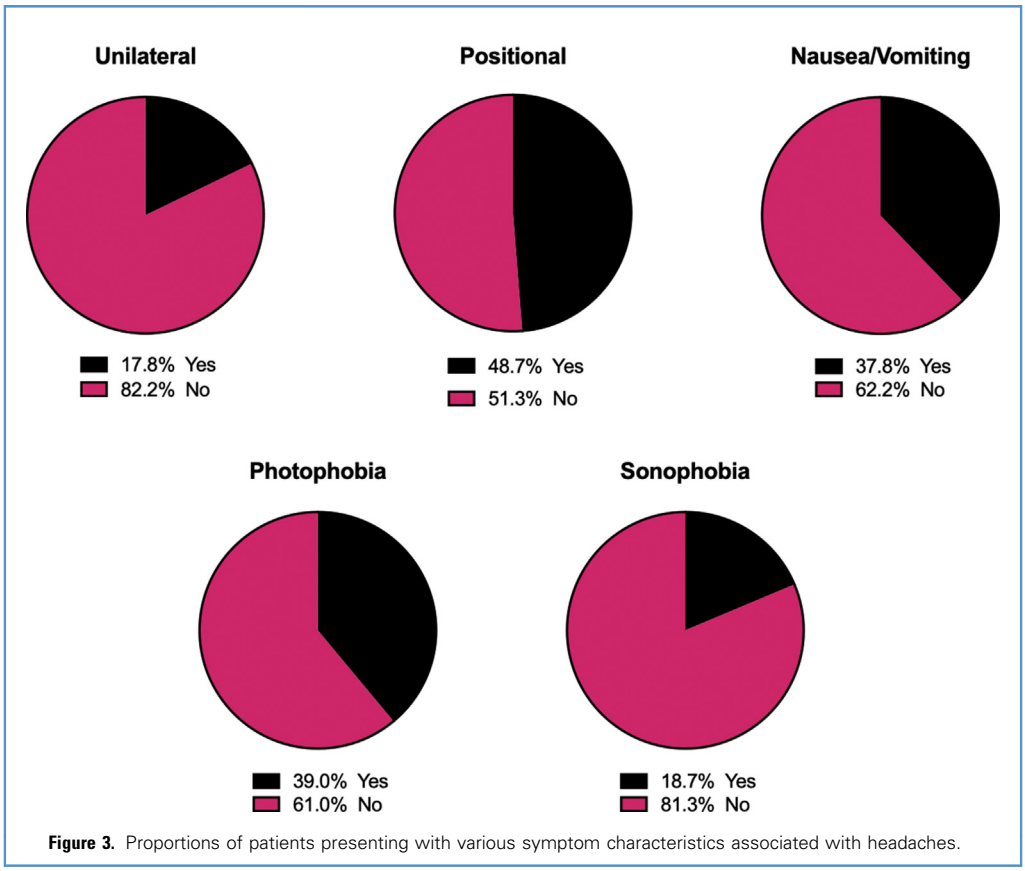

Figure 3. Proportions of patients presenting with various symptom characteristics associated with headaches.

with photophobia and sonophobia, respectively, concurrent with their headaches. Most patients (82%) presented with bilateral headaches. Finally, 38% of patients presented with nausea and/or vomiting that were associated with their headaches.

Non-headache Symptomatology

All patients who presented with headaches as their primary complaints had a constellation of other neurologic complaints (Figure 4). In order from most common to least common, patients often presented with visual disturbance (blurry, flashy lights, transient obscurations) (73%), dizziness (60%), sensory disturbance (58%), poor sleep quality (40%), poor short-term memory (31%), tinnitus (26%), and syncope (17%). None had Parinaud syndrome.

Surgical Outcome and Complications

Of all the patients who presented with headache as their primary complaint and underwent surgical resection of their pineal cysts, 75 out of 84 patients (89%) had improvement in their headache along with their ancillary symptoms (1 did not present with headaches but her uncontrolled syncope resolved completely) (Figure 5A). The length of follow-up of this group was 32.0 ± 3.8 months. Of the 9 patients who did not improve, it was found in 3 patients postoperatively that they had unrelated issues with spinal CSF leak (n = 2) and benign intracranial hypertension (n = 1). Interestingly, all non-headache symptoms improved together with headaches. Of the 74 patients who experienced headache improvements, 70 patients had complete resolution and 4 had partial resolution, but definitive improvements, especially in the frequency of their headache. Seventy patients had postoperative MRI performed, in which 64 (91%) patients demonstrated widening of their cerebral aqueduct and concurrent reconstitution of their tectal plate caliber (Figure 5B).

There were no major complications in our series (Figure 6). There were no postoperative CSF fistulas. There was 1 mild surgical site infection that resolved with oral antibiotic administration. Five of 85 patients (6%) had perioperative complications, including postoperative diplopia, of which 2 cases were permanent, requiring prism correction. Chronic incision pain that was beyond the perioperative period occurred in 3 patients for which 2 patients underwent neuroma excision that resolved the pain. Postoperative sleep disturbance that was either absent preoperatively or worsened postoperatively occurred in 12% of all patients. All patients reported good resolution of their sleep disturbance with the use of melatonin supplements.

DISCUSSION

Pineal cyst resection is increasingly being recognized in the medical literature as a promising treatment for patients presenting with headaches that are recalcitrant to typical medical therapies.[7,10,15] Through this current surgical series, the largest to date to our knowledge, we were able to investigate further into the variability in symptomology and demonstrate the effectiveness

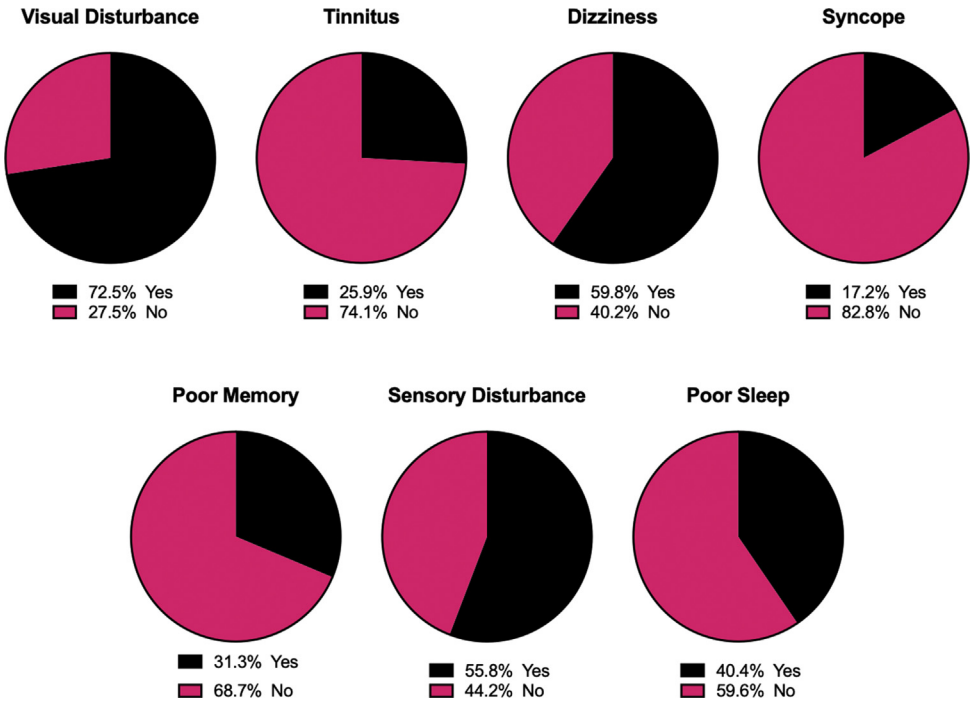

Figure 4. Proportions of patients presenting with various symptom not directly related to headaches.

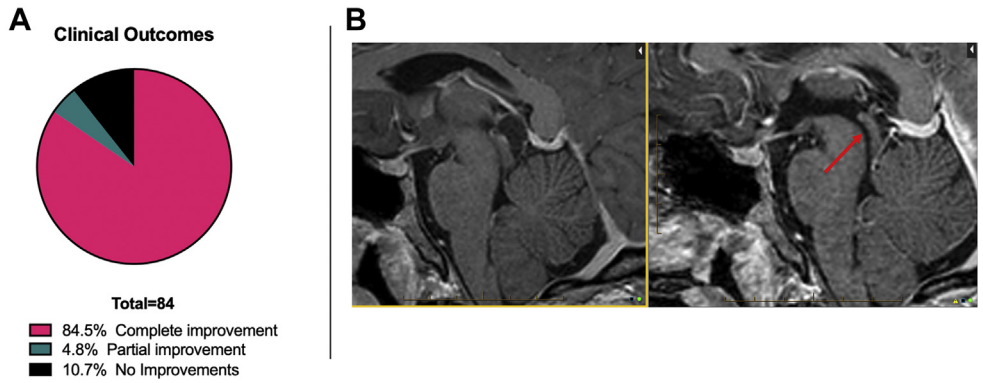

Figure 5. Surgical outcomes after pineal cyst resection. (**A**) Proportion of patients with resolution of chief complaint of headaches, including 1 patient who presented mainly with uncontrolled syncope. (**B**) MRI T1-weight post-gadolinium images demonstrating preoperative pineal cyst causing compression of the cerebral aqueduct (**left**) and reconstitution of the aqueduct (**right**, *red arrow*).

and safety of surgical treatment for symptomatic pineal cysts in experienced hands.

Patient Selection

In the current series, approximately 9 out of 10 patients obtained clinical improvements after resection of their pineal cysts. We attribute the positive outcomes to thoughtful patient selection and what we have coined "Teo's Triad": (1) headache accompanied by visual obscuration or corporal sensory disturbances, (2) previous assessment by a headache specialist/neurologist to exclude other causes and exhaustive conservative management, and (3) radiographic stenosis of the cerebral aqueduct, albeit subtle. Although headaches can vary in characteristics, as discussed subsequently, we never operated on a single patient just for headaches alone. An overwhelming majority of patients displayed visual symptoms that were different than upgaze restriction and they ranged from "blurry vision" to transient blindness, consistent with previous reports.[7,10] The one consistent inconsistency with this was that the visual complaints were never constant, but rather intermittent in frequency. In our opinion, it is imperative that every patient undergoes a thorough workup with a neurologist or a headache specialist to rule out all other possible causes before undertaking intracranial surgery.

Heterogeneity in Headache Characteristics

Most symptomatic pineal cysts patients in our series, similar to other series, presented with headaches in the absence of ventriculomegaly.[7,8,10,13] Our cohort corroborated with the sex differences as other series, that symptomatic pineal cysts tend to occur in female patients more so than male patients at a

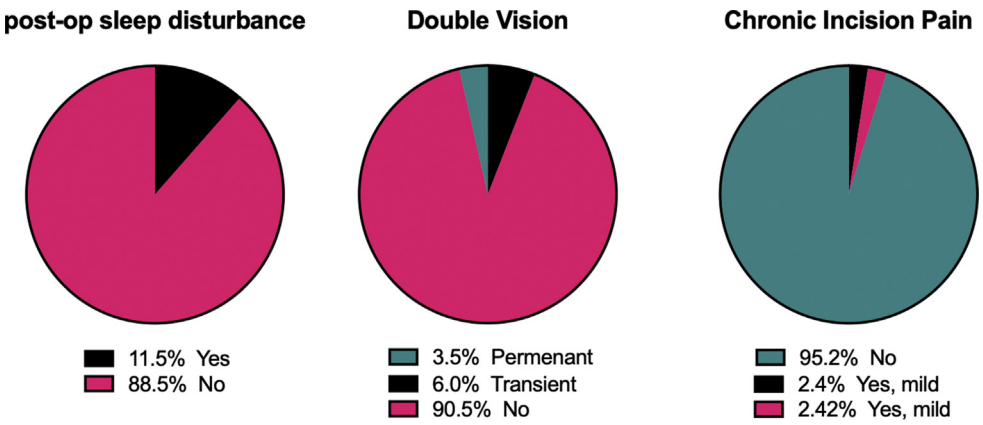

Figure 6. Surgical complications after pineal cyst resection.

ratio of 4 to 1. This female predominance is akin to that seen in migraine headaches, and opposite to that of cluster headaches and is likely due to the overall higher prevalence of pineal cysts in the female sex.[5,16] Similarly, it appeared that this clinical condition mostly affects young adults. A unique question that we tried to answer in our current series was the role played by the characteristics of headaches. In our experience, many of our patients presented to our institution after being labeled with a diagnosis of migraine headaches, although many of these patients exhibited heterogenous patterns. Although some patients presented with bilateral headaches, there were some that were unilateral, admixed with characteristics of migraine, such as photophobia and, less commonly, sonophobia. Therefore, our results suggest that a patient who has failed conventional interventions should not be precluded as a surgical candidate just because they demonstrate migraine-like symptoms.

Lack of Correlation Between Headaches and Signs of Increased ICP

Pineal cysts occur adjacent to the tectal plate and can cause stenosis of the cerebral aqueduct of Sylvius, often visible as a T2-flow void on MRI. However, patients with symptomatic pineal cysts in our and other cohorts did not present with frank hydrocephalus and ventriculomegaly. Many patients' headaches were not positional, nor did the patients present with Parinaud syndrome, arguing against situations with increased ICP. Anecdotally, in a rare patient who did present with radiographic hydrocephalus, her headache was not reported to be positional. She underwent an endoscopic third ventriculostomy (ETV) at an outside institution that did not improve her headache syndrome. After resection of her pineal cyst, she had complete resolution of her headaches (**Figure 7**).

Certainly, the heterogeneity of symptoms and poor correlation with imaging would suggest another potential mechanism for headache generation that is different from intermittent increased ICP. Of note, this case is in contrast to a recently reported series in which ETV was used as the mainstay of treatment for these patients, although that series was admixed with patients who had hydrocephalus.[17] In that series, 3 of these patients (21.4%) developed recurrence, which suggested that ETV alone may not be satisfactory for treatment of these pathologies. In our surgical series, we found that 3 out of 9 patients postoperatively had underdiagnosed spinal CSF leakage and benign intracranial hypertension, despite having undergone extensive medical workup prior. This further underscores the need to exhaust all conventional workup before considering patients for pineal cyst resection.

Potential Cause of Symptoms

We acknowledge the opening of the cerebral aqueduct post-resection; in addition, it should also be noted that the tectal plate tends to regain its caliber as well, suggestive of a local compressive phenomenon being a potential symptom generator. This is further supported by the fact that some patients had small pineal cysts with no overt aqueductal stenosis; yet they derived considerable improvement after surgical resection. Of course, there were 6 out of 9 patients who did not respond to surgery in whom we could not ascertain the cause, other than co-incidental pain syndromes. However, the vast majority of our patients derived obvious benefit from pineal cyst resection regardless of cyst size. We hypothesize, in concert with other groups, that the local compressive effects from the pineal cyst, perhaps causing focal venous congestion, combined with variability at the individual level, may be the cause of these patients' symptoms.[12,18-20] This further corroborates with a large surgical series by Hajnsek et al. in which neurophysiologic/electroencephalogram changes were detected in their patients with expanding pineal cysts.[12] One option going forward as a field is to establish an international registry for patients with pineal cysts in order to gain further understanding of this pathologic entity.

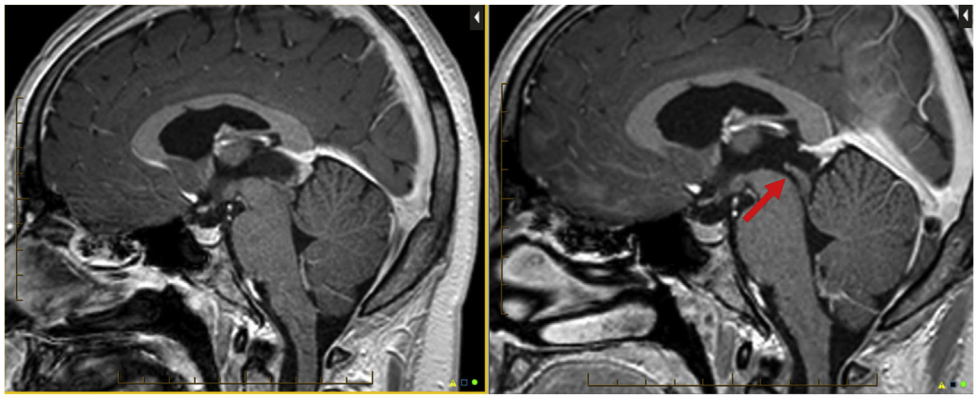

Figure 7. Point for discussion: Focal stenosis of cerebral aqueduct. MRI T1-weight post-gadolinium images demonstrates preoperative pineal cyst causing compression of the cerebral aqueduct even after ETV (**left**) and reconstitution of the aqueduct correlating with symptom resolution (**right**, *red arrow*).

Limitations

The current study is limited by its retrospective nature and the associated biases, such as recall bias during follow-up. There was inherently a referral and selection bias of the patients, as those who came to our highly specialized practice were patients who had undergone very comprehensive workup, including previous consultation with a headache specialist. Therefore, our results should not be readily applied to all patients presenting with headaches and pineal cysts. Placebo effects should always be considered in these situations as these patients were often orphaned by other clinicians and out of therapeutic options. However, the long average follow-up of our patients and their durable responses suggested that the placebo effect, if true, would have worn off after some time. Our results are in line with El Damaty et al., further attesting to the durability of surgical treatment for symptomatic pineal cysts.[7] A prospectively collection multicenter study that highlights patient symptomology and radiographic characterization of pineal cysts using standardized classifications would be beneficial in furthering our understanding of this disease.[21]

CONCLUSIONS

Pineal cysts can present with variable headache symptomatology. Surgical resection of pineal cysts in symptomatic patients who have had exhaustive conservative management can be performed safely and results in durable symptomatic relief.

CRediT AUTHORSHIP CONTRIBUTION STATEMENT

Jacky T. Yeung: Investigation, Formal analysis, Data curation, Writing - original draft. **Isabella M. Young:** Writing - review & editing, Visualization. **Christos Profyris:** Investigation. **Konstantinos Katsos:** Investigation. **Michael E. Sughrue:** Supervision, Validation. **Charles Teo:** Conceptualization, Supervision, Writing - review & editing.

REFERENCES

1. Storey M, Lilimpakis K, Grandal NS, Rajaraman C, Achawal S, Hussain M. Pineal cyst surveillance in adults—a review of 10 years' experience. *Br J Neurosurg*. 2020;34:565-568.
2. Sawamura Y, Ikeda J, Ozawa M, Minoshima Y, Saito H, Abe H. Magnetic resonance images reveal a high incidence of asymptomatic pineal cysts in young women. *Neurosurgery*. 1995;37:11-15 [discussion: 15-16].
3. Golzarian J, Balériaux D, Bank WO, Matos C, Flament-Durand J. Pineal cyst: normal or pathological? *Neuroradiology*. 1993;35:251-253.
4. Mamourian AC, Towfighi J. Pineal cysts: MR imaging. *AJNR Am J Neuroradiol*. 1986;7:1081-1086.
5. Al-Holou WN, Terman SW, Kilburg C, et al. Prevalence and natural history of pineal cysts in adults. *J Neurosurg*. 2011;115:1106-1114.
6. Májovský M, Netuka D, Beneš V. Clinical management of pineal cysts: a worldwide online survey. *Acta Neurochir (Wien)*. 2016;158:663-669.
7. El Damaty A, Fleck S, Matthes M, Baldauf J, Schroeder HWS. Pineal cyst without hydrocephalus: clinical presentation and postoperative clinical course after infratentorial supracerebellar resection. *World Neurosurg*. 2019;129:e530-e537.
8. Kalani MY, Wilson DA, Koechlin NO, et al. Pineal cyst resection in the absence of ventriculomegaly or Parinaud's syndrome: clinical outcomes and implications for patient selection. *J Neurosurg*. 2015;123:352-356.
9. Michielsen G, Benoit Y, Baert E, Meire F, Caemaert J. Symptomatic pineal cysts: clinical manifestations and management. *Acta Neurochir (Wien)*. 2002;144:233-242 [discussion: 242].
10. Májovský M, Netuka D, Beneš V. Conservative and surgical treatment of patients with pineal cysts: prospective case series of 110 patients. *World Neurosurg*. 2017;105:199-205.
11. Wisoff JH, Epstein F. Surgical management of symptomatic pineal cysts. *J Neurosurg*. 1992;77:896-900.
12. Hajnsek S, Paladino J, Gadze ZP, Nanković S, Mrak G, Lupret V. Clinical and neurophysiological changes in patients with pineal region expansions. *Coll Antropol*. 2013;37:35-40.
13. Koziarski A, Podgórski A, Zieliński GM. Surgical treatment of pineal cysts in non-hydrocephalic and neurologically intact patients: selection of surgical candidates and clinical outcome. *Br J Neurosurg*. 2019;33:37-42.
14. Peres MF, Zukerman E, Porto PP, Brandt RA. Headaches and pineal cyst: a (more than) coincidental relationship? *Headache*. 2004;44:929-930.
15. Milton CK, Pelargos PE, Dunn IF. Headache outcomes after surgery for pineal cyst without hydrocephalus: a systematic review. *Surg Neurol Int*. 2020;11:384.
16. Allena M, De Icco R, Sances G, et al. Gender differences in the clinical presentation of cluster headache: a role for sexual hormones? *Front Neurol*. 2019;10:1220.
17. Davidson L. Endoscopic management of pineal cyst-associated aqueductal stenosis. *Acta Neurochir (Wien)*. 2020;162:2975-2982.
18. Eide PK, Pripp AH, Ringstad GA. Magnetic resonance imaging biomarkers indicate a central venous hypertension syndrome in patients with symptomatic pineal cysts. *J Neurol Sci*. 2016;363:207-216.
19. Eide PK, Ringstad G. Increased pulsatile intracranial pressure in patients with symptomatic pineal cysts and magnetic resonance imaging biomarkers indicative of central venous hypertension. *J Neurol Sci*. 2016;367:247-255.
20. Eide PK, Ringstad G. Results of surgery in symptomatic non-hydrocephalic pineal cysts: role of magnetic resonance imaging biomarkers indicative of central venous hypertension. *Acta Neurochir (Wien)*. 2017;159:349-361.
21. Sirin S, de Jong MC, Galluzzi P, et al. MRI-based assessment of the pineal gland in a large population of children aged 0-5 years and comparison with pineoblastoma: part II, the cystic gland. *Neuroradiology*. 2016;58:713-721.

Conflict of interest statement: M. Sughrue and C. Teo are co-founders of Omniscient Neurotechnology. No products related to this are discussed in this paper. No other authors report any conflict of interest.

Received 24 February 2021; accepted 16 March 2021

Citation: World Neurosurg. (2021) 150:e668-e674. https://doi.org/10.1016/j.wneu.2021.03.087

Journal homepage: ***www.journals.elsevier.com/world-neurosurgery***

Available online: ***www.sciencedirect.com***

1878-8750/$ - see front matter © 2021 Elsevier Inc. All rights reserved.