

https://dspace.org/

A topographical and surgical anatomical description of the recurrent laryngeal nerve Observations from cadaveric dissection and thyroidectomy patients

Joshua Kiluba; Candice Small; Ifongo Bombil; Kasonga Bulabula; Thifhelimbilu Luvhengo ...

https://hdl.handle.net/10539/42474
SCOPUS

Downloaded from a DSpace repository. https://dspace.org/

Translational Research in Anatomy 37 (2024) 100348

Contents lists available at ScienceDirect

Translational Research in Anatomy

journal homepage: www.elsevier.com/locate/tria

A topographical and surgical anatomical description of the recurrent laryngeal nerve: Observations from cadaveric dissection and thyroidectomy patients

Joshua BL. Kiluba [a,1], Candice Small [a,1], Ifongo Bombil [b], Kasonga Paul Bulabula [b], Thifhelimbilu Emmanuel Luvhengo [b], Pedzisai Mazengenya [c,d,*]

[a] Human Variation and Identification Research Unit (HVIRU), School of Anatomical Sciences, University of the Witwatersrand, Johannesburg, South Africa
[b] Department of Surgery, School of Clinical Medicine, University of the Witwatersrand, Johannesburg, South Africa
[c] College of Medicine, Ajman University, Ajman, United Arab Emirates
[d] Center of Medical and Bio-allied Health Sciences Research, Ajman University, Ajman, United Arab Emirates

ARTICLE INFO

Keywords:
Recurrent laryngeal nerve
Inferior thyroid artery
Tracheoesophageal groove
Anatomical variation
Thyroidectomy
Neck pathology

ABSTRACT

Background: Recurrent laryngeal nerve (RLN) injuries account for most successful litigations against surgeons following head and neck surgery. Most injuries to the RLN occur during thyroidectomy with the best strategy to reduce injury to the RLN being through intraoperative monitoring of its normal anatomy, extra-laryngeal trajectory and topography. Identification of the RLN during thyroidectomy is possible at the tracheoesophageal groove (TEG), where it crosses the inferior thyroid artery (ITA) and or pierces the suspensory ligament of the thyroid gland (ligament of Berry). The extra-laryngeal course and branching patterns of the RLN are highly variable, increasing the likelihood of iatrogenic injury.

Materials and methods: The current study investigated the extra-laryngeal course, branching patterns and topographical relationships of the RLN in the TEG in adult cadavers and patients who underwent thyroidectomy. The study examined 30 thyroidectomy patients and 50 adult cadavers.

Results: The mean diameters of the RLN were 1.74 ± 0.59 mm and 1.63 ± 0.47 mm on the left and right sides, respectively, with no statistically significant difference between the genders and sides ($P \geq 0.05$). The majority of the RLNs on the left side coursed in the first 0–15° relative to the TEG while on the right side the majority deviated from the TEG at an angle ranging between 0 and 30°. The distribution of the RLN in relation to the inferior thyroid artery in the cadaveric sample was as follows: 29.6 % posterior to the artery, 33.7 % anterior to the artery and 36.7 % in-between its branches with statistically significant differences between genders ($P \leq 0.05$). The majority of the RLN exhibited two or more branches on both sides, with a maximum of four branches being observed. In the surgical cohort, majority of the RLN ran posterior to the ITA followed by the anterior course and least in-between the branches of the ITA.

Conclusions: The present findings augment the vital information about the course, topography and branching patterns of the RLN along the TEG by outlining differences between the a cadaveric and a surgical sample as well as between two major South African population groups in order to minimise the iatrogenic injuries to the RLN and also to improve the diagnoses and management of the disorders of the neck, larynx and voice production.

1. Introduction

The recurrent laryngeal nerve (RLN) is a branch of the vagus nerve in the neck that follows an asymmetrical path on the left and right sides and provides motor innervation to the majority of the intrinsic muscles of the larynx as well as sensory innervation to the laryngeal mucosa below the vocal folds. The nerve facilitates the laryngeal reflex that acts as a sphincter to prevent solids from entering the lower respiratory tract and is also involved in phonation [1–4]. Injury to the RLN is a dreaded complication of head and neck surgery and it affects up to 11 % of

* Corresponding author. College of Medicine, Ajman University, Ajman, United Arab Emirates.
E-mail address: p.mazengenya@ajman.ac.ae (P. Mazengenya).
[1] Joshua Kiluba and Candice Small share the first authorship to this manuscript.

https://doi.org/10.1016/j.tria.2024.100348
Received 12 July 2024; Received in revised form 1 September 2024; Accepted 3 September 2024
Available online 4 September 2024
2214-854X/© 2024 The Authors. Published by Elsevier GmbH. This is an open access article under the CC BY-NC license (http://creativecommons.org/licenses/by-nc/4.0/).

patients following thyroidectomy and represents the majority of malpractice litigations against surgeons [5–13]. Despite the abundance of research describing the anatomy of the RLN [1–4] and the advent of intraoperative nerve monitoring [10,14], the rates of its iatrogenic injuries remain significantly high. Approximately 71 % of RLN intraoperative injuries occur between the inferior thyroid artery crossing point and the entrance into the larynx [15]. Intraoperative identification, exposure and tracing of the RLN throughout its extra-laryngeal course is a recommended procedure to reduce nerve damage [6,9,16]. Sites that are normally used for the initial identification of the RLN during thyroidectomy include: inferiorly at the beginning of the TEG [17]; the inferior thyroid artery (ITA) crossing point [18,19]; the cricopharyngeal border of inferior constrictor muscle as it pierces the ligament of Berry; and at the inferior cornu of the thyroid cartilage [2,4,8,15,20,21].

Iatrogenic injuries to the RLN may result from transection, overstretching of the nerve during retractions and/or thermal injury [8,13]. The presence of extra-laryngeal branches and non-recurrence of the RLN increases the likelihood of iatrogenic injuries during head and neck surgeries including thyroidectomy [22–25]. The RLN is also prone to injuries in patients undergoing high-risk thyroidectomies [26] that includes total thyroid removal [26], thyroid cancer with or without cervical lymphadenectomy [27], goitre with retrosternal extension [28,29], and repeat thyroidectomy associated with recurrent disease [28]. Reported rates of RLN injury are also higher when the procedure is performed by low-volume surgeons with limited experience [30]. The anatomy of the RLN is highly variable, and perhaps the so-called "normal anatomy" may not exist. Total thyroidectomy is a standard treatment of some benign diseases of the thyroid gland and high-risk differentiated malignant tumours. The RLN may be infiltrated by a malignant tumour [31] or displaced by a benign nodular goitre making its identification and intraoperative monitoring difficult, thereby increasing the risk of injury [32,33].

There is a paucity of information on the normal anatomy of the RLN and its associated injuries during thyroidectomies in South Africa, despite a high prevalence of thyroidectomies, with Chris Hani Baragwanath Academic Hospital alone performing up to 50 thyroidectomies per year [34]. A recent study conducted on a paediatric cohort in South Africans showed that the RLN is highly variable even between the left and right sides of the same individual [35]. High variability of the RLN trajectory, topography and branching patterns observed in the paediatric sample necessitated the development of the current study in order to determine, firstly the growth-related changes in the adult populations particularly its course in the TEG and secondly to decipher the anatomical parameters of the RLN in formaldehyde fixed adult cadavers as compared to those in adult patients undergoing thyroidectomies. Evidence has showed that formaldehyde fixation of cadaveric specimens causes stiffening of the tissues leading to shrinkage and immobility [36,37]. These factors will render the information obtained from formaldehyde fixed specimens difficult to translate to surgical patients [37]. Thus, the current study investigated the variations of the topographical relationships of the RLN with the TEG and ITA and patterns and frequency of the extra-laryngeal branching of the RLN of both formaldehyde fixed cadavers and surgical patients undergoing thyroidectomies.

2. Materials and methods

2.1. Study sample

For the cadaveric cohort, 49 formalin fixed cadavers aged 77.6 ± 12.3 years (range: 42–77 years) and donated for learning and research to the School of Anatomical Sciences at the University of the Witwatersrand, were dissected and photographed. A total of 98 RLNs was examined. The sample distribution by genders is shown in Table 1.

For the surgical cohort, 30 female individuals aged 49.8 ± 14.3 years (range: 21–80 years) scheduled for thyroidectomy were recruited using convenient sampling. In total, 38 of the 60 RLNs were identified. Twenty-two RLNs could not be visualized due to tumour invasion or because the surgeon reported that exposure of the nerve would increase the risk of injury (Tables 1 and 2). Eligible participants were recruited through a 3-step process comprising detailed information on the study, an open invitation to participate in the study and written informed consent that could be withdrawn at any point during the study. Indications for thyroidectomy included benign and malignant conditions. Re-do thyroidectomies were excluded due to their high-risk nature [28]. Patients were operated upon by a single surgeon at each of the participating hospitals.

Table 1
Demographics for the cadaveric and the surgical sample.

Variables	Cadaveric	Surgical
	N = 49	N = 30
Gender, N (%)		
Male	24 (48.97 %)	0
Female	25 (51.10 %)	30 (100 %)
Ethnicity, N (%)		
Black	0	28 (93.33 %)
White	50 (100 %)	1 (3.33 %)
Indian	0	1 (3.33 %)
Age		
Mean ± SD	77.7 ± 12.2	49.8 ± 14.3
Median (IQR)	80 (70–87)	50 (39–59)
Range	47–95	21–80
Normality (Shapiro Wilk test)	P = 0.026	P = 0.983

*SD = Standard deviation; IQR = Interquartile range.

2.2. Ethical considerations

Ethical clearance for the cadaveric dissection was covered under the Human Tissue Act No. 65 of 1983 and the National Health Act No. 61 of 2003 of South Africa, reference number (W-CJ-140604-1) obtained from the University of the Witwatersrand. Ethical clearance for the collection of data on candidates undergoing thyroidectomies was granted by the Human Research Ethics Committee (Medical) at the University of the Witwatersrand (M160664). The data collection procedures did not interfere or delay any of the patient's therapeutic procedures.

2.3. Data collection

2.3.1. Cadaveric dissection

The dissection technique described by Kieser and Allan [38] was followed to locate the RLN in cadavers. To confirm the recurrence of the nerve, the sternum was disarticulated from the clavicle and the ribs to expose the great vessels, including the aorta and subclavian arteries, in preparation for the neck dissection. A midline superficial incision was made from the mandible to the sternal notch and the skin was dissected superficially to expose the platysma muscle. The investing layer of fascia was dissected to reveal the omohyoid, sternohyoid, thyrohyoid and sternothyroid muscles i.e. the strap muscles. The sternocleidomastoid muscle was reflected superiorly. The strap muscles were reflected to reveal the carotid sheath and its contents. The vagus nerve was identified in the carotid sheath on the right and traced caudally up to the point of recurrence around the right subclavian artery. On the left, the point of

Table 2
Surgical sample distribution in relation to the presence of the RLN.

RLN	Bilateral	Unilateral	Total
Present	32	6	38
Absent	8 (16 total)	6	22

RLN = Recurrent laryngeal nerve.

recurrence was around the arch of the aorta.

Standard photographs were taken at a 15–30 cm distance from the exposed structure of interest and at an angle of 45° using a high-resolution Nikon® Camera and 1 mm scale bar was applied to all the images. The open-source software ImageJ® (National Institutes of Health in Bethesda, Maryland, USA) was used to calculate pixel differences between two selected points and translate them into accurate metric measurements of diameter and angle between the RLN and the TEG. The following was therefore noted: 1) The diameter of the RLN; 2) The angular course of the RLN in the TEG and this was divided based on the angulation (X) into: $X < 15°$; $15° < X < 30°$; $30° < X < 45°$ and $X > 45°$; 3) The relationship between the RLN and the ITA; and 4) The presence and number of branches at the terminal end of the RLN.

2.3.2. Thyroidectomy procedure

All the patients recruited for this study underwent indirect laryngoscopy pre- and post-operatively and vocal fold mobility was assessed. After general anaesthesia and endotracheal intubation, patients were placed in a supine position with the head on a donut pillow. The neck was slightly extended, and the bed placed at 15–30º in reverse Trendelenburg position. Thyroidectomies were done using the surgical procedure described by Zollinger and Ellison [39]. A 3–4 cm collar incision was made ±2 cm above the sternal notch or 1 cm below the cricoid cartilage. The platysma was retracted to expose the strap muscles which were separated in the midline. Each lobe of the thyroid gland was mobilized and retracted antero-medially after ligation of the ipsilateral middle thyroid vein and superior thyroid vessels to reveal the external superior laryngeal nerve. Routine identification of the RLN was carried out in all cases and started where the nerve crosses the ITA (Fig. 1A–C). Photographs were taken to document the surgical process and to identify the RLN *in situ*. Unfortunately, in order to ensure patient welfare and reduce the risk of harm, the surgical sterile field did not allow photographs to be taken close enough so that measurements could later be taken using ImageJ®. The 1) relationship between the RLN and ITA and 2) the presence of terminal branches of the RLN were recorded by the surgeon.

2.4. Data analysis

The collected data were managed in Microsoft Excel 2013 (Microsoft Corporation) and STATA® version 14 statistical software was used for the statistical analyses. Percentages were used to summarize categorical data. Measurements derived from the photographs of each specimen using ImageJ® software were compared using the student t-test for between measures. The topography of the RLN in males and females; the dissected side, its relationship with the ITA, its angular course in the TEG and branching pattern were subjected to a Chi-square statistical test to test for respective associations and Wilcoxon Signed Rank Test to compare the difference between sides using two matched samples.

3. Results

3.1. Cadaveric cohort

3.1.1. Diameter of the recurrent laryngeal nerves

The RLN mean diameters showed no statistically significant differences with regards to side and or gender. A breakdown of the descriptive statistics and RLN diameters are given in Table 3.

3.2. Relationship of the recurrent with the tracheoesophageal groove

The angle that the RLN formed in relation to the TEG was highly

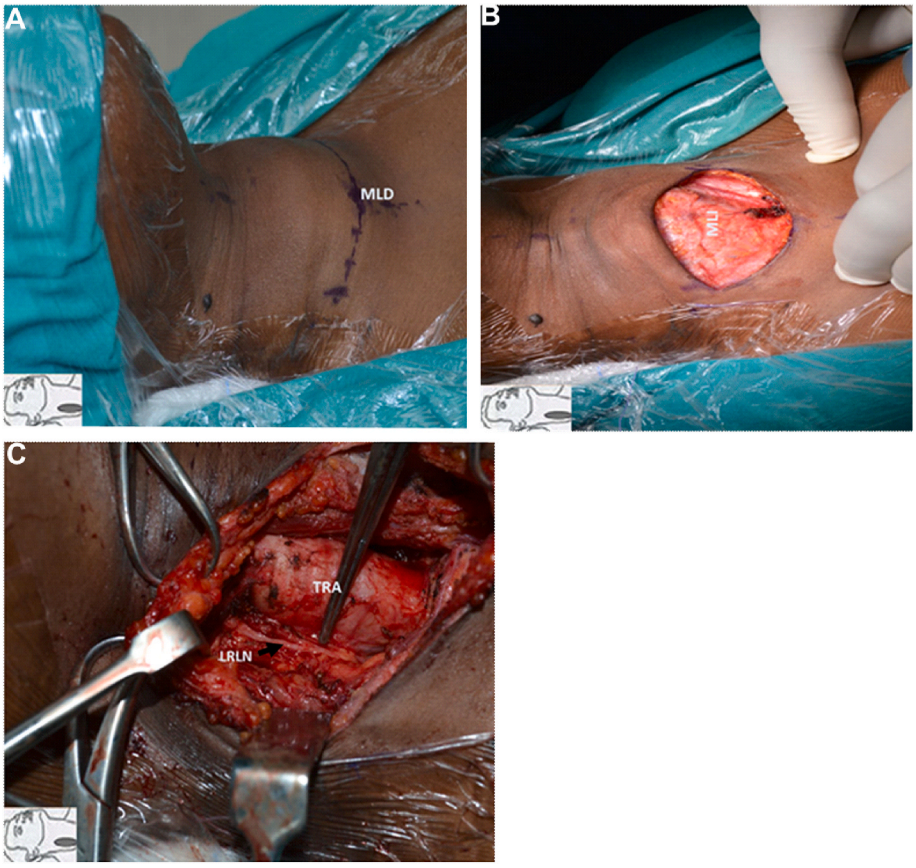

Fig. 1. The photographs (A–C) depicts the thyroidectomy procedure as described in Zollinger and Ellison (2016). MLD = Midline, MLI = Midline incision, TRA = Trachea, LRLN = Left recurrent laryngeal nerve.

Table 3
Descriptive statistics for the cadaveric and surgical samples including recurrent laryngeal nerve diameters stratified by side and gender.

Variables	Left side	Right side	P-value
Males			
Number of RLNs	24	24	
Mean (SD)	1.69 ± 0.66	1.71 ± 0.53	0.912
Median (IQR)	1.6 (1.37–1.94)	1.76 (1.30–2.07)	0.773
Shapiro Wilk test	0.020	0.824	
Females			
Number of RLNs	25	25	
Mean (SD)	1.80 ± 0.51	1.56 ± 0.41	0.049
Median (IQR)	1.83 (1.43–2)	1.59 (1.23–1.92)	0.051*
Shapiro Wilk test	0.505	0.483	
Total			
Number of RLNs	49	49	
Mean (SD)	1.74 ± 0.59)	1.63 ± 0.47	0.222
Median (IQR)	1.65 (1.37–1.97)	1.64 (1.28–1.98)	0.255*
Shapiro Wilk test	P = 0.016	P = 0.604	

RLN= Recuurent laryngeal nerve; SD= Standard deviation; IQR= Interquartile range; * Median differences tested using Wilcoxon Signed Rank test.

variable with 93.9 % of RLNs in all participants on the left side coursing within 0–15° of the TEG as compared to 46.9 % on the right side (Table 4), with a total of 87.7 % coursing below 30°. The difference in angle of approach of the RLN to the TEG between the right and left was statistically significant (p = 0.0001) and symmetry was observed in only 20 % of all the participants. A comprehensive breakdown of the angular course of the RLN relative to the TEG is given in Table 4.

3.3. Anatomical relationship of the recurrent laryngeal nerve with the inferior thyroid artery

All the RLNs studied showed a recurrent course. Overall, there was a nearly identical total distribution of the RLN bilaterally coursing anteriorly (33.7 %) (Fig. 2A and B), posteriorly (29.6 %) (Fig. 3A and B) and in-between (36.7 %) (Fig. 4A and B and 5A, B) the branches of the ITA (Table 5). There was a significant statistical difference in the distribution when the data was stratified by side only.

3.4. Extra-laryngeal branching of recurrent laryngeal nerve

Extra-laryngeal branching of the RLN was observed in 61 % of the cadaveric RLNs studied. Of these, 36.7 % (18/49) revealed a symmetrical bilateral bifurcation i.e. on both the left and right side equally. The difference in the presence and number of extra-laryngeal branches on left and right sides was not statistically significant. The highest number of branches observed in this study was four (Fig. 6A and B).

Table 4
Relationship of the recurrent with the tracheoesophageal groove stratified by side and gender.

Variables	0–15°	16–30°	31–45°	>45°
	N (%)	N (%)	N (%)	N (%)
Females				
Left	22 (88.0)	2 (8.0)	1 (4.0)	0
Right	12 (48.0)	11 (44.0)	1 (4.0)	1 (4.0)
Total	34 (68.0)	13 (26.0)	2 (4.0)	1 (2.0)
Males				
Left	24 (100)	0	0	0
Right	11 (45.83)	9 (37.5)	4 (16.67)	0
Total	35 (72.92)	9 (18.75)	4 (8.33)	0
Total				
Left	46 (93.88)	2 (4.08)	1 (2.04)	0
Right	23 (46.94)	20 (40.82)	5 (10.2)	1 (2.04)
	69 (70.41)	22 (22.45)	6 (6.12)	1 (1.02)

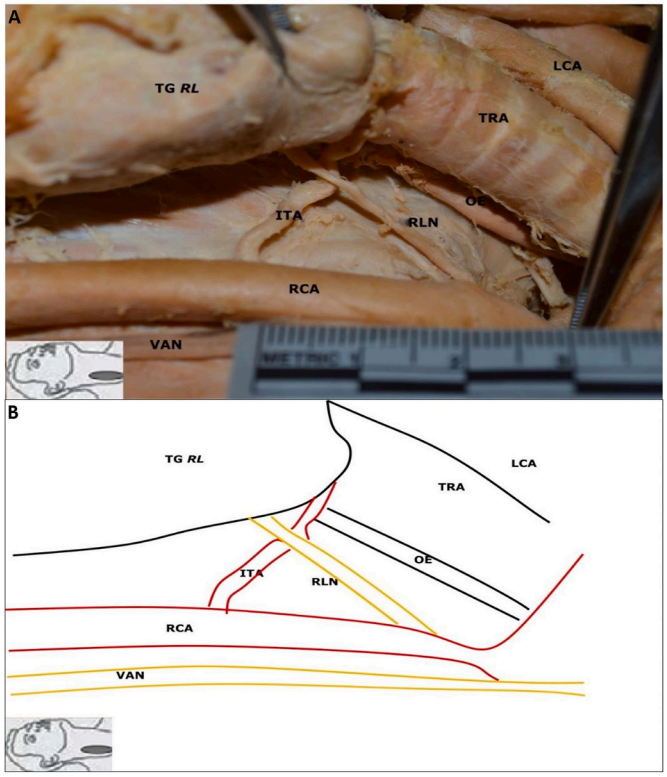

Fig. 2. The images (**A, B**) show the RLN coursing anterior to the ITA on the right side. **A**. Dissection photograph; **B**. Line drawing. Abbreviations ITA, inferior thyroid artery; TRA, trachea; OE, oesophagus; RCA, right common carotid artery; VAN, vagus nerve; TG, thyroid gland; RL, right lobe of thyroid gland.

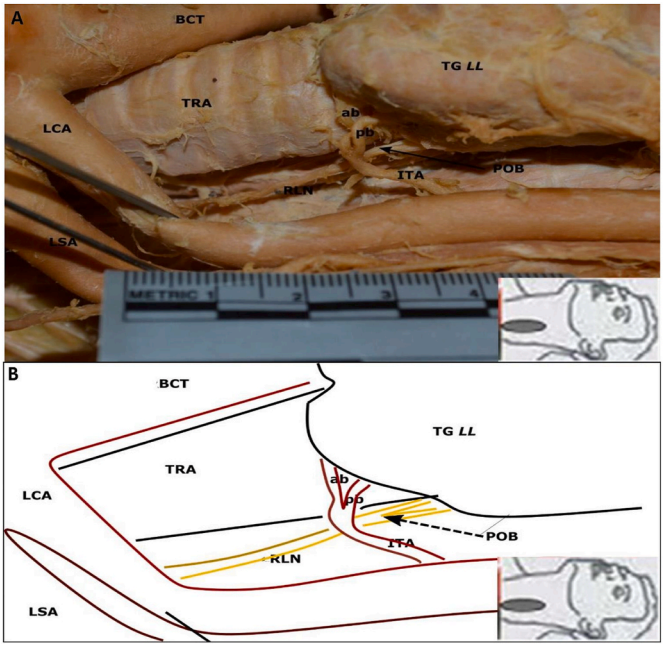

Fig. 3. The images (**A, B**) show the RLN coursing posterior to the ITA on the left side. **A**. Dissection photograph; **B**. Line drawing. Abbreviations RLN, recurrent laryngeal nerve; ITA inferior thyroid artery; ab, anterior branch of ITA; pb, posterior branch of the ITA; TG, thyroid gland; LL, left lobe lobe of thyroid gland; TRA, trachea; POB point of bifurcation; LCA, left common carotid artery; LSA, left subclavian artery.

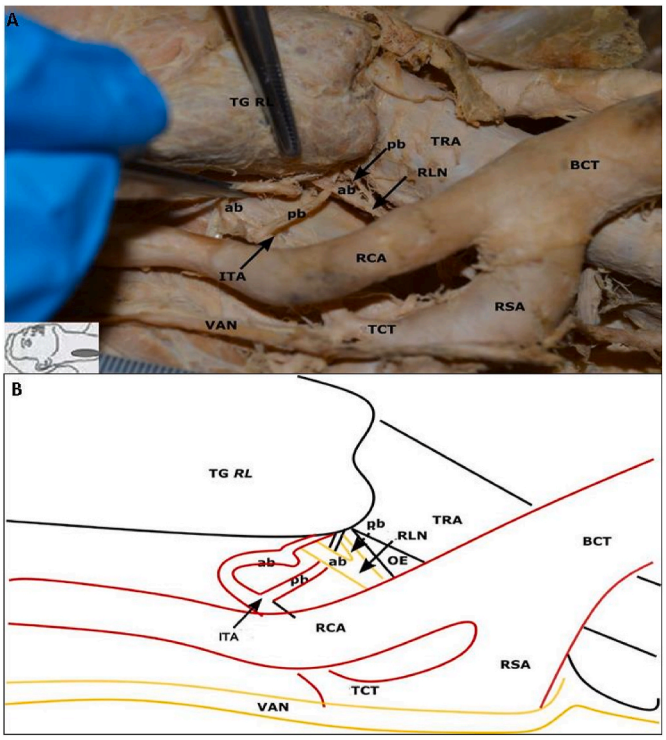

Fig. 4. The images (**A, B**) show the RLN coursing in between the branches of the ITA on the right side. **A.** Dissection photograph; **B**. Line drawing. Abbreviations RLN, right recurrent laryngeal nerve; ab, anterior branch of RLN; pb, posterior branch of the RLN; ITA inferior thyroid artery; ab, anterior branch of ITA; pb, posterior branch of the ITA; TG, thyroid gland; RL, right lobe lobe of thyroid gland; TRA, trachea; OE, oesophagus; RCA, right common carotid artery; BCT, brachiocephalic trunk; RSA, right subclavian artery; VAN, vagus nerve.

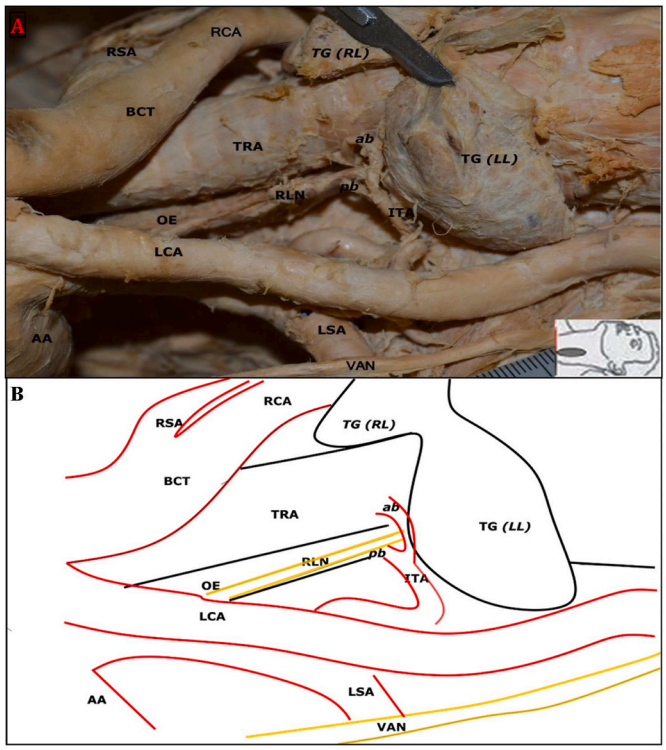

Fig. 5. The images (**A, B**) show the RLN coursing in between the branches of the ITA on the left side. **A**. Dissection photograph; **B.** Line drawing. Abbreviations RLN, left recurrent laryngeal nerve; ITA left inferior thyroid artery; ab, anterior branch of RLN; pb, posterior branch of the ITA; TG, thyroid gland; RL, right lobe of thyroid gland; LL, left lobe of thyroid gland; TRA, trachea; OE, oesophagus; LCA, left common carotid artery; BCT, brachiocephalic trunk; RSA, right subclavian artery; LSA, left subclavian artery; AA, aortic arch; VAN, vagus nerve; RCA, right common carotid artery.

3.5. Surgical cohort

3.5.1. Anatomical relationship of the recurrent laryngeal nerve with the inferior thyroid artery

Only 63 % (38 of the 60 nerves; Table 2) of the of RLNs in the surgical sample could be visualized on account of obstructive pathological masses as compared to 98 % of nerves in the cadaveric sample. All RLNs recurred. The majority of RLN on the right side (79 %) were posterior to the ITA, 21.0 % anterior and none in between its branches. The anatomical relationship of the RLN to the ITA on the left were posterior 73.7 %, in-between the branches 5.3 % and anterior 21.1 %.

3.5.2. Extra-laryngeal branching of the recurrent laryngeal nerve

Extra-laryngeal branching of the RLN was recorded in 9.52 % on the left compared to 15 % on the right side in participants that had thyroidectomy. No symmetrical branching was observed. The difference in the pattern of extra-laryngeal branching of the RLN on the left versus right side was not statistically significant.

Table 5
The relationship between recurrent laryngeal nerves and the inferior thyroid artery in males and females given in percentages.

Variables	Anterior	Posterior	In-between	Total
	N (%)	N (%)	N (%)	N (%)
Females				
Left	9 (36.0 %)	3 (12.0 %)	13 (26.0 %)	25 (100 %)
Right	7 (28.0 %)	10 (40.0 %)	8 (32.0 %)	25 (100 %)
Total	16 (32.0 %)	13 (26.0 %)	21 (42.0 %)	50 (100 %)
Males				
Left	12 (50.0 %)	2 (8.33 %)	10 (41.67 %)	24 (100 %)
Right	5 (20.83 %)	14 (58.33 %)	5 (20.83 %)	24 (100 %)
Total	17 (35.42 %)	16 (33.33 %)	15 (31.25 %)	48 (100 %)
Total				
Left	21 (41.86 %)	5 (10.2 %)	23 (46.94 %)	49 (100 %)
Right	12 (24.49 %)	24 (48.98 %)	13 (26.53 %)	49 (100 %)
Total	33 (33.67 %)	29 (29.59 %)	36 (36.73 %)	98 (100 %)

4. Discussion

This investigation described the topographical anatomy of the RLN in a cohort of formalin fixed cadavers and surgical patients undergoing thyroidectomies in a South African population. This is especially important as tissue changes are known to occur during the process of tissue preservation using formaldehyde. The inclusion of an ethnically diverse sample was used to explore whether variations in anatomy could be observed between two of the major South African populations.

The majority (70.4 %) of RLNs that ran within 15° of the TEG were on the left side, which is not consistent with previous findings by Henry et al. [17] in a meta-analysis that examined 5970 nerves and showed that there is a similar distribution of RLN in the TEG irrespective of side or ancestry (62.1 % - right; 68.0 % - left and on the overall 63.7 %). This result is however similar to the findings by Kiluba et al. [35] in a study of formalin fixed paediatric cadavers. The population affinity of this paediatric sample was however not specified. Symmetry (which refers to the proportion of nerves that have an identical, bilateral course in the TEG) of 20 % was found in the current study which is considerably less when compared to the pooled prevalence of 61.1 % reported by Henry et al. [17]. The TEG would therefore be a less reliable landmark for the identification of the RLN during thyroidectomy compared to other

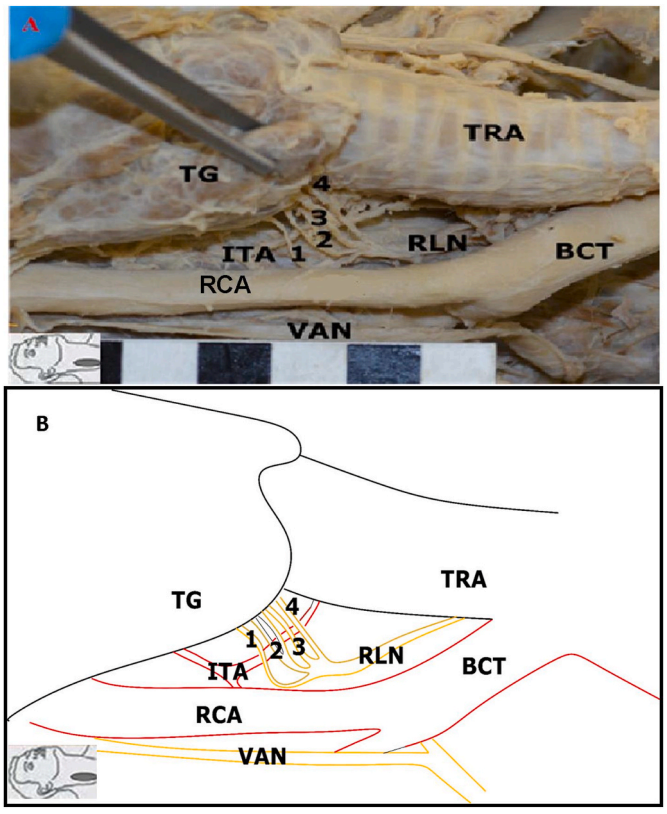

Fig. 6. The images (**A, B**) show the recurrent laryngeal nerve branching into four (4) pre-arterial extra-laryngeal branches before entering the larynx. The branch labelled number 2 further bifurcates outside the larynx. **A.** Dissection photograph. **B.** Line drawing. Abbreviations; TRA, trachea; RLN, recurrent laryngeal nerve; VAN, vagus nerve; TG, thyroid gland; BCT, brachiocephalic trunk; RCA, right common carotid artery; ITA inferior thyroid artery.

commonly used structures such as the ligament of Berry due to its variable anatomy [17].

In the current study, 93.9 % of the RLNs on the left side travelled at an angle less than 15° relative to the TEG, which is consistent with the findings from a study by Lee et al. [40] and Kiluba et al. [35] that demonstrated that 80 % of RLNs on the left side travel at an angle of less than 30° to the TEG. On the right side, 87 % of the RLNs in our study coursed between 0 and 30°. It has been shown that around 50 % of RLNs, irrespective of side or gender, course at an angle within the TEG of less than 30° and this proportion increased to 78.6 % when the nerve was sought in its course between 15 and 45° relative to the TEG [40].

In the present study, gender and sidedness did not influence the diameter of the RLN. A total of 29.6 % of all the RLNs passed posterior to the ITA, which is within the range of 24.9–100 % reported by Ardito et al. [41], Wiseman et al. [42], Uen et al. [43], Henry et al. [3], and Henry et al. [17], Over the past one-hundred years, the relationship between ITA and RLN has been classified into numerous subtypes, with researchers finally settling on the three subtypes which are now widely used and thus also used in this investigation [18]. This classification system denotes the position of the RLN as either coursing anterior, posterior or in between the branches of the ITA [44]. The relationship between RLN and ITA on the right side in the current investigation were anterior (24.5 %), posterior (49.0 %) and in-between (26.5 %) this structure. On the left side, the RLN coursed mainly in-between at 46.9 % and anterior at 42.9 %, with only 10.2 % of nerves coursing posterior to the ITA. These findings are inconsistent with reports by researchers who found that the majority of RLNs passes anterior to the ITA on the right side (37.1 %) versus posterior on the left (62.6 %) [18].

In the surgical cohort herein, the RLN was only seen in 63 % of individuals owing to the complete distortion of the regional anatomy due to neck masses. Visualization and identification of the RLN is advocated for by many authors and is considered a standard procedure to prevent RLN injury [1,4,6,8,41–43]. Although, it has been proven that visualization of the nerve is associated with a reduction in RLN injury, it is not always possible to see or dissect the nerve when resecting a locally invasive lesion in the thyroid gland [8,45]. In this cohort the majority of RLNs coursed posterior to the ITA on both the right and left sides, followed by the anterior course and least in-between the branches of the ITA. These findings correspond with the literature in finding that a posterior course of the RLN to the ITA is most common. Henry et al. [18] concluded that 50.7 % of all RLNs assume a posterior course relative to the ITA. In addition, a review by Ling and Smoll [4] of 32 studies with a total of 8655 nerves, found that 50.95 % of all RLN coursed posterior to the ITA.

Ultimately, the current investigation demonstrated that there was no recognizable pattern in the course of the RLN, consistent with the fact that the anatomy of the nerve is highly variable [6,18]. Variations in the pattern of the RLN between cadaveric and surgical populations reported herein may be due to ancestry differences, since most of the cadaveric cohort consisted of older white individuals while the surgical cohort was mainly from younger black individuals. In the current study, the relationship of the RLN to ITA was symmetrical between 22 % and 44 % of the time. In a meta-analysis of 79 studies, a symmetrical RLN to ITA relationship was observed in less than 37 % of cases [18], which falls within the range of the findings of the current study.

It is generally accepted that the anterior branch of the RLN provides motor innervation whereas the posterior branch provides sensory innervation to the larynx [8]. Extra-laryngeal branching of the RLN is a recognized phenomenon which is sub-classified into four types: pre-arterial, arterial, post-arterial and pre-laryngeal [46]. In most cases, branching happens 1–2 cm from the site where RLN enters the larynx as reported by Henry et al. [3] in a meta-analysis of 28 387 RLNs. In our study, 61 % of RLN in the cadaveric population demonstrated extra-laryngeal branching while in the surgical cohort the extra-laryngeal branching rate was only 9.5 %. This could once again be due to differences in the sample age and ancestry and or difficulty in visualization of the nerve and branches during surgery. Gurleyik [46] also reported a high rate of extra-laryngeal branching in cadavers as compared to thyroidectomy cases. The finding of high prevalence of extra-laryngeal branching of RLN in cadavers is within the range of 43%–78 % of the prevalence of extra-laryngeal branching reported by Thompson et al. (1973). Ardito et al. [41] analysed 2626 RLNs and reported a similar bifurcation rate of 70.6 % happening at 0.6cm–4.0 cm distance prior to entering the larynx. Henry et al. [3] in a meta-analysis of 69 studies and 28 387 RLNs showed a 60 % extra-laryngeal branching rate.

In the current study the maximum number of extra-laryngeal branches observed was four. Henry et al. [3] reported that the terminal branching pattern of the RLN can be expected at about 2 cm from the cricothyroid joint and the number of terminal branches ranges from one to six. Similarly, Sun et al. (2002) analysed 100 cadaveric specimens and demonstrated that most of the RLNs branch 10.13 ± 7.19 mm above the inferior pole of the thyroid gland. In addition, Uen et al. [43] showed a similar rate of extra-laryngeal branching showing that it can occur anywhere between 0.5cm and 1.2 cm (average 0.8 cm) from the inferior horn of the thyroid cartilage. Serpell et al. [1] reported that there is more extra-laryngeal branching of the RLN on the right side than the left side. In the same study, symmetrical bilateral bifurcation of the RLN was observed in only 8.9 % of 838 nerves examined [1]. Henry et al. [3] reviewed 28387 nerves, and described a wide range of extra-laryngeal branching of 5%–100 % with a bilateral symmetrical branching of 36.5 %. Bifurcation, trifurcation and more than three branches were observed in 51.1 %, 4.7 % and 2.2 % respectively. Prades et al. [2] reported higher rates of extra-laryngeal branching of the RLN including bifurcation (88 %), trifurcation (12 %) and greater than 3 branches (0.2

%). The point at which branching takes place creates a vulnerable area of the RLN [8].

This study is of immense clinical significance to the surgeons as it shows that there is nothing like normal anatomy of the RLN, extra-laryngeal branching is common and that anatomical findings on one side should not be used to guide dissection of the contralateral side. Although a lot is written on the variable number and anatomical positions of the parathyroid gland, variation of topographical relationships of RLN and existence of extra-laryngeal branching is not emphasized in the surgical literature. Surgeons regard anatomy and topographical relationships of the RLN uniform and symmetrical. Although extremely rare, non-recurrent laryngeal nerve is virtually the only anatomical variation that is emphasized to surgeons during training. Surgeons will appreciate that there is no consistent and supremely reliable landmark for initial identification of the RLN. The topographical relationship of RLN with the TEG or ITA varies and is not always reliable. It is therefore not advisable for a surgeon to rely on a single landmark and approach for initial identification of RLN while performing thyroidectomy. That the RLN may give off more than two extra-laryngeal branching is significant since some of the branches may be damaged unknowingly, if a surgeon is only aware of the anterior and posterior branches. Some patients develop transient or permanent RLN injury even when the RLN remained intact during thyroidectomy. The surprising postoperative RLN dysfunction may not always be due to traction injury but caused by damage to branches that were not identified. It is therefore recommended that all surgeons performing thyroidotomies must expose, visualise and trace the RLN throughout its entire extra-laryngeal course.

5. Conclusion

The RLN showed a variable anatomy with minimal symmetry between the right and left sides. The observations on one side may not be representative of the other side, hence it is imperative to monitor the RLN on both sides when performing bilateral surgery of the neck and or total thyroidectomy. Irrespective of age, gender and side, the RLN coursed in-between the branches of the ITA in most cases. The majority of RLNs on the left side coursed in the TEG while on the right side the nerve deviated from the TEG at an angle ranging between 0º - 30º. Most of the RLNs give at least two or more extra-laryngeal branches bilaterally, with a maximum of four branches reported in this investigation. RLN remains vulnerable to iatrogenic injuries due to its poor visualization during. Invasion by pathological masses make the identification of the nerve, its branches and the course difficulty. The understanding of these anatomical variations will assist surgeons during intraoperative nerve monitoring and reduce the risk of iatrogenic injuries to the RLN.

6. Study limitations

The greatest limitation of the current investigation is its small sample size distribution which limits the depth of inferences that can be drawn for the side, gender or population affinity differences. Additionally, none of the authors of this study were blinded to the sample demographics which may have introduced a degree of bias in the conclusions drawn in this study.

Funding

This research did not receive any specific grant from funding agencies in the public, commercial, or not-for-profit sectors.

Ethical statements

Ethical clearance for the cadaveric dissection was covered under the Human Tissue Act No. 65 of 1983 and the National Health Act No. 61 of 2003 reference number (W-CJ-140604-1) obtained from the University of the Witwatersrand. Ethical clearance for the collection of data on candidates undergoing thyroidectomies was granted by the Human Research Ethics Committee (Medical) at the University of the Witwatersrand (M160664). The data collection procedures used in the current study did not interfere or delay any of the patient's therapeutic procedures.

Funding statement

The current study received NO funding from any funding agent.

CRediT authorship contribution statement

Joshua BL. Kiluba: Writing – original draft, Visualization, Methodology, Investigation, Formal analysis, Data curation. **Candice Small:** Writing – review & editing, Writing – original draft, Validation, Supervision, Methodology, Investigation, Formal analysis, Data curation, Conceptualization. **Ifongo Bombil:** Writing – original draft, Visualization, Validation, Methodology, Formal analysis, Data curation. **Kasonga Paul Bulabula:** Writing – original draft, Visualization, Validation, Methodology, Investigation, Formal analysis, Data curation. **Thifhelimbilu Emmanuel Luvhengo:** Writing – review & editing, Validation, Supervision, Methodology, Formal analysis, Data curation, Conceptualization. **Pedzisai Mazengenya:** Writing – review & editing, Writing – original draft, Validation, Supervision, Investigation, Formal analysis, Data curation, Conceptualization.

Declaration of competing interest

The authors declare that they have no known competing financial interests or personal relationships that could have appeared to influence the work reported in this paper.

Acknowledgements

The authors would like to thank the patients who granted us the opportunity to investigate the RLN during surgery and the school of Anatomical Sciences at the University of the Witwatersrand for granting access to cadaveric specimens. Special thanks go to Drs Eloise Miller and Claire Mitchell for their assistance with the data collection process during surgery.

References

[1] J.W. Serpell, M.J. Yeung, S. Grodski, The motor fibers of the recurrent laryngeal nerve are located in the anterior extralaryngeal branch, Ann. Surg. 249 (2009) 648–652, https://doi.org/10.1097/SLA.0b013e31819ed9a4.
[2] J.M. Prades, M.D. Dubois, J.M. Dumollard, L. Tordella, J. Rigail, A.P. Timoshenko, M. Peoch, Morphological and functional asymmetry of the human recurrent laryngeal nerve, Surg. Radiol. Anat. 34 (2012) 903–908, https://doi.org/10.1007/s00276-012-0999-7.
[3] B.M. Henry, J. Vikse, M.J. Graves, S. Sanna, B. Sanna, I.M. Tomaszewska, R. S. Tubbs, K.A. Tomaszewski, Extralaryngeal branching of the recurrent laryngeal nerve: a meta-analysis of 28,387 nerves, Langenbeck's Arch. Surg. 401 (2016) 913–923, https://doi.org/10.1007/s00423-016-1455-7.
[4] X.Y. Ling, N.R. Smoll, A systematic review of variations of the recurrent laryngeal nerve, Clin. Anat. 29 (2016) 104–110, https://doi.org/10.1002/ca.22613.
[5] H. Wagner, C. Seiler, Recurrent laryngeal nerve palsy after thyroid gland surgery, Br. J. Surg. 81 (1994) 226–228.
[6] S.-Q. Sun, J. Zhao, H. Lu, G.-Q. He, J.-H. Ran, X.-H. Peng, An anatomical study of the recurrent laryngeal nerve: its branching patterns and relationship to the inferior thyroid artery, Surg. Radiol. Anat. 23 (2002) 363–369.
[7] F.Y. Chiang, L.F. Wang, Y.F. Huang, K.W. Lee, W.R. Kuo, Recurrent laryngeal nerve palsy after thyroidectomy with routine identification of the recurrent laryngeal nerve, Surgery 137 (2005) 342–347, https://doi.org/10.1016/j.surg.2004.09.008.
[8] F.Y. Chiang, I.C. Lu, W.R. Kuo, K.W. Lee, N.C. Chang, C.W. Wu, The mechanism of recurrent laryngeal nerve injury during thyroid surgery—the application of intraoperative neuromonitoring, Surgery 143 (2008) 743–749, https://doi.org/10.1016/j.surg.2008.02.006.
[9] H. Dralle, C. Sekulla, K. Lorenz, M. Brauckhoff, A. Machens, I.S.G. German, Intraoperative monitoring of the recurrent laryngeal nerve in thyroid surgery, World J. Surg. 32 (2008) 1358–1366, https://doi.org/10.1007/s00268-008-9483-2.

[10] P.G. Calo, F. Medas, E. Erdas, M.R. Pittau, R. Demontis, G. Pisano, A. Nicolosi, Role of intraoperative neuromonitoring of recurrent laryngeal nerves in the outcomes of surgery for thyroid cancer, Int. J. Surg. 12 (2014) S213–S217, https://doi.org/10.1016/j.ijsu.2014.05.003.
[11] R. Schneider, G.W. Randolph, M. Barczynski, G. Dionigi, C.W. Wu, F.Y. Chiang, A. Machens, D. Kamani, H. Dralle, Continuous intraoperative neural monitoring of the recurrent nerves in thyroid surgery: a quantum leap in technology, Gland Surg. 5 (2016) 607–616.
[12] C.K. Stefanou, G. Papathanakos, S.K. Stefanou, K. Tepelenis, A. Kitsouli, A. Barbouti, S. Flindris, P. Tsoumanis, P. Kanavaros, P. Kitsoulis, Thyroid surgery during the COVID-19 pandemic: difficulties–how to improve. Innov, Surg. Sci. 7 (2022) 125–132, https://doi.org/10.1515/iss-2022-0015.
[13] S.M. Alqahtani, H.R. Al-Sohabi, M.F. Rayzah, A.S. Alalawi, A.A. Alfattani, Y. S. Alalawi, Recurrent laryngeal nerve injury after thyroidectomy: a national study from Saudi Arabia, Saudi Med. J. 44 (2023) 80–84, https://doi.org/10.15537/2Fsmj.2023.44.1.20220710.
[14] I. Wong, D.K.H. Tong, R.K.Y. Tsang, C.L.Y. Wong, D.K.K. Chan, F.S.Y. Chan, S. Law, Continuous intraoperative vagus nerve stimulation for monitoring of recurrent laryngeal nerve during minimally invasive esophagectomy, J. Vis. Surg. 3 (2017) 3–9, https://doi.org/10.21037/jovs.2016.12.11.
[15] S. Mantalovas, K. Sapalidis, V. Manaki, V. Magra, S. Laskou, S. Pantea, V. Lagopoulos, I. Kasisoglou, Surgical significance of Berry's posterolateral ligament and frequency of recurrent laryngeal nerve injury into the last 2 cm of its caudal extralaryngeal part (P1) during thyroidectomy, Medicina 58 (2022) 755, https://doi.org/10.3390/medicina58060755.
[16] H. Dralle, C. Sekulla, J. Haerting, W. Timmermann, H.J. Neumann, E. Kruse, S. Grond, H.P. Muhlig, C. Richter, J. Voss, O. Thomusch, H. Lippert, I. Gastinger, M. Brauckhoff, O. Gimm, Risk factors of paralysis and functional outcome after recurrent laryngeal nerve monitoring in thyroid surgery, Surgery 136 (2004) 1310–1322, https://doi.org/10.1016/j.surg.2004.07.018.
[17] B.M. Henry, B. Sanna, M.J. Graves, S. Sanna, J. Vikse, I.M. Tomaszewska, R. S. Tubbs, K.A. Tomaszewski, The reliability of the tracheoesophageal groove and the ligament of Berry as landmarks for identifying the recurrent laryngeal nerve: a cadaveric study and meta-analysis, BioMed Res. Int. 2017 (2017) 4357591, https://doi.org/10.1155/2017/4357591.
[18] B.M. Henry, J. Vikse, M.J. Graves, S. Sanna, B. Sanna, I.M. Tomaszewska, W. C. Hsieh, R.S. Tubbs, K.A. Tomaszewski, Variable relationship of the recurrent laryngeal nerve to the inferior thyroid artery: a meta-analysis and surgical implications, Head Neck 39 (2017) 177–186, https://doi.org/10.1002/hed.24582.
[19] A. Patra, A. Asghar, P. Chaudhary, K.S. Ravi, Identification of valid anatomical landmarks to locate and protect recurrent laryngeal nerve during thyroid surgery: a cadaveric study, Surg. Radiol. Anat. 45 (2023) 73–80, https://doi.org/10.1007/s00276-022-03054-y.
[20] C.R. Cernea, F.C. Hojaij, D. De Carlucci, R. Gotoda, C. Plopper, F. Vanderlei, L. G. Brandao, Recurrent laryngeal nerve: a plexus rather than a nerve? Arch, Otolaryngol. Head Neck Surg. 135 (2009) 1098–1102, https://doi.org/10.1001/archoto.2009.151.
[21] R. Dolezel, J. Jarosek, L. Hana, M. Ryska, Clinical relevance and surgical anatomy of non-recurrent laryngeal nerve: 7 year experience, Surg. Radiol. Anat. 37 (2015) 321–325, https://doi.org/10.1007/s00276-014-1369-4.
[22] G.S. Gopi, S. Sarkar, A. Nayak, Extra-laryngeal branching of recurrent laryngeal nerve: a possibility thyroid surgeons need to keep in mind to prevent inadvertent nerve injury, BMJ Case Rep. 12 (2019) e231305, https://doi.org/10.1136/bcr-2019-231305.
[23] A.M. Thomas, D.K. Fahim, J.M. Gemechu, Anatomical variations of the recurrent laryngeal nerve and implications for injury prevention during surgical procedures of the neck, Diagnostics 10 (2020) 670, https://doi.org/10.3390/diagnostics10090670.
[24] P. Krishnan, M. Santosh, An atypical bilateral trifurcation of recurrent laryngeal nerve, BMC Surg. 22 (2022) 176, https://doi.org/10.1186/s12893-022-01624-w.
[25] Q.V. Le, D.Q. Ngo, Q.X. Ngo, Non-recurrent laryngeal nerve in thyroid surgery: a report of case series in Vietnam and literature review, Int. J. Surg. Case Rep. 50 (2018) 56–59, https://doi.org/10.1016/j.ijscr.2018.07.017.
[26] G.R. Joliat, V. Guarnero, N. Demartines, V. Schweizer, M. Matter, Recurrent laryngeal nerve injury after thyroid and parathyroid surgery: incidence and postoperative evolution assessment, Medicine 96 (2017) e6674, https://doi.org/10.1097/MD.0000000000006674.
[27] X. Liu, D. Zhang, G. Zhang, L. Zhao, L. Zhou, Y. Fu, S. Li, Y. Zhao, C. Li, C.W. Wu, F. Y. Chiang, G. Dionigi, H. Sun, Laryngeal nerve morbidity in 1.273 central node dissections for thyroid cancer, Surg. Oncol. 27 (2018) A21–A25, https://doi.org/10.1016/j.suronc.2018.01.003.
[28] M. Pelizzo, Difficult thyroidectomies, J.Italian Surg. Ass. 36 (2015) 49–56.
[29] R.K.A. Fiorelli, A.J.V. Duarte, A. De Quadros Teixeira, P.E.P. Filho, M.R.S. Morard, A.M. Da Silva Ascencao, C.A.B. Oliveira, P. Novellino, Anatomical and developmental aspects of iatrogenic injury to the right recurrent laryngeal nerve in surgical resections of substernal goiter, Anat. Rec. 304 (2021) 1242–1254, https://doi.org/10.1002/ar.24629.
[30] A. Hauch, Z. Al-Qurayshi, G. Randolph, E. Kandil, The importance of surgical volume on outcomes in thyroid surgery revisited: old is in again: editorial response to "what's old is new again" by Julie Ann Sosa (doi: 10.1245/s10434-014-3850-z), Ann. Surg Oncol. 21 (2014) 3721–3722, https://doi.org/10.1245/s10434-014-3993-y.
[31] H.S. Na, H.K. Kwon, S.C. Shin, Y.I. Cheon, M. Seo, J.C. Lee, E.S. Sung, M. Lee, I. J. Kim, B.H. Kim, B.J. Lee, Clinical outcomes of T4a papillary thyroid cancer with recurrent laryngeal nerve involvement: a retrospective analysis, Sci. Rep. 11 (2021) 6707, https://doi.org/10.1038/s41598-021-86226-x.
[32] E. Gurleyik, Two cases of enlarged Zuckerkandl's tubercle of the thyroid displacing the recurrent laryngeal nerve laterally, Case Rep. Med. 1 (2011) 303861, https://doi.org/10.1155/2011/303861.
[33] R. Moorthy, A. Balfour, J.P. Jeannon, R. Simo, Recurrent laryngeal nerve palsy in benign thyroid disease: can surgery make a difference? Eur. Arch. Oto-Rhino-Laryngol. 269 (2012) 983–987, https://doi.org/10.1007/s00405-011-1711-y.
[34] A. Elgahani, I. Bombil, R. Muganza, Thyroidectomy at Chris Hani Baragwanath Academic Hospital: is routine admission to intensive care unit justified? Indian J. Med. Res. Parm. Sci. 6 (2021) 6–11, https://doi.org/10.29121/ijmrps.v7.i10.2020.2.
[35] J.B.L. Kiluba, C. Small, T.E. Luvhengo, P. Mazengenya, A topographical description of the recurrent laryngeal nerve in paediatric cadavers, S. Afr. J. Surg. 60 (2022) S50–S54, https://doi.org/10.17159/2078-5151/SAJS3718.
[36] E. Hohmann, N. Keough, V. Glatt, K. Tetsworth, P. Putz, A. Imhoff, The mechanical properties of fresh versus fresh/frozen and preserved (Thiel and Formalin) long head of biceps tendons: a cadaveric investigation, Ann. Anat. 221 (2019) 186–191, https://doi.org/10.1016/j.aanat.2018.05.002.
[37] A. Rajabian, M. Walsh, N.A. Quraishi, Right-versus left-sided exposures of the recurrent laryngeal nerve and considerations of cervical spinal surgical corridor: a fresh-cadaveric surgical anatomy of RLN pertinent to spine, Spine 45 (2020) 10–17, https://doi.org/10.1097/BRS.0000000000003204.
[38] J. Kieser, J. Allan, Practical Anatomy, Witwatersrand University Press, Johannesburg, 2001.
[39] R.M. Zollinger, E.C. Essison, Thyroidectomy' in Zollinger's Atlas of Surgical Operations, McGraw Hill/Medical, 2016, pp. 402–403.
[40] M.S. Lee, U.Y. Lee, J.H. Lee, S.H. Han, Relative direction and position of recurrent laryngeal nerve for anatomical configuration, Surg. Radiol. Anat. 31 (2009) 649–655, https://doi.org/10.1007/s00276-009-0494-y.
[41] G. Ardito, L. Revelli, L. D'alatri, V. Lerro, M.L. Guidi, F. Ardito, Revisited anatomy of the recurrent laryngeal nerves, Am. J. Surg. 187 (2004) 249–253, https://doi.org/10.1016/j.amjsurg.2003.11.001.
[42] S.M. Wiseman, P.I. Tomljanovich, N.R. Rigual, Thyroid lobectomy: operative anatomy, technique, and morbidity. Operative Techniques in Otolaryngology, Otolaryngol. Head Neck Surg. 15 (2004) 210–219, https://doi.org/10.1016/j.otot.2004.07.008.
[43] Y.-H. Uen, T.-H. Chen, J.-F. Shyu, Y.-M. Shyr, C.-H. Su, J.-Y. Chen, C.-S. Lee, J.-C. Liu, Surgical anatomy of the recurrent laryngeal nerves and its clinical applications in Chinese adults, Surg. Today 36 (2006) 312–315, https://doi.org/10.1007/s00595-005-3151-z.
[44] B.M. Henry, P.A. Pekala, B. Sanna, J. Vikse, S. Sanna, K. Saganiak, I. M. Tomaszewska, R.S. Tubbs, K.A. Tomaszewski, The anastomoses of the recurrent laryngeal nerve in the larynx: a meta-analysis and systematic review, J. Voice 31 (2017) 495–503, https://doi.org/10.1016/j.jvoice.2016.11.004.
[45] D. Casal, A. Pecas, D. Sousa, J. Rosa-Santos, A non-recurrent inferior laryngeal nerve in a man undergoing thyroidectomy: a case report, J. Med. Case Rep. 4 (2010) 1–3.
[46] E. Gurleyik, Extralaryngeal terminal division of the inferior laryngeal nerve: anatomical classification by a surgical point of view, J. Thyroid Res. 1 (2013) 731250, https://doi.org/10.1155/2013/731250.