

UNIVERSITY OF WITWATERSRAND

# An Evaluation of Orbital Exenteration at St. John Eye Hospital

---

*Dr P. Raman-Abdulla*

*MBBCh (Wits), Dip Ophth (SA), FCOphth(SA)*

*A dissertation submitted to the Faculty of Health Sciences, University of the Witwatersrand,  
Johannesburg, in fulfillment of the requirements for the degree of Master of Medicine in  
Ophthalmology*

## TABLE OF CONTENTS

DECLARATION	5
ABSTRACT	6
ACKNOWLEDGMENTS	8
PERSONAL CONTRIBUTIONS	9
LIST OF FIGURES	10
LIST OF TABLES	11
LIST OF ABBREVIATIONS	12
CHAPTER 1.	13
1.1) INTRODUCTION	13
1.2) LITERATURE REVIEW	14
1.3) RESEARCH AIM	17
1.4.) RESEARCH QUESTIONS	17
1.5) RESEARCH OBJECTIVES	17
1.6) OUTCOME MEASURES	17
<b>CHAPTER 2.</b>	17

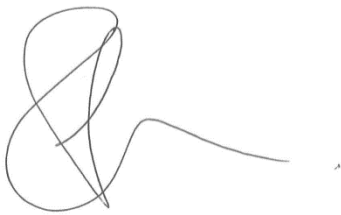
2.1)	STUDY DESIGN	18
2.2)	DATA COLLECTION	18
2.3)	INCLUSION CRITERIA	18
2.4)	EXCLUSION CRITERIA	18
2.5)	DATA MANAGEMENT	19
	- Number of cases per annum	19
	-Age	19
	-Laterality	19
	-The type of orbital exenteration	19
	- Indication for surgery	19
	-Tissue of origin	19
	- Histological diagnosis	19
	- Histological grade	19
	-Staging	20
	- Tumour-free resection margin	20
	- HIV status	20
2.6)	DATA ANALYSIS	21
2.7)	LIMITATIONS	21
2.8)	STAFF AND ADMINISTRATION	21
2.9)	ETHICAL CONSIDERATIONS	21

<b>CHAPTER 3.</b>	22
3.1) TOTAL NUMBER OF CASES EXENTERATED	22
3.2) AGE AT TIME OF SURGERY	24
3.3) SEX	24
3.4) LATERALITY	24
3.5) TYPE OF PROCEDURE PERFORMED	25
3.6) INDICATION FOR ORBITAL EXENTERATION	26
3.7) TISSUE OF ORIGIN	27
3.8) HISTOLOGICAL DIAGNOSIS	28
3.9) HISTOLOGICAL GRADE	29
3.10) TUMOUR STAGING	30
3.11) COMPLETENESS OF EXCISION	31
3.12.) RETROVIRAL STATUS	32
<b>CHAPTER 4</b>	33
4.1) DISCUSSION	33
4.2) CONCLUSION	43

REFERENCES	45
APPENDIX A. HUMAN RESEARCH ETHICS COMMITTEE (MEDICAL) CLEARANCE CERTIFICATE	48
APPENDIX B. PATHOLOGICAL CLASSIFICATION ( pTNM ): CONJUNCTIVAL CARCINOMA	49
APPENDIX C. HISTOPATHOLOGICAL GRADE: REPRESENTS THE PRIMARY TUMOUR	50

## DECLARATION

I, Dr Raman-Abdulla declare that this dissertation is my own work and is being submitted for the degree of Master of Medicine in the branch of Ophthalmology at the University of the Witwatersrand, Johannesburg. This work has not been submitted before for any degree or examination at this or any other University.

A handwritten signature in black ink, consisting of a large, stylized initial 'R' followed by a long, horizontal tail.

Signed

1<sup>st</sup> October 2016

This study was conducted out at St. John Eye Hospital, Chris Hani Baragwanath Academic Hospital.

Permission to carry out the study was obtained by the Human Ethics Committee (Medical), University of the Witwatersrand (Appendix A).

## **ABSTRACT**

Orbital exenteration is a surgical procedure used in the management of advanced malignant disease. It is used to treat both invasive and recurrent orbital tumours. This disfiguring surgical procedure involves removal of orbital contents, including the periorbita, eyelids and sometimes varying amounts of the surrounding peri-orbital skin. Studies from developing countries have shown that Squamous Cell Carcinoma (SCC) is the predominant indication for orbital exenteration. The high prevalence of conjunctival SCC in Sub-Saharan African has a strong link to ultraviolet radiation, Human Immunodeficiency Virus infection (HIV) and Human Papilloma Virus (HPV) infection. As the burden of disease increases, it becomes crucial for clinicians in Africa and other developing countries to understand how these Tumours' behave, and how HIV potentially impacts on the disease. Such an evaluation may potentially benefit current management strategies. Furthermore, the need to effectively and appropriately manage such a neoplastic burden in a developing world setting with limited resources is of fundamental importance. This study reports an experience of orbital exenteration at this institution.

**OBJECTIVES:** Firstly to describe all orbital tumours exenterated at St. John Eye Hospital over a four year period in terms of histopathology, tumour behaviour and completeness of excision. Secondly to determine if a link to HIV infection exists.

**DESIGN AND METHOD:** A retrospective analysis of electronic records from the National Health Laboratory System (NHLS) was conducted on all the patients who underwent an orbital exenteration at St. John Eye Hospital from the 1<sup>st</sup> of July 2008 to 30<sup>th</sup> of June 2012

**RESULTS:** The total number of patients who underwent an orbital exenteration in the stated time period was 84. Twenty eight patients were excluded from the study and the final sample size was therefore 56.

The average age of presentation was 42 and the overall female to male ratio was 1:1.07. Four patients underwent a lid sparing procedure while the remaining 52 patients had a total exenteration. The tissue of origin was conjunctival in 75% of cases. The most frequent presenting complaint and indication for surgery was an invasive conjunctival tumour in 56% of patients, followed by a gross orbital tumour in 27% of patients. Squamous cell carcinoma of the conjunctiva was the most frequently diagnosed tumour. Out of 56 specimens, 51(91.06%) were of the squamous cell type, 1.79% High Grade Squamous Dysplasia, 3.57% Leiomyosarcoma, 1.79% Metastatic Breast Adenocarcinoma and 1.79% Spindle Cell Melanoma.

Histological grading of all specimens showed 69.64% of these tumours were moderately differentiated, 21.43% poorly differentiated and 8.93% were unknown.

The distribution of the tumour staging in the sample group, according to the TNM Classification was as follows, 51.79%- Stage 4, 19.64% -Stage 3, 10.71%-Stage 2, 1.79% Stage 1, 1.79% Stage Tumour In Situ and 14.28% unknown.

Regarding completeness of excision, 53.57% of tumours had positive tumour margins and 42.86% showed complete excision with clear margins, 3.57% were unknown. Only 28(50%) patients had a HIV result on electronic record. CD4 counts were available for 23 out of the 28 patients.



## ACKNOWLEDGEMENTS

1. Professor G. McLaren, my supervisor, for his expertise and insight into this study. I am grateful for your guidance and support throughout this project.
2. Professor Carmichael for his invaluable advice and interest in this study.
3. Prof Hale from the Department of Anatomical Pathology for his support and assistance with the data collection process from the National Health Laboratory System.
4. Dr. Gaylard for her expertise and assistance with all aspects of the statistical analysis. Thank you for being so patient and for your attention to the details.
5. Dr. Goolam for her assistance in writing up my thesis and keeping me motivated throughout the process.
6. The theatre staff at St. John Eye Hospital for their assistance in accessing the theatre records.

## **PERSONAL CONTRIBUTIONS**

All data collection both from theatre, and electronic records was undertaken by myself at St John's Eye Hospital (Chris Hani Baragwanath Academic Hospital.)

Data preparation was performed using Microsoft Excel 2007. Statistical analysis and subsequent review was done by Dr Petra Gaylard.

## LIST OF FIGURES

Figure 1.	The distribution of exenteration patients over the 4 year study period	22
Figure 2.	Clinical indication for performing surgery, expressed as a percentage of all tumours analysed in the study group	26
Figure 3.	Tissue of origin of each tumour represented as a percentage of all tumours analysed in study group	27
Figure 4.	Histopathological diagnosis represented as a percentage of all tumours excised in the study group	28
Figure 5.	Histological grade of each tumour represented as a percentage of all tumours analysed in the study group	29
Figure 6.	The staging of each tumour analysed, expressed as a percentage of the total number of cases exenterated in the study group	30
Figure 7.	The completeness of excision of each tumour exenterated expressed as a percentage of total number of tumours exenterated in the study group	31
Figure 8.	HIV blood results of the study group	32

## LIST OF TABLES

Table 1.	Age Distribution	24
----------	------------------	----

## LIST OF ABBREVIATIONS

Acquired Immune Deficiency Syndrome	AIDS
Basal Cell Carcinoma	BCC
Chris Hani Baragwanath Hospital	CHBAH
Enzyme-Linked Immunosorbent Assay	ELISA
Highly Active Antiretroviral Therapy	HAART
Human Immunodeficiency Virus	HIV
Human Papilloma Virus	HPV
National Health Laboratory System	NHLS
Ocular Squamous Cell Carcinoma	OSSN
Sebaceous Gland Carcinoma	SGC
Squamous Cell Carcinoma	SCC
St John's Eye Hospital	SJEH
Systemic Lymph Node	SLN
Tumour, Node, Metastases	TNM
Ultraviolet-light B	UVB
World Health Organization	WHO

## CHAPTER 1

### 1.1) INTRODUCTION

Squamous cell carcinoma (SCC) is the most common malignancy of the conjunctiva in Sub-Saharan Africa and worldwide.<sup>1,2,3</sup> It forms part of a spectrum of disease referred to as Ocular Surface Squamous Cell Neoplasia (OSSN), extending from simple dysplasia, to carcinoma in situ and ultimately to invasive carcinoma.<sup>4,5,6</sup>

Invasive squamous cell carcinoma is distinguished histo-pathologically, by breachment of the epithelial basement membrane and invasion of the stroma by tumour cells.<sup>1, 3</sup> Human Immunodeficiency Virus (HIV) is a well-recognized risk factor for the development of invasive conjunctival SCC. The association was first reported in the early 1990's in sub-Saharan Africa.<sup>4-8</sup> HIV infection increases the risk of SCC 10 fold.<sup>9</sup>

While HIV infection in itself is thought to have oncogenic effects,<sup>9</sup> the high prevalence of conjunctival squamous cell carcinoma in Sub-Saharan Africa is complex and likely to be multifactorial.<sup>1-4, 7, 11, 14</sup> High ultraviolet light-B (UVB) exposure and Human Papilloma Virus (HPV) infection, especially the type 16 and 18 infections are compounding factors involved in the complex carcinogenic process.<sup>2, 3, 5, 7, 9, 11, 14</sup>

P-53 mutations are a form of UVB light induced damage identified with increased frequency in HIV positive patients with conjunctival squamous cell carcinoma. This gene is responsible for a protein thought to play a critical role in tumour suppression and cell cycle control.<sup>5</sup> Presuming HIV and HPV are in fact linked, it may be that HIV infection disrupts the immune system's control over HPV's oncogenic effects.<sup>12</sup> The exact interaction of HIV, sunlight exposure and HPV infection in the tumour's pathogenesis, remains unclear.<sup>6, 7, 12, 14</sup>

As the burden of this and other Acquired Immune Deficiency Syndrome (AIDS) - related neoplasm's increase<sup>2, 6-8, 11, 13</sup> it becomes crucial for clinicians in Africa and other developing countries to understand how these tumours behave, and how HIV potentially impacts on this behaviour. Such an evaluation may potentially benefit current management strategies. Furthermore, the need to effectively and appropriately manage such a neoplastic burden in the context of limited resources is of fundamental importance.

It is in this context that the following study will analyse invasive orbital tumours exenterated at St. John Eye Hospital, looking specifically at the indications for surgery, the invasiveness of the tumour and how HIV infection may be related to these two features.

## **1.2) LITERATURE REVIEW**

The World Health Organization (WHO) estimates that since 1993 there are more than 40 million adults and children living with HIV/AIDS worldwide. Sub-Saharan Africa is home to more than two thirds of all these individuals living with HIV.<sup>6, 11, 14</sup>

This has had a dramatic effect on the profile of cancer and in this, the fourth decade of the pandemic, it is evident that the burden of neoplastic diseases is increasing in developing countries.<sup>6,8,12</sup> Furthermore, in a post-HAART (Highly Active Antiretroviral Therapy) era, the lengthening of life expectancy has also meant an increased risk of developing both AIDS and NON-AIDS defining cancers.<sup>14</sup> The loss of tumour surveillance in HIV infected individuals may be important in the development of cancer. Increased overall survival allows more time for the tumour to evolve and grow.<sup>10</sup>

Squamous cell carcinoma of the conjunctiva is a well-recognized AIDS associated cancer in Sub-Saharan Africa<sup>1-3, 6, 8, 9, 11, 14</sup> with a natural history that is unique to this region.<sup>6, 11, 13, 14</sup>

The increase in the epidemic of conjunctival SCC has furthermore coincided with the HIV epidemic.<sup>9, 11, 13, 14</sup> Almost 80% of patients diagnosed with conjunctival squamous cell

carcinoma are found to be HIV positive<sup>11</sup> and this may be the first presenting manifestation of HIV infection.<sup>5</sup>

In HIV infected individuals conjunctival squamous cell carcinoma is more malignant, aggressive<sup>1, 3, 11</sup> and more likely to metastasize and recur.<sup>3, 7, 11</sup> Furthermore, patients in developing countries tend to present at a younger age, and at more advanced stages of neoplastic disease due to the financial burdens of a low income society.<sup>1-3, 6, 7</sup>

Several studies from Africa revealed that a proportion of these patients with invasive conjunctival squamous cell carcinoma presented for the first time with an orbital mass<sup>1, 3, 6, 7</sup> requiring an orbital exenteration as the primary modality of treatment with or without chemotherapy.<sup>1-3, 6, 7</sup> Furthermore patients undergoing orbital exenteration in developing countries like Africa and India are doing so for neglected advanced ocular surface and peri-orbital malignant disease<sup>1-3, 7, 15, 16</sup>

Studies from tropical regions seem to all show that SCC is the predominant indication for orbital exenteration.<sup>1-3, 6-8, 15, 16</sup> There is some variation from different case studies regarding the indication for surgery and some reports from western populations have found Basal Cell Carcinoma (BCC) to be the major indication for orbital exenteration.<sup>18, 19</sup> A large study conducted in Turkey examined 429 cases found SCC to be the single most common indication for orbital exenteration.<sup>20</sup> Recent studies emerging from the developed world have also reported SCC as the most frequently exenterated tumour.<sup>21</sup>

Orbital Exenteration is a surgical strategy used in the management of advanced malignant disease.<sup>15- 19</sup> It is used to treat both invasive and recurrent orbital masses.<sup>15-18</sup> The surgical procedure involves removal of orbital contents, including the periorbita, eyelids and sometimes varying amounts of the surrounding peri-orbital skin.<sup>15-19</sup> Orbital exenteration may be classified into a total or subtotal procedure, the latter involves preservation of the



eyelids i.e. lid sparing exenteration to yield a cosmetically more acceptable result.<sup>15</sup> Tumour eradication however must always take priority over cosmesis.<sup>19</sup> When clear surgical margins are achieved, the recurrence rate can be as low as 7-10%.<sup>17</sup>

Orbital exenteration is a step in the sequential management plan that includes surgical cure and cosmetic rehabilitation.<sup>15-19</sup> The risk of recurrence is dependent on multiple factors. This includes completeness of surgical excision, the type, stage and aggressiveness of the tumour which, as mentioned may be related to HIV infection.<sup>3, 11, 15, 16, 17</sup> Surgeons fearing recurrence may opt to simply leave the orbit to granulate or delay orbital reconstruction aimed at improving cosmesis with the use of a split skin graft or local flap.<sup>15,17,18</sup> Orbital reconstruction is usually reserved for less advanced tumours and when the surgeon is confident about tissue clearance.<sup>15</sup>

Greater understanding of these factors discussed above, particularly in a setting like St. John Eye Hospital (SJEH) with limited resources, may give the surgeon greater insight into the effectiveness of the current procedure as well as the follow up of these patients once the tumour is excised.<sup>14</sup>

### **1.3) RESEARCH AIM**

This study aimed to describe all orbital tumours exenterated over a four year period at SJEH.

### **1.4) RESEARCH QUESTIONS**

- The following research questions were posed:

-What is the main indication for exenteration of orbital tumours at SJEH?

-Is this surgical procedure effectively removing the tumour?

- The subsequent hypotheses were:

-Squamous cell carcinoma, with a strong association to HIV infection, is primarily the indication for orbital exenteration at SJEH.

-Orbital exenteration is an effective surgical cure.

### **1.5) RESEARCH OBJECTIVES**

- To investigate the histo-pathology of orbital tumours exenterated at SJEH over the stated time period.
- To investigate the aggressiveness of the tumour excised.
- To document the presence of HIV infection in these patients and the degree of immune suppression as reflected by the CD4 count.
- To investigate the completeness of surgical excision of the tumour.

### **1.6) OUTCOME MEASURES**

- Histo-pathological diagnosis of the orbital tumour
- Presence or absence of clear tumour-free surgical margins
- Staging of the tumour
- HIV status and CD4 count

## **CHAPTER 2**

### **2.1) STUDY DESIGN**

A retrospective cross-sectional study was conducted. Electronic records from the National Health Laboratory System (NHLS) were reviewed of all the patients who underwent an orbital exenteration at St. John Eye Hospital (SJEH) from the 1<sup>st</sup> of July 2008 to the 30<sup>th</sup> of June 2012.

### **2.2) DATA COLLECTION**

Data collection commenced upon obtaining ethics approval from the Human Research Ethics Committee (Appendix A) and consent from the Head of Pathology at the University of Witwatersrand, to access and reviews the histo-pathology reports from the NHLS. Consent was granted from the chief executive officer at Chris Hani Baragwanath Academic Hospital (CHBAH) to use the hospitals theatre records at SJEH. Theatre records were used to find the name and hospital number of the patients who underwent surgery in the stated time period and it was this hospital number that was then used to electronically access the histo-pathology reports.

### **2.3) INCLUSION CRITERIA**

All patients who had an orbital exenteration performed at SJEH from the 1<sup>st</sup> of July 2008 to 30<sup>th</sup> of June 2012 with a formal histo-pathology report on record was included in the study.

### **2.4) EXCLUSION CRITERIA**

Any patient who did not have a formal histo-pathology report recorded by the NHLS was excluded from the study.

## 2.5) DATA MANAGEMENT

Data from the records of patients meeting the inclusion criteria for the study were captured on a Microsoft Word Excel spread sheet by the primary researcher. Each patient was allocated a serial number to maintain privacy throughout data analysis. Information regarding all patient names and hospital numbers were available only to the primary researcher. The following information was recorded:

- **NUMBER OF CASES PER ANNUM:** An audit was done of the total number of surgical cases done each year.
- **AGE AND SEX:** The age of the patient at the time of the surgery as recorded in the histopathology report. Gender was assigned as male or female.
- **LATERALITY:** The eye involved by the tumour; either left or right was recorded.
- **THE TYPE OF ORBITAL EXENTERATION:** The procedure was recorded as either a total or lid-sparing exenteration.
- **INDICATION FOR SURGERY:** The type of gross anatomical tumour each patient presented with was recorded. If this was not specified in the patient's report, the data entry was captured as "not specified."
- **TISSUE OF ORIGIN:** The tissue from which tumour cells were seen to arise was recorded. If no comment was recorded in the pathologist's report regarding the tissue of origin, a data entry of "not specified" was recorded.
- **HISTOLOGICAL DIAGNOSIS:** This was recorded as a final assessment of the diseased eye's tissue following histological analysis by the pathologist.
- **HISTOLOGICAL GRADE:** Histological grade or differentiation describes how closely the tumour resembles the tissue of origin. (Appendix C.) This was recorded as well differentiated, moderately differentiated or poorly differentiated. If no comment on

histological grading was included in the report the data entry was captured as “not specified.”

- **STAGING:** The “Tumour, Node, Metastases” (TNM) classification (Appendix B) was used to stage the tumour following histo-pathological analysis. The staging done by the pathologist and included in the histopathology report was restricted to the “T category” only. In keeping with current protocols lymph nodes were not routinely biopsied and sent with the primary excised specimens to the pathologist for analysis. No radiological tests were sent to the pathologist either to assist with comprehensive staging of the tumour. A complete TNM staging could therefore not be done by the pathologist at the time of histological and pathological diagnosis. When lymph nodes in the “N category” could not be assessed, the notation “Nx” was added to the final staging. Similarly when metastases could not be assessed in the “M category” a notation “Mx” was recorded. If the pathologist did not include a comment on staging in the histopathology report, the data entry “not specified” was recorded.
- **TUMOUR-FREE RESECTION MARGINS:** Surgical margins of the tumour were recorded in the histopathology report as being either tumour free or as being involved by the tumour. The latter would imply that the tumour was not completely excised. The data entry for a tumour-free resection margin was entered as either Yes or No.
- **HIV STATUS:** The hospital number of every patient was used to check the electronic NHLS database to determine if an HIV blood test had been performed and its result. The result was recorded as either reactive (positive) or non-reactive (negative). HIV testing is a voluntary process in South Africa and this precluded testing in some instances. If no HIV test record was available, the data entry was captured as “unknown.”

## **2.6) DATA ANALYSIS**

A descriptive analysis of the data was conducted. Continuous variables were described using the mean, median, standard deviation, and an interquartile range, while categorical variables were described by their frequency distributions.

## **2.7) LIMITATIONS**

The retrospective nature of the study meant that data collection was limited by the availability of information in each patient's electronic record. Furthermore, since HIV testing was a voluntary procedure and by some patients refusing testing, the number of HIV infected patients undergoing orbital exenteration may have been underestimated. Another limitation is that the TNM staging could not be assessed accurately due to the limited availability of data.

## **2.8) STAFF AND ADMINISTRATION**

The study was conducted by Dr P.Y Raman (Ophthalmology registrar) and supervised by Prof. GD McLaren (Head of Department at St John Eye Hospital).

## **2.9) ETHICAL CONSIDERATIONS**

The protocol was submitted to the Wits Human Research Ethics Committee and upon review a clearance certificate was received. (Appendix A).

Patient confidentiality regarding all patients' names, hospital numbers, blood results and histopathology reports, was maintained throughout data collection and analysis by allocation of a serial number to each patient. Only this serial number was used during data capture.

## CHAPTER 3

### 3.1) TOTAL NUMBER OF CASES EXENTERATED CASES

The total number of patients who underwent an orbital exenteration in the stated time period was 84 cases. The fewest cases (17) were recorded in year 1 (1 July 2008-30 June 2009) and the most cases (25) were recorded in year 4 (1 July 2011- 30 June 2012).

The total number of cases performed each year in the stated 4 year period is illustrated in Figure 1.

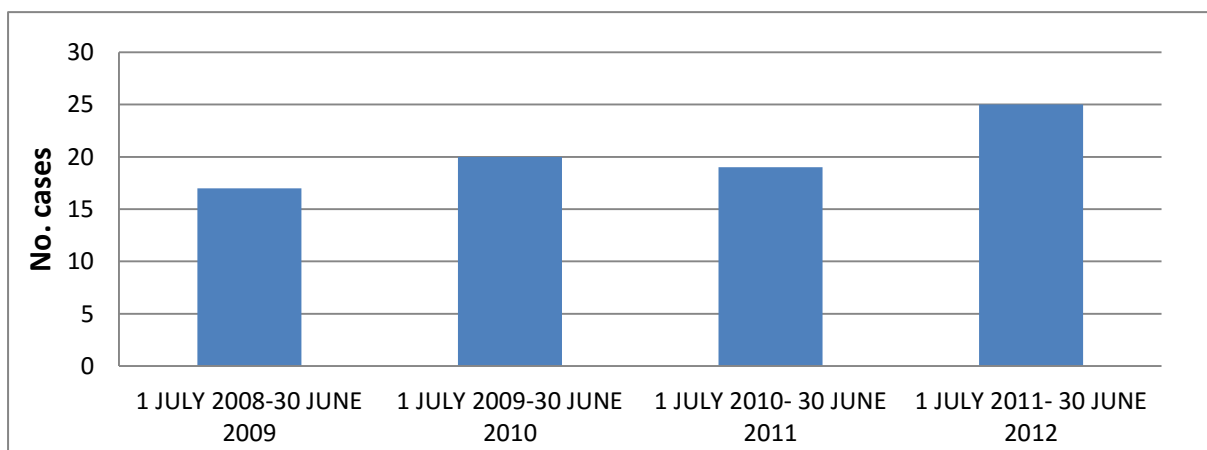


Figure 1. The distribution of orbital exenteration patients over the 4 year study period

56 of the 84 patients had complete data. Every patient in the study had only one eye involved by the disease process.

If large amounts of relevant data were missing or if there was no electronic information recorded on the NHLS database for a patient, the patient was excluded from the study. This was a standardized process applied without bias to any patient record obtained from SJEH theatre book in the stated time period. When electronic records were inadequate or not found, the hard copy of that patient's file was not used. The reason for this is that many patients at

SJEH take their files home with them or lose their files along the course of their follow up, leaving the filing system in the hospital inevitably incomplete and unhelpful in the process of data collection.

The sample size therefore comprised 56 patients.



### 3.2) AGE AT THE TIME OF SURGERY

The univariate statistics for age at the time of surgery is represented by univariate statistics in Table 1.

*Table 1: Age distribution*

<b>Mean</b>	42.2
<b>Standard deviation</b>	10.04
<b>Median</b>	41
<b>Interquartile range</b>	39-45.3
<b>Range</b>	26-80

### 3.3) SEX

The study population comprised 48% males and 52% females. The overall ratio of female to male in the study was 1:1.07.

### 3.4) LATERALITY

43% of tumours involved the right eye and 57% involved the left eye

### **3.5.) TYPE OF PROCEDURE PERFORMED**

The tumour was assessed by the operating surgeon preoperatively by clinical examination and a CAT scan of the involved orbit done. If the tumour was grossly invasive and seen to involve the lids, a total exenteration was performed which involved removal of the entire orbital contents including the lids. When the tumour was confined to the globe and orbit only, the lids were spared in the procedure leaving a cosmetically better result.

52 patients (93%) had a total exenteration performed and 4 patients (7%) had a lid sparing procedure.

### 3.6) INDICATION FOR ORBITAL EXENTERATION

The clinical indications in terms of gross anatomical presentation are illustrated in Figure 2. An invasive conjunctival tumour (55%) and gross orbital tumour (27%) were the presenting complaint and indication for surgery in the majority of patients.

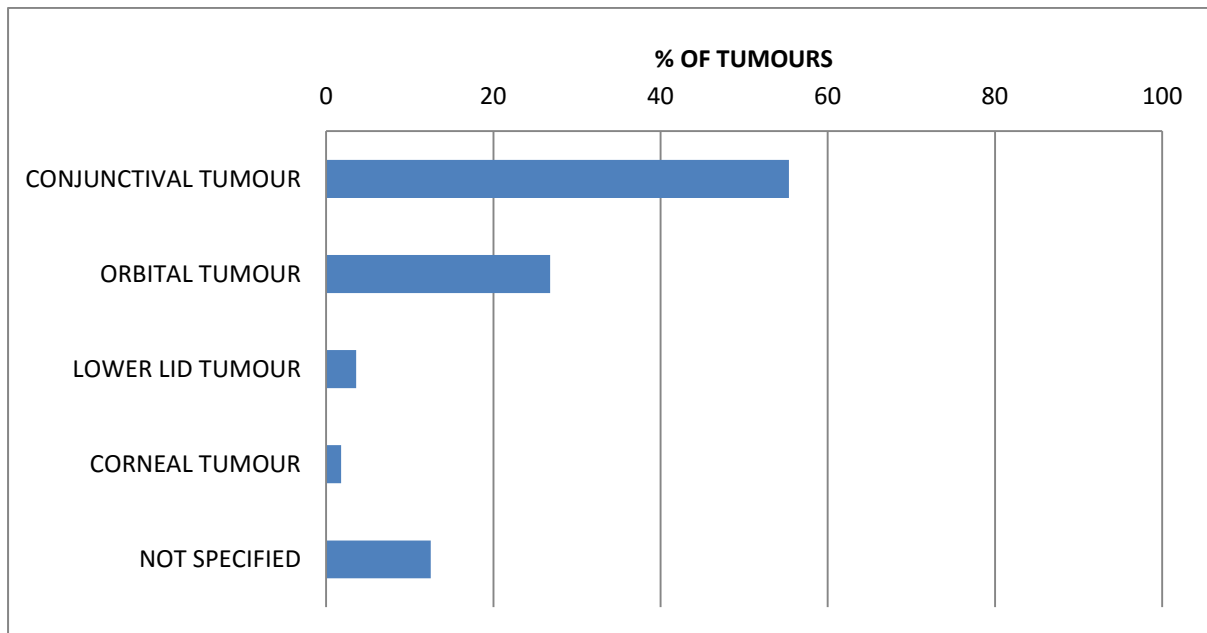


Figure 2. Clinical indication for performing surgery, expressed as a percentage of all tumours analysed in the study group

### 3.7) TISSUE OF ORIGIN

A summary of all anatomical tissues detected, from which tumours were seen to arise is illustrated in Figure 3. A total of 42 (75%) specimens revealed that the tissue from which malignant tumour cells were seen to arise, was the conjunctiva.

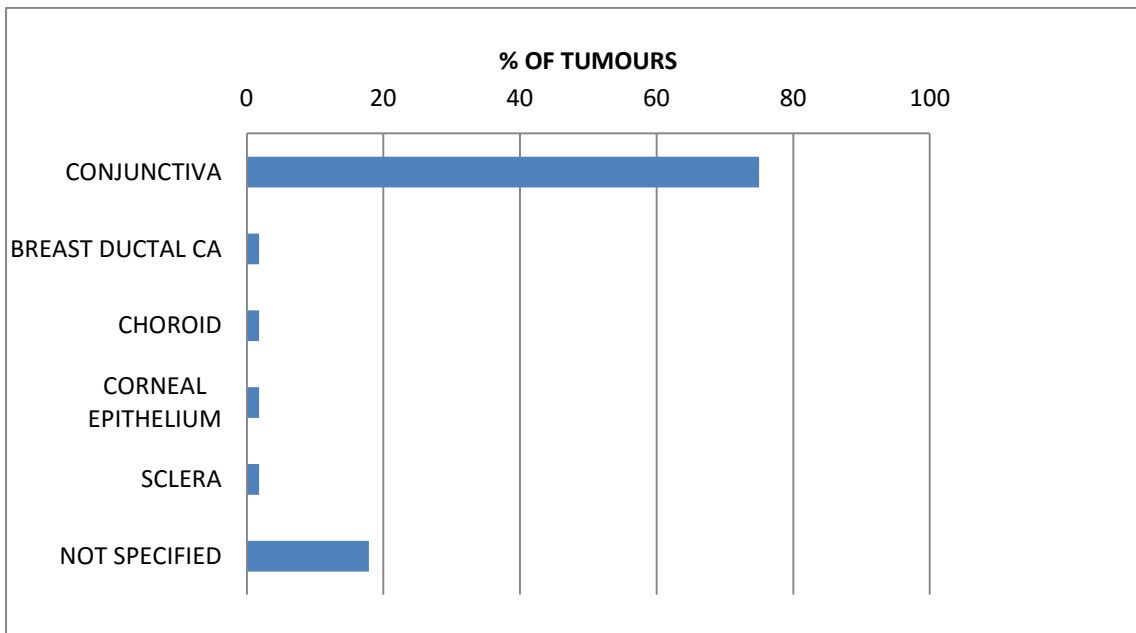


Figure 3. Tissue of origin of each tumour represented as a percentage of all tumours analysed in the study group.

### 3.8) HISTOPATHOLOGICAL DIAGNOSIS

The distribution of the histo-pathological diagnoses made for all tumours analysed is illustrated in Figure 4.

Squamous cell carcinoma of the conjunctiva was the most frequently diagnosed tumour. Out of 56 specimens, 51(91.06%) were of the squamous cell type. Further analysis of the 51 squamous cell carcinoma tumours, revealed that 29 (51.78%) were non- keratinising on histopathological examination and 22 (39.28%) were keratinising.

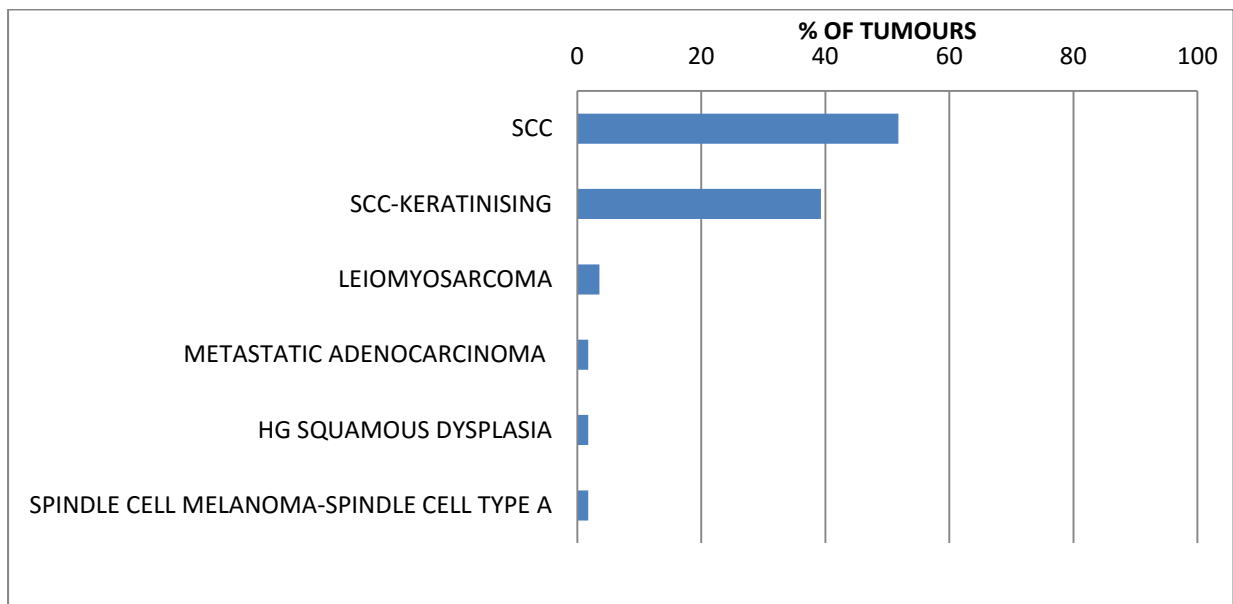


Figure 4. Histopathological diagnosis represented as a percentage of all tumours excised in the study group

### 3.9) HISTOLOGICAL GRADE

The frequency of the histopathological grade of each tumour is illustrated in Figure 5.

How closely the tumour resembles the tissue from which it arises constitutes differentiation.

5 specimens (8.93%) had no comment on histological grade included in their pathology reports overall, the majority of specimens analysed were moderately differentiated (69.64%).

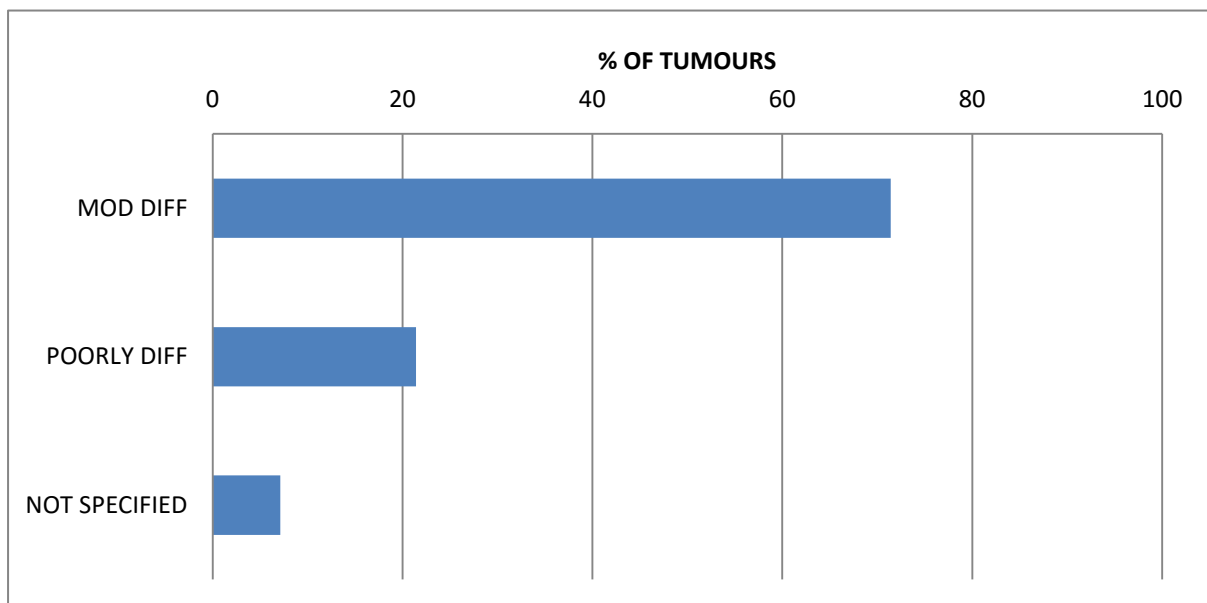


Figure 5. Histological grade of each tumour represented as a percentage of all tumours analysed in the patient study group

### 3.10) TUMOUR STAGING

The frequency of each stage (TNM Staging system) of tumour exenterated in the patient study group is illustrated in Figure 6.

The histopathology report of 48 patients included tumour staging. 29 (51.79%) specimens analysed were Stage 4 and 11 (19.64%) that were Stage 3.

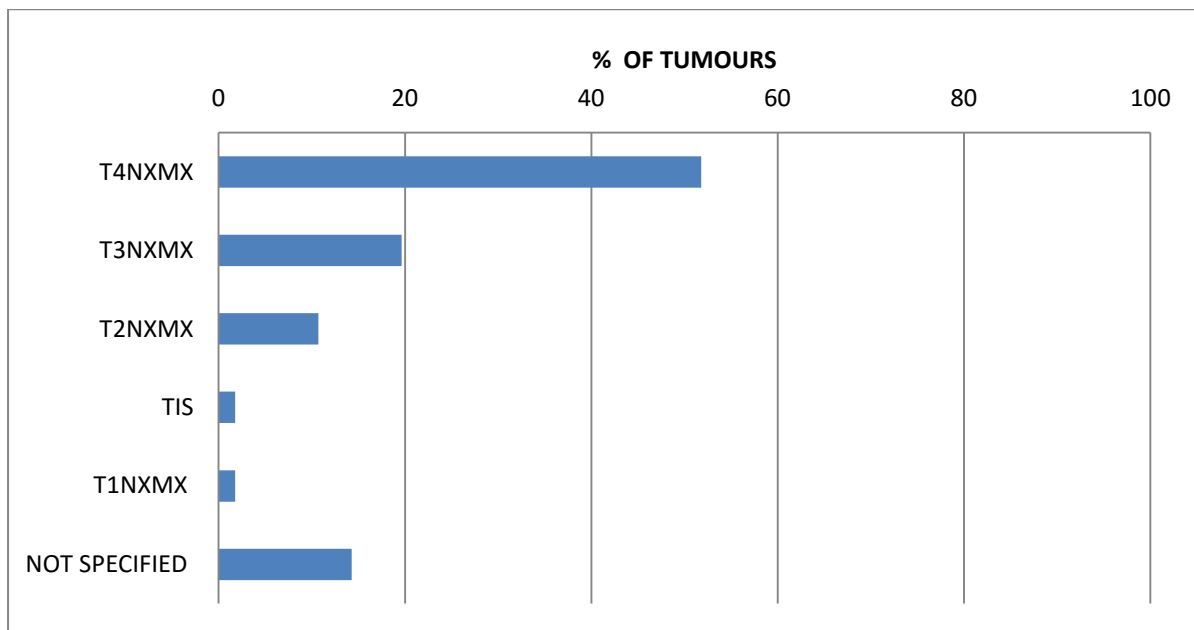


Figure 6. The staging of each tumour analysed and expressed as a percentage of the total number of cases in the study group

### 3.11) COMPLETENESS OF EXCISION

The incidence of complete excision and attainment of tumour-free surgical margins is illustrated in Figure 7.

Out of 56 specimens, 30(53.57%) showed incomplete excision; evident by the presence of tumour cells at the resection margins, 24(42.86%) specimens revealed tumour-free resection margins, i.e. complete excision of the tumour and 2 specimens (3.57%) were not specified.

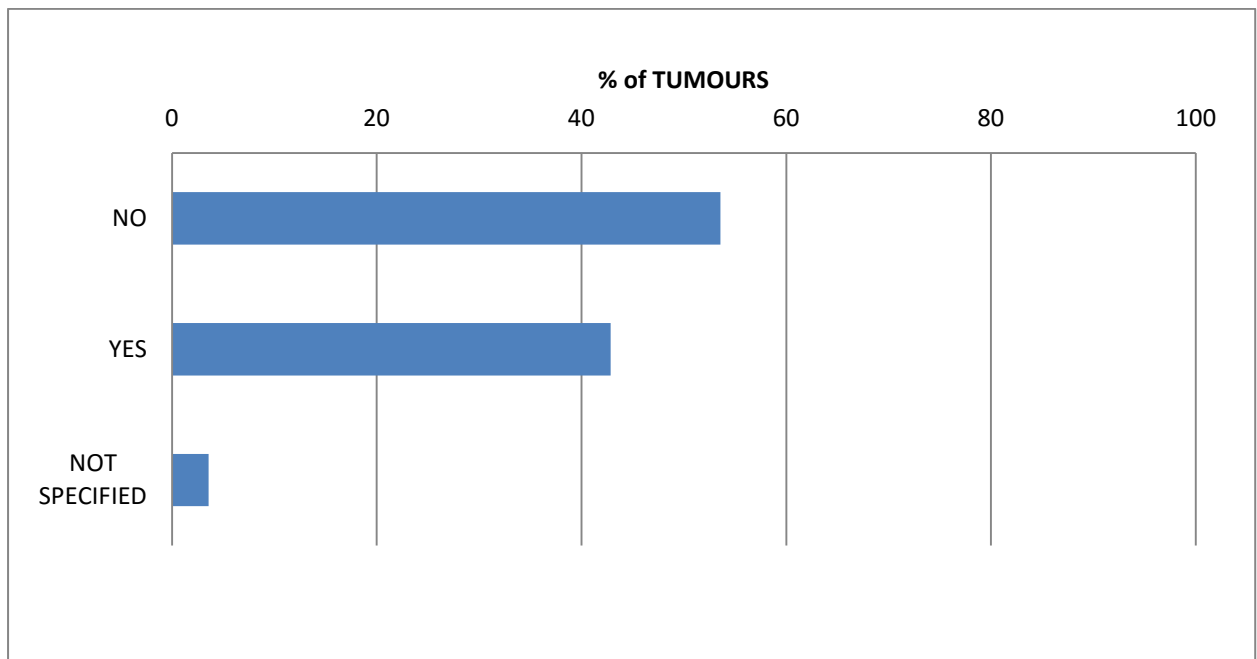


Figure 7. The completeness of excision of each tumour exenterated expressed as a percentage of total number of tumours exenterated in the study group



### 3.12) RETROVIRAL STATUS

The HIV status of each patient in the study group is represented in Figure 8.

HIV testing was performed using an Enzyme-linked immunosorbent assay (ELISA). This is the first test used to detect infection with HIV. If antibodies to HIV are detected (reactive/positive), the test will be repeated to confirm the diagnosis.

Only 28(50%) patients had an HIV result on electronic record. CD4 counts were available for 23 out of these 28 patients. The average CD4 count was 157.

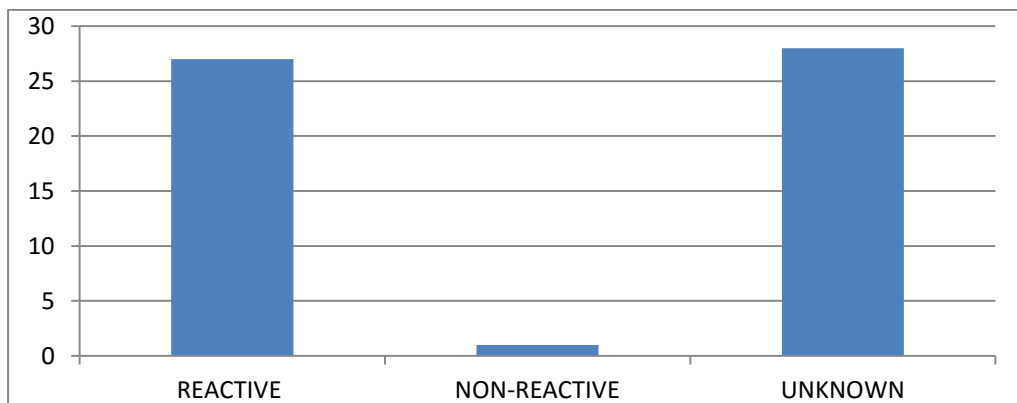


Figure 8.HIV blood results of the study group

## CHAPTER 4

### 4.1) DISCUSSION

The total amount of orbital exenteration surgeries performed at SJEH in the stated 4 year study period was 89. The largest study that was done on the procedure, originated in a study from Turkey.<sup>20</sup> The study reviewed 429 cases over a 30 year period and remains the largest collection of data found on orbital exenteration.

When compared to more recent reports from the western world where data was also collected over a much longer period (up to 14 years), the number of cases done at SJEH remains much higher.<sup>17,19,21</sup> Similar studies in developing countries<sup>2, 3, 15, 16</sup> also show a higher number of cases when compared to data from first-world countries.<sup>17, 19</sup>

Interestingly, the number of cases of orbital exenterations performed at SJEH is still much higher even in comparison with similar studies in other parts of Africa which were also done over a 4 year period or even longer.<sup>3,15</sup> SJEH is a part of Chris Hani Baragwanath Academic Hospital (CHBAH), the largest hospital in Africa. Furthermore, the high burden of disease seen at SJEH could be attributable to the eye clinic being the largest eye care referral centre in Africa.

The high number of patients with incomplete data meant that out of the total number of 89 patients who had undergone exenteration, only 56 patients could be analysed and provide information that would address the study aims and objectives.

The reason that data was incomplete on electronic record or entirely missing is not clear. Furthermore when electronic data was not available the paper filing system at SJEH could not be relied on because this too was incomplete. The reason for this was thought to be due to some patients keeping their files with them and not leaving them at the hospital after their

appointments. Furthermore patient follow up was generally poor and it was not possible to track down all patient files on patient follow up visits in the period allocated for data collection.

Poor follow up due to socio-economic circumstances and incomplete data in is a well described challenge for developing countries trying to collect data for research purposes.<sup>3,15,16</sup>

The distribution of orbital exenteration surgeries over the 4 year study shows that since 2008, this procedure is being performed with increased frequency at SJEH.

The mean age at presentation was 42.16 years, with a range from 26 to 80 years. This is much younger than studies that have emerged from the developed world where the average age of presentation is in the 6<sup>th</sup> decade.<sup>17, 19, 21</sup> SCC however, even when involving the lid, seems to present at a younger age.<sup>21</sup>

Younger age of presentation in this study was suspected to be related to a positive HIV status. Several studies in Africa have shown that patients with OSSN who have a reactive HIV status present at a younger age and at a more advanced stage in the cancer.<sup>1-3, 6, 7</sup> Such conclusions however could not be drawn in this study due to an inadequacy of data regarding retroviral status. There was little disparity regarding gender and the overall female to male ratio was 1:1.07.

A conventional orbital exenteration was performed in 52 patients. This involved removing the eyelids and total orbital and periorbital contents. The remaining 4 patients had a lid-sparing procedure. All operations were performed under general anaesthetic.

With regards to surgery of invasive tumours, reports on how aggressive local surgical resection should be, remains controversial.<sup>17</sup> What is clear is that when a tumour is locally invasive and a surgical cure is thought to be possible with complete excision, a total

exenteration with removal of the entire orbital contents and periorbita is preferred. When clear surgical margins are achieved, total exenteration can result in the recurrence rate being as low as 7-10%.<sup>17</sup>

While patients are thought to have a better cosmetic results and easier facial rehabilitation with a lid sparing procedure, cosmesis will be sacrificed over the control of local disease.<sup>17-19,</sup>

<sup>21</sup> The fact that most of the study patients at SJEH had a total exenteration, may reflect the advanced stage of disease with which these patients presented.

The historical records at SJEH showed a distribution in the use lid-sparing procedures extending from 2009 to 2012 which provides evidence that when appropriate, this procedure was used. This is in keeping with publications at the time advocating a more individualized and tissue sparing approach.<sup>17-19, 21</sup> The fact that a “total” type of exenteration surgery was performed in the majority of cases despite a trend to a more conservative approach reflected in the literature, suggests that the tendency to perform more extensive local resection at SJEH was indicated in light of more advanced clinical disease presenting in these patients rather than surgeon preference.

All patients in the study had a neoplastic indication for exenteration. The majority of patients presented with either a conjunctival neoplastic mass (55%). The second commonest presentation was an orbital neoplastic mass (27%). Only 4% of patients presented with a lid neoplasm. This is in contrast to similar studies from western countries<sup>17, 19, 21</sup> and even a study from India<sup>16</sup>, where most exenteration procedures were performed for tumours originating from the eyelids.

Furthermore 51 of 54 (91%) of all tumours showed a histopathological diagnosis of SCC arising from the conjunctiva. This type of malignancy is known to be the commonest carcinoma of the conjunctiva across the globe.<sup>1,2,3</sup> The results of this study are in keeping

with reports from other developing countries in Africa which showed that the most common indication for exenteration was a malignant orbital mass due to an invasive conjunctival SCC.<sup>2,3,6-7,15</sup> Reports from other cases series in different parts of the world do show some variation in terms of the indication for orbital exenteration, with reports that Basal Cell Carcinoma (BCC) was the main indication for surgery emerging from western countries<sup>19, 21</sup> and Sebaceous Gland Carcinoma (SGC) being more common in Indian patients.<sup>16</sup> These results may reflect a demographic and geographic pattern in the prevalence of certain tumours.

This study found none of the tumours to be due to BCC or SGC. Interestingly 2 patients were found to have Leiomyosarcoma, 1 patient had a Spindle Cell Melanoma and 1 patient had metastatic breast Adenocarcinoma. The rare incidence of orbital metastases found in this study group is in keeping with other case reports that have found orbital metastases to account for a very small percentage of all orbital tumours.<sup>23,24</sup> Carcinoma of the breast has furthermore, been found to be the most common primary site giving rise to orbital metastases.<sup>23</sup>

Regarding the two cases of Leiomyosarcoma, both were primary tumours arising within the orbital and periorbital region. The one patient was 35 years old and had a reactive retroviral status. The CD4 count was 77. The second patient was 46 years old and had no record of retroviral status on the NHLS.

Leiomyosarcoma rarely occurs in the orbit and there are few publications documenting such cases.<sup>24</sup> Leiomyosarcoma is a malignant soft tissue tumour with features of smooth muscle differentiation and is the most prevalent type of sarcoma. Liposarcomas and Leiomyosarcomas occur most frequently in adults.<sup>24, 25</sup> The tumour may be of a primary or metastatic origin. In the case of a primary tumour, cancerous cells are thought to arise from

vascular smooth muscle.<sup>24</sup> Secondary tumours have been identified to originate from primary tumours in the uterus, gastrointestinal tract and soft tissues.<sup>24</sup> Haematogenous spread from primary orbital Leiomyosarcoma results in distant metastatic disease to mainly the liver and lungs.<sup>24</sup>

While being the most common form of sarcoma, its occurrence in the orbit, primary or metastatic, remains rare.<sup>24</sup> The two cases in this study affirm this. The overall incidence of sarcoma in this report is 4%.

Research suggests that Leiomyosarcoma is the most commonly reported sarcoma in HIV infected individuals and occurs with increased frequency in HIV positive children and young adults. The patients typically have low CD4 counts.<sup>25</sup> Both patients in this study were under the age of 50. The one patient whom was known to be HIV infected, showed severe levels of immune suppression, and this supports existing research.<sup>25</sup>

While certain sarcomas such as Kaposi's sarcoma are clearly linked to immune deficiency, the contribution of a compromised immune system to the occurrence of other sarcomas such as Leiomyosarcoma remains unclear.<sup>25</sup>

The solitary patient, whose tumour was found on histopathology to be Spindle Cell Melanoma, was a 40 year old male of African descent. His HIV status was reactive. No CD4 count was available on electronic records.

This is an extremely rare occurrence and there is a paucity of data on uveal melanoma in this racial group.<sup>26,27</sup> A case report on an African-American patient with uveal melanoma noted that the incidence of uveal melanoma in Caucasians to be eight times higher than that of African-Americans. Phillipotts et al in O'Keefee N. et al stated that these tumours, in a Non-Caucasian ethnic group, tend to be larger, show signs of necrosis, inflammation and

secondary glaucoma.<sup>26</sup> Choroidal Melanoma has also shown to present at a younger age in African/Asian patients than was described by the Collaborative Ocular Melanoma study where the mean age was 60 years.<sup>26</sup>

These features were also found to be present in this study. The patient in this study was young, similar to a study in India where the average age of presentation was 45.94 years.<sup>26,27</sup> The tumour was shown on histological examination, to occupy the entire globe and showed signs of central necrosis, although there was no significant inflammation present. The tumour was furthermore of the mixed cell type which is keeping with studies that have described it as the most common subtype.<sup>26</sup>

Despite such variations in different case series regarding the incidence of tumours, the most recent reports including this study, seem to reflect SCC is the most common indication for orbital exenteration globally.<sup>17, 21</sup>

Ackuaku-Dogbe reported in a study from Ghana that although conjunctival SCC is not typically aggressive, there is growing evidence supporting an aggressive type of neoplasm in tropical and subtropical regions that also affect younger patients. A study from Australia, which also has a harsher climate with high degrees of ultraviolet radiation, also reported SCC of the ocular surface to have a higher incidence of scleral invasion (30%) and orbital invasion (15%) compared to previous data that reported the malignancy to be of a low grade and intraocular invasion by SCC to be rare.<sup>21</sup>

Regarding the histopathological classification, 71% of patients had moderately differentiated squamous cell carcinoma and 21% were poorly differentiated tumours, the remaining 8% was unknown. 52% of tumours were at least a stage 4 tumour (orbital invasion) according to the TNM classification.<sup>22</sup> The majority of tumours exenterated in this study were therefore both aggressive and invasive. Neither lymph nodes nor distant metastatic disease could be

assessed by the pathologist as routine sentinel lymph node (SLN) biopsy is not performed at the time of surgery. Metastatic spread to lymphatic nodes is not common in conjunctival SCC, and SLN biopsy is usually reserved for tumours known to be highly metastatic like sebaceous gland carcinoma and melanoma.<sup>22</sup> It has however, been suggested that it may be valuable to also consider a sentinel lymph node biopsy in patients with advanced conjunctival SCC stage 3 or 4 disease.<sup>22</sup>

A substantial proportion of the patients at SJEH had stage 3 disease or a more advanced stage (72%) at the time of surgery and this may support the implementation of SLN biopsy at the time of primary surgery to detect early metastatic disease.

The current protocol at SJEH involves a preoperative clinical examination and Computerized Tomography (CT) scan of the brain and orbits. CT scan best demonstrates bony erosion while Magnetic Resonance Imaging (MRI) would be better at detecting soft tissue involvement in the orbit.<sup>17</sup> Due to the cost of MRI scans this is reserved for select cases and is not routinely done at SJEH as part of the patients metastatic workup. Blood tests are also done which include a baseline blood work up comprising a full blood count and renal function blood test. Pre-test counselling and testing for HIV may also be conducted if the patient is agreeable.

During surgery the surgeon will record whether or not bony erosion and sinus spread was observed and a record will be made in the patients file. Frozen section analysis has been suggested as being useful in such cases<sup>17</sup> but is not available at SJEH and SLN biopsy is not routinely done.

If bony erosion and sinus invasion is noted, patients are referred with the final histopathology report of the excised tumour and a post-operative CT scan to the radiation-oncology department at the Charlotte Maxeke Johannesburg Academic Hospital. The follow up visits



of patients especially once referred for radiation is extremely poor. This may be due to patient morbidity and socio-economic factors.

Further studies focussing on the reason for demise in patients undergoing orbital exenteration would be most useful in evaluating the true benefit of frozen section analysis intra-operatively and SLN biopsy in this population.

The trend of poor follow up of patients at SJEH is much like other African countries and is mainly due to socioeconomic reasons.<sup>2, 3, 16</sup> Furthermore the burden of disease in these patients is often compounded by other diseases like HIV and Tuberculosis and patients may be too sick to travel long distances using public transport to get to hospital. In a setting like SJEH which faces these challenges of a developing country, it remains unknown in this study population what the mortality seen in orbital exenteration patients is truly related to.

Regarding the success of surgical excision, more than half of all tumours excised showed incomplete removal on histopathological examination. 54% of patients had tumour- positive margins, 43% had clear margins and an inconclusive result remained in 3% of specimens. These results are inferior to similar case series that reported tumour-free margins in 62%-68% of cases.<sup>22</sup> The reason for this may be due to the aggressive nature of the tumours described and the advanced stage at presentation.

Solar radiation, HPV and HIV are established risk factors for the development of conjunctival SCC<sup>2, 3, 5, 7, 9, 11, 14</sup> and this could be the reason for the high prevalence of this cancer in both this study and similar studies in sub-Saharan Africa as well as countries with a similar climate like India and Australia.<sup>16, 21</sup>

While the high prevalence of HIV in Sub-Saharan Africa could be predisposing these patients to conjunctival squamous cell carcinoma, no definitive link between HIV and OSSN could be

established in this report as mentioned earlier, because only 50% of patients had a record of their status on the NHLS.

The reason for such incomplete data regarding HIV results may be due to several reasons. HIV testing is a voluntary procedure and following pre-test counselling patients may have declined to do an ELISA blood test. Secondly data may have been lost when the hospital changed the electronic lab system in 2013 to a more updated software system (LABtrack). Blood results that may have been reflected on the old system were, following the change, no longer available on the new electronic system during the period of data collection.

Finally some patients may have been tested in peripheral clinics and already knew their HIV status was reactive, therefore the only blood test on the labs electronic system was a CD4 count.

This is a challenge that continues at SJEH and the paucity of such important information highlights the need for more emphasis being placed on pre-test counselling and a high index of suspicion among health care workers when dealing with patients with OSSN. A study in Malawi suggested from the findings, that OSSN may be both the initial presenting and only observable sign of infection with HIV and subsequently recommended that every patient who was younger than 60, living in an area with high HIV infection rates should strongly be advised to have a test performed.<sup>5</sup>

A surgical procedure in a patient who is HIV-infected has an impact on both the individual and the surgeon. It is important to know a patients viral load and CD4 count preoperatively to make a sound surgical risk assessment for the individual patient. Evidence has shown in some cases, that patients with low CD4 counts have poorer surgical outcomes and while not conclusively so, there is also data suggesting that patients with viral suppression may do better postoperatively.<sup>28</sup> Furthermore, a surgeon's risk of exposure is much lower if an HIV-

infected patient is on treatment and has undetectable viral loads.<sup>28</sup> This evidence only reiterates the vital importance of attaining knowledge of a patient's retroviral status preoperatively.

It may be valuable for the managing doctor to explain to the involved patient if testing is refused, that an ELISA can still be done without the result being disclosed to the patient until they are ready to be informed. Only the doctor in charge need know the patients HIV status and this can give much guidance in the patients overall best management. Patients may then be willing to undergo testing despite being afraid and can be assured they will be getting best practice management. A patient coming to terms with their status may entail a stepwise process of acceptance.

## 4.2) CONCLUSION

This study presents an analysis of orbital tumours exenterated over a four year period at St John Eye Hospital. Information is provided regarding patient demographics, the indications for surgery and histopathology. The data emerging from this study supports evidence from other developing African countries that the majority of orbital tumours arise from the conjunctiva and are typically invasive, presenting at an advanced stage in the disease course.<sup>2, 3, 5, 6, 7, 8, 9</sup> In keeping with these studies, the patients were found to be younger, but no association with HIV infection could be definitively established due to the lack of data available. More than half of all tumours excised in this study showed incomplete excision implying that these patients would need to be referred for radiotherapy. SLN biopsy may assist in more efficient post-operative management and support the need for adjuvant therapy in patients with metastatic disease.<sup>22</sup>

This study's experience reflects a high burden of disease in a limited resources setting. The socio-economic challenges facing these patients result in a later clinical presentation as well as a poor follow-up after surgery. This is likely to affect their prognosis overall. Educating patients who present with conjunctival masses about the seriousness of their condition may improve this, as well as advising patients to not delay excision of conjunctival masses and to seek immediate medical attention if recurrences occur following excision.

The fact that the findings of this study closely resemble other case series from other parts of Africa that demonstrated a strong association between HIV and conjunctival SCC suggest that more efforts need to be made regarding pre-test counselling and HIV testing in this facility.<sup>2, 3, 5, 6, 7, 8, 9</sup> This information is fundamental in the offering patient's holistic care. Finally attention to data capturing and record keeping as well as advising patients to hand in their files at reception after every visit may, moving forward, offer more information

regarding patient morbidity and mortality post-operatively. This may lead the way for further studies to examine rehabilitation and survival in these patients.

What was known before?

Orbital exenteration is performed at SJEH for the treatment of invasive neoplastic orbital tumours. HIV testing is not mandatory. Metastatic workup and lymph node biopsy is not routinely performed.

What this study adds?

Orbital exenteration is being performed with increased frequency at SJEH as the neoplastic burden of disease has increased. The most common neoplasm detected on histopathology was SCC arising from the conjunctiva. The tumour was found to be aggressive and invasive. The findings were in keeping with other developing countries found to have high UV-light exposure and a high incidence of HIV. Although no definite association to HIV could be established due to insufficient data, in patients who did have a reactive status, their CD4 count was below 300cells/mm<sup>3</sup>. If these patients were not already on treatment, this would warrant initiation of ARVs. Furthermore SCC of the conjunctiva is well defined AIDS-associated cancer in other parts of Sub-Saharan Africa. The findings of this study have similar implications and reinforce the importance of pre-test HIV counselling testing to encourage patients to take both an HIV ELISA test and CD4 count.

More than half of all patients undergoing orbital exenteration for these tumours at SJEH had incompletely excised tumours and were at risk of metastatic disease. This may warrant re-evaluation of the current management protocol to possibly include wider excision margins such as a limited ethmoidectomy and sentinel lymph node biopsy at the time of surgery.

## REFERENCES


1. Tulvatana W, Tirakunwichcha S. Multifocal squamous cell carcinoma of the conjunctiva with intraocular penetration in a patient with AIDS. *Cornea* 2006; 25(6): 745-747.
2. Masanganise R, Magava A. Orbital Exenterations and Squamous cell carcinoma of the conjunctiva at Sekuru Kaguvi Eye Unit, Zimbabwe. *Cent Afr J Med* 2001; 47(8):196-9.
3. Ogun G, Ogun O, Bekibele C, et al. Intraepithelial and invasive squamous neoplasms of the conjunctiva in Ibadan, Nigeria: a clinicopathological study of 46 cases. *Int Ophthalmol* 2009; 29: 401-40.
4. Newton R. A review of the aetiology of squamous cell carcinoma of the conjunctiva. *British J Cancer* 1996; 74: 1511-1513.
5. Spitzer M.S, Batumba N.H, Chirambo T, et al. Ocular surface squamous neoplasia as the first apparent manifestation of HIV infection in Malawi. *Clin Exper Ophthalmol* 2008; 36: 422-425.
6. Orem J, Otieno M.W, Remick S.C. AIDS-associated cancer in developing nations. *Curr Opin Oncol* 2004; 16: 468-476.
7. Waddell K.M, Lewallen S, Lucas S.B, et al. Carcinoma of the conjunctiva and HIV infection in Uganda and Malawi. *Br J Ophthalmol* 1996; 80: 503-508.
8. Chokunonga E, Levy L.M, Bassett M.T, et al. Aids and cancer in Africa: the evolving epidemic in Zimbabwe. *AIDS* 1999; 13: 2583-2588.
9. Beare N, Batumba N. The impact of HIV on sub-Saharan African eye departments. *Eye* 2006; 20: 1414-1415.

10. Burgi A, Brodine S, Wegner S, et al. Incidence and risk factors for the occurrence of Non-AIDS-Defining cancers among Human Immunodeficiency Virus-infected individuals. *Cancer* 2005; 104(7): 1505-1511.
11. London N.J.S, Shukla D, Heiden D, et al. HIV/AIDS in the developing world. *Int Ophthalmol Clin* 2010; 50(2): 201-215.
12. Goedert J, Cote T, Virgo P, et al. Spectrum of AIDS-associated malignant disorders. *Lancet* 1998; 351: 1833-1839.
13. Parkin D.M, Wabinga H, Nambooze S, et al. AIDS-related cancers in Africa: maturation of the epidemic in Uganda. *AIDS* 1999; 13: 2563-2570.
14. Sasco A.J, Jaquet A, Boidin E, et al. The challenge of AIDS-Related malignancies in Sub-Saharan Africa. *PLOS One* 2010; 5(1): e8621.
15. Ackuaku-Dogbe E. Review of Orbital Exenteration in Korle-Bu Teaching Hospital. *Ghana Med J* 2011; 45(2): 45-49.
16. R. Maheshwari. Review of Orbital Exenteration from an Eye Care Centre in Western India. *Orbit* 2010; 29(1): 35-38.
17. Simon G.B.S, Schwarcz R.M, Douglas R, et al. Orbital exenteration: One size does not fit all. *Am J Ophthalmol* 2005; 139(1): 11-17.
18. Tyers A.G. Orbital Exenteration for invasive skin tumours. *Eye* 2006; 20: 1165-1170.
19. Rahman I, Cook A.E, Leatherbarrow B. Orbital exenteration: a 13 year Manchester experience. *Br J Ophthalmol* 2005; 89:1335–1340.
20. Gtinalp I, Gtintiz K, Dtirtik K. Orbital exenteration: a review of 429 cases. *Int Ophthalmol* 1996; 19:177-184
21. Nemet A. Y, Martin P, Bengner R, et al. Orbital Exenteration: A 15-Year Study of 38 Cases. *Ophthal Plast Reconstr Surg* 2007; 23(6): 1-6

22. McGowan HD. Squamous Neoplasia of the Conjunctiva: The New TNM Classification by the American Joint Committee on Cancer (AJCC). *Ophthalmol Rounds*. 2009; 7(1): 130-38E.
23. Vlachostergios P J, Voutsadakis I A and Papandreou C N. Orbital Metastasis of Breast Carcinoma. *Breast Cancer (Auckl)* 2009; 3:91-97
24. Feinstein E, Kaliki S, Shields C.L, et al. Choroidal metastasis from leiomyosarcoma in two cases. *Oman J Ophthalmol* 2014; 7(1): 19-21
25. Bhatia K, Shiels MS, Berg A, et al. Sarcomas other than Kaposi sarcoma occurring in immunodeficiency: interpretations from a systematic literature review. *Curr Opin Oncol* 2012; 24(5):537-46
26. O' Keeffee N.A, Lin C.J, Shields C, Choroidal Melanoma in an African American Patient. *Retina Today* 2014; 9(6): 58-60
27. Dhupper M, Biswas J, Gopal L, et al. Clinicopathological correlation of choroidal melanoma in Indian population: A study of 113 cases. *Oman J Ophthalmol* 2012; 5(1): 42-45
28. New York State Department of Health AIDS Institute. "Perioperative management of HIV-infected individuals." 2012. < <http://www.hivguidelines.org/wp-content/uploads/perioperative-management-of-hiv-infected-patients-posted-01-24-2012.pdf>.> [Accessed 21 Dec 2014]



# APPENDIX A

  
M130642

R14/49 Dr PY Raman

**HUMAN RESEARCH ETHICS COMMITTEE (MEDICAL)**  
**CLEARANCE CERTIFICATE NO. M130642**

**NAME:** Dr PY Raman  
**(Principal Investigator)**

**DEPARTMENT:** Ophthalmology  
Department of Neurosciences


**PROJECT TITLE:** Orbital Exenteration at St John's Eye Hospital

**DATE CONSIDERED:** 28/06/2013

**DECISION:** Approved unconditionally

**CONDITIONS:**

**SUPERVISOR:** Prof Grant McLaren

**APPROVED BY:**   
Professor PE Cleaton-Jones, Chairperson, HREC (Medical)

**DATE OF APPROVAL:** 28/06/2013

This clearance certificate is valid for 5 years from date of approval. Extension may be applied for.

**DECLARATION OF INVESTIGATORS**

To be completed in duplicate and **ONE COPY** returned to the Secretary in Room 10004, 10th floor, Senate House University.

I/we fully understand the conditions under which I am/we are authorized to carry out the above-mentioned research and I/we undertake to ensure compliance with these conditions. Should any departure be contemplated, from the research protocol as approved, I/we undertake to resubmit the application to the Committee. I agree to submit yearly progress report.

Principal Investigator Signature \_\_\_\_\_ Date \_\_\_\_\_

PLEASE QUOTE THE PROTOCOL NUMBER IN ALL ENQUIRIES

## APPENDIX B

**Pathological classification (pTNM): Conjunctival carcinoma** (McGowan HD. Squamous Neoplasia of the Conjunctiva: The New TNM Classification by the American Joint Committee on Cancer (AJCC). *Ophthalmology Rounds*. 2009, 7(1): 130-38E.)

### Primary tumour (pT)

pTX Primary tumour cannot be assessed
pT0 No evidence of primary tumour
pTis Carcinoma <i>in situ</i>
pT1 Tumour(s) of bulbar conjunctiva, greatest dimension less than 5 mm.
pT2 Tumour(s) of bulbar conjunctiva, greatest dimension greater than 5 mm.
pT3 Tumour(s) of conjunctiva invading adjacent structures (excluding the orbit)
pT4 Tumour invades orbit with or without further extension

### Regional lymph nodes (pN)

pNX Regional lymph nodes cannot be assessed
pN0 No regional lymph node metastasis
pN1 Regional lymph node metastasis

### Distant metastasis (pM)

pMX Distant metastasis cannot be assessed
pM0 No distant metastasis
pM1 Distant metastasis

## APPENDIX C

**Histopathological grade: represents the primary tumour** (McGowan HD. Squamous Neoplasia of the Conjunctiva: The New TNM Classification by the American Joint Committee on Cancer (AJCC). *Ophthalmology Rounds*. 2009, 7(1): 130-38E.)

GX – Grade cannot be assessed
G1 – Well differentiated
G2 – Moderately differentiated
G3 – Poorly differentiated
G4 – Undifferentiated