

https://dspace.org/

Ulcerative keratitis in the South African black with particular emphasis on the management of supperative keratitis

Carmichael, Trevor Robin

1991

http://hdl.handle.net/10539/22087

Carmichael, Trevor Robin (1991) Ulcerative keratitis in the South African black with particular emphasis on the management of supperative keratitis, University of Witwatersrand, Johannesburg, <http://wiredspace.wits.ac.za/handle/10539/22087>

Downloaded from a DSpace repository. https://dspace.org/

Ulcerative Keratitis in the South African Black with Particular Emphasis on the Management of Suppurative Keratitis.

Trevor Robin Carmichael

A Thesis Submitted to the Faculty of Medicine,
University of the Witwatersrand, Johannesburg
for the degree of Doctor of Philosophy (Medicine).

Johannesburg 1991

Declaration

I declare that this thesis is my own, unaided work. It is being submitted for the degree of Doctor of Philosophy (Medicine) at the University of the Witwatersrand, Johannesburg. It has not been submitted before for any degree or examination in any other University.

Trevor Robin Carmichael

22nd day of October 1991

Abstract

This thesis describes corneal ulceration in the black South African and how the pattern of the disease differs from that seen in white South Africans.

Initial comparative surveys of one year each were conducted at St John Eye Hospital and the Johannesburg Hospital. These surveys showed that the main problem area in the black patient was central bacterial corneal ulcers while in the white, central viral ulcers accounted for most of the cases seen. Marginal catarrhal ulceration in the black was commonly seen but it showed a better response to treatment and a better visual outcome. There was generally a marked male predominance in blacks and this was mainly related to predisposing factors. The commonest predisposing factors in the black patient were episodes of corneal trauma, climatic droplet keratopathy, corneal scarring, malnutrition and alcohol abuse. Pretreatment with antibiotics was found in nearly half of the patients and this was significantly associated with the absence of significant isolates in 40% of central ulcers. Single Gram-positive bacterial isolates were found in 30% of central ulcers and single Gram-negative isolates in 15%, while fungal isolates were recovered in 5.5% of central ulcers. *Streptococcus pneumoniae* was by far the commonest organism, accounting for 42% of significant bacterial isolates. This organism and *Pseudomonas aeruginosa* were associated with some of the major complications (descemetocoeles and perforations). Using fixed treatment regimens, the results of treatment in mild and moderate bacterial and fungal keratitis were good, as well as most types of marginal ulcers. Vision was shown to improve significantly in the moderate bacterial infections but not in the severe and complicated bacterial cases.

A numerical ranking system for the statistical analysis of visual acuity is described and the method was found to produce consistent results.

In a controlled clinical trial using topical steroids plus antibiotics versus antibiotics alone, no difference in visual outcome could be shown. Complications in the two groups were similar, however, and the steroid did not appear to retard the rate of healing. Recommendations for the incorporation of topical steroid into a treatment regimen are made. Principles for the management of suppurative keratitis in a developing population are outlined in the conclusions.

Dedication

This thesis is dedicated to the people who work, have worked or will work at St John Eye Hospital.

And to the patients.

Contents

Abstract iii

List of Illustrations viii

List of Tables ix

Preface x

References xiv

1.0 Introduction 1
- Literature Review 1
- Aims and Structure of Thesis 4

2.0 The Epidemiology of Corneal Ulcers 8
- Introduction 8
- Patients and Methods 9
- Classification of Corneal Ulcers 11
- Corneal Ulceration at St John Eye Hospital 14
  - Seasonal Variation in Presentation 15
  - Ethnic Groups 17
  - Age 19
  - Sex 23
  - Residence and Occupation 25
  - Treatment Prior to Admission 26
  - Delay before Presentation to Hospital (Admitted Cases) 27
  - OPD Visits and the Duration of Inpatient Treatment 29
  - Vision in the Fellow Eye 31
- Corneal Ulceration at the Johannesburg Hospital 33
- Comparison Between Corneal Ulcers at St John Eye Hospital and the Johannesburg Hospital 35
- Discussion 37
- References 40

3.0 Predisposing Factors in Corneal Ulceration 42
- Introduction 42
- Patients and Methods 42
- Factors Predisposing to Central Corneal Ulcers 45
  - Local Factors 45
    - Corneal Trauma and Foreign Bodies 46
    - Climatic Droplet Keratopathy (CDK) 47
    - Corneal Scarring 49
    - Other 49
    - Spontaneous Onset 49
  - General Factors 49
    - Malnutrition 50
    - Alcohol 53
    - Other 55
- Factors Predisposing to Marginal Corneal Ulcers 56

Local Factors 56
General Factors 59
Discussion 60
Conclusions 66
References 66

4.0 Microbiology of Corneal Ulceration 70
Introduction 70
Patients and Methods 70
Microbiology of Central Corneal Ulcers 72
Central Bacterial Ulcers 72
Fungal Corneal Ulcers 75
Viral Corneal Ulcers 75
Microbiology of Marginal Corneal Ulcers 76
Marginal Catarrhal Corneal Ulcers 76
Marginal Ring Ulcers 77
Marginal Mooren's and Marginal "Other" 77
Marginal Primary Ulcers 77
Microscopy and Antibiotic Sensitivities 77
Microbial Findings and their Possible Relationship with Clinical Features and Risk Factors 79
Clinical Features of Corneal Ulcers 79
Comparison of Local Antibiotic Pretreatment with Significant Isolates Obtained 91
Isolates in Cases of Foreign Bodies and Other Corneal Trauma Causing Central Corneal Ulcers 91
Isolates in Cases of Climatic Droplet Keratopathy 93
Isolates in Adult Cases where Malnutrition was a Predisposing Factor 95
Organisms Isolated in Cases with Alcohol Abuse as a Predisposing Factor 97
Organisms Isolated in Cases with Spontaneous Onset and No Predisposing Factor 99
Comparison of Bacterial Isolates, Selected Clinical Features and Predisposing Factors 101
Discussion 102
References 107

5.0 The Treatment and Results of Treatment of Corneal Ulcers 110
Introduction 110
Patients and Methods 110
Management and Results 115
Central Bacterial Ulcers 115
Results of Treatment of the Moderate Group 116
Results of Treatment of the Severe Group 128
Results of Treatment of the Group that was Pressure Padded and Received Daily Subconjunctival Injections 145
Results of Treatment of the Group that was Pressure Padded and Received Twice Daily Subconjunctival Injections 149
Treatment Methods in the "Other" Group 155

Central Fungal Ulcers 157
Central Viral Ulcers 168
Marginal Catarrhal Ulcers 180
Marginal Ring Ulcers 181
Marginal Mooren's Ulcers 181
Marginal Primary Ulcers 183
Marginal "Other" 187
Discussion 188
References 195

6.0 Topical Steroids in the Treatment of Central and Paracentral Corneal Ulcers 199
Introduction 199
Patients and Methods 199
Results 203
Discussion 207
Conclusions 209
References 209

7.0 Conclusion 211
References 216

List of Illustrations

2.1 St John Eye Hospital 9
2.2 Geographical Situation of Towns and Cities on the Reef 10
2.3 Central Bacterial Ulcer 12
2.4 Marginal Catarrhal Ulcer 13
2.5 Marginal Ring Ulcer (Rheumatoid Disease) 13
2.6 Marginal Mooren's Ulcer 14
2.7 Seasonal Variation in Presentation of Patients 15
2.8 Age of Central Corneal Ulcer Patients 20
2.9 Age of Marginal Corneal Ulcer Patients 20
2.10 Incidence Rates of Central Ulcer Patients by Age 22
2.11 Incidence Rates of Marginal Ulcer Patients by Age 22
2.12 Sex of Central Corneal Ulcer Patients 24
2.13 Sex of Marginal Corneal Ulcer Patients 24
2.14 Inpatient Treatment Central and Marginal Ulcer Patients 30
2.15 Vision in Fellow Eye by Age Group 32
2.16 Corneal Ulcer Types St John Eye Hospital 36
2.17 Corneal Ulcer Types Johannesburg Eye Hospital 36
5.12 Scattergram of Visual Acuities - Central Bacterial - Moderate Treatment, All Cases 126
5.13 Scattergram of Visual Acuities - Central Bacterial - Moderate Treatment, Cases that Healed Well 126
5.14 Scattergram of Visual Acuities - Moderate Treatment - Cases with Complications 127
5.54 Scattergram of Visual Acuities - Central Bacterial - Severe Treatment . 143
5.47 Scattergram of Visual Acuities - Pressure Padded Cases 155
5.81 Scattergram of Visual Acuities - Marginal Catarrhal Group 180
6.1 Scale Drawing of Corneal Ulcer 202
6.2 Linear Regression of Visual Acuities Before & After Treatment 207

List of Tables

Types of Corneal Ulcers at St John Eye Hospital (1/7/82-30/6/83) 11
Seasonal Presentation: Number of Corneal Ulcer Patients 16
Ethnic Groups by Corneal Ulcer Type (Numbers) 17
Number of Soweto Cases by Ethnic Group with
Incidence Rates (per 100 000 population) 18
Mean Age (years) and Standard Error by Group 19
Age and Incidence Rates of Central and Marginal Corneal Ulcer Patients 21
Sex of Corneal Ulcer Patients by Group (Numbers) 23
Occupation of Adult Corneal Ulcer Patients at St John Eye Hospital 25
Local Treatment of Corneal Ulcers before Admission 26
Delay Before Presentation for Treatment 28
Average Number of Patient Days by Group 30
Types of Corneal Ulcers at the Johannesburg Hospital (1/9/83 - 31/8/84) 33
Occupation of Adult Corneal Ulcer Patients at the Johannesburg Hospital 34
Local Predisposing Factors by Type of Central Corneal Ulcer 46
Cases with Foreign Bodies and Other Trauma as Predisposing Causes 47
Cases with Climatic Droplet Keratopathy (CDK) as a Predisposing Cause 48
General Predisposing Factors by Type of Central Corneal Ulcer 50
Anthropometric Measurements (Percentile) 50
Corneal Isolates from Central Bacterial Ulcers 73
Corneal Isolates from Central Fungal Ulcers 75
Corneal Isolates from Marginal Catarrhal Ulcers 76
Microscopy of Smears 78
Clinical Features of Corneal Ulcers 79
Cases with Foreign Bodies and Other Trauma as Predisposing Causes 92
Cases with Climatic Droplet Keratopathy (CDK) as a Predisposing Cause 94
Central Corneal Ulcer Patients with Malnutrition as a Predisposing Factor 96
Central Corneal Ulcer Patients with Alcohol as a Predisposing Factor 98
Cases with Spontaneous Onset and No Predisposing Cause 100
Summary of Clinical Features and Significant Isolates by Predisposing Factor for
Central Ulcers 101
The Spectrum of Isolates in Central Ulcers at St John Eye Hospital 103
Medical Treatment of Central Bacterial Corneal Ulcers 115
Comparison of Results of Treatment for Larger Groups 190
Visual Acuities (follow-up at 2 months) 201
Comparison of Groups 203
Comparison of Ulcers (ulcers) 204
Corneal Cultures 204
Complications 205

Preface

In 1979, W.G.Douglas, a consultant at St John Eye Hospital, suggested corneal ulceration as a topic for Ph.D research. This resulted from the observation that many hypopyon ulcers were treated at the hospital and many unanswered questions surrounded their diagnosis and management.

During my National Service training between 1979 and 1981 I was fortunate to spend part of my time in the Ophthalmology Department at 1 Military Hospital (Pretoria) and the other 18 months in the Epidemiology Section of the Department of Health in Pretoria. This early grounding laid the basis for this thesis. At 1 Military Hospital I conducted my first clinical study on Pterygia[1]. Under the supervision of the State Epidemiologist, H.G.V.Kustner, I wrote or co-authored papers on Poliomyelitis[2], Cholera[3], Trachoma[4] and Measles[5].

On returning to St John Eye Hospital (St John) in November 1981 I found a fellow registrar, L.D.Ormerod, had already started work on corneal ulceration. He had collected retrospective data and was collecting cases in a prospective manner. He has subsequently moved to the United States of America, but later published some of the early data collected[6].

The initial objectives for this thesis were:

1. To establish the extent of the problem: How many cases and what types of corneal ulcers were seen.
2. To fully describe the microbiological spectrum responsible for corneal ulcers in this population.
3. To establish predisposing causes with preventative measures in mind.
4. Testing of unregistered anti-fungal medication.
5. Determining the visual prognosis for the condition as well as the drain on hospital resources in terms of bed occupancy.
6. Assessing the response to treatment when a standard treatment regime was followed.
7. Altering the treatment to improve the prognosis.

Writing a thesis is a feat which can be likened to running the Comrades Marathon. The first half you do for yourself but the second half you complete for all those whose efforts got you there.

One does not know whether to thank these people or curse them but their support and encouragement are beyond measure.

W.G.Douglas for the idea (and the platinum spatula!).

L.D.Ormerod for his wonderful enthusiasm, direction, and the references he freely made available to me.

My consultants at St John Eye Hospital, P.Rush and M.Wolpert for their encouragement and welcome advice and for allowing a junior in the department to manage those difficult cases.

The registrars and nursing staff at St John for putting up with my antics. Any research work done at St John is painfully accomplished as the service work load is so great without voluntarily adding to it. Without their support the work could not have been done.

The back-room boys, the laboratory personnel at the South African Institute for Medical Research in Johannesburg and at Baragwanath Hospital. Val Kuhnle, Avril Wasas, Celia Young, Kevin Stead and Marion Carmichael for all the advice and guidance and their meticulous work.

Hamish Gilbert for assistance in the initial computer analysis in 1983 and Denis Matzkin for forcing me into the fascinating world of computers.

My coauthors for their valuable input. In particular Iain Gibson and John Salmon, two exceptional friends, for their very important contributions and their support.

Jeanine Dreyer, my partner, for helping to carry the load and continually reminding me that the thesis had to be finished.

E.T.Meyer, one of my initial supervisors, for his continued encouragement right up to the time of his death

Alcon laboratories and John Patrick in particular for continued support and helping to finance the photographs appearing in this thesis. Eli Lilly (Kefzol) kindly subsidized reprints of the steroid paper.

Colleen and Charlie Pope, the computer boffins, for the production of this thesis in it's final format.

Dolores Rokos for producing the scattergrams and the map.

H.G.V. Kustner for showing me the way. Any resemblance between the analysis approach used in this thesis and what he taught me is more than coincidental.

To Marion, Bradley and Bronwyn, who know better than anyone what it cost.

To my father and mother who really believed it could be done.

Terri Baker for her incredible patience and love.

Prof. H.J.Koornhof and Prof. N.H.Welsh my supervisors, whose continual encouragement, advice and guidance were fundamental to the completion of this thesis.

Journal Articles arising from this thesis:

Carmichael TR, Mervitz MD, Bezwoda W, Rush PS. [illegible] a exchange in the treatment of Mooren's Ulcer. *Ann Ophthalmol* 1985; 17: 311-4.

Carmichael TR, Wolpert M, Koornhof HJ. Corneal ulceration at an urban African hospital. *Br J Ophthalmol* 1985; 69: 920-6.

Di Bisceglie AM, Carmichael TR. Factors predisposing to central corneal ulceration in a developing population. *S Afr Med J* 1987; 71: 769-70.

Carmichael TR, Gelfand Y, Welsh N. Topical steroids in the treatment of central and paracentral corneal ulcers. *Br J Ophthalmol* 1990; 74: 528-31.

The above article was also published as an abstract in *Ophthalmology Digest* 1991; 3: 14-5.

Congress papers arising from this thesis:

Epidemiological aspects of corneal ulceration at St John Eye Hospital- one hundred cases.
O.S.S.A. (Ophthalmological Society of South Africa) Congress (Durban) March 1983.

Mycotic keratitis and endophthalmitis.
Symposium on the Mycoses and Fungal associated diseases.
(Johannesburg) February 1984.

Management of corneal ulceration and results of treatment.
O.S.S.A. Congress (East London) May 1984.

Problems in managing corneal ulceration.
Ophthalmology refresher course (Cape Town)
November 1987.

Topical steroids in bacterial corneal ulcers.
O.S.S.A. Congress (Port Elizabeth)
March 1989.

This thesis was typed using "Wordperfect 5.1", the spreadsheet used for the tables was "Quattro" and "Harvard Graphics" was used for the graphs and charts. Databases were created using "dBase 3 plus" before final data analysis. "Statgraphics" and "Epistat" were used for most of the statistical calculation

The photographs appearing in this thesis were taken by myself, using a slit-lamp camera and a medical Nikon camera. The microbiology photographs were kindly provided by the South African Institute for Medical Research in Johannesburg.

References

1. Carmichael TR, Maritz JC. High pterygium recurrence rates in Defence Force personnel. *South African Archives of Ophthalmology* 1982; 9: 21-5.
2. Carmichael TR, Gibson IHN, Kustner HGV. Problems in eradicating poliomyelitis from South Africa. *S Afr Med J* 1981; 59: 374-6.
3. Kustner HGV, Gibson IHN, Carmichael TR, Van Zyl L, Chouler CA, Hyde JP, Du Plessis JN. The spread of cholera in South Africa. *S Afr Med J* 1981; 59: 87-90.
4. Carmichael TR, Gibson IHN, Kustner HGV. Blinding trachoma-a public health challenge. *S Afr Med J* 1982; 61: 5-8.
5. Gibson IHN, Carmichael TR, Kustner HGV. Measles notifications-the first year. *S Afr Med J* 1982; 61: 84-8.
6. Ormerod LD. Causation and management of microbial keratitis in subtropical Africa. *Ophthalmology (Rochester)* 1987; 94: 1602-8.

1. Introduction

Published work related to corneal ulceration falls into prospective and retrospective studies. The prospective technique is more powerful but much useful information can be gleaned from the often larger retrospective reviews.

In this section only the more comprehensive studies are discussed, and they constitute an overview of important work that has been reported from areas around the world. The relatively few studies recorded in the literature probably reflect the paucity of clinical material in the larger centres and this may be the reason why more prospective work has not been done. It appears that in most instances, where the medical manpower and technology exists, it probably would take too long to do prospective clinical trials, and adding control groups would double the time.

1.1 Literature Review

Retrospective Studies

The most impressive review on all microbiological aspects of eye disease is in a book entitled " Microbiology of the Eye " by Locatcher-Khorazo and Seegal[1] It contains an analysis of data gathered mostly in the Laboratory of Microbiology at the Edward S. Harkness Eye Institute, Columbia-Presbyterian Medical Center. The historical perspectives in the first chapter of this book provide many useful references. The data analyzed were based on 50,000 patients and controls examined in the laboratory over a 30 year period, between 1938 to 1968.

Rhodes[2], presented bacteriological findings on 120 cases of hypopyon ulcer in 1939. Sixty-seven percent of the patients were mine workers. The report is from Edinburgh, Scotland and the study period is not mentioned.

In 1948, Thygeson[3] published a report of 50 cases of central ulcers collected over a 15-year period (1932 to 1947) from San Francisco. These were not consecutive and were culture-positive patients only.

Brightbill[4] reviewed 115 central corneal ulcers (110 patients including culture-negative cases) seen during a 20 year period (1950 to 1970) at University Hospital, Wisconsin.

Jones[5] published 232 cases from Baylor College of Medicine and the Cullen Eye Institute

(Houston, Tex.) in 1979. He included only culture-positive cases and stipulated a case definition, based on class of isolate, for patients included. The patients were seen over a seven-year period between 1972 and 1979.

In 1980, a larger series of 663 ulcers (2 bilateral) was reported from Miami, Florida. Liesegang[6] commented on the unusual spectrum of organisms seen in Southern Florida which featured relatively large numbers of isolates of *Pseudomonas* and fungi. The patients were seen during a nine year period between 1969 and 1977 and the report included culture-negative cases. There were 238 bacterial and 133 fungal infections while 292 were culture-negative.

A laboratory based review covering 30 years (1950 to 1979) was published in 1982 by Asbell and Stenson[7]. Isolates were obtained in 547 of the 677 cases at the New York University-Bellevue Medical Center.

From Ann Arbor, Michigan, a series of 224 patients was compiled by Musch et al[8] using a computer search of hospital records. From these, 100 patients were drawn by random sample, for analysis. The patients were seen during a six year period between 1975 and 1981.

Experience in treating microbial corneal ulcers as outpatients was published by Groden and Brinser[9] in 1986. Twenty-six consecutive patients were reviewed of which 20 had been managed as outpatients. The report was from Tampa, South Florida and covers the period August 1984 to May 1985.

Wilson[10] reported 306 isolates from bacterial keratitis cases at Emory University School of Medicine, Atlanta, Georgia. These were cases seen in the ten year period between 1974 and 1984.

In 1986, Gur[11], from Turkey, included details of 39 cases of corneal ulcers in a paper on bacterial etiology of eye infections. The paper was in Turkish with an English abstract and the study period was not mentioned.

In 1987, Ormerod et al[12], published 227 cases of microbial keratitis from Southern California. This included a multivariate analysis and covers admissions to the Los Angeles County-University of Southern California Medical Center, Harbor General and

Martin Luther King Hospitals. The study period was 11 years (1972 to 1983) and patients records were accessed and analyzed using computers.

From Australia, Coster and Badenoch[13], reviewed 87 cases of infective keratitis seen at the Flinders Medical Centre in Adelaide. The study period was from August 1980 to February 1986.

Experience in treating bacterial corneal ulcers in Arabs in Kuwait was published in 1989 by al-Samarrai and Sunba[14]. There were 228 consecutive cases, including culture-negative cases and the study period was five years (1982-1986).

Prospective Studies

The prospective studies published have generally been smaller and of shorter duration.

In 1969, Aronson and Moore[15] published a series of 75 patients from San Francisco General Hospital and the University of California Hospitals. These patients had central stromal keratitis and high dosage corticosteroid treatment was used in conjunction with specific treatment. The group included 37 patients with Herpes simplex, nine with Herpes zoster, 16 with bacterial (culture-positive) keratitis, and one fungal infection (*Candida albicans*). The remaining 12 were placed into an "other" category as the cause was not apparent.

In 1972 they updated their series to 146 patients[16] which then consisted of 81 cases of Herpes simplex, 19 of Herpes zoster, 44 of bacterial keratitis and 2 fungal infections.

The study period over which the cases were seen was not mentioned but since the numbers double in 3 years one might assume it took about 6 years to reach a total of 146 patients.

In a survey of *Moraxella* corneal ulcers between 1966 and 1968, Baum et al[17], studied 20 ulcers from 19 patients.The patients came from the Manhattan Bowery Project and were treated at Bellevue Hospital, New York. They also included nasal cultures from 100 chronic alcoholics to show a high carrier rate (35%) of *Moraxella spp.* in the nose to explain *Moraxella* being the most common cause of bacterial corneal ulcer in the derelict alcoholic.

Lim[18], in 1977 published the results of a survey at the Singapore General Hospital. He treated 147 consecutive cases during a two and a half year period. The largest groups treated were viral (36%), bacterial (23%) and fungal (15%). The reported cases were not all culture-positive and conjunctival swabs yielding pathogenic organisms were accepted as bacterial cases.

Chaudhuri and Godfrey[19] reported management of 32 cases of clinically diagnosed bacterial corneal ulcers, 15 of which were culture-negative. These patients were admitted to the Leicester Royal Infirmary, Leicester, over the period 1981 (January) to 1982 (March).

A cornea project in Bangladesh, initiated in 1974, resulted in the publication of 48 cases of acute corneal ulcer by Katz et al[20] in 1983. The cases were treated at the Islamia Eye Hospital and the study period was not stated.

In 1985, Panhalkar et al[21] published a series of 130 corneal ulcer patients from Vellore, India, of which 20 were culture-negative. There were 141 control patients included in the study and the study period is not mentioned.

From St John Eye Hospital, Soweto, Carmichael et al[22] published 283 corneal ulcers from 274 patients in 1985.This survey was conducted over a one year period (mid 1982 to mid 1983) and the report centred around the 161 patients admitted to hospital. All cases seen during the year were included.

Masko et al[23] from Groote Schuur Hospital, Cape Town, reported a series of 48 clinically diagnosed bacterial corneal ulcers in 1986. The study period was 1983 (January) to 1984 (March).

In 1991, Upadhyay et al[24] reported 405 patients with corneal ulcers from Kathmandu, Nepal. The patients were seen between September 1985 and August 1987 (2 years).

1.2 Aims and Structure of Thesis

Ulceration of the cornea assumes many forms and many different individuals are at risk. Categorizing corneal ulcers is itself a challenge, and the management of these patients requires much individual attention and is time consuming, but very rewarding.

If relief of pain or chronic discomfort can be achieved, one can feel satisfied, and if a good visual result is attained, there is cause to celebrate.

The objects of this thesis were to accurately define and address problem areas of corneal ulceration and to improve it's management. The problem areas were defined in terms of the types of corneal ulcer most frequently seen, patients most likely to present fac s predisposing to corneal ulceration and causative microbial organisms and complications. Improved management was assessed by comparing the results achieved by conventional antibiotic therapy with those when topical steroid was added.

The thesis presented here is essentially a clinical study, but laboratory work is closely interwoven, to accurately establish the role of microorganisms in ulcerative keratitis in our patients. It includes two initial surveys of one year each , one at St John Eye hospital (St John), and one at the Johannesburg Hospital. These surveys contrast the differences in corneal ulceration in white and black patients. The initial studies which featured conventional therapy were followed by a clinical study at St John to establish the role of topical steroids in managing ulcerative bacterial keratitis, the major problem area.

Presenting samples are consecutive series of patients with the same disease, presenting for a particular form of treatment[25]. Differing severities of diseases are seen and with increasing numbers, the sample resembles, more and more, a random sample. This technique was used for the two surveys. The more familiar randomized controlled method was used for the steroid trial.

The data presented were largely those of a single observer. During the surveys (309 patients), all 170 admitted patients were managed by myself. I managed 97 of the outpatient cases, saw a further 24 on at least one occasion and only 18 outpatients were not seen by me (data were collected from patients files). The steroid study (40 patients) was done in conjunction with Y. Gelfand but the protocol for the study was designed by myself and I supervised management of all the cases.

In the third chapter dealing with predisposing factors, heights and weights were determined by nursing staff. All other measurements were done by myself when the patient was admitted. Assistance only in the analysis of the nutritional data for the published paper[26], was obtained from A. Dibisceglie, a physician at Baragwanath hospital.

1.3 References

1. Locatcher-Khorazo D, Seegal BC. *Microbiology of the eye*. St Louis: Mosby, 1972.
2. Rhodes AJ. Studies on the bacteriology of hypopyon ulcer. III.- A bacterial investigation of 120 cases of hypopyon ulcer. *Br J Ophthalmol* 1939; 23: 627-30.
3. Thygeson P. Acute central (hypopyon) ulcers of the cornea. *Californ Med* 1948; 69: 18-21.
4. Brightbill F. Central corneal ulcers. *Ann Ophthalmol* 1972; 4: 331-7.
5. Jones DB. Initial therapy of suspected microbial corneal ulcers. II. Specific antibiotic therapy based on corneal smears. *Surv Ophthalmol* 1979; 24: 105-16.
6. Liesegang TJ, Forster RK. Spectrum of microbial keratitis in South Florida. *Am J Ophthalmol* 1980; 90: 38-47.
7. Asbell P, Stenson S. Ulcerative keratitis - survey of thirty years' laboratory experience. *Arch Ophthalmol* 1982; 100: 77-80.
8. Musch DC, Sugar A, Meyer RF. Demographic and predisposing factors in corneal ulceration. *Arch Ophthalmol* 1983; 101: 1545-48.
9. Groden LR, Brinser JH. Outpatient treatment of microbial corneal ulcers. *Arch Ophthalmol* 1986; 104: 84-6.
10. Wilson LA. Acute bacterial infection of the eye: Bacterial keratitis and endophthalmitis. *Trans Ophthalmol Soc UK* 1986; 105: 43-60.
11. Gur D, Yulug N. Goz enfeksiyonlarinda bakteriyel etkenler. *Mikrobiyol Bul* 1986; 20: 145-59.
12. Ormerod LD, Hertzmark E, Gomez DS, Stabiner RG, Schanzlin DJ, Smith RE. Epidemiology of microbial keratitis in Southern California - A multivariate analysis. *Ophthalmology* 1987; 94: 1322-33.
13. Coster DJ, Badenoch PR. Host, microbial, and pharmacological factors affecting the outcome of suppurative keratitis. *Br J Ophthalmol* 1987; 71: 96-101.
14. al-Samarrai AR, Sunba MS. Bacterial corneal ulcers among Arabs in Kuwait. *Ophthalmic Res* 1989; 21: 278-84.
15. Aronson SB, Moore TE, Jr. Corticosteroid therapy in central stromal keratitis. *Am J Ophthalmol* 1969; 67: 873-96.
16. Aronson SB, Moore TE, Jr. Corticosteroids in infectious corneal disease. *Symposium on Ocular Therapy*. Leopold IH (Ed). Vol 5. CV Mosby, St Louis, 1972; 77-89.

17. Baum J, Fedukowicz HB, Jordan A. A survey of moraxella corneal ulcers in a derelict population. *Am J Ophthalmol* 1980; 90: 476-80.

18. Lim KH. Corneal ulcers in Singapore. *Singapore Medical Journal* 1977; 18: 110-3.

19. Chaudhuri PR, Godfrey B. Treatment of bacterial corneal ulcers with concentrated antibiotic eye drops. *Trans Ophthalmol Soc UK* 1982; 102: 11-4.

20. Katz NNK, Wadud SA, Ayazuddin M. Corneal ulcer disease in Bangladesh. *Ann Ophthalmol* 1983; 15: 834-6.

21. Panhalkar S, Thomas A, Alexander TA, Koshi G. Bacterial and mycotic agents of corneal ulcers in Vellore. *Ind. J. Ophthalmol* 1985 ; 33: 289-93.

22. Carmichael TR, Wolpert M, Koornhof HJ. Corneal ulceration at an urban African hospital. *Br J Ophthalmol* 1985 ; 69: 920-6.

23. Maske R, Hill JC, Oliver SP. Management of bacterial corneal ulcers. *Br J Ophthalmol* 1986; 70: 199-201.

24. Upadhyay MP, Karmacharya PCD, Koirala S, Tuladhar NR, Bryan LE, Smolin G, Whitcher JP. Epidemiologic characteristics, predisposing factors, and etiologic diagnosis of corneal ulceration in Nepal. *Am J Ophthalmol* 1991; 111: 92-9.

25. Allan JC. Learning about statistics. Macmillan South Africa (Publishers), 1982: 101.

26. Di Bisceglie AM, Carmichael TR. Factors predisposing to central corneal ulceration in a developing population. *S Afr Med J* 1987; 71: 769-70.

2.0 The Epidemiology of Corneal Ulcers

2.1 Introduction

Susceptibility to many diseases varies according to age, sex, occupation, and area of residence. Ethnic or racial susceptibilities may also exist although it is often difficult to separate these from environmental, including socio-economic factors.

In South Africa, the political situation, especially since 1948 with the birth of apartheid, created a system where whites and non-whites had been kept separate. This does not mean that whites have predominantly occupied the urban areas and blacks the rural areas. Over this period blacks have increasingly moved to the cities, currently at near one million per annum[1], but have remained distinct, living in black urban townships. Indians and mixed races (coloureds) have also lived in their own distinct residential areas and this was enforced by the laws of the country.

This situation gave rise to a fairly unique opportunity to compare diseases as they affect the different race groups, with each retaining very much it's own identity, albeit enforced. This will now change with scrapping of the controversial Group Areas Act. While most enlightened people will welcome this, some epidemiologists may well shed a tear at the removal of a structure that so comfortably lended itself to demographic research.

St John Eye Hospital (Fig. 2.1) is an integral part of the giant Baragwanath Hospital and serves as the ophthalmic department of the hospital. Baragwanath Hospital provides health facilities for the population of Soweto, a sprawling black city near Johannesburg (Fig 2.2), whose population numbered nearly a million in the 1980 census[2]. Unofficial estimates of the population are higher. Baragwanath is a referral hospital and treats patients from many other parts of the country, and occasionally further afield.

The Johannesburg Hospital was the white equivalent serving Johannesburg whose white population was calculated to be nearly 400 000 during the 1985 census[3]. It is also a referral centre for the surrounding towns and cities (Fig 2.2).

In this chapter the epidemiology of corneal ulceration will be discussed and the cases seen during one year at each hospital will be compared.



Figure 2.1 St John Eye Hospital

2.2 Patients and Methods

The study at St John Eye Hospital (St John) comprised the period from the beginning of July 1982 to the end of June 1983. Patients with corneal ulcers were divided into mild, moderate, and severe groups.

The mild group generally contained patients with corneal ulcers considered suitable for outpatient treatment. This group was treated in the outpatient department (OPD) by a number of different doctors and treatment methods varied. The OPD at St John is run by two units of about seven doctors each and the units alternate days in OPD with days spent in the operating theatres. Adequate details of all corneal ulcers and types were kept in a record book in the OPD, and this allowed the inclusion of all cases in the study.

Patients with moderate to severe corneal ulceration were admitted for intensive investigation and treatment. The severe cases had features of severity as defined by Jones[4]. These included a rapid rate of progression, a suppuration area >6mm diameter, depth of suppuration into inner 1/3rd of cornea, depth of ulcer into inner 1/3rd of cornea, perforation present or imminent, and the presence of scleral suppuration. Recording sheets were used to detail relevant history and examination, and a drawing of the cornea was made along the lines suggested by Bron[5] and Harrison[6].

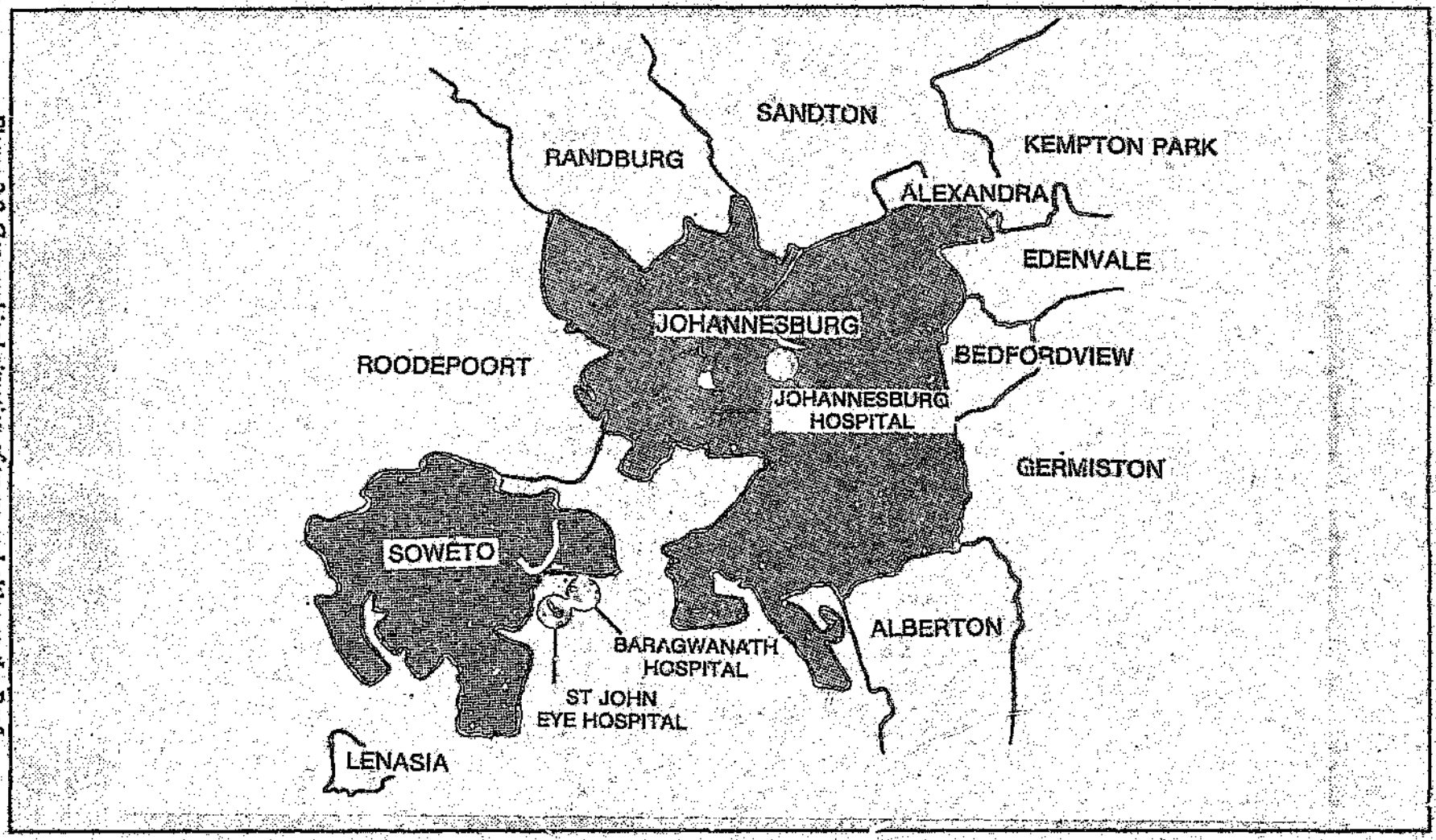

Figure 2.2 Geographical situation of towns and cities on the Reef

Anterior segment photography recorded the appearance of the ulcer on admission, discharge, and when otherwise indicated. Nearly half of the central corneal ulcers treated during the initial survey at St John appear as photographs in this thesis. Ulceration due to chemical burns and simple traumatic abrasions and superficial lacerations without secondary infection were excluded from the survey.

The study period at the Johannesburg Hospital was from the beginning of September 1983 to the end of August 1984. Similar methods were used in collecting the data and the numbers reported reflect all corneal ulcers presenting during the survey periods.

In the analysis central ulcers as a group were often compared with marginal ulcers in order to highlight the differences between a primarily infectious process and a non-infectious process. The marginal primary infection group is numerically small and has been considered as part of the marginal group for this analysis.

2.3 Classification of Corneal Ulcers

Ulcers were classified according to a method similar to that used by Kimura[7] (Table 2.1).

Types of Corneal Ulcers at St John Eye Hospital (1/7/82-30/6/83)		
Type of Ulcer	Number of Eyes	
	Mild (outpatients)	Moderate & Severe (admitted)
Central:		
Bacterial	28	91
Fungal	0	6
Viral	23	13
Other	3	0
Marginal:		
Catarrhal	30	30
Ring/melting	4	4
Mooren's	0	4
Primary infection	0	6
Other	25	5
TOTAL	113	167

Table 2.1

The classification used by Kimura was expanded to include an "other" etiological category for both central and marginal groups. Thus a central parasitic (eg. amoebic) ulcer, would be classified as "central other". A further subgroup, that of marginal primary infection was added to the marginal group to accommodate primary infections which occurred in the paralimbal area of the cornea, instead of the more usual central and paracentral areas.

It should be appreciated that most central hypopyon ulcers were diagnosed as central bacterial on admission. With microbiology results becoming available, and clinical progression, the ulcer was then reclassified into a final diagnostic category for analysis.

Examples of types of corneal ulcers:

Central Bacterial Ulcer

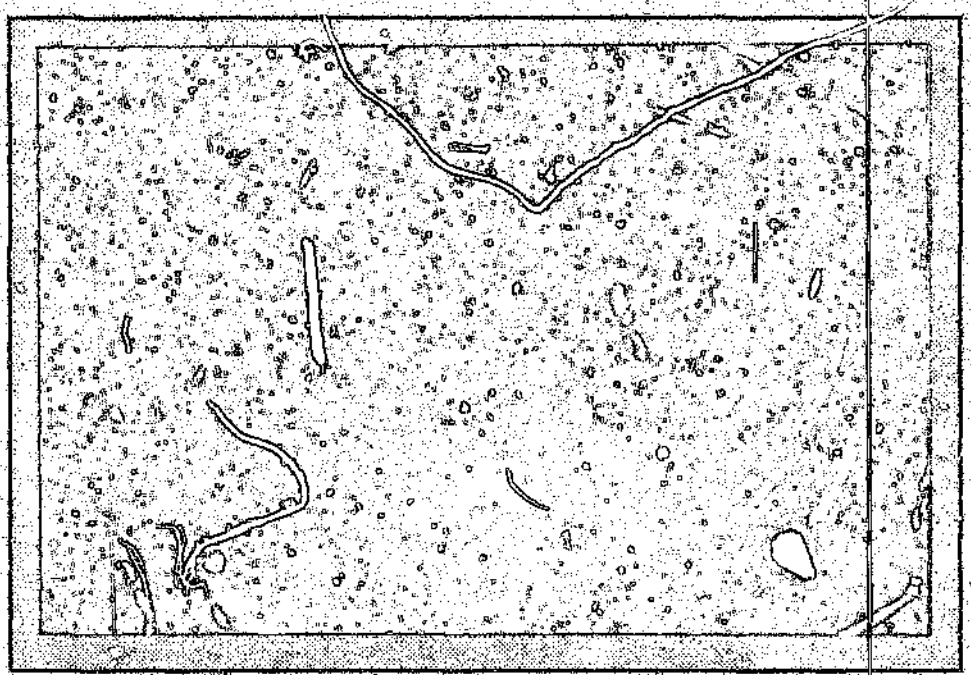

Figure 2.3

Marginal Catarrhal Ulcer



Figure 2

Marginal Ring Ulcer (Rheumatoid Disease)



Figure 2.5

Marginal Mooren's Ulcer



Figure 2.6

An example of a central fungal ulcer is Fig. 5.56 on page 161, a central viral ulcer is Fig. 5.76 on page 176, and a marginal primary infection is Fig. 5.82 on page 183.

2.4 Corneal Ulceration at St John Eye Hospital

During the 12-month-period 280 corneal ulcers from 273 patients were treated. There were seven bilateral cases.Three ulcers from OPD patients reported initially[8] were considered to be unsuitable on review and have been excluded from this analysis.

There were 113 ulcers (one bilateral) of a mild nature suitable for outpatient treatment. This group contained 17 cases admitted for various reasons (see below). There were 55 right eyes and 58 left eyes which were affected.

There were 167 ulcers (six bilateral) from 161 patients with moderate to severe corneal ulcers admitted for treatment. Some of the data presented refer only to this group which was intensively investigated. Eighty-five ulcers involved right eyes and 82 ulcers affected left eyes.

Sixty-four percent of the ulcers seen during the year were either central bacterial ulcers (119), or marginal catarrhal ulcers (60).

2.4.1 Seasonal Variation in Presentation

All cases were plotted by month, by date of admission or date of presentation. (Fig. 2.7).

There was a peak late in winter and smaller peaks just before and after mid summer. The winter peak can be seen to be due to an increase in central ulcers as the marginal ulcers showed little variation throughout the year. The peaks around summer were composed of a summation of equal numbers of central and marginal ulcers.

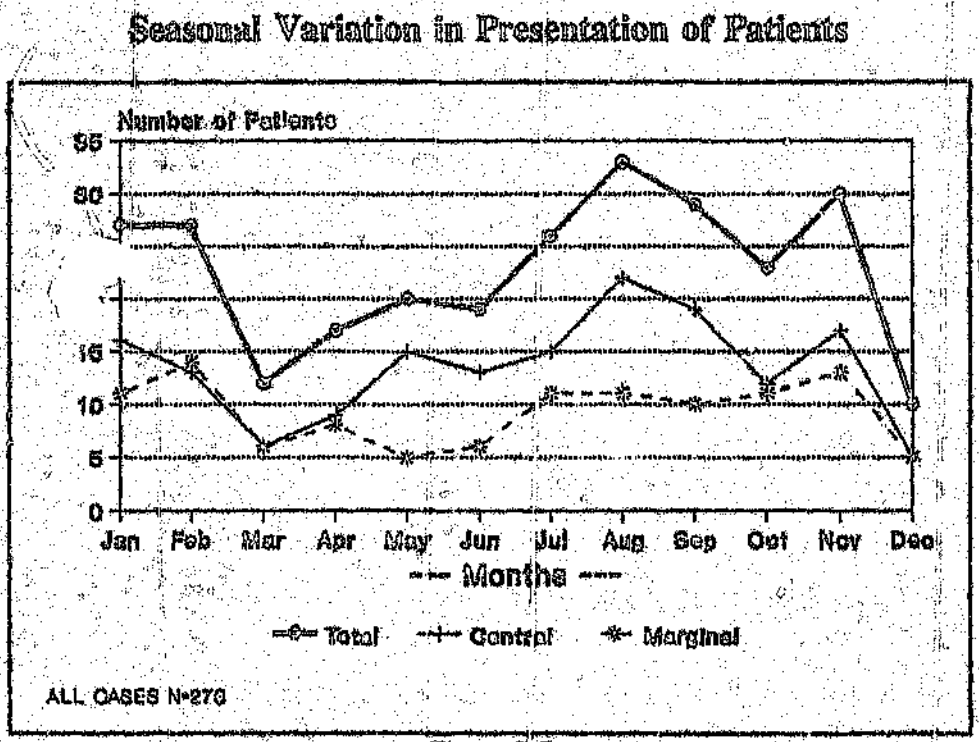

Figure 2.7

From Table 2.2 it can be seen that the winter peak reflected bacterial and to a lesser extent fungal types of central ulcer and did not apply to viral ulcers.

Seasonal Presentation: Number of Corneal Ulcer Patients by Six Month Period		
Type of Ulcer	Summer Months (October to March)	Winter Months (April to September)
Central:		
Bacterial	48	69
Fungal	2	4
Viral	18	18
Other	1	2
Marginal:		
Catarrhal	30	27
Ring	7	8
Mooren's	4	0
Primary	3	3
Other	16	13
TOTAL	129	144

Table 2.2

If the winter months (April to September) are compared with the summer months (October to March), it can be shown that there were significantly more central ulcers that present during the winter months than marginal ulcers (p less than 0,01 , Student's *t* test). There was no significant difference between these two groups in presentation during the summer months. During the winter months the monthly average for central ulcer patients was 15,5 and marginal ulcer patients 8,5. During the summer months the monthly average for central ulcer patients was 11,5 compared with 10 for the marginal ulcer patients.

COMMENT

These data support the view that infective central ulcers, occur more commonly during the winter months than do marginal ulcers where the basic underlying pathology is not infective. Marginal ulcers show a fairly uniform presentation throughout the year as might be expected. The summer peaks might in part be artifactual, and caused by cases presenting during January and February which have not presented, for various reasons, during the Christmas period.

2.4.2 Ethnic Groups

Nearly half (47%) of all the corneal ulcer patients were either Zulu or Sotho (Table 2.3). Central viral ulcers were the only type which showed a large percentage of patients other than black. The Coloureds accounted for 22% of the central viral ulcers, and these were mainly dendritic.

Ethnic Groups by Corneal Ulcer Type (Numbers)						
Type of Ulcer	Zulu	Sotho	Tswana	Xhosa	Swazi	Shangaan
Central:						
Bacterial	34	27	10	11	5	8
Fungal	0	0	1	0	1	0
Viral	5	5	2	4	3	2
Other	0	0	0	0	1	1
Marginal:						
Catarrhal	21	10	4	5	3	0
Ring	5	2	1	1	2	0
Mooren's	0	1	1	1	0	0
Primary	2	1	1	0	0	0
Other	10	4	3	4	2	0
Total	77	50	23	26	17	11

Type of Ulcer	Venda	Ndebele	Other	Coloured	Indian	No Data	Total
Central:							
Bacterial	1	7	6	4	1	3	117
Fungal	0	1	1	1	1	0	6
Viral	5	0	0	8	1	1	36
Other	0	0	0	1	0	0	3
Marginal:							
Catarrhal	1	3	4	2	0	4	57
Ring	0	2	0	1	0	1	15
Mooren's	0	1	0	0	0	0	4
Primary	0	0	1	0	1	0	6
Other	2	0	1	3	0	0	29
TOTAL	9	14	13	20	4	9	273

Table 2.3

A further breakdown was done, in which only cases resident in Soweto were analyzed (Table 2.4). Population data for Soweto are available and incidence rates were calculated. It can be seen that much of the variation in numbers can be explained on the basis of differing population sizes and the incidence of central bacterial ulcers is fairly constant.

The high incidence of marginal catarrhal ulcers in Zulus should be noted and this group might be more susceptible to this disease.

Number of Soweto Cases by Ethnic Group with Incidence Rates (per 100 000 population)						
Ethnic group Population	Zulu 255540	Sotho 191640	Tswana 145140	Xhosa 79860	Swazi 54900	Shangaan 52100
Central:						
Bacterial	17	12	5	6	3	3
Rate	6.7	6.3	3.5	7.5	5.5	5.8
Fungal	0	0	0	0	0	0
Viral	3	1	1	3	0	1
Other	0	0	0	0	0	0
Marginal:						
Catarrhal	15	4	3	1	2	0
Rate	5.9	2.1	2.1	1.3	3.6	
Ring	2	1	0	1	0	0
Mooren's	0	0	0	0	0	0
Primary	1	1	0	0	0	0
Other	6	2	2	3	0	0
TOTAL	44	21	11	14	5	4

Ethnic group Population	Venda 31200	Ndebele 13160	Other 3980	Coloured No data	No data	Total 827520
Central:						
Bacterial	1	2	2	1	2	54
Fungal	0	0	0	0	0	0
Viral	3	0	0	0	0	12
Other	0	0	0	0	0	0
Marginal:						
Catarrhal	1	1	3	1	2	33
Ring	0	0	0	0	1	5
Mooren's	0	0	0	0	0	0
Primary	0	0	0	0	0	2
Other	0	0	0	0	0	13
TOTAL	5	3	5	2	5	119

Population data source:
Geographical distribution of the population in conjunction with Population census of 1980, Report 02\80\01.
Department of Health, Welfare and Pensions, Pretoria.

Table 2.4

2.4.3 Age

There was no significant difference between the mean ages of the central and marginal groups. The mean age of the central group was 40.7 years (standard error 1,9) and the marginal group 36.6 years (standard error 1,8).

The mean age varied according to the type of ulcer (Table 2.5). There was a significant difference between the mean ages of the central bacterial and central viral groups (p less than 0.05, Student *t* test), with the central viral group being younger, but no other significant differences were found.

Mean Age (years) and Standard Error by Group				
Type of Ulcer	Mean Age	Standard Error	Number in Group	Bilateral Cases
Central:				
Bacterial	42.4	2.2	117	2
Fungal	63.3	4.0	6	0
Viral	32.8	4.0	36	0
Other	26.3	13.8	3	0
Marginal:				
Catarrhal	40.5	2.6	57	3
Ring	44.9	5.8	15	1
Mooren's	39.3	12.9	4	0
Primary	30.5	7.4	6	0
Other	25.1	3.3	29	1

Table 2.5

Central ulcers showed a peak in patients of under 10 years and then the numbers rose between the ages of 20 to 70 years (Fig 2.8).

Marginal ulcers (Fig 2.9), mainly peak between the ages of 20 and 60 years, where the numbers are fairly constant.

Age of Central Corneal Ulcer Patients

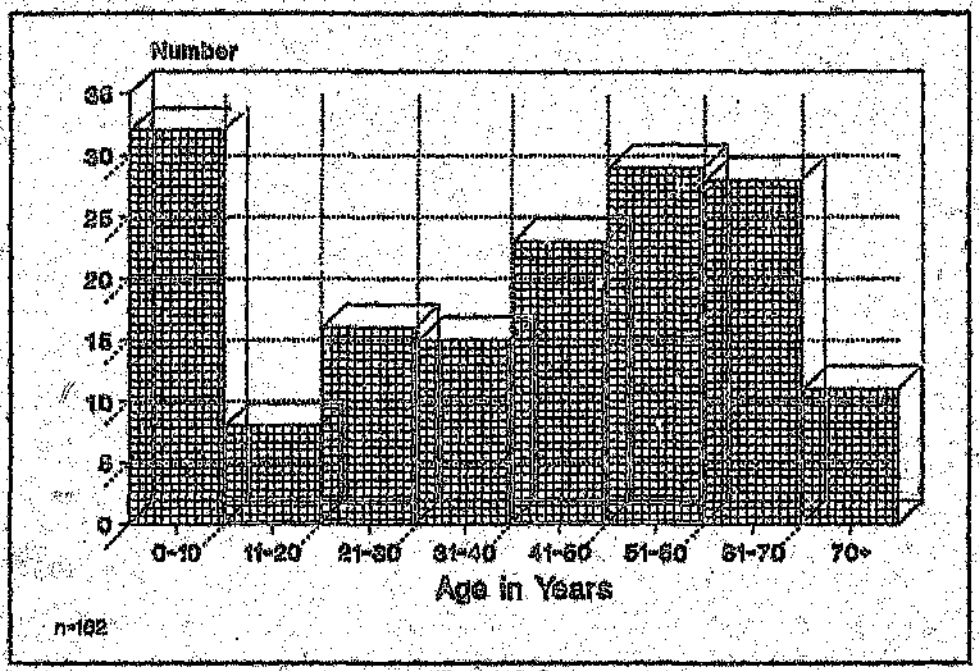

Figure 2.8

Age of Marginal Corneal Ulcer Patients

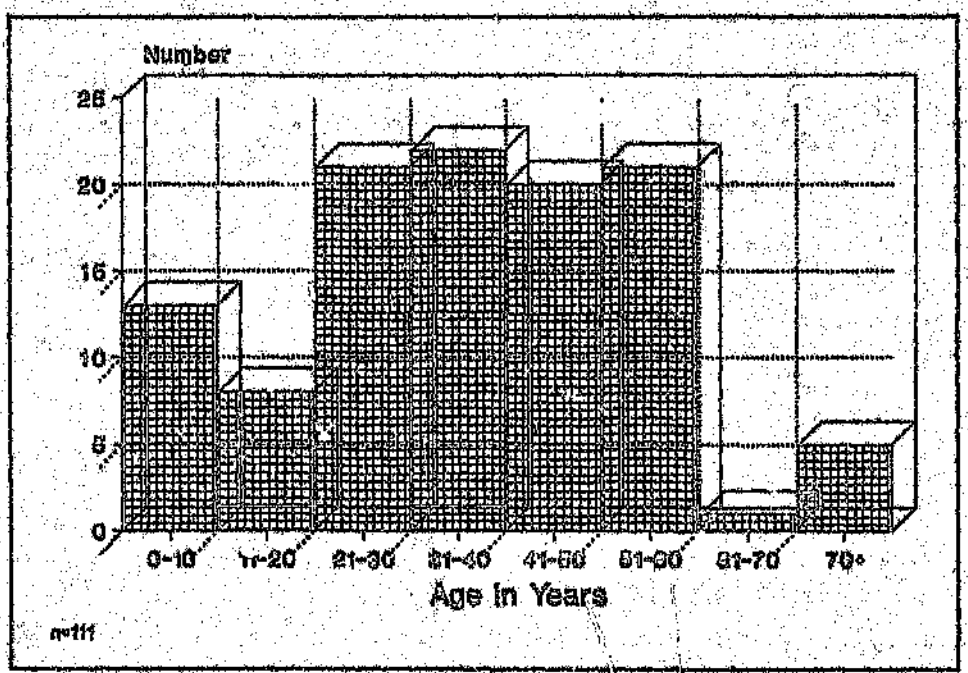

Figure 2.9

Incidence rates were calculated using population data from the 1985 census (Table 2.6). The population counted was the blacks in the Johannesburg urban area (including Soweto), and the total number of persons was similar to the 1980 census total for Soweto. For central ulcers (Fig. 2.10), the incidence rate increased steadily after the age of about 35 years. For marginal ulcers (Fig. 2.11), the incidence rate rose from age 20 years to peak in the age groups 45-64 years. The peak in the age group 75 years and over is probably artifactual and is due to 4 cases occurring in this group.

Age and Incidence Rates of Central and Marginal Corneal Ulcer Patients				
Age Group Years	Number of Central	Rate per 10 000	Number of Marginal	Rate per 10 000
0 - 4	20	2.8	7	1.0
5 - 9	12	1.8	5	0.8
10 - 14	3	0.4	4	0.5
15 - 19	3	0.4	4	0.5
20 - 24	10	1.1	8	0.9
25 - 34	12	0.7	22	1.3
35 - 44	20	1.9	20	1.9
45 - 54	27	3.4	22	2.8
55 - 64	27	5.5	13	2.6
65 - 74	18	7.5	2	0.8
75 and over	10	13.0	4	5.2
TOTAL	162		111	

Population data source:
Central Statistical Services, Population Census 1985.
Report no. 02/85/02.
Department of Health, Welfare and Pensions, Pretoria.

Table 2.6

Incidence Rates of Central Ulcer Patients by Age

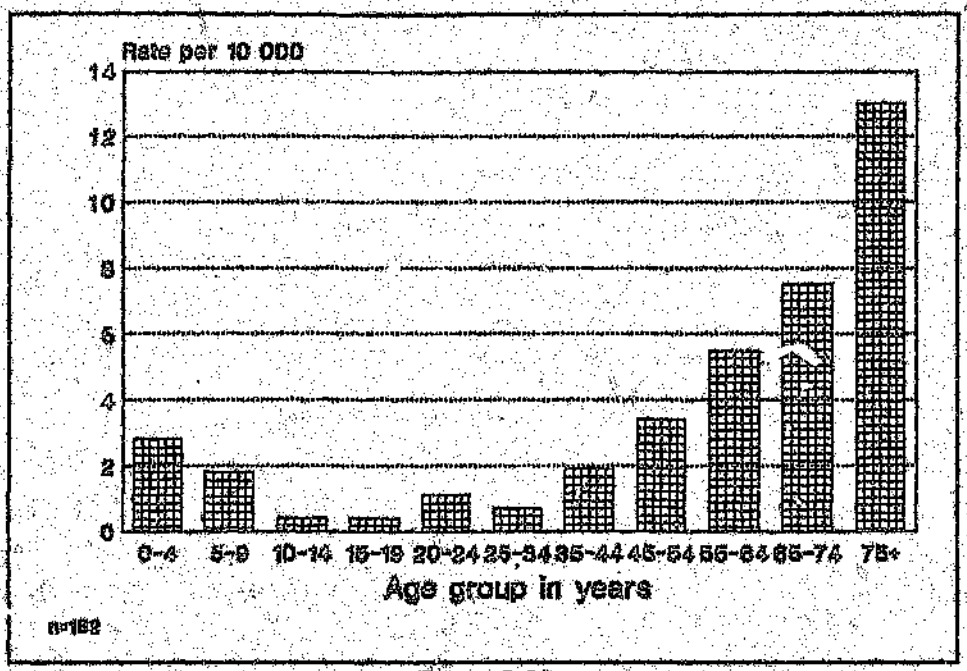

Figure 2.10

Incidence Rates of Marginal Ulcer Patients by Age

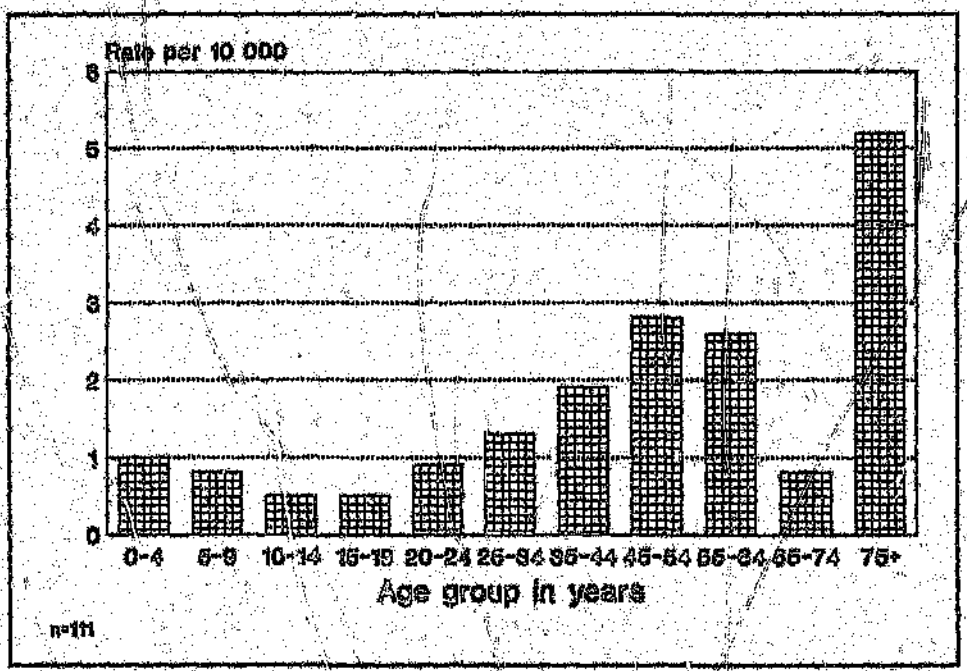

Figure 2.11

2.4.4 Sex

Of the 273 patients, 78% were male. The proportions varied according to type of ulcer as shown in Table 2.7.

Eighty percent of the central group were males compared with 74% for the marginal group. This difference is significant (p less than 0.05, Chisquare with Yates correction factor), and is due to the 85% males in the central bacterial group (Fig.2.12 and 2.13 on next page).

Sex of Corneal Ulcer Patients by Group (Numbers)			
Type of Ulcer	Male	Female	Total
Central:			
Bacterial	100	17	117
Fungal	4	2	6
Viral	24	13	36
Other	2	1	3
Marginal:			
Catarrhal	44	13	57
Ring	11	4	15
Mooren's	3	1	4
Primary	2	4	6
Other	22	7	29
TOTAL	212	61	273

Table 2.7

COMMENT

There was a preponderance of males in almost all the groups with this preponderance being more marked in the central bacterial ulcers. Predisposing factors are examined in Chapter 3 and these explain some of the reasons for the large number of males seen. The population of Soweto showed a population of 827 520 in the 1980 census[4], and this consisted of 425 960 males and 401 560 females. The small male excess does not explain the difference in numbers between the sexes and raises the question whether there is a difference in the likelihood of each sex to present for treatment, a factor which is not known.

Sex of Central Corneal Ulcer Patients

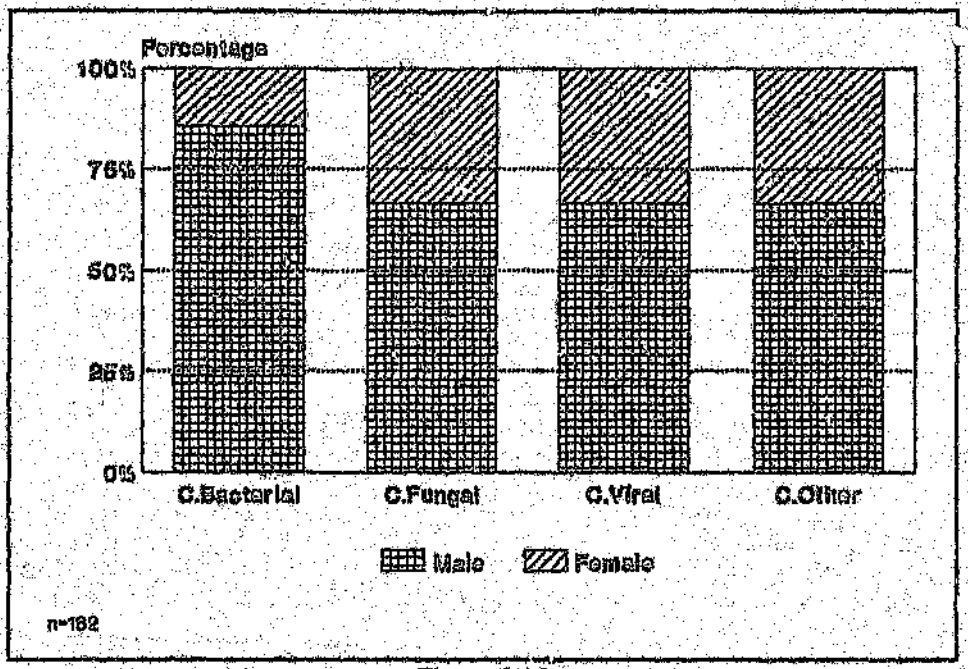

Figure 2.12

Sex of Marginal Corneal Ulcer Patients

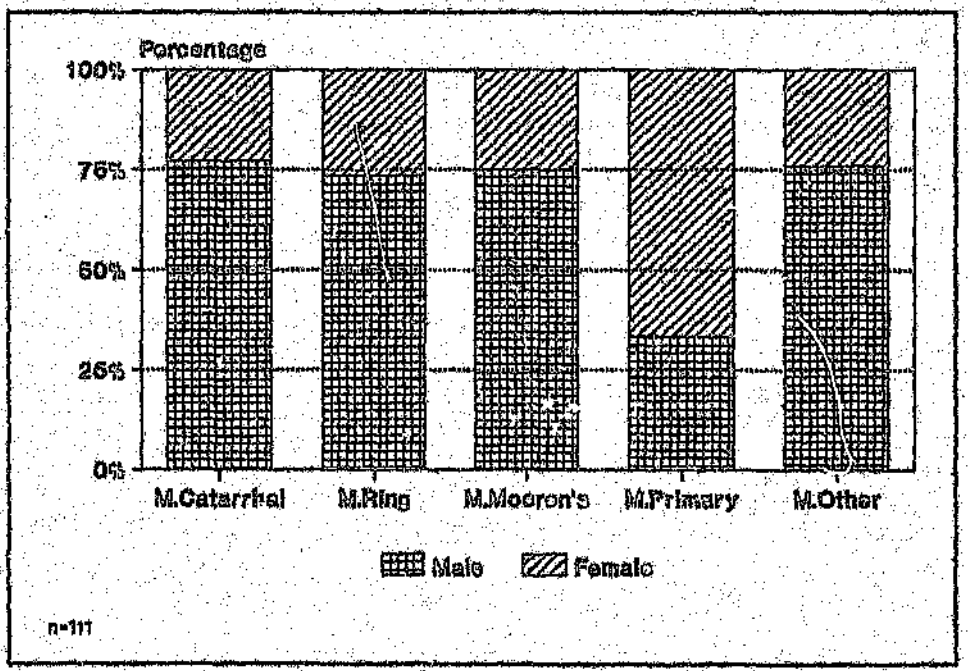

Figure 2.13

2.4.5 Residence and Occupation

Of the OPD cases (n=107, no data in 5 patients), 55% lived in Soweto, 38% in urban Transvaal areas, and 7% lived on farms or smallholdings.

Of the admitted patients (n=161), 39% resided in Soweto, 48% in other urban areas within the Transvaal province and 13% in rural areas of the Transvaal.

Details regarding occupation were noted for the admitted adult patients (Table 2.8). It can be seen that about half were manual labourers of which only 8 patients worked on farms. A quarter of the patients were unemployed.

Occupation of Adult Corneal Ulcer Patients at St John Eye Hospital		
Type of Work	Number	Percentage
Manual labourer (non farm)	61	47
Manual labourer (farm)	8	6
Unemployed	33	25
Domestic worker	16	12
Pensioner	11	8
Clerical	2	2
TOTAL	131	100

Table 2.8

COMMENT

The patients treated at St John were mostly an urban population (87% of admitted patients, 93% of OPD cases), which partly explains the low incidence of fungal keratitis.

More of the OPD patients lived in Soweto suggesting that many of the more severe cases were referred from peripheral hospitals. This influences the delay in presentation for treatment.

As most patients were manual labourers, exposure to episodes of ocular trauma could be expected to be high.

2.4.6 Treatment Prior to Admission

Of the admitted patients, nearly half had been treated with topical antibiotic before presentation (Table 2.9).

Local Treatment of Corneal Ulcers before Admission				
Central Group (110 ulcers)				
	Bacterial	**Fungal**	**Viral**	**Total**
Antibiotic:				
Definite	16	3	2	21
Probable	21	0	5	26
plus Steroid	2	0	0	2
Steroid only	3	0	1	4
Antiviral	0	1	0	1
Other	24	0	2	21
TOTAL	66	4	10	75

Marginal Group (57 ulcers)						
	Catarrhal	**Ring**	**Mooren's**	**Primary Infection**	**Other**	**Total**
Antibiotic:						
Definite	5	4	1	3	1	14
Probable	7	2	1	0	1	11
plus Steroid	1	0	0	0	1	2
Other	6	3	0	0	1	10
TOTAL	19	9	2	3	4	37

Table 2.9

Note: Antibiotic treatment was considered definite where the patient could produce the medication or knew its name. Probable denoted a patient using ointment, or drops and ointment which had been obtained from a medical source (doctor, chemist or clinic). The category "other" was used to indicate that the medication consisted of drops only, which may or may not have contained antibiotic.

In 11 cases, oral antibiotics had certainly been given in addition to local treatment. In a further five cases the description of the tablets suggested that they were antibiotics. Only one patient was receiving systemic steroid therapy and this was a case of systemic lupus erythematosis with keratitis sicca who developed a pseudomonas corneal ulcer.

COMMENT

Forty-five percent of central group and 47% of the marginal group had been pretreated with antibiotic, either definitely or probably. Sixty-eight percent of central ulcers and 65% of marginal ulcers had used a form of treatment before presentation.

This refutes the concept that we saw mainly untreated cases at St John and partly explains previous difficulties in isolating organisms from corneal ulcers.

2.4.7 Delay before Presentation to Hospital (Admitted Ca

The overall mean delay between the onset of symptoms and presentation to hospital was 16 days, but this varied, depending on the ulcer type. It was previously reported that there was a significantly greater delay in the case of the marginal catarrhal group than the central bacterial group (p less than 0.05, Student's t test)[8].

To try to explain the differences in delay between the groups, a further analysis was done correlating pain on presentation and initial (admission) visual acuity with the delay.

One hundred and forty eyes were included in which there were data for delay (days) before presentation, pain on admission, and initial visual acuity. Excluded from this analysis were 27 eyes from 25 patients of which 19 patients (two bilateral) were small children, and in whom the relevant data were not obtainable.

The delay was estimated by asking the patients when the problem with the eye began, and the estimated duration eg. three weeks was converted to days. The presence or absence of pain on admission was noted, and if the patient volunteered that the eye was extremely painful, it was noted as severe pain. The initial visual acuities were measured on admission by a single observer.

There was a marked difference in delay before presentation depending on ulcer type (Table 2.10) .

Delay Before Presentation for Treatment		
Type of Ulcer	Mean (days)	Number
Central:		
Bacterial	12	76
Fungal	26	6
Viral	9	10
Marginal:		
Catarrhal	18	28
Ring	39	11
Mooren's	15	2
Primary	38	4
Other	11	3

Table 2.10

The mean delay for the central group was 12,7 days and for the marginal group 23,6 days. The marginal group showed a significantly longer delay before presentation to hospital (p less than 0,05, Student's *t* test) .

There was no correlation between the presence of pain on admission and the duration of delay before presentation. The initial visual acuities were analyzed using the numerical system[9] and the method is fully described in Chapter 6. The average vision for the central group was 4,5 and the marginal group was 8,1. The initial vision in the marginal group was better and the difference highly significant (p less than 0,0001).

COMMENT

There are many variables which might affect the speed with which a patient presents to hospital for treatment. Some did not have transport or sought help which was not effective (half the cases were pretreated with antibiotics). The appearance of the eye to the patient, discharge, redness etc. might affect the decision to go to hospital. Many marginal catarrhal ulcers will not heal on antibiotic alone as topical steroid is necessary[10] and the initial treatment period with antibiotic can delay the eventual presentation. The rapid deterioration in the eye seen with severe central bacterial ulcers probably made this group present quickly but this aspect is difficult to quantitate.

It would seem likely that a chronic ulcer might develop a secondary infection causing

pain and presentation and this might explain why there was no difference between the two groups in pain on presentation.

Early loss of visual acuity with central corneal ulceration seems to be an important factor determining the time of presentation.

2.4.8 OPD Visits and the Duration of Inpatient Treatment

Of the OPD cases, 17 were admitted; five of these lived too far away for OPD management, three dendrites were large geographic ulcers and were admitted for inpatient antiviral treatment, two patients had bilateral pathology only ulcerative in one eye, and one patient had bilateral mild ulceration. Four patients were admitted for surgery (one child for examination under anaesthetic, one enucleation of an eye with endophthalmitis and no light perception, one conjunctival flap and one lid repair for lid notching).

The remaining 95 patients attended OPD a total of 241 times with an average 5 visits. The average was similar for each type of ulcer.

Patient days were calculated for all moderate and severe admitted cases, by subtraction of the date of admission from the date of discharge. Thus the day of admission and the day of discharge were counted as one complete day.

The entire group had an average of 14 days inpatient treatment. The average for the central group was 14 days (standard error 0.83), and for the marginal group was 15 days (standard error 2.03). There was no significant difference between these two groups.

The average varied according to type of ulcer (Table 2.11) but the limited number of cases in some groups makes further statistical analysis unreliable.

Average Number of Patient Days by Group		
Type of Ulcer	Mean (days)	Standard error
Central:		
Bacterial	13	0.85
Fungal	23	5.17
Viral	17	2.36
Other		
Marginal:		
Catarrhal	14	2.54
Ring	13	1.81
Mooren's	39	17.15
Primary	15	3.45
Other	7	0.51

Table 2.11

Thirty percent of patients (48 of 161) required 1 week of inpatient treatment and only 16% (24 of 161) stayed longer than 3 weeks (Fig 2.14).

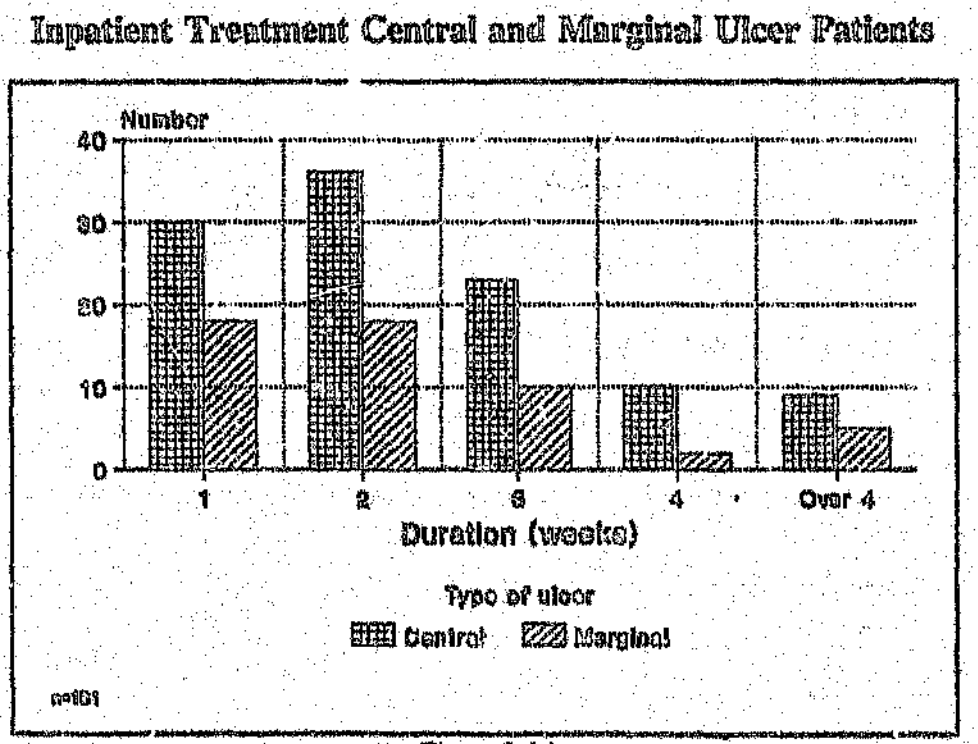

Figure 2.14

COMMENT

Corneal ulcer patients constitute a problem in terms of bed occupancy. At one stage 20 beds of the 110 bed hospital were occupied by corneal ulcer patients. The total duration of bed occupancy for the moderate and severe group was 2380 days or 6,5 years.

2.4.9 Vision in the Fellow Eye

The seven bilateral ulcers shown above did not do justice to the amount of bilateral ocular pathology seen.

The admission vision in the fellow eye was measured in 138 of the admitted patients. Excluded from this analysis were 29 eyes, including all bilateral cases (12 eyes) , 16 children in whom vision could not be measured, and a schizophrenic patient who could not communicate effectively. All excluded fellow eyes appeared normal on examination.

One third (33%) of the 138 patients had vision in the fellow eye of 6/24 or worse. More than half (54%) of the fellow eyes showed pathology. Central ulcer patients tended to show central pathology in the fellow eye and marginal ulcer patients peripheral scarring and/or infiltrates in the fellow eye.

Of the 92 eyes with vision of 6/6 to 6/18, 35% showed abnormality, not always reducing the vision. There were 16 eyes showing climatic droplet keratopathy (CDK) , seven showing peripheral scarring, three with central corneal scarring and single instances of peripheral pannus, diabetic retinopathy, cataract, peripheral infiltrates (active), peripheral vernal follicles, and old uveitis.

In the group with vision 6/24 to 6/60, 15 of the 17 eyes showed pathology. There were six with CDK, four central corneal scarring, one peripheral scar and one had peripheral infiltrates. One patient had keratitis sicca, one a peripheral conjunctival flap and one had central corneal scarring with a leaking corneal fistula and shallow anterior chamber.

In the group with count fingers vision all 11 showed abnormality. Two had central scarring, one peripheral scarring and one had peripheral infiltrates and one amblyopia due to high myopia. The others were combinations of; CDK and dislocated lens, central scarring with CDK, corneal graft and cataract, central scarring with leukoma adherens and cataract, CDK with corneal graft, CDK with cataract.

In the group with hand movement vision, the cause of visual loss could not be established in one patient, one showed central scarring with leukoma adherens, and one had a central scar from an old corneal laceration with peripheral scarring suggestive of previous marginal corneal pathology.

In the group with light perception vision, two showed dense central corneal scarring, two had cataracts, and two had central corneal scars with leukoma adherens.

In the group with no light perception, there were four phthisical eyes, three sockets, and one eye had dense corneal scarring. In one case the cause of vision loss was not apparent.

To attempt to show a difference in vision in the fellow eye in older patients compared with younger patients, visions in patients 40 years of age and younger were compared with those over 40 years (Fig 2.15).

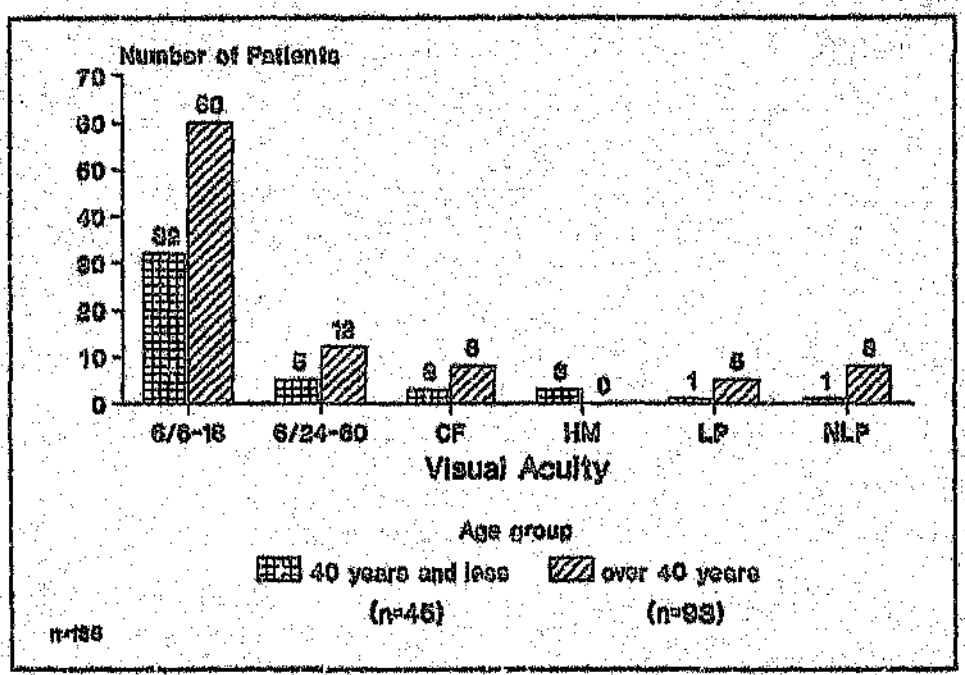

Figure 2.15

It can be seen that although there were more patients with poor vision (less than 6/18) in the older group, this was largely due to the fact that the number of patients in this older group was about double that of the younger group. Seventy one percent of the younger group had a vision of 6/18 or better versus 65% for the older group (no significant difference).

This finding tends to negate the clinical impression that poor vision in the fellow eye is confined to the older patients.

2.5 Corneal Ulceration at the Johannesburg Hospital

During the 12-month-period 36 corneal ulcers were treated. All were unilateral and *all* patients were white.

There were 27 cases of a mild nature which were treated at outpatients and nine moderate to severe cases admitted for treatment (Table 2.12).

Types of Corneal Ulcers at the Johannesburg Hospital (1/9/83 - 31/8/84)		
Type of Ulcer	Number of Eyes	
	Mild (outpatients)	Moderate & Severe (admitted)
Central:		
Bacterial	0	4
Fungal	0	0
Viral	23	2
Other	1	1
Marginal:		
Catarrhal	2	1
Ring/melting	0	0
Mooren's	0	0
Primary infection	0	1
Other	1	0
TOTAL	27	9

Table 2.12

The mean age for the admitted cases was 64 years and for the OPD cases 48 years (no data two cases) . There were six females and three males in the admitted group, and 20 males and five females (no data two cases) in the OPD group.

Occupations for both groups are shown in Table 2.13.

Occupation of Adult Corneal Ulcer Patients at the Johannesburg Hospital		
Type of Work	Number	Percentage
Manual labourer (non farm)	1	3
Manual labourer (farm)	0	0
Unemployed	9	25
Domestic worker	1	3
Pensioner	12	33
Clerical	7	20
Scholar	3	8
No data	3	8
TOTAL	36	100

Table 2.13

Of the admitted patients, five patients lived in Johannesburg and four originated in urban Transvaal areas around Johannesburg. Of the OPD cases 17 lived in Johannesburg and seven in urban Transvaal areas. There were no data in 3 cases.

For the admitted cases, the mean delay before presentation to hospital was 24.5 days.

Seven of the nine patients (78%) had received topical antibiotics prior to admission. Six had definite antibiotic treatment of which one had also received topical steroid and one had also received topical antiviral therapy. One patient had probable antibiotic (ointment prescribed by an ophthalmologist) and the other two had used drops only.

The other eye was not normal in three of the nine cases. In one the vision in the other eye was counting fingers at 1 m due to retinal disciform degeneration. Another had a corneal graft with vision of 6/9. One was an only eye, the other eye having been enucleated as a child.

COMMENT

The white patients showed a relatively small number of corneal ulcers over a 1 year period, most of which (85%) were viral. Twenty were dendritic ulcers and were treated at OPD. Overall, males outnumbered females 2:1.

Sixty one percent of the patients lived in Johannesburg and the remainder in urban areas in the Transvaal. Half of the more severe cases (admitted) were not Johannesburg

residents ie. referral cases. A quarter were unemployed and a third were pensioners. Twenty percent did clerical work.

2.6 Comparison Between Corneal Ulcers at St John Eye Hospital and the Johannesburg Hospital

There was a marked difference in the number and type of corneal ulcers seen at a white hospital compared with a black hospital.

The overwhelming numbers of corneal ulcers at St John must be seen against the larger population at risk and availability of alternative medical treatment. The drainage population might be considered as being the Soweto population (827 520 in 1980) plus a proportion of the population in urban areas around Soweto.

This can be compared with a white population of Johannesburg of 376 933 (1985 census) plus a proportion of the population of urban areas around Johannesburg.

In addition, many whites sought medical attention from the private sector and certainly the numbers seen at the Johannesburg Hospital less accurately reflect total pathology than the numbers at St John Eye Hospital. In 1982 there were 19 clinics in Soweto, 8 of which provided curative services, and 16 private practitioners[1].

Bearing in mind the above, population and alternative treatment might account for a difference of approximately four times the numbers. In fact the incidence of corneal ulceration in blacks, coloureds, and Asians was nearly 8 times as high as whites. Blacks accounted for more than 90% of the patients at St John.

There was a difference in the types of ulcer seen at the two hospitals (Fig.2.16 and 2.17).

Corneal Ulcer Types St John Eye Hospital

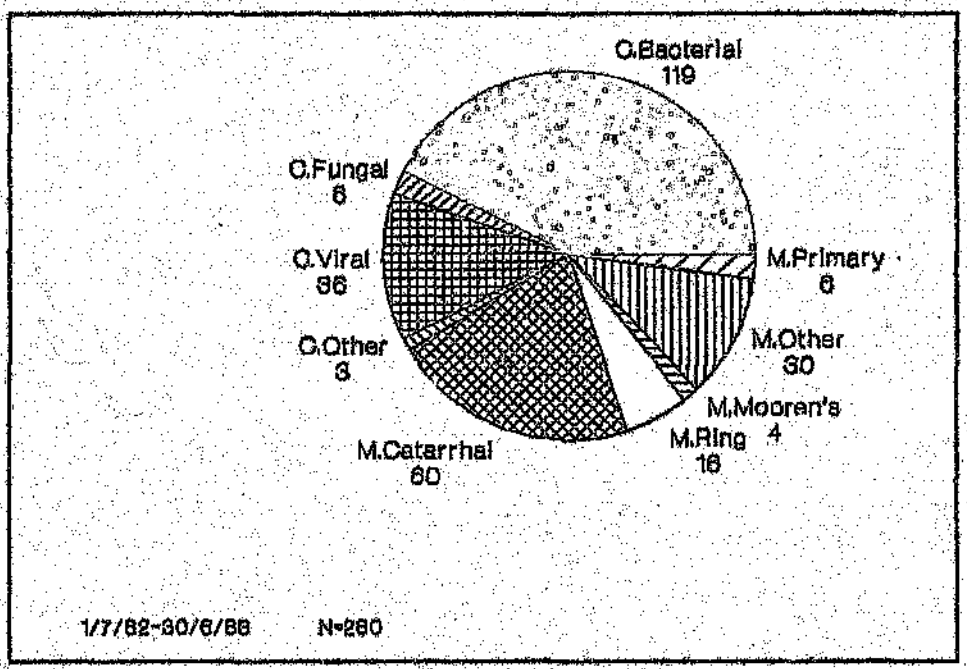

Figure 2.16

Corneal Ulcer Types Johannesburg Hospital

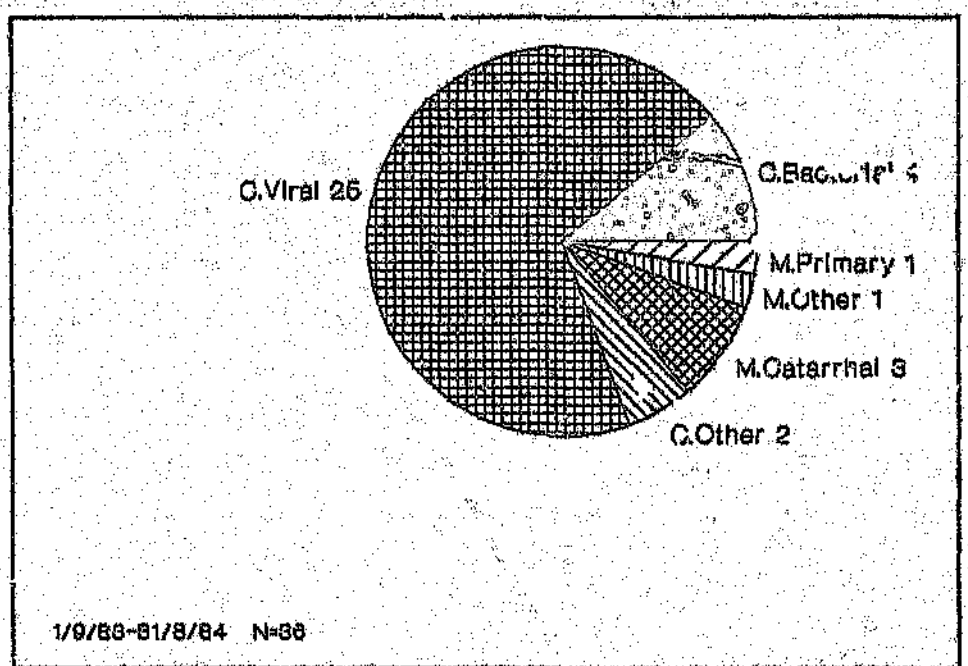

Figure 2.17

At St John the ulcers were mainly of the central bacterial and marginal catarrhal types, while in the white population, viral keratitis was the most common with central bacterial a distant second. At both hospitals fungal keratitis was uncommon.

The mean age for the Johannesburg patients was 52 years (34 patients, no data in two cases) and for the St John patients was 39 years (273 patients). The Johannesburg patients were significantly older (p less than 0.005, Student *t* test).

Males predominated in both hospitals and for most groups except for the admitted cases at Johannesburg where the numbers were small.

In both hospitals most OPD cases resided in he adjacent urban area, Soweto and Johannesburg, and the severe, admitted cases showed a higher number of referral cases.

The patients seen at St John were mostly manual labourers in urban areas while Johannesburg hospital patients were mostly pensioners. A quarter from each hospital were unemployed.

In both areas pretreatment with antibiotic was common . Of admitted patients, half at St John and more than 2/3rds at Jehannesburg, were pretreated with antibiotic.

Vision in the fellow eye was poor in about 1/3rd of admitted patients at both hospitals.

2.7 Discussion

The differences in corneal ulceration, between black and white patients were so vivid that it was considered useful to include a comparative survey.

The pattern of ulceration differed with mainly central bacterial and marginal catarrhal ulcers in black patients, and viral keratitis in white patients. It should not be assumed that the black patients were immune to viral keratitis, as stromal, disciform keratitis, presumably herpetic, was commonly seen at St John OPD.

Seasonal variation in presentation is, to an extent, determined by referral patterns from surrounding hospitals and clinics. It is interesting that marginal ulceration had a fairly even presentation throughout the year, while central ulcers showed an excess during the winter months, (dry, cold, and windy in Johannesburg).

Liesegang and Forster[12], reviewing 663 cases, found more of a seasonal variation with fungal than bacterial ulcers. However, both types showed a peak during the dry and windy months in Miami, Florida, with a peak in November. Ormerod et al[13], in reviewing 242 ulcers, found a peak in autumn and early winter.

Ethnic groups presenting, largely reflected their distribution in the population at risk. An exception was central viral ulcers, mainly dendritic, which occurred more commonly in patients of mixed race (coloureds). It is possible that whites are genetically predisposed to dendritic keratitis and coloureds show a transition between blacks and whites. Marginal catarrhal ulceration was commonly seen in black patients, particularly the Zulu.

Ormerod et al[13], suggested a predilection of nonpseudomonal gram-negative bacillary infection for black patients, and *Pseudomonas aeruginosa* infection for Hispanics. Whether this was genetically based or due to other factors is not known.

Age analysis shows the age groups which might be at high risk and require further investigation. Predisposing factors are closely related to the age of presentation eg. corneal trauma occurring in a young male labourer may result in a central bacterial ulcer as might a degenerative condition, like climatic droplet keratopathy, in an older patient. The use of incidence rates illustrates the difference in analyzing age groups with and without population data. The risk of developing central corneal ulceration clearly increased with age, after 35 years, and the numbers of children with this condition can be seen in perspective. For marginal ulceration, the high risk age groups appear to be those between 25 and 64 years of age with a peak toward the older patients in this group.

There are no published incidence rates for suppurative ulcers, but most of the larger studies showed mean ages of 45 to 55 years for their patients[14-17]. The series from England[18], showed a peak in older patients with a mode in the 61-80 year age group. Several studies showed bimodal peaks. Musch[19], in 224 patients, showed peaks in the 20-29 and 65-74 year groups, and Coster[20], peaks in the 20-30 and 60-80 year groups. Coster related the peaks in his study to various predisposing factors eg. trauma in the young group and pre-existing Herpes simplex keratitis in the older group. Ormerod[13], showed a peak in the under ten-year-olds and then a steady rise between 20 and 69 years of age.

An excess of males was present almost throughout the two surveys and the proportions

for each ulcer type were remarkably similar. As previously mentioned, this might reflect a social difference in males being more likely to present for treatment. It might also be related to occupation.

In reviewing the epidemic of almost 4000 documented cases of acute haemorrhagic conjunctivitis presenting to St John for treatment between March and May 1982[11], it was found that males outnumbered females by 2 to 1. This was attributed to a need by the male patients to provide adequate sick notes for work. In 80 patients presenting to St John for treatment of vernal keratoconjunctivitis, Dahan and Appel[21], found 75% of the children to be male.

The available figures from the literature[12-15,20] suggest that around 70% male predominance is usual for corneal ulceration. With contact lens related ulcers being widely reported it is likely that more female cases will be seen, and in Groden's series of 26 patients[16], there was an equal sex ratio. This series contains ten patients wearing cosmetic extended wear soft lenses, eight of whom were female.

Pretreatment with antibiotics was very common. It can be expected that about half of St John patients and more at Johannesburg have been pretreated, and this affects the likelihood of culturing the bacteria responsible (Chapter 4).

It is of interest to note that in a Cape Town study[14], Maske also found half the patients to have been pretreated with antibiotic. Liesegang[12], noted that 25% of their fungal keratitis patients were pretreated with a topical steroid.

The delayed presentation of patients for treatment was related to prior treatment, and the retention of good vision in the eye. Patients sought assistance in a manner most convenient to them, and, if this was not successful, presented to a higher level of the health structure. If good vision was retained, there was less anxiety and pressure to seek definitive therapy. This behaviour pattern is what we try to produce in our patients and must be accepted as an inevitable consequence of a system designed to protect referral centres from being overwhelmed by trivia. Education of medical personnel at primary health care level could assist in timeous referral of severe cases.

There is no question that corneal ulceration at St John constituted a problem in terms of time in OPD and bed occupancy. Corneal ulcers accounted for 5% of admissions to St

John (from admission records). Most patients could be treated at OPD with two or three visits and the more severe cases could mostly be healed within two weeks of hospitalization, although the latter also required follow-up at OPD after discharge.

Chaudhuri[18], showed that 54% of their patients healed in one week of inpatient treatment and 82% within two weeks of admission. The time for healing was related to many variables and will be discussed later.

At first glance, the amount of bilateral ocular pathology seen in the admitted patients at St John, must surely testify to a low standard of ocular health care in the urban Black. It was thus interesting that at the Johannesberg Hospital, bilateral ocular pathology was also not uncommon, although the numbers were too small to generalize.

2.8 References

1. Bureau of Market Research of Unisa. In: *Recommendations by the Pharmaceutical Manufacturers' Association of South Africa* , Revised edition 1989: 7.
2. Central Statistical Services. Population Census 1980. Sample Tabulation: *Geographical distribution of the population.* Report No. 02-80-01: 184.
3. Central Statistical Services. Population Census 1985. *Sample Tabulation: Age by development region, statistical region and district.* Report no. 02-85-02: 105, 509.
4. Jones DB. Initial therapy of suspected microbial corneal ulcers. II. Specific antibiotic therapy based on corneal smears. *Surv Ophthalmol* 1979; 24: 106.
5. Bron AJ. A simple scheme for documenting corneal disease. *Br J Ophthalmol* 1973; 57: 629-34.
6. Harrison SM. Grading corneal ulcers. *Ann Ophthalmol* 1975; 7: 537-42.
7. Kimura SJ. Corneal ulcers. In: Infectious diseases of the conjunctiva and cornea. *Symposium of the New Orleans Academy of Ophthalmology.* St Louis: Mosby, 1963: 88-102.
8. Carmichael TR, Wolpert M, Kournhof HJ. Corneal ulceration at an urban African hospital. *Br J Ophthalmol* 1985; 69: 920-6.
9. Carmichael TR, Gelfand Y, Welsh NH. Topical steroids in the treatment of central and paracentral corneal ulcers. *Br J Ophthalmol* 1990; 74: 528-31.

10. Chignell AH, Easty DL, Chesterton JR, Thomsitt J. Marginal ulceration of the cornea. *Br J Ophthalmol* 1970; 54: 433-40.

11. Acute haemorrhagic conjunctivitis. *Epidemiological Comments* June 1982; 9: 1-17. Department of Health, Welfare and Pensions, Pretoria.

12. Liesegang TJ, Forster RK. Spectrum of microbial keratitis in South Florida. *Am J Ophthalmol* 1980; 90: 38-47.

13. Ormerod LD, Hertzmark E, Gomez DS, Stabiner RG, Schanzlin DJ, Smith RE. Epidemiology of microbial keratitis in Southern California - A multivariate analysis. *Ophthalmology* 1987; 94: 1322-33.

14. Maske R, Hill JC, Oliver SP. Management of bacterial corneal ulcers. *Br J Ophthalmol* 1986; 70: 199-201.

15. Asbell P, Stenson S. Ulcerative keratitis-survey of thirty years' laboratory experience. *Arch Ophthalmol* 1982; 100: 77-80.

16. Groden LR, Brinser JH. Outpatient treatment of microbial corneal ulcers. *Arch Ophthalmol* 1986; 104: 84-6.

17. Baum J, Fedukowicz HB, Jordan A. A survey of moraxella corneal ulcers in a derelict population. *Am J Ophthalmol* 1980; 90: 476-80.

18. Chaudhuri PR, Godfrey B. Treatment of bacterial corneal ulcers with concentrated antibiotic eye drops. *Trans Ophthalmol Soc UK* 1982; 102: 11-4.

19. Musch DC, Sugar A, Meyer RF. Demographic and predisposing factors in corneal ulceration. *Arch Ophthalmol* 1983; 101: 1545-48.

20. Coster DJ, Badenoch PR. Host, microbial, and pharmacological factors affecting the outcome of suppurative keratitis. *Br J Ophthalmol* 1987; 71: 96-101.

21. Dahan E, Appel R. Vernal keratoconjunctivitis in the black child and its response to therapy. *Br J Ophthalmol* 1983; 67: 688-92.

3.0 Predisposing Factors in Corneal Ulceration

3.1 Introduction

There are three important factors in the development of infective corneal ulceration; the virulence of the infecting organism, local factors providing a portal of entry for those organisms not capable of primary infection, and a poor general health status allowing the organism to flourish.

Many of the local factors are well documented[1-6], but scant attention has been paid to general factors, largely due to the retrospective nature of many of the studies.

Corneal ulceration is commonly seen in black populations and there must be a reason for this. A report from [illegible] 1976[9], concentrated on cases of mycotic keratitis selected from the "large[illegible]s with corneal ulcers" treated at that hospital. The largest prospective [illegible] with corneal ulceration was reported by Foster[8], from Tanzania and [illegible]er a four year period. The largest prospective series ever reported were the [illegible] St John eye hospital, Soweto, South Africa[10].

There are many causes of secondary immunodeficiency[11], and features in a low risk patient include mild malnutrition, alcoholism, aging, diabetes mellitus, hepatic and renal failure, chronic infection eg. tuberculosis, and auto-immune disorders eg. rheumatoid disease[12]. The medium risk patient would show features such as severe malnutrition, treatment with systemic corticosteroids or lymphoma. The authors categorize a high risk patient as one with bone marrow failure, acquired immune deficiency syndrome, or organ transplant.

Many of the factors examined in this chapter as general predisposing factors are thus considered as being low risk from an immunological standpoint but some infer medium risk. An additive or synergistic effect is seen when two or more factors are present in the same patient[12]. Thus with combinations, a moderate or even severe increase in the risk of infection can result.

3.2 Patients and Methods

Over a one year period, 161 patients with 167 corneal ulcers were admitted to St John eye hospital (July 1982 to June 1983). This consisted of 110 central ulcers

Table 3.4 shows the general factors by type of central corneal ulcer. Whereas single local factors were the rule, several general factors were often present in the same patient and Table 3.4 shows a total of all the general factors present in the group.

General Predisposing Factors by Type of Central Corneal Ulcer				
	Bacterial	Fungal	Viral	Total
Malnutrition:				
Mild	10	2	2	14
Moderate	13		2	15
Severe	3			3
Children	6			6
Alcohol:				
Two factors	14			14
Three factors	7			7
Diabetes	3	3	1	7
Tuberculosis	2			2
Blood dyscrasia	2			2
Collagen disease	2			2
TOTAL	62	5	5	72

Table 3.4

3.3.2.1 Malnutrition

In assessing the 87 adult patients and comparing with I.S., 22 patients (25% of the adults admitted) weighed less than 80% of expected weight for their height and sex (Table 3.5).

Anthropometric Measurements (Percentile)							
Less than	60	60-69	70-79	80-89	90-99	100+	Total
TSP	68	2	6	5	2	4	87
MAMC	-	1	5	20	31	30	87
Weight for height	-	7	15	22	25	15	84

Table 3.5

Tissue wasting was seen in 76 patients (87%), and in fact 68 (78%) were considered to have severe fat depletion, having TSF values under 60% of standard. This phenomenon was more marked in men than women. MAMC fell under the 80th percentile in only six cases

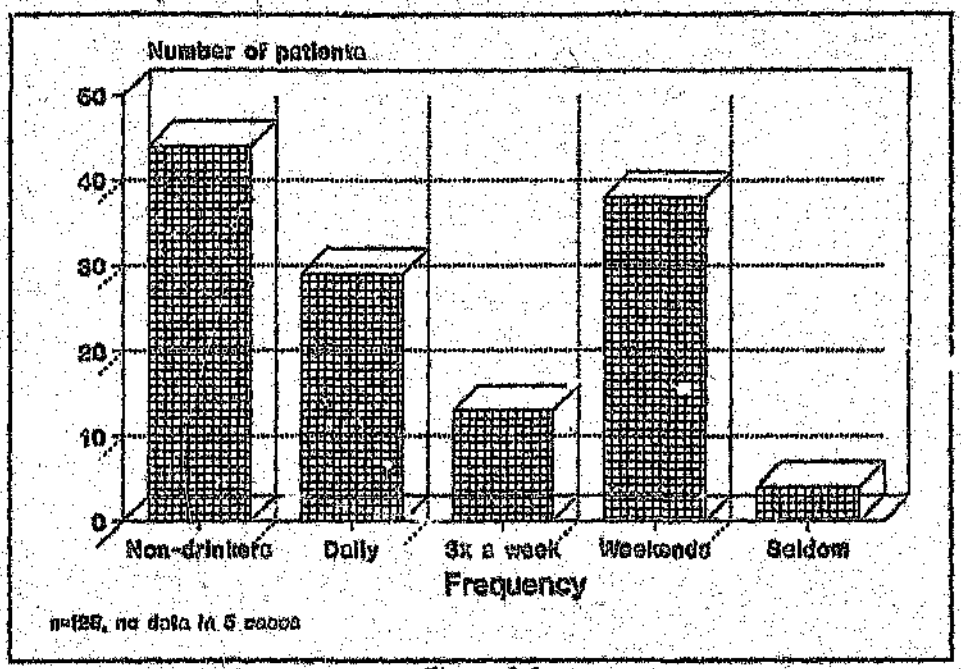

Figure 3.2

In the central group, alcohol markers were measured in 73 adults (82%) and not measured in 16 adults.

All alcohol abusers were in the central bacterial group and there were 14 patients with 2 factors and seven with 3 factors for alcohol abuse.

Table 3.7 shows the alcohol parameters for the alcohol abusers. The group had a mean age of 52 years and contained 1 female and 20 males. Eight of the group were unemployed or pensioners.

(two bilateral) and 57 marginal ulcers (four bilateral). Included were 30 children of which 19 had central ulcers (two bilateral) and nine had marginal ulcers.

All patients were admitted by the same doctor who took the history and examined the patients. Slit-lamp examination and anterior segment photography were used to document local predisposing factors.

The nutritional status of 87 of the 89 adult patients with central corneal ulcers was assessed. This included 75 men and 12 women with a mean age of 53 years and a range of 19-82 years. Serum albumin, transferrin and full blood counts were estimated. Weight and height were measured together with triceps skinfold thickness (TSF) and mid-arm circumference (MAC). MAC was measured with a soft tape midway between the elbow and the shoulder. Skinfolds at four sites (biceps, triceps, supra-scapular and supra-iliac) were measured using a Harpenden skin calliper. The mid-arm muscle circumference (MAMC), was calculated using the formula MAMC=MAC-Pi(TSF). The measurements were compared with international standards[12], and recorded as a percentage of standard. The standards used by Jelliffe[13] will be referred to as international standards (I.S.).

In assessing the group as a whole, underweight was defined as under 80% of standard weight for height and a low fat reserve as a TSF under 80% of standard. Protein depletion was indicated by a serum albumin under 30 g/l, transferrin under 1,6 g/l and MAMC under 80% of standard.

The assessment of the nutrition of an individual patient is difficult as there are many variables to reconcile. It is nevertheless of some interest and importance to note those patients in whom malnutrition was considered an underlying factor. Serum transferrin levels were found to be a sensitive indicator of nutritional status, much more so than albumin, which tends to decrease late in malnutrition. Transferrin, albumin and MAMC are indicators of protein depletion which is probably a more important concern than fat depletion (skinfold thickness).

In assessing the malnutrition of individuals, the transferrin level was used as the primary determinant. Cases were placed into categories of;

mild - less than the lower limit of normal, 2,0 g/L,

moderate - less than the 80th percentile, 1,6 g/L,

severe - less than the 60th percentile, 1,2 g/L.

In cases where the transferrin level was not measured, the albumin level was considered. Cases were placed into categories of;

mild - less than the lower limit of normal, 35 g/l,
moderate - less than the 80th percentile, 28 g/L,
severe - less than the 60th percentile, 21 g/L.

Individual cases were excluded if they lacked both measurements, or if they had a single incongruous measurement and their other parameters appeared normal. The latter usually applied to albumin levels being low due to diabetic nephropathy with increased albumin loss and alcoholic liver damage with reduced synthesis.

The difference in transferrin levels between the malnourished group and the remainder was significant (p less than 0.0001, Student *t* test). When the transferrin levels of the mildly malnourished group were compared to the better nourished remainder, the difference was still significant (p less than 0.0001, Student *t* test). The use of transferrin levels thus appears to be sensitive in distinguishing between the malnourished and better nourished individual.

The MAMC was not a sensitive indicator for two reasons;

1) many patients were labourers and this increased their upper arm muscle bulk,
2) the group studied, generally, had low TSF values and the MAMC formula will produce a higher value if the TSF is low.

As I.S. are available for TSF, this measurement was shown separately as an assessment of skinfold thickness while total skinfold thicknesses at four sites of less than 40mm was regarded as below normal[14].

In defining malnourished children, a patient referred from another hospital with a diagnosis of malnutrition was accepted as a case as were children with a weight for age of under 80%.

The alcohol consumption of the adult central corneal ulcer patients was estimated by questioning the patients regarding the type of alcohol consumed and frequency of alcohol consumption. This information was combined with serum diagnostic markers for alcohol abuse, gamma-glutamyltransferase (gamma GT) and aspartate aminotransferase (AST)[15,16], to define patients in whom alcohol abuse might have been considered a general

predisposing factor.

The following three factors were considered;

1) history of daily alcohol consumption, or previous heavy drinking,
2) Gamma GT level over 50 u/L at 37° in males and 32 u/L at 37° in females,
3) AST level over 38 u/L at 37° in males and 31 u/L at 37° in females.

Cases to whom two or three of these factors applied were considered alcohol abusers. A further case which was added was a woman who was admitted in delirium tremens with a very strong alcohol history but was too psychotic for blood to be taken. She had a marginal primary ulcer and was included with the cases having two factors present.

The number of factors present was not considered to imply severity but rather certainty of alcohol abuse. Combinations of interview tests and gamma GT, mean corpuscular volume and serum AST were regarded as having both sensitivity and specificity[15].

In assessing possible general factors in marginal ulceration the presence of rheumatoid factor, antinuclear factor and LE cells was determined. Serology for syphilis (T.P.H.A.) was also estimated, as it was felt that syphilis might be a cause of some marginal ulcers.

3.3 Factors Predisposing to Central Corneal Ulcers

3.3.1 Local Factors

In 77% (83 of 108 patients) a local predisposing factor was found (Table 3.1). In addition, two of the children had xerophthalmia with bilateral ulceration.

Local Predisposing Factors by Type of Central Corneal Ulcer				
	Bacterial	Fungal	Viral	Total
Foreign body	3			3
Trauma (other)	16		1	17
Corneal scarring	9		4	13
Climatic droplet keratopathy	17	2	1	20
Dry eye (including xerophthalmia)	7			7
Eye surgery	6			6
Corneal anaesthesia			4	4
Bullous keratopathy	2		1	3
Trichiasis	3			3
Exposure	2			2
Lid edge defect	1			1
Band keratopathy	1			1
Combination	3			3
TOTAL	70	2	11	83
Patients in group	89	6	13	108

Note: Combinations were; proptosis, exposure and corneal anaesthesia caused by an orbital tumour, a previous graft with corneal anaesthesia, and previous cataract surgery associated with central scarring and blepharitis. Two children in the Dry eye group had bilateral ulcers.

Table 3.1

Local factors were mostly important in bacterial ulcers, and trauma (including foreign bodies), corneal scarring and climatic droplet keratopathy were most prominent.

In considering local factors, attention should be paid to general underlying factors present in the same individual.

The more important local causes are reported in more detail below.

3.3.1.1 Corneal Trauma and Foreign Bodies

In examining the cases where corneal trauma was a cause, children were involved in 7 of the 20 cases (Table 3.2). The mean age of this group of patients was 29 years and there were 5 females in the group. The numbers involved were considered too small to apply incidence rates in a meaningful way.

In the adults, the trauma sometimes related to work exposure, but this did not seem a major problem area.

Malnutrition or alcohol abuse were co-existent in 6 of the 13 adults.

Cases with Foreign Bodies and Other Trauma as Predisposing Causes					
Case No	Type of Injury (history)	Age (yrs)	Sex	Occupation	Other Predisposing Factors
94	Black object from stove	19	F	Nil	Malnut++
134	FB in eye	45	M	Driver	
142	Piece of bone	28	M	Butchery	
18	Sharp grass	67	F	Nil	
3	Catapult, corneal laceration	8	M	Child	
6	MVA, glass in eye	33	M	Hardware	
10	Hit with open hand	40	F	Housewife	
20	Brick chip	41	M	Brick factory	
28	Hit with fist (father)	12	F	Child	
37	Branch, climbing tree	8	M	Child	
39	Fell and hit eye	8	M	Child	Old xerophthalmia scars
110	Wire, corneal laceration	32	M	Prisoner	
41	Fell in hole	48	M	Nil	Malnut+++
128	Stick in eye	54	M	Gardener	Malnut+
147	Stone injury	4	M	Child	
148	Ball hit eye	2	M	Child	
150	Bottle hit eye	38	M	Cleaner	Malnut+
151	Hit with carpet by wife	43	M	Security	Alcohol**
159	Other child poked wood in eye	2	F	Child	
77	Branch in eye	49	M	Tree pruning	Malnut++

Note: F is female, M is male, yrs is years, FB is foreign body, MVA is motor vehicle accident. Malnut +, ++ or +++ is malnutrition of mild, moderate or severe grades. Alcohol ** and *** are 2 and 3 factors for alcohol abuse. No is number. The last case is a central viral ulcer, the remainder are central bacterial.

Table 3.2

3.3.1.2 Climatic Droplet Keratopathy (CDK)

The cases with CDK examined in Table 3.3 included all cases with grade 3 CDK ie. the nodular form. Grade 4 CDK was used to describe cases where the infiltrate and abscess formation indicated that the mechanism involved was flaking off of the gelatinous plaque with resulting infection.

CDK was mainly a predisposing factor in bacterial and fungal ulcers. The patients were all male with a mean age of 64 years and an age range of 44-82 years. The group, being older, showed more patients being either unemployed or pensioners.

Nutrition, alcohol, leukaemia and tuberculosis were general factors which possibly played a role in the infection in some cases. As in the trauma cases, about half the adults showed some degree of malnutrition.

It is of interest that 65% of the CDK cases (13 of 20), showed a general predisposing factor in addition to the local factor.

Cases with Climatic Droplet Keratopathy (CDK) as a Predisposing Cause						
Case No	Ulcer Type	CDK grade	Age (yrs)	Sex	Occupation	Other Predisposing Factors
27	Central Bacterial	4	69	M	Nil	Malnut+++
38		3	55	M	Nil	
49		4	60	M	Watchman	Malnut+
58		4	62	M	Nil	Tuberculosis
60		3	44	M	Packer	Alcohol***
65		3	65	M	Farm, cattle	Malnut++, Alcohol**, CLL
67		4	72	M	Nil	
72		3	82	M	Pensioner	Malnut+
79		3	64	M	Nil	Malnut+, Alcohol***
80		4	64	M	GPO, repair	Malnut+, Alcohol***
83		3	75	M	Pensioner	
87		4	62	M	Cleaner	Malnut+
99		3	68	M	Brick factory	
116		3	63	M	Nil	Alcohol**
123		3	66	M	Pensioner	
140		4	50	M	Labourer	Malnut++
146		4	60	M	Gardener	Alcohol**, CML
54	Central Fungal	4	62	M	Prison warden	
154		4	55	M	Plumber	Malnut+
132	Central Viral	3	65	M	Pensioner	

Note: CML is chronic myeloid leukaemia. CLL is chronic lymphocytic leukaemia. GPO is post office. Malnut+, ++ and +++ are malnutrition of mild, moderate and severe grades. Alcohol** and *** are 2 and 3 factors for alcohol abuse.

Table 3.3

3.3.1.3 Corneal Scarring

Corneal scarring in the bacterial cases reflected previous trauma or ulceration. In seven of the nine cases this probably resulted in an overlying epithelial defect which became infected. In the other two cases the scar was probably not influential in the development of the subsequent ulcer.

In the viral cases there was a history of trauma (brick chip) in one case and the other three testified to the recurrent nature of the condition.

3.3.1.4 Other

In the dry eye patients there were two adults with keratitis sicca confirmed on Schirmer testing. One had rheumatoid disease and the other systemic lupus erythematosis. There were five children with dry eye who were malnourished two of whom had a history of measles infection preceding the corneal ulcer. These five were suspected to have xerophthalmia as a cause but as Vitamin A levels were not taken, this was not documented and the diagnosis was clinical.

Preceding cataract and corneal graft surgery produced three cases each and one ulcer followed a combined cataract and trabeculectomy operation. The other patient had a corneal laceration repaired and had continual postoperative uveitis. She was admitted with a hypopyon ulcer six weeks after the repair.

Corneal anaesthesia was seen in viral keratitis either as a result of the viral infection or playing a role in the pathogenesis of indolent corneal ulcers.

3.3.1.5 Spontaneous Onset

Although more than half of the patients gave a history of spontaneous onset of the ulcer, a predisposing factor was usually obvious on admission. In only 12 cases (11%) was the cause of the ulcer a mystery on admission and no predisposing cause identified.

3.3.2 General Factors

These were not as common as local factors, but malnutrition and alcohol were the most important factors.

(7%). Serum albumin values have previously been found to correlate well with MAMC and with other tests of protein depletion. Only 11 patients (13%) had serum albumin levels under 30 g/l and of these only one patient's level was below 20 g/l. Serum transferrin levels are a more sensitive index of protein status than albumin and this is reflected by the fact that 47% of patients had below normal transferrin levels (under 2,0 g/l) while 25% had levels below 1,6 g/l.

In assessing individual adult cases, there were 14 cases with mild malnutrition, 14 with moderate malnutrition and three with severe malnutrition. In addition there were six children who were malnourished, two of whom had a history of measles.

Table 3.6 shows the nutritional parameters for the adult patients. This group had a mean age of 53 years and contained 4 females and 27 males. Ten of the group were unemployed or pensioners.

Central Corneal Ulcer Patients with Malnutrition as a Predisposing Factor											
Severity of Malnutrition and Ulcer Type		Age (yrs)	Sex	Wt/ht % (below)	TSF in mm	TCF % (below)	MAMC % (below)	Occupation	Albumin g/L	Transferrin g/L	Sum of 4 Skinfold Thickness in mm
Case No	Ulcer type										
	Mild:										
5	CB	44	M	95	4.4	40	110	Factory	47.0	1.7	21.0
49	CB	60	M	95	3.2	30	100	Watchman	39.0	1.7	27.2
72	CB	82	M	90	5.4	50	90	Pensioner	36.3	1.6	35.6
75	CB	32	M	85	4.2	40	100	Driver	39.4	1.8	20.0
79	CB	64	M	85	5.8	50	100	Nil	34.4	-	28.0
7	CB	64	M	95	7.8	70	110	GPO lab.	34.5	1.9	39.0
84	CB	47	M	90	4.4	40	100	Road lab.	37.7	1.9	18.9
123	CB	54	M	90	5.0	50	100	Gardener	41.8	1.8	26.0
150	CB	38	M	70	5.5	50	100	Cleaner	37.1	1.8	38.9
36	CB	58	M	80	6.2	50	90	Painter	40.5	1.7	22.8
154	CF	62	M	100	5.6	50	100	P.warden	37.6	1.6	23.0
91	CF	80	F	80	9.7	60	100	Nil	33.1	1.7	23.6
66	CV	40	M	85	4.4	40	110	Road lab.	30.7	-	19.2
138	CV	56	M	100	7.0	60	80	Storeman	28.3	-	30.4
	Moderate:										
93	CB	27	M	105	6.4	60	100	Garbage	36.7	1.5	29.6
120	CB	50	M	100	6.0	50	110	Builder	41.4	1.5	29.5
165	CB	80	M	75	4.2	40	110	Farm lab.	39.5	1.5	17.2
180	CB	37	F	-	9.0	60	90	-	20.5	1.4	40.6
63	CB	65	M	105	5.2	30	100	Farm lab.	31.2	1.5	20.0
16	CB	55	M	65	3.0	30	70	Nil	26.1	-	12.4
59	CB	52	M	90	5.2	50	90	Nil	36.7	1.5	28.2
61	CB	49	M	80	2.2	20	100	Farm lab.	27.8	1.2	17.6
74	CB	36	M	90	6.0	50	100	Nil	35.2	1.5	30.0
140	CB	50	M	95	5.6	30	100	Labourer	41.1	1.4	27.4
165	CB	80	M	75	4.2	40	110	Farm lab.	39.3	1.5	17.2
82	CB	62	M	75	4.4	40	90	Cleaner	30.6	1.3	20.8
94	CB	19	F	70	12.3	80	100	Nil	42.0	1.4	33.2
77	CV	49	M	90	5.2	50	100	Farm lab.	-	1.4	20.0
156	CV	67	F	85	3.6	30	90	Pensioner	39.3	1.3	14.4
	Severe:										
56	CB	30	M	70	3.2	30	90	-	26.5	1.1	16.4
27	CB	69	M	80	6.6	60	90	Nil	33.0	0.6	26.4
41	CB	48	M	-	5.6	50	80	Nil	20.0	0.8	20.8

Note: CB is central bacterial, CF is central fungal, CV is central viral, lab. is labourer.
GPO is Post Office, P is prison, - means no data.

Table 3.6

3.3.2.2 Alcohol

There were 133 adults with corneal ulcers and data on type and frequency of alcohol use were obtained in 128 of them.

Most of the adult drinkers (93%) consumed beer exclusively (78 of 84 drinkers). Half of them drank sorghum beer (commercial or homebrew) and there were very few spirits drinkers (Fig. 3.1).

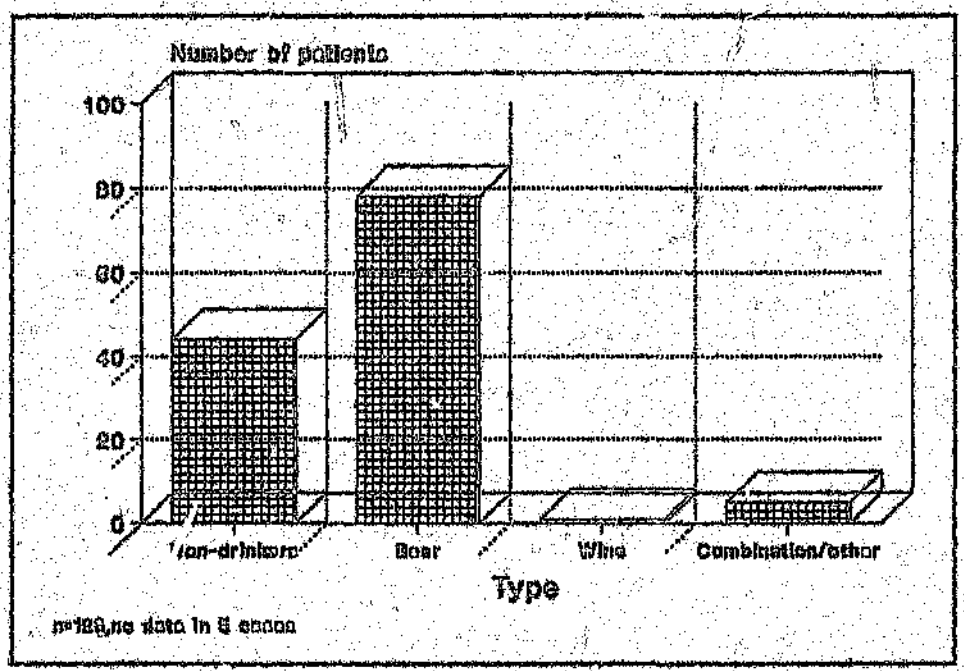

Figure 3.1

Daily alcohol consumption was admitted by 35% of the drinkers (29 of 84), while 34% of the patients (44 of 128) were non-drinkers (Fig. 3.2).

Central Corneal Ulcer Patients with Alcohol as a Predisposing Cause							
Case No	Ulcer Type	Age	Sex	Gamma GT	AST	Alcohol, Type and Frequency	Occupation
Alcohol 2 Factors							
8	CB	63	M	34	44	Beer, daily	Painter
13	CB	65	M	129	56	Nil	Nil
16	CB	55	M	49	48	Beer, daily	Nil
19	CB	42	M	49	40	Beer, daily	Telephone fitter
50	CB	60	M	79	41	Beer, 3 x a week	Nil
51	CB	29	M	100	58	Beer, weekends	Cleaner
65	CB	65	M	15	101	Beer daily	Farm lab.
74	CB	36	M	174	32	Beer, daily	Nil
93	CB	27	M	52	56	Beer, weekends	Garbage [illegible]
106	CB	64	F	680	60	Beer, weekends	Pensioner
116	CB	63	M	94	24	Beer, daily	Nil
146	CB	80	M	136	58	Nil	Gardener
151	CB	43	M	159	22	Beer, cane, daily	Security
163	CB	38	M	180	27	Beer, anything, daily	Cobbler
Alcohol 3 factors							
15	CB	50	M	232	96	Beer, daily	Cleaner
36	CB	58	M	270	56	Used to drink heavily	Painter
60	CB	44	M	137	53	Beer, daily	Packer
61	CB	49	M	54	44	Beer, daily	Farm lab.
79	CB	64	M	74	46	Beer, daily	Nil
80	CB	64	M	71	77	Beer, daily	GPO repair
141	CB	41	M	97	47	Beer, daily	Nil

Table 3.7

3.3.2.3 Other

There were seven diabetic patients in the group and it is interesting to note that three of the six fungal ulcer patients had this predisposing factor. Tuberculosis was considered a predisposing factor if there was radiological evidence of the disease and this was confirmed on sputum culture in the two documented cases. There were two cases of leukaemia. One was a known case of chronic myeloid leukaemia who was clinically wasted with hepatosplenomegaly. The other presented with massive hepatosplenomegaly, ascites and bronchial breathing indicative of patchy consolidation in his lungs. His haemoglobin was 9,0 g/dl and white cell count was 110 thousand (9" % lymphocytes).

Protein electrophoresis was normal but he showed mild malnutrition. He was diagnosed as having chronic lymphocytic leukaemia.

3.4 Factors Predisposing to Marginal Corneal Ulcers

As the emphasis was placed on suppurative corneal ulcers, this group of patients was not, as a rule, assessed nutritionally or for serum diagnostic markers for alcohol abuse and can thus not be used as a control group for the central cases. It was assumed that this group might show auto-immune diseases causing ring ulcers and emphasis was placed on this in the investigation. In fact, although the basic underlying pathology is usually of an auto-immune or allergic nature many showed secondary bacterial infection and, of course, non-infectious corneal ulceration is itself a local predisposing factor for infectious ulceration.

3.4.1 Local Factors

Local factors were prominent in the catarrhal, primary infection and "other" groups (Table 3.8 and 3.9).

Predisposing Factors in Marginal Catarrhal Corneal Ulcer Patients										
Case No	Age (yrs)	Sex	Local Factors	General Factor	Alcohol Frequency	Type	FTAB	Rh. Factor	ANF	Le Cells
11	42	M			Daily	Beer	+ve	-ve	-ve	-ve
14	58	F	K.sicca		Nil		-ve	-ve	-ve	
17	68	M			Nil		-ve		-ve	
21	42	M			Weekends	Wine				
23**	32	M	C.scar		Weekends	Beer	+ve			
34	77	F	Bl/meib.	Diabetic	Nil		-ve			
47	53	F			Nil		-ve			
48	45	F	C.scar		Nil		-ve	-ve	-ve	-ve
64	31	M	Bl/meib.		Weekends	Beer	+ve			
69	45	M	Bl/meib.		Weekends	Beer	-ve	-ve		
70	49	M	Bl/meib.		Nil					
71	51	M	Bl/meib.		Weekends	Beer	+ve			
82	35	M			Daily	Beer	-ve			
85	60	M		Alc**	Weekends	Beer	+ve			
86	55	F			Nil		-ve	-ve	-ve	-ve
89	60	F	Exposure		Nil		+ve			
92	38	M			Weekends	Beer	-ve	-ve	-ve	-ve
108	59	F			Nil		-ve	-ve	-ve	-ve
129	51	M	Bl/meib.		Weekends	Beer	-ve	-ve	-ve	-ve
133	24	F	Bl/meib.		Nil		-ve	-ve	-ve	-ve
136	37	M	Bl/meib.		Daily	Beer	+ve		-ve	-ve
142	45	M	C.scar		Weekends	Beer	-ve	-ve		-ve
144	28	F	Bl/meib.		Weekends	Beer	+ve	-ve	-ve	-ve
149	29	M	Bl/meib.		Weekends	Beer	+ve	-ve	-ve	-ve
157	4	M	Polycon	Tuberculosis						
161**	50	M	Bl/meib.		Daily	Beer	+ve	-ve	-ve	-ve
167**	52	M	Bl/meib.	Alc**	Daily	Beer	+ve			

Note: ** are bilateral cases, Alc** is 2 factors for alcohol abuse, Bl/meib. is blepharitis/meibomitis C.scar is corneal scar, K.sicca is Keratitis sicca, Rh. is rheumatoid.

Table 3.8

Predisposing Factors in Non-Catarrhal Marginal Corneal Ulcer Patients

Case No	Age (yrs)	Sex	Local Factors	General Factors	Alcohol Frequency	Type	FTAB	Rh. Factor	ANF	Le Cells
Ulcer Type: Ring										
25	29	F			Nil		-ve	-ve	-ve	-ve
43**	22	M			Nil		-ve			-ve
52	33	F			Nil		+ve	-ve	-ve	-ve
62	32	M			Daily	Beer	-ve	-ve	-ve	-ve
76	75	M		Rheumatoid	Nil		-ve	+ve	+ve	+ve
119	16	F			Nil		-ve	-ve	-ve	-ve
122	43	F		Rheumatoid	Nil		+ve	+ve	-ve	-ve
127	50	M		CA Kidney	Nil		-ve	-ve	-ve	-ve
131	57	M	CDK(3), surgery		Nil		-ve	-ve		-ve
139	14	F			Nil		-ve	-ve	-ve	-ve
158	31	M		Rheumatoid	3x a week	Beer	+ve	+ve	-ve	-ve
Mooren's										
90	10	F			Nil		-ve	-ve	-ve	
97	37	M			3x a week	Beer		-ve	-ve	-ve
98	38	M			Daily	Beer	-ve	-ve	-ve	-ve
160	73	M	Graft, bullous K		Nil		+ve		-ve	-ve
Primary										
2	16	M	FB seed husk		Nil					
9	27	M	Conj.	Gonorrhoea	Seldom	Beer	-ve	-ve	-ve	-ve
57	40	F		Alc**, DT's	Daily	Beer				
117	5	F	Dendrite		Nil					
126	40	F		RadioRx, diabetic	Nil		+ve			
164	55	F	Anaes. Cornea	Diabetic	Nil		-ve	-ve	-ve	-ve
Other										
42	55	M	Dellen	Alc**	Daily	Beer	-ve			
46	5	M	Vernal		Nil					
95	4	M	Vernal		Nil					
109	5	F	Vernal		Nil					
145	43	M	Trichiasis		Daily	Beer	-ve	-ve		ve

Note: ** is a bilateral case, CA is carcinoma, CDK (3) is Grade 3 climatic droplet keratopathy.
Conj. is conjunctivitis, DT's is delirium tremens, anaes. is anaesthetic,
bullous K is bullous keratopathy, RadioRX is radiotherapy.

Table 3.9

In the catarrhal group, blepharitis and/or meibomitis was seen in 12 patients including two of the three bilateral cases. The four year old with tuberculosis was originally thought to be a case of catarrhal ulceration but probably had phlyctenular corneal involvement secondary to the tuberculosis. If the child is excluded, the catarrhal group consisted of 26 patients, with three bilateral ulcers. The mean age was 47 years and 2/3rds were male. Corneal scarring in this group reflects previous similar pathology and

shows the recurrent nature of the condition.

Within the primary infective group a local factor or cause was seen in four of the six cases. A seed husk was removed from the marginal corneal area in one case. In one case gonococcal conjunctivitis was present with secondary corneal ulceration. A child presented with a marginal corneal dendrite and was included in this group. Trichiasis caused the marginal ulcer in one case.

The marginal "other" group contained three children with vernal catarrh which caused the marginal ulcer.

3.4.2 General Factors

The most notable was rheumatoid disease as a cause of ring ulceration in three cases. Two of the cases had associated arthritis and X ray evidence of bony erosions in the hands suggestive of rheumatoid disease. These patients had rheumatoid factor titres of 1:320 and 1:640. The other patient had no other signs of rheumatoid disease and a titre of 1:40.

It was a clinical impression that catarrhal ulcer patients have a heavy alcohol consumption but this was not borne out by the data, and only two were considered alcohol abusers (Table 3.8). Of the 26 adults with catarrhal ulceration (three bilateral), eight were tested for alcohol markers (31%). There were ten non-drinkers in the group and only five daily drinkers. Instead, this group revealed a relationship between alcohol consumption and positive serology for syphilis which was generally true for all the corneal ulcer patients. Thus there was a fairly direct correlation between alcohol consumed and the chance of being positive for syphilis on T.P.H.A. screening. This lead to a less well established relationship between the presence of blepharitis (and catarrhal ulceration) and positive syphilis serology.

Within the catarrhal group, if the child is excluded, 24 T.P.H.A. tests were done in the 26 patients. Of the daily drinkers, four of the five were positive for syphilis. Of the non-drinkers, only one in nine was positive and of the other drinkers, six of ten were positive. All three bilateral cases were positive. Of the 12 cases with blepharitis, seven were positive compared with four positive out of 14 patients without blepharitis.

If this is compared with the group of central corneal ulcer patients a similar relationship

is found. Excluding children, none of whom was positive and many of whom were not tested, there were 56 tests done. Of daily drinkers, ten of 17 were positive while only four of 16 non-drinkers were positive. The other drinkers showed seven of 23 positive.

The association was true for males but not females, who presumably are subject to their partners excesses.

There was no obvious association between ethnic groups and positive serology, alcohol consumption or blepharitis.

3.5 Discussion

In central corneal ulcers, local predisposing factors could be identified in 77% of patients. Corneal trauma, climatic droplet keratopathy (CDK), and corneal scarring were most important. Malnutrition and alcohol abuse were the most important general factors.

Brightbill[1] could not identify the cause in 22% of 115 central ulcers. In the others, infective causes and corneal degenerations were prominent. Within his corneal degenerations he includes 14 neurotropic ulcers. These were caused by radiation therapy to the head and neck in seven cases, and associated with dry eye and chronic lymphocytic leukaemia in two cases, and dry eye and rheumatoid disease in one patient.

Liesegang and Forster[2] emphasized the importance of agricultural employment and trauma involving vegetable matter in cases of fungal keratitis. Pseudomonas keratitis was seen against a background of previous contact lens wear (33%) and trauma (22%), or previous inflammatory eye disease (20%). Significant general medical diseases (unspecified), were detected in 18% of fungal ulcer patients and 37% of Pseudomonas patients.

Chaudhuri and Godfrey[3], in a prospective study, were unable to identify a predisposing factor in seven of 32 cases (22%). In the others, glaucoma (presumably eye-drop contamination) and trauma (abrasions and foreign bodies) were the most important factors.

Musch et al[4], in a retrospective study, found trauma to be important in males aged 20-29 years and trauma and contact lens wear to be important in females in this age group. In the older group (65-74 years) there were more cases following eye surgery, 2/3rds of

whom had corneal grafts. Herpetic keratitis, bullous keratopathy and entropion were also important in this age group. Dry eye states were generally important as a predisposing cause.

Coster and Badenoch[5] found local and general predisposing factors in 84% of 87 cases. About a third had trauma or Herpes simplex (HS) keratitis and the mean ages were 44 years for the trauma cases and 59 years for HS cases. Of course HS keratitis is an independent entity and not a predisposing factor in the usual sense but might predispose to secondary bacterial or fungal infection. They reported systemic lupus erythematosis and multiple myeloma plus malnutrition as general factors in two cases.

Ormerod et al[6] found local factors in 76% of their retrospective analysis of 227 cases. Trauma occurring in the home or due to assault was very much more common than industrial trauma in this series. Previous surgery or scarring, blepharitis, exposure and bullous keratopathy were also important factors. Important general factors included chronic alcoholism in 32% and diabetes mellitus in 8%.

In the patients at St John Eye Hospital, corneal trauma was important in the younger patients and the mean age for this group was 29 years. Children (16 years and under) were involved in seven of the 20 cases. Malnutrition or alcohol abuse coexisted in six of the 13 adults in this group. Foreign bodies in the usual sense ie. metallic foreign bodies and rust rings appear to be a very uncommon cause of infective ulcers. This is presumably because the condition is irritating and treatment rapidly sought, the metal is often hot and sterile when it strikes the cornea, and the foreign material remains localized to the epithelial layer. Even organic foreign bodies can be fairly benign and in a report of 28 patients, Zauberman and Neumann[17] found only one case where a significant ulcer resulted. They felt that in long-standing cases, erosion into the stroma was inevitable. These long-standing cases presumably epithelialize for periods and are not uncomfortable for much of the time.

Corneal scarring should be noted, as persistent epithelial defects seem important in subsequent infective ulceration. The scar might also reflect previous similar pathology and this is true of viral keratitis which is known to be recurrent.

Climatic droplet keratopathy is a name proposed by Arnold Freedman[18] in 1973 to enclose a number of similar conditions reported worldwide. He described three grades

or stages of the condition. Grade 1 comprises corneal droplets, visible on retro-illumination of the cornea and present in the nasal and temporal areas. Grade 2 is where the droplets are seen in the pupillary area, and grade 3 is where yellowish nodules elevate the corneal epithelium. In his definition he also states that grade 3 CDK should have a vision of 6/60 or less but this would seem to unnecessarily complicate an otherwise useful anatomical classification and this stipulation was not followed in the St John cases. Grade 3 CDK is designated to all cases showing nodular CDK, as the nodules sometimes flake off resulting in persistent epithelial defects.

CDK is commonly seen in black adults in the Johannesburg area and its presence was first reported in 1964 by Etzine and Kaufmann[19]. In their original description of three cases they comment that malnutrition was not obvious in their patients. The present series confirms that although general factors were present in some patients, they appear to be related more to the age of the patients than with causation of the CDK. In the histology report in one of the three patients[19] the hyaline material was subepithelial but caused abnormalities and thinning of the overlying epithelium. There was also some evidence of the material in the superficial stroma. This explains the clinical observation that persistent epithelial defects are common in the nodular form of the disease.

A study by Jeffrey Freedman in 1971[20], surveyed CDK (named by him "Nama keratopathy") in the Nama people of South West Africa. In a survey of 680 people, a prevalence of 50% was found in persons over the age of 55 years. There was an age-related increase over the age of 35 years and a male predominance only in some age groups. He felt that malnutrition might be a cause but that genetic factors were more likely as the condition is extremely rare in South African caucasians.

As CDK is an important predisposing factor in suppurative keratitis some consideration should be given to its treatment. Usually lubricant drops can be used[20] and superficial keratectomy reserved for very severe cases. Interestingly, the condition would appear to be at least partially reversible[21], and clinical trials are indicated to elucidate the situation.

Dry eye syndromes including xerophthalmia in children were the causative factor in some ulcer patients. The incidence of xerophthalmia and keratomalacia appears to have decreased since the survey by Kuming and Polilzer[22] in 1962/3. During their one year survey of 1,116 malnourished children admitted to Baragwanath hospital they found 108 cases of xerophthalmia, 70% of which were bilateral. This included 79 eyes showing mild

ulceration, 43 with moderate ulceration and 21 with severe ulceration. They also reported 15 eyes showing keratomalacia. Compared with the present study, even if not all cases were seen at St John, the incidence would appear to have fallen markedly since, and hopefully because of, their survey.

Post-surgical keratitis is fortunately uncommon given the volume of surgery performed at St John (estimated to be more than 1500 cataract operations annually).

There have been suggestions that nutritional factors and alcoholism might play a significant role in central corneal ulceration[6,23,24]. The general nutritional status of the St John patients has been previously reported[25] and in this chapter an attempt was made to define the nutritional and alcohol status of individual patients and associate this with other patient details and predisposing factors.

It is common clinical experience at St John that many of the central corneal ulcer patients are malnourished, suffer from alcohol abuse, and have low hygienic standards. The latter is difficult to quantitate in scientific terms but might be surmised from the organisms cultured ie. enteric organisms might suggest faecal-ocular contamination. This was, in fact, not found (see Chapter 4).

With the use of a combination of anthropometric, biochemical, and immunological methods, the nutritional status of patients can be assessed[14,26,27]. These methods have been used to show malnutrition in general medical and surgical patients and are reproducible[28,29]. Locally, these methods have been used to show malnutrition in hospitalised urban[30] and rural[31] black South Africans as well as coloureds[32], and black thoracic surgical patients[33].

The relationship between malnutrition and susceptibility to infection is a complex but fairly well established one. The most striking effect of malnutrition on the immune system is found in defective cell-mediated immunity[34-36] with suppression of the delayed hypersensitivity response. There is also probably a defective humeral response with decreased secretory IgA production and decreased complement levels[37]. It would also appear that the cornea of a protein deficient animal is susceptible to infection[38]. The adult St John patients with central ulcers showed evidence of fat depletion in 87% (TSF under 80%) and protein depletion in 47% (transferrin under 2,0 g/L). Thirty-one of the 89 were malnourished according to the parameters for individual patients and a third of these

malnourished patients were not working.

Alcohol abuse was observed in 21 adult central ulcer patients. In detecting alcohol abusers, a combination of drinking and social histories and alcohol markers is the most sensitive and specific means available[15,16]. The suggested clinical history to detect alcoholics is fairly complex and time-consuming and in this study, only frequency and type of alcohol were measured. No attempt was made to quantify alcohol consumption in grams per day.

The African is traditionally a beer drinker. Originally, beer was brewed using sorghum berries and allowing fermentation to take place in a container such as a gourd or clay pot[9]. Later, sorghum beer was produced by municipalities and commercially in cartons. Sorghum is a small reddish berry and is grown as a crop on the Transvaal Highveld. The beer produced from the sorghum berry is sour, opaque and pinkish brown and is regarded by many as a food rather than a beverage. It is thicker than clear beer due to the solid particles and yeast suspended in solution, and resembles a thin gruel. The alcohol content of sorghum beer varies according to the length of the fermentation process and the amount of other carbohydrate eg. sugar, added to the mixture. Commercially produced sorghum beer has an alcohol content of two to three percent, about half that of malt beers (lagers and ales). Sorghum beer is a fairly rich source of vitamins, notably Vitamin B.

It would seem likely that large quantities of sorghum beer would need to be consumed in order to produce alcoholic liver damage. If a change was made to malt beer, wine or spirits, a person accustomed to drinking large volumes might produce liver damage with a smaller volume consumed.

More than 90% of our patients consumed beer exclusively, about half which drank sorghum beer. Presumably, this reflects socio-economic status and with an increase in affluence might switch to malt beers, wines and spirits. About a third were daily drinkers and a third were non-drinkers. It is not known whether this was a general pattern in the community but there was more evidence of alcohol abuse in the central ulcer group than in the marginal ulcer group. It should be remembered that alcohol markers were not studied as comprehensively in the marginal group so the two groups are not fully comparable.

There were seven diabetics in the central ulcer group and three of the six fungal ulcer

patients had this predisposing factor.

In marginal catarrhal patients, blepharitis was an important factor and general factors were not prominent. There was an association between drinking habits and positive serology for syphilis and this related drinking to blepharitis and thus catarrhal ulcers, but alcohol abuse did not appear to be an important factor in this group. The group had a mean age of 47 years and 2 to 1 male predominance. This is similar to that reported by Chignell et al[40], where, in 84 patients, two thirds of the patients were between 40 and 60 years, and males predominated by 3.5 to 1. Marginal ulceration is a known complication of staphylococcal blepharitis[41] and the ulceration is considered to be an allergic or toxic reaction to the staphylococci or their products[40,41]. The prevalence of staphylococcus in the conjunctival sac and lid margins is climate-dependant, with about a third of all patients being carriers in cool climates and two thirds in warmer climates[42]. The carrier rate in black South Africans is not known, but might be high, as complications of staphylococcal blepharitis are commonly seen at St John.

Ring ulcers were most commonly associated with rheumatoid disease (three cases) and were also seen in association with renal carcinoma.

Mooren's ulcer is an idiopathic condition but may be seen following eye surgery[4]. This was observed following a corneal graft in one patient but causative factors were not identified in the remainder.

Primary infections of the marginal cornea have the same causative mechanisms as central ulcers generally. In one case an organic foreign body (seed husk) was removed from the marginal cornea. A marginal dendrite was observed in a child. General factors in this group included two diabetic patients, one of whom had previous radiotherapy to the head, one alcohol abuser, and a patient with gonorrhoea. Following conjunctivitis due to gonorrhoea the tremendous chemosis allows a furrow to develop in the limbal area. This is followed by marginal corneal ulceration, perforation, endophthalmitis and loss of the eye if untreated.

In the "other" group, vernal ulcers were seen in three children. A dellen ulcer was seen adjacent to a pingueculum in an alcohol abuser and trichiasis caused marginal ulceration in one case. Vernal conjunctivitis can result in corneal ulceration and affects males more than females[4]. The mechanism of dellen ulcers is thought to be a localized break in the

oily part of the tear film with a localized, dehydrated, thinned area developing in the cornea[45]. This usually develops adjacent to a raised paralimbal area eg. pingueculae.

3.6 Conclusions

When considering why so many corneal ulcers are seen in black males, predisposing factors provide some of the answers.

Important local predisposing factors like ocular trauma[46] and climatic droplet keratopathy[18] show a greater incidence and prevalence in the male, and CDK is fairly restricted to blacks in South Africa. There are no published accounts of CDK in white South Africans. Marginal catarrhal ulceration, secondary to chronic staphylococcal blepharitis is more common in the male[40] and is commonly seen at St John Eye hospital.

Local studies show black males to be undernourished compared with their female counterparts[30] and a similar situation exists in coloureds but not in whites[32]. Alcohol abuse is more common in males with a risk of two to three times greater than females for primary alcoholism in western countries[47].

The factors causing infective corneal ulceration vary from simple mechanisms like corneal penetration due to trauma, to more complex mechanisms eg. CDK combined with malnutrition and alcohol abuse.

Whether an infective ulcer will result, in a given situation, also depends upon an infecting organism being present and its virulence. The types of organism found in a population will work together with local and general factors in ultimately determining whether an infective ulcer is produced.

3.7 References

1. Brightbill F. Central corneal ulcers. *Ann Ophthalmol* 1972; 4: 331-7.
2. Liesegang TJ, Forster RK. Spectrum of microbial keratitis in South Florida. *Am J Ophthalmol* 1980; 90: 38-47.
3. Chaudhuri PR, Godfrey B. Treatment of bacterial corneal ulcers with concentrated antibiotic eye drops. *Trans Ophthalmol Soc UK* 1982; 102: 11-4.
4. Musch DC, Sugar A, Meyer RF. Demographics and predisposing factors in corneal ulceration. *Arch Ophthalmol* 1983; 101: 1545-48.

5. Coster DJ, Badenoch PR. Host, microbial, and pharmacological factors affecting the outcome of suppurative keratitis. *Br J Ophthalmol* 1987; 71: 96-101.

6. Ormerod LD, Hertzmark E, Gomez DS, Stabiner RG, Schanzlin DJ, Smith RE. Epidemiology of microbial keratitis in Southern California - A multivariate analysis. *Ophthalmology* 1987; 94: 1322-33.

7. Ormerod LD, Murphree AL, Gomez DS, Schanzlin DJ, Smith RE. Microbial keratitis in children. *Ophthalmology* 1986; 93: 449-55.

8. Foster A, Sommer A. Corneal ulceration, measles, and childhood blindness in Tanzania. *Br J Ophthalmol* 1987; 71: 331-43.

9. Gugnani HC, Talwar RS, Njoku-Obi ANU, Kodilinye HC. Mycotic keratitis in Nigeria. *Br J Ophthalmol* 1976; 60; 607-13.

10. Carmichael TR, Wolpert M, Koornhof HJ. Corneal ulceration at an urban African hospital. *Br J Ophthalmol* 1985; 69: 920-6.

11. Kotrosen D, Gallin JI. Evaluation of the patient with suspected immunodeficiency. In: *Principles and practice of infectious diseases*. Church Livingstone, 1990; 9: 145.

12. Starke I, Donnelly P. Part 1: Patient recognition and classification. In: Finch R, ed. Antimicrobial therapy in the immunocompromised patient. *Current Medical Literature*, 1986, pages 5, 13, 14, 16, 17, 19, 22, 25, 39.

13. Jelliffe DB. The assessment of the nutritional status of the community. *WHO Monograph Series* No. 53. Geneva: World Health Organisation, 1966.

14. James WPT. The assessment of nutritional status. *Medicine International (SA)* 1982; June: 663-7.

15. Lumeng L, ed. New diagnostic markers of alcohol abuse. *Hepatology* 1986; 6: 742-5.

16. Skinner HA, Holt S, Sheu WJ, Israel Y. Clinical versus laboratory detection of alcohol abuse: the alcohol clinical index. *Br Med J* 1986; 292: 1703-8.

17. Zaubermann H, Neumann E. Superficial corneal foreign bodies of organic origin. *Am J Ophthalmol* 1965; 60: 467-9.

18. Freedman A. Climatic droplet keratopathy. 1. Clinical aspects. *Arch Ophthalmol* 1973; 89: 193-7.

19. Etzine S, Kaufmann JCE. Band-shaped nodular dystrophy of the cornea. *Am J Ophthalmol* 1964; 57: 760-3.

20. Freedman J. Nama keratopathy. *Br J Ophthalmol* 1973; 57: 685-91.

21. Dahan E, Judelson J, Welsh NH. Regression of Labrador keratopathy following cataract extraction. *Br J Ophthalmol* 1986; 70: 737-741.

22. Kuming BS, Politzer WM. Xerophthalmia and protein malnutrition in Bantu children. *Br J Ophthalmol* 1967; 51: 649-66.

23. Katz NNK, Wadud SA, Ayazuddin M. Corneal ulcer disease in Bangladesh. *Ann Ophthalmol* 1983; 15: 834-6.

24. Baum J, Fedukowicz HB, Jordan A. A survey of moraxella corneal ulcers in a derelict population. *Am J Ophthalmol* 1980; 90: 476-80.

25. Di Bisceglie AM, Carmichael TR. Factors predisposing to central corneal ulceration in a developing population. *S Afr Med J* 1987; 71: 769-70.

26. Frisancho AR. Triceps skin fold and upper arm muscle size norms for assessment of nutritional status. *Am J Cln Nutr* 1974; 27: 1052-1053.

27. Blumenkrantz MJ, Kopple JD, Gutman RA, Chan YK, Barbour GL, Roberts C, Shen Fu H, Gandhi VC, Tucker CT, Curtis FK, Coburn JW. Methods for assessing nutritional status of patients with renal failure. *Am J Cln Nutr* 1980; 33: 1567-1585.

28. Bistrian BR, Blackburn GL, Hallowell E, Heddle R. Protein status of general surgical patients. *JAMA* 974; 230: 858-860.

29. Bistrian BR, Blackburn GL, Vitale J, Cochran D, Naylor J. Prevalence of malnutrition in general medical patients. *JAMA* 1976; 235: 1567-1570.

30. O'Keefe SJD, Thusu K, Epstein S. The fat and the thin- a survey of nutritional status and disease patterns among urbanized Black South Africans. *S Afr Med J* 1983; 63: 679-683.

31. O'Keefe SJD. Malnutrition among adult hospitalized patients in Zululand during the drought of 1983. *S Afr Med J* 1983; 64: 628-629.

32. Steyn K, Fourie J, Rossouw JE, Langenhoven ML, Joubert G, Chalton DO. Anthropometric profile of the coloured population of the Cape Peninsula. *S Afr Med J* 1990; 78: 68-72.

33. Delikaris P, Conlan AA, Silvis N, Studii R, Curcio CA. Nutritional status of thoracic surgical patients - a prospective evaluation. *S Afr Med J* 1983; 64: 818-820.

34. Smythe PM, Schonland M, Brereton-Stiles GG, Coovadia HM, Grace HJ, Loening WEK, Mafoyane A, Parent MA, Vos GH. Thymolymphatic deficiency and depression of cell-mediated immunity in protein-calorie malnutrition. *Lancet* 1972; ii: 939-944.

35. Jose DG, Good RA. Immune resistance and malnutrition. *Lancet* 1972; i: 314.

36. Neumann CG, Lawler GJ, Stiehm ER, Swendseid ME, Newton C, Herbert J, Ammann AJ, Jacob M . Immunologic responses in malnourished children. *Am J Clin Nutr* 1975; 28: 89-104.

37. Chandra RK. Immunoglobulins and antibody response in protein-calorie malnutrition: a review. In Suskind RM ed. *Malnutrition and the Immune response*. New York: Raven Press, 1977: 155-168.

38. Ratnakar KS. Protein deficiency and cornea. *Indian J Ophthalmol* 1981; 29: 463-466.

39. Haggblade S. Industrialization of Africa's indigenous beer brewing. In: *Industrialization of indigenous fermented food*. Steinkraus KH ed. Marcel Dekker Inc., 1989: 191-283. C.S.I.R. Copy No. 550042.

40. Chignell AH, Easty DL, Chesterton JR, Thomsitt J. Marginal ulceration of the cornea. *Br J Ophthalmol* 1970; 54: 433-440.

41. Thygeson P. Complications of staphylococcal blepharitis. *Am J Ophthalmol* 1969; 68: 446-449.

42. Smolin G, Okumoto M. Staphylococcal blepharitis. *Arch Ophthalmol* 1977; 95: 812-816.

43. Mondino BJ. Peripheral corneal ulcers and thinning disorders. Perspectives in *Ophthalmology* 1980; 4: 9-14.

44. Foster CS. Vernal keratoconjunctivitis. *Perspectives in Ophthalmology* 1980; 4: 35-38.

45. Baum JL, Mishima S, Boruchoff SA. On the nature of dellen. *Arch Ophthalmol* 1968; 79: 657-662.

46. Duke Elder. *System of Ophthalmology*. Vol. xiv. Injuries, Part 1. Henry Kimpton, 1962: 5,6.

47. Wilson, Braunwald, Isselbacher, Petersdorf, Martin, Fauci, Root. In *Harrison's Principles of Internal Medicine*. 12th ed. 1991: 2149.

4.0 Microbiology of Corneal Ulceration

4.1 Introduction

The spectrum of micro-organisms responsible for corneal ulceration varies according to geographical location. Usually Gram-positive bacteria predominate, with *Staphylococcus aureus* and *Streptococcus pneumoniae* being the most common[1,2]. In the southern parts of the United States of America, Gram-negative bacteria and fungi have presented a particular problem[3]. The spectrum of organisms might also shift over a period of decades[4].

Predisposing factors such as pretreatment with topical steroids[3], the increasing use of soft contact lenses[5], trauma[3,6] and alcoholism[7] can also affect the type of isolate found in a population.

Certain infections have a "typical" clinical appearance[8] and it is of more than just academic interest to attempt to correlate clinical appearance with isolate as complications are experienced more frequently with some bacteria than others[9]. A knowledge of the organisms and their sensitivities to antimicrobial agents is essential for rational and successful treatment regimens.

In this chapter the spectrum of micro-organisms seen in the urban African patient at St John Eye Hospital is examined and the isolates obtained correlated with predisposing and other factors such as clinical features.

4.2 Patients and Methods

From the beginning of July 1982 to the end of June 1983, 161 cases (167 eyes) were admitted for inpatient treatment at St John Eye Hospital.

Culture Techniques

All cultures except two were taken prior to admission by the author and the other two were cultured under direct supervision by the same technique.

The culture technique was as advocated by Jones[10]. Conjunctival specimens were taken with calcium alginate swabs (Calgiswab, Inolex) moistened in serum broth. One was swabbed over the lower fornix, avoiding the lid margins, plated on to blood agar, and

inoculated into serum broth. A second swab was moistened in chopped meat broth and a conjunctival swab taken in the same way and placed in the chopped meat broth. The cornea was then anaesthetized with oxybuprocaine or proparacaine hydrochloride. Multiple corneal scrapings were then taken with platinum spatulae and inoculated on to blood agar in several rows, and serum broth and brain-heart infusion broth were also inoculated. From the corneal scrapings two smears were made, one of which was stained the same day with Gram's staining technique, while the other was examined microscopically the following day by the Mycology Department of the South African Institute for Medical Research (SAIMR). A swab moistened in chopped meat broth was rubbed over the bases and edges of the ulcer and inserted into the chopped meat broth. The chopped meat broth replaced a brain-heart infusion broth under oil which was used for the first 4 months of the study (80 cases) and during which time no anaerobic bacteria were grown. In 54 cases a dry cotton swab was used to take a specimen for viral culture, and this was placed in bovine plasma albumin for transport to the laboratory. In 30 cases corneal scrapings were plated onto Lowenstein and Jenson medium to check specifically for mycobacteria, as tuberculosis is not uncommonly treated at Baragwanath hospital. The viral cultures were kept at 4° C and the rest of the specimens were incubated overnight. The serum broths were incubated in 10% CO_2 to enhance the growth of more fastidious organisms. Swabs moistened in serum broth were used to take lid margin cultures from the same eye in cases of marginal corneal ulcer, and these were plated on to blood agar.

Bacteria were classified according to Bergey's Manual[11]. Conventional microbiological techniques were used for the isolation and identification of bacteria, fungi and viruses isolated. All specimens were processed by the Central SAIMR Laboratories, Johannesburg, except for virology specimens, which were forwarded to the National Institute for Virology for virological investigation. Some fungal cultures were confirmed by the Identification Services, Commonwealth Mycological Institute, Surrey, England.

Classification of Isolates

The following classification to determine the significance of bacterial isolates, suggested by Jones[12], was used:

Class 1. Growth of any organism (s) in two or more corneal media.

Class 2. Growth of more than one colony on one solid medium of *S. aureus*, *S. pneumoniae* or *Pseudomonas aeruginosa*.

Class 3. Growth in one medium of an organism identified in the direct smear.

These three classes will be referred to as "significant isolates".

In order to utilize conjunctival isolates in a meaningful way, two further classes were defined:

Class 4. Growth of any organism (s) in a corneal medium plus conjunctival media.

Class 5. Growth of a pathogen on conjunctival media only.

As anaerobic bacteria were cultured from a single cornea and conjunctival medium, these were not placed in the above-mentioned classes.

In the following text, the class of the organism will be noted in brackets.

4.3 Microbiology of Central Corneal Ulcers

4.3.1 Central Bacterial Ulcers

Corneal isolates were obtained from 62 of the 91 eyes in the central bacterial ulcer group (Table 4.1). By far the commonest isolate was *S. pneumoniae*, which was cultured from 26 eyes. Other streptococcal species (*Streptococcus sanguis* and *Streptococcus pyogenes*) were isolated from a further four eyes. Of the pneumococci which were isolated from the central bacterial ulcers, four were isolated from children, three of whom were under 5 years old. From all types of ulcer there were 29 pneumococcal isolates, of which 24 were typed. Type 6 was the commonest (six isolates), followed by type 10 (four isolates). These and the other eight types reflected the usual upper respiratory tract pneumococci in the area. Minimal inhibitory concentrations (MIC's) of drugs against 12 pneumococcal isolates were determined and all the strains were susceptible to penicillin-G MIC levels at < 0.01 micrograms/ml, except one which had an MIC of 0.25 microgram/ml.

Corneal Isolates from Central Bacterial Ulcers		
	Organism	Number of Isolates
Single Isolates		
Class 1:	*S. pneumoniae*	20
	P. aeruginosa	9
	S. aureus	3
	Corynebacterium species	2
	S. epidermidis	2
	S. sanguis	2
	P. mirabilis	2
	M. lacunata	1
	K. pneumoniae	1
Class 2:	*S. pneumoniae*	1
Class 3:	*M. lacunata*	3
	S. pneumoniae	1
	Corynebacterium species	1
Class 4:	*S. epidermidis*	2
	Corynebacterium species	1
	Moraxella species	1
Anaerobe:	*P. prevotii*	1
TOTAL ISOLATES		53 from 53 eyes

Mixed isolates (classes of isolates in brackets)

S. pneumoniae(2) with *S. aureus*(1)
S. pneumoniae(2) with *S. epidermidis*(4)
S. pneumoniae(1) with *Propionibacterium acnes*
S. pneumoniae(1) with *Pasteurella species*(4)
M. lacunata(3) with *Corynebacterium species*(1)
M. lacunata(1) with *S. epidermidis*(1) and *Corynebacterium species*(4)
S. epidermidis(4) with *Corynebacterium species*(4)
S. pyogenes(1) with *S. epidermidis*(1): this combination was isolates from both eyes of a bilateral case

TOTAL 19
from 9 eyes

Note: for description of classes of isolates see "Patients and Methods".

Table 4.1

S. aureus was not found to be a common cause of central corneal ulceration in this survey. Isolates of Gram-negative bacteria were obtained from 18 eyes, with *P.*

aeruginosa (nine isolates) being the most common, followed by *Moraxella species* (four significant isolates).

In Class 5 (conjunctival pathogens) two *S. aureus*, and one *S. pneumoniae* strains were recovered as single isolates from each of three patients. In addition, a Class 5 *P. aeruginosa* was cultured together with a *Corynebacterium species* (Class 1), *Proteus mirabilis* (Class 5) together with a *S. epidermidis* (Class 4) and a *S. aureus* (Class 5) in addition to a *S. pneumoniae* (Class 2).

No mycobacteria were cultured on Lowenstein-Jenson media.

The anaerobes isolated were all obtained from chopped meat broth and consisted of five isolates from four cases.

Three were conjunctival isolates;

Peptostreptococcus micros with *S. pneumoniae* (Class 1) and a *Pasteurella species* (Class 4),

Bacteroides vulgatis with *S. epidermidis* (Class 4) and *Proteus mirabilis* (Class 5), and a

Peptococcus asaccharolyticus as a single isolate.

The following anaerobic isolates were recovered from the cornea of two patients:

Propionibacterium acnes with *S. pneumoniae* (Class 1), and

Peptococcus prevotii from another.

The latter *Peptococcus prevotii* was recovered from a case of severe bullous keratopathy and was confirmed on the direct smear. This isolate was considered significant and has been included in Table 4.1. This was the only corneal isolate in this case and the *Peptococcus asaccharolyticus* listed above was cultured from the conjunctiva of the same case. The significance of the other corneal isolate is doubtful in the presence of a Class 1 pneumococcus.

In addition to classes 4 and 5, conjunctival isolates (growth in more than one conjunctival media and no corneal media) were obtained in four eyes;

Streptococcus bovis group II with no corneal isolates,

S. epidermidis with no corneal isolates,

S. epidermidis with a *S. pneumoniae* (Class 1),

Streptococcus salivarius with a *Moraxella lacunata* (Class 1), a *S. epidermidis* (Class 1) and a *Corynebacterium species* (Class 4).

Illustrative cases showing direct smears were; Case 74 (Fig. 4.10, page 86), Case 51 (Fig. 5.19, page 131), Case 10 (Fig. 5.21, page 132), Case 9 (Fig. 5.83, page 184), Case 54 (Fig. 5.54, page 160) and Case 91 (Fig. 5.57, page 162).

4.3.2 Fungal Corneal Ulcers

The isolates from the cases of fungal keratitis are listed in Table 4.2. There was only one significant bacterial isolate from this group and that was a Class I *S. epidermidis* which was isolated in addition to a *Curvularia lunata* in a case with diabetes and renal failure. There were no conjunctival isolates in this group.

Corneal Isolates from Central Fungal Ulcers		
Isolate	**Class of Isolate**	**Predisposing Factor**
Aspergillus flavus	1	Diabetes
Phoma eupyrena*	1**	CDK
Candida guilliermondii	BHI	Diabetes
Fusarium moniliforme*	1**	Malnutrition
Curvularia lunata*	BHI	Diabetes, renal failure
Curvularia lunata	1**	CDK, malnutrition

Note: * Identification confirmed at the Identification Services Commonwealth Mycological Institute, Surrey, England
** Confirmation of fungus on direct smear, CDK is climatic droplet keratopathy
BHI = Fungus cultured from brain heart infusion broth only after repeated corneal scraping in clinically suggestive cases.

Table 4.2

4.3.3 Viral Corneal Ulcers

In the cases of central viral keratitis the corneal isolates were as follows;

S. epidermidis (Class 4),

Streptococcus mitior (Class 1),

Corynebacterium species (Class 4),

P. micros,

Escherichia coli (Class 4),

Herpes simplex.

The *P. micros* was not confirmed on direct smear and was not considered significant. The *S. mitior* occurred as a secondary infection in a dendritic ulcer.

Conjunctival isolates in this group included a *S. epidermidis* and also a *Clostridium sordellii* which was cultured in addition to the *E. coli.*

4.4 Microbiology of Marginal Corneal Ulcers

4.4.1 Marginal Catarrhal Corneal Ulcers

The corneal isolates from this group are shown in Table 4.3. There were six significant isolates of *S. aureus* from corneal specimens, two of these in conjunction with other organisms, and it was recovered as a tear film contaminant (Class 4) in two instances. In addition, *S. aureus* was cultured from lid specimens only in three cases. There were no other conjunctival isolates of *S. aureus.*

Corneal Isolates from Marginal Catarrhal Ulcers		
Organism	Number of Isolates	Class of Isolate
Single isolates		
S. aureus	6	1,1,1,3,4,4
Corynebacterium species	3	1,4,4
S. epidermidis	2	1,4
Corynebacterium hofmanii	1	4
S. pneumoniae	1	1
TOTAL ISOLATES	13 from 13 eyes	

Mixed isolates (classes in brackets)

P. mirabilis(4) with *S. pneumoniae*(4)
S. aureus(1) with *S. pneumoniae*(1)
S. aureus(1) with *S. pyogenes*(1) and *S. epidermidis*(1)
S. anginosis(1) with *Neisseria flava*(4)
S. anginosis(1) with *N. flava*(4) and *Proteus vulgaris*(1)

Total isolates from 5 eyes
(the last 2 eyes were
from a bilateral case)

Table 4.3

S. epidermidis was isolated as a Class 1 infection in two instances and Class 4 in one. It was isolated from the conjunctiva and lids of a further case.

Corynebacterium species were prominently isolated, but mainly as tear film contaminants. In addition, a *Corynebacterium spp.* was isolated in conjunction with *S. mitior* from the conjunctiva in two cases and from the lids of one case.

Streptococcal species were fairly common, usually as significant isolates and usually in mixed infections.

4.4.2 Marginal Ring Ulcers

The only corneal isolate in this group was a *Corynebacterium spp.* (Class 4) from one case. There were no other conjunctival isolates.

S. epidermidis and *Corynebacterium spp.* were found as lid isolates in two different cases.

4.4.3 Marginal Mooren's and Marginal "Other"

There were no isolates in the cases of Mooren's ulceration.

In the "other" group there was a *S. aureus* isolated as a conjunctival pathogen (Class 5) and a *Corynebacterium spp.* (Class 4) isolated from a different case.

4.4.4 Marginal Primary Ulcers

In four of the six eyes a significant isolate was obtained;

S. aureus (Class 1),
Neisseria gonorrhoeae (Class 3),
M. lacunata (Class 1) with *S. epidermidis* (Class 1),
Corynebacterium spp. (Class 1) with *S. aureus* (Class 5).

In the last case a *S. mitior* was isolated from the conjunctiva and a *P. micros* isolated from the cornea, but the latter was not confirmed on direct smear.

4.5 Microscopy and Antibiotic Sensitivities

Microscopy of smears was helpful in 85 of the 128 instances in which this investigation was done (Table 4.4). In 47 the organism was correctly identified and in 38

the negative slide was confirmed by no growth. There were only two instances where an organism was observed microscopically but nothing cultured. On the other hand, a negative slide with a positive culture was common and was the experience with a third of the slides.

Microscopy of Smears				
Result	Ulcer Group (Numbers)		Total	
	Central	Marginal	Number	Percentage
Organism identified	40	7	47	37
Smear negative, culture negative	23	15	38	29
Smear negative, culture positive	21	20	41	32
Smear positive, culture negative	2	0	2	2
TOTAL	86	42	128	100

Table 4.4

All aerobic bacterial isolates were tested for antibiotic susceptibility with a modified Kirby-Bauer disc diffusion technique on blood agar plates All isolates were sensitive to either cefazolin or gentamicin, which were the two antibiotics used in treating the bacterial infections.

The anaerobic isolates were all sensitive to cefoxitin and chloramphenicol but no change from the usual antibiotics was made.

The fungal isolate seusitivities (MIC in microgram/ml) were as follows;

	Amp.B	Keto.	Micon.	Clot.	Nat.	5FC
Aspergillus flavus	3.1	3.1	0.18	-	3.1	-
Phoma eupyrena	3.1	0.38	0.38	0.38	0.75	-
Candida guilliermondii	3.1	0.04	0.04	0.04	3.1	0.04
Fusarium moniliforme	6.25	25.0	6.25	-	1.5	-
Curvularia lunata	0.18	1.5	0.09	0.38	0.75	-
Curvularia lunata	-	6.25	6.25	3.1	0.18	-

Note: Amp. B is Amphotericin B, Keto. is ketoconazole, Micon. is miconazole, Clot. is clotrimazole, Nat. is natamycin and 5FC is 5-fluorocytosine. - means no data.

4.6 Microbial Findings and their Possible Relationship with Clinical Features and Risk Factors

4.6.1 Clinical Features of Corneal Ulcers

A hypopyon was present in 71 eyes, two-thirds of which were central bacterial ulcers (Table 4.5). All of the fungal ulcers, eleven of thirty marginal catarrhal ulcers and five of thirteen central viral ulcers showed hypopyons on admission. Significant anterior chamber activity without hypopyon was seen in a further seven central bacterial and three marginal catarrhal ulcers. Hypopyon sizes varied from 0.2mm in height to full hypopyons, but the average size was 1.3mm and 83% of all the hypopyons were 2mm or less in height.

Clinical Features of Corneal Ulcers

Type of Ulcer	Number of eyes				
	Hypopyons	Significant A.C. Activity	Descemetocoele on Admission	Perforation on Admission	Number in Group
Central:					
Bacterial	46	7	12	14	91
Fungal	6	0	0	0	6
Viral	5	0	2	1	13
Marginal:					
Catarrhal	11	3	1	5	30
Ring	1	0	1	5	12
Mooren's	0	0	0	0	4
Primary	2	0	0	1	6
Other	0	0	0	0	5
TOTAL	71	10	16	26	167

Note: Significant A.C. activity is anterior chamber activity of 2+ cells or greater.

Table 4.5

Of the twelve descemetocoeles in the central bacterial group, one was leaking (and thus was also perforated on admission) and another perforated after admission. In the central fungal group one perforated after admission. In the central viral group, one of the descemetocoeles was leaking and is shown also as a perforation on admission.

Both of the descemetocoeles in the marginal catarrhal and marginal ring groups were leaking and are also shown as perforations. There was one perforation after admission in the marginal Mooren's group.

In the central bacterial group, more significant isolates were obtained when an hypopyon or significant anterior chamber activity (two plus of cells or greater) was present. In 70% of these cases a significant isolate was obtained compared with 53% in the remaining cases without significant anterior chamber activity but this difference was not statistically significant.

S. pneumoniae was associated with 38% f the cases with hypopyon or significant anterior chamber activity.

Of the twelve central bacterial ulcers showing descemetocoeles on presentation, isolates were obtained in seven cases.

S. pneumoniae was recovered from four eyes, of which one perforated after admission (three Class 1 and one Class 3), while *M. lacunata* (Class 3), *Moraxella species* (Class 4), and *P. aeruginosa* (Class 1) were each isolated from one eye.

Of the fourteen central bacterial ulcers showing perforation on admission, isolates were obtained in eight eyes. These were:

S. pneumoniae (two Class 1 and one Class 5),
P. aeruginosa (Class 1),
S. epidermidis (Class 1),
P. prevotii,
S. aureus (Class 1) with *S. pneumoniae* (Class 2),
Corynebacterium species (Class 1) with *P. aeruginosa* (Class 5).

Perforations after admission occurred in six cases in the central bacterial group. Only two organisms were responsible;

S. pneumoniae (Class 1) in four eyes, one of which had presented as a descemetocoele,
P. aeruginosa (Class 1) in two eyes.

Endothelial plaque formation was not a predictor of whether an organism would be cultured. It was present in 30 of the 91 central bacterial ulcers. There was a relationship between endothelial plaque presence and significant anterior chamber activity (two plus cells or greater). With endothelial plaque present, 24 of 30 eyes showed hypopyon or significant anterior chamber activity. With no endothelial plaque, 29 of 61 showed hypopyon or significant anterior chamber activity. This difference is significant with p

less than 0,01 (Chi square using Yates correction factor).

As more eyes with hypopyon and significant anterior chamber activity showed isolates, and endothelial plaques were associated with anterior chamber activity, it follows that endothelial plaques would probably be associated with positive cultures if there was no antibiotic pretreatment. This would occur because significant isolates would induce anterior chamber activity and endothelial plaques.

In central bacterial ulcers, folds in Descemet's membrane surrounding the ulcer and radiating out from it were not found to be a predictor of impending perforation. Neither were the folds present in particularly deep ulcers. Four were seen in outer third ulcers and three in middle third ulcers. In two cases with folds the depth of the ulcer could not be determined.

Whether the ulcer was round, oval or irregular was not useful in predicting the likely causative organism. Pneumococcal ulcers were, however, seen in association with corneal abscess, limited in area but penetrating deeply with early perforation or descemetocoele formation, whereas pseudomonal ulcers showed a more superficial spreading involving a large area of cornea before perforation.

Cases illustrating some of the clinical features were;

Case 31: A six-year-old male with malnutrition and tuberculosis showed corneal ulceration typical of vitamin A deficiency (Fig. 4.1). *S. aureus* (Class 5) was isolated and response to vitamin A treatment and the antibiotic regimen used was good (Fig. 4.2).



Figure 4.1



Figure 4.2

Case 143: This 28-year-old male had been struck by a piece of bone in the eye. *S. pneumoniae* (Class 1) was isolated and there were no other predisposing factors. Response to treatment was good and folds in descemet's membrane can be seen in the photographs (Fig. 4.3 and 4.4).



Figure 4.3



Figure 4.4

Case 151: This 43-year-old male security guard was struck in the eye by his wife with a piece of carpet. *S. pneumoniae* (Class 1) and *Pasteurella species* (Class 4) were isolated and the man had two factors for alcohol abuse. The ulcer healed well on the treatment given (Fig. 4.5 and 4.6).



Figure 4.5



Figure 4.6

Case 28: A 12-year-old girl struck with a fist by her father and presented with a superficial 4mm by 4mm corneal ulcer (Fig. 4.7) from which *P. aeruginosa* (Class 1) was isolated. The ulcer healed well (Fig. 4.8) and the final vision was 6/36.



Figure 4.7



Figure 4.8

Case 74: A 36-year-old male with trichiasis presented with an ulcer below the visual axis (Fig. 4.9). *P. mirabilis* (Class 1) was isolated (Fig. 4.10) and he had moderate malnutrition and 2 factors for alcohol abuse. Electrolysis was done for the trichiasis and the ulcer healed well.



Figure 4.9



Figure 4.10

Case 84: This 47-year-old male had no local predisposing factor but was mildly malnourished with a central hypopyon ulcer (Fig. 4.11). *S. epidermidis* (Class 4) and *P. mirabilis* (Class 5) were isolated, and the ulcer healed well (Fig. 4.12).



Figure 4.11



Figure 4.12

Case 93: A 27-year-old male presented with a paracentral ulcer (Fig. 4.13) and had moderate malnutrition and 2 factors for alcohol abuse. *Corynebact. spp.* (Class 1) and *M. lacunata* (Class 3) were isolated and the ulcer healed well (Fig 4.14).



Figure 4.13

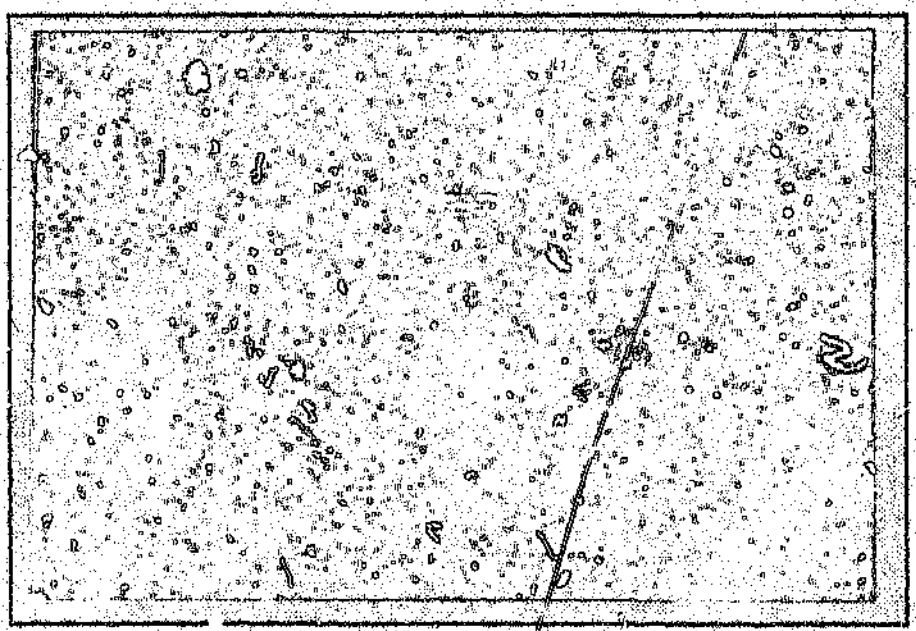

Figure 4.14

Case S6: A deaf schizophrenic male presented with a paracentral ulcer (Fig. 4.5). He was severely malnourished but had no other predisposing factors. *S. pneumoniae* (Class 2) and *S. epidermidis* (Class 4) were isolated and the ulcer healed well (Fig.4.16).



Figure 4.15



Figure 4.16

Case 96: This 52-year-old female had been treated with topical steroid drops after a corneal laceration repair (chopping wood). She presented with a central hypopyon ulcer (Fig 4.17) and *S. sanguis* (Class 1) was isolated. She had no other predisposing factors and the ulcer healed well.



Figure 4.17

4.6.2 Comparison of Local Antibiotic Pretreatment with Significant Isolates Obtained

As discussed in Chapter 2, nearly half of patients presenting to St John Eye Hospital with corneal ulceration had used local antibiotics prior to presentation.

Antibiotic pretreatment in the eyes in which significant isolates (Classes 1-3) were obtained were compared with those in which no growth or only Class 4 or 5 isolates were obtained. This analysis is only valid for the larger groups.

In the central bacterial group, 18 of 56 (32%) of the eyes with significant isolates had been pretreated, while 21 of 35 (60%) of the eyes with no growth or insignificant isolates had been pretreated with antibiotics. This difference is significant (p less than 0,05 with Chi square test using Yates correction factor). Antibiotic pretreatment thus reduced the number of significant isolates.

In the marginal catarrhal group there was no significant difference between eyes with significant isolates and those without with respect to pretreatment with antibiotics.

4.6.3 Isolates in Cases of Foreign Bodies and Other Corneal Trauma Causing Central Corneal Ulcers

Significant isolates were obtained in 14 of the 20 cases (Table 4.6). The most common was *S. pneumoniae* with eight Class 1 isolates and one Class 2 isolate. *P. aeruginosa* was isolated in four cases, all of which were categorized as Class 1 isolates.

Cases with Foreign Bodies and Other Trauma as Predisposing Causes

Case No	Type of Injury (history)	Age (years)	Sex	Hypopyon or A.C. Activity	Perforation on Admission	Descemetocele	Antibiotic Pretreatment	Organism(s) Isolated
94	Black object from stove	19	F	Yes	No	No	Yes	*P. aeruginosa*(1)
134	FB in eye	45	M	Yes	No	No	Yes	*P. aeruginosa*(1)
143	Piece of bone	28	M	Yes	No	No	Yes	*S. pneumoniae*(1)
18	Sharp grass	67	F	No	No	No	No	No growth
3	Catapult, corneal laceration	8	M	Yes	No	No	Yes	*S. aureus*(1)
6	MVA, glass in eye	33	M	Yes	No	No	Yes	*S. pneumoniae*(1)
10	Hit with open hand	40	F	Yes	After	No	No	*S. pneumoniae*(1)
20	Brick chip	41	M	No	No	No	Yes	No growth
28	Hit with fist (father)	12	F	Yes	No	No	No	*P. aeruginosa*(1)
37	Branch, climbing tree	8	M	Yes	No	No	Yes	No growth
39	Fell and hit eye	8	M	Yes	No	No	No	*S. pneumoniae*(1)
110	Wire, corneal laceration	32	M	Yes	No	No	Yes	*S. epidermidis*(4) *Corynebact. species*(4)
41	Fell in hole	48	M	Yes	No	No	No	*P. aeruginosa*(1)
128	Stick in eye	54	M	Yes	No	No	Yes	*S. pneumoniae*(1)
147	Stone injury	4	M	Yes	No	No	No	*S. pneumoniae*(1)
148	Ball hit eye	2	M	Yes	No	No	No	*S. pneumoniae*(1)
150	Bottle hit eye	38	M	No	No	Yes	Yes	No growth
151	Hit with carpet by wife	43	M	Yes	No	No	No	*S. pneumoniae*(1) *Pasteurella species*(4)
159	Other child poked wood in eye	2	F	No	No	No	Yes	*S. pneumoniae*(2)
77	Branch in eye	49	M	No	No	No	No	No growth

Note: MVA is motor vehicle accident. The last case is a central viral ulcer, the remainder are central bacterial. A.C. Activity is significant anterior chamber activity (2 plus cells or greater).

Table 4.6

Antibiotic pretreatment was common in this group with eleven of the twenty cases having received definite or probable pretreatment.

Four of the isolates of *S. pneumoniae* occurred in children.

Fifteen of the 20 had a hypopyon or significant anterior chamber activity on admission (75%). There was only one descemetocoele on admission and only one perforation occurring after admission in this group.

4.6.4 Isolates in Cases of Climatic Droplet Keratopathy

Significant isolates were obtained in ten of the 20 cases (Table 4.7).

Cases with Climatic Droplet Keratopathy (CDK) as a Predisposing Cause										
Case No	Ulcer Type	CDK Grade	Age (years)	Sex	Hypopyon	A.C. Activity	Descemetocoele on Admission	Perforation on Admission	Antibiotic Pretreatment	Organism(s) Isolated
27	Central Bacterial	4	69	M	No	2+	No	Yes	No	*S. pneumoniae*(5)
38		3	55	M	No	No	No	Yes	No	No growth
49		4	60	M	Yes	-	No	No	No	*S. pneumoniae*(1)
58		4	62	M	No	No	No	No	No	No growth
60		3	44	M	No	No	Yes	No	No	No growth
65		3	65	M	Yes	-	Yes	No	Yes	*Moraxella species(4)*
67		4	72	M	No	3+	No	No	No	No growth
72		3	82	M	Yes	-	No	After	Yes	*S. pneumoniae*(1)
79		3	64	M	Yes	-	No	After	No	*S. pneumoniae*(1)
80		4	64	M	Yes	-	No	No	Yes	*S. epidermidis*(4)
83		3	75	M	No	No	No	No	Yes	No growth
87		4	62	M	No	No	Yes	Yes	No	*S. pneumoniae*(1)
99		3	68	M	No	No	No	Yes	Yes	No growth
116		3	63	M	Yes	-	Yes	No	No	*S. pneumoniae*(1)
123		3	66	M	No	4+	Yes	No	Yes	*S. pneumoniae*(3)
140		4	50	M	Yes	-	No	No	Yes	*Corynebact. species*(3)
146		4	80	M	No	No	No	No	No	*Corynebact. species*(1)
54	Central Fungal	4	62	M	Yes	-	No	No	No	*Phoma enpyrena*(1)
154		4	55	M	Yes	-	No	No	No	*Curvularia lunata*(1)
132	Central Viral	3	65	M	Yes	-	No	No	No	*E. coli*(4)

Note: After is perforation occurring after admission.

Table 4.7

S. pneumoniae was the commonest bacterial isolate in this group with five Class 1 isolates, one Class 3, and one Class 5. *Corynebacterium species* was recovered as Class 1 and 3 isolates in two eyes.

Tear film contaminants (Class 4) were found in three eyes and included *S. epidermidis*, *Moraxella species* and *E. coli*.

There were two fungal isolates in this group.

Seven of the 20 eyes had been pretreated with antibiotic.

Of the twenty cases, thirteen had hypopyon or significant anterior chamber activity on admission (65%). Four eyes showed perforation on admission and two perforated after admission. Five presented with descemetocoeles.

4.6.5 Isolates in Adult Cases where Malnutrition was a Predisposing Factor

Significant isolates were obtained in 22 of the 31 patients with more than one significant isolate in one case (Table 4.8).

Central Corneal Ulcer Patients with Malnutrition as a Predisposing Factor

Case No	Severity of Malnutrition	Ulcer Type	Age (years)	Sex	Hypopyon	A.C. Activity	Descemetocele on Admission	Perforation on Admission	Antibiotic Pretreatment	Organism(s) Isolated
5	Mild	CB	44	M	No	No	No	Yes	No	*Corynebact. species*(1), *P. aeruginosa*(5)
49		CB	60	M	Yes	-	No	No	No	*S. pneumoniae*(1)
72		CB	82	M	Yes	-	No	After	Yes	*S. pneumoniae*(1)
75		CB	52	M	No	No	No	No	No	No growth
79		CB	64	M	Yes	-	No	After	No	*S. pneumoniae*(1)
83		CB	64	M	Yes	-	No	No	Yes	*S. epidermidis*(4)
85		CB	47	M	Yes	-	No	No	Yes	*S. epidermidis*(4), *P. mirabilis*(5)
128		CB	54	M	Yes	-	No	No	Yes	*S. pneumoniae*(1)
150		CB	38	M	No	No	Yes	No	Yes	No growth
36		CB	58	M	Yes	-	No	No	No	*S. aureus*(1)
154		CF	62	M	Yes	-	No	No	No	*Curvularia lunata*(1)
91		CF	80	F	Yes	-	No	No	Yes	*Fusarium moniliforme*(1)
66		CV	40	M	No	No	No	No	No	*Corynebact. species*(4)
138		CV	56	M	No	No	No	No	No	*Herpes simplex*
93	Moderate	CB	27	M	Yes	-	No	No	No	*Corynebact. species*(1), *M. lacunata*(3)
120		CB	50	M	No	No	No	No	Yes	*S. pneumoniae*(1)
165		CB	80	M	Yes	-	No	No	Steroid	*S. pneumoniae*(1)
130		CB	37	F	No	No	Yes	No	Yes	*P. aeruginosa*(1)
65		CB	65	M	Yes	-	Yes	No	Yes	*M. species*(4)
16		CB	55	M	No	No	No	Yes	No	*S. pneumoniae*(1)
59		CB	52	M	No	No	No	No	Yes	*S. epidermidis*(4), *P. mirabilis*(5)
61		CB	49	M	No	4+	Yes	After	No	*S. pneumoniae*(1)
74		CB	36	M	No	No	No	No	No	*P. mirabilis*(1)
140		CB	50	M	Yes	-	No	No	Yes	*Corynebact. species*(3)
87		CB	62	M	No	No	Yes	Yes	No	*S. pneumoniae*(1)
94		CB	19	F	Yes	-	No	No	Yes	*P. aeruginosa*(1)
77		CV	49	M	No	No	No	No	No	No growth
156		CV	67	F	Yes	-	Yes	No	Yes	No growth
55	Severe	CB	30	M	Yes	-	No	No	No	*S. pneumoniae*(2), *S. epidermidis*(4)
27		CB	69	M	No	2+	No	Yes	No	*S. pneumoniae*(5)
41		CB	48	M	Yes	-	No	No	No	*P. aeruginosa*(1)

Note: After is perforation occurring after admission. Steroid is steroid pretreatment only.

Table 4.8

There were nine Class 1 isolates of *S. pneumoniae*, and a further Class 5, and a Class 2 *S. pneumoniae* isolate associated with a Class 4 *S. epidermidis*.

P. aeruginosa (Class 1) was isolated from three eyes and a Class 5 isolated in conjunction with a *Corynebacterium species* (Class 1).

In addition to the latter, *Corynebacterium species* was isolated from two eyes as Class 3 and 4 isolates and as a Class 1 in conjunction with a *M. lacunata* (Class 3).

S. epidermidis was isolated as a Class 4 alone in one eye, and in conjunction with *P. mirabilis* (Class 5) in two eyes. It was also cultured in addition to a Class 2 *S. pneumoniae* mentioned above.

Single isolates of *S. aureus* (Class 1), *P. mirabilis* (Class 1), and *Moraxella species* (Class 4) were obtained.

There were two fungal and one viral isolate from this group.

Thirteen of the 31 patients had been pretreated with antibiotic, one with topical steroid only, and there were only four patients in whom a culture was not obtained.

Nineteen of the 31 eyes showed hypopyon or significant anterior chamber activity on admission (61%). Perforations were seen in three eyes on admission and three after admission. There were six descemetocoeles on admission.

4.6.6 Organisms Isolated in Cases with Alcohol Abuse as a Predisposing Factor

Significant isolates were obtained in 15 of the 21 patients including two significant organisms from one patient (Table 4.9). *S. pneumoniae* was isolated as a Class 1 isolate in six cases as an only organism and in one eye in conjunction with *Pasteurella species* (Class 4).

Central Corneal Ulcer Patients with Alcohol as a Predisposing Factor									
Case No	Ulcer Type	Age (years)	Sex	Hypopyon	A.C. Activity	Descemetocoele on Admission	Perforation on Admission	Antibiotic Pretreatment	Organism(s) Isolated
	Alcohol 2 factors:								
8	CB	63	M	Yes	-	Yes	No	Yes	No growth
13	CB	65	M	Yes	-	No	No	No	*S. aureus*(5)
16	CB	55	M	No	No	No	Yes	No	*S. pneumoniae*(1)
19	CB	42	M	Yes	-	No	No	Yes	*S. pneumoniae*(1)
50	CB	60	M	No	No	No	No	No	*S. aureus*(1)
51	CB	29	M	Yes	-	Yes	No	No	*M. lacunata*(3)
65	CB	65	M	Yes	-	Yes	No	Yes	*M. lacunata*(4)
74	CB	36	M	No	No	No	No	No	*P. mirabilis*(1)
93	CB	27	M	Yes	-	No	No	No	*Corynebact. species*(1), *M. lacunata*(3)
105	CB	64	F	Yes	-	No	No	No	*S. pneumoniae*(1)
115	CB	63	M	Yes	-	Yes	No	No	*S. pneumoniae*(1)
146	CB	80	M	No	No	No	No	No	*Corynebact. species*(1)
151	CB	43	M	Yes	-	No	No	No	*S. pneumoniae*(1), *Pasteurella species*(4)
163	CB	38	M	Yes	-	No	No	No	*P. mirabilis*(1)
	Alcohol 3 factors:								
15	CB	50	M	No	No	No	Yes	Yes	No growth
36	CB	58	M	Yes	-	No	No	No	*S. aureus*(1)
60	CB	44	M	No	No	Yes	No	No	No growth
61	CB	49	M	No	4+	Yes	After	No	*S. pneumoniae*(1)
79	CB	64	M	Yes	-	No	After	No	*S. pneumoniae*(1)
80	CB	64	M	Yes	-	No	No	Yes	*S. epidermidis*(4)
141	CB	41	M	Yes	-	No	No	No	*M. lacunata*(3)

Note: After is perforation occurring after admission.

Table 4.9

M. lacinata was isolated as Class 3 from two eyes as an only organism and in one eye in conjunction with a Class 1 *Corynebacterium species*. It was also cultured as a Class 4 isolate in one eye.

P. mirabilis was found as a Class 1 isolate in two eyes and as a Class 2 isolate in one eye.

S. aureus (Class 1) was isolated from two eyes and a Class 5 from one eye.

Two Class 1 isolates of *Corynebacterium species* were obtained, one of which was in association with the *M. lacunata* above.

S. epidermidis (Class 4) was isolated from one eye.

Only five of the 21 cases had been pretreated with antibiotics and in only three eyes was no isolate obtained.

Fifteen of the 21 eyes showed hypopyon or significant anterior chamber activity on admission (71%). There were two perforations and six descemetocoeles on admission and two perforations after admission.

4.6.7 Organisms Isolated in Cases with Spontaneous Onset and No Predisposing Factor

There were only six organisms isolated from four eyes in this group of twelve patients and only three eyes had significant isolates (Table 4.10).

Six of the 12 had been pretreated with antibiotic.

There were five hypopyons on admission (42%). Three eyes showed perforations and one a descemetocoele on admission.

Cases with Spontaneous Onset and No Predisposing Cause									
Case No	Ulcer Type	Age (years)	Sex	Hypopyon	A.C. Activity	Perforation	Descemetocoele	Antibiotic Pretreatment	Organism(s) Isolated
26	Central Bacterial	63	M	No	No	No	No	Yes	No growth
32		60	M	No	No	Yes	No	No	No growth
35		42	M	No	No	No	No	Yes	No growth
53		3	M	No	No	No	No	No	*P. aeruginosa*(1)
73		32	M	No	No	No	No	No	No growth
81		81	M	Yes	-	Yes	No	No	No growth
55		60	M	Yes	-	No	No	Yes	No growth
103		50	M	Yes	-	No	No	No	*M. lacunata*(1), *S. epidermidis*(1),
107		53	M	Yes	-	No	No	Yes	*K. pneumoniae*(1)
152		58	M	Yes	-	No	No	No	No growth
30	Central Viral	2	F	No	No	No	No	Yes	No growth
29		2	M	No	No	Yes	Yes	Yes	*S. epidermidis*(4)

Table 4.10

4.6.8 Comparison of Bacterial Isolates, Selected Clinical Features and Predisposing Factors

Clinical features and isolates varied according to the predisposing factor (Table 4.11).

Summary of Clinical Features and Significant Isolates by Predisposing Factor for Central Ulcers					
	Percentage Significant Isolates	Of which the Commonest Organisms were:	Hypopyon or Significant A.C. Activity (%)	Pretreatment with Antibiotic (%)	Complications: Perforation or Descemetocoele (%)
Trauma (and FB's)	70	*S. pneumoniae*(45%) *P. aeruginosa*(20%)	75	55	10
CDK	50	*S. pneumoniae*(30%) *Coryneibact. spp.*(10%)	65	35	50
Malnutrition	71	*S. pneumoniae*(46%) *P. aeruginosa*(14%)	61	42	36
Alcohol	71	*S. pneumoniae*(33%) *M. lacunata*(14%) *P. mirabilis*(14%)	71	24	43
Spontaneous onset	25	-	42	50	25

Note: There were only four different significant organisms isolated from three eyes in the last group. FB is foreign body, CDK is climatic droplet keratopathy, A.C. is anterior chamber.

Table 4.11

It can be seen that in the trauma category many of the cases had been pretreated with an antibiotic, virulent organisms were commonly isolated, and complications were few. This might suggest that this group receives better medical attention than the patients in whom alcohol was a predisposing factor. The "alcohol" group shows a different spectrum of common organisms isolated with a low level of antibiotic pretreatment and a high complication rate.

There were significantly more complications in both the CDK and "alcohol" groups than in the trauma cases (p less than 0,05 using Chi square with the Yates correction factor).

Strains of *Corynebacterium species* were seen in association with the CDK group and *M.lacunata* and *P.mirabilis* in association with alcohol. *S.pneumoniae* was commonest in all groups (except for the spontaneous onset group), and *P. aeruginosa* was associated with cases involving trauma and malnutrition.

The spontaneous onset group shows a high level of antibiotic pretreatment with few significant isolates and a fairly low complication rate.

4.7 Discussion

Leber[13] described the first corneal ulcer in which an infection was the cause. The organism was *Aspergillus glaucus* and the year was 1879. The first bacterial ocular pathogen, the gonococcus, was reported in the same year by Neisser[14]. Between 1883 and 1886 the Koch-Weeks bacillus *(Haemophilus aegypticus)* was described and between 1896 and 1899 the Morax-Axenfeld diplobacillus *(Moraxella lacunata)* was described and shown to cause serpiginous hypopyon keratitis[1]. In 1896 Gifford[15] reported the pneumococcus as a cause of acute catarrhal conjunctivitis.

The class system of placing laboratory findings in different categories was to assess the relevance of microbial isolates and to exclude effectively contaminant bacteria and fungi. From Class 1 to Class 5 presents a decreasing likelihood of significance. Florid growth of an organism in several media (Class 1) would be highly significant, whereas recovery of a pathogen only from the conjunctiva (Class 5) would be of questionable significance. The latter isolate may be considered when antibiotic pretreatment is suspected of having sterilised the cornea. Classes 4 and 5 are included in an attempt to use conjunctival media in a meaningful way, rather than relying solely on corneal specimens. A Class 4 isolate may reflect a tear film contaminant such as *S. epidermidis*, or a more fastidious organism that will only grow on a certain type of medium. An example of this is *Moraxella species* which grew in serum broth of cornea and conjunctiva. During the study it was found that about 1 in 5 of the broths which were incubated prior to inoculation were turbid when removed from the incubator and were discarded.

Corneal isolates were obtained in 62 of the 91 eyes with central bacterial corneal ulcers (67%). There were 72 organisms isolated of which 62 were significant (Classes 1-3 and the anaerobic isolate).

S. pneumoniae was clearly the commonest isolate with 26 significant isolates (42 % of significant bacterial isolates), followed by *P. aeruginosa* with nine significant isolates (15% of significant bacterial isolates). *S. aureus* was only significantly isolated from four eyes, one of these in conjunction with *S. pneumoniae*.

Looking at it another way, when significant isolates in the central group of ulcers are examined, the spectrum shows that in this population, single Gram positive isolates were twice as common as single Gram negative isolates, and fungal ulcers constituted only about 5% of cases. There was no growth or insignificant isolates in 40% of the cases

(Table 4.12).

The Spectrum of Isolates in Central Ulcers at St John Eye Hospital		
Significant Isolates	Number of Eyes	% of Central Ulcers
Gram +ve bacteria	33	30.0
Gram -ve bacteria	16	14.5
Mixed bacteria	9	8.2
Fungal	6	5.5
Viral	2	1.8
No growth	44	40.0
	110	100.0

Note: The significant isolates from viral cases were *S. mitior* and Herpes simplex.

Table 4.12

S. aureus is usually the commonest Gram-positive bacterium reported as a cause of central bacterial keratitis[1,2,6,16], although the early series reported by Thygeson[17] showed pneumococci to be causative in 70% of 50 central corneal ulcers. Rhodes[18] found pneumococci to be three times as common as *S. aureus* in a group of 120 patients, 67% of whom were mine workers.

S. epidermidis has featured as most prominent organism, usually in retrospective studies[9,12,19,20] but also in a prospective study[21]. *P. aeruginosa* has been most prominent in some areas[3,22,23,24,25].

In their retrospective analysis of a 30 year period (1938 to 1968), Locatcher-Khorazo and Seegal[1] reported 3,535 bacterial corneal ulcers with 95% of the isolates being only four organisms;

S. aureus	1755	(50%)
		(212 were marginal ulcers)
S. pneumoniae	1233	(35%)
P. aeruginosa	194	(6%)
M. lacunata	77	(2%)
S. aureus plus *S. pneumoniae*	72	(2%)

The difference in the range of organisms is at least partly due to a worldwide difference in the conjunctival sac carrier rates of various organisms[1]. In a large series, Locatcher-Khorazo and Seegal[1] showed a high (13%) carrier rate of pneumococci in the normal conjunctival sac in children under 5 years of age but only 2-3% thereafter. In the St John Eye Hospital study, five children had pneumococcal ulcers, four of whom were under 5 years old (three were central bacterial ulcers). The other pneumococcal ulcers were evenly spread through the age groups over 20 years.

Pneumococcal typing is not particularly useful in that organisms usually reflect upper respiratory tract pneumococci[1]. This was found to be true in this study, although the types of pneumococci differed from those previously reported. As multiple antibiotic resistant pneumococci have been reported from South Africa[26], a careful watch was kept for these organisms, but none was found.

Reliable isolation of anaerobic bacteria is more time-consuming than of aerobic bacteria, and indications are that these organisms should not be ignored. Corneal ulceration caused by anaerobic bacteria was considered uncommon enough to warrant single case reporting from the 1950's into the 1970's[27-30]. In 1977, Jones and Robinson reviewed the subject[31] and included details of five cases of anaerobic keratitis. They also proposed guidelines for defining a significant isolate. Perry et al[32] reported 11 cases of anaerobic corneal ulcer, using very strict criteria for case definition, from a series of 162 bacterial corneal ulcers. All these anaerobic cases[31,32] had some predisposing factor(s). Anaerobic bacteria may be pathogenic alone or acting synergistically with aerobic bacteria, as has been suggested[33,34]. The practical implications of this group of organisms with respect to treatment is uncertain, as they are usually sensitive to the same antibiotics as have been used for aerobic bacterial keratitis. A change to chloramphenicol is recommended[32] once an anaerobe is isolated, but this information may not be available in time to be useful.

In marginal catarrhal ulcers at St John Eye Hospital, *S. aureus* was the most common isolate and it was recovered from eight of the 30 eyes. The other prominent isolates in these ulcers were streptococcal species which were often recovered in mixed isolates. *S. epidermidis* was isolated from three eyes, and two of these isolates were regarded as significant. The recovery of streptococcal species from mixed cultures has been reported by Jones[35].

There were no significant isolates from the marginal ring, Mooren's, and "other" groups.

The isolates from marginal primary ulcers were generally similar to those found in central bacterial ulcers as causative factors were similar. The one unique infection occurring in the marginal cornea was the *N. gonorrhoeae* infection which typically occurs in this position.

Direct smears were found to be significantly more helpful in central as opposed to marginal ulcers (p less than 0,05 using the normal deviate test). This difference was largely due to the fact that an organism could be identified from many of the central ulcers. The results confirm the fact that, if an organism is seen on the smear, it is very likely to be the causative organism, but if no organism is seen there is still a 50% chance that an organism will be cultured.

There were no instances of antibiotic resistance in the aerobic and anaerobic bacteria encountered. The cefazolin and gentamicin used covered the full spectrum of organisms.

Miconazole was the mainstay of treatment for fungal ulcers and ketoconazole was used as an adjunct in sensitive isolates. All of the organisms were sensitive to natamycin and this was used as a second-line anti-fungal agent.

Hypopyon formation or significant anterior chamber activity (two plus cells or greater) was associated with endothelial plaque formation on the cornea around the ulcer. This association was significant with p less than 0,01 (Chi square test). These two factors were also associated with significant isolates but there was no statistical significance present. If hypopyon or significant anterior chamber activity was present there was usually endothelial plaque formation and a significant organism could be isolated so long as the cornea had not been sterilised with antibiotic pretreatment.

Descemetocoeles on presentation were seen in association with *S. pneumoniae*, *Moraxella spp.* and *P. aeruginosa*.

Perforations both on admission and after admission were mostly seen with *S. pneumoniae* and *P. aeruginosa*.

Pretreatment with antibiotic was associated with either no bacterial isolation or isolates that were not significant (Classes 4 and 5). This association was statistically significant with p less than 0,05 (Chi square test).

Clinical features and isolates varied according to the predisposing factors. In general, *S. pneumoniae* was the commonest isolate in all the groups while *P. aeruginosa* was usually associated with the trauma and malnutrition cases. In the CDK cases, *Corynebacterium species* were the second commonest isolate while *Moraxella species* and *P. mirabilis* were isolated in patients with alcohol as a predisposing factor. *Corynebacterium spp.* have been reported as a cause of infection in indolent corneal ulcers[36] while *Moraxella spp.* have been described in association with alcoholism[7]. In the trauma cases antibiotic pretreatment was common and complications were low while complications were highest in the CDK and alcohol groups. In the group with spontaneous onset and no predisposing cause identified, there was a high rate of pretreatment with antibiotic and a corresponding low rate of bacterial isolation and complications. This latter, rather small group, were perplexing to treat as causation was usually not obvious. Fortunately they had few complications and the nature of the group appears to be largely determined by antibiotic pretreatment.

Several early studies[17,18] reported *S. pneumoniae* as a prominent organism in central corneal ulcers. Following the reports from Southern India[37] and South Africa[38] in 1985 it has been suggested[9] that *S. pneumoniae* might remain the most important organism in developing countries and that there might later be a shift to *S. aureus* being the most common organism. Confirmation of this was found in the report from Nepal[39] in 1991. In this large prospective study, *S. pneumoniae* was the commonest isolate (31%).

The other shift in bacterial patterns has been to Gram-negative organisms, particularly *P. aeruginosa*, in soft contact lens wear. This shift has been mainly observed in developed countries notably the United States of America where an estimated 12000 of the 13 million soft contact lens wearers will develop ulcerative keratitis annually[40]. *P. aeruginosa* is not usually pathogenic[1] and has previously been reported mostly in association with corneal trauma[3,6]. The other organism which has achieved prominence mainly in contact lens wearers is *Acanthamoeba*[41]. This infection has been reported from South Africa only once[42] and this patient was not a contact lens wearer.

The multiple scrape technique, described by Jones[10], was largely successful in view of the fact that half the cases had been pretreated with antibiotics. The use of Classes 4 and 5 helped differentiate tear film contaminants and indicated possible etiological agents when corneal cultures were negative. From a practical standpoint, however, the corneal scrapes for slides and culture remain the priority and if resources are limited, conjunctival

and lid cultures need not be taken.

In designing an initial treatment protocol, attention should be directed at the spectrum of organisms usually responsible while remaining alert for the less common isolates like anaerobic bacteria and fungi. The microbial isolates were related to predisposing causes and complications occurred more commonly in association with some predisposing factors than with others. As would be expected, availability of antibiotic was an important determinant of the eventual outcome.

4.8 References

1. Locatcher-Kh. azo D, Seegal BC. *Microbiology of the eye.* St Louis: Mosby, 1972: 1-12,69-71.
2. Asbell P, Stenson S. Ulcerative keratitis-survey of thirty years' laboratory experience. *Arch Ophthalmol* 1982; 100: 77-80.
3. Liesegang TJ, Forster RK. Spectrum of microbial keratitis in South Florida. *Am J Ophthalmol* 1980; 90: 38-47.
4. Ostler HB, Okumoto M, Wilkey C. The changing pattern of the etiology of central bacterial (hypopyon) ulcer. *Trans Pacific Coast Otolaryngol Ophthalmol Soc* 1976; 57: 235-45.
5. Jaibson PR, Donnenfeld ED. Corneal ulcers related to contact lens use. *Int Ophthalmol Clin* 1986; 26: 3-14.
6. Coster DJ, Badenoch PR. Host, microbial, and pharmacological factors affecting the outcome of suppurative keratitis. *Br J Ophthalmol* 1987; 71: 96-101.
7. Baum J, Fedukowicz HB, Jordan A. A survey of moraxella corneal ulcers in a derelict population. *Am J Ophthalmol* 1980; 90: 476-80.
8. Wilson LA. Acute bacterial infection of the eye: bacterial keratitis and endophthalmitis. *Trans Ophthalmol Soc UK* 1986; 105: 43-60.
9. Ormerod LD, Hertzmark E, Gomez DS, Stabiner RG, Schanzlin DJ, Smith RE. Epidemiology of microbial keratitis in Southern California - a multivariate analysis. *Ophthalmology* 1987; 94: 1322-33.
10. Jones DB. Early diagnosis and therapy of bacterial corneal ulcers. *Int Ophthalmol Clin* 1973; 13: 1-29.
11. Buchanan RE, Gibbons NE, eds. *Bergey's Manual of determinative bacteriology.* 8th ed. Baltimore: Williams and Wilkins, 1974.
12. Jones DB. Initial therapy of suspected microbial corneal ulcers. II. Specific

antibiotic therapy based on corneal smears. *Surv Ophthalmol* 1979; 24: 105-16.

13. Leber T. Keratomycosis aspergillina als ursache von hypopyonkeratitis. *Albrecht Von Graefe's Archiv Fur Ophthalmologie* 1879; 25: 285-301.
14. Neisser A. Ueber eine der Gonorrhoe eigentumliche Micrococcusform. *Zbl Med Wiss* 1879; 17: 457.
15. Gifford H. Pneumococcus of Fraenkel as a frequent cause of acute catarrhal conjunctivitis. *Arch Ophthalmol* 1896; 25: 314.
16. Chaudhuri PR, Godfrey B. Treatment of bacterial corneal ulcers with concentrated antibiotic eye drops. *Trans Ophthalmol Soc UK* 1982; 102: 11-4.
17. Thygeson P. Acute central (hypopyon) ulcers of the cornea. *Californ Med* 1948; 69: 18-21.
18. Rhodes AJ. Studies on the bacteriology of hypopyon ulcer. III.- A bacterial investigation of 120 cases of hypopyon ulcer *Br J Ophthalmol* 1939; 23: 627-30.
19. Ormerod LD. Causation and management of microbial keratitis in subtropical Africa. *Ophthalmology (Rochester)* 1987; 94: 1662-8.
20. al-Samarrai AR, Sunba MS. Bacterial corneal ulcers among Arabs in Kuwait. *Ophthalmic Res* 1989; 21: 278-84.
21. Maske R, Hill JC, Oliver SP. Management of bacterial corneal ulcers. *Br J Ophthalmol* 1986; 70: 199-201.
22. Lim KH. Corneal ulcers in Singapore. *Singapore Medical Journal* 1977; 18: 110-3.
23. Musch DC, Sugar A, Meyer RF. Demographic and predisposing factors in corneal ulceration. *Arch Ophthalmol* 1983; 101: 1545-48.
24. Katz NNK, Wadud SA, Azizuddin M. Corneal ulcer disease in Bangladesh. *Ann Ophthalmol* 1983; 15: 834-6.
25. Groden LR, Brinser JH. Outpatient treatment of microbial corneal ulcers. *Arch Ophthalmol* 1986; 104: 84-6.
26. Jacobs MJ, Koornhof HJ, Robins-Browne RM. Emergence of multiply resistant pneumococci. *N Engl J Med* 1978; 299: 735-40.
27. Tsutsui J. Tetanus infection of cornea-its treatment with achromycin. *Am J Ophthalmol* 1957; 43: 772-4.
28. Gingrich WD, Pinkerton ME. Anaerobic *Actinomycosis bovis* corneal ulcer. *Arch Ophthalmol* 1962; 67: 549-53.
29. Ostler HB, Okumoto M. Anaerobic streptococcal corneal ulcer. *Am J Ophthalmol* 1976; 81: 518-9.

30. Majekodunmi S, Odugbemi T. *Clostridium welchii* corneal ulcer -a case report. *Can J Ophthalmol* 1975; 10: 290-1.

31. Jones DB, Robinson NM. Anaerobic ocular infections. *Ophthalmology (Rochester)* 1977; 83: 309-31.

32. Perry LD, Brinser JH, Kolodner H. Anaerobic corneal ulcers. *Ophthalmology (Rochester)* 1982; 89: 636-42.

33. Editorial: Bacterial synergy in mixed aerobic/anaerobic infections. *Lancet* 1980; i: 405-6.

34. Dankert J, Holloway Y, Bouwer J. Bacterial synergy in mixed aerobic/anaerobic infections. *Lancet* 1980; i: 714.

35. Jones DB. Polymicrobial keratitis. *Trans Am Ophthalmol Soc* 1981; 79: 153-67.

36. Rubinfeld RS, Cohen EJ, Arentsen JJ, Laibson PR. Diphtheroids as ocular pathogens. *Am J Ophthalmol* 1989; 108: 251-54.

37. Panhalkar S, Thomas A, Alexander TA, Koshi G. Bacterial and mycotic agents of corneal ulcers in Vellore. *Ind J Ophthalmol* 1985; 33: 289-93.

38. Carmichael TR, Wolpert M, Koornhof HJ. Corneal ulceration at an urban African hospital. *Br J Ophthalmol* 1983 ;69 :920-6.

39. Upadhyay MP, Karmacharya PCD, Koirala S, Tuladhar NR, Bryan LE, Smolin G, Whitcher JP. Epidemiologic characteristics, predisposing factors, and etiologic diagnosis of corneal ulceration in Nepal. *Am J Ophthalmol* 1991; 111: 92-9.

40. Schein OD, Poggio EC. Ulcerative keratitis in contact lens wearers. Incidence and risk factors. *Cornea* 1990; 9 Suppl 1: S55-8, discussion S62-3.

41. Stehr-Green JK, Bailey TM, Visvesvara GS. The epidemiology of *Acanthamoeba* keratitis in United States. *Am J Ophthalmol* 1989; 107: 331-6.

42. Maske R, Hill JC, Bowen RM. *Acanthamoeba* keratitis. *S Afr Med J* 1989; 76: 516.

5.0 The Treatment and Results of Treatment of Corneal Ulcers

5.1 Introduction

There is no standard way of treating corneal ulcers as each type of ulcer may pose a different problem and even within a group, treatment required may differ.

In assessing treatment methods and results of treatment the ulcers were kept within distinct treatment groups.

The initial approach to many of the ulcers was similar, however, with time, availability of microbial cultures, and clinical progression a different form of management was sometimes necessary.

In designing the initial treatment protocol for suppurative keratitis the following points were considered: Jones[1,2,3] has stressed the importance of the direct smear in choosing the initial antibiotic as opposed to Baum[4,5] who has advocated a broad-spectrum antibiotic approach. Where experienced technicians are not available and antibiotic pretreatment is common, there seems no alternative to an initial broad-spectrum approach.

On analysis of two years of retrospective data from St John Eye Hospital, extracted by Dr. L.D. Ormerod for the period 1979 to 1981 (later published[6]), Gram-positive organisms were recovered in 80% of the positive cultures and there were few fungal isolates. There was a culture-negative rate of some 40%. This did, however, indicate that attention might need to be directed towards Gram-positive bacterial isolates.

It seemed reasonable to plan a regimen in which mild, moderate and severe infections were treated differently, with more attention being paid to the severe infections as resources at St John Eye Hospital were limited.

5.2 Patients and Methods

This report concerns the 161 patients (167 eyes) studied at St John Eye Hospital from the beginning of July 1982 to the end of June 1983.

Treatment methods

The patients were provisionally classified into groups on admission according to type of ulcer, severity of infection and presence of complications.

The treatment groups were:

1. Mild:

In this group the infective element was considered minimal. Treatment was with drops only, consisting of; Guttae Neosporin (Polymyxin B sulphate, Zn-bacitracin, neomycin sulphate, Wellcome) and Guttae gentamicin (Garamycin 0.3%, Scherag) given hourly, or fortified Guttae Kefzol (Cefazolin, Eli Lilly, 32g/L) and fortified Guttae gentamicin (14 g/L) given hourly. The method of preparing fortified drops is well described[7]. Chloramphenicol ointment was given at night (22^{00} hours).

2. Moderate:

The infective element in this group was considered significant and admission was justified on this criterion alone.

Treatment consisted of drops and su[illegible] of antibiotic; Guttae Kefzol and Guttae gentamicin, both fortified, [illegible] hourly and chloramphenicol ointment was given at night. In additio[illegible] id by separate injection, gentamicin 20mg were given by subconjunctival [illegible] into a bleb of lignocaine for at least three days and longer if necessary.

3. Severe:

In addition to the criteria for moderate infection, the severe group had features of severity as defined by Jones[2];

1) rapidly progressive,
2) area of suppuration greater than 6mm diameter,
3) ulceration or suppuration present in the inner 1/3rd of the cornea,
4) scleral suppuration present.

The treatment approach was the same as with moderate infections but the subconjunctival antibiotics were injected twice daily for three days and subsequently if necessary.

Although both antibiotics were initially injected subconjunctivally, when the organism was identified only the appropriate antibiotic was subsequently used. Both fortified antibiotic drops were continued for the duration of the treatment.

Intravenous therapy was also used, not routinely, but if perforation was imminent or the

suppuration was uncontrolled and the responsible organism and antibiotic sensitivity was known.

Intravenous agents used included;

Kefzol (Cefazolin) 1 gram six hourly or Penicillin G 3-4 million units 6 hourly as a bolus injection for *Streptococcus pneumoniae*, and gentamicin 80mg eight hourly as a rider of 200ml normal saline (depending on renal function) run in over 30 minutes for *Pseudomonas aeruginosa*.

4. Pressure padding plus daily subconjunctival injection.

For ulcers in which there was perforation on admission or imminent perforation (descemetocoeles) combined with a minimal or moderate infective element, both subconjunctival antibiotics were injected daily and Guttae atropine 1% instilled at the same time. The eye was kept double padded with a pressure (crepe) bandage the remainder of the time.

5. Pressure padding plus twice daily subconjunctival injections.

If the infective element was considered severe and perforation was present or imminent, the subconjunctival antibiotics were injected twice daily and Guttae atropine 1% given twice daily. The eye was kept pressure bandaged the remainder of the time.

Intravenous agents were used, when indicated, once the organism was identified.

6. Other.

Treatment consisted of a deviation from the above protocol, for example when antiviral agents were initiated from the time of admission.

In the treatment of fungal keratitis, all patients were treated with the standard antibiotic regimens above and only changed to antifungal agents once the fungus had been identified and if it was considered a significant isolate. In two cases fungi were isolated from single media, not confirmed on microscopy and clinical response to antibiotics was good. In these cases the fungal isolate was ignored.

Application for the use of unregistered antifungal agents was granted by the South African Medicines Control Council for the duration of the study if case reports were submitted,

and this latter requirement was fulfilled.

Antifungal agents used during the study included:

Miconazole: This was made available in a 2% concentration as an ointment. Intravenous miconazole (Daktarin, Cilag, 10mg/ml) was used as eye drops, for subconjunctival injection (1ml) and intravenously (600mg, 8 hourly).

Natamycin (Natacyn, Alcon, 50mg/ml) drops were used 3 hourly.

Ketoconazole (Nizoral,Janssen): An oral agent was used as adjunct therapy in a dose of 200mg twice daily where the organism isolated was sensitive.

In treating marginal corneal ulcers, with a significant infective component, the patient received the standard antibiotic regimen as applicable. Further treatment usually involved the use of steroids given as drops, subconjunctival injections and/or systemically, or various surgical procedures eg. conjunctivectomy and conjunctival flaps.

Assessing the results of treatment

Results of treatment were assessed in terms of visual acuity and complications.

Visual acuity was measured by taking the initial visual acuity (on admission) and the visual acuity when the patient was last seen (at outpatients or on discharge from hospital).

To analyze statistically the visual acuity data, visual acuity was converted to a number between 1 and 15. This meant that no light perception was assigned the number one and 6/6 was assigned the number 15. Visions between these values were:

a) Snellen chart values;
b) counting fingers (CF) from 1 to 5 metres;
c) hand movements;
d) light perception (LP);
e) no light perception (NLP).

For comparative purposes, the transition, for example, between 6/24 and 6/36 was regarded as being the same as a deterioration from CF 1m to CF 2m.

Visual acuities were also compared by plotting scattergrams for pre- and post-treatment visual acuities for the central bacterial and marginal catarrhal ulcers. Linear regression lines were then fitted.

In interpreting these scattergrams, it should be remembered that the better the treatment result the closer the regression line would be to a line parallel to the X axis and intercepting 15 on the Y axis. In other words the regression line should be as far above the line of no improvement as possible. A measure of the fit between the regression ...sation and the actual data is the coefficient of determination (R^2). This would be 1 for a perfect fit whereas 0 would indicate the complete absence of any linear relationship between initial and final vision. For the smaller groups the linear relationship was poor but the method does allow the visual results in a treatment group to be compared with another group in a graphical way and the degree of visual improvement in a group can be compared with the line of no improvement.

Complications observed in the groups were also noted and included:

1) Perforations - on admission or occurring after admission.
2) Descemetocoeles - on admission or occurring after admission.
3) Persistent epithelial defects, indolent or slow healing. In this group of patients there was no sign of ulcer healing in the first five days and/or the ulcer had an indolent appearance clinically (well demarcated edges with very slow healing).
4) Uncontrolled infection. This was an infection which progressed, failing to respond to the antibiotic regime used.
5) Recurrence of infection. This was a recurrence of abscess or hypopyon after an initial positive response to treatment.

5.3 Management and Results

5.3.1 Central Bacterial Ulcers

It can be seen (Table 5.1) that more than half of the central bacterial ulcers (56%) were treated using the moderate regimen. Eighteen percent were judged to warrant the severe regimen.

Medical Treatment of Central Bacterial Corneal Ulcers		
Treatment Regimen	Number of Eyes	Percentage
Mild (drops only)	4	4
Moderate	51	56
Severe	16	18
P.P. and subconj. daily	9	10
P.P. and subconj. twice daily	8	9
Other	3	3
TOTAL	91	100

Note: P.P. is pressure pad.
subconj. is subconjunctival injection

Table 5.1

Using these treatment regimes, 45 of the 91 eyes (50%) healed uneventfully while 33 eyes (36%) showed single complications and 13 eyes (14%) showed multiple complications.

There were 24 perforations, 17 of which were already present on admission, and 13 descemetoceles only one of which formed after admission (and did not perforate). Slow, indolent healing was seen in 12 eyes and there were 11 eyes in which infection was uncontrolled by the treatment given. There was recurrence of infection after an initial positive response in one case.

In the following text the Class of bacterial isolate (see Chapter 4) will be given in brackets.

5.3.1.1 Results of Treatment of the Mild Group (Four Eyes)

The average delay before presentation was five days. The average number of inpatient treatment days was nine days. There were no complications and no surgery was performed.

5.3.1.2 Results of Treatment of the Moderate Group (51 Eyes)

The average delay before presentation was seven days. The average number of inpatient days was ten days.

Complications included uncontrolled infection in one case, slow or indolent healing in ten cases and multiple complications in three patients.

Uncontrolled infection was seen in case number 120 (Fig. 5.1) and *S. pneumoniae* (Class 1) and *Propionibacterium acnes* (doubtful significance) were isolated. Climatic droplet keratopathy (CDK Grade 2) was a local predisposing factor and the patient had moderate to severe malnutrition as previously defined (see Chapter 3). There was persistent abscess formation which did not clear on the antibiotics given and the patient eventually refused hospital treatment and left after 13 days.



Figure 5.1

There were ten eyes from nine patients showing indolent or slow healing persistent epithelial defects:

Case 26: A soft contact lens was used after six days and healing occurred subsequently. There was no growth obtained and there were no predisposing factors.

Case 41: The patient had fallen into a hole and sustained a fractured femur and the corneal ulcer subsequently. On presentation he had a plaster of paris cast and an ulcerated hip with exposure of the greater trochanter. From the corneal ulcer (Fig. 5.2) *P. aeruginosa* (Class 1) was cultured but this organism was not isolated from the hip culture. This was an only eye, a socket being present on the other side. He was severely malnourished and was treated with intramuscular gentamicin (80 mg tds) for ten days because of the hip. The ulcer healed with an eventual vision of 6/60 (Fig. 5.3).



Figure 5.2



Figure 5.3

Case 49: A soft contact lens was used after seven days and healing subsequently occurred. *S. pneumoniae* (Class 1) was isolated and predisposing factors included CDK (Grade 3) and mild malnutrition.

Case 75: This patient was pressure padded after five days as there was no sign of healing but the epithelial defect remained and never healed. There was no growth on cultures and predisposing factors included corneal scarring and mild malnutrition.

Case 80: Slow healing occurred and *Staphylococcus epidermidis* (Class 4) was isolated. Predisposing factors included CDK (Grade 3), mild malnutrition and three factors for alcohol abuse.

Cases 100 and 101:

Indolent healing was seen in this child with bilateral ulceration. The ulcers were infero-nasal and typical of xerophthalmia (Fig. 5.4 to Fig. 5.7). There was a history of measles the previous week and the child had a weight for age under the 80th percentile. From both eyes, *Streptococcus pyogenes* (Class 1) and *S. epidermidis* (Class 1) were cultured.



Figure 5.4



Figure 5.5



Figure 5.6

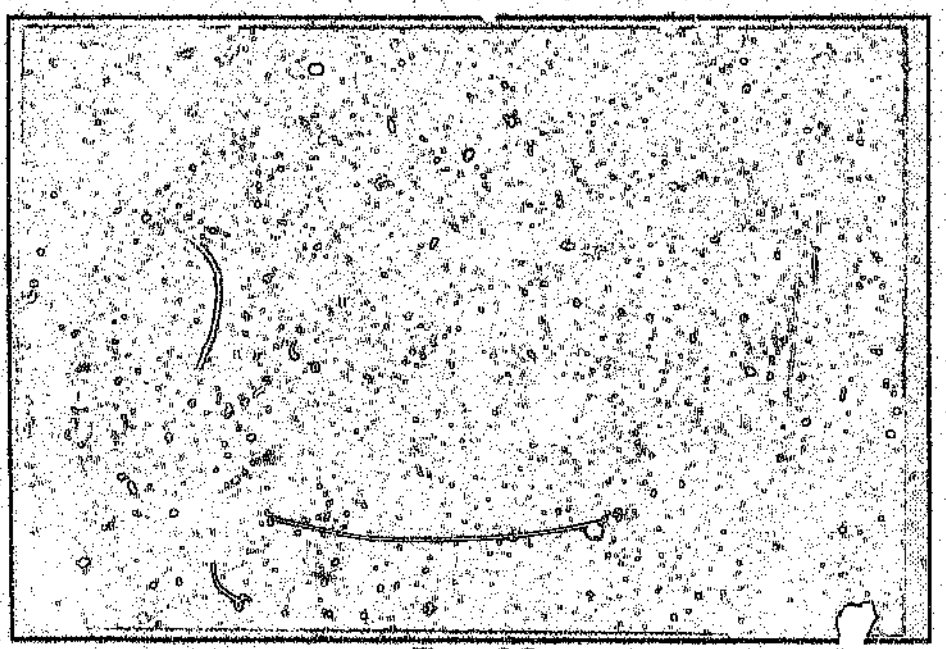

Figure 5.7

Case 105: In this case which showed indolent healing, there was a history of previous eye surgery and corneal scarring in the area of indolent ulceration. *Moraxella lacunata* (Class 1), *S. epidermidis* (Class 1) and *Corynebacterium spp.* (Class 4) were isolated.

Case 140: CDK (Grade 3) caused a persistent epithelial defect and a soft contact lens was tried. This caused an hypopyon to develop and the contact lens

was removed. The patient had moderate malnutrition and *Corynebacterium spp.* (Class 3) was isolated. The patient was discharged after 16 days but the epithelial defect remained and the patient was readmitted two weeks later for possible lamellar keratoplasty. The area healed on the second admission and surgery was avoided.

Case 146: In a patient with chronic myeloid leukaemia, CDK (Grade 3) and two factors for alcohol abuse, the ulcer was paracentral (Fig. 5.8) and the area was still staining on discharge seven days after admission (Fig. 5.9). *Corynebacterium spp.* (Class 1) was isolated and the patient subsequently defaulted. Clinically, he was wasted with hepatosplenomegaly.



Figure 5.8

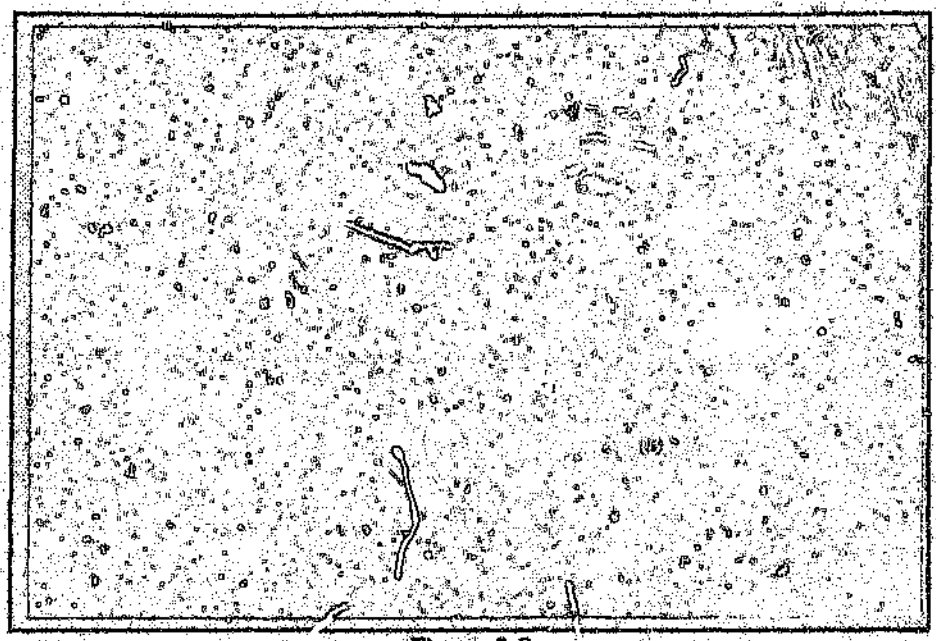

Figure 5.9

There were three patients showing multiple complications:

Case 60: This patient presented with a leaking descemetocoele and shallow anterior chamber which flattened after admission. It did not reform on pressure-padding which was started two days after admission. The ulcer was chronic with a delay before presentation of 28 days and the descemetocoele measured 8mm by 9 mm. The eye was not considered salvageable and a purse-string conjunctival flap was performed four days after admission. The patient was seen twice at outpatients (OPD) and the flap retracted and there was iris exposed in the superior part of the cornea. There were no isolates obtained and predisposing factors included CDK (Grade 3) and alcohol abuse (three factors).

Case 72: In this patient response to treatment was slow with persistent corneal abscess and nine days of subconjunctival antibiotics were given. The ulcer was paracentral and not large, measuring 1,1mm by 1,5mm on presentation but the surrounding abscess extended to half corneal thickness (Fig. 5.10). During the treatment period the cornea thinned to form a descemetocoele but did not perforate. *S. pneumoniae* (Class 1) was isolated and predisposing factors included CDK (Grade 3) and mild malnutrition. The ulcer healed with a paracentral scar (Fig. 5.11) and the patient subsequently defaulted. Vision in the other eye was 6/60 due to Grade 3 CDK.



Figure 5.10



Figure 5.11

Case 111: Following a severe acid burn during an assault this patient was treated and had lid surgery to protect the cornea. He presented one month later with a corneal ulcer involving the entire cornea, and a full hypopyon and proceeded to perforate four days later. The entire central cornea dissolved with vitreous prolapse and the eye was eviscerated eight days after admission. *P. aeruginosa* (Class 1) was isolated and the acid burn, lid contracture and corneal erosion were the predisposing factors in this case.

Note:
In this group of 51 eyes, the treatment used was largely successful with 37 eyes (73%) healing uneventfully.

Of the complications, the inability to control infection in cases 72 and 120 was a source for concern. In both cases the organism isolated was *S. pneumoniae*. In case 111 the pseudomonas infection was so severe at the time of presentation that success was not considered attainable.

CDK and malnutrition were common predisposing factors in the eyes showing complications and this was particularly true of the indolent and slow-healing ulcers. In these patients soft contact lenses were used successfully in two cases and caused hypopyon formation in one. It was not possible to show a statistical difference (Chi square test with Yates correction factor) in malnutrition between the adult patients who healed without complication as opposed to those who showed one or more complication. However, of the 41 adult patients in this group six of 30 (20%) that healed well had malnutrition (mild to severe) whereas six of 11 patients (55%) with complications had a degree of malnutrition. It might also be supposed that the age of the patient might well play a role in healing but the mean age of the adults that healed well was 50 years and those that showed complications was 54 years and there was no statistical difference using the Student *t* test.

Visual acuity was measured in 43 patients in this group of 50 patients (51 eyes). One patient refused hospital treatment and no discharge vision was available. This patient was excluded as was a deaf schizophrenic patient in whom visual acuity could not be measured. In addition there were five children (six eyes) in whom visual acuity could not be measured. Of the entire group of 43 patients, more than half (55%) eventually

defaulted from follow-up. Twelve of the group were not seen post-discharge and of the remainder, the mean follow-up period was 32 days.

The average pretreatment visual acuity (admission) was 4.3 and the average final vision was 7.8. The difference was significant with p less than 0,0001 using the Student *t* test (paired analysis).

For the ulcers which healed without complication (31 eyes), the average pretreatment visual acuity was 5.1 and the average final vision was 8.1. The difference was significant with p less than 0,0001 (paired analysis with Student *t* test).

In the 12 eyes with complications, the average pretreatment visual acuity was 4 and final was 6.8. The difference is significant with p less than 0,01 (paired analysis with Student *t* test).

There was no significant difference between the average pretreatment vision in the group with no complications versus the group with complications. There was also no significant difference between the average final vision in these two groups. For the last two calculations a two-sample Student *t* test was used.

Using scattergrams to plot the initial and final visual acuities, it can be seen that only four eyes showed visual deterioration after treatment (Fig. 5.12). The linear regression lines for the eyes which healed well (Fig. 5.13) and all patients were similar and the line for complicated cases (Fig 5.14) was steeper showing poorer final visions in this group.

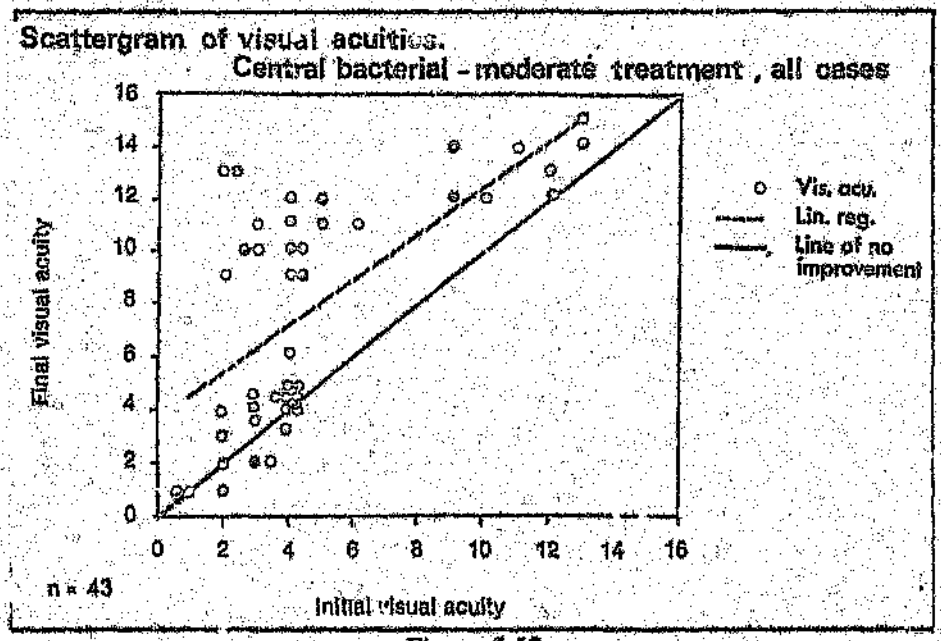

Figure 5.12

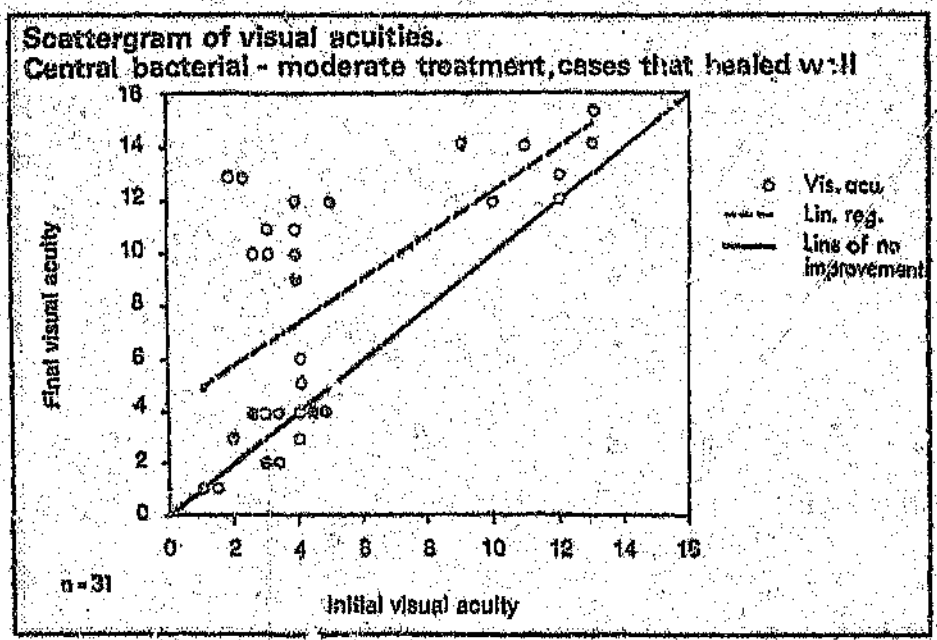

Figure 5.13

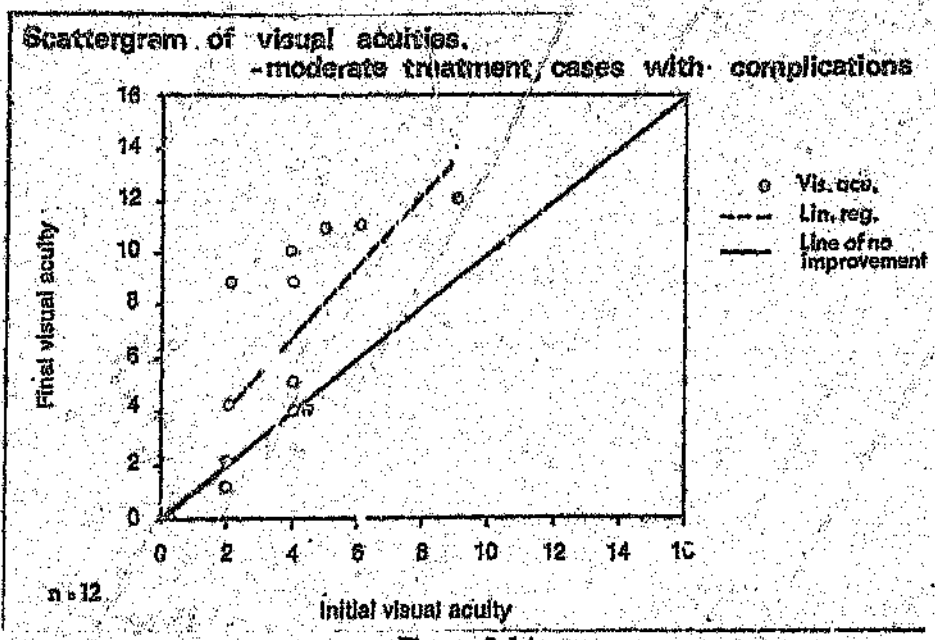

Figure 5.14

The coefficients of determination (R^2) for all cases was 0,43, for cases that healed well 0,42, and for complicated cases was 0,49.

5.3.1.3 Results of Treatment of the Severe Group (16 Eyes)

In this group all 16 eyes were unilateral. The average delay before presentation was eight days and the average duration of hospital treatment (patient days) was 18 days.

Complications occurred in 13 of the 16 eyes. The three cases that healed without complication were;

Case 6: A partial thickness corneal laceration secondarily infected by *S. pneumoniae* (Class 1) presented as a corneal abscess 4 by 5 mm extending into the inner third of the cornea. The patient was 33 years old and there were no predisposing factors other than trauma. Response to treatment was good and final vision 6/18.

Case 12: An assault one year previously had resulted in no light perception due to optic atrophy and recent trauma (falling on steel) had caused a lid laceration which had healed onto the globe as a symblepharon. Due to an exposure effect a 1,9 by 2,3 mm full thickness abscess had developed (Fig. 5.15) and *M. lacunata* (Class 3) was isolated. The patient was 22 years old and there were no other predisposing factors. A symblepharon release and secondary lid repair was done 20 days after admission and a glass shell was inserted. The ulcer healed without complication.

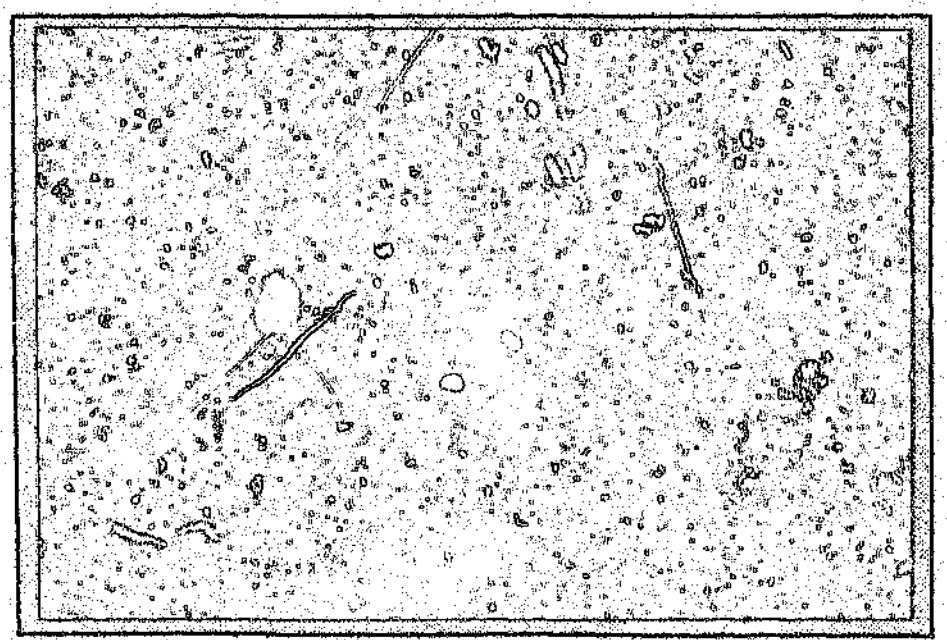

Figure 5.15

Case 94: A foreign body from a stove seven days previously gave rise to a 7,4 by 5 mm ulcer extending into the inner third of the cornea (Fig 5.16). *P. aeruginosa* (Class 1) was isolated and this 19 year old female had moderate malnutrition. The infection healed well on treatment (Fig. 5.17).



Figure 5.16



Figure 5.17

There were two patients who presented with descemetocoeles and did not perforate:

Case 8: A patient treated for hypopyon ulcer two months previously presented with a 1mm descemetocoele and fresh abscess formation and hypopyon (Fig. 2.3 on page 12 in Chapter 2). There was no isolate obtained and apart from the corneal scarring from the previous ulcer there were no predisposing factors. Because of the recurrence, a lamellar keratoplasty was done 14 days after admission. When last seen, a month after discharge, there was early vascularisation of the graft and fibrosis at the graft interface reducing vision to hand movements.

Case 51: This patient presented with a 1mm descemetocoele and a surrounding abscess which was full-thickness (Fig. 5.18). *M. lacunata* (Class 3) was isolated (Fig. 5.19) and he had two factors for alcohol abuse. Healing was assisted by the use of a soft contact lens after 15 days. The cornea thickened well under the contact lens which fell out after six weeks.



Figure 5.18



Figure 5.19

Perforations after admission occurred in six eyes;

Case 10: After being assaulted with an open hand, this patient treated her eye with a combination of Eyegene and dissolved sugar. She presented with a 4 by 6.2mm ulcer with abscess extending full-thickness through the cornea (Fig. 5.20). *S. pneumoniae* (Class 1) was isolated in abundance (Fig. 5.21) and apart from the trauma there were no other predisposing factors. The infection was not controlled and it progressed to a large descemetocoele then perforated three days after admission. Penetrating keratoplasty was performed three days after perforation and the patient was not seen after discharge.



Figure 5.20



Figure 5.21

Case 61: This patient presented with an 8 by 8mm descemetocoele and full-thickness surrounding abscess (Fig. 5.22). *S. pneumoniae* (Class 1) was isolated and the patient had moderate malnutrition and three factors for alcohol abuse. The infection was not controlled and perforation occurred three days after admission. Penetrating keratoplasty was performed seven days later and the patient was discharged with a deep anterior chamber, a clear graft and was not seen subsequently.



Figure 5.22

Case 63: Following a motor vehicle injury, this 20 year old was being treated in intensive care for flail chest and was on a ventilator with a tracheostomy (Fig. 5.23). Ten days later he had a corneal ulcer involving virtually the entire corneal surface (Fig. 5.24). *P. aeruginosa* (Class 1) was isolated and corneal exposure was a predisposing factor. Although the organism was sensitive to gentamicin, it was suggested that Amikacin would be more efficacious. After two days Amikacin (Amikin, Bristol-Myers Squibb) was used as fortified drops, sub-conjunctival injection and intravenously. Infection was not controlled and a superior paralimbal perforation occurred on the third day of treatment. A purse-string conjunctival flap was performed six days later as a bedside procedure.

Following perforation, the eye became quiet and the anterior chamber reformed. This eye was saved for penetrating keratoplasty later.



Figure 5.23



Figure 5.24

Case 79: The patient presented with a 3 by 4,4mm hypopyon ulcer and suppuration extending into the middle third of the cornea. *S. pneumoniae* (Class 1) was isolated and CDK (Grade 3) and mild malnutrition were predisposing factors. In addition the patient had three factors for alcohol abuse. After an initial improvement, the infection continued and a descemetocoele formed after seven days and perforation two days later. A penetrating keratoplasty was performed five days later. The patient was last seen two weeks after discharge with a clear graft but some peripheral anterior synechiae formation.

Case 116: This patient with Grade 3 CDK presented with a 2 by 1,3mm descemetocoele in a 2 by 4,5mm ulcer and full thickness abscess (Fig. 5.25). There were two factors for alcohol abuse present and *S. pneumoniae* (Class 1) was isolated. The infection was poorly controlled and intravenous Penicillin G, 3 million units every 4 hours was given from 2 days after admission for 14 days. Perforation occurred six days after admission and the anterior chamber reformed on pressure padding. The fortified antibiotic drops were stopped during pressure padding and there was a flare-up in the abscess on the ninth day after admission. This responded to the use of fortified Kefzol drops. The ulcer then healed, the cornea thickened and the patient was discharged after 22 days of inpatient treatment (Fig. 5.26). He was not seen after discharge.



Figure 5.25



Figure 5.26

Case 130: This lady had suffered from systemic lupus erythematosis for 14 years and was receiving 30mg of prednisone per day. She was admitted for sepsis of the foot, thought to be secondary to vasculitis. She then developed pain in the right eye and presented with a 2,5 by 2,5mm central ulcer with a 1mm central descemetocoele. *P. aeruginosa* (Class 1) was cultured from the cornea. This organism was not recovered from the cultures taken from the foot, where *S.aureus*, *P. mirabilis* and group B Streptococcus were isolated. The patient had moderate malnutrition and severe keratitis sicca as further predisposing factors. On treatment the abscess enlarged slowly and perforation occurred 11 days after treatment was begun. After perforation the abscess resolved and the anterior chamber reformed on pressure padding . The patient was followed up for a month following discharge and had a dense central corneal scar which was vascularised resulting in hand movement vision.

In five cases the eye was lost due to uncontrolled infection and/or the severity of the infection on presentation:

Case 16: This patient gave a one month history of problems with the right eye and presented with a circular 4,8mm area of perforation and iris prolapse with surrounding corneal melt (Fig. 5.27). *S. pneumoniae* (Class 1) was isolated and predisposing factors included tuberculosis, moderate malnutrition and two factors for alcohol abuse. Because of the poor prognosis an enucleation was done 13 days after admission.



Figure 5.27

Case 59: In this case of uncontrolled infection, there was a large slough-covered descemetocoele on presentation and no light perception (Fig. 5.28). *S. pneumoniae* (Class 1) was isolated and predisposing factors included corneal scarring and moderate malnutrition. The eye was evisserated six days after admission and the intraocular contents showed the appearances of acute endophthalmitis on histology.



Figure 5.28

Case 134: An ulcer 8 by 5,5mm with associated infiltrations into the stroma extended into the middle third of the cornea (Fig. 5.29). There was a history of foreign body but no other predisposing factors were noted. *P. aeruginosa* (Class 1) was isolated and the infection progressed relentlessly (Fig. 5.30). Although perforation did not occur there was eventual loss of light perception and an evisceration was done 11 days after admission.

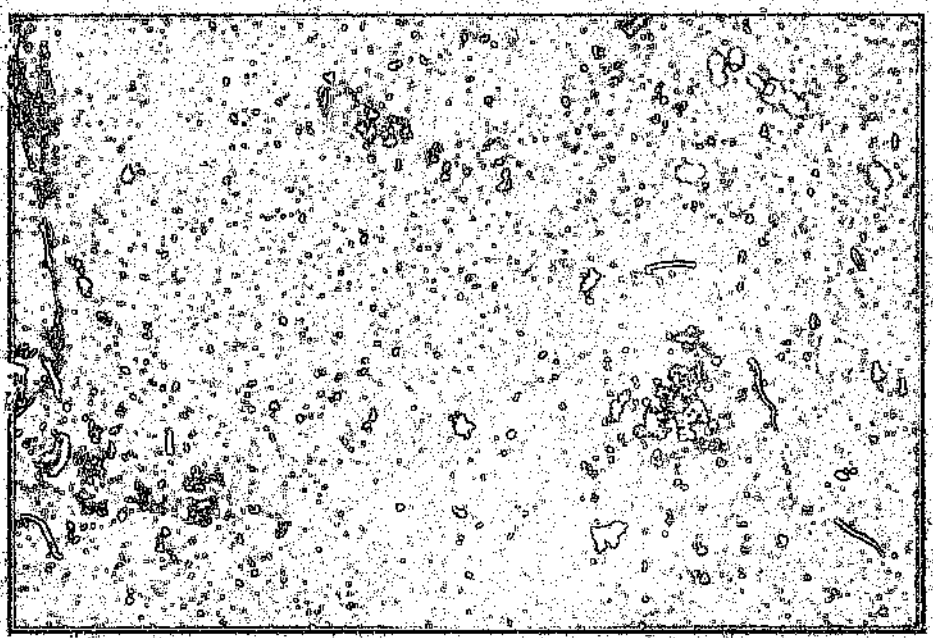

Figure 5.29



Figure 5.30

Case 110: Following a wire injury causing laceration of the cornea, this patient presented with a 2 by 2,9mm ulcer and full thickness abscess adjacent to the laceration (Fig. 5.31). Only *S. epidermidis* (Class 4) and *Corynebacterium spp.* (Class 4) were cultured. There were no other predisposing factors. Infection was uncontrolled and an evisceration was performed seven days after admission.



Figure 5.31

Case 165: This patient presented two weeks after intraocular lens surgery with a 5,9 by 5,3mm ulcer with full thickness abscess associated with the wound (Fig. 5.32). *S. pneumoniae* (Class 1) was isolated and the patient had moderate malnutrition. The ulcer progressed unabated in spite of the use of intravenous Penicillin G 3 million units 4 hourly and eventually Penicillin powder was poured on to the cornea. The eye eventually quietened (Fig. 5.33) and a penetrating graft was done eight days after admission. Postoperative ultrasound showed vitreous haemorrhage and retinal detachment and the eye subsequently became phthisical.



Figure 5.32



Figure 5.33

Note:

The severity of infections in this group of patients was such that treatment objectives changed from visual outcome to saving the eye. Six of the patients were not seen after discharge and the average follow-up for the remaining ten was 27 days.

The average visual acuity on admission for the 16 eyes was 2,7 and the average final vision was 3,8. There was no statistical difference between the pre-treatment and post-treatment visual acuities (paired analysis using Student *t* test).

The average initial and final visions were significantly worse in the severe ulcers than the moderate ulcers (p less than 0,05 in both cases using a two sample Student *t* test).

Plotting the visual acuities as a scattergram (Fig. 5.34), it can be seen that the linear regression line has moved closer to the line of no improvement with visions clustered in the lower left corner. The coefficient of determination (R^2) decreased to 0,33 showing a decline in the association between initial and final visions.

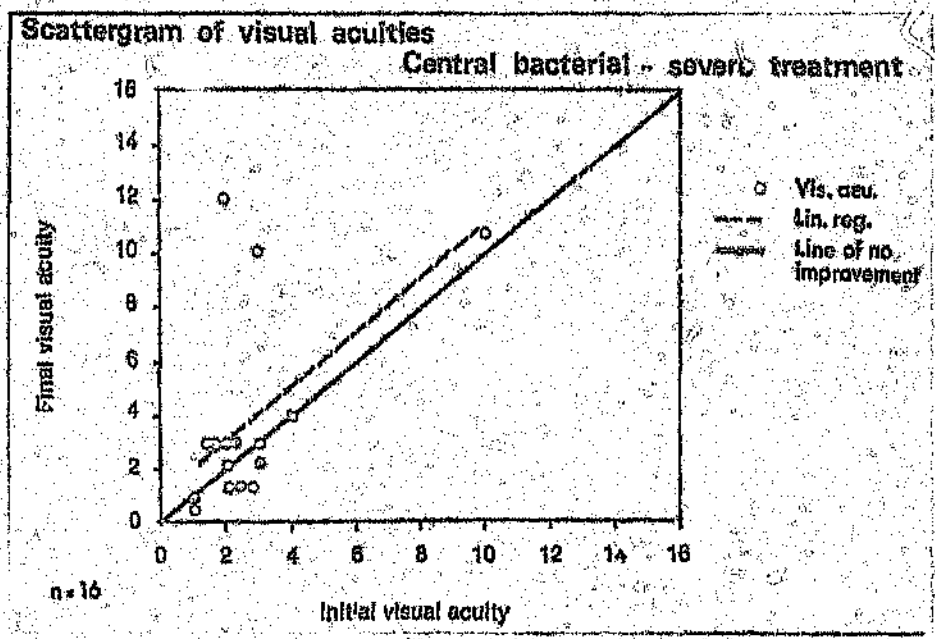

Figure 5.34

Of the 16 cases, *S. pneumoniae* (Class 1) was isolated in eight cases and *P. aeruginosa* (Class 1) in four cases (Table 5.2).

Summary of Treatment Results: Severe Cases			
Case Number	Organism Isolated	Surgery	Result
No complications:			
6	*S. pneumoniae* (1)		6/18
12	*M. lacunata* (3)	Lid surgery	NLP
94	*P. aeruginosa* (1)		6/36
Descemetoceles:			
8	No growth	L.K.	HM's
51	*M. lacunata* (3)		6/24
Perforations:			
10	*S. pneumoniae* (1)	P.K.	HM's
61	*S. pneumoniae* (1)	P.K.	HM's
63	*P. aeruginosa* (1)	Conj. flap	HM's
79	*S. pneumoniae* (1)	P.K.	LP
116	*S. pneumoniae* (1)		CF 1m
130	*P. aeruginosa* (1)		HM's
Uncontrolled infections:			
16	*S. pneumoniae* (1)	Enucleation	
59	*S. pneumoniae* (1)	Evisceration	
134	*P. aeruginosa* (1)	Evisceration	
110	*S. epidermidis* (4)	Evisceration	
	Corynebact. spp. (4)		
165	*S. pneumoniae* (1)	P.K., phthisical	

Note: Class of isolate is given in brackets.
P.K. is penetrating keratoplasty,
L.K. is lamellar keratoplasty,
HM's is hand movement vision,
NLP is no light perception,
Conj. is conjunctiva,
CF is counting fingers.

Table 5.2

Comment

At this very severe level of infection the results of treatment were not good. The antibiotics seemed not to reach the organisms and the infection ran it's course unabated. The results of keratoplasty were also disappointing with the battle often being lost with obliteration of the drainage angle by peripheral anterior synechiae formation.

5.3.1.4 Results of Treatment of the Group that was Pressure Padded and Received Daily Subconjunctival Injections (9 Eyes)

The average delay before presentation was 15 days. The mean period of hospital treatment for the group was 20 days. In terms of definition all cases were complicated.

In three cases the patient presented with a descemetocoele or sealed perforation with the anterior chamber formed:

Case 7: A five-year old with a history of measles presented with a 4 by 4mm slough covered area of perforation with the anterior chamber deep above. *Streptococcus bovis* group ii was cultured from the conjunctiva and there were no corneal isolates. The child had mild malnutrition. There was no significant infective element and the eye remained quiet. A partial conjunctival flap was done after 12 days to cover the thinned area of cornea.

Case 78: A nine-year old with a history of previous eye infection at age three years presented with a scarred, vascularised cornea and a 2 by 3mm descemetocoele below the centre of the cornea (Fig. 5.35). There were no other predisposing factors and no corneal isolates. the infective element cleared and the ulcer healed on the treatment given (Fig. 5.36).

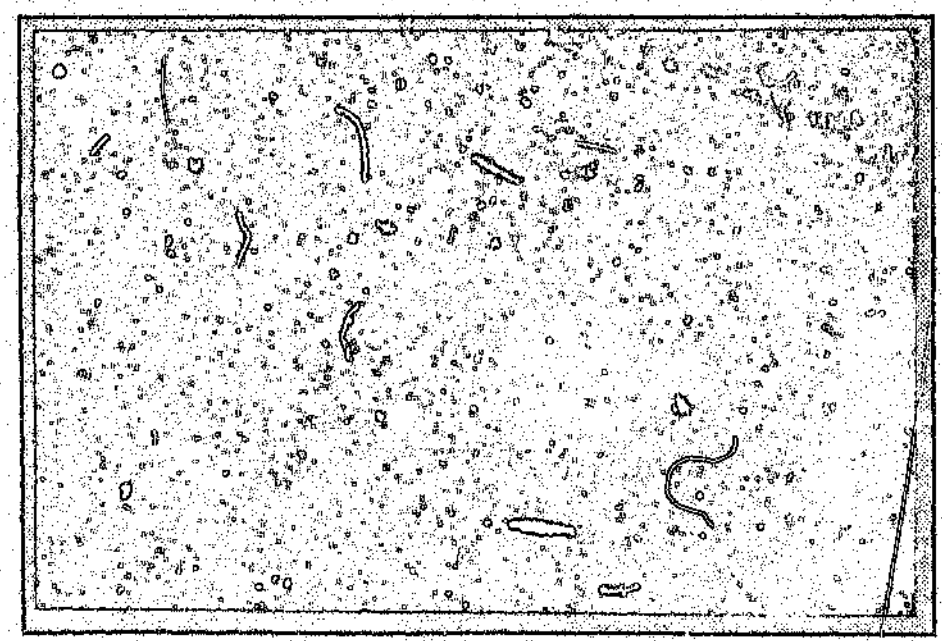

Figure 5.35



Figure 5.36

Case 150: Following assault with a bottle five days previously, the patient presented with a 7,8 by 5,1mm leaking descemetocoele (Fig. 5.37). The anterior chamber was shallow above on admission and remained shallow on pressure padding. There were no corneal isolates and the patient had mild malnutrition. A penetrating corneal graft was performed 12 days after admission (Fig. 5.38). The graft was clear ten weeks postoperatively with a corrected vision of 6/36.



Figure 5.37



Figure 5.38

In the other six eyes the anterior chamber was flat on admission:

Case 5: The cornea was absent in the upper half and very thin in the lower half with iris prolapse above. *Corynebacterium spp.* (Class 1) and *P. aeruginosa* (Class 5) were cultured and the patient had mild malnutrition. A tectonic corneal graft was performed 12 days after admission and the eye subsequently became phthisical.

Case 15: The ulcer was a 5,8 by 5,6mm slough covered leaking descemetocoele (Fig. 5.39). There were no corneal isolates and the patient suffered from tuberculosis and had three factors for alcohol abuse. The anterior chamber did not reform on pressure padding and a penetrating corneal graft was performed six days after admission. When seen at OPD five weeks after the surgery, the graft was vascularising, the intraocular pressure slightly elevated at 24mm Hg and the anterior chamber shallow but formed.



Figure 5.39

Case 38: There was a small central perforation of 1mm in an area of Grade 3 CDK. There were no corneal isolates and no other predisposing factors. A penetrating corneal graft was performed three days after admission. When last seen at OPD three months after the surgery, he had an opaque, vascularised graft, an intraocular pressure over 40mm Hg and a shallow anterior chamber.

Case 83: The ulcerated area of CDK was 10 by 4mm but the area of perforation was small and peripheral. The anterior chamber reformed on pressure padding and healing was uneventful. No organisms were cultured and there were no other predisposing factors.

Case 115: This seven-month-old child was referred from a peripheral hospital where he was being treated for pneumonia. He had a 6 by 6mm perforated ulcer and *P. aeruginosa* (Class 1) was isolated. The possibility of malnutrition and vitamin A deficiency might be considered but no measurements were done and the other eye appeared normal. The eye became quiet on treatment but no surgery was attempted and the eye became phthisical.

Case 155: This 60 year old lady had no light perception in either eye the cause of which was not fully apparent. There was a 6,1 by 4,2mm ulcer with a flat anterior chamber, cataract, rubeosis and bullous keratopathy. *Peptococcus prevotii* was isolated and there were no other predisposing factors. The ulcer healed slowly, the anterior chamber remained flat and no surgery was attempted.

5.3.1.5 Results of Treatment of the Group that was Pressure Padded and Received Twice Daily Subconjunctival Injections (Eight Eyes)

The average delay before presentation was 11 days. The mean period of hospital treatment for the group was 18 days.

All the cases were complicated bu in three cases the anterior chamber was formed on admission;

Case 27: In a patient with Grade 3 CDK, the anteri.. chamber was shallow and the ulcerated area was 3,7 by 2,4mm. *S. pneumoniae* (Class 5) was isolated and the patient was severely malnourished. A partial conjunctival flap was performed six days after admission and the eye became quiet but the anterior chamber remained very shallow.

Case 65: The patient was found to have chronic lymphocytic leukaemia and had massive hepatosplenomegaly, ascites, generalized lymphadenopathy and pneumonia. He had Grade 3 CDK, moderate malnutrition, two factors for alcohol abuse and presented with a 2,8 by 2mm descemetocoele (Fig. 5.40). *Moraxella species* (Class 4) was isolated. Response to treatment was excellent and the cornea thickened with pressure padding (Fig. 5.41).



Figure 5.40



Figure 5.41

Case 123: A patient with Grade 3 CDK presented with a 5,4 by 4mm descemetocoele (Fig. 5.42) and *S. pneumoniae* (Class 3) was isolated. There were no other predisposing factors and the cornea thickened on pressure padding.



Figure 5.42

In the remaining three cases, the anterior chamber was flat on admission;

Case 32: There was a three day history of pain in the eye but no obvious predisposing factors were found. The ulcer was central and 3,6 by 2,6mm in size. There were no significant isolates and a penetrating corneal graft was done three days after admission. The 9mm graft was clear on discharge and the patient was not seen subsequently.

Case 35: The paracentral ulcer was 3 by 2mm with associated abscess. There were no predisposing factors and no isolates obtained. The anterior chamber reformed on pressure padding and the cornea thickened.

Case 45: A 2,3mm round paracentral ulcer (Fig. 5.43) occurred in a recently diagnosed diabetic patient with rheumatoid arthritis and keratitis sicca who also gave a vague history of trauma to the eye. Isolates included *Staphylococcus aureus* (Class 1) and *S. pneumoniae* (Class 2). The anterior chamber reformed on pressure padding and a partial conjunctival flap was performed to cover the thinned corneal area five days after admission. An abscess developed in the area of the ulcer postoperatively and this responded to subconjunctival Kefzol and fortified Kefzol drops. Healing was subsequently good and the conjunctival flap remained in place (Fig. 5.44).



Figure 5.43



Figure 5.44

Case 87: This patient had been treated previously for pain related to nodular CDK and presented with a 6,7 by 8mm ulcer with a leaking descemetocoele. *S. pneumoniae* (Class 1) was isolated and the patient was moderately malnourished. The anterior chamber remained flat and a penetrating corneal graft was performed four days after admission. The eye seemed to be going phthisical on discharge but the patient defaulted subsequently.

Case 99: A paracentral ulcer 2,9 by 2,4mm occurred in an area of Grade 3 CDK and the area of perforation was small (Fig. 5.45). There were no other predisposing factors and no significant isolates were obtained. The anterior chamber reformed on pressure padding and the cornea thickened (Fig. 5.46)



Figure 5.45



Figure 5.46

Note:

In many of the pressure padded cases, no bacterial growth was obtained (Table 5.3).

Summary of Treatment Results: Pressure Padded Cases			
Case Number	Organism Isolated	Surgery	Result
Daily subconj. injection:			
5	*Corynebact. spp.* (1), *P. aeruginosa*	Corneal graft	Phthisical
135	*Peptococcus prevoti*	Nil	NLP
7	No growth	Conj. flap	-
15	No growth	Corneal graft	LP
38	No growth	Corneal graft	Rejected
78	No growth	Nil	CF 1m
83	No growth	Nil	6/18
115	*P. aeruginosa* (1)	Nil	Eye lost
150	No growth	Corneal graft	6/36
Twice daily subconj. injections:			
27	*S. pneumoniae* (5)	Conj. flap	HM's
32	No growth	Corneal graft	CF 1m
35	No growth	Nil	6/18
45	*S. aureus* (1), *S. pneumoniae* (2)	Conj. flap	HM's
65	*Moraxella spp.* (4)	Nil	CF 1m
87	*S. pneumoniae* (1)	Corneal graft	LP
99	No growth	Nil	CF 1m
123	*S. pneumoniae* (3)	Nil	6/36

Note: NLP is no light perception,
LP is light perception,
- is a child, no vision recorded,
Conj. is conjunctival.

Table 5.3

The number of positive cultures and the treatment group were related in an obvious way ie. the severe infections had more positive cultures. In fact 32 of the 51 eyes (63%) in the moderate group had significant positive cultures (Classes 1-3) while 14 of 16 eyes (88%) in the severe group had positive cultures. In the pressure padded groups six of 17 eyes (35%) had positive cultures. There were several Class 5 pathogens in the pressure padded cases pointing to possible responsible organisms.

Visual acuities in the pressure padded groups were not good and overall, the two groups had an initial average vision of 3,4 and a post-treatment vision of 5,0 (data were available in 15 of the 17 eyes).

The scattergram (Fig. 5.47) shows a clustering of visions to the lower left with nine of the 15 eyes showing unchanged or worse vision following treatment. In this group the correlation coefficient (R^2) had dropped to 0,14.

Scattergram of visual acuities. Pressure padded cases

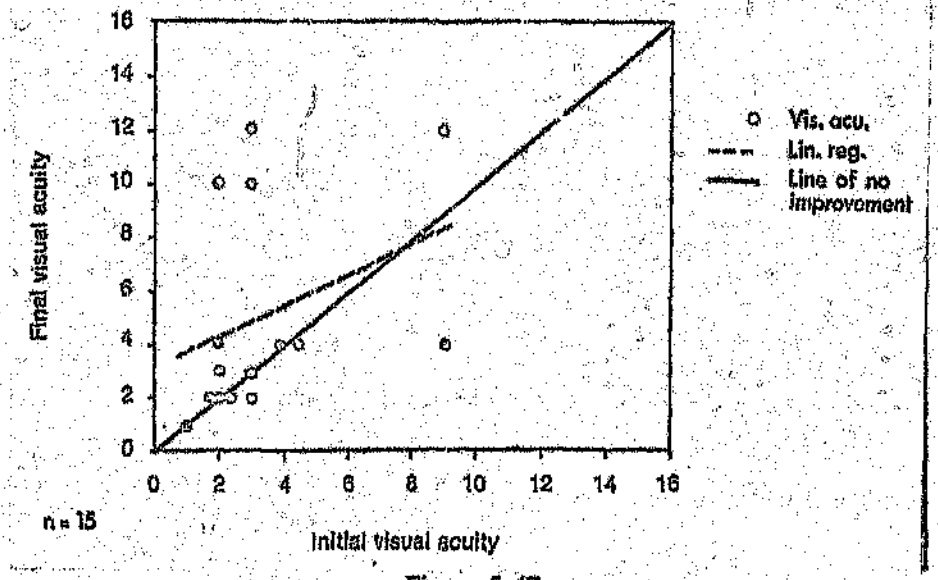

Figure 5.47

5.3.1.6 Treatment Methods in the "Other" Group (Three Eyes)

There were three eyes from two patients in whom treatment methods were different;

Case 22: A 15 month old child who had a rash, possibly measles at the time the eye became red and presented with a total corneal perforation and pus coming from the eye. There was surrounding orbital cellulitis. *S. aureus* (Class 5) was cultured from the pus and the eye was eviscerated the following day. The patient received ampicillin and cloxacillin intravenously and Polysporin ointment (Polymyxin B sulphate, Zn-bacitracin, Wellcome) to the socket and the cellulitis settled.

Cases 113 and 114:

A 7-month-old with kwashiorkor (Fig. 5.48) had a large perforation of the left cornea (Fig. 5.49) and a 2 by 1mm inferonasal ulcer of the right cornea (Fig. 5.50) typical of keratomalacia. *S. epidermidis* (Class 1) was isolated from both eyes. Vitamin A in a dose of 100 000 IU/day and chloramphenicol ointment for the eyes was given but the child died two days later.



Figure 5.48

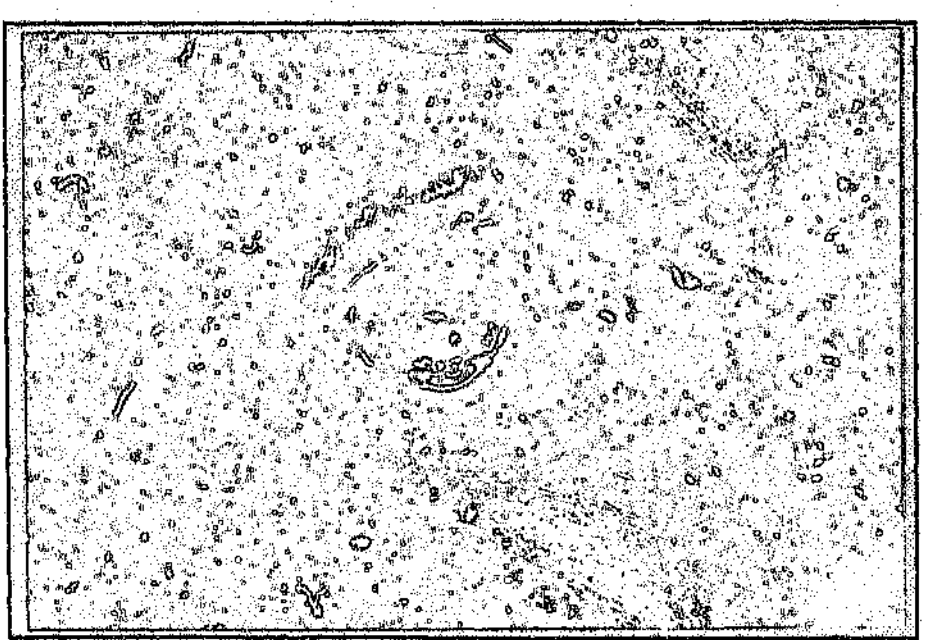

Figure 5.49



Figure 5.50

5.3.2 Central Fungal Ulcers

These cases were uncommonly seen and particular attention was paid to the response to antifungal medications.

During the one year study at St John there were six cases;

Case 1: A 60 year-old female presented with a three week history of spontaneous onset of pain in the left eye. There was a corneal ulcer and abscess involving the entire corneal surface and a 4,4mm hypopyon (Fig. 5.51). She was a maturity-onset diabetic but there were no other predisposing factors. *Aspergillus flavus* was isolated, sensitive to miconazole (MIC 0,18 micrograms/ml) and ketoconazole and natamycin (MIC's 3,1 micrograms/ml for both). Initial treatment consisted of miconazole drops hourly (the intravenous Daktarin in a 10mg/ml strength was used) and the same medication was injected subconjunctivally twice daily for five days then daily for eight days. The oral antifungal, ketoconazole, was given in a dose of 200mg twice daily for 14 days. Although antifungal therapy was started within 24 hours of admission, the cornea thinned (Fig. 5.52)

and intravenous miconazole was added in a dose of 600mg eight hourly and continued for three days. Corneal perforation occurred 16 days after admission and light perception was lost. The patient declined any form of surgery and lived in the Northern Transvaal and was not seen after discharge. Repeat cultures taken prior to discharge were negative.

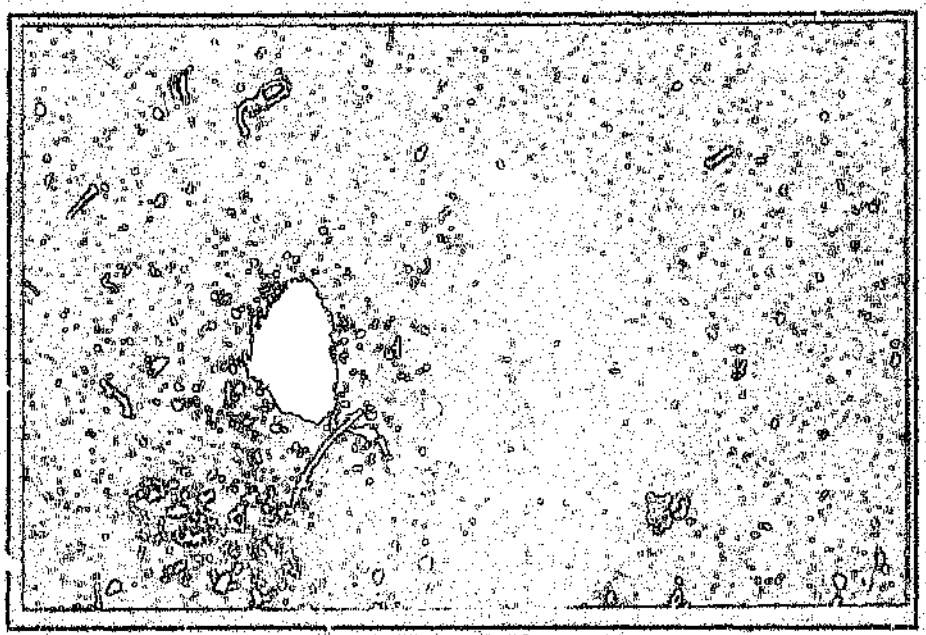

Figure 5.51



Figure 5.52

Case 54: A male of 55 years presented with a five-day history of pain in the left eye. He had nodular CDK (Grade 3) which had become infected and he had a 1mm bloodstained hypopyon (Fig. 5.53). *Phoma eupyrena* (Fig. 5.54) was isolated sensitive to miconazole and ketoconazole (MIC's 0,38 micrograms/ml) and natamycin (MIC 0,75 micrograms/ml). Antifungal treatment was started three days after admission with hourly miconazole drops and subconjunctival injections daily for two days. Thereafter miconazole ophthalmic cream (2%) was used two-hourly.The ulcer healed after two weeks then broke down again. The eye was padded overnight with chloramphenicol ointment and a hypopyon developed. Treatment was then continued with ketoconazole 200mg twice daily and two hourly miconazole cream. Antifungal treatment continued for 14 weeks and the eventual visual acuity was 6/9 (Fig. 5.55). It was of interest that during the treatment period there was improvement in the CDK as can be seen from the photographs.



Figure 5.53



Figure 5.54



Figure 5.55

Case 91: This 60-year-old woman lived on a small-holding near Carltonville. She presented with a one week history of a painful right eye. Onset was spontaneous and she had mild malnutrition but no other predisposing factors. She presented with a 4 by 4 mm ulcer with a 2,4mm hypopyon (Fig. 5.56). *Fusarium monliiforme* (Fig. 5.57) was isolated and this was sensitive to natamycin (MIC 1,5 micrograms/ml), miconazole (MIC 6,25 micrograms/ml) and relatively insensitive to ketoconazole (MIC 25 micrograms/ml). Treatment was begun within 24 hours of admission with miconazole cream 3 hourly and subconjunctival injections of miconazole daily for four days. During this period the situation deteriorated and the hypopyon enlarged (Fig. 5.58) but subsequently steady progress was seen. Three days after admission ketoconazole 200mg twice daily was added and as the clinical response was good this was continued. As there was still hypopyon present one month after admission, topical steroid (prednisolone acetate 1%, Pred forte, Allergan) was added and one drop per day was given for seven days. This reduced the hypopyon but on discharge the ulcer was 3,4 by 3,4 mm and the hypopyon 2,4mm and this after a hospital stay of 39 days. One month after discharge the ulcer was 1mm in diameter with only a trace of hypopyon. On discharge from OPD this patient had a vision of counting fingers at half a metre due to corneal scarring (Fig. 5.59).



Figure 5.56



Figure 5.57



Figure 5.58



Figure 5.59

Case 104: This 69 year old man gave a four week history of a red right eye of spontaneous onset. He had suffered from insulin-dependant diabetes mellitus for 10 years and nephrolithiasis causing reduced renal function. He had a 5 by 4,7mm superficial corneal ulcer with a 1,5mm hypopyon and peripheral corneal vascularization (Fig. 5.60). He had been pretreated with antibiotic and initial culture showed *S. epidermidis* (Class 1). There was no response to the antibiotics given (moderate regimen) and a repeat scrape was done which showed *Curvularia lunata*. This was sensitive to miconazole (MIC 0,39 micrograms/ml) and the 2% ointment was used 3 hourly. There was a slow but favourable response and the patient was discharged with the ulcer 3 by 3mm and a trace of hypopyon (Fig. 5.61). He died at home from renal failure subsequently.



Figure 5.60



Figure 5.61

Case 154: A 62 year old man with mild malnutrition and Grade 3 CDK presented with a one week history of pain in the left eye. The ulcer was 3,3 by

1,3mm with a 1mm hypopyon (Fig. 5.62). *Curvularia lunata* was cultured and was sensitive to miconazole (MIC 6,25 micrograms/ml) and this was started three days after admission with four daily injections of miconazole and 3 hourly cream. Healing was uneventful and the duration of hospital treatment was 15 days. The miconazole cream was continued for three weeks after discharge. Final vision in the eye was 6/9 two months after discharge (Fig. 5.63). Improvement in the CDK following treatment can be seen in the photographs.



Figure 5.62

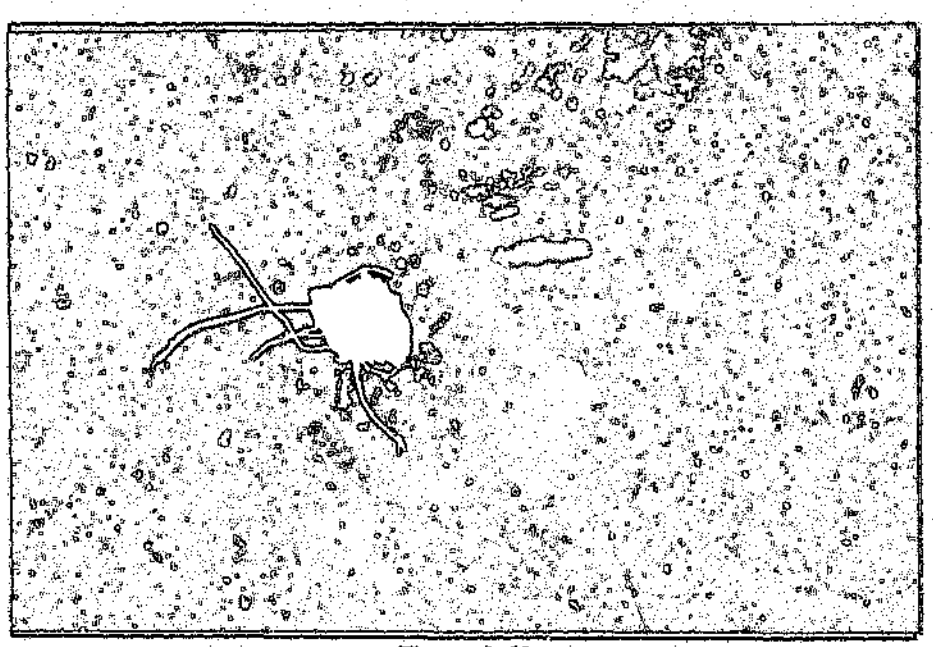

Figure 5.63

Case 124: A 54 year old coloured female presented with a 5,5 by 3,5mm ulcer and a 1,3mm hypopyon (Fig. 5.64). She had been treated with antibiotics and later antiviral medications and the eye had continued to deteriorate with the development of a hypopyon. Corneal sensation was very poor and the patient was diabetic. Initial scrapes showed no growth and on a rescrape *Candida guilliermondii* was isolated. After a hospital stay of seven days the patient requested discharge and subsequently was lost to follow-up and so did not receive antifungal medication.



Figure 5.64

There were two other cases which were treated;

Mr W.: Was seen on 4/3/83 and was a white construction worker of 38 years of age. He gave a history of trauma to the right eye in November 1982 and had subsequently been treated privately for a chronic corneal ulcer. Vision in the eye was reduced to hand movements and corneal sensation was very much reduced. There was a 4,3 by 2,2mm corneal ulcer below the centre of the cornea and limited to the outer third of the cornea with a trace of hypopyon (Fig. 5.65). Corneal scrapings produced a growth of *Curvularia spp.* from BHI broth only after repeated incubation. The case was followed up by a private practitioner subsequently, natamycin was used and the hypopyon, which had been enlarging, disappeared after

two weeks. This eye was grafted the following year and although the graft remained clear, vision was reduced to light perception because of a macular scar.



Figure 5.65

Ms R.: Presented on 6/8/87 and was a 28 year old white female who had a seven week history of a left corneal ulcer which had apparently looked like a dendritic ulcer initially. There were no predisposing factors and corneal sensation was intact. Vision was 6/36 and there was a 2,3 by 2mm paracentral ulcer in the outer third of the cornea with radiating filaments into the stroma. She had been pretreated with topical antibiotics and steroids. Corneal scrapes showed hyphae on the direct smear and *Curvularia spp.* was isolated which was reported as being sensitive to ketoconazole, miconazole and natamycin (MIC's were not done). Within 24 hours miconazole cream was started 3 hourly and subconjunctival miconazole was given daily for five days. Natamycin three hourly was started seven days after presentation as the initial response was slow and

ketoconazole 200mg twice daily started two weeks after presentation. The ulcer was healed in six weeks, treatment having been done as an outpatient. Topical steroid was used in conjunction with the natamycin after two months and continued for five weeks. Thereafter small amounts of natamycin were used for a further month. Antifungals were used for five months and the patient was seen [illegible] times during the treatment period). Final vision was 6/9 uncorrected and 6/7.5 with a correction of plano/-1 at 80° and this last visit was almost three years after initial presentation.

5.3.3 Central Viral Ulcers

This group of 13 ulcers contains many problem cases where the exact diagnosis was in doubt and response to therapy was poor. In the absence of a positive culture the diagnosis was based upon clinical appearance and clinical response.

Case 29: This two-year-old boy had a vague history of trauma and presented with a 5 by 4mm inferonasal leaking descemetocoele. There was associated punctate keratopathy and no corneal sensation. The child was not malnourished but had been treated at a peripheral hospital before referral. *S. epidermidis* (Class 4) was isolated and there was no substantial change in the eye after pressure padding and daily subconjunctival injections and so a partial conjunctival flap was placed over the descemetocoele area to assist healing. The anterior chamber remained shallow after the surgery.

Case 30: A two-year-old coloured girl presented with a 2 by 1mm ulcer and superficial corneal abscess. There were no predisposing factors and corneal scrapings done under general anaesthetic showed no growth. It became obvious that it was a dendritic ulcer and idoxuridine ointment was started three hourly. It healed well leaving a small paracentral scar.

Case 33: This 61-year-old man presented with a 3,5 by 3mm corneal ulcer and abscess extending full thickness (Fig. 5.66). The patient was diabetic and had bullous keratopathy following cataract surgery and there was no corneal sensation. There were no organisms cultured and response to the severe regimen was poor. After nine days antibiotics were discontinued for 24 hours and the ulcer rescraped. There were again no organisms cultured. After 17 days a descemetocoele formed but the cornea did not perforate (Fig. 5.67). Slow vascularization of the cornea took place and a purse-string conjunctival flap was done 30 days after admission. The conjunctival flap retracted postoperatively and the patient was left with a vascularized paracentral corneal scar and light perception vision (Fig. 5.68).



Figure 5.56



Figure 5.67



Figure 5.68

Case 40: This two-year-old boy presented with a paracentral abscess with 1mm overlying ulcer. There were no predisposing factors and *Streptococcus mitior* (Class 1) was isolated. Treatment was initially with a moderate regime but as the abscess resolved a dendritic ulcer could be seen and idoxuridine ointment was used after five days. There was subsequent resolution with scarring off the visual axis.

Case 66: A brick injury the previous year resulted in no light perception in the left eye of this 40-year-old. He had a 2,9 by 2,8mm outer third ulcer with associated abscess and corneal scarring. He had an absence of corneal sensation, mild malnutrition and *Corynebacterium spp.* (Class 4) was isolated. He was treated with the moderate regime and the ulcer healed leaving a ground glass appearance to the cornea.

Case 77: A 49 year old gave a three week history of problems with the right eye after a branch poked it. He had a 3,9 by 2,8mm ulcer with full thickness abscess, surrounding epithelial bullae and posterior synechiae but no active uveitis when seen (Fig. 5.69). He had moderate malnutrition and very reduced corneal sensation and he had been pretreated with all available medications. There was no growth on the initial scrapes or on the repeat scrapes. During his 31 day stay in hospital he was treated initially with the moderate treatment regime for a week with no response. This was followed by five days of idoxuridine and then 11 days of trifluorothymidine. Topical steroids were used twice daily in addition to the antivirals. There was no real response and cryotherapy was applied as four applications over the area repeated five times and then a combination of gamma-globulin and patients serum applied to the ulcer one drop per minute for an hour. When seen at OPD ten days after discharge, there was a 4,4 by 3,6mm abscess with overlying stain (Fig. 5.70) and he was not seen subsequently.



Figure 5.69



Figure 5.70

Case 102: This nine-year-old girl had a history of previous trauma to the eye and had corneal scarring, no corneal sensation and a 1mm ulcer which

extended into the inner third of the cornea (Fig. 5.71). There was a small hypopyon and no bacterial growth was obtained. The moderate regime was used initially but there was little response and a bandage contact lens was inserted on two occasions for a week. Eventually the eye was pressure padded with idoxuridine ointment but on discharge after a 24 day hospital stay there was still slight staining (Fig. 5.72). The eventual visual outcome was 6/24 and the cornea was healed.



Figure 5.71



Figure 5.72

Case 112: This 46 year old man had a 1,6 by 1,3mm paracentral ulcer in a cornea showing scarring and absent corneal sensation. There was no growth and the ulcer was treated with the moderate regimen and ulcer healed slowly, the duration of in-patient treatment being 26 days.

Case 118: This 47 year-old lady gave a history of previous ulceration of the eye as a teenager and the cornea showed a leukoma adherens below the centre of the cornea with a small ulcerated area. The cornea was scarred and vascularised and there was a 1mm hypopyon (Fig. 5.73). Vision in the eye was a surprising 6/9. No growth was obtained and on the moderate regimen the hypopyon became blood-stained and enlarged (Fig. 5.74). Some vitreous opacification followed and it appeared to have progressed to endophthalmitis. An anterior chamber tap and vitreous biopsy were performed and these showed no growth. The uveitis subsequently subsided although some intracorneal haemorrhage developed in the area of the original ulcer. Eventual vision on discharge from hospital after 15 days was 6/12 and the final diagnosis herpes keratouveitis (Fig. 5.75).



Figure 5.73



Figure 5.74



Figure 5.75

Case 125: A 51-year-old with a previous episode of keratouveitis presented with a 1,3 by 1,1mm ulcer in a scarred, vascularised cornea with very reduced corneal sensation. There was a 0,8mm hypopyon and *Peptostreptococcus micros* was isolated but not confirmed on microscopy. The infection

resolved satisfactorily in eight days on the moderate regimen and the anaerobic infection in this situation might have been significant.

Case 132: A 65 year-old presented with a 1,2 by 1mm ulcer and a 1mm hypopyon. He had absent corneal sensation and Grade 3 CDK as predisposing factors. *Escherichia coli* (Class 4) was isolated and the ulcer healed on the moderate regimen in 11 days of inpatient treatment.

Case 138: This 56 year old had been treated two years previously for a supposed bacterial corneal ulcer that had responded poorly to antibiotics. The ulcer had subsequently cleared on antiviral therapy. On this occasion he presented with a 2 by 2mm ulcer above the centre of the cornea in a scarred and vascularised cornea (Fig. 5.76). There was a peripheral leukoma adherens and keratic precipitates indicative of previous uveitis. The patient had mild malnutrition. The other (left) eye showed scarring with vascularisation and 2/60 vision (Fig. 5.77). There were no bacterial isolates but Herpes simplex was recovered from the corneal swab. The ulcer responded well to idoxuridine and the patient later underwent penetrating keratoplasty of the right eye.



Figure 5.76



Figure 5.77

Case 155: This 67 year old had a previous history of admission for keratouveitis eleven years previously. She now presented with a 3 by 2mm ulcer with 1,2 by 0,6mm descemetocoele and a 0,6mm hypopyon (Fig. 5.78). She had moderate malnutrition, Grade 2 CDK and the cornea had no sensation. Initial treatment was daily subconjunctival injections and pressure padding and there was no isolate obtained. The hypopyon persisted and one week after admission corneal glue was applied (Fig. 5.79) and treatment continued with trifluorothymidine hourly and later topical steroid was added. The response to this was excellent and the glue remained in place with an overlying soft contact lens for three weeks after discharge (Fig. 5.80). The glue and contact lens were in place for a total of four weeks. The anterior chamber then became shallow but deepened on pressure padding and the patient declined to have a corneal graft.



Figure 5.78

Case 156: This 67 year old had a previous history of admission for keratouveitis eleven years previously. She now presented with a 3 by 2mm ulcer with 1,2 by 0,6mm descemetocoele and a 0,6mm hypopyon (Fig. 5.78). She had moderate malnutrition, Grade 2 CDK and the cornea had no sensation. Initial treatment was daily subconjunctival injections and pressure padding and there was no isolate obtained. The hypopyon persisted and one week after admission corneal glue was applied (Fig. 5.79) and treatment continued with trifluorothymidine hourly and later topical steroid was added. The response to this was excellent and the glue remained in place with an overlying soft contact lens for three weeks after discharge (Fig. 5.80). The glue and contact lens were in place for a total of four weeks. The anterior chamber then became shallow but deepened on pressure padding and the patient declined to have a corneal graft.



Figure 5.78



Figure 5.79



Figure 5.80

5.3.4 Marginal Catarrhal Ulcers

Of the 30 eyes in this group, 17 (57%) were initially treated with the moderate regimen. Three were treated with the severe regimen and two treated with pressure padding (one with daily and one with twice-daily injections). The remaining eight received the mild regimen of drops only and in three cases this included steroid from the outset. In addition to these three, 57% of the eyes received topical steroid once the infection had been controlled so that overall two-thirds of these eyes received steroid.

Generally, this group of patients did well, as the infective element was not very severe. The delay before presentation was 17 days and mean duration of hospital treatment was 13 days.

Visual results were better than with the central ulcers and the average initial visual acuity was 7,4 and final visi[illegible] This improvement in vision being significant, p being less than 0,0001 (pa[illegible] [illegible]dent *t* test)

The scattergram of visual a[illegible] onfirms the good visual result obtained in this group. The regression line [illegible] the line of no improvement and the coefficient of determination (R^2) was 0.57 showing a reasonable fit of the regression equation to the data.

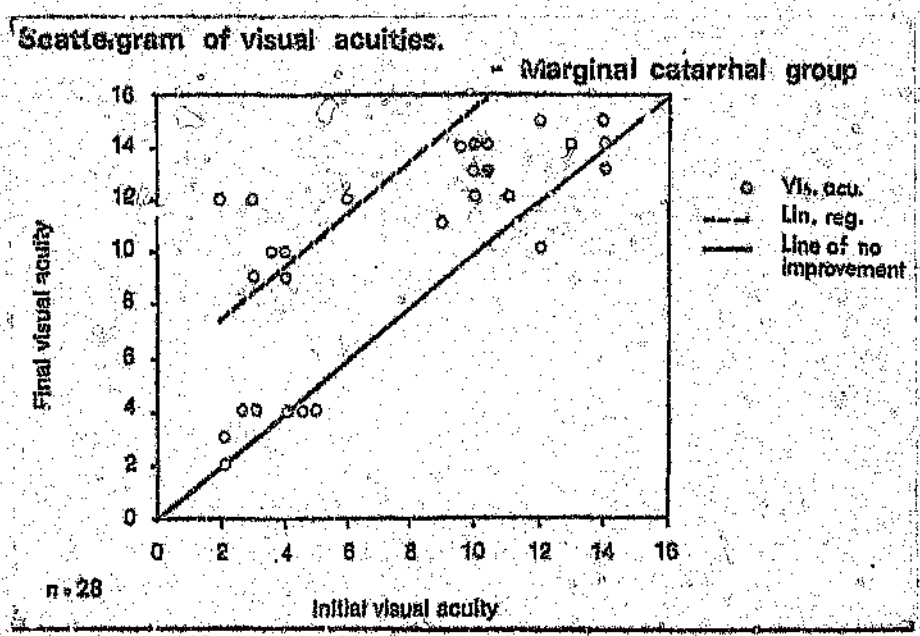

Figure 5.81

Only five eyes showed complications and this included three eyes perforated on admission, one descemetocoele on admission, and one descemetocoele which formed after admission and required a partial conjunctival flap.

One of the perforations was peripheral, the anterior chamber was deep and it healed well. One was pressure padded and healed, and the other perforation occurred in a bilateral case. The latter had a purse-string conjunctival flap and later a penetrating corneal graft which was clear on discharge but the patient was not seen subsequently.

5.3.5 Marginal Ring Ulcers

There were 12 eyes from 11 patients in the group. Eight eyes were treated with drops only and four of these included topical steroids from the outset. In a further three eyes, steroid drops were added to the initial antibiotic drops given. Three eyes received the moderate regimen and one perforation was pressure-padded and received daily subconjunctival antibiotics.

This group of patients did well as the pathology was largely confined to the marginal cornea. The mean delay before presentation was 28 days (one case of 150 days was excluded) and the average inpatient treatment period was 13 days.

The average initial visual acuity was 9,3 and the average final visual acuity was 13,5.

There were three descemetocoeles on presentation and one perforation on admission. The bilateral peripheral descemetocoeles in one patient were covered by partial conjunctival flaps and the other descemetocoele was covered by a corneal patch and this was covered by a partial conjunctival flap. The perforation presented with a flat anterior chamber, reformed on pressure padding and subsequently had a partial conjunctival flap to cover the area. Three other patients had conjunctivectomy procedures done to assist healing of the marginal ulceration. In all cases it was followed by slow healing of the ulcer.

5.3.6 Marginal Mooren's Ulcers

There were four cases regarded as being Mooren's ulcers:

Case 90: A ten year-old female presented with a typical ulcer extending almost halfway around the peripheral cornea and 3,4mm centrally. Vision was 6/6 on admission and there were no predisposing factors. Treatment was with fortified drops and then topical steroids in addition to the antibiotic.

Perforation occurred 12 days after admission and the anterior chamber reformed on pressure-padding. A peritomy and conjunctivectomy was performed 23 days after admission but the ulcer progressed relentlessly. A purse-string conjunctival flap was done three days later, which retracted, and a superficial keratectomy was done a month after this, to remove the remaining area of central cornea as the eye remained painful. A final vision of counting fingers at half a metre was recorded nearly five months after presentation and the eye showed the vascularised, thinned cornea typical of an end-stage Mooren's ulcer.

Case 97: A 37-year-old male with a history of problems with the right eye for four years presented with an active Mooren's ulcer covering two thirds of the cornea. There were no predisposing factors and the ulcer was treated with topical steroids from the outset. On discharge eight days later, the ulcer was unchanged. Two months later, the ulcer was seen to be slowly extending and a penetrating corneal graft was done three months after the initial presentation. There was a recurrence of the ulcer in the graft and a purse-string conjunctival flap was done which retracted. A repeat graft was done nine months after first presentation and a month later the patient had an oedematous graft with an intra-ocular pressure over 20mm Hg.

Case 98: A 37 year-old male presented with a 0,4 by 0,1mm staining area in his left eye having been unsuccessfully treated for a Mooren's ulcer in his other eye one year previously. The second eye was successfully treated using a combination of conjunctivectomy, plasma exchange and immunosuppressive therapy. The use of plasma exchange was a new method of treatment and this case has been fully reported[8].

Case 160: A 73 year-old male who had Grade 3 CDK had a penetrating corneal graft the previous year for a perforated corneal ulcer. He presented with a rejected vascularised graft with bullous keratopathy and no corneal sensation. He had two areas of marginal corneal ulceration affecting the cornea outside the graft. Graft sutures were removed and a partial conjunctival flap done to cover the ulcer. Progression was relentless and when last seen (two months later), there was only a small area of central cornea remaining unaffected.

5.3.7 Marginal Primary Ulcers

This group contained six ulcers which were considered primarily infective in origin but nevertheless occurred in the marginal cornea. The results of treatment should thus be better as the central cornea was spared. The average initial vision for the group was 5,6 and final vision 10,8. The group otherwise had predisposing factors similar to central bacterial ulcers.

Case 2: A 16 year-old male had a seed husk embedded in the marginal cornea and a *S. aureus* (Class 1) was isolated. Response to fortified drops was excellent and final vision 6/6.

Case 9: This 27 year-old male presented with a marked purulent discharge and marginal furrow ulcers in the left eye (Fig. 5.82). He had a history of epiphora and lower lid ectropion in the same eye. An isolate of *Neisseria gonorrhoeae* (Class 3) confirmed the clinical diagnosis (Fig. 5.83) and the patient was treated with the moderate regime and Penicillin systemically for the gonorrhoea. Vision when last seen was 6/9 (Fig. 5.84).



Figure 5.82



Figure 5.83



Figure 5.84

Case 57: This 40 year-old female was admitted in delirium tremens and had marginal corneal ulceration in the left eye and a large hypopyon (Fig. 5.85). The other eye was phthisical. Alcohol abuse was a predisposing factor and *M. lacunata* (Class 1) and *S.epidermidis* (Class 1) were isolated. Treatment was with the severe regimen and intravenous penicillin G, 1 million units 6 hourly was given. Healing was slow and inpatient treatment was continued for 29 days, but a final vision of 6/18 was obtained five weeks after discharge (Fig. 5.86).



Figure 5.85

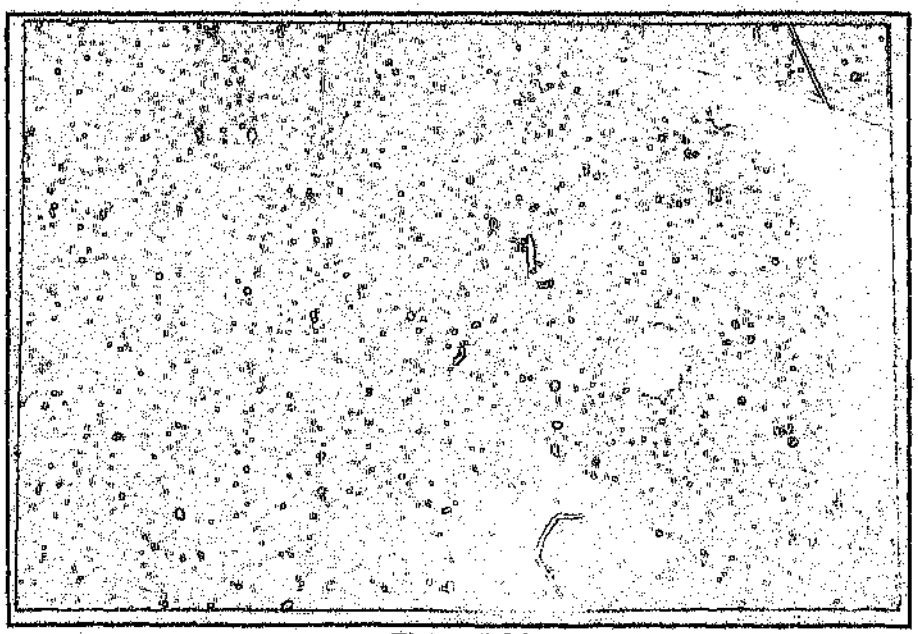

Figure 5.86

Case 117: A five-year old female was admitted with a marginal dendritic ulcer (Fig. 5.87). Treatment was with idoxuridine and the ulcer healed well (Fig. 5.88).



Figure 5.87

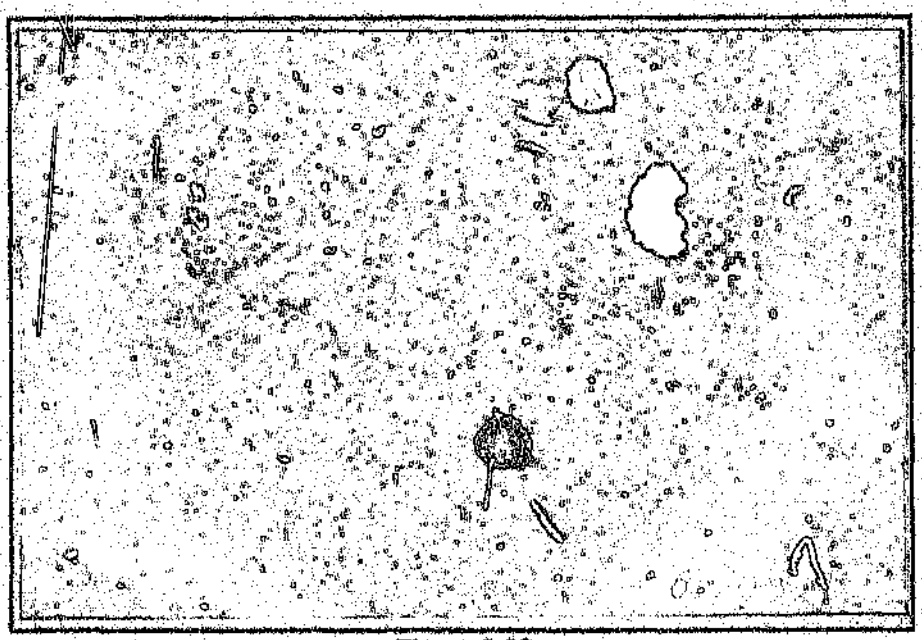

Figure 5.88

Case 126: This 40 year-old lady had previously had surgery to the right frontal sinus and radiotherapy six months before presentation. She had a peripheral ulcer, rubeosis iridis and no light perception in the eye. There was a marked muco-purulent discharge from the eye and *Corynebacterium spp.* (Class 1) and *S. aureus* (Cla 5) were isolated. Treatment was with the severe regimen and a partial conjunctival flap was done four days after discharge. Two months after discharge the conjunctival flap was in place and a retrobulbar alcohol injection was done for chronic pain in the eye.

Case 164: A 55 year-old lady with adult onset diabetes presented with a marginal corneal ulcer and absent corneal sensation. Response to antibiotic, antiviral, and topical steroid drops was poor and the ulcer never became larger but took about four months to heal. Vesicles in the ear at one stage made the diagnosis of herpes zoster a likelihood and there was also palsy of some extraocular muscles and ptosis. A C.T. scan done previously in 1980 was reported as normal. This patient is still being followed up and has a slow growing intracranial mass lesion which was visible on the initial scan. In retrospect it seems likely that the ulcer was neurotropic in origin as the neurologic signs have remained . No surgery was permitted by the patient so the nature of the tumour is not known but no further deterioration has occurred and the patient was last seen during 1990.

5.3.8 Marginal "Other"

This group of five eyes contained three eyes with vernal ulcers treated with antibiotic/steroid combinations and one marginal ulcer caused by trichiasis and one dellen ulcer. The latter two healed well with topical antibiotic drops.

5.4 Discussion

The principles behind treatment of corneal ulceration were:

1) Control of any infectious element,

2) Healing of the ulcer,

3) Preservation of vision.

Further considerations in treatment included; time taken to achieve healing and the reduction of inpatient treatment to allow the patient to continue working; a graded approach that mild infections did not receive unwarranted resources of time or medication, reduction in the number of complications occurring after presentation and prompt handling of complications such as perforations; and selection of antibiotics to be used, based upon the usual microbiological spectrum in the area.

Part of ulcer management is preventative which mainly concerns addressing predisposing factors common in the area as well as primary treatment and timeous referral by primary health care workers (general practitioners, clinics and peripheral hospitals).

The basic approach to the management of bacterial corneal ulcers appears to have remained unchanged since Allen[9] outlined his methods in 1971. This paper by Allen was apparently based on the teaching notes used for graduate students at Harvard Medical School and Massachusetts Eye and Ear Infirmary and was one of the first on general management of bacterial corneal ulcers[7]. Both Allen[9] and Theodore[7] emphasized the use of concentrated (fortified) antibiotic drops and episcleral (subconjunctival) antibiotic injections as the mainstay of management rather than systemic antibiotic therapy. In particular, Theodore[7] mentions his successful use of these concentrated antibiotic drops over a 20 year period and in 1952 had suggested methods for preparing eye drops in a sterile way[10].

Since the early 1970's there have been many fine papers advising on improvements to these methods. The meticulous approach of Jones[1,2,3] seemed to set new standards in the approach to management. Baum[4,5], Wilhelmus[11], and Wilson[12] have also provided useful approaches based on their extensive experience in the field.

An area in which there seems to have been a deficiency is in the assessment of the treatment methods. This is perhaps because there are many confounding variables and because the condition is uncommon, there is a problem collecting enough similar cases for prospective trials. Results of treatment have been reported by Chaudhuri and Godfrey[13] who found that 54% of the 32 bacterial corneal ulcers in their study healed in one week. Eighty-two percent had healed by two weeks and 88% by three weeks. Nine percent (three eyes) were lost due to uncontrolled infection and late presentation. Groden and Brinser[14] commented on the variation in healing time with *P. aeruginosa* ulcers. The range was from seven to 42 days for the eight ulcers with a mean of 22 days. Coster and Badenoch[15] reported on a series of 78 eyes and found that in 20% there was "complete resolution", and in a further 35% useful vision was achieved (hand movements to count fingers). Including the cases that had successful corneal grafts (12 eyes) the total percentage with a good outcome was 72%. Thirteen eyes (18%) were lost during the five and a half year period. Ormerod et al[16] reported 24% major complications in 227 cases of microbial keratitis in Los Angeles. These included mainly corneal perforation (18%), descemetocoeles (3%) and endophthalmitis (3%). Ormerod[6] reported retrospective data from St John Eye hospital and found major complications occurring in 29% of the 131 cases. This included 15% early corneal perforations (on admission or within three days) and a further 3% late perforations. Early descemetocoeles were seen in 7% and late descemetocoeles in a further 4%. Endophthalmitis occurred in 3%. The results in corneal ulcer treatment at these two different hospitals were remarkably similar.

In assessing the results of treatment of the survey at St John Eye Hospital reported in this chapter, results were measured in terms of complications and visual acuity (Table 5.4). It was difficult to compare the results directly with the other studies mentioned above as different approaches were used and the severity of individual cases often determines the outcome.

Comparison of Results of Treatment for Larger Groups						
	Treatment Group					
	Central Bacterial			Marginal		
	Mod.	Sev.	P.P.	CV	MC	MR
No. of eyes	51	16	17	13	30	12
Delay in presentation	7	8	13	9	17	28
Patient days	10	18	19	17	15	13
Initial vision	4.8	2.7	3.4	5.9	7.4	9.3
Final vision	7.8	3.8	5.0	6.1	10.1	13.5
Complications (%)	27	81	100	31	17	33
Surgery (%)	12	69	47	15	7	58

Note: Mod. is moderate treatment group, Sev. is severe group, P.P. is all cases in pressure-padded groups, CV is central viral group, MC is marginal catarrhal group, MR is marginal ring group, No. is number.

Table 5.4

The duration of hospital stay (patient days) was an index of healing time as patients were generally discharged as soon as the ulcer was healed. It can be seen (Table 5.4) that the severe ulcers remained in hospital for almost double the time that the moderate ulcers did. This difference was significant (p less than 0,0001 using the Student *t* test). The percentage of complications and surgical intervention rose with severity of bacterial ulcer as might be expected. The differences in the outcome (Table 5.4) for the different ulcer groups, illustrates the difficulty in reporting results unless the study has been done in a prospective way. The results clearly confirm that severe bacterial corneal ulcers have a poor prognosis when compared to mild and moderate bacterial ulcers and marginal ulcers (excluding Mooren's ulcer). It is also clear from the published results in the literature (given above) that these severe infections and patients presenting late for treatment tend to do badly wherever they are treated.

At St John Eye Hospital the results of treatment of the mild and moderate groups of bacterial corneal ulcers was good in three quarters of cases during the prospective survey. In the remainder, complications were usually related to slow, indolent healing. In this group of patients, a poor healing response was seen in relation to malnutrition (sometimes associated with measles or alcoholism), and climatic droplet keratopathy. There was not statistically more malnutrition in the complicated cases as opposed to those who healed well although the percentage of those with malnutrition was double in those who had complications.

In moderately severe ulcers there was a statistically significant visual improvement following treatment. In severe bacterial corneal infections and those showing perforations or descemetocoeles on admission, the outcome was very different. No significant visual improvement was seen in these groups following treatment. In the severe group one in three eyes was lost (five of 16). Only three eyes achieved useful vision (Snellen chart acuity) and these included two with no complications and the other had a small descemetocoele caused by a *M. lacunata* infection. Of the other severe infections, half were caused by *S. pneumoniae* and quarter by *P. aeruginosa*. In cases which were pressure-padded there was no bacterial growth obtained in half of the cases perhaps suggesting a sterilising effect of a perforating ulcer.

In selecting the initial antibiotic regime the two approaches widely quoted are those of Jones[3] and Baum[4]. Dan Jones stressed the importance of using the Gram stain of the direct smear to choose an antibiotic while Baum advocated a broad spectrum approach initially. During this study many of Jones' methods were followed but a broad spectrum approach to initial antibiotic therapy was used. Although direct microscopy was found to be useful in 66% of ulcers (Chapter 4) when no organism was seen there was still a 50% chance of culturing an organism. Relying totally on direct smears can result in inappropriate therapy in some cases[17]. Jones[18] has added that the severity and clinical impression of the ulcer are also important in making the initial decision on therapy but in using direct smears to determine therapy, absence of antibiotic therapy for the preceding 24-48 hours and adequate laboratory services are required.

The antibiotic selection available has greatly expanded since Thygeson[19] reported using thermal cautery to treat pneumococcal ulcers prior to 1938 and thereafter satisfactorily using sulphonamides and later penicillin. The aminoglycosides, particularly gentamicin have been the backbone of therapy for more than 20 years and the only serious fault in the antibiotic is a variable effect on streptococci[20]. In fact, total resistance of streptococci to gentamicin has been reported[21]. Experimentally, it has been suggested that tobramycin might be more effective against pseudomonas infections of the cornea[22]. The combination of gentamicin or tobramycin with a beta-lactam antibiotic produces a synergistic action and the cephalosporins have generally been used for this action and to complete the antibacterial spectrum[23]. The third generation cephalosporins, like ceftazidime, have a virtually full spectrum (enterococcus perhaps the only exception) but they have considerably less activity against Gram-positive organisms than first generation cephalosporins (eg. cephazolin)[23]. Currently, the use of a cephalosporin or bacitracin

against Gram-positive organisms and gentamicin or tobramycin against Gram-negative organisms is recommended[24]. The search for broad spectrum, non-toxic antibiotics continues and renewed interest in the quinolone antibiotics ciprofloxacin, oxfloxacin and norfloxacin may result in a useful successor to gentamicin[25].

There are several adjuncts at our disposal to assist in the management of complications. In dealing with indolent ulcers and descemetocoeles bandage contact lenses may be useful in selected patients[26]. Soft contact lenses (Plano T, Bausch & Lomb Inc.) were used in cases 26, 49 and 140 in the moderate group to promote corneal healing and in case 51 in the severe group to manage a descemetocoele. They can be used together with various medications[27] but this was not tried during this study. As the available contact lenses were of a single base curve they either worked or they were removed. In one case (case 140) a hypopyon developed presumably due to a tight fit and the contact lens had to be removed. In the other cases the lens was tolerated well and the patient could be discharged with the lens in situ. Good patient compliance limited their use in this population as some patients lived too far away for safe follow-up.

Penetrating keratoplasty was generally reserved for cases in which medical treatment was unsuccessful. As many of the patients were manual labourers (Chapter 2) and duration of hospital stay usually approached three weeks for the complicated cases, the emphasis was on rapidly returning the patient to their occupation and not primary visual rehabilitation. In this setting the results of penetrating keratoplasty were not good but inadequate follow-up prevented the eventual outcome being known in some cases. Welsh[28] found that at half of corneal grafts were successful in 55 cases of keratitis. The success rate was not affected by race group and 40 of the patients were African. Hill[29] reported the use of early keratoplasty in 23 patients with central indolent ulcers and descemetocoeles. The hospitalization period was 18 days and 12 rejected. Six of the rejections were reversed and half the patients with clear grafts had a corrected acuity of 6/12 or better at follow-up. Dixon[30] reported 11 patients who had been grafted for bacterial keratitis in Canada. Two had clear grafts, five were opaque and four patients died or were lost to follow-up.

Tissue adhesive is a useful adjunct in the management of perforations[31] and can be used together with sodium hyaluronate[32] in the treatment of perforations up to 2mm in diameter. Izobutyl-2-cyanoacrylate (Ethicon,Bucrylate) was used successfully in case 156 (central viral ulcer) with the addition of an overlying soft contact lens. A further use is

in anterior chamber reformation prior to penetrating keratoplasty[33] and this was used in the marginal catarrhal patient who had a corneal graft.

Recent adjuncts include collagen shields used to deliver gentamicin and vancomycin[34] and tobramycin[35]. Fibrin tissue has been used to seal perforations[36] and they might replace adhesives which are generally rough and need a soft contact lens as a cover to prevent lid movement removing the adhesive. Excimer laser has been used[37] in an attempt to ablate suppurative areas but was only found to be useful in localized, superficial areas of infection.

Although the general treatment regimens used in bacterial keratitis seem now fairly established, the general approach best suited for fungal keratitis is less sure. Barrie Jones[38] in 1975, pointed out the rising incidence of this condition and the hitherto poor prognosis it carried. He discussed the various drugs available, the poor penetration and unacceptable toxicity of Amphotericin B, the broad spectrum but lack of corneal penetration of natamycin, and the narrow spectrum of flucytosine. These three drugs were the only antifungals generally available for ocular use at that time and still are. He pointed out the advantages of the imidazole derivatives in terms of their ocular penetration and broad spectrum. Prior to this a surgical approach was standard using thin conjunctival flaps[39] or penetrating keratoplasty[40,41,42]. The approval of pimaricin (natamycin) for ocular use in the United States of America in 1975 saw a shift to medical therapy using this drug with good results[43,44]. Later, miconazole[45] and ketoconazole[46] were used successfully. In 1986 Fitzsimons and Peters[47] in Natal, South Africa, used a combination of miconazole and ketoconazole to heal 13 of 20 fungal ulcers and modified therapy (using natamycin) to heal a further three ulcers so 16 of the 20 eyes were eventually successfully treated. Mohan[48] reported a prospective series of 85 cases where 1% miconazole was used successfully in 65% of the ulcers.

In the cases of fungal keratitis reported in this thesis, good results were achieved in all cases except for one (case 1) in which there was an extremely severe fungal ulcer on presentation. The cases showed a greater chronicity and slower response to treatment than bacterial ulcers. This latter fact makes it imperative that a diagnosis is made rapidly so that appropriate therapy can be initiated. The direct smear is crucial in the early diagnosis of fungal infection[49] as clinical impressions can be misleading[50]. The insidious onset of secondary fungal infection in a viral corneal ulcer was suggested in several cases (case 124 and Ms R.) and this diagnostic dilemma can be subtle. When seen weeks later by

another observer the ulcer might appear typical of a fungus infection and no real evidence of viral infection might be seen.

Viral conditions of the cornea may provide diagnostic dilemmas. In addition to the dendritic pattern that is so classical of herpes keratitis, the presentation of herpes keratouveitis may be varied and the diagnosis might not be obvious[51]. The poor response to antibiotics and absence of fungal growth should prompt a rescrape (after about five to seven days). The rescrape should be done after 24 hours without antimicrobial therapy. Secondary bacterial infection can mask a viral keratitis[51,52] and this was seen in case 40 and possibly case 125. The history of previous episodes was probably the best clue to the nature of the pathology and the best sign was corneal scarring and stromal vascularisation in either the same or fellow eye. The most confusing history was that of trauma to the eye as a healing abrasion and subsequent recurrent epithelial defect can closely mimic a dendritic keratitis and be quite confusing. The indolent healing pattern and indolent ulcer appearance might be typical and surgical procedures are sometimes required to assist healing or manage descemetocoeles and perforations. In a very resistant ulcer/abscess (case 77) a combination of cryotherapy and immunotherapy[53] was attempted with no improvement being observed.

Marginal catarrhal ulceration is generally a benign disease[54] and is usually a complication of chronic staphylococcal blepharitis[55]. In a controlled prospective study[56] it was shown that topical steroids were the treatment of choice. During the study at St John Eye Hospital, the management of this condition was fairly straightforward and the results of treatment very good. The average final vision in the group was 10,1 which is about 6/36. The group showed super-infections in some cases and once these were controlled and steroid added topically, resolution was rapid, few complications seen and surgery seldom required.

Marginal ring ulcers showed an even better eventual visual acuity of 13,5 which is about 6/9-6/12. Surgery was fairly commonly required and was done usually for perforated ulcers or as conjunctivectomy procedures[57] to eliminate the ulcer.

The use of plasma exchange in treating an early Mooren's ulcer was fully reported[8] and the management of Mooren's ulceration will not be further discussed as the number of cases seen was small and it is not a significant cause of morbidity at St John Eye Hospital.

To establish the role of topical steroid therapy in the management of bacterial corneal ulcers and improve the assessment of treatment results, a further study was planned and this is reported in Chapter 6. In the steroid study, healing rates based on the area of the ulcer were used rather than the less accurate "patient days" in measuring ulcer healing in order to take into account the initial size of the ulcer.

5.5 References

1. Jones DB. Early diagnosis and therapy of bacterial corneal ulcers. *Int Ophthalmol Clin* 1973; 13: 1-29.
2. Jones DB. Initial therapy of suspected microbial corneal ulcers. II. Specific antibiotic therapy based on corneal smears. *Surv Ophthalmol* 1979; 24: 105-16.
3. Jones DB. Strategy for the initial management of suspected microbial keratitis. In: Barraquer JI,ed. *Transactions of the New Orleans Academy of Ophthalmology*. Symposium on medical and surgical diseases of the cornea. St Louis: Mosby, 1980; 86-119.
4. Baum JL. Initial therapy of suspected microbial corneal ulcers. I Broad antibiotic therapy based on prevalence of organism. *Surv Ophthalmol* 1979; 24: 97-105.
5. Baum JL. Therapy for ocular bacterial infection. *Trans Ophthalmol Soc UK* 1986; 105: 69-77.
6. Ormerod LD. Causation and management of microbial keratitis in subtropical Africa. *Ophthalmology (Rochester)* 1987; 94: 1662-8.
7. Theodore FH. Points in the treatment of bacterial corneal ulcers. In: Leopold IH, ed. *Symposium on ocular therapy*. St Louis: Mosby, 1973; 5: 48-55.
8. Carmichael TR, Mervitz MD, Bezwoda W, Rush PS. Plasma exchange in the treatment of Mooren's Ulcer. *Ann Ophthalmol* 1985; 17: 311-4.
9. Allen HF. Current status of prevention, diagnosis, and management of bacterial corneal ulcers. *Ann Ophthalmol* 1971; 3: 235-46.
10. Theodore FH, Feinstein RR. Practical suggestions for the preparation and maintenance of sterile ophthalmic solutions *Am J Ophthalmol* 1952; 35: 656-9.
11. Wilhelmus KR. Bacterial corneal ulcers. *Int Ophthalmol Clin* 1984; 24: 1-16.
12. Wilson LA. Acute bacterial infection of the eye: bacterial keratitis and endophthalmitis. *Trans Ophthalmol Soc UK* 1986; 105: 43-60.
13. Chaudhuri PR, Godfrey B. Treatment of bacterial corneal ulcers with concentrated antibiotic eye drops. *Trans Ophthalmol Soc UK* 1982; 102: 11-4.

14. Groden LR, Brinser JH. Outpatient treatment of microbial corneal ulcers. *Arch Ophthalmol* 1986; 104: 84-6.

15. Coster DJ Badenoch PR. Host, microbial, and pharmacological factors affecting the outcome of suppurative keratitis. *Br J Ophthalmol* 1987; 71: 96-101.

16. Ormerod LD, Hertzmark E, Gomez DS, Stabiner RG, Schanzlin DJ, Smith RE. Epidemiology of microbial keratitis in Southern California · a multivariate analysis *Ophthalmology* 1987; 94: 1322-33.

17. Maske R, Hill JC, Oliver SP. Management of bacterial corneal ulcers. *Br J Ophthalmol* 1986; 70: 199-201.

18. Jones DB. Decision-making in the management of microbial keratitis. *Ophthalmology* 1981; 88: 814-20.

19. Thygeson P. Acute central (hypopyon) ulcers of the cornea. *Californ Med* 1948; 69: 18-21.

20. Records RE. Gentamicin in ophthalmology. *Surv Ophthalmol* 1976; 21: 49-58.

21. Seal DV, Barrett SP, McGill JI. Aetiology and treatment of acute bacterial infection of the external eye. *Br J Ophthalmol* 1982; 66: 357-60.

22. Smolin G, Okumoto M, Wilson II FM. The effect of tobramycin on pseudomonas keratitis. *Am J Ophthalmol* 1973; 76: 555-60.

23. Leopold IH. Update on antibiotics in ocular infections. *Am J Ophthalmol* 1985; 100: 134-40.

24. van Bijsterveld OP, van Hemel OLH. Bacterial conjunctivitis and keratitis. *Current Opinion in Ophthalmology* 1990; 1: 323-32.

25. Borrmann LR, Leopold IH. The potential use of quinolones in future ocular antimicrobial therapy. *Am J Ophthalmol* 1988; 106: 227-9.

26. Morrison R, Shovlin JP. A review of the use of bandage lenses. *Metab Pediatr Syst Ophthalmol* 1982; 6: 117-21.

27. Dada VK, Acharjee SC. Soft lenses as therapeutic device. *Indian Journal of Ophthalmology* 1982; 30: 201-3.

28. Welsh NH. The results of corneal grafting in different racial groups. *South African Archives of Ophthalmology* 1979; 6: 19-30.

29. Hill JC. Use of penetrating keratoplasty in acute bacterial keratitis. *Br J Ophthalmol* 1986; 70: 502-6.

30. Dixon WS. Treatment of corneal perforations and ulcers with primary keratoplasty. *Dev Ophthalmol* 1989; 18: 176-80.

31. Weiss JL, Williams P, Lindstrom RL, Doughman DJ. The use of tissue adhesive in corneal perforations. *Ophthalmology* 1983; 90: 610-5.

32. Hirst LW, De Juan E. Sodium hyaluronate and tissue adhesive in treating corneal perforations. *Ophthalmology* 1982; 89: 1250-3.

33. Maguen E, Nesburn AB, Macy JI. Combined use of sodium hyaluronate and tissue adhesive in penetrating keratoplasty of corneal perforations. *Ophthalmic Surg* 1984; 15: 55-7.

34. Phinney RB, Schwartz SD, Lee DA, Mondino BJ. Collagen- shield delivery of gentamicin and vancomycin. *Arch Ophthalmol* 1988; 106: 1599-1604.

35. Hobden JA, Reidy JJ, O'Callaghan RJ, Hill JM, Insler MS, Rootman DS. Treatment of experimental pseudomonas keratitis using collagen shields containing tobramycin. *Arch Ophthalmol* 1988; 106: 1605-7.

36. Lagoutte FM, Gauthier L, Comte PRM. Fibrin sealant for perforated and preperforated corneal ulcers. *Br J Ophthalmol* 1989; 73: 757-61.

37. Gottsch JD, Gilbert ML, Goodman DF, et al. Excimer laser ablative treatment of microbial keratitis. *Ophthalmology* 1991; 98: 146-9.

38. Jones BR. Principles in the management of oculomycosis. XXXI Edward Jackson Memorial Lecture. *Am J Ophthalmol* 1975; 79: 719-51.

39. Kaufman HE, Wood RM. Mycotic keratitis. *Am J Ophthalmol* 1965; 59: 993-1000.

40. Sanders N. Penetrating keratoplasty in treatment of fungus keratitis. *Am J Ophthalmol* 1970; 70: 24-30.

41. Singh G, Malik SRK. Therapeutic keratoplasty in fungal corneal ulcers. *Br J Ophthalmol* 1972; 56: 41-5.

42. Singh G, Malik SRK, Bhatnagar PK. *Arch Ophthalmol* 1974; 92: 48-50.

43. Newmark E, Ellison AC, Kaufman HE. Pimaricin therapy of cephalosporium and fusarium keratitis. *Am J Ophthalmol* 1970; 69: 458-66.

44. Jones DB, Forster RK, Rebell G. *Fusarium solani* keratitis treated with Natamycin (Pimaricin). *Arch Ophthalmol* 1972; 88: 147-54.

45. Foster CS. Miconazole therapy for keratomycosis. *Am J Ophthalmol* 1981; 91: 622-9.

46. Ishibashi Y. Oral ketoconazole therapy for keratomycosis. *Am J ophthalmol* 1983; 95: 342-5.

47. Fitzsimons R, Peters AL. Miconazole and ketoconazole as a satisfactory first-line treatment for keratomycosis. *Am J Ophthalmol* 1986; 101: 605-8.

48. Mohan M, Panda A, Gupta SK. Management of human keratomycosis with miconazole. *Australian and New Zealand Journal of Ophthalmology* 1989; 17: 295-7.

49. Wilson LA, Sexton RR. Laboratory diagnosis in fungal keratitis. *Am J Ophthalmol* 1968; 66: 646-53.

50. Mahajan VM, Moledina N. Direct microscopy: An adjunct to clinical diagnosis of sloughing corneal ulcers. *Mykosen* 1983; 26: 154-8.

51. Wilhelmus KR. Suppurative corneal ulceration following herpetic keratitis. *Doc Ophthalmol* 1982; 53: 17-36.

52. Nissenkorn I, Wood TO. Secondary bactetial infections in Herpes simplex keratitis. *Ann Ophthalmol* 1982; 14: 757-9.

53. Amoils SP, Maier G. Cryosurgery and immunotherapy in herpes keratitis. *Br J Ophthalmol* 1973; 57: 809-14.

54. Kinsura SJ. Corneal ulcers. In: *Infectious diseases of the conjunctiva and cornea.* Symposium of the New Orleans Academy of Ophthalmology. St Louis: Mosby, 1963; 88-102.

55. Thygeson P. Complications of staphylococcal blepharitis. *Am J Ophthalmol* 1969; 68: 446-9.

56. Chignell AH, Easty DL, Chesterton JR, Thomsitt J. Marginal ulceration of the cornea. *Br J Ophthalmol* 1970; 54: 433-40.

6.0 Topical Steroids in the Treatment of Central and Paracentral Corneal Ulcers

6.1 Introduction

The treatment of central (primarily infectious) corneal ulcers with topical steroids has remained a controversial subject since the introduction of steroids in the 1950's[1]. The use of steroids is a two-edged sword; they may protect the cornea from host inflammatory response but at the risk of enhancing the infection. There has been no controlled clinical trial to resolve the issue. This is due mainly to a lack of suitable clinical material combined with a large number of variables, such as type of ulcer, isolates, and others.

Experimental data, mainly in rabbits, suggest no adverse effects so long as an appropriate antibiotic is given concurrently with steroids. This has been shown for *Pseudomonas aeruginosa*[2,3] and *Staphylococcus aureus*[4] infections. However Smolin *et al*[5] suggested that wound healing may be delayed and there may be prolonged replication of organisms in pseudomonas infections. Fungal infections seem adversely affected by the use of steroid because the available antifungals achieve only fungistatic levels in the cornea[6]. Clinical studies[7,8] have supported these experimental findings.

This study compares the results of treating one group of corneal ulcer patients with antibiotic only with another group receiving antibiotic plus steroid.

6.2 Patients and Methods

This report concerns 39 patients (40 eyes) studied at St John Eye Hospital between August 1986 and May 1988. The patients included in the study had central or paracentral bacterial corneal ulcers severe enough to warrant hospital admission. Patients were excluded if they had fungal isolates, perforated ulcers or descemetocoeles, underlying viral corneal conditions, atopic ulcers, no light perception on admission, or were less than 13 years of age.

Treatment consisted of Kefzol eye drops (cefazolin, fortified, 32 g/l) and gentamicin eye drops (fortified, 14 g/l) hourly, Atropine eye drops 1% twice daily, chloramphenicol ointment at night (22^{00}) and twice daily multivitamin tablets (Multivites). In addition, subconjunctival cefazolin (125mg) and gentamicin (20mg) were given on admission, the

following morning, and one or two further injections as indicated by the severity of the infection. The subconjunctival antibiotics were injected separately into a blebb of lignocaine. No oral or intravenous antibiotics were used.

Once accepted into the study, the patients were randomised and both groups received the same treatment for 24 hours. On the day after admission if the steroid group were considered to be the same or improved, dexamethasone eye drops (dexamethasone 0,1%) four times a day were added to their treatment and continued until healing was complete, with a minimum of two weeks. If there was frank deterioration the steroid was withheld for 24 hours and the case reassessed and so on.

ASSESSMENT OF RESULTS

Recording sheets were used to document the initial appearance of the ulcer and its size and depth by means of a drawing. The appearance and best corrected visual acuity were noted on the same sheet during the follow-up period. Follow-up was continued until the final best corrected visual acuity was determined (minimum of four weeks). All assessments were done by two doctors (T. Carmichael and Y. Gelfand). In measuring visual acuity the same method with the same Snellen chart was used by both doctors.

To analyze statistically the visual acuity data, visual acuity was converted to a number (Table 6.1).

Visual Acuities (follow-up at 2 months)							
Steroid Group				Non-steroid Group			
Initial	N. eq.	Final	N. eq.	Initial	N. eq.	Final	N. eq.
6/24	11	6/6	15	CF 3m	6	6/12	13
HM	3	6/60	9	HM	3	NLP	1
6/12	13	6/9	14	CF 1m	4	CF 5m	8
CF 4m	7	6/60	9	6/24	11	6/12	13
LP	2	LP	2	HM	3	CF 3m	6
HM	3	CF 1m	4	6/36	10	6/6	15
CF 4m	7	6/12	13	HM	3	6/60	9
HM	3	CF 1m	4	HM	3	HM	3
CF 5m	8	6/24	11	HM	3	HM	3
6/60	9	6/36	10	6/6	15	6/6	15
LP	2	6/36	10	CF 1m	4	6/24	11
CF 2m	5	6/12	13	HM	3	CF 5m	8
CF 1m	4	6/60	9	6/6	15	6/6	15
CF 1m	4	6/36	10				
6/60	9	6/18	12				

Note: N. Eq. is numerical equivalent.

Table 6.1

This meant that no light perception was assigned the number 1 and 6/6 was assigned the number 15. Visions between these values were:

(a) Snellen chart values; (b) counting fingers (CF) from 1 to 5 metres; (c) hand movements (HM); light perception (LP); (e) no light perception (NLP).

For the purpose of comparison between the groups the transition, for example, between 6/24 and 6/36 is regarded as being the same as a deterioration from CF 1m to CF 2m.

Results of treatment were assessed in terms of:

1) Complications
2) Heal rate (mm^2 of ulcer per day)
3) Visual acuity

BACTERIOLOGY

Corneal specimens were taken using a platinum spatula at the slit-lamp. These were inoculated on to blood agar and into serum broth, and brain-heart infusion broth. Two

glass slides were prepared, one for Gram stain and one for a special stain if required. Both base and edges of the ulcer were sampled after necrotic debris were removed. Specimens were processed by the Bacteriology department of Baragwanath Hospital by one technician.

Area of Ulcers

Each ulcer was drawn to scale on to 1mm ruled graph paper and the squares counted. This gave an area for each ulcer, on admission, based on the dimensions measured at the slit-lamp (Fig. 6.1).

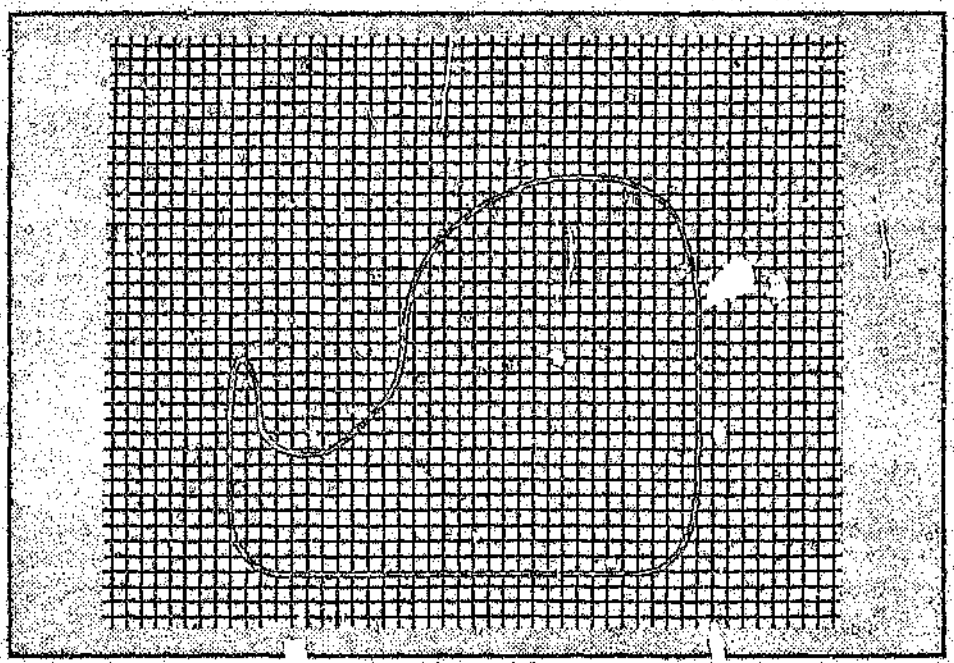

Figure 6.1

The size of the ulcers in mm^2 was used in dividing the ulcers into small (under $3mm^2$), medium (3-$10mm^2$) and large (over $10mm^2$) ulcers, to compare the groups further. The area of ulcer healed per day was then calculated to compare the rate of epithelialization.

6.3 Results

There were 21 eyes in the steroid group and 19 in the non-steroid group. One patient had bilateral corneal ulcers and they were randomised separately.

The groups were statistically comparable in terms of number of eyes in each group, age and duration of inpatient treatment. There were significantly more males in the steroid group (chisquare, p less than 0,01),(Table 6.2).

Comparison of Groups		
	Steroid	Non-steroid
No. of eyes	21	19
Mean age (years)	51.6	51.4
Percentage males	90	76
Inpatient days (mean)	18	20

Table 6.2

There was no significant difference between the ulcers in the two groups with respect to; depth, size, positive cultures, or presence of hypopyon (Table 6.3).

	Comparison of Ulcers (ulcers)	
	Steroid	Non-steroid
Site: Central	7	9
Paracentral	14	10
Depth: Outer third	10	8
Middle third	5	9
Inner third	6	2
Size: Small	9	8
Medium	8	5
Large	4	6
Hypopyon present	16	12
Positive culture	14	14

Table 6.3

Table 6.4 shows that the corneal isolates obtained were similar in both groups and comparable to the isolates previously obtained in this population[9].

	Corneal Cultures	
	Steroid	Non-steroid
Streptococcus pneumoniae	3	4
Streptococcus agalacticae		1
Streptococcus viridans	3	
Staphylococcus aureus		1
Staphylococcus epidermidis	2	3
Bacillus spp.		1
Haemophilus influenzae		2
Pseudomonas paucimobilis		1
Proteus mirabilis		1
Morganella morganii		1
Serratia spp.	1	
Acinetobacter anitratus	1	
Corynebact. spp.	5	1
No growth	7	5
TOTAL	22	21

Note: Mixed culture in steroid group:
Acinetobacter anitratus with *S.epidermidis.*
Mixed cultures in non-steroid group:
S.pneumoniae with *H.Influenzae,*
P.mirabilis with *S.epidermidis.*

Table 6.4

Complications (Table 6.5) were similar in the 2 groups.

Complications		
	Steroid	Non-steroid
Perforation	1	1
Corneal thinning	1	1
Uncontrolled infection	0	2
Recurrence of infection	1	2
Persistent epithelial defect	4	3
Epithelial breakdown	1	1
TOTAL	8	10

Note: Persistent epithelial defect is failure of healing of the ulcer within 21 days.
Recurrence of infection is recurrence of abscess/hypopyon occurring within one week of discharge where the infective element was previously considered cleared.
Epithelial breakdown is breakdown of epithelium after initial healing.
One patient in the steroid group had both persistent epithelial defect and recurrent infection.

Table 6.5

Within the steroid group one case showed descemetocoele formation the morning after admission, and, according to the protocol, steroids were not started. There was corneal perforation the following day and, as the anterior chamber did not reform after pressure padding, a penetrating keratoplasty was performed. Corneal thinning with early descemetocoele formation made it necessary to discontinue steroids after 12 days in one case. The ulcer subsequently healed uneventfully. One patient with a pneumococcal infection showed a persistent epithelial defect (epithelial defect over 21 days) and then presented five days after discharge with a recurrence of corneal abscess and hypopyon. This patient appears under both headings in Table 6.5. Persistent epithelial defects were seen in four cases. Two of these were large ulcers and healed slowly and two had severe climatic droplet keratopathy (CDK). In one case the ulcer healed in five days but the epithelium broke down and rehealing took a further seven days (12 days for final healing). Steroid therapy was discontinued after 12 days in the case of corneal thinning and not given in the case of corneal perforation. All other cases received full courses of topical steroid.

Within the non steroid group a pneumococcal ulcer perforated after three days but responded to conservative treatment (pressure padding) and healed without surgery. One patient showed corneal thinning and descemetocoele formation but responded to pressure

padding and healed uneventfully. Uncontrolled infection occurred in two eyes,the one being a *S.aureus* infection and the other eye was eviscerated but only *S.epidermidis* was isolated. Infection recurred in a patient whose hypopyon had cleared and who was discharged 11 days after admission with a remaining epitheli l defect. This patient presented five days later with fresh corneal infiltrate and hypopyon and was readmitted. In the other patient with recurrent infection healed the ulcer within 21 days but the corneal abscess recurred and he was readmitted to hospital.

There were t ree cases of persistent epithelial defect, two of which were large ulcers and one showed severe CDK. The patient with epithelial breakdown also had CDK but the ulcerated area rehealed in under 21 days.

Healing rates were calculated for 1[illegible] ulcers in the steroid group and 11 in the non-steroid group. Patients were excluded from this analysis if they showed persistent epithelial defects as some never healed completely, and others took two or three months, which would have distorted the analysis. Patients were also excluded if they required therapy other than that in the protocol - for example, pressure padding for perforations or corneal thinning - as this might influence the rate of healing. The two patients with uncontrolled infection did not heal and were excluded from this analysis.

The only patients with complications (Table 6.5) that were included in the heal rate analysis were those with epithelial breakdown and one with recurrent infection in the non-steroid group. These three patients all showed healing within 21 days. This meant that six patients from the steroid group and eight from the non steroid group were excluded.

There was no significant difference when the two groups were compared by Student's *t* test. The mean healing rate for the steroid group was 0.36 mm^2/day and for the non-steroid group was 0.30 mm^2/day.

When the visual acuities between the two groups were compared using the numerical system in Table 6.1, no difference could be shown. A statistically significant improvement in both groups followed treatment, as might be expected. The steroid group had an average pre-treatment vision of 6 and an average post-treatment vision of 9.7 (p less than 0.001, paired analysis by *t*-test). The non-steroid group had an average 6.4 pretreatment and 9.2 post--treatment (p less than 0.01, paired analysis by *t*-test). Visual acuities were also compared by plotting scattergrams for pre- and post-treatment visual

acuities for each group and fitting linear regression lines. There was again no discernible difference between the two groups, though the improvement in the steroid group was slightly greater (Fig. 6.2). The coefficient of determination (R^2) was 53% for the steroid group and 64% for the non-steroid group.

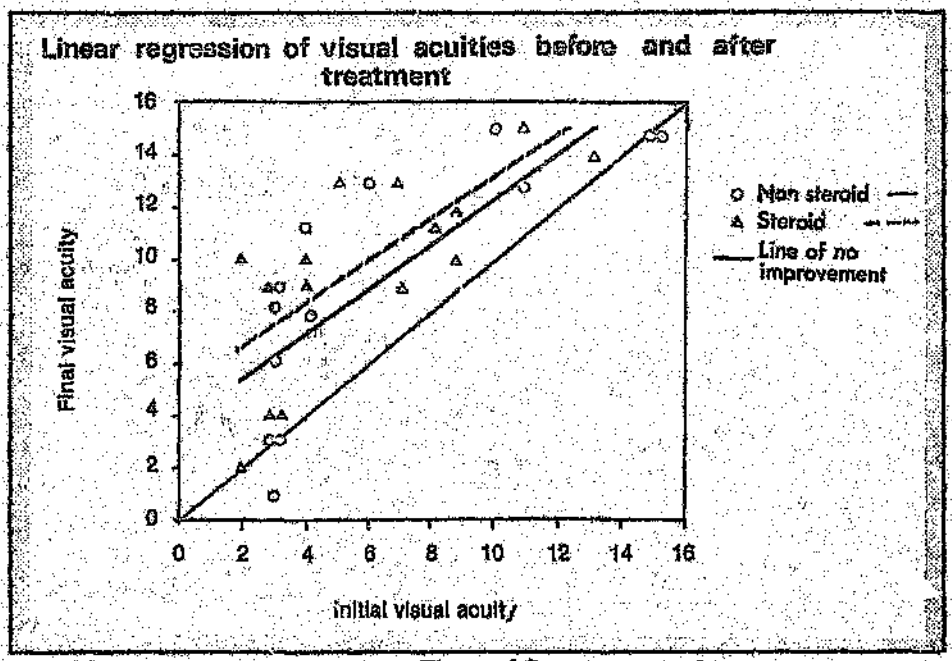

Figure 6.2

6.4 Discussion

Inflammation and subsequent scarring in the cornea may compromise vision. When designing a treatment regimen some consideration must be given to including an anti-inflammatory agent if this can be done safely.

Evidence against the use of steroids include possible:

1) Detrimental effect should fungal[6] or viral[10] infection be present.
2) Recurrence of pseudomonas infection.[11,12]
3) Prolonged replication of organisms and delayed wound healing[5]

Supporting the use of steroids is the experimental evidence that pseudomonas[2,3] and *S.aureus*[4] keratitis are not adversely affected by steroid use so long as the appropriate antibiotic is used. There are also clinical reports of the use of steroid in bacterial keratitis[7,8]. Wilson[13] mentions that topical steroids were used "in some but not all" of the 200 bacterial corneal ulcers he treated over a 10 year period.

In the present study the two groups were similar in most respects and the preponderance of males in the steroid group should not cause undue bias. The ulcers within each group were also comparable although the ulcer rates differed somewhat. Obviously the larger the groups, the greater the chance that one can collect totally comparable groups.

Benefits or adverse effects of using steroids were assessed in the most objective ways possible under the circumstances. Complications within the two groups were remarkably similar and the feared perforations and corneal thinning in the steroid treated group did not materialise.

Severe infections may recur, and this was seen with a pneumococcal ulcer in the steroid group. Recurrence of infection was otherwise associated with conditions causing persistent epithelial defects. As previously reported[14], the severe nodular form of climatic droplet keratopathy is a common predisposing factor for corneal ulceration in this population. The plaques flake off leaving epithelial defects which are slow to heal and become reinfected.

Patterson and Jones[10] reported using area of ulcers as a means of assessing the negative effects of topical steroids on dendritic keratitis. If accurate measurements are taken at the slit-lamp and the ulcers are carefully drawn to scale on to graph paper, group comparison is possible and any inaccuracies should tend to cancel out. During the present study the method was found to be consistent and it provides another means of assessment.

No delay in heal rates was seen with the dosage of steroid used. If corneal inflammation and scarring can be reduced by the concurrent use of topical steroids, it should be possible to show an improvement in visual acuity. Two methods of comparing the visual acuities were used, but neither showed a difference between the groups. When visions were converted to a numerical quantity, a statistically significant improvement in vision was seen in both groups following treatment, but the steroid group did not do significantly better . Scattergrams with linear regression lines showed very similar visual improvements in the two groups. The correlation coefficients were not particularly high, and this should be taken into account when interpreting the scattergram.

6.5 Conclusions

No adverse effects were encountered when using topical steroids in the dosage shown above. In order to demonstrate benefits from using steroids a larger study would be needed and perhaps some refinements in assessment techniques.

It is suggested that steroid treatment should be delayed for 24 hours to exclude rapidly deteriorating infections, allow appropriate selection of antibiotic, and exclude as many of the fungal infections as possible. It would seem prudent to reduce or discontinue steroid treatment if delayed healing is encountered. Special care should be exercised when dealing with *Streptococcus pneumoniae* and *Pseudomonas aeruginosa* infections as they can become active again after an initial positive response to antibiotics.

A large prospective study is needed, perhaps on a multicentric basis, to collect enough similar cases for meaningful analysis. Different steroid doses need to be assessed to optimise our approach. Complications within a steroid treated group of patients must be accepted as the present study clearly confirms that complications will occur with and without steroid treatment.

6.6 References

1. Gordon DM, Mclean JM,Koteen H. Present status of corticotropin (A.C.T.H.), cortisone, and hydrocortisone in ophthalmology. *Br J ophthalmol* 1953; 37: 85-98.
2. Suie T, Taylor FW. The effect of cortisone on experimental pseudomonas corneal ulcers. *Arch Ophthalmol* 1956; 56: 53-6.
3. Davis SD, Sarff LD, Hyndiuk RA. Corticosteroid in experimentally induced pseudomonas keratitis. *Arch Ophthalmol* 1978; 96: 126-8.
4. Leibowitz HM, Kupferman A. Topically administered corticosteroids: effect on antibiotic-treated bacterial keratitis. *Arch Ophthalmol* 1980; 98: 1287-90.
5. Smolin G, Okumoto M, Leong-Sit L. Combined gentamicin-tobramycin-corticosteroid treatment. ii. Effect on gentamicin-resistant pseudomonas keratitis. *Arch Ophthalmol* 1980; 98: 473-4.
6. O'Day DM, Ray WA, Robinson R, Head WS. Efficacy of antifungal agents in the cornea. ii. Influence of corticosteroids. *Invest Ophthalmol Vis Sci* 1984; 25: 331-5.

7. Aronson SR, Moore TE Jr. Corticosteroid therapy in central stromal keratitis. *Am J Ophthalmol* 1969; 67: 873-96.

8. Aronson SB, Moore TE Jr. Corticosteroids in infectious corneal disease. In: Leopold IH, ed. *Symposium on Ocular Therapy*. St Louis: Mosby, 1972; 5: 77-89.

9. Carmichael TR, Wolpert M, Koornhof HJ. Corneal ulceration at an urban African hospital. *Br J Ophthalmol* 1985; 69: 920-6.

10. Patterson A, Jones B. The management of ocular herpes. *Trans Opthal Soc UK* 1967; 87: 59-83.

11. Theodore FH. Points in the treatment of bacterial corneal ulcers. In: Leopold IH, ed. *Symposium on ocular therapy*. St Louis: Mosby, 1972; 5: 48-55.

12. Burns RP. *Pseudomonas aeruginosa* keratitis: mixed infections of the eye. *Am J Ophthalmol* 1969; 67: 257-62.

13. Wilson LA. Acute bacterial infection of the eye: bacterial keratitis and endophthalmitis. *Trans Opthal Soc UK* 1986; 105: 43-60.

14. Di Bisceglie AM, Carmichael TR. Factors predisposing to central corneal ulceration in a developing population. *S Afr Med J*. 1987; 71: 769-770.

7.0 Conclusion

Corneal ulceration was an important cause of visual loss in the urban African in Johannesburg. The series of patients reported from St John Eye Hospital in 1985[1] was the largest prospective study of corneal ulcers reported by the end of 1990. In January 1991 a larger prospective series of 405 patients treated over a two-year period was reported from Nepal[2].

At St John Eye Hospital (St John), the largest problem area in terms of numbers and complications was central bacterial ulcers (Chapter 2). Marginal catarrhal ulcers were numerically the next most common but showed fewer complications and better visual outcome. These two groups accounted for 64% of the ulcers seen during the one year survey at St John Eye Hospital.

Bilateral corneal ulcers were uncommon and only seven of the 273 patients (2,6%) at St John showed bilateral ulcers. There was a modest increase in infective (central) ulcers seen during the winter months and this was mainly due to an increase in central bacterial ulcers.

The main type of ulcer seen in the white patient was central viral ulcers (dendritic) and this accounted for 85% of the total number in that group. Severe bacterial corneal ulceration in whites was uncommonly seen. Ethnic or racial grouping did not otherwise appear to be an important factor except for mixed races (coloureds) showing more than expected viral (mostly dendritic) keratitis and possibly Zulus more marginal catarrhal ulceration.

At St John Eye Hospital, the risk of developing central corneal ulceration (incidence rate) increased after age 30 years in a fairly linear fashion, although the under ten year age group showed fairly large numbers with corneal ulcers. For marginal ulcers, the 25-64 year age group was at highest risk.

Males predominated in most groups at St John and this was most apparent in the central bacterial ulcers where 85% were male. Overall, 78% were male and the male to female ratio for most groups was fairly constant. The higher risk of corneal ulcer in males was partly due to work exposure and possibly males are more likely to present for treatment in this population. Half the St John patients were manual labourers and a quarter

unemployed and 90% were of urban origin. In Nepal where 95% of males and females were involved in the production of rice[2], equal numbers of males and females presented with corneal ulcers.

The overall delay in presentation for treatment at St John was 16 days but acute central ulcers (bacterial and viral) with early vision loss showed shorter delays while marginal ulcers with good initial vision presented later.

At St John, corneal ulcer patients required an overall average of 14 days of inpatient treatment.

Although bilateral ulceration was uncommon, there was often pathology in the fellow eye. One third of the admitted patients at St John had a vision of 6/24 or worse in the fellow eye and more than half of fellow eyes showed pathology.

It was of interest that at the Johannesburg Hospital one third of admitted patients also showed abnormalities in the fellow eye although the numbers seen were too small to generalise.

Taking population sizes and alternative treatment options into account, blacks appear to have a two to four times greater chance of developing corneal ulceration than whites. The reasons underlying this susceptibility are varied but local factors were found in 77% of the admitted patients at St John Eye Hospital (Chapter 3). Trauma, climatic droplet keratopathy and corneal scarring were the most important. Corneal trauma was more important in younger patients and the mean age was 29 years in patients with this predisposing factor.

Of the general factors, underlying malnutrition and alcohol abuse were the most prominent in central corneal ulcers at St John Eye Hospital. About one third of the adult central corneal ulcer patients were malnourished according to the criteria for individual patients. Twenty-four percent of the adult central ulcer patients had evidence of alcohol abuse (two or three factors present). It is possible that with the shift to urbanisation and increased consumption of malt beer, wine and spirits, rather than the traditional sorghum beer, that alcohol abuse might become more prevalent in the African.

Chronic blepharitis/meibomitis was seen in association with 40% of the admitted marginal catarrhal patients. Rheumatoid disease was the commonest established cause of marginal

ring ulcers. There was a relationship between alcohol consumption and the risk of being sero-positive for syphilis but this was true of all ulcers and there was no obvious relationship between positive syphilis serology and marginal corneal ulceration.

Pretreatment with antibiotics was found in 45% of the central ulcers and 47% of the marginal ulcers and more than 2/3rds of each group had received some form of treatment before presentation. This has been confirmed in subsequent studies where half the patients were pretreated with antibiotics. This initial treatment is sometimes not effective and results in a delay of definitive therapy and difficulty in isolation of the responsible organism.

Fungal keratitis was uncommonly seen in all race groups in Johannesburg and this is likely to be due to a combination of work factors and climate [4]. In Nepal, where half the 405 patients were farmers, 68 positive fungal isolates were obtained[2].

At St John Eye Hospital, corneal isolates were obtained in 62 of the 91 eyes (67%) with central bacterial ulcers (Chapter 4). *Streptococcus pneumoniae* was the commonest isolate and accounted for 42% of significant bacterial isolates. This organism had been replaced in recent years by *Staphylococcus aureus* as the most important cause of central corneal ulceration[5,6,7] but since 1985 there have been several studies showing the pneumococcus to be the main problem in developing counties[1,3,6]. At St John Eye Hospital single Gram positive isolates were found in 30% of the central ulcers while single Gram negative isolates were recovered in 15%. Forty percent of the central ulcers showed no growth or insignificant isolates (Classes 4 and 5). Pretreatment with antibiotics was found to be partially responsible as the association between negative cultures and antibiotic pretreatment was statistically significant.

The association between hypopyon formation or significant anterior chamber activity (two plus cells or greater) and endothelial plaque formation was statistically significant. These factors were also associated with the significant (Classes 1-3) isolation of bacteria but not in a statistically significant way perhaps due to antibiotic pretreatment.

Clinical features of central ulcers and isolates varied according to the predisposing factor. In general, *S. pneumoniae* was the commonest isolate in all groups but *Pseudomonas aeruginosa* was associated with trauma and malnutrition while *Moraxella spp.* and *Proteus mirabilis* were associated with alcohol abuse. *Corynebacterium spp.* were

associated with cases of climatic droplet keratopathy.

Complications (descemetocoeles and perforations) were mainly seen in association with *S. pneumoniae* and *P. aeruginosa*.

Direct smears were significantly more helpful in central ulcers than marginal ulcers. The smear results showed that if an organism was seen on the smear it was likely to be the causative organism whereas if no organism was seen, there was still a 50% chance of the organism being cultured.

The class system of placing laboratory findings in different categories was to assess the relevance of microbial isolates and to exclude effectively contaminant bacteria and fungi. The first three classes proposed by Jones[9] were used to define significant isolates. Classes 4 and 5 were added and these helped to differentiate tear film contaminants and also indicated possible etiological agents when corneal cultures were negative.

In the management of corneal ulcers fixed treatment regimens were followed (Chapter 5). Using these regimens, the results of treatment of the mild and moderate groups of bacterial ulcers was good in three quarters of cases. In the remainder, complications were usually related to slow indolent healing. This poor healing was seen in relation to malnutrition and climatic droplet keratopathy. In the moderate group a statistically significant visual improvement was seen following treatment. In the severe ulcers and those showing perforations or descemetocoeles on admission (pressure padded groups), no statistically significant visual improvement was seen. In the severe group, one in three eyes was lost and only three of the sixteen eyes achieved Snellen chart acuity after treatment. In this group half of the infections were caused by *S. pneumoniae* and a quarter by *P. aeruginosa*. Currently, the use of a cephalosporin or bacitracin against Gram-positive organisms and gentamicin or tobramycin against Gram-negative organisms is recommended[10].

Good results in the treatment of fungal keratitis were obtained in all but one of the eight cases reported in Chapter 5. The two antifungals used were miconazole and/or natamycin with ketoconazole being used as an adjunct.

During the steroid study at St John Eye Hospital (Chapter 6), attention was paid to methods of assessing the results of treatment. Results were assessed in terms of

complications, healing rate (mm^2 of ulcer per day), and visual acuity. An improvement in visual acuity was considered the main objective and visual acuity was converted to a number using a simple ranking system which allowed statistical comparison between the study groups and other groups. A scattergram technique with linear regression lines was also used which provides a graphical display of the visual result. The numerical equivalent visions and the Student *t* test will show whether the difference between two groups on a scattergram is significant.

Neither method could show a significant difference in visual outcome when topical steroid was used. Complications in the two groups were similar and healing rates did not appear retarded by the use of steroid in this dosage.

It is suggested that steroid treatment should be delayed for 24 hours to exclude rapidly deteriorating infections as provisional culture results should be available by this time. Special care should be exercised in treating *Streptococcus pneumoniae* and *Pseudomonas aeruginosa* infections with topical steroids as these infections can be difficult to control. Fungal and viral conditions should be excluded as far as possible and an appropriate antibiotic selected. If delayed healing or corneal thinning are encountered, steroid treatment can be reduced or discontinued.

The numerical equivalent system for statistically comparing visions appeared satisfactory in that similar types of ulcers produced similar results. The visions in the steroid and non-steroid groups (Chapter 6) were better, both before and after treatment, than the visions in the group of central bacterial ulcers of moderate severity (Chapter 5) but this was not statistically significant with the numbers analyzed.

Some modification in approach to management must be made according to circumstances[11] and some principles in management of suppurative corneal ulcers in a developing population might be:

1. Correct and timeous referral of problem corneal ulcers by primary health care workers, and improved education of these groups would probably assist in achieving this goal.
2. Rapid diagnosis in hospital using direct smears and multiple corneal cultures in order to determine the significance and antimicrobial sensitivity of isolates.
3. Recognition and management of local and general predisposing factors like

climatic droplet keratopathy and malnutrition, to try and facilitate healing and prevent recurrence of the ulcer.

4. Broad spectrum antibiotics used both as fortified eye-drops and injected subconjunctivally. Intravenous antibiotics should possibly be reserved for the indications as outlined in Chapter 5 because of the cost involved.
5. Topical steroid drops might be considered once the infective element has been controlled, although the benefits seem marginal. The use of topical steroids must be carefully controlled and should probably not be attempted as an outpatient in this population because of the difficulty of follow-up.
6. The emphasis should be on returning the patient to his work as quickly as possible and penetrating keratoplasty might be postponed where possible to be done as a secondary procedure in reasonable prognosis cases.

Since this thesis was begun a decade ago there has been major social and political change in South Africa. Some of the changes have been for the better but the situation of academic medicine has not improved.

In the "new" South Africa that will develop over the next decade it seems as if major effort will have to be applied to maintain acceptable academic standards in the face of economic cutbacks.

In South Africa, we occupy a unique position on the fringes of first and third world medicine. Many opportunities exist for clinical research and we must continue to contribute as best we can even under the difficult conditions which we face.

7.1 References

1. Carmichael TR, Wolpert M, Koornhof HJ. Corneal ulceration at an urban afri an hospital. *Br J Ophthalmol* 1985 ;69 :920-6.
2. Upadhyay MP, Karmacharya PCD, Koirala S, Tuladhar NR, Bryan LE, Smolin G, Whitcher JP. Epidemiologic characteristics, predisposing factors, and etiologic diagnosis of corneal ulceration in Nepal. *Am J Ophthalmol* 1991; 111: 92-9.
3. Maske R, Hill JC, Oliver SP. Management of bacterial corneal ulcers. *Br J Ophthalmol* 1986; 70: 199-201.
4. Liesegang TJ, Forster RK. Spectrum of microbial keratitis in South Florida. *Am J Ophthalmol* 1980; 90: 38-47.

5. Asbell P, Stenson S. Ulcerative keratitis-survey of thirty years' laboratory experience. *Arch Ophthalmol* 1982; 100: 77-80.

6. Coster DJ, Badenoch PR. Host, microbial, and pharmacological factors affecting the outcome of suppurative keratitis. *Br J Ophthalmol* 1987; 71: 96-101.

7. Chaudhuri PR, Godfrey B. Treatment of bacterial corneal ulcers with concentrated antibiotic eye drops. *Trans Ophthalmol Soc UK* 1982; 102: 11-4.

8. Panhalkar S, Thomas A, Alexander TA, Koshi G. Bacterial and mycotic agents of corneal ulcers in Vellore. *Ind. J. Ophthalmol* 1985; 33: 289-93.

9. Jones DB. Initial therapy of suspected microbial corneal ulcers. II. Specific antibiotic therapy based on corneal smears. *Surv Ophthalmol* 1979; 24: 105-16.

10. van Bijsterveld OP, van Hemel OLH. Bacterial conjunctivitis and keratitis. *Current Opinion in Ophthalmology* 1990; 1: 323-32.

11. Ormerod LD. Causation and management of microbial keratitis in subtropical Africa. *Ophthalmology (Rochester)* 1987; 94: 1662-8.

Author: Carmichael, T.R.
Name of thesis: Ulcerative Keratitis in the South African black with particular emphasis on the Management of Suppurative

PUBLISHER:
University of the Witwatersrand, Johannesburg
©2015

LEGALNOTICES:

Copyright Notice: All materials on the University of the Witwatersrand, Johannesburg Library website are protected by South African copyright law and may not be distributed, transmitted, displayed or otherwise published in any format, without the prior written permission of the copyright owner.

Disclaimer and Terms of Use: Provided that you maintain all copyright and other notices contained therein, you may download material (one machine readable copy and one print copy per page)for your personal and/or educational non-commercial use only.

The University of the Witwatersrand, Johannesburg, is not responsible for any errors or omissions and excludes any and all liability for any errors in or omissions from the information on the Library website.