

# **THE OUTCOMES OF RADIAL HEAD REPLACEMENT IN MASON TYPE III And IV RADIAL HEAD FRACTURES**

---

A Retrospective Review

**Dr Muhammad Naadir Bismilla**

A research report submitted to the Faculty of Health Sciences, University of  
the Witwatersrand, in partial fulfillment of the requirements for the degree of

Master of Medicine in the branch of Orthopaedic Surgery

Johannesburg

31 January 2017

<b>DECLARATION</b>	<b>6</b>
<b>ABSTRACT</b>	<b>7</b>
<i>Background</i>	7
<i>Objectives</i>	7
<i>Method</i>	7
<i>Results</i>	7
<i>Conclusions</i>	8
<b>ACKNOWLEDGEMENTS</b>	<b>9</b>
<b>LIST OF TABLES</b>	<b>10</b>
<b>NOMENCLATURE</b>	<b>11</b>
<b>TERMINOLOGY</b>	<b>11</b>
<b>Chapter 1 : OVERVIEW OF THE STUDY</b>	<b>13</b>
<i>1.1 Introduction</i>	13
<i>1.2 Background</i>	13
<i>1.3 Research Focus</i>	13
<i>1.4 Overall Research Aim and Individual Research Objectives</i>	14
1.4.1 Aim	14
1.4.2 Objectives	14
<i>1.5 Ethical Considerations</i>	14
<i>1.8 Methodology</i>	14
1.8.1 Study Design	14
1.8.2 Study Population	15
1.8.3 Study Sample	15
1.8.4 Data Collection	16
<i>1.9 Significance of the Study</i>	16
<i>1.10 Validity and Reliability Summary</i>	16
<i>1.11 Report Outline</i>	17
<i>1.10 Summary</i>	17
<b>Chapter 2 : LITERATURE REVIEW</b>	<b>17</b>
<i>2.1 Introduction</i>	17
<i>2.2 Background</i>	18
2.3.1 Functional Anatomy	18
2.3.2 Stability of the Elbow Joint	20
<i>2.4 Classification of Elbow Fractures</i>	21
2.5 Associated injuries	22

<b>2.6 Current Management of Elbow Fractures</b>	<b>23</b>
2.6.1 Radial Head Resection	24
2.6.2 Open Reduction Internal Fixation of Elbow Fractures	25
2.6.3 Radial Head replacement	26
2.7 ORIF versus Replacement of the Radial Head	29
<b>2.9 The Mayo Elbow Score</b>	<b>30</b>
<b>2.10 Summary</b>	<b>30</b>
<b>Chapter 3: RESEARCH DESIGN AND METHODOLOGY</b>	<b>31</b>
<b>3.1 Introduction</b>	<b>31</b>
<b>3.2 Problem Statement</b>	<b>31</b>
<b>3.3 Aim and Objectives</b>	<b>31</b>
3.3.1 Aim	31
3.3.2 Objectives	32
<b>3.4 Ethical Considerations</b>	<b>32</b>
<b>3.5 Research Methodology</b>	<b>33</b>
3.5.1 Study Design	33
3.5.2 Study population	33
3.5.3 Study Sample	34
3.5.4 Data Collection	35
3.5.5 Data Analysis	37
<b>3.6 Validity and reliability</b>	<b>38</b>
<b>3.7 Summary</b>	<b>38</b>
<b>Chapter 4: RESULTS AND DISCUSSION</b>	<b>38</b>
<b>4.1 Introduction</b>	<b>38</b>
<b>4.2 Results</b>	<b>39</b>
4.2.1 Sample Realization	39
4.2.2 Objective 1: Demographics	39
4.2.3 Objective 2 and 3: Details of injury and length of follow up	40
4.2.4 Objective 4: Assessment of elbow function	41
4.2.5 Objective 5: Assessment of pain post-arthroplasty	42
4.2.6 Objective 6: Assessment of mobility post-arthroplasty	43
4.2.7 Objective 7: Assessment of joint stability	44
4.2.8 Objective 8: Complications post-radial head replacement	45
4.2.9 Consolidated MEPS Data Table	46
<b>4.3 Discussion</b>	<b>47</b>
<b>4.4 Summary</b>	<b>50</b>
<b>Chapter 5: CONCLUSIONS AND RECOMMENDATIONS</b>	<b>51</b>
<b>REFERENCE LIST</b>	<b>51</b>
<b>Appendices</b>	<b>55</b>

<b><i>Appendix 1: PERMISSION FROM POSTGRADUATE COMMITTEE</i></b>	<b>55</b>
<b><i>Appendix 2 :PERMISSION FROM ETHICS COMMITTEE</i></b>	<b>56</b>
<b><i>Appendix 3: PATIENT INFORMATION SHEET</i></b>	<b>57</b>
<b><i>Appendix 4: DATA COLLECTION SHEET</i></b>	<b>58</b>
<b>Appendix 5: Mayo Elbow Performance Score</b>	<b>59</b>

# DECLARATION

I, Muhammad Naadir Bismilla, declare that this research report is my own work. It is being submitted for the degree of Master of Medicine in the branch of Orthopaedic Surgery at the University of the Witwatersrand, Johannesburg. It has not been submitted before for any degree or examination at this or any other university.

.....

31st day of January 2017.

# **ABSTRACT**

## **Background**

Fractures of the radial head are classified according to the Mason System modified by Johnston. The fracture is managed according to its classification. Fractures of the Mason Type III and IV are complex and management is controversial. The early literature regarding the outcome of patients after arthroplasty of fracture dislocation of the elbow is limited by small patient numbers, short-term follow-up, and high complication rates. More recent literature has shown radial head replacement to have better functional outcomes in the short to medium term.

## **Objectives**

To assess outcomes of radial head replacements in acute 3 and 4 radial head fractures by assessing elbow function, pain, elbow mobility post radial head arthroplasty and complications.

## **Method**

A retrospective study design was used. Records were retrieved for all 40 patients who underwent a radial head replacement for a Mason III and IV fracture at Helen Joseph Hospital over a ten year period. Participants were traced and asked to complete a data sheet and undergo an examination by an interviewer. The data sheet included demographics, surgical and injury details, as well as details relating to function based on the Mayo Elbow Performance Score.

## **Results**

Of a sample size n=16, 8 were male and 8 were female with an age range of 29 to 61 years and a mean age of 42.5 years. The length of follow up ranged from 2 to 8 years.

When asked about daily functionality, 4 reported difficulty with one of the five tasks assessed on the Mayo Elbow Performance Score and 12 reported no difficulty with any of the tasks assessed. Moderate pain was reported by 8 with the other 8 patients reporting no pain. The flexion-extension arc ranged from 60° to 160° on examination with an average of 111°. An arc of greater than 100° was achieved in 11 out of 16 patients. A total of five patients had an arc of greater than 50° but less than 100. No patients had an arc less than 50°. Stability was assessed and scored. No study participants had any gross instability. Moderate instability was detected in 6 participants. Complications were noted in 2 of the 16 participants (One posterior interosseus nerve injury and one possible Essex-Lopresti injury). The final MEPS scores showed that 8 patients had good results and 8 patients had excellent functional outcomes with no fair or poor outcomes.

## **Conclusions**

Good to excellent functional outcomes can be achieved with radial head replacement in Mason III and IV fractures with minimal complications however, longer term follow up with level one evidence is still needed.



# ACKNOWLEDGEMENTS

My thanks go to the following people:

To my supervisors, Professor Aden and Tatolo Sefeane for their support, guidance, and patience.

A special thanks to Dr Taimeia Hussain and Dr Allan Seiketto who helped with collection of articles for literature review and for conducting the data collection.

Thanks also to Professor Bischof and Dr Brenda Milner for all the valuable input and evaluating and overseeing the MMed project.

## LIST OF TABLES

Table 3.1: MEPS - Elbow Function Questions	36
Table 4.1 Details of patient demographics of all study participants.	40
Table 4.2 : Patients' Injury and Surgery Details	41
Table 4.3: MEPS Function Score	42
Table 4.4: Grading of Pain Severity	42
Table 4.5: Mobility of the elbow and Range of Movement scores	43
Table 4.6: MEPS Range of movement score	44
Table 4.7: Elbow Stability Scores	45
Table 4.8: Patient Complications	45
Table 4.9: Mayo Elbow Performance Score	46

# NOMENCLATURE

LCL- Lateral collateral ligament

MCL- Medial collateral ligament

MEPS - Mayo Elbow Performance Score

ORIF - Open reduction and internal fixation

TFCC - Triangular Fibrocartilage Complex

## TERMINOLOGY

Arthroplasty	The operative formation or restoration of a joint
Capitellum	A knoblike protuberance situated at the end of the humerus, laterally
Comminuted	Being a fracture in which the bone is splintered or crushed into numerous pieces
Complication	Refers to any adverse effect, with or without reoperation
Coronoid	Flared process at the anterior part of the upper ulna, fitting into the coronoid fossa of the humerus when arm is bent
Distal	Situated away from the point of attachment or origin or a central point e.g. a part located away from the center of the body
Humerus	Long bone extending from the shoulder to the elbow
Implant failure	Refers to a mechanical failure eg. screws pullout, bent plate, broken plate or other implant-related problem with or without exchange of implant with or without bone graft.
Interosseus membrane	Membrane found spanning between the radius and ulna along their longitudinal margins
Ipsilateral	Situated or appearing on or affecting the same side of the body
Lateral	Outer most border
Lateral Collateral Ligament	Stabilising ligament found along the outermost edges of the elbow joint connecting the humerus to the forearm bones
Longitudinal	Lengthwise

Medial	Lying or extending toward the median axis of the body
Non-union	Failure of the fragments of a broken bone to knit together
Osteoarthritis	Arthritis that is characterized by degenerative changes in the bone and cartilage of joints and a progressive wearing down of apposing joint surfaces with consequent distortion of joint position
Osteopaenia	Reduction in bone volume to below normal levels especially due to inadequate replacement of bone lost to normal breakdown
Pronate	Rotation of an anatomical part towards the midline e.g. rotation of the hand and forearm so that the palm faces backwards or downwards
Proximal	Situated next to or near the point of attachment or origin or a central point
Radius	The bone on the thumb side of the human forearm
Radial Head	The proximal part of the radius, cylindrical in form
Radiocapitellar Articulation	The joint between the head of the radius and the capitellum of the humerus
Revision	Refers to any local surgical procedure, with or without retrieval of the implants
Subchondral	Situated beneath cartilage
Terrible Triad Injury	Posterolateral dislocation of ulna humeral joint, radial head fracture, coronoid fracture
Trabeculae	Intersecting osseous (bony) bars occurring in cancellous bone
Ulna	The bone on the little-finger side of the forearm.
Ulnohumeral Joint	Joint between the ulna and the humerus
Valgus	Turned outward

# Chapter 1 : OVERVIEW OF THE STUDY

## 1.1 Introduction

Fractures of the radial head and neck account for 1.5-4% of all fractures. These fractures can be associated with dislocation of the elbow joint and injury to the medial and lateral collateral ligaments. <sup>1</sup>

## 1.2 Background

Fractures of the radial head are classified according to the Mason Classification modified by Johnston. The fracture is managed according to its classification. <sup>2</sup>

Fractures of the Mason Type III and IV are complex and management is controversial.

<sup>3</sup>

The early literature regarding the outcome of patients after arthroplasty of fracture dislocation of the elbow is limited by small patient numbers, short-term follow-up, and high complication rates.<sup>20</sup> More recent literature has shown radial head replacement to have better functional outcomes in short to medium term. <sup>20</sup>

## 1.3 Research Focus

This study focused on the follow up of participants who have undergone arthroplasty for radial head fractures in Mason III and IV radial head fractures. Participants had completed questionnaires and undergone a physical examination providing researchers with information regarding functionality, pain and mobility post radial head replacement.

## **1.4 Overall Research Aim and Individual Research Objectives**

### **1.4.1 Aim**

To determine the outcomes of radial head replacement in acute Mason III and IV radial head fractures in adults.

### **1.4.2 Objectives**

To assess outcomes of radial head replacements in acute Mason III and IV radial head fractures by assessing elbow function, pain and elbow mobility post radial head arthroplasty.

To assess complications of radial head replacement such as injury to the posterior interosseus nerve.

## **1.5 Ethical Considerations**

Approval to conduct the study was obtained from the Postgraduate Committee and the Human Research Ethics Committee (Medical) (HREC) of the University of the Witwatersrand (see Appendix 2).

## **1.8 Methodology**

### **1.8.1 Study Design**

A retrospective study design was used. Orthopaedic records were reviewed in patients at least 12 months post-surgery. Information from records regarding patient demographics and surgical procedures were recorded on a demographic and

surgery form. Participants were contacted for permission to view files as well as to complete a questionnaire and physical examination. The questionnaire and examination was based on the Mayo Performance elbow score.

### **1.8.2 Study Population**

All patients who had acute Mason Type III and IV radial head fractures, and were treated with radial head replacements by multiple surgeons at Helen Joseph Hospital between 2001 and 2013, were included in the study.

### **1.8.3 Study Sample**

#### **1.8.3.1 Sample Size**

Hospital files were pulled out for all patients treated with a radial head replacement from 2001 to end 2013. (Patients were all treated with the same implant by the same company). Some patient details were provided by the company as well. The sample size was 40 patients using both sources. Attempts were made to contact all patients telephonically to arrange an interview.

#### **1.8.3.2 Inclusion and Exclusion Criteria**

Patients with radial head replacements in Mason Type III and IV radial head fractures were included in the study, provided that consent was given. Participants with missing and incomplete records, as well as patients with missing radiographic imaging, were excluded from the study. Furthermore, patients who could not be contacted for an interview and to complete a questionnaire were also excluded from the study.

#### **1.8.4 Data Collection**

Data was collected once ethical clearance and permission from the hospital CEO to conduct research was obtained (see Appendix 3). The data was collected from hospital records and interviews, and examinations were conducted with participants by appointment. Prior to developing the Data Sheets, a review of the literature was done to identify possible important demographic factors. The Mayo Elbow Score, which is a validated elbow score, was found to be the most useful method in assessing functional outcomes.

#### **1.9 Significance of the Study**

There are various options for the surgical management of Mason Type III and IV radial head fractures and management of these fractures are controversial. Early literature is limited by small patient numbers, short-term follow-up and high complication rates.<sup>20</sup> Recent literature has shown radial head replacement to have better functional outcomes in short-term however, there are few long-term follow up studies.<sup>20</sup> This study will provide information as to the long and medium term functional outcomes of such procedures and may further be used to assist with the clinical care of patients with Mason III and IV injuries.

#### **1.10 Validity and Reliability Summary**

The validity and reliability of this study and of the data collection was ensured by the following:

- A sample size of patients similar to that of the current literature.



- The use of the Mayo Elbow score to assess function. This score has been shown in numerous studies to be a good predictor of elbow function.
- Short, concise data collection sheet

### **1.11 Report Outline**

The report is set out as follows : Chapter one presents an overview; chapter two reviews current relevant literature; chapter three covers the research methodology in more detail; chapter four presents the results and discussion; chapter five summarises the study, addresses the limitations, makes recommendations and presents the final conclusion.

### **1.10 Summary**

In this chapter the following was addressed: a background to the study; the aim and objectives; ethical considerations; a summary of the methodology; the significance of the study; and the validity and reliability of the study. The next chapter comprises a review of the current relevant literature.

## **Chapter 2 : LITERATURE REVIEW**

### **2.1 Introduction**

This chapter deals with the background of radial head fractures, the anatomy of the elbow joint, commonly associated injuries with this type of fracture, the classification system used to direct management, details of the current management options used to treat radial head fractures (radial head resection, open reduction and internal

fixation of the radial head, and radial head replacement) and the Mayo Elbow Performance Score which is used to assess elbow function.

## **2.2 Background**

Fractures of the radial head and neck account for 1.5 - 4 % of all fractures. A radial head fracture usually results from a fall on an outstretched arm with the forearm in a position of pronation and flexion. The radial head is fractured as it absorbs the indirect force of the fall and impacts on the capitellum of the humerus. These fractures are usually associated with dislocation of the elbow joint and injury to the medial (ulnar) and lateral (radial) collateral ligaments (MCL and LCL). <sup>1</sup>

Fractures of the radial head are classified according to the Mason System modified by Johnston. The fracture is managed according to its classification.<sup>2</sup> Fractures of the Mason Type III and IV are complex and management is controversial.<sup>3</sup>

The early literature regarding the outcome of patients after arthroplasty of fracture dislocation of the elbow is limited by small patient numbers, short-term follow-up, and high complication rates. <sup>25</sup> More recent literature has shown radial head replacement to have better functional outcomes in short to medium term. There are limited long term follow up studies.<sup>20</sup>

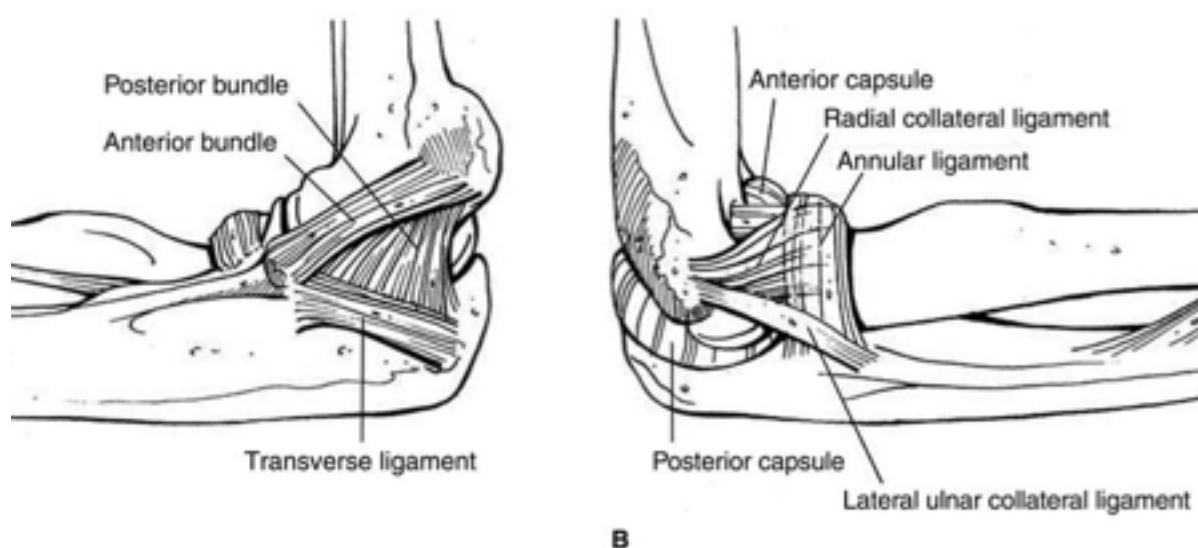
### **2.3.1 Functional Anatomy**

The elbow joint has a unique orientation and configuration. There are three bones, the ulna, radius, and humerus. At the distal end of the humerus, the capitellum

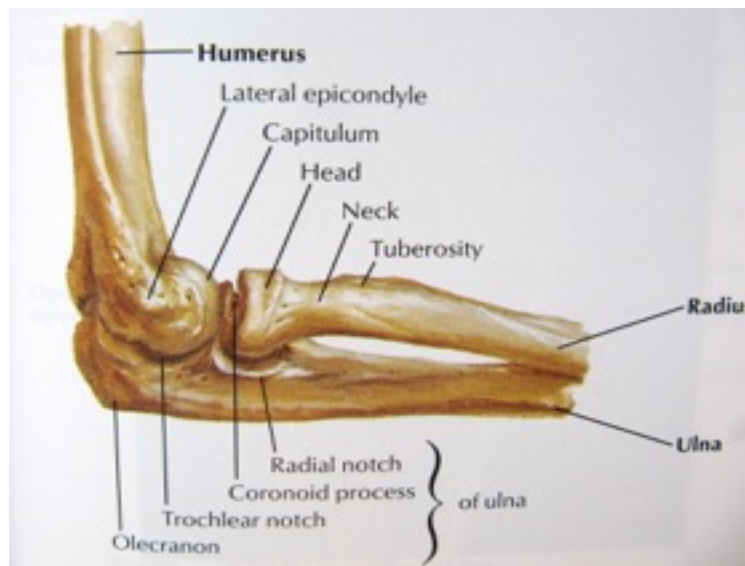
articulates with the elliptical radial head to form the humero-radial joint (see figure 2.1). The radial head is offset from the radial neck. It is encircled by cartilage for about 240 degrees of the margin of the head. The olecranon of the ulna is received into the olecranon fossa of the humerus and the trochlea of the humerus articulates with the sigmoid notch of the olecranon to form the humero-ulnar joint. This joint is highly congruous and is hinge-like. <sup>4</sup>

The articulations provide the elbow with strong static stabilization. These articulations are reinforced by the annular ligament, the lateral ulnar collateral ligament complex, the medial collateral ligament(mcl) and the elbow joint capsule (see Figure 2.2). There are 23 muscles that are directly associated with the elbow. The grouping of the muscles is as follows; the elbow flexors and extensors and the flexor-pronator and extensor-supinator groups. <sup>4</sup>

*Figure 2.1: Bony Anatomy of Elbow, Lateral View* <sup>5</sup>



*Figure 2.2: Ligamentous Anatomy of the Elbow, Medial and Lateral Views* <sup>6</sup>



### **2.3.2 Stability of the Elbow Joint**

The radial head, elbow ligaments and interosseus membrane are vital in maintaining the stability of the elbow joint. The radial head in isolation is responsible for both longitudinal and valgus stability. Histologically, the radial head has longitudinally oriented trabeculae situated deep to the subchondral bone. These trabeculae confirm the load-bearing role of the radial head. <sup>4</sup>

Proximally, migration of the radius is prevented by the radiocapitellar joint.<sup>1,7</sup> If the radial head has been excised, the interosseus membrane then contributes to 71% of the longitudinal stiffness. The triangular fibrocartilage (TFCC) provides an additional 8% of the resistance to proximal radial migration. <sup>8</sup> If the interosseous membrane or TFCC is injured, then the radio-capitellar articulation must be reconstructed to prevent proximal radial migration.<sup>1</sup>

The radial head transmits 60% of load to the humerus. In the absence of a radial head, 100% of the forces is transmitted through the ulno-humeral joint predisposing the elbow joint to secondary osteoarthritis in the future. <sup>9</sup>

The anterior band of the MCL is the primary stabilizer of the elbow to valgus stress, and the radial head is the secondary stabilizer. When studying the effect of radial head excision on valgus stability of the elbow, it has been shown that radial head arthroplasty restores valgus stability to elbows that have deficient MCLs. The degree of stability is similar to that of elbows with a native intact head. <sup>8</sup>

The ulnar band of the LCL and the radial head work together to promote posterolateral stability. The radial head maintains the necessary tension in the LCL, which in turn prevents instability in the radiocapitellar joint and the ulno - humeral joint. <sup>8</sup>

## 2.4 Classification of Elbow Fractures

Radial head fractures are classified using a system by Mason, modified by Johnson as explained in the following table. <sup>2</sup>

**Table 2.1: Mason classification of radial head fractures, modified by Johnson**

Mason classification of Radial head and Neck fractures	
I	Non-displaced
II	Displaced fractures > 2mm or involving 30 % of articulating surface or being depressed or impacted
III	Comminuted and displaced, involving entire radial head
IV	Radial head fractures associated with ipsilateral ulnohumeral dislocation

Hotchkiss' modification of Mason's classification directly reflects current treatment options. This is shown in the table below. <sup>10</sup>

**Table 2.2: Hotchkiss' modification of Mason's classification** <sup>10</sup>

Hotchkiss' modification of Mason's classification		
Class	Definition	Treatment
<b>Type I</b>	Non-displaced or mildly displaced fractures	Non-operative
<b>Type II</b>	Displaced fractures	ORIF
<b>Type III</b>	Severely comminuted /irreparable fractures	Excision +- prosthetic replacement

## **2.5 Associated injuries**

Terrible triad injuries are radial head fractures associated with coronoid fractures and ulno - humeral dislocation. There is a high association of ligament injuries with terrible triad injuries. Both Mason III and IV fractures are associated with ligament disruption as well. <sup>3</sup>

Commonly the lateral collateral ligament (LCL) is injured. The LCL is responsible for primary restraint to varus translation of the elbow. It is commonly injured with a fall on an outstretched arm and varus force applied to the elbow. This may lead to posterior rotatory instability of the elbow. Injuries which are more severe can injure the MCL in addition to the LCL leading to gross elbow instability. <sup>18</sup> These ligaments need to be repaired.

The coronoid process also plays a role in preventing posterolateral instability. Fractures of 50% of the coronoid in conjunction with radial head fractures require fixation of the coronoid in addition to radial head arthroplasty to restore elbow stability.<sup>3</sup> The goal of surgical treatment is to restore stability to the ulnohumeral and radiocapitellar joints, allowing early range of motion and avoiding stiffness. Fracture of the anterior medial facet of the coronoid process can lead to posteromedial varus instability and needs to be treated operatively with fixation. When the coronoid process is fractured, repair or open reduction internal fixation (ORIF) of the radial head is recommended to prevent re-dislocation <sup>3</sup>

## **2.6 Current Management of Elbow Fractures**

Mason type I fractures which are undisplaced can be treated conservatively and there is good evidence for it. <sup>2</sup>

Mason type II fractures which are displaced are treated in many centers with ORIF to reduce the joint surface and there are good studies showing good outcomes in these patients. <sup>18</sup>

Akkesson and colleagues (2006) carried out their study by treating Mason II fractures conservatively with displacement between 2 - 5 mm and showed good results. <sup>18</sup>

Currently there are no prospective studies showing a better outcome with reconstructing the radial head over non operative treatment in Mason II radial head fractures. <sup>2</sup>

Kaas et al (2011) performed a systematic review of nine retrospective studies which showed no difference between ORIF and conservative management.<sup>19</sup> A study by Duckworth in 2011 followed 82 patients who were treated conservatively. They found excellent results in 80 patients.<sup>20</sup> Yoon et al (2014) compared two groups of 30 patients each, one group treated with ORIF and the other treated non-operatively. This study also found no difference in outcomes.<sup>8,18,</sup>

There are three different approaches to surgical management for Mason III and IV fractures namely ORIF, resection and radial head replacement. When managing unstable elbow dislocations and injuries that affect the forearm it is vital to restore radiocapitellar contact to restore stability.<sup>8</sup> The options are discussed in more detail below.

### **2.6.1 Radial Head Resection**

Resection of the radial head is currently not recommended in the acute radial head fracture. Resections have been associated with poor outcomes, chronic pain and instability of the elbow joint. Acute excision of the radial head is contraindicated in the presence of disruption of the MCL, interosseus membrane, posterolateral rotatory instability or terrible triad injuries.<sup>12</sup>

Lindenhovius and Ikeda both showed poor results in excision compared to reconstruction.<sup>18</sup> Most recent biomechanical studies have shown problems with stability of the elbow when excision is performed.<sup>18</sup>

The radial head is a secondary stabilizer to longitudinal and valgus forces as previously mentioned. It follows that resection of this stabilizer leads to longitudinal



and valgus instability.<sup>2</sup> Once the radial head has been excised, all forces pass through the ulno-humeral joint which leads to secondary osteoarthritis of this articulation in the long term<sup>3</sup>

### **2.6.2 Open Reduction Internal Fixation of Elbow Fractures**

Open reduction and internal fixation (ORIF) is a treatment option for some types of radial head fractures. Traditionally results for reconstruction (i.e. ORIF) of the radial head have been poor. A study in 2002 by Ring et al shows poor outcomes with high failure rates with reconstruction of the elbow joint. The authors recommended replacement for Mason Type III or IV fractures due to poor results with ORIF.<sup>10</sup>

Most of the poor results have been attributed to poor implant constructs leading to early implant failure. More recently, pre-contoured locking plates have been used with headless compression screws.<sup>21</sup> A bio-mechanical cadaver study by Klaus et al (2010) shows superior results with the newer design compared to previous constructs however, there are very few studies in the current literature supporting reconstruction of the radial head in Mason Type III or IV fractures.<sup>18</sup>

Koslowski et al (2003) conducted a prospective study with 23 patients in 2003 using ORIF of the radial head. They found a satisfactory range of movement with no instability.<sup>23</sup>

Nalbantoglu published a study in 2007 which included 17 patients with Mason III fractures and 8 patients with Mason IV. The study showed good outcomes for reconstructions.<sup>24</sup>

Businger et al (2009) suggested an on-table reconstruction technique (where the radial head and pieces are removed and reconstructed on the table and then replaced). They had four patients in the study with all four patients achieving good results. <sup>21</sup>

Despite recent advances, reconstruction of comminuted fractures are still technically demanding as it is a difficult space to work with and the screws are often placed in the safe zone causing obstruction to pronation and supination and the future removal of hardware. <sup>18</sup>

Complications associated with reconstruction of the radial head are non-union, failure of hardware, avascular necrosis, chronic pain and injury to posterior interosseous nerve injury. <sup>13</sup>

### **2.6.3 Radial Head replacement**

Radial head replacement is a good treatment of choice for Mason III and IV fractures. <sup>14, 15</sup> This consists of excision of the fractured head and replacement with an implant.

It has many advantages. Arthroplasty of the head is technically easier to perform and the procedure is common. A smaller incision is required compared to ORIF and there are generally shorter operating times. <sup>12</sup>

A disadvantage with using a prosthesis is that it may be difficult for the prosthesis to replicate the normal anatomy of the elbow. The prosthesis also needs to withstand the normal loading force placed on the radial head as a stabilizer of the elbow joint. Different types of prostheses have been designed to target these problems. <sup>12</sup>

### 2.6.3.1 Types of Implant and Outcomes

Silicone implants were one of the first types used. These implants do not do well and have high rates of failure due to wear with repetitive stresses. Morrey and colleagues (1981) found five failures of silicone implants out of 117 patients (17%). A recent review of 23 patients by Maghen and colleagues (2011) found good results with silicone implants if concomitant ligament repair was done to the elbow and stability was not completely reliant on the implant.<sup>21</sup> Other problems with this type of implant are silicone synovitis and poor stability due to valgus stress.<sup>21</sup>

Titanium implants have done better than silicone implants however the results have been mixed. Moro and colleagues (2001) retrospectively reviewed 25 patients with radial head replacements in Mason III and IV fractures and followed them for a mean period of 34 months. They found 16 (64%) good or excellent outcomes. There were 5 (20%) patients with evidence of post-traumatic arthritis and 8 patients (32%) showing heterotrophic ossification.<sup>21</sup>

Currently, radial head replacements containing cobalt chromium have been favoured. There have been two long term studies to date. Popovic et al (2007) reported 76% of patients had good to excellent results with a cobalt chrome implant over a mean of 8.4 years.<sup>21</sup> Flinkkila et al 2012 reported good to excellent results in 74% of patients with this implant followed over a mean of 4.8 years.<sup>21</sup> Multiple studies have shown good outcomes in the short to medium term as well.<sup>1,</sup>

Pyrocarbon has been used more recently. While studies are currently few, results have been promising. Ricon (2012) conducted a retrospective review of patients with Mason III fractures treated with pyrocarbon. The patients were followed up over the medium term (mean of 1.9 years). They reported good to excellent results in 81% of the patients. These outcomes are comparable to those achieved with the cobalt chromium radial heads, however longer term studies are needed. <sup>21</sup>

A Radial head pilot study was conducted in 2011 looked at Modular versus bipolar versus monoblock type replacements. <sup>27</sup> Monoblock radial heads are not easy to size which can lead to subluxation of the elbow mal-articulation of the joint. The bipolar design may improve articular congruency but the concern with this implant is polyethylene wear. Popovic et al (2007) reported on outcomes of 51 patients treated with Judet's bipolar radial head prosthesis after a mean of 8.4 years. They found 14 excellent results, 25 good results, 9 fair results, and 3 poor results. Outcomes were assessed using the Mayo Elbow Performance Score addressed later in this chapter. <sup>26</sup> In 31 patients, radiolucent lines were observed: 11 of these were observed within the 1st postoperative year and remained stable, while the other 16 were progressive. Furthermore, 16 patients showed proximal bone loss and 5 had complete loosening.

The newer modular implants have a polished stem for a loose press fit system. It allows the soft tissue and ligaments to heal enough with enough mobility to adapt to the anatomy of the elbow. This press fit replacement is further advantageous due to the different diameters and lengths of head that can be used. The press fit nature of the system allows for rotation of the stem in the medullary canal which allows for better articulation at the radiocapitellar joint. <sup>21</sup>

### **2.6.3.2 Complications of Replacement**

There are several possible complications of radial head replacement and these are listed below:

- Overstuffing of the radiocapitellar joint
- Wear and loosening of the stem
- Secondary osteoarthritis of ulno-humeral joint
- Heterotopic ossification
- Injury to the posterior interosseous nerve

## **2.7 ORIF versus Replacement of the Radial Head**

Two prospective randomized control trials were conducted to compare open reduction and internal fixation with radial head replacement. Chen et al (2007) followed 45 patients and found significantly better outcomes with radial head replacement (91% good results compared to 61% from ORIF). They also found fewer complications with replacements (13.6% with replacement versus 47% with ORIF). Of the patients treated with ORIF, 10% later required radial head replacement.<sup>27</sup> Ruan et al (2009) reported better satisfaction with replacement (93%) versus ORIF (12%).<sup>18</sup>

### **2.7.1 Terrible triad injuries**

Whether the treatment of the radial head is ORIF or replacement, the associated coronoid fractures need to be repaired.

In these fractures generally 30 - 50 % of the coronoid process is involved and are usually best fixed with cannulated screws. Smaller fractures with the coronoid

process fractures are unstable if related to terrible triad injury as they have been proven to be shear fractures of the tip and can lead to instability of the elbow if not fixed.<sup>6</sup>

## **2.9 The Mayo Elbow Score**

The Mayo Elbow Score (see Appendix) is an assessment of function, pain, mobility and stability. It was first described by Morrey (1981) and was used to evaluate the results of treatment of elbow fractures and dislocations. It has been shown to be a reliable assessor of elbow function post-operatively. It includes a questionnaire and physical examination. It has been used successfully in a number of studies and is a good predictor of elbow function.<sup>17,30</sup>

## **2.10 Summary**

This chapter addressed the current literature surrounding radial head fractures. The background and etiology of radial head fractures were addressed along with the functional anatomy of the elbow and factors contributing to elbow stability. Elbow fractures were classified and the different surgical options were discussed (resection, reconstruction and replacement) and compared. The literature surrounding replacement and different types of implant, the outcomes for each type of prosthesis, the surgical technique for replacement as well as common complications was discussed. Finally, the scoring system for assessing elbow function (Mayo Elbow Performance Score) was also explained.<sup>30</sup>

# **Chapter 3: RESEARCH DESIGN AND METHODOLOGY**

## **3.1 Introduction**

This chapter discusses the following in more detail: problem statement, aim and objectives of the study; ethical considerations; research methodology; and validity and reliability of the study.

## **3.2 Problem Statement**

There are various options for the surgical management of Mason Type III and IV fractures of the elbow. The earlier literature regarding the outcome of these patients after surgical management (either radial head replacement, ORIF or radial head resection) of fracture dislocations of the elbow is limited by small patient numbers, a short-term follow-up, and high complication rates. More recent literature has shown radial head replacement to have better functional outcomes in short to medium term but there are very few long-term follow up studies to support the more recent findings.

## **3.3 Aim and Objectives**

### **3.3.1 Aim**

The aim of this study was to determine the functional outcomes of radial head replacement in Mason III and IV radial head fractures in adults.

### **3.3.2 Objectives**

The broad objective was to assess the functional outcomes of radial head replacements in Mason III and IV fractures.

The specific objectives were as follows:

- a. To assess patient demographics
- b. To ascertain patient's injury and surgical details
- c. To assess elbow function
- d. To assess pain post replacement
- e. To assess elbow range of movement
- f. To assess stability of the elbow
- g. To assess complications of radial head replacement

### **3.4 Ethical Considerations**

Approval to conduct the study was obtained from the Postgraduate Committee and the Human Research Ethics Committee (Medical) (HREC) of the University of the Witwatersrand.

Patient confidentiality was maintained during the data collection process. The data sheet did not contain any patient names or hospital numbers. Hospital files were requested from the hospital Records Department by the researcher so that patients were not charged for the opening of files.

Patients examined were referred to the outpatient Orthopaedics clinic when any correctable problems were identified. Physiotherapy was offered to patients with stiff



elbows or weak muscle function without charge. Complications picked up were treated at Helen Joseph Hospital Orthopaedic Outpatients Department.

### **3.5 Research Methodology**

#### **3.5.1 Study Design**

A retrospective descriptive study design was used.

This retrospective study measured the outcomes of patients in the present to the same exposure in the past (in this case, the exposure was a radial head replacement after a Mason III or IV fracture).

A contextual study is conducted in a specific location. This study was carried out in Helen Joseph Hospital.

A descriptive study is used when information is required in a particular field and describes the variables in order to answer the research question, with no intention of establishing a cause-effect relationship. Whilst collecting the data, emphasis in this case was placed on structured observation and questionnaires. This study was descriptive in nature as it aimed to gain information about long to medium term functional outcomes of radial head replacements

#### **3.5.2 Study population**

The study population included all patients who had a Mason Type III and IV radial head fractures treated by multiple surgeons at Helen Joseph Hospital between 2001 to 2013 with immediate prosthetic implantation. The Orthopaedic Department at this hospital keeps records of all procedures performed and a list was consolidated. To

prevent patients being missed due to administration errors, the company supplying the prosthetic for this operation also provided a list of patients they had on record.

### **3.5.3 Study Sample**

#### **3.5.3.1 Sample Size**

Hospital files were retrieved for all of the patients noted in the departmental and company records who had a radial head replacement from 2001 to 2013. Attempts were made to contact all patients telephonically to arrange an interview. There were many difficulties in attempting to contact patients using hospital records. This was due to many factors including poor record keeping and administration, lost patient files or x-rays, the long time frame of the study (meaning patients may have moved away) and the fact that many patients change their cellular phone numbers often. For all these reasons a smaller sample size was expected. Out of 40 names on the initial list, only 18 were reached. Of those, 2 patients had moved away and were not able to come for examination. The remaining 16 were all available for interview and examination. Therefore, a sample of  $n=16$  was achieved (patients who consented to the study and had complete hospital records and x-rays).

#### **3.5.3.2 Inclusion and Exclusion Criteria**

Patients with radial head replacements in Mason Type III and IV radial head fractures were included in the study, provided that consent was given. Participants with missing and incomplete records, as well as patients with missing radiographic imaging, were excluded from the study. Furthermore, patients who could not be

contacted for an interview and to complete a questionnaire were also excluded from the study.

#### **3.5.4 Data Collection**

Data was collected from hospital records and interviews and examinations were conducted with participants by appointment.

Prior to developing the Data Sheets, a review of the literature was done to identify possible important demographic factors. The Mayo Elbow Score was found to be most useful in assessing functional outcomes

##### **3.5.4.1 Surgical Technique**

The following surgical technique is in use at Helen Joseph Hospital for radial head replacement and it was performed on all patients in this study according to their records. It must be noted that operations were performed by multiple surgeons over the years.

The patient was positioned supine and the surgical area was prepared. A tourniquet was applied. A Kocher approach was used (interval between the extensor carpi ulnaris muscle and the anconeus). The radial head was removed with an oscillating saw. If the radial neck was fractured remaining fragments were removed with a bone nibbler. The largest fragment was used to size the prosthesis with respect to thickness and height. The system used provided sizes in increments of 2 mm for both height and diameter. The radial neck was reamed to

remove excess bone and a stem size was selected. A retractor was placed under the radial neck. <sup>26</sup>

Patients were all treated with the same implant by the same company. A smooth stem, uncemented, modular Cobalt Chrome Implant was used.

If the coronoid process was fractured, the lateral approach was used and the coronoid was fixed before replacing the radial head for easier access. A suture fixation technique using two drill holes through the fracture surface at the base of the olecranon and passing the suture through the brachialis muscle was used to repair the coronoid process fracture. <sup>26</sup>

#### **3.5.4.2 Interview and Examination of the patient**

The elbow function was assessed using 5 questions from the Mayo Elbow Performance Score. The questions are shown in Table 4.3 below. Participants answered these questions during interview and were given a score for each question with an affirmative answer getting a score of 5 and a negative answer being scored 0. The maximum amount of points awarded is 25.

***Table 3.1: MEPS - Elbow Function Questions***

Are you able to comb your hair?	5 points
Are you able to feed yourself?	5 points
Are you able to perform personal hygiene tasks?	5 points
Are you able to put on shirt?	5 points
Are you able to put on shoes?	5 points

Pain was assessed on questioning. Participants graded their pain as none, moderate or severe.

The mobility of the elbow joint was examined by the interviewer. This was done by testing the basic movements of the elbow joint, namely, flexion and extension and recording the degrees to which the movement could occur. This was not recorded with a goniometer but was an estimation as the Mayo Elbow Performance Score provided wide ranges for scoring. A flexion-extension arc of greater than 100 degrees was scored as 20 points, an arc of 50 to 100 degrees was scored as 15 points and an arc of less than 50 degrees was scored as 5 points. The other basic movements of the elbow, namely pronation and supination are not assessed as part of the Mayo Elbow Performance Score (MEPS) but were assessed by the examiner as an important aspect of elbow function.

Stability was assessed by performing a varus and valgus stress test with the elbow in 20 degrees of flexion. This was then repeated on the normal side as a comparison.

Complications were assessed on inspection and examination of the elbow and forearm as well as focussed questions regarding any neurology.

### **3.5.5 Data Analysis**

Due to the largely descriptive nature of the study, simple statistics were used including means, medians and modes.

### **3.6 Validity and reliability**

The validity and reliability of this study, and of the data collection, was ensured by the following:

- A representative sample of patients including a wide variety of demographics.
- The use of the Mayo Elbow score to assess function. This score has been shown in numerous studies to be a good predictor of elbow function.
- Short, concise data collection sheet.

### **3.7 Summary**

In this chapter the following was addressed: the problem statement, the aim and objectives of the study; ethical considerations; research methodology; and the validity and reliability of the study. The next chapter presents the results of this study and is followed by a discussion.

## **Chapter 4: RESULTS AND DISCUSSION**

### **4.1 Introduction**

Results from this study are presented as per the study objectives. The data presented includes the following:

- a) Patient demographics including current patient age, sex and dominance.
- b) Further information regarding the injury (including the side and whether it was open or closed) and the surgery.
- c) The length of follow up since arthroplasty.

- d) An assessment of elbow function.
- e) An assessment of pain symptoms post-arthroplasty.
- f) An assessment of mobility post-arthroplasty.
- g) An assessment of elbow joint stability.
- h) Assessing for the presence of any complications post-radial head replacement.

## **4.2 Results**

### **4.2.1 Sample Realization**

During the data collection period, departmental records were accessed for a ten year period and a list of patients derived. Furthermore, the company supplying the implants for the radial head replacements, was also contacted and a second list was derived to supplement the first. Patient records for these 40 patients were requested from the hospital's records department. A total of 24 hospital files were found. Of these, 21 patients had radiographic films available. The files were then used to contact patients to request an interview and examination date. Of the total patients on the list, only 18 were contactable. A majority of those not found were due to incorrect or outdated contact information. One patient had demised and two had relocated to another province.

### **4.2.2 Objective 1: Demographics**

Of the 16 patients interviewed, 8 were male and 8 were female. Patient ages ranged from 29 to 61 years old with a mean age of 42.5 years at interview.

Most patients were right hand dominant, with only 3 (18.75 %) being left handed.

**Table 4.1 Details of patient demographics of all study participants.**

ID	Age at injury	Age now	Sex	Dominance	ID	Age at injury	Age now	Sex	Dominance
1	35	38	Female	Right	9	42	47	Male	Right
2	38	42	Female	Right	10	57	61	Female	Right
3	40	45	Male	Right	11	31	34	Male	Right
4	50	52	Female	Right	12	59	63	Female	Right
5	49	52	Male	Right	13	25	28	Female	Right
6	38	40	Female	Left	14	24	31	Male	Right
7	38	46	Male	Right	15	27	34	Male	Left
8	27	29	Male	Right	16	33	38	Female	Left

#### **4.2.3 Objective 2 and 3: Details of injury and length of follow up**

The average age at injury was 38.3 years with the patient ages ranging from 24 to 59 years. A total of 9 patients had a Mason Type III fracture, with 7 having a Mason IV type fracture. Open injuries were present in 5 of the 16 patients.

Associated coronoid process injuries were present in 5 of the patients (62.5%), with all of those patients having a Mason type IV injury.

Patients were all treated with the same implant by the same company. A smooth stem, uncemented, modular Cobalt Chrome Implant was used.

The average length of follow up was 4.19 years with a range of 2 to 8 years.



**Table 4.2 : Patients' Injury and Surgery Details**

ID	Open/ Closed	Mason III or IV	Side	Other injury	Follow up: Years	ID	Open/ Closed	Mason III or IV	Side	Other injury	Follow up: Years
1	Closed	IV	Left	No	3	9	Closed	III	Right	No	5
2	Closed	IV	Right	No	4	10	Closed	III	Right	No	4
3	Closed	IV	Right	Coronoid process	5	11	Open	IV	Left	Coronoid process	3
4	Open	III	Right	No	2	12	Closed	III	Right	No	4
5	Open	IV	Left	Coronoid process	3	13	Closed	III	Right	No	3
6	Closed	IV	Left	Coronoid process	2	14	Open	IV	Right	Coronoid process	7
7	Open	III	Left	No	8	15	Closed	III	Left	No	7
8	Closed	III	Left	No	2	16	Closed	III	Right	No	5

#### 4.2.4 Objective 4: Assessment of elbow function

The elbow function was assessed using 5 questions from the Mayo Elbow Performance Score as discussed in the methods. Participants answered questions during interview and were given a score for each question with an affirmative answer getting a score of 5 and a negative answer being scored 0. The maximum amount of points awarded is 25.

All study participants scored between 20-25 for this section, meaning they were still able to perform at least four of the five tasks assessed (4 patients scored 20 points meaning they had difficulty with one task, all other participants had no difficulties with the tasks). The raw score data is presented in Table 4.3

**Table 4.3: MEPS Function Score**

ID	Function Score	ID	Function Score
1	25	9	25
2	20	10	25
3	25	11	25
4	20	12	25
5	25	13	20
6	25	14	25
7	25	15	25
8	25	16	20

#### 4.2.5 Objective 5: Assessment of pain post-arthroplasty

Participants were asked to grade their pain as mild, moderate or severe. A score of 45 was given for patients reporting no pain, 30 for patients reporting moderate pain and 0 for patients reporting severe pain. There were no study participants who reported having severe pain. Moderate pain was reported by 8 patients (50%) with the other 8 (50%) reporting no pain. The score data for each participant are presented in Table 4.4.

**Table 4.4: Grading of Pain Severity**

ID	Pain Score	ID	Pain Score
1	45	9	45
2	30	10	30
3	30	11	45
4	45	12	45
5	30	13	45
6	30	14	30
7	45	15	30
8	30	16	45

#### 4.2.6 Objective 6: Assessment of mobility post-arthroplasty

The mobility of the elbow joint was examined by the interviewer as discussed in the methods section of this report.

All raw data are contained in Table 4.5. The values for all movements of the elbow are given in degrees. The range for pronation of the elbow was from 85° to 40° with an average of 71° of pronation. The range for supination of the elbow was 30° to 80° with an average of 68° of supination.

The range for flexion of the elbow was 90° to 120° with an average of 119°. The range for extension of the elbow was -50° to 0° with an average of -5°. The flexion-extension arc therefore ranged from 60° to 160° with an average of 111°.

**Table 4.5: Mobility of the elbow and Range of Movement scores**

ID	Pro	Sup	Flex	Ext	ID	Pro	Sup	Flex	Ext
1	70	80	120	-10	9	80	75	120	0
2	80	80	160	0	10	60	45	110	-10
3	40	45	120	-50	11	75	80	120	0
4	75	55	120	0	12	85	80	120	0
5	60	30	90	-30	13	75	75	120	0
6	70	80	120	0	14	80	80	110	-10
7	75	60	120	0	15	60	45	110	-10
8	80	80	120	0	16	80	80	120	0
Pro: Pronation ; Sup: Supination ; Flex : Flexion ; Ext : Extension									

The flexion extension arc is not directly represented in the table, instead the final MEPS Range of Movement score is given in Table 4.6. No patient scored less than

15 points i.e. all patients achieved an arc greater than 50°. A total of eleven out of 16 patients (68.75%) achieved an arc of greater than 100°.

**Table 4.6: MEPS Range of movement score**

ID	ROM Score	ID	ROM Score
1	20	9	20
2	20	10	15
3	15	11	20
4	20	12	20
5	15	13	20
6	20	14	15
7	20	15	15
8	20	16	20

#### **4.2.7 Objective 7: Assessment of joint stability**

Stability was assessed by performing a varus and valgus stress test with the elbow in 20 degrees of flexion. This was then repeated on the normal side as a comparison. The data is presented in Table 4.7 below.

This was scored according to the MEPS stability score. A stable joint was awarded 10 points, a moderately unstable joint was awarded 5 points and a grossly unstable joint is awarded 0 points. No study participants had any gross instability. Moderate instability was detected in 6 patients out of 16 (37.5%) participants. Details regarding whether the participant had a varus or valgus instability are presented in Table 4.7 below, along with the final MEPS stability score.

**Table 4.7: Elbow Stability Scores**

ID	Instability detected	Stability Score	ID	Instability detected	Stability Score
1	No	10	9	No	10
2	No	10	10	No	10
3	Varus	5	11	Varus	5
4	No	10	12	No	10
5	Valgus	5	13	No	10
6	Varus	5	14	Valgus	5
7	No	10	15	No	10
8	No	10	16	Valgus	5

#### 4.2.8 Objective 8: Complications post-radial head replacement

Any complications reported by the participants during the interview or elicited upon examination were recorded. Complications include nerve injuries with sensory and/or motor deficits as well as instability of the elbow joint.

Complications were present in 2 of the 16 participants. One patient had a posterior interosseus nerve injury. One participant presented with chronic pain of the forearm and wrist with a possible Essex-Lopresti injury. All complications are detailed in Table 4.8.

**Table 4.8: Patient Complications**

ID	Complication	ID	Complication
1	None	9	None
2	Posterior interosseous nerve injury	9	None
3	none	11	none
4	None	12	None
5	none	13	None

6	Essex Lopresti injury. Pain over distal radius ulna joint.	14	none
7	None	15	None
8	None	16	none

#### 4.2.9 Consolidated MEPS Data Table

The final MEPS scores of all participants are presented in Table 4.9.

**Table 4.9: Mayo Elbow Performance Score**

ID	Function	Pain	Stability	ROM	Total MEPS	Interpretation
1	25	45	10	20	100	Excellent
2	20	30	10	20	75	Good
3	25	30	5	15	75	Good
4	20	45	10	20	95	Excellent
5	25	30	5	15	75	Good
6	25	30	5	20	80	Good
7	25	45	10	20	100	Excellent
8	25	30	10	20	85	Good
9	25	45	10	20	100	Excellent
10	25	30	10	15	80	Excellent
11	25	45	5	20	195	Excellent
12	25	45	10	20	100	Excellent
13	20	45	10	20	95	Excellent
14	25	30	5	15	75	Good
15	25	30	10	15	80	Good
16	20	45	5	20	85	Good

A score greater than 90 is regarded as an excellent outcome. A score of 75-89 is regarded as a good outcome, scores of 60-74 are fair and a score below 60 is a poor functional outcome.

Based on the results of the Mayo elbow performance score, 8 patients had good results and 8 patients had excellent results. There were no patients with fair or poor functional outcomes.

### **4.3 Discussion**

The management of radial head fractures is controversial. The excision of the radial head is no longer used in the acute setting due to poor outcomes as previously stated. There is also little evidence supporting radial head reconstruction/ORIF in Mason III and IV fractures. Only a few of these studies exist and one of the studies was a biomechanical study on cadavers.<sup>31</sup> A third study supporting ORIF by Businger et al (2009)<sup>18</sup> looked at 'on table' reconstruction but had a very small sample size (four patients). This 'on table' technique potentially makes it easier to reconstruct the comminuted radial head but since this requires extensive periosteal and vascular stripping, it can lead to non-union and sepsis.

This study focused on radial head replacement with a cobalt chrome prosthesis as these are currently favoured in the literature. Radial head replacements are used routinely in local institutions but to date there are no studies that have been done in South Africa.

The aim of the study was to determine functional outcomes of radial head replacements in terms of daily function, range of movement, pain and stability. All patients achieved scores of 20 or 25 for function (good and excellent scores) and were able to carry out activities of daily living such as hygiene, dressing and feeding themselves.

Pain was commonly reported by participants with 8 out of 16 patients (50%) scoring 30 out of 45. It should be noted that all patients interviewed reported that they had mild pain but the MEPS does not make provision to record mild pain and so these patients were scored according to a moderate pain score.

All patients achieved adequate range of movement in terms of flexion/extension and pronation/supination. Unfortunately, there was no standardized post-operative rehabilitation provided for these patients and this may have had an impact on elbow stiffness and caused lower scores for some patients.

No patients presented with any gross instability on examination. Out of 16 patients, 6 (37.5%) had moderated instability compared to the normal side. Associated coronoid fractures have been fixed in all patients with this injury as this may cause instability if left untreated. The LCL has also been repaired in all cases where it was damaged to allow more stability of the elbow.

One patient had posterior interosseous nerve injury. She originally presented with poor MEPS. She was initially lost to follow up at the time but was referred for a radial nerve tendon transfer. On the 2nd follow up six months after tendon transfer she had excellent MEPS function.



The final MEPS scores observed in this study in which eight patients had excellent outcomes and eight patients had good outcomes is comparable to other studies with medium to long term follow up of radial head replacements.<sup>20</sup>

Many studies in the literature included a Dash score which looks at elbow, shoulder and hand function which theoretically should be more accurate in predicting overall upper limb function. The use of a Dash score in assessing function may have been of benefit in this study.<sup>1, 20, 29</sup>

The biggest challenge in the study was the small sample size used due to patients being lost to follow up and contact details changing. Small patient numbers could have potentially missed complications which could explain the low complication rate observed in this study.

According to Fowler et al (2013)<sup>20</sup>, a long term study includes patient follow up of more than eight years. This study originally set out to include patients from 2001 to 2013 to make it a long term study however, due to poor early record keeping patients were lost in the early years of the study. This study only included one patient with an eight year follow up and a mean follow up of 4.19 years making it a short to medium term follow up.

As many patients are young, it was not possible to predict if the implants will be able to last for 20 - 30 years. Therefore, a true long term study, in this case, should occur over a period longer than eight years.

Common complications of the surgery are overstuffing of the radial head, loosening and heterotopic ossification. Unfortunately re-xrays of the patients were not included in the study design and the above problems could not be assessed. The second complication of possible Essex Lopresti injury was diagnosed clinically and could not be confirmed on X-ray.

This study which used a press fit modular cobalt chrome radial head has comparable results to a study published in the Journal of Bone and Joint Surgery by Grewal et al (2005). A similar implant was used in their review and they reported good clinical outcomes.

There are currently only two prospective studies by Chen et al <sup>26</sup> and Ryan et al (2009)<sup>27</sup> show significantly better outcomes of radial head replacement over reconstruction. Different rehabilitation protocols were used in both studies for the two groups which could have led to better outcomes in the radial head replacement group.

#### **4.4 Summary**

This chapter addressed the results of the study including the patient demographics, the details of injury and surgery, the length of follow up, and assessments of outcomes by assessing function of the elbow, pain, instability, range of movement and complications. A discussion of the results was undertaken and limitations of the study were discussed. The following chapter summarises the study, the major findings and the limitations. Recommendations for further research and clinical practice is also addressed.

## Chapter 5: CONCLUSIONS AND RECOMMENDATIONS

The study found that all patients had excellent or good outcomes post-radial head replacement and this is comparable to other studies with medium to long term follow up of radial head replacements. Complications were noted in the form of nerve injury in two patients. This study was limited in that it was a retrospective review, with limited patient numbers and short to medium term follow up. Furthermore, no radiographs were performed as a part of the study. From the limited data available in this study, radial head replacement can be recommended as a safe procedure in Mason III and IV radial head fractures as good to excellent outcomes are achievable with limited complications. There remains a need for more prospective randomised control trials as well as studies with more patient numbers over a longer duration to truly assess long term outcomes. These types of studies will be difficult to attain due to the heterogeneous nature of the injury and different implants available.

## REFERENCE LIST

1. Iftimie, PP et al. Resection arthroplasty for radial head fractures: long-term follow-up. *Journal of Shoulder and Elbow Surgery*. 2011;20(1), 45-50.
2. Kumar , V, Wallace, WA. Radial head fractures update on classification and management. *Orthopaedics and Trauma*. 2012;26 (2), 124-131.
3. Calfee, R, Madom I, Weiss, APW. Radial Head Arthroplasty. *Journal of Hand Surgery*. 2006;31(A), 313-321.

4. Stroyan, M, Wilk, KE. The functional anatomy of the elbow complex. *J Orthop Sports Phys Ther.* 1993;17(6):279-88
5. Image from Netter's Atlas of Human Anatomy. Netter, FH, Hansen JT. *Atlas of Human Anatomy.* Third Edition. Icon Learning Systems. Teterboro, New Jersey. 2003
6. Image from Mathew, PK, Athwal, GS, King, GJW. *Terrible Triad Injury of the Elbow: Current Concepts.* Journal of the American Academy of Orthopaedic Surgeons. 2009;17(3) p27
7. Ring, D. Radial head fracture: open reduction internal fixation or prosthetic replacement. *Journal of Shoulder and Elbow Surgery.* 2011;20 (1), p107-112.
8. Yoon, A, Athwal G, Faber, K, King, GJW. Radial Head Fractures. *Journal of Hand Surgery.* 2012;37 (A), 2626-1337
9. An K, Zobitz ME, Morrey BF. Biomechanics of the elbow. *In: Morrey BF, Sanchez-Sotelo J, editors. The elbow and its disorders.* 4th edition. Philadelphia: Elsevier; 2009. p. 39–63
10. Ring, D. Displaced, unstable fractures of the radial head: Fixation vs. replacement: What is the evidence? *Injury, International Journal of Care of the Injured.* 2008;39 (1):p1329-1337.
11. Dodds SD, Fishler T. Terrible Triad of the Elbow. *Orthop Clin N Am.* 2013; 44: p47–58
12. King, GJW. Management of radial head fractures with implant arthroplasty. *Journal of the American Society for Surgery of the Hand.* 2004; 4 (1): p11-26.
13. Harrington et al. Replacement of the radial head in the treatment of unstable elbow fracture. *Injury: the British Journal of Accident Surgery.* 2012; 11(No. 5) :p405-4 12

14. Beingessner, DM, Dunning, CE, Beingessner CJ, Johnson, JA, King, GJW. The effect of radial head fracture size on radiocapitellar joint stability. *Clinical Biomechanics*. 2003; 18 (1):p677-681.
15. Burkhart KJ et al. Mid- to long-term results after bipolar radial head Arthroplasty. *Journal of Shoulder and Elbow Surgery* 2010; 19: p965-972
16. Torres-Torres M, Ortiz-Espada A, Corella-Montoya F and J. Vaquero-Martín. Bipolar radial head prosthesis implantation: a review of 15 cases. *Rev. esp. cir. ortop. traumatol*. 2008; 52:p306-14
17. Burkhart KJ et al. Fractures of the Radial Head. *Hands Clinic Review* 2015. <http://dx.doi.org/10.1016/j.hcl.2015.06.003>
18. Kaas et al. The epidemiology of elbow fractures. *Journal of Shoulder and Elbow Surgery*. 2011,19(4):p520-3
19. Duckworth et al. The epidemiology of the radial head and neck fractures. *J Hand Surgery*. 2012 37(1): p112–119
20. Fowler, JR. Goitz, RJ. Radial Head Fractures : Indications and outcomes for Radial Head Arthroplasty. *Orthopedic Clinics of North America* 2013, p425-431
21. Businger A, Ruedi TP, Sommer C. On-table reconstruction of comminuted fractures of the radial head. *Injury* 2009;41(6):p583–8.
22. Koslowski TC, Mader K, Gausepohl T, et al. Reconstruction of Mason type-III and type-IV radial head fractures with a new fixation device. *Acta Orthop* 2007;78:p151–6.

23. Nalbantoglu U, Kocaoglu B, Gereli A, et al. Open reduction and internal fixation of Mason Type III radial head fractures with and without an associated elbow dislocation. *Journal of Hand Surgery* 2007;32:1560–8.
24. Wang ML, Pedro PD. Management of Radial Head Fracture With Elbow Dislocation. *Journal of Hand Surgery, America*. 2015 (40): p323-332
25. Ring, D, King, G. Radial Head Arthroplasty with a Modular Metal Spacer to Treat Acute Traumatic Elbow Instability. *J Bone Joint Surg Am*. 2008;90 Suppl 2 (Part 1):p 63-73
26. Chen X et al. Comparison between radial head replacement and open reduction and internal fixation in clinical treatment of unstable, multi-fragmented radial head fractures. *Int Orthop*. 2011; 35(7): p1071–1076.
27. Grewal et al. Comminuted Radial Head Fractures Treated with a Modular Metallic Radial Head Arthroplasty. Study of Outcomes. *J Bone Joint Surg Am*. 2006 (88) : p2192-2200
28. Ryan et al. A comparative study of internal fixation and prosthesis replacement for radial head fractures of Mason Type III. *Int Orthop*. 2009; 33(1): p249–253.
29. Klaus et al. Mid- to long-term results after bipolar radial head arthroplasty. *The Journal of Hand Surgery*. **2007**;32 (10): p1569–1575
30. Cusick MC et al . Accuracy and reliability of the Mayo Elbow Performance Score. *J Hand Surg Am*. 2014;39(6):1146-50.
31. Klaus et al. Stability of Radial Head and Neck Fractures: A Biomechanical Study of Six Fixation Constructs With Consideration of Three Locking Plates. *The Journal of Hand Surgery*. 2007;32(10): p1569–1575

# Appendices

## Appendix 1: PERMISSION FROM POSTGRADUATE COMMITTEE



Private Bag 3 Wits, 2050  
Fax: 027117172119  
Tel: 02711 7172076

Reference: Ms Thokozile Nhlapo  
E-mail: [thokozile.nhlapo@wits.ac.za](mailto:thokozile.nhlapo@wits.ac.za)

20 January 2016  
Person No: 0201027J  
PAG

Dr MN Bismilla  
Po Box 84378  
Greenside  
2034  
South Africa

Dear Dr Bismilla

### **Master of Medicine: Approval of Title**

We have pleasure in advising that your proposal entitled *Outcomes of radial head replacement in Mason 3 and 4 radial head fractures* has been approved. Please note that any amendments to this title have to be endorsed by the Faculty's higher degrees committee and formally approved.

Yours sincerely



Mrs Sandra Benn  
Faculty Registrar  
Faculty of Health Sciences

## Appendix 2 :PERMISSION FROM ETHICS COMMITTEE



R14/49 Dr Muhammad Naadir Bismilla

### HUMAN RESEARCH ETHICS COMMITTEE (MEDICAL)

#### CLEARANCE CERTIFICATE NO. M140832

**NAME:** Dr Muhammad Naadir Bismilla  
**(Principal Investigator)**

**DEPARTMENT:** Orthopaedics  
Helen Joseph Hospital

**PROJECT TITLE:** Functional Outcomes of Radial Head Replacement in  
Mason Type 3 and 4 Fractures

**DATE CONSIDERED:** 29/08/2014

**DECISION:** Approved unconditionally

**CONDITIONS:**

**SUPERVISOR:** Dr AAA Aden

**APPROVED BY:**   
Professor P Cleaton-Jones, Chairperson, HREC (Medical)

**DATE OF APPROVAL:** 01/10/2014

This clearance certificate is valid for 5 years from date of approval. Extension may be applied for.

#### DECLARATION OF INVESTIGATORS

To be completed in duplicate and **ONE COPY** returned to the Secretary in Room 10004, 10th floor, Senate House, University.

I/we fully understand the conditions under which I am/we are authorized to carry out the above-mentioned research and I/we undertake to ensure compliance with these conditions. Should any departure be contemplated, from the research protocol as approved, I/we undertake to resubmit the application to the Committee. **I agree to submit a yearly progress report.**

Principal Investigator Signature

Date

PLEASE QUOTE THE PROTOCOL NUMBER IN ALL ENQUIRIES



### **Appendix 3: PATIENT INFORMATION SHEET**

#### Functional Outcomes of Radial Head Replacement in Mason Type 3 and 4 Fractures

Dear Participant

My name is Naadir Bismilla. I am a registrar in the Department of Orthopaedics at the Charlotte Maxeke Johannesburg Academic Hospital and registered for a Master of Medicine (Orthopaedic Surgery) degree at the Faculty of Health Sciences, University of the Witwatersrand. As part of the course requirement, I am expected to conduct research under supervision.

I would like to invite you to participate in my study. I am trying to find out the outcomes of patients who have had a radial head replacement. I am contacting patients who, like you, had a specific type of surgery (radial head replacement) for their broken elbow and finding out how they are functioning now to see if this surgery gives good results.

I will be looking at your patient file to find out what type of fracture you had as well as what type of surgery was done. I will also be looking at your old x-rays. I will then invite you to see me at Helen Joseph Hospital where you will be asked a short 5 minute interview. I will examine your elbow to assess function. A single x-ray of your elbow will also be taken to check your progress. There is no risk involved in this, but please do tell me if you are pregnant or think you might be pregnant.

The study has been approved by the Human Research Ethics Committee (Medical) (HREC) and Postgraduate Committee of the University of the Witwatersrand. Your participation is voluntary and you may stop at any time should you wish not to finish the interview. All questionnaires will be secret so information you give me can therefore not be traced back to you.

There are no risks or benefits to being involved in the study. I will however, reimburse you for transportation costs of travelling to the hospital.

The published data will be made available to all participants once the research is complete.

Should you have any further questions or complaints, please contact me on 0845170899. You may also contact the chair of the Research Ethics Committee via the Wits Research Office on 011-717-1234 if you have any further complaints or problems.

Many thanks for your participation,

Dr MN Bismilla

## Appendix 4: DATA COLLECTION SHEET

### DEMOGRAPHICS & SURGERY

Study ID: \_\_\_\_\_

Date of Birth (dd/mm/yy) : \_\_\_\_ / \_\_\_\_ / \_\_\_\_ Gender: ☐ Male ☐ Female

Occupation then: \_\_\_\_\_ Occupation Now \_\_\_\_\_

Dominance: ☐ R ☐ L Date of Admission (dd/mm/yy) : \_\_\_\_ / \_\_\_\_ / \_\_\_\_

Mechanism of injury: ☐ MVA ☐ PVA ☐ Fall ☐ Assault

☐ Other: \_\_\_\_\_

Previous injury/disorder Shoulder: ☐ No ☐ Yes Specify \_\_\_\_\_

Previous injury/disorder Elbow: ☐ No ☐ Yes Specify \_\_\_\_\_

Previous injury/disorder wrist or hand: ☐ No ☐ Yes Specify \_\_\_\_\_

Fracture Type: ☐ Closed ☐ Open: ☐ Mason III ☐ Mason IV

Side: ☐ R ☐ L

☐ Coronoid fracture

☐ Monteggia fracture

Other Associated INJURIES: \_\_\_\_\_

Surgery date (dd/mm/yy) : \_\_\_\_ / \_\_\_\_ / \_\_\_\_

Surgery Type: ☐ Radial Head Replacement

Approach:

☐ Repair LCL

☐ Repair MCL

☐ Fixation coronoid

☐ Fixation olecranon

☐ Other

☐ Fixation

ARCHIVING: ☐ A: Available ☐ B1: Lost to FU ☐ B2: Dead ☐ C: Refused

Complication? ☐ Wound breakdown

☐ Infection

☐ Compartment syn. ☐ Median Nerve ☐ PIN N.

☐ Ulnar N.

☐ Vascular ☐ Other: \_\_\_\_\_

Revision? ☐ No ☐ Yes Date: \_\_\_\_\_

Implant Failure? ☐ No ☐ Yes Date: \_\_\_\_\_

Exchange implant? ☐ No ☐ Yes Date: \_\_\_\_\_

Data Entry on: \_\_\_\_ / \_\_\_\_ / \_\_\_\_ by: \_\_\_\_\_

## Appendix 5: Mayo Elbow Performance Score

### Function

1. Are you able to comb your hair (5 points) \_\_\_\_\_
2. Are you able to feed yourself (5 points) \_\_\_\_\_
3. Are you able to perform personal hygiene tasks (5 points) \_\_\_\_\_
4. Are you able to put on shirt (5 points) \_\_\_\_\_
5. Are you able to put on shoes (5 points) \_\_\_\_\_

### Do you have pain? How much (maximum 45 points)

- None (45 points) \_\_\_\_\_
- Mild (30 points) \_\_\_\_\_
- Severe (0 points) \_\_\_\_\_

### Examination

#### Stability (10 points)

- Stable (10 points) \_\_\_\_\_
- Moderately unstable (5 points) \_\_\_\_\_
- Grossly unstable (0 points) \_\_\_\_\_

#### Range of Motion (20 points)

- Arc > 100 degrees (20 points) \_\_\_\_\_
- Arc 50 to 100 degrees (15 points) \_\_\_\_\_
- Arc < 50 degrees (5 points) \_\_\_\_\_

Total Score: \_\_\_\_\_

### Interpreting the Mayo Elbow Performance Score

Score greater than 90	Excellent
Score 75-89	Good
Score 60-74	Fair
Score below 60	Poor