



**A RETROSPECTIVE REVIEW OF THE RELATIONSHIP
BETWEEN PERITONSILLAR ABSCESS AND HIV**

Dr IMRAAN VARIAVA

**A Research Report submitted to the
Faculty of Health Sciences, University of Witwatersrand,
in partial fulfilment of the requirements for the degree of Master of Medicine in
the branch of Otorhinolaryngology**

Gauteng 2009

DECLARATION

I, Dr Imraan Variava, hereby declare that this research report is my own work and has not previously been presented for any degree of any university.

DR IMRAAN VARIAVA

10 November 2009

DEDICATION

To my beautiful wife Hasina,
for her undying love, magnificent support, patience,
understanding and exceptional encouragement

and

To all my children, Azita, Mizaan and Tazkia
the light in my life

and

To my mother Fatima and father Ishaak
for their encouragement and support

ABSTRACT

HIV/AIDS continues to be an important public health challenge in sub Saharan Africa. It is estimated that approximately 68% of people living with HIV in the world are from this region [1]. South Africa has the largest infected population in the world, the adult (15-49 years) HIV prevalence is estimated at 17.64% [2]. It has been estimated that 40 - 70% of such HIV positive individuals present with head and neck manifestations, which include infection, inflammation and tumours, and are often the only and initial presenting sign [3,4]. Peritonsillar abscess is the most common deep infection of the head and neck in young adults and can occur in all age groups, but the highest incidence is in adults 20 to 40 years of age [5].

The aim of this study was to assess the relationship between peritonsillar abscess and the HIV status of patients. Method: An analytical cross sectional study utilising retrospective clinical data from ward registers, patient records, treatment registers and National Health Laboratory System (NHLS) databases. This study was conducted in the adult ENT ward at the Chris Hani Baragwanath Hospital and sample consisted of patient records over a 4 year period from January 2005 to December 2008. All patients admitted to the ENT ward with the discharge diagnosis of peritonsillar abscess that have been tested for HIV were included in this study.

In this study period 450 patient files were reviewed of which 291 fulfilled the inclusion criteria. The demographic details, clinical presentation which included head and neck manifestations of HIV, the HIV status, management and complications of peritonsillar abscess were recorded. This data was analysed using STATA-10 software.

Results: The age ranged from 15 to 63 years with a mean (SD) 29.3 years (9.58). From the 291 patients, 86 (29.55%) were HIV positive. This is significantly higher than the adult (15-49years) HIV prevalence rate of 17.64% [6]. The male: female ratio of HIV positive patients 1:1.53. Forty-nine (16.84%) patients presented with cervical lymph nodes of which 65.31% were HIV positive ($P < 0.001$). From the 86 HIV positive patients oral candida was present in 15.12% ($P < 0.001$), lymphoma in 6.98% ($P < 0.001$), oral hairy leukoplakia in 2.33%, Kaposi's sarcoma in 1.16% and complications (parapharyngeal abscess) 3.48%. There was no statistical significance in the management of HIV positive patients, however hospital stay was longer with a mean of 3.802 days ($P < 0.001$).

From this study sample the HIV prevalence of 29.55% suggests that peritonsillar abscess may be an early clinical marker of HIV infection. Due to the high incidence of head and neck manifestations in HIV positive patients identifying a clinical marker (quinsy) in the earlier stages of HIV infection would allow for better screening, earlier diagnosis and treatment of HIV infection.

ACKNOWLEDGEMENTS

I would like to extend special thanks and profound appreciation to the following:

- My supervisor : Adjunct Professor P.C. Modi, Head of ENT Department, for his magnificent support, inspirational enthusiasm, professional guidance and above all his availability.
- My Co- Supervisor : Dr Shahpar Motakef for her encouragement.
- Dr Rasvi Ahmed, Head of ENT Department C.H. Baragwanath Hospital, for his encouragement, support and guidance.
- Dr Waasila Jassat, Department of Public Health for her patience, support, encouragement and help in planning and evaluating the statistics.
- Dr Yahya Attiya, registrar in ENT Department, for his tireless efforts in assisting me with the data collection.
- Dr Mohammed Variava for his encouragement and assisting in data collection.
- Dr Alison Bently for her guidance and advice.
- Finally to my family without whose support this research would not have been possible.

TABLE OF CONTENTS

	<u>Page</u>
Title page	
Declaration	I
Dedication	II
Abstract	III
Acknowledgements	V
Table of Contents	VI
List of Tables	X
List of Figures	XI

CHAPTER 1 - INTRODUCTION

1.0 General Remarks	1
1.1 Review of literature	2
1.1.1 Prevalence of HIV	2
1.1.2 Classification of HIV	6
1.2 Oral and oropharyngeal manifestations of HIV	9
1.2.1 Fungal Infections	11
1.2.2 Viral Infections	13
1.2.3 Bacterial Infections	14
1.2.4 Neoplasms	15
1.3 Peritonsillar Abscess	16
1.3.1 Prevalence and etiology	16
1.3.2 Relevant anatomy	18
1.3.3 Clinical Manifestations	19
1.3.4 Diagnosis	19
1.3.5 Management	20
1.3.6 Complications	21

CHAPTER 2 – MATERIALS AND METHODS

2.0	Justification of the study	22
2.1	Purpose of the study	22
2.1.1	Aim	22
2.1.2	Specific objectives	23
2.2	Study Design	23
2.3	Study Setting	24
2.4	Data Collection	24
2.5	Inclusion and Exclusion Criteria	26
2.6	Data Analysis	26
2.7	Limitations	27
2.8	Ethical and Legal considerations	27

CHAPTER 3 – RESULTS

3.1	Sample Studied	28
3.2	Demographic Data	28
3.2.1	Gender	28
3.2.2	Age	29
3.2.3	Race	30
3.3	Clinical Features of peritonsillar abscess	31
3.3.1	Temperature	31
3.3.2	Trismus	31
3.3.3	Site of Abscess	32
3.3.4	Lymphadenopathy	33
3.4	Oral Manifestations of HIV	33
3.4.1	Oral Candida	33
3.4.2	Oral Hairy Leukoplakia	34
3.4.3	Lymphoma	34
3.4.4	Kaposi's Sarcoma	35
3.4.5	Angular Chelitis	35
3.4.6	Other HIV Manifestations	35

3.5	Laboratory Data	36
3.5.1	HIV Results	36
3.6	Management	36
3.6.1	Incision and Drainage	36
3.6.2	Antibiotics	37
3.6.3	Tonsillectomy	38
3.6.4	Complications	38
3.6.5	Number of Days Admitted	39

CHAPTER 4 – Discussion

4.1	Sample Collection	40
4.2	HIV prevalence in Peritonsillar abscess	41
4.3	Demographic Data	41
4.3.1	Gender	41
4.3.2	Age	41
4.3.3	Race	42
4.4	Clinical Features of peritonsillar abscess	42
4.4.1	Temperature	42
4.4.2	Trismus	42
4.4.3	Site of Abscess	42
4.4.4	Lymphadenopathy	43
4.5	Oral Manifestations of HIV	43
4.5.1	Oral Candida	43
4.5.2	Oral Hairy Leukoplakia	43
4.5.3	Lymphoma	44
4.5.4	Kaposi's Sarcoma	44
4.5.5	Other HIV Manifestations	44

4.6	Management	44
4.6.1	Incision and Drainage	45
4.6.2	Antibiotics	45
4.6.3	Tonsillectomy	46
4.6.4	Complications	47
4.6.5	Number of Days Admitted	47
4.7	Summary	48
4.8	Suggested Further Research	48
4.9	Conclusion	49
CHAPTER 5 – REFERENCES		50
APPENDIX		55

LIST OF TABLES

	Page
1.1 Provincial HIV prevalence estimates among antenatal clinic Attendees, South Africa, 2005 – 2007.	5
1.2 National HIV prevalence estimates by age group among antenatal clinic attendees, South Africa, 2005 – 2007.	6
1.3 WHO Clinical Staging of HIV/AIDS for Adults and Adolescents	8
1.4 Classifications of Oral Manifestations of HIV	10
1.5 Clinical types of Candidiasis	11
1.6 Common organisms	17
1.7 Complications of Peritonsillar Abscess	21
3.1 HIV status by gender	28
3.2 HIV positive % by Age Group	29
3.3 HIV Status by Race	30
3.4 HIV status by Trismus	31
3.5 HIV status by Site	32
3.6 HIV status by Cervical Lymphnodes	33
3.7 HIV status by presence of Candida	33
3.8 HIV status by OHL	34
3.9 HIV status by Lymphoma	34
3.10 HIV status by Kaposi's Sarcoma	35
3.11 Tabulation of HIV Status	36
3.12 HIV Status by Antibiotics	38

LIST OF FIGURES

	Page
1.1 Estimated numbers of people living with HIV and adult HIV prevalence. Global HIV epidemic, 1990–2007; and, HIV epidemic in Sub-Saharan Africa, 1990–2007	3
1.2 National HIV prevalence trends among antenatal clinic attendees, South Africa, 1990 to 2007.	4
2.1 Data collection sheet	25
3.1 HIV Status by Gender	28
3.2 HIV positive % by Age Group	29
3.3 HIV Status by Race	30
3.4 HIV status by Site	32
3.5 HIV Status	36
3.6 HIV status by Incision and Drainage	37
3.7 HIV status by Antibiotics	38
3.8 HIV Status by Days admitted	39

CHAPTER 1 – INTRODUCTION

1.0 General Remarks

HIV/AIDS continues to be an important public health challenge in sub Saharan Africa. It is estimated that approximately 68% of people living with HIV in the world are from this region [1]. South Africa has the largest infected population in the world, the adult (15-49 years) HIV prevalence is estimated at 17.64% [2]. It has been estimated that 40 - 70% of such HIV positive individuals present with head and neck manifestations, which include infection, inflammation and tumours, and are often the only and initial presenting sign [3,4].

The otorhinolaryngological abnormalities in HIV patients have been reported, but the literature is lacking a description of their occurrence during the earlier stages of the HIV infection. Peritonsillar abscess is the most common deep infection of the head and neck in young adults, despite the widespread and early use of antibiotics for treating tonsillitis and pharyngitis. Peritonsillar abscess can occur in all age groups, but the highest incidence is in adults 20 to 40 years of age [5]. Peritonsillar abscesses are almost always first encountered by the family physician or primary health care clinics, and those with appropriate training and experience can diagnose and treat most patients. Prompt recognition and initiation of therapy is important to avoid potential serious complications.

The aim of this project is to assess the relationship between peritonsillar abscess and the HIV status of patients, with regards to clinical presentation and management. The study was conducted at the Chris Hani Baragwanath Hospital. This hospital, with its 2888 beds, is the largest acute care hospital in the world. It is situated to the south west

of Johannesburg, on the southern border of Soweto. The Hospital grounds cover an area of 173 acres, consisting of 429 buildings with a total floor area of 233 785 m². The hospital has a staff establishment of nearly 5000, of which approximately 600 are doctors and 2 000 are nurses. It is the only public hospital serving ±3,5 million people in Soweto and provides half of all the hospital services in Southern and Western Gauteng[7].

1.1 Review of literature

1.1.1 Prevalence of HIV

The Joint United Nations Programme on HIV/AIDS (UNAIDS) and the World Health Organization (WHO), estimated the number of people living with HIV at the end of 2007 to be 39.5 million worldwide [1]. While approximately 10% of the world's population lives in sub-Saharan Africa, an enormous 64% of all people living with HIV live in this region including 77% of all women living with HIV.

Levels of infection vary throughout this region with countries north and west having adult (15-49) prevalence levels of between 1% and 5%, while Southern Africa have prevalence levels of between 10-20%. HIV prevalence has declined in some countries, Uganda in the early 1990s, and recently Zimbabwe, Kenya and urban areas of Burkina Faso. These declines seem to be linked to changes in key sexual behaviors [8]. Overall, HIV prevalence in this region appears to be leveling off, albeit at high levels [Figure 1.1].

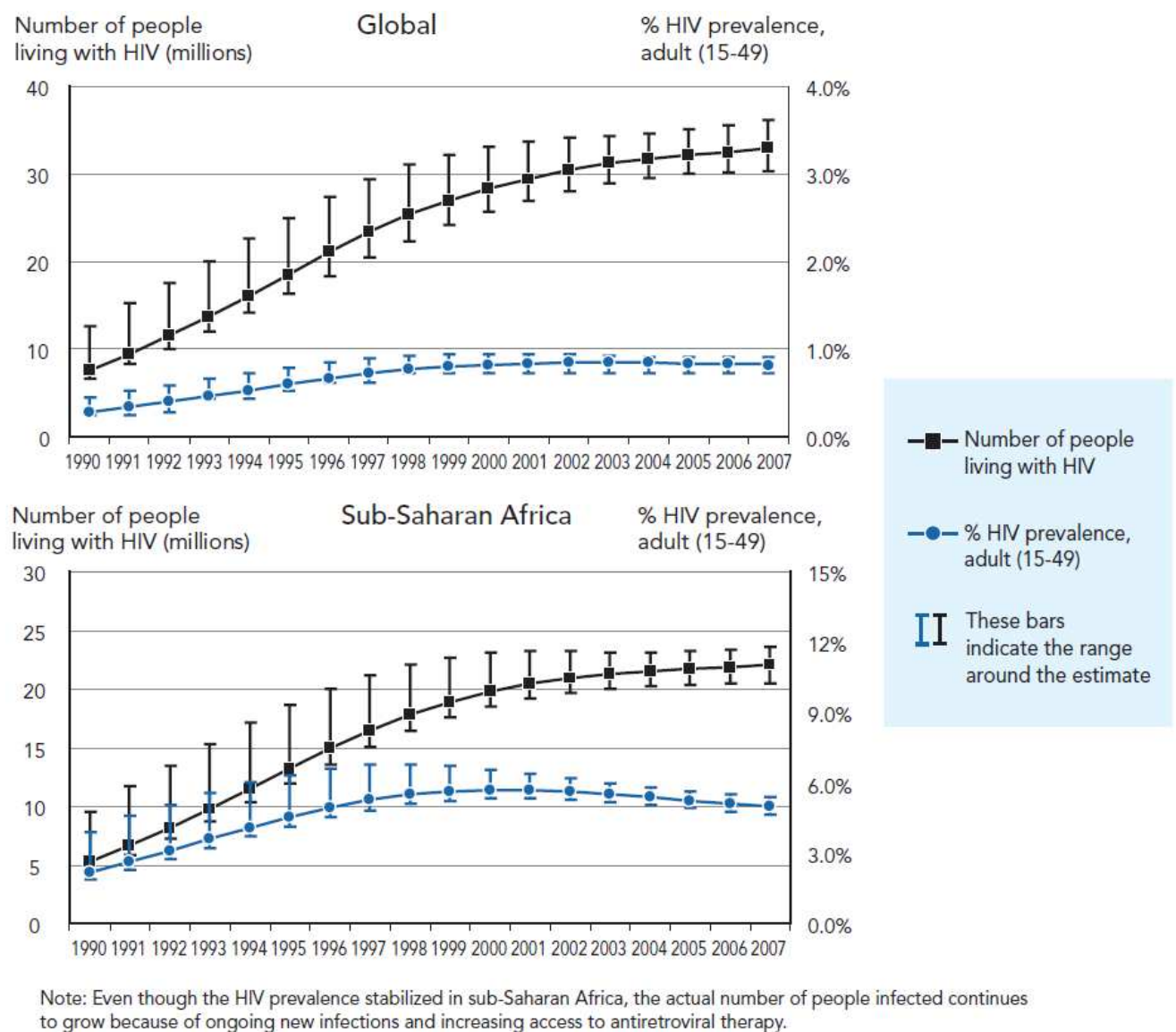


Figure 1.1 Estimated numbers of people living with HIV and adult HIV prevalence. Global HIV epidemic, 1990–2007; and, HIV epidemic in Sub-Saharan Africa, 1990–2007

HIV and AIDS is one of the major challenges facing South Africa today. Some two decades since the introduction of this disease in the general population, the epidemiological situation is characterized by very large numbers of people living with HIV and a disproportionate effect on particular sectors of society, young women, the

poor, as well as those living in underdeveloped areas in the country. HIV and AIDS, however affects the lives of all people who live in South Africa in different ways [9].

The national HIV prevalence rates have been stable for several years and there is now evidence of the epidemic being on the decline. The 2007 national antenatal HIV prevalence stands at 28.0%. This represents a possible 1.1% reduction in HIV prevalence from 2006 to 2007 [6]. When the 2005 and 2007 HIV estimates are compared, we observe a statistically significant decline in HIV prevalence [Figure 1.2].

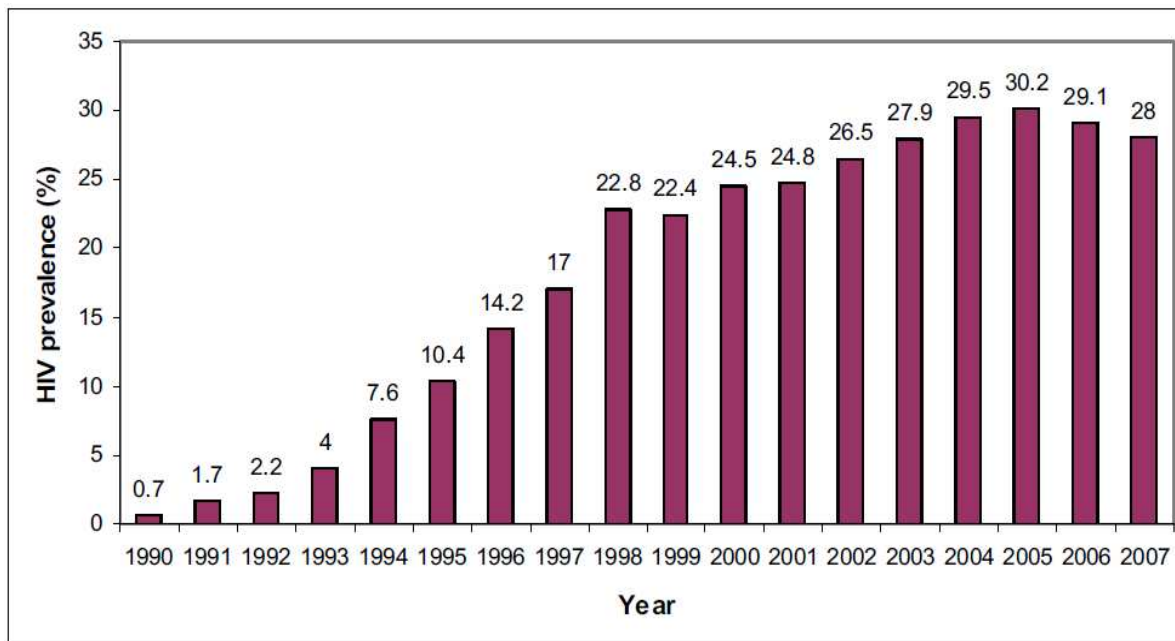


Figure 1.2 National HIV prevalence trends among antenatal clinic attendees, South Africa, 1990 to 2007.

Although the provincial HIV prevalence estimates among antenatal clinic attendees showed that there was a decline in the Gauteng province the prevalence still remains the fourth highest in South Africa [6]. The distribution of HIV by province is shown in [table 1.1]

Table 1.1 Provincial HIV prevalence estimates among antenatal clinic attendees, South Africa, 2005 – 2007.

Province	HIV pos. 95% CI 2005	HIV pos. 95% CI 2006	HIV pos. 95% CI 2007
KwaZulu-Natal	39.1 (36.8 - 41.4)	39.1 (37.5 - 40.7)	37.4 (35.0 - 39.8)
Mpumalanga	34.8 (31.0 - 38.5)	32.1 (29.8 - 34.4)	32.0 (29.2 – 34.9)
Free State	30.3 (26.9 - 33.6)	31.1 (29.2 - 33.1)	33.5 (28.3 - 39.1)
Gauteng	32.4 (30.6 - 34.3)	30.8 (29.6 - 32.1)	30.3 (29.9 – 32.8)
North West	31.8 (28.4 - 35.2)	29.0 (26.9 - 31.1)	29.0 (24.8 – 33.5)
Eastern Cape	29.5 (26.4 - 32.5)	28.6 (26.8 - 30.4)	26.0 (24.0 - 28.1)
Limpopo	21.5 (18.5 - 24.6)	20.6 (18.9 - 22.3)	18.5 (16.7- 20.4)
Northern Cape	18.5 (14.6 - 22.4)	15.6 (12.7 - 18.5)	16.1 (13.9 – 18.7)
Western Cape	15.7 (11.3 - 20.1)	15.1 (11.6 - 18.7)	12.6 (10.1 – 15.6)
National	30.2 (29.1 - 31.2)	29.1 (28.3 - 29.9)	28.0 (26.9 – 29.1)

The HIV prevalence estimate in older age groups (30 – 34 years and 35 – 39 years) is of concern as it remains at similar levels with a tendency towards an increase. The HIV prevalence has significantly increased in these specific age groups, from 37.0% in 2006 to 40.2% in 2007 and 29.30% in 2006 to 33.2% in 2007 respectively [Table 1.2].

The decline in the age group (15-19years) particularly, implies a reduction in new infections (incidence) in the general population [10].

Table 1.2 National HIV prevalence estimates by age group among antenatal clinic attendees, South Africa, 2005 – 2007.

Age Group (Years)	2005 HIV prev. (CI 95%)	2006 HIV prev. (CI 95%)	2007 HIV prev. (CI 95%)
15 – 19	15.9 (14.6 - 17.2)	13.7 (12.8 - 14.6)	12.9 (12.1 – 13.8)
20 – 24	30.6 (29.0 - 32.2)	28.0 (26.9 - 29.1)	28.1 (27.3 – 29.0)
25 – 29	39.5 (37.7 - 41.3)	38.7 (37.3 - 40.2)	37.9 (36.8 – 39.0)
30 – 34	36.4 (34.3 - 38.5)	37.0 (35.5 - 38.5)	40.2 (38.8 – 41.6)
35 – 39	28.0 (25.2 - 30.8)	29.3 (27.7 - 31.5)	33.2 (31.4 – 35.0)
>40	19.8 (16.1 - 23.6)	21.3 (18.5 - 24.1)	21.5 (16.9 – 27.1)

Antenatal surveys are not designed to provide information on HIV prevalence in the overall population (men, non-pregnant women and even children). These estimates are derived using mathematical models on the basis of antenatal survey data. The UNAIDS Spectrum model (UNAIDS, 2002) has been used. The number of people who are estimated to have HIV infection is approximately 5.27 million. The HIV prevalence amongst adults 15-49 years is estimated at 17.64% [2].

1.1.2 Classification of HIV

HIV disease staging and classification systems are critical tools for tracking and monitoring the HIV epidemic and for providing clinicians and patients with important information about HIV disease stage and clinical management. Two major classification systems currently are in use: the U.S. Centers for Disease Control and Prevention

(CDC) classification system and the World Health Organization (WHO) Clinical Staging and Disease Classification System [11].

The WHO clinical staging system for HIV/ AIDS was developed in 1990 and emphasized the use of clinical parameters to guide clinical decision-making for the management of HIV/AIDS patients. It was designed for use in resource-limited settings such as limited access to laboratory services. The WHO clinical staging system has been widely used in resource-limited countries, particularly in the African Region, and has proved pragmatic and useful in facilities at both the first and referral level [12].

In contrast to the WHO system, the CDC disease staging system assesses the severity of HIV disease by CD4 cell counts and by the presence of specific HIV-related conditions. The definition of AIDS includes all HIV-infected individuals with CD4 counts of <200 cells/ μ L (or CD4 percentage <14%) as well as those with certain HIV-related conditions and symptoms. Although the fine points of the classification system rarely are used in the routine clinical management of HIV-infected patients, a working knowledge of the staging criteria (in particular the definition of AIDS) is useful in patient care. In addition, the CDC system is used in clinical and epidemiologic research [11].

In response to the changing landscape of HIV/AIDS, particularly in resource-limited settings, and specifically to support scale up of anti-retroviral treatment, revisions and harmonization of the clinical staging and case definitions for surveillance are required [12]. The WHO clinical staging of HIV/AIDS is universally used in South Africa and presented in summary [table 1.3]

Table 1.3 WHO Clinical Staging of HIV/AIDS for Adults and Adolescents

Primary HIV Infection

- Asymptomatic
- Acute retroviral syndrome

Clinical Stage 1

- Asymptomatic
- Persistent generalized lymphadenopathy

Clinical Stage 2

- Moderate unexplained weight loss (<10% of presumed or measured body weight)
- Recurrent respiratory infections (sinusitis, tonsillitis, otitis media, and pharyngitis)
- Herpes zoster
- Angular cheilitis
- Recurrent oral ulceration
- Papular pruritic eruptions
- Seborrheic dermatitis
- Fungal nail infections

Clinical Stage 3

- Unexplained severe weight loss (>10% of presumed or measured body weight)
- Unexplained chronic diarrhea for >1 month
- Unexplained persistent fever for >1 month (>37.6°C, intermittent or constant)
- Persistent oral candidiasis (thrush)
- Oral hairy leukoplakia
- Pulmonary tuberculosis (current)
- Severe presumed bacterial infections (eg, pneumonia, empyema, pyomyositis, bone or joint infection, meningitis, bacteremia)
- Acute necrotizing ulcerative stomatitis, gingivitis, or periodontitis
- Unexplained anemia (hemoglobin <8 g/dL)
- Neutropenia (neutrophils <500 cells/ μ L)
- Chronic thrombocytopenia (platelets <50,000 cells/ μ L)

Table 1.3 WHO Clinical Staging of HIV/AIDS for Adults and Adolescents continued.

Clinical Stage 4

- HIV wasting syndrome, as defined by the CDC (see Table 3, above)
- Pneumocystis pneumonia
- Recurrent severe bacterial pneumonia
- Chronic herpes simplex infection (orolabial, genital, or anorectal site for >1 month or visceral herpes at any site)
- Esophageal candidiasis (or candidiasis of trachea, bronchi, or lungs)
- Extrapulmonary tuberculosis
- Kaposi sarcoma
- Cytomegalovirus infection (retinitis or infection of other organs)
- Central nervous system toxoplasmosis
- HIV encephalopathy
- Cryptococcosis, extrapulmonary (including meningitis)
- Disseminated nontuberculosis Mycobacteria infection
- Progressive multifocal leukoencephalopathy
- Candida of the trachea, bronchi, or lungs
- Chronic cryptosporidiosis (with diarrhea)
- Chronic isosporiasis
- Disseminated mycosis (eg, histoplasmosis, coccidioidomycosis, penicilliosis)
- Recurrent nontyphoidal Salmonella bacteremia
- Lymphoma (cerebral or B-cell non-Hodgkin)
- Invasive cervical carcinoma
- Atypical disseminated leishmaniasis
- Symptomatic HIV-associated nephropathy
- Symptomatic HIV-associated cardiomyopathy
- Reactivation of American trypanosomiasis (meningoencephalitis or myocarditis)

1.2 Oral and oropharyngeal manifestations of HIV

The oral cavity is one of the most common sites of HIV infection and may be the initial site of symptoms and signs. Oral manifestations of HIV include adenotonsillar hypertrophy, oral candidiasis, angular cheilitis, oral hairy leukoplakia, Kaposi sarcoma, herpes virus and non-Hodgkins lymphoma. The otorhinolaryngological abnormalities in HIV patients have been reported, but the literature is lacking a description of their occurrence during the earlier stages of the HIV infection. A study presented at the international AIDS conference in 1992 reported that out of 210 asymptomatic patients

only 16% had a normal ENT examinations, 27% had palpable neck nodes (greater than 1, less than 3 cm), 7% neck mass (greater than 3 cm), 43% nasopharyngeal lymphatic tissue hyperplasia (particularly during earlier stages), 8% extranodal non-Hodgkin's lymphomas, 7% Kaposi's sarcoma, 18% oral hairy leukoplakia, 22% oral/pharyngeal candidiasis, 2% benign lymphoepithelial cyst of the parotid gland [13]. However there was no mention of peritonsillar abscess or deep neck space infections related to HIV.

Based on standard classification and diagnostic criteria, common HIV-associated oral disorders can be broadly classified into four categories by pathophysiological process: infection (fungal, viral, bacterial), neoplasm, immune-mediated, and other (xerostomia, pain syndromes, and nutritional) [14], [table 1.4]

Table 1.4 Classifications of Oral Manifestations of HIV

<i>Common HIV-Associated Oral Disorders</i>	
INFECTION	
Fungal:	candidiasis; cryptococcus; histoplasmosis; aspergillosis.
Viral:	herpes simplex virus; oral hairy leukoplakia (Epstein-Barr); human papilloma virus; cytomegalovirus.
Bacterial:	bacillary angiomatosis (<i>Rochalimaea henselae</i>); linear erythematous gingivitis; necrotizing ulcerative periodontitis; syphilis (<i>Treponema pallidum</i>).
NEOPLASM:	
Fungal:	Kaposi's sarcoma.
Viral:	non-Hodgkin's lymphoma.
IMMUNE-MEDIATED:	
Fungal:	major aphthous.
Viral:	necrotizing stomatitis.
OTHER:	
Fungal:	xerostomia; parotid disease.
Viral:	pain syndromes.
Bacterial:	nutritional.

No particular oral lesion is uniquely associated with HIV infection. However, the presence of one or more lesions requires that HIV infection be considered as a possible underlying cause. Some oral lesions, such as oral candidiasis and oral hairy leukoplakia, are so strongly associated with HIV infection that they have been incorporated into the Centers for Disease Control and Prevention clinical classification of HIV disease [11]. Indeed, the emergence of one or more oral lesions correlates highly with HIV progression. A CD4 lymphocyte count of less than 200/mm³ is a reliable prognosticator of active disease and probability of shortened lifespan [15–17]. The spectrum of HIV associated oral lesions also varies with transmission risk-factor, gender, age, and health-care access.

1.2.1 Fungal Infections

The most common HIV-related oral lesion is candidiasis, predominantly due to *Candida albicans*. While *Candida* can be isolated from 30–50% of the oral cavities of healthy adults, making it a constituent of the normal oral flora, clinical oral candidiasis rarely occurs in healthy patients [18, 19]. In stark contrast, clinical oral candidiasis has been reported to occur in 17–43% of patients with HIV infection and in more than 90% of patients with AIDS [20–22]. One report found that unexplained oral candidiasis in healthy adults with risk factors for HIV infection predicted the development of clinical signs of AIDS within 3 months [23].

Based on clinical appearance, oral candidiasis can appear as one of four distinct clinical entities: erythematous or atrophic candidiasis, pseudomembranous candidiasis, hyperplastic or chronic candidiasis, and angular cheilitis. In all cases, the infection is superficial. While in most instances the clinical appearance is adequate to arrive at a diagnosis, simple exfoliative cytology will identify the characteristic budding yeast and

hyphae when the clinical diagnosis is uncertain. The appearance of each clinical type of candidiasis is summarized in Table 1.5. Treatment of oral candidiasis is determined by the clinical type, distribution, and severity of infection [24].

Table 1.5 Clinical types of Candidiasis

Type	Appearance	Significance
Erythematous /Atrophic disease	erythematous or atrophic macular patches on palate, buccal mucosa, and tongue	associated with early HIV
Pseudomembranous	yellow-white plaque which can be easily wiped away; any mucosal surface	associated with initial and progressive immune deterioration; CD4<400
Hyperplastic / Chronic	white non-removable plaque; may be stained by food; any mucosal surface	associated with severe immune suppression / long-standing disease; may be associated with increased risk for carcinoma.
Angular Cheilitis	radiating fissures from labial commissure, sometimes covered with a pseudomembrane	can occur during all stages of HIV disease; xerostomia may be a contributing factor.

Unlike the superficial infection of candidiasis, several systemic fungal infections can infrequently lead to single or multiple, deep oral lesions with the potential for considerable local tissue destruction. Cryptococcosis, histoplasmosis, aspergillosis, and mucormycosis are uncommon oral deep fungal infections which require histological diagnosis. Treatment typically requires the use of intravenous antifungal therapy with amphotericin.

1.2.2 Viral Infections

Herpes virus accounts for the majority of HIV-related oral viral infections, most frequently as recurrent oral herpes due to herpes simplex virus (HSV) or Epstein-Barr virus (EBV)-induced oral hairy leukoplakia (OHL) [25]. Less commonly occurring viral infections involving the oral cavity include cytomegalovirus and human papilloma virus.

Intraoral herpes in healthy individuals results in multiple, small, shallow ulcerations with irregular raised white borders. Small clusters of lesions usually coalesce to form a larger ulcer, which heals uneventfully in 7–10 days. While the prevalence of seropositive HSV and the rate of reactivation is similar among both HIV-infected and non-infected populations, estimated to be 60% for those older than 30 years of age, recurrent intra-oral HSV in patients with HIV infection often results in ulceration and pain of longer duration [26-27]. Recurrent intra-oral HSV lesions occur more commonly on poorly keratinized tissue like the buccal and labial mucosa, an uncommon site in healthy individuals [28].

Although Oral Hairy Leukoplakia (OHL) was originally postulated to be pathognomonic for HIV infection [29], this lesion has subsequently been reported in other immune deficiency states as well as in immunocompetent individuals [30, 31]. It appears as an asymptomatic adherent white patch with vertical corrugations, most commonly on the lateral borders of the tongue. It may infrequently be confused with hypertrophic candidiasis and is predominantly found in homosexual males.

Oral hairy leukoplakia has since been shown to be associated with a localized Epstein-Barr virus (EBV) infection and occurs most commonly in individuals whose CD4 lymphocyte count is less than 200/mm³ [17]. While the diagnosis is most often clinical, histological inspection will reveal typical epithelial hyperplasia suggestive of EBV infection. This asymptomatic lesion does not require treatment. However, for cosmetic purposes, some patients may request treatment. Oral acyclovir (3,200 mg daily in divided doses), topical podophyllum resin, retinoids, and surgical removal have all been reported as successful treatments. In most cases, the lesion returns after initial therapy, thus requiring prophylactic treatment with acyclovir 200 mg daily [32-34].

1.2.3 Bacterial infections

Although isolated cases of oral infection with *Klebsiella pneumoniae*, *Enterobacter cloacae*, *Actinomyces israelii*, *Escherichia coli*, and *Mycobacterium avium intracellulare* have been reported in patients with HIV infection, the most common oral lesions associated with bacterial infection are linear erythematous gingivitis, necrotizing ulcerative periodontitis, and much less commonly, bacillary epithelioid angiomatosis and syphilis. In the case of the periodontal infections, the bacterial flora is no different from that of a healthy individual with periodontal disease. Thus, the clinical lesion is a manifestation of the altered immune response to the pathogens [35].

While the prevalence of syphilis infection has risen significantly over the past decade, it is an uncommon cause of intraoral ulceration, even in HIV infection. Its appearance is no different from that observed in healthy individuals; it is a chronic, non-healing, deep, solitary ulceration; often clinically indistinguishable from that due to tuberculosis, deep fungal infection, or malignancy. Dark field examination may demonstrate treponema.

Positive reactive plasma reagin (RPR) and histological demonstration of *Treponema pallidum* is diagnostic. Patients with newly diagnosed syphilis should be referred to their physicians for evaluation and treatment; combination treatment with penicillin, erythromycin and tetracycline is the treatment of choice, the dosage and duration of treatment depending on presence or absence of neurosyphilis [35].

1.2.4 Neoplasms

Kaposi's sarcoma (KS) is the most common intraoral malignancy associated with HIV infection. Recognition of the lesion is essential, since oral KS is often the first manifestation of the disease and is a diagnostic criterion for AIDS [11]. The lesion may appear as a red-purple macule, an ulcer, as a nodule or mass. Intraoral KS occurs on the heavily keratinized mucosa, the palate being the site in more than 90% of reported cases. However, lesions have also been reported on the gingivae, tongue, and buccal mucosa. The skin should also be examined for lesions whenever oral lesions are discovered. KS is especially common among homosexual and bisexual males and is rarely found in HIV-infected women [36-38].

A new human herpes virus (HHV8) has recently been demonstrated to be an important cofactor in the development of KS, and prophylaxis with foscarnet and ganciclovir, but not acyclovir, has been shown to reduce the incidence of KS in a large at-risk cohort [39, 40]. Definitive diagnosis of KS requires histological examination.

There is no cure for KS. Therapy for intraoral KS should be instituted at the earliest sign of the lesion, the goal being local control of the size and number of lesions. When only

one or a few lesions exist and the lesions are small (<1 cm), intralesional chemotherapy is effective. Radiation therapy (800–2,000 cGy) is effective for larger or multiple lesions.

Non Hodgkins Lymphoma is the most common lymphoma associated with HIV infection and is usually seen in late stages with CD4 lymphocyte counts of less than 100/mm³. It appears as a rapidly enlarging mass, less commonly as an ulcer or plaque, and most commonly on the palate or gingivae. NHL may be indistinguishable from masses caused by KS or other diseases in HIV-infected patients. Histological examination is essential for diagnosis and staging. Prognosis is poor, with mean survival time of less than one year, despite treatment with multi-drug chemotherapy [41].

1.3 Peritonsillar Abscess

1.3.1 Prevalence and Etiology

Peritonsillar abscess most commonly occurs in adult patients during November to December and April to May, which coincides with the highest incidence rates of streptococcal pharyngitis and exudative tonsillitis [42]. Peritonsillar abscess has traditionally been regarded as the end point of a continuum that begins as acute exudative tonsillitis, progresses to cellulitis, and eventually forms an abscess.

A recent review implicates Weber's glands as playing a key role in the formation of peritonsillar abscesses [43, 44]. This group of 20 to 25 mucous salivary glands are located in the space just superior to the tonsil in the soft palate and are connected to the surface of the tonsil by a duct [44]. The glands clear the tonsillar area of debris and

assist with the digestion of food particles trapped in the tonsillar crypts. If Weber's glands become inflamed, local cellulitis can develop. As the infection progresses, the duct to the surface of the tonsil becomes progressively more obstructed from surrounding inflammation. The resulting tissue necrosis and pus formation produce the classic signs and symptoms of peritonsillar abscess [45].

These abscesses generally form in the area of the soft palate, just above the superior pole of the tonsil, in the location of Weber's glands. The occurrence of peritonsillar abscesses in patients who have undergone tonsillectomy further supports the theory that Weber's glands have a role in the pathogenesis. Other clinical variables include significant periodontal disease and smoking [43].

A peritonsillar abscess is a polymicrobial infection, but Group A streptococcus is the predominate organism [43]. Common organisms associated with peritonsillar abscess are shown in table 1.6

Table 1.6 Common organisms

Aerobic bacteria	Anaerobic bacteria
Group A streptococcus	Fusobacterium
<i>Staphylococcus aureus</i>	Peptostreptococcus
<i>Haemophilus influenzae</i>	Pigmented Prevotella

1.3.2 Relevant Anatomy

The palatine tonsils are paired lymphoid organs found between the palatoglossal and palatopharyngeal folds of the oropharynx. They are surrounded by a thin capsule that separates the tonsil from the superior and middle constrictor muscles. The anterior and posterior pillars form the front and back limits of the peritonsillar space. Superiorly, this potential space is related to the torus tubarius, while inferiorly it is bounded by the pyriform sinus [44].

Composed solely of loose connective tissue, a severe infection may rapidly result in pus formation. The inflammation and suppurative process may extend to involve the soft palate, the lateral wall of the pharynx, and, occasionally, the base of the tongue. The tonsillar fossa has a rich network of lymphatic vessels leading to the parapharyngeal space and the upper cervical lymph nodes, which explains the pattern of adenopathy observed clinically. Ipsilateral upper cervical lymphadenopathy is the result of the spread of infection to the regional lymphatics. Occasionally, the severity of the suppurative process may lead to a cervical abscess, especially in very fulminant or rapidly progressive cases [43, 44].

The tonsils form during the last months of gestation and grow irregularly, reaching their largest size at approximately six or seven years of age. The tonsils begin to gradually involute at puberty, and by older age little tonsillar tissue remains [46]. When healthy, the tonsils do not project beyond the tonsillar pillars medially [47].

1.3.3 Clinical Manifestations

Patients with peritonsillar abscess appear ill and present with fever, malaise, sore throat, dysphagia, or otalgia. The throat pain is markedly more severe on the affected side and is often referred to the ear on the same side. Physical examination usually reveals varying degrees of trismus, with the patient having difficulty opening his or her mouth because of pain from inflammation and spasm of masticator muscles [43]. Swallowing is also highly painful, resulting in pooling of saliva or drooling [48]. Patients often speak in a muffled voice (also called “hot potato voice”).

Markedly tender cervical lymphadenitis may be palpated on the affected side. Inspection of the oropharynx reveals tense swelling and erythema of the anterior tonsillar pillar and the soft palate overlying the infected tonsil. The tonsil is generally displaced inferiorly and medially with contralateral deviation of the uvula.

1.3.4 Diagnosis

The diagnosis of peritonsillar abscess is often made on the basis of a thorough history and physical examination. Differential diagnosis includes infectious mononucleosis, lymphoma, peritonsillar cellulitis, and retromolar or retropharyngeal abscess. Patients often present with peritonsillar cellulitis with the potential to progress to abscess formation. In peritonsillar cellulitis, the area between the tonsil and its capsule is oedematous and erythematous, but pus has not yet formed [5].

On occasions when the diagnosis of peritonsillar abscess is in question, the presence of pus on needle aspiration or radiological testing may help confirm the diagnosis. Transcutaneous or intraoral ultrasonography also can be helpful in identifying an abscess and

in distinguishing peritonsillar abscess from peritonsillar cellulites [5, 43]. If spread of the infection beyond the peritonsillar space or complications involving the lateral neck space are suspected, computed tomography (CT) or magnetic resonance imaging (MRI) is indicated.

1.3.5 Management

Drainage of the abscess, antibiotics, and supportive therapy to maintain hydration and pain control are the foundation of treatment for peritonsillar abscess. The main procedures for the drainage of peritonsillar abscess are needle aspiration, incision and drainage, and immediate tonsillectomy.

Drainage using any of these methods combined with antibiotic therapy will result in resolution of the peritonsillar abscess in more than 90 percent of cases [43]. The acute surgical management of peritonsillar abscess has evolved over time from routine immediate tonsillectomy to increased use of incision and drainage or needle aspiration [49]. Immediate abscess tonsillectomy has not been proven to be any more effective than needle aspiration or incision and drainage, and it is considered to be less cost-effective [50]. Several studies comparing needle aspiration with incision and drainage have found no significant statistical differences in outcomes [49, 50].

Although it is not routinely performed for the treatment of peritonsillar abscess, immediate tonsillectomy should be considered for patients who have strong indications for tonsillectomy, including those who have symptoms of sleep apnoea, a history of recurrent tonsillitis (four or more infections per year despite adequate medical therapy), or a recurrent or nonresolving peritonsillar abscess[43]. Initial empiric antibiotic therapy

should include antimicrobials effective against Group A streptococcus and oral anaerobes [51].

Several studies have shown intravenous penicillin alone to be as clinically effective as broader-spectrum antibiotics, provided the abscess has been adequately drained [50,52]. In these studies, inadequate clinical response following 24 hours of antibiotic therapy played a significant role in the decision to use broad-spectrum antibiotics. Several other studies have reported that more than 50 percent of culture results demonstrated the presence of beta-lactamase producing anaerobes, leading many physicians to use broader-spectrum antibiotics as first-line therapy [45, 52].

1.3.6 Complications

Potential complications of peritonsillar abscess include extension into deep spaces in the neck (parapharyngeal abscess), airway obstruction, aspiration, or haemorrhage from erosion or septic necrosis into the carotid sheath [43]. See table 1.7

Table 1.7 Complications of Peritonsillar Abscess

Airway obstruction
Aspiration pneumonitis or lung abscess secondary to peritonsillar abscess rupture
Death secondary to hemorrhage from erosion or septic necrosis into carotid sheath
Extension of the infection into the tissues of the deep neck or posterior mediastinum
Poststreptococcal sequelae (e.g., glomerulonephritis, rheumatic fever) when infection is caused by Group A streptococcus

CHAPTER 2 - MATERIALS AND METHODS

2.0 Justification of the Study

There has been only one documented study describing the relationship between peritonsillar abscess and the HIV status of patients (1995). Conclusions drawn from this study revealed a HIV positive rate of 18% in patients with peritonsillar abscess, higher than the adult prevalence rate of 17.6 % from Statistics South Africa 2008, coupled with the absence of HIV symptoms [53]. Due to the high incidence of head and neck manifestations in HIV positive patients identifying a clinical marker (quinsy) in the earlier stages of HIV infection would allow for better screening, earlier diagnosis and treatment of HIV infection.

2.1 Purpose of the Study

Hypothesis: *“The clinical characteristics and/or management of peritonsillar abscess will be affected by the HIV status of patients ”*

2.1.1 Aim

The overall aim of this project was to assess the relationship between peritonsillar abscess and the HIV status of patients admitted to the adult ENT wards at the Chris Hani Baragwanath Hospital.

2.1.2 Specific Objectives

1. Determine the prevalence of HIV in patients with peritonsillar abscess.
2. Describe:
 - Demographic details of HIV positive patients with peritonsillar abscess with regards to age, gender and race
 - Presenting clinical features of peritonsillar abscess which include
 - Pyrexia
 - Trismus
 - Site of Peritonsillar swelling (unilateral/bilateral)
 - Lymphadenopathy
 - Pus aspirated and if incision and drainage performed
 - Associated oral and oropharyngeal manifestations of HIV (candida, angular cheilitis, oral hairy leukoplakia, Kaposi's sarcoma and lymphoma) in patients with peritonsillar abscess
 - Laboratory features, including
 - HIV Rapid and Elisa
 - Determine if HIV affects the length of treatment, complications and hospital stay in patients with peritonsillar abscess

2.2 Study Design

This was an analytical cross sectional study utilising retrospective clinical data. This involved analysis of retrospective data from ward registers, patient records, treatment registers and National Health Laboratory System (NHLS) databases.

2.3 Study Setting

The study was conducted in the adult ENT ward at the Chris Hani Baragwanath Hospital. Being primarily based at this hospital as an ENT registrar and aware of the record keeping and protocols for admission and management, I opted to use this study sample. This hospital, with its 2 888 beds, is the largest acute care hospital in the world. It is situated to the south west of Johannesburg, on the southern border of Soweto. The Hospital grounds cover an area of 173 acres, consisting of 429 buildings with a total floor area of 233 785 m². The hospital has a staff establishment of nearly 5000, 600 are doctors and 2 000 are nurses. It is the only public hospital serving ±3, 5 million people in Soweto and provides half of all the hospital services in Southern and Western Gauteng [7]. The study sample consisted of patient records over a 4 year period from January 2005 to December 2008. The study population included all patients admitted to the ENT ward with peritonsillar abscess who have been tested for HIV.

2.4 Data Collection

Patients included in this study were identified by using the ward register to search for the discharge diagnosis (Peritonsillar abscess/ Quinsy). The Patient name and hospital number were obtained and records retrieved from records department. Laboratory information (HIV rapid/elisa) was accessed via data recorded in the NHLS database. Data collection sheets were utilized for the record reviews [Figure 2.1].

The following data was extracted from patient records onto the data capture sheet

- HIV status and peritonsillar abscess by gender, age and race
- Clinical presentation including oral manifestations of HIV (candida, angular cheilitis, oral hairy leukoplakia, Kaposi sarcoma and lymphoma and other)
- Number of days admitted

- Antibiotics used
- Aspiration and/or Incision and Drainage
- Complications

Figure 2.1 DATA COLLECTION SHEET

Patient Identity No.		1			2			3			4			5			6		
Demographic details	Age																		
	Gender																		
	Race																		
Clinical presentation of Quinsy	Temp(Pyrexial)	Y	N		Y	N		Y	N		Y	N		Y	N		Y	N	
	Trismus	Y	N		Y	N		Y	N		Y	N		Y	N		Y	N	
	Aspirate	Y	N		Y	N		Y	N		Y	N		Y	N		Y	N	
	LN	Y	N		Y	N		Y	N		Y	N		Y	N		Y	N	
	Site	L	R	B	L	R	B	L	R	B	L	R	B	L	R	B	L	R	B
Oral manifestation of HIV	Candida	Y	N		Y	N		Y	N		Y	N		Y	N		Y	N	
	Angular Cheilitis	Y	N		Y	N		Y	N		Y	N		Y	N		Y	N	
	Hairy Leukoplakia	Y	N		Y	N		Y	N		Y	N		Y	N		Y	N	
	Kaposi	Y	N		Y	N		Y	N		Y	N		Y	N		Y	N	
	Lymphoma	Y	N		Y	N		Y	N		Y	N		Y	N		Y	N	
	Other																		
Laboratory	HIV (Rapid/Elisa)																		
Management	Days Admitted																		
	Antibiotics used																		
	Aspiration	Y	N		Y	N		Y	N		Y	N		Y	N		Y	N	
	Incision+Drainage	Y	N		Y	N		Y	N		Y	N		Y	N		Y	N	
	Complications																		

2.5 Inclusion and Exclusion Criteria

All patients admitted to the ENT ward with the diagnosis of peritonsillar abscess during the 4 year period were reviewed. In this study period 450 patient files were reviewed of which 291 fulfilled the inclusion criteria. There were 3 exclusion criteria:

- Incomplete or lost Files, 54 patients
- Not tested for HIV or Refused HIV testing, 84 patients
- Not confirmed Peritonsillar abscess (negative aspirate), 21 patients

2.6 Data Analysis

Numerical data from the records reviewed were coded and captured onto Excel spreadsheets and transferred to STATA-10 software for analysis by computer. To protect the integrity of the database, I wrote-protected the Excel data and stored it in two safe places (CD-ROM and dedicated memory stick) and then only worked with copies.

Descriptive statistics (proportions) were employed to summarize the data. Measures of spread, central tendency and association will be calculated. The analytical tests that were used to determine associations are chi square test for categorical variables, and unpaired 't' test when two groups of continuous data will be compared. Differences will be considered statistically significant if the 'p' value is less than 0.05.

2.7 Limitations

- Retrospective Study – Rely on existing primary data of which the quality and consistency of the patient records may vary.
- Loss of patient records thereby excluding them from the study
- Study performed only at one institute (not multicentre study). The results may not be generalizable to other districts or provinces in the country.

2.8 Ethical and Legal Considerations

This study was approved by the Ethics Committee (medical) of the University of the Witwatersrand (clearance no. MP090638). Permission has been granted from the CEO of Chris Hani Baragwanath Hospital, National Health Laboratory Services and the Head of ENT Department to access patient files and laboratory results for the purpose of completing this Mmed research report.

This was a retrospective study in which all patient information and data were accessed from existing records. All HIV results on patients included in this study have been tested as per ward protocols which included pre and post test counselling, as well as referral for further management and follow up.

Data analyzed did not include patient names or hospital numbers but had patient identifiers which were only known to the researcher and all records and documentation housed securely. Electronic records were maintained in password protected computers.

CHAPTER 3 – RESULTS

3.1 Sample studied

In this study period 450 patient files were reviewed of which 291 (64.7%) fulfilled the inclusion criteria. One hundred and fifty nine patients were excluded from the study due to incomplete or lost files, not tested for HIV and no confirmed peritonsillar abscess. The age ranged from 15 to 63 years with a mean (SD) 29.3 years (9.58). From the 291 patients, 86 (29.55%) were HIV positive.

3.2 Demographic Data

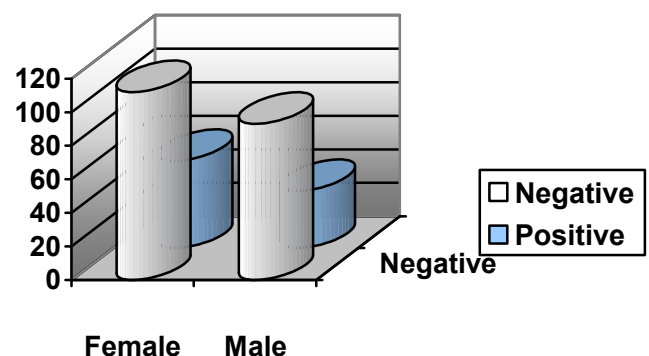
3.2.1 Gender

The study sample consisted of 164 females (56.36%) and 127 males (43.64%) with a female to male ratio of 1.29 to 1. Among the 86 HIV positive patients, 52 were female and 34 male, with a gender ratio of 1.53F: 1M [Table 3.1, Figure 3.1]. No statistical difference in HIV status was noted.

Table 3.1 :HIV status by gender

HIV	Female	Male	Total
Negative	112	93	205
Positive	52	34	86
Total	164	127	291

Figure 3.1 :HIV Status by Gender



P- value = 0.360

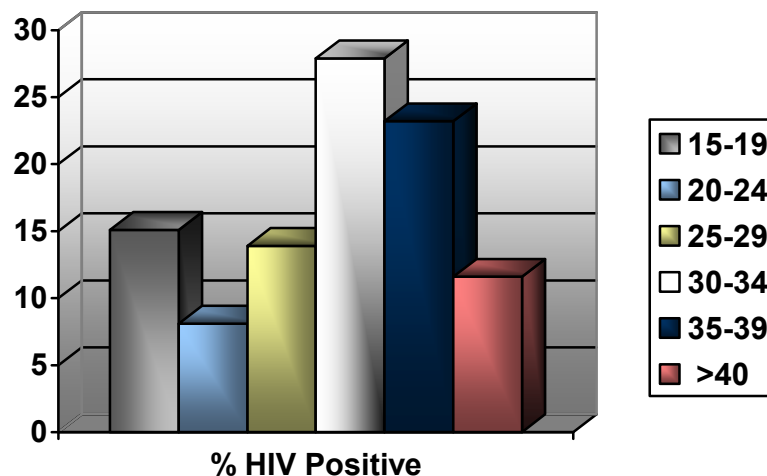
3.2.2 Age

The age ranged from 15 to 63 years with a mean (SD) 29.3 years (9.58). From the 86 HIV positive patients, the age group 30-34 showed the highest HIV positive rate of 27.9% [Table 3.2, Figure 3.2]. Two-sample t test revealed a mean (SD) age of 28.7years (9.67) in the HIV negative group and a mean (SD) age of 30.89years (9.58) in the HIV positive group. No statistical significance was noted (P=0.0815).

Table 3.2 : HIV positive % by Age Group

Age Group (Years)	% HIV Positive
15-19	15.1
20-24	8.1
25-29	13.9
30-34	27.9
35-39	23.2
>40	11.6

Figure 3.2 : HIV positive % by Age Group



3.2.3 Race

Two hundred and thirty-six patients (81.1%) were Black, of whom 74 (31.36%) were HIV positive. The Coloured patients had a 20% HIV positive rate, whilst from the 9 Indian patients admitted 3 were positive (33.33%). The White patient population had a HIV positive rate of 18.18% [Table 3.3, Figure 3.3].

Table 3.3 : HIV Status by Race

HIV	Black	Coloured	Indian	White	Total
Negative	162	28	6	9	205
Positive	74	7	3	2	86
Total	236	35	9	11	291

P- value = 0.449

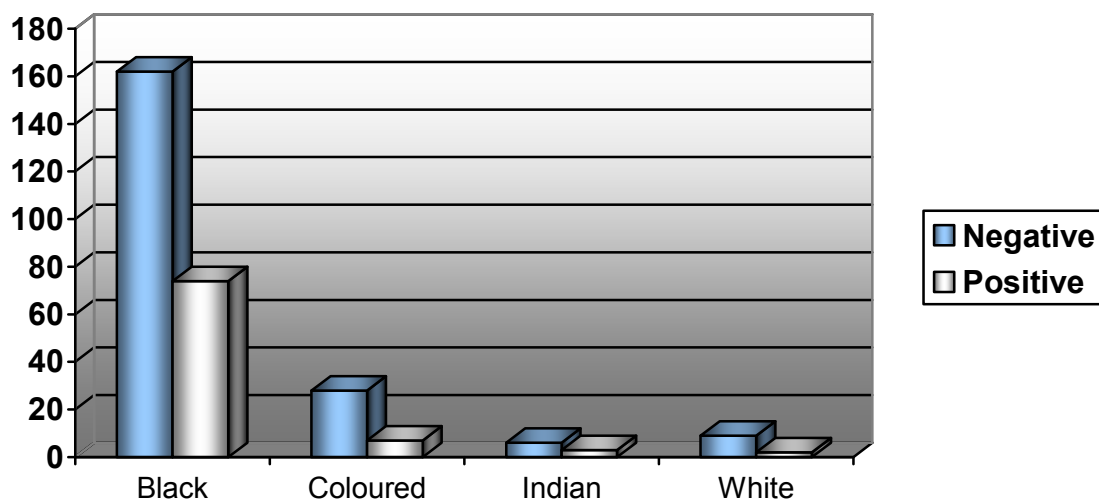


Figure 3.3: HIV Status by Race

3.3 Clinical Features of peritonsillar abscess

3.3.1 Temperature

The temperature ranged from 36°C to 39.5°C. From the 291 patients a mean (SD) temperature of 37.77°C (2.32°C) was noted. The t- test revealed no statistical difference (P=0.2056).

3.3.2 Trismus

Two hundred and eighteen patients (74.9%) presented with trismus of which 69 (31.65%) were HIV positive [table 3.4]. From the clinical notes trismus was not adequately graded but its presence clearly documented. There was no Statistical significance noted (P=0.217).

Table 3.4 : HIV status by Trismus

HIV Status	No Trismus	Trismus	Total
Negative	54	149	203
Positive	19	69	88
Total	73	218	291

P- value = 0.217

3.3.3 Site of Abscess

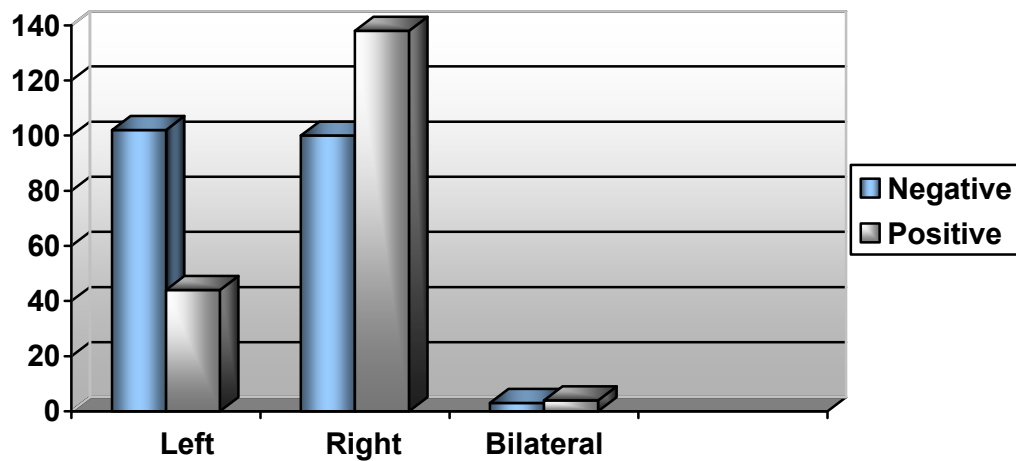
One hundred and forty-six patients (50.17%) presented with a left sided peritonsillar abscess. Seven patients presented with bilateral abscess of which 4 were HIV positive [Table 3.5, Figure 3.4].

Table 3.5 : HIV status by Site

HIV Status	Left	Right	Bilateral	Total
Negative	102	100	3	205
Positive	44	138	4	86
Total	146	218	7	291

Fisher's Exact P- value = 0.240

Figure 3.4 HIV status by Site



3.3.4 Lymphadenopathy

Forty-nine of patients (16.84%) presented with cervical lymphadenopathy of whom 17 (34.69%) were HIV negative. Thirty-two HIV positive patients (37.21%) had cervical lymphnodes. There was no mention of generalized lymphadenopathy in the clinical notes. A statistical significance was noted with a P value of < 0.001, [table 3.6].

Table 3.6 : HIV status by Cervical Lymphnodes

HIV Status	Not palpable	Palpable	Total
Negative	188	17	205
Positive	54	32	86
Total	242	49	291

P- value <0.001

3.4 Oral Manifestations of HIV

3.4.1 Oral Candida

Candida was noted in 13 patients (4.47%), all of which were HIV positive shown in [table 3.7]. This is statistically significant with a Fisher's exact P-value < 0.001.

Table 3.7 : HIV status by presence of Candida

HIV Status	No Candida	Candida	Total
Negative	205	0	205
Positive	73	13	86
Total	278	13	291

Fisher's Exact P- value <0.001

3.4.2 Oral Hairy leukoplakia (OHL)

Only 2 patients (0.69%) presented with oral hairy leukoplakia and were in the HIV positive group shown in table 3.8. This is statistically not significant with a Fisher's exact P-value =0.087.

Table 3.8 : HIV status by OHL

HIV Status	No OHL	OHL	Total
Negative	205	0	205
Positive	84	2	86
Total	289	2	291

Fisher's Exact P- value =0.087

3.4.3 Lymphoma

Six patients (2.06%) presented with lymphoma which was diagnosed by performing tonsillectomy biopsy. The average hospital stay for these patients was 14 days and all were HIV positive [table 3.9]. Statistically significance was shown with P-value <0.001.

Table 3.9 : HIV status by Lymphoma

HIV Status	No Lymphoma	Lymphoma	Total
Negative	205	0	205
Positive	80	6	86
Total	285	6	291

P- value <0.001

3.4.4 Kaposi's Sarcoma

Only 1 patient (0.34%) presented with palatal Kaposi's sarcoma which was biopsied.

This patient also presented with pulmonary Tuberculosis. This is statistically not significant with a Fisher's exact P-value =0.296.

Table 3.10 : HIV status by Kaposi's Sarcoma

HIV Status	No Kaposi's	Kaposi's	Total
Negative	205	0	205
Positive	85	1	86
Total	290	1	291

Fisher's Exact P- value =0.296

3.4.5 Angular Chelitis

From the 291 patients in this study none presented with angular chelitis.

3.4.6 Other HIV manifestations

Two of the HIV positive patients who presented with peritonsillar abscess also had pulmonary tuberculosis. Both patients had oral Candida with one of these also having Kaposi's sarcoma.

3.5 Laboratory Data

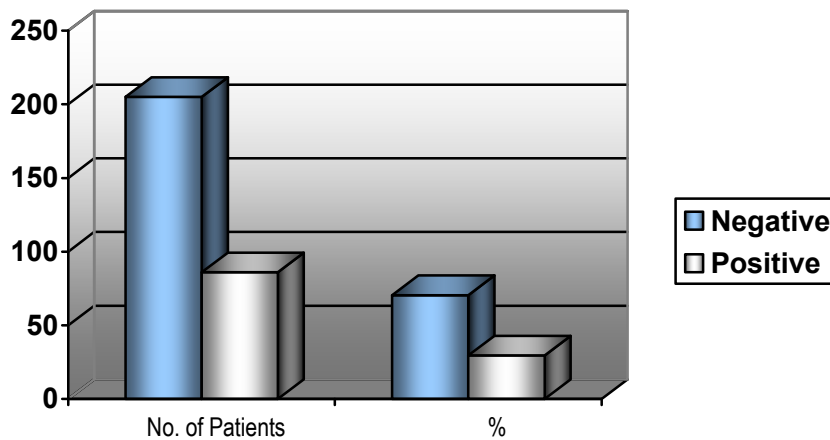
3.5.1 HIV Results (Rapid/ Elisa)

In this study sample 86 (29.55%) patients were HIV positive [Table 3.11, Figure 3.5].

Table 3.11 : Tabulation of HIV Status

HIV Status	No. of Patients	%
Negative	205	70.45
Positive	86	29.55
Total	291	100

Figure 3.5 HIV Status



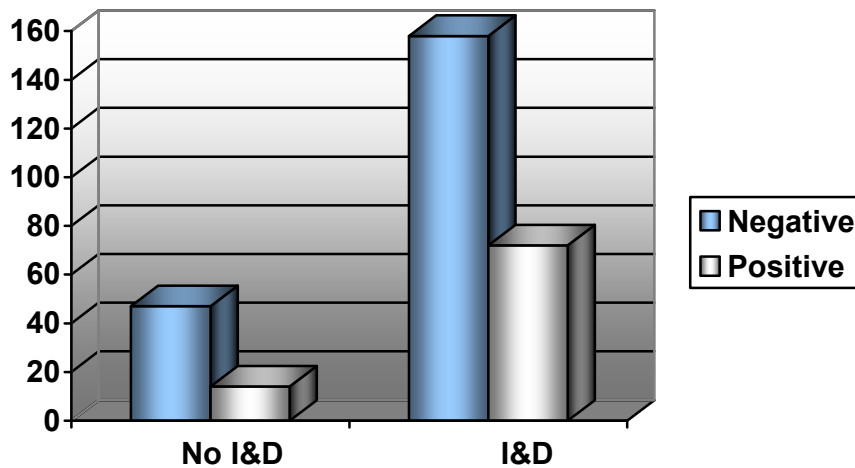
3.6 Management

3.6.1 Incision and Drainage

Aspiration of peritonsillar abscess is part of the inclusion criteria (confirming the presence of pus). From the 291 patients 230 (79.04%) had incision and drainage

performed. Eight of these patients required a repeated incision and drainage and 4 developed a parapharyngeal abscess which required an incision and drainage in theatre. Seventy-two patients (31.30%) were HIV positive shown in Figure 3.6. There was no statistical significant noted.

Figure 3.6 HIV status by Incision And Drainage



P- value = 0.204

3.6.2 Antibiotics

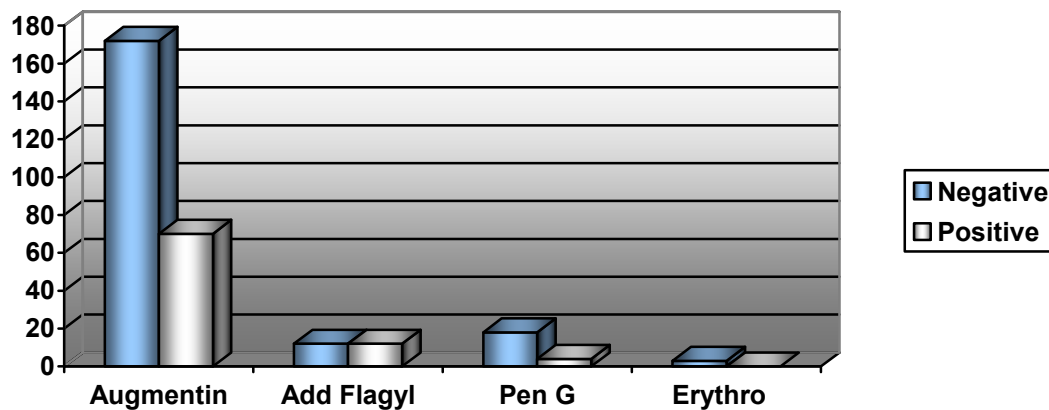
Two hundred and forty-two patients (83.16%) were treated with Augmentin. There were 24 patients (8.25%) who required the addition of a second antibiotic (Flagyl), of which 12 were HIV positive (P-value = 0.039). Two of these patients also had pulmonary TB and were started on Rifafour. Twenty-two patients were treated with Pen G while 3 patients with penicillin allergies were given Erythomycin. Table 3.12 and Figure 3.7 shows the relationship between HIV status and antibiotic use.

Table 3.12 HIV Status by Antibiotics

HIV Status	Augmentin	Add Flagyl	Pen G	Erythro	Total
Negative	172	12	18	3	205
Positive	70	12	4	0	86
Total	242	24	22	3	291

P- value =0.039

Figure 3.7 HIV status by Antibiotics



3.6.3 Tonsillectomy

There were 6 HIV positive patients who underwent tonsillectomy- biopsy which confirmed lymphoma. Only 1 patient had a quinsy- tonsillectomy and was HIV negative.

3.6.4 Complications

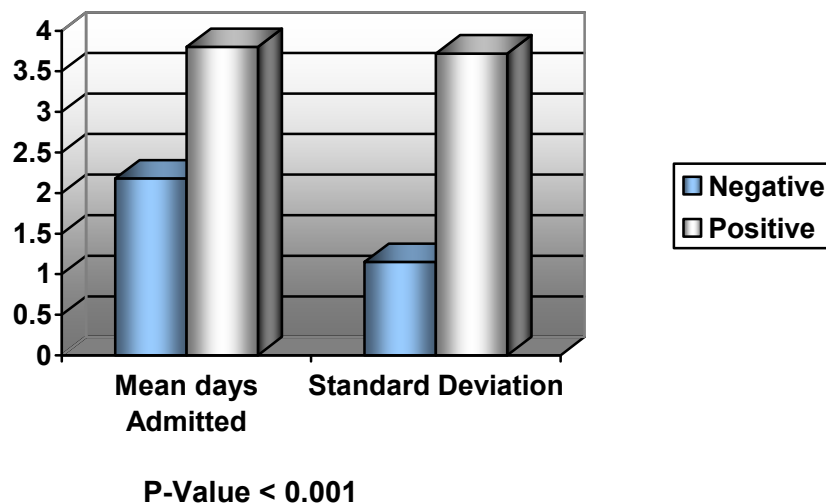
Four patients developed a parapharyngeal abscess and were taken to theatre for incision and drainage. Three were HIV positive and 1 of these patients required a tracheotomy for airway compromise.

3.6.5 Number of Days Admitted

The admission length ranged from 1 to 17 days with a mean (SD) 2.65 (2.35) days.

From the 86 HIV positive patients, the mean length of hospital stay was 3.80 days with a standard deviation of 3.72 days. [Figure 3.8]. Two-sample t test revealed a statistical significance with a P-value of <0.001.

Figure 3.8 HIV Status by Days admitted



CHAPTER 4– DISCUSSION

The overall aim of this project was to assess the relationship between peritonsillar abscess and the HIV status of patients with regards to demographic details, presenting clinical features, oral manifestations of HIV and management.

4.1 Sample Collection

In considering the findings of this study it is important to bear in mind the following limitations. Being a retrospective study I relied on existing primary data of which the quality and consistency of the patient records varied.

This study was conducted at Chris Hani Baragwanath Hospital which serves a population of $\pm 3,5$ million people in Soweto and provides half of all the hospital services in Southern and Western Gauteng [7]. Due to this large number of patients being admitted on a daily basis, accessing filed records proved to be a major challenge. From the 450 patient files reviewed 54 (12%) were incomplete or lost and 84 patients (18.6%) were not tested for HIV and subsequently excluded. Thus the absolute presentation rate of peritonsillar abscess at this hospital is inaccurate.

Another limitation of note is that this study was performed at only one institute (not multicentre study). The results may not be generalizable to other districts or provinces in this country. Two hundred and ninety-one patients fulfilled the inclusion criteria.

4.2 HIV Prevalence in Peritonsillar Abscess

HIV and AIDS is one of the major challenges facing South Africa today. The national HIV prevalence rates have been stable for several years and there is now evidence of the epidemic being on the decline. From the 291 patients included in this study, 86 (29.55%) were HIV positive. This is significantly higher than the adult (15-49years) HIV prevalence rate of 17.64% [6].

4.3 Demographic Data

There was no statistical significance for the demographic data reviewed; however there are some trends that need further discussion.

4.3.1 Gender

The study sample consisted of 164 females (56.36%) and 127 males (43.64%) with a female to male ratio of 1.29 to 1. Among the 86 HIV positive patients, 52 were female and 34 male, with a gender ratio of 1.53F: 1M. This is in keeping with the South African adult HIV prevalence gender ratio of 1.55F:1M [2]

4.3.2 Age

In this study the mean age of presentation of peritonsillar abscess was 29.3 years. The age groups 30-34 and 35-39 years showed the highest HIV positive rates of 27.9% and 23.2% respectively. This is confirmed when compared with the South African antenatal HIV survey of 2007 where there was a significant increase in these specific age groups, from 2006 to 2007 with the age group 30-34 being the highest with 40.2%. The decline

in the age group (15-19years) particularly, implies a reduction in new infections (incidence) in the general population [6].

4.3.3 Race

Two hundred and thirty-six patients (81.1%) were black, of which 31.36% were HIV positive. The large number of black patients can be explained by the fact that Chris Hani Baragwanath Hospital falls in a region with a higher black population.

4.4 Clinical Features of peritonsillar abscess

4.4.1 Temperature

The mean temperature in the HIV positive group was 37.5°C compared with the HIV negative group of 37.8°C. There was no statistical significance with HIV status

4.4.2 Trismus

Trismus was clearly documented in patient files but not adequately graded. Two hundred and eighteen patients (74.9%) presented with trismus of which 69 (31.65%) were HIV positive. No significance was noted.

4.4.3 Site of Abscess

One hundred and forty-six patients (50.17%) presented with a left sided peritonsillar abscess. Seven patients presented with bilateral abscess of which 4 were HIV positive. There was no effect of HIV on the site of the abscess.

4.4.4 Lymphadenopathy

Only the presence of cervical lymphnodes was documented in the clinical notes. There was no mention of generalized lymphadenopathy. Forty-nine patients (16.84%) presented with cervical lymphadenopathy of whom 17 (34.69%) were HIV negative. Thirty-two HIV positive patients (37.21%) had cervical lymphnodes. Analysis revealed a statistical significance; however cervical lymphadenopathy is also a common presenting sign of peritonsillar abscess.

4.5 Oral Manifestations of HIV

4.5.1 Oral Candida

Candida was noted in 13 patients (4.47%), all of which were HIV positive. There was a statistical significance noted confirming the current literature that candidiasis is a common HIV-related oral lesion. Clinical oral candidiasis has been reported to occur in 17-43% of patients with HIV infection and in more than 90% of patients with AIDS [20-22].

4.5.2 Oral Hairy Leukoplakia

Only 2 patients (0.69%) presented with oral hairy leukoplakia and were in the HIV positive group. This was not significant. OHL falls under the clinical stage 3 of the WHO classification and is not one of the common early manifestations of HIV.

4.5.3 Lymphoma

The type of lymphoma was not clearly described in the patient records. Six patients (2.06%) presented with lymphoma which was diagnosed by performing tonsillectomy biopsy. The average hospital stay for these patients was 14 days and all were HIV positive. Statistical significance was demonstrated. Lymphoma associated with HIV infection is usually seen in late stages with CD4 lymphocyte counts of less than 100/mm³ [41].

4.5.4 Kaposi's Sarcoma

Only 1 patient (0.34%) presented with palatal Kaposi's sarcoma which was biopsied. This patient also presented with pulmonary Tuberculosis (Advanced stages of HIV). Kaposi's sarcoma is the most common intraoral malignancy associated with HIV infection and is a diagnostic criterion for AIDS [11].

4.5.5 Other HIV manifestations

Not one patient presented with Angular Chelitis. Two patients with advanced HIV disease who presented with peritonsillar abscess also had pulmonary tuberculosis. Both patients had oral Candida with one of these also having Kaposi's sarcoma.

4.6 Management

Drainage of the abscess, antibiotics, and supportive therapy to maintain hydration and pain control are the foundation of treatment for peritonsillar abscess.

4.6.1 Incision and Drainage

The gold standard for diagnosis of peritonsillar abscess remains the collection of pus from the abscess through needle aspiration. A positive aspirate was part of the inclusion criteria, so all patients had the peritonsillar swelling aspirated. Two hundred and thirty patients (79.04%) had an incision and drainage performed, with 31.3% being HIV positive. Eight patients required a repeated incision and drainage and 4 developed a parapharyngeal abscess which was taken to theatre for incision and drainage. There was no significance noted.

The main procedures for the drainage of peritonsillar abscess are needle aspiration, incision and drainage, and immediate tonsillectomy. Drainage using any of these methods combined with antibiotic therapy will result in resolution of the peritonsillar abscess in more than 90 percent of cases [43]. The acute surgical management of peritonsillar abscess has evolved over time from routine immediate tonsillectomy to increased use of incision and drainage or needle aspiration [49]. Immediate abscess tonsillectomy has not been proven to be any more effective than needle aspiration or incision and drainage, and it is considered to be less cost-effective [50]. Several studies comparing needle aspiration with incision and drainage have found no significant statistical differences in outcomes [49, 50].

4.6.2 Antibiotics

Augmentin was the antibiotic of choice with 242 patients (83.16%) treated with this antibiotic. There were 24 patients (8.25%) who required the addition of a second antibiotic (Flagyl), of which 12 were HIV positive. Two of these patients also had pulmonary TB and were started on Rifampin. Twenty-two patients were treated with

Pen G while 3 patients with penicillin allergies were given Erythromycin. There was no significant difference with regards to hospital stay and resolution of symptoms in patients treated with Pen G or Augmentin.

Several studies have shown intravenous penicillin alone to be as clinically effective as broader-spectrum antibiotics, provided the abscess has been adequately drained [50, 52]. In these studies, inadequate clinical response following 24 hours of antibiotic therapy played a significant role in the decision to use broad-spectrum antibiotics. Several other studies have reported that more than 50 percent of culture results demonstrated the presence of beta-lactamase producing anaerobes, leading many physicians to use broader-spectrum antibiotics as first-line therapy [45, 52].

4.6.3 Tonsillectomy

Only one Quinsy-tonsillectomy was performed on a 43 year old HIV negative patient for potential airway compromise. Six HIV positive patients underwent tonsillectomy biopsy for suspected lymphoma after having a non resolving peritonsillar abscess. All of which were confirmed with lymphoma.

Although it is not routinely performed for the treatment of peritonsillar abscess, immediate tonsillectomy should be considered for patients who have strong indications for tonsillectomy, including those who have symptoms of sleep apnoea, a history of recurrent tonsillitis (four or more infections per year despite adequate medical therapy), or a recurrent or nonresolving peritonsillar abscess [43].

4.6.4 Complications

Four patients developed a parapharyngeal abscess of which 3 were HIV positive. One of these patients required a tracheotomy for airway compromise. This is a relatively low complication rate of peritonsillar abscess.

4.6.5 Number of Days Admitted

The admission length ranged from 1 to 17 days with a mean (SD) 2.65 (2.35) days.

From the 86 HIV positive patients, the mean length of hospital stay was 3.80 days with a standard deviation of 3.72 days. This was statistically significant with HIV positive patients requiring a longer hospital stay. The bacterial flora within the oral cavity is no different from that seen in healthy patients, and thus the altered immune response in HIV infection probably results in a higher incidence of adding a second antibiotic and increased hospital stay. Also the increased incidence in Lymphoma and Kaposi's sarcoma in HIV patients may prolong the hospital stay due to the necessity of performing biopsies.

4.7 Summary

The clinical data reviewed in this study revealed that majority of the patients presenting with Peritonsillar abscess were generally healthy and exhibited limited or no signs of HIV infection, (WHO clinical stage 1).

From the 291 patients, 86 (29.55%) were HIV positive. This is significantly higher than the adult (15-49years) HIV prevalence rate of 17.64% [6]. The age ranged from 15 to 63 years with a mean (SD) 29.3 years (9.58). The age group 30-34 showed the highest HIV positive rates of 27.9% which is in keeping with the results of the South African antenatal HIV survey of 2007. There was no difference in the clinical presentation of peritonsillar abscess in HIV positive and negative patients. There was no statistical significance in the management of HIV positive patients; however hospital stay was longer with a mean of 3.802 days and 1.2 days longer than HIV negative patients.

4.8 Suggested further research

There has been only one documented prospective study describing the relationship between peritonsillar abscess and the HIV status of patients (1995). A prospective study should be carried out with a multi-centre sample. A useful addition would be to include the CD4 and CD8 counts as well as looking at the microbiology of peritonsillar abscess.

4.9 Conclusions

From this study sample the HIV prevalence of 29.55% suggests that peritonsillar abscess may be an early clinical marker of HIV infection. Due to the high incidence of head and neck manifestations in HIV positive patients identifying a clinical marker (quinsy) in the earlier stages of HIV infection would allow for better screening, earlier diagnosis and treatment of HIV infection.

5 REFERENCES

- [1] UNAIDS/WHO AIDS epidemic update: December 2007, November 2007. UNAIDS and World Health Organization.
- [2] Statistics South Africa. 2008. Mid-year population Estimates, South Africa: 2008. P0302. Pretoria: Statistics South Africa.
- [3] Lucente FE. Impact of Aquired Immunodeficiency Syndrome on the practice of Laryngology. *Ann Oto Rhino Laryng* 1993; 102: 1-21.
- [4] Barzan L, Tavo M, Tirelli U et al. Head and neck manifestation during HIV infection. *J Laryng & Otol* 1993; 107: 133-136.
- [5] Steyer TE. Peritonsillar abscess: diagnosis and treatment [Published correction appears in *Am Fam Physician*. 2002;66(1):30]. *Am Fam Physician*. 2002;65(1):93-96.
- [6] Department of Health. National HIV and Syphilis Antenatal Sero-prevalence Survey in South Africa: 2007. Pretoria, South Africa: Department of Health, 2007.
- [7] Accessed on: www.chrishanibaragwanathhospital.co.za.
- [8] UNAIDS (2008), '2008 Report on the Global AIDS epidemic'.
- [9] Dorrington RE, Johnson LF, Bradshaw D and Daniel T. The Demographic Impact of HIV/AIDS I South Africa. National and Provincial Indicators for 2006. Cape Town: Centre for Actuarial Research, South African Medical Research Council and Actuarial Society of South Africa.
- [10] Department of Health, 2006. Report: National HIV and Syphilis Antenatal seroprevalence survey in South Africa, 2007.
- [11] Centers for Disease Control and Prevention. Guidelines for national human immunodeficiency virus case surveillance, including monitoring for human immunodeficiency virus infection and acquired immunodeficiency syndrome . *MMWR Recomm Rep*. 1999 Dec 10;48(RR-13):1-27, 29-31. Available online www.cdc.gov/mmwr/preview/mmwrhtml/rr4813a1.htm.

- [12] World Health Organization. WHO Case Definitions of HIV for Surveillance and Revised Clinical Staging and Immunological Classification of HIV-Related Disease in Adults and Children . 2007. Available online at www.who.int/hiv/pub/guidelines/HIVstaging150307.pdf.
- [13] Barzan L, Tavio M, Tirelli U, Comoretto R; International Conference on AIDS. Int Conf AIDS. 1992 Jul 19-24; 8: 138 (abstract no. PuB 7539).
- [14] EC-Clearinghouse on Oral Problems Related to HIV Infection and WHO Collaborating Centre on Oral Manifestations of the Immunodeficiency Virus. Classification and diagnostic criteria for oral lesions in HIV infection. J Oral Pathol Med 1993; 22:289-291.
- [15] Begg MD, Lamster IB, Panageas KS, et al. A prospective study of oral lesions and their predictive value for progression of HIV disease. Oral Dis 1997; 3:176-183.
- [16] Glick M. Evaluation of prognosis and survival of HIV infected patients. Oral Surg Oral Med Oral Pathol 1992; 74:386-392.
- [17] Glick M, Muzyka BC, Lurie D, Salkin LM. Oral manifestations associated with HIV disease as markers for immune suppression and AIDS. Oral Surg Oral Med Oral Pathol 1994; 77:344-349.
- [18] Brawner DL, Cutler JE. Oral *Candida albicans* isolates from nonhospitalized normal carriers, immunocompetent hospitalized patients, and immunocompromised patients with or without acquired immunodeficiency syndrome. J Clin Microbiol 1989; 27:1335-1341.
- [19] Thomas I. Superficial and deep candidosis. Int J Dermatol 1993; 32:778-783.
- [20] Brawner DL Hovan AJ. Oral candidiasis in HIV-infected patients. Curr Top Med Mycol 1995; 6:113-125.
- [21] Korting HC, Ollert M, Georgii A, Froschl M. In vitro susceptibilities and biotypes of *Candida albicans* isolates from the oral cavity of patients infected with human immunodeficiency virus. J Clin Microbiol 1989; 26:2626-2631.
- [22] Tsang PC, Porter SR, Scully C, et al. Biotypes of oral *Candida albicans* isolates in human Immunodeficiency virus-infected patients from diverse geographic locations. J Oral Pathol Med 1995; 24(1):32-36.

- [23] Klein RS, Harris CA, Butkus Small C, et al. Oral candidiasis in high-risk patients as the initial manifestation of the acquired immunodeficiency syndrome. *N Eng J Med* 1984; 311:354-358.
- [24] Mooney M, Thomas I, Sirois DA. Oral candidiasis. *Int J Dermatol* 1995; 34:759-765.
- [25] Eversole LR. Viral infections of the head and neck among HIV sero-positive patients. *Oral Surg Oral Med Oral Pathol* 1992; 73:155-163.
- [26] Oliver L, Wald A, Kim M, et al. Seroprevalence of herpes simplex virus infections in a family medicine clinic. *Arch Fam Med* 1995; 4:228-232.
- [27] Fleming DT, McQuillan GM, Johnson RE, et al. Herpes simplex virus type 2 in the United States, 1976 to 1994. *N Engl J Med* 1997 Oct 16; 337(16):1105-1111.
- [28] Annunziato PW, Gershon A. Herpes simplex virus infections. *Pediatr Rev* 1996 Dec;17(12):415-423.
- [29] Greenspan D, Greenspan JS, Conant M, et al. Oral "hairy" leukoplakia in male homosexuals: Evidence of association with papillomavirus and a herpes-group virus. *Lancet* 1984; 2:831- 834.
- [30] Syrjanen S, Laine P, Happonen RP, Niemela M. Oral hairy leukoplakia is not a specific sign of HIV infection but related to immunosuppression in general. *J Oral Pathol Med* 1989; 18:28- 31.
- [31] Felix DH, Watret K, Wray D, Southam JC. Hairy leukoplakia in an HIV-negative, nonimmunosuppressed patient. *Oral Surg Oral Med Oral Pathol* 1992; 74:563-566.
- [32] Glick M, Pliskin ME. Regression of oral hairy leukoplakia after oral administration of acyclovir. *Gen Dent* 1990; 38:374-375.
- [33] Greenspan JS, Greenspan D. Oral hairy leukoplakia: Diagnosis and management. *Oral Surg Oral Med Oral Pathol* 1989; 67:396-403.
- [34] Lozada-Nur F. Podophyllum resin 25% for treatment of oral hairy leukoplakia: An old treatment for a new lesion. *J Acquir Immune Defic Syndr* 1991; 4:543-546.

- [35] Centers for Disease Control and Prevention. 1993 sexually transmitted diseases treatment guidelines. *MMWR Morb Mortal Wkly Rep* 1993 Sep 24; 42(RR-14):1-102.
- [36] Lamster IB, Phelan JA, Zambon JJ, et al. Oral manifestations of HIV infection in homosexual men and intravenous drug users. Study design and relationship of epidemiologic, clinical, and immunological parameters to oral lesions. *Oral Surg Oral Med Oral Pathol* 1994; 78(2):163-174.
- [37] Shiboski CH, Cohen JB, Katz MH, et al. HIV-related oral manifestations in two cohorts of women in San Francisco. *J Acquir Immune Defic Syndr* 1994; 7(9):964-971.
- [38] Feigal DW, Katz MH, Greenspan D. The prevalence of oral lesions in HIV-infected homosexual and bisexual men: Three San Francisco cohorts. *AIDS* 1991; 5:519-525.
- [39] Flaitz CM, Su IJ, Wang YW, et al. Kaposi's sarcoma-associated herpes virus-like DNA sequences (KSHV/HHV-8) in oral AIDS-Kaposi's sarcoma: A PCR and clinicopathologic study. *Oral Surg Oral Med Oral Pathol Oral Radiol Endod* 1997 Feb; 83(2):259-264.
- [40] Mocroft A, Phillips AN, Halai R, et al. Anti-herpes virus treatment and risk of Kaposi's sarcoma in HIV infection. Royal Free/Chelsea and Westminster Hospitals Collaborative Group. *AIDS* 1996 Sep; 10(10):1101-1105.
- [41] Serrano M, Bellas C, Campo E, et al. Hodgkin's disease in patients with antibodies to human immunodeficiency virus. *Cancer* 1990; 65:2248-2254.
- [42] Bisno AL, Gerber MA, Gwaltney JM, Kaplan EL, Schwartz RH, for the Infectious Diseases Society of America. Practice guidelines for the diagnosis and management of group A streptococcal pharyngitis. Infectious Diseases Society of America. *Clin Infect Dis*. 2002;35(2):113-125.
- [43] Herzon FS, Martin AD. Medical and surgical treatment of peritonsillar, retropharyngeal, and parapharyngeal abscesses. *Curr Infect Dis Rep*. 2006;8(3):196-202.
- [44] Passy V. Pathogenesis of peritonsillar abscess. *Laryngoscope*. 1994;104(2):185-190.
- [45] Brook I. Microbiology and management of peritonsillar, retropharyngeal, and parapharyngeal abscesses. *J Oral Maxillofac Surg*. 2004;62(12):1545-1550.

- [46] Berkovitz BK, ed. Pharynx. In: Standring S, ed. Grays Anatomy. The Anatomical Basis Clinical Practice. 39th ed. New York, NY: Churchill Livingstone, 2005:623-625.
- [47] Khayr W, Taepke J. Management of peritonsillar abscess: needle aspiration versus incision and drainage versus tonsillectomy. *Am J Ther.* 2005;12(4):344-350.
- [48] Nwe TT, Singh B. Management of pain in peritonsillar abscess. *J Laryngol Otol.* 2000;114(10):765-767.
- [49] Johnson RF, Stewart MG, Wright CG. An evidence-based review of the treatment of peritonsillar abscess. *Otolaryngol Head Neck Surg.* 2003;128(3):332-343.
- [50] Herzon FS. Peritonsillar abscess: incidence, current management practices, and a proposal for treatment guidelines. *Laryngoscope.* 1995;105(8 pt 3 suppl 74):1-17.
- [51] Brook I. The role of beta lactamase producing bacteria and bacterial interference in streptococcal tonsillitis. *Int J Antimicrob Agents.* 2001;17(6):439-442.
- [52] Kieff DA, Bhattacharyya N, Siegel NS, Salman SD. Selection of antibiotics after incision and drainage of peritonsillar abscesses. *Otolaryngol Head Neck Surg.* 1999;120(1):57-61.
- [53] Friedland PL. Peritonsillar abscess in HIV positive patients. Mmed, University of Witwatersrand, 1998.

UNIVERSITY OF THE WITWATERSRAND, JOHANNESBURG

Division of the Deputy Registrar (Research)

HUMAN RESEARCH ETHICS COMMITTEE (MEDICAL)

R14/49 Dr Imraan Variava

CLEARANCE CERTIFICATE

M090638

PROJECT

A Retrospective Review of the Relationship
between Peritonsillar Abscess and HIV (new title)

INVESTIGATORS

Dr Imraan Variava.

DEPARTMENT

Department of Otorhinolaryngology

DATE CONSIDERED

09.06.26

DECISION OF THE COMMITTEE*

Approved unconditionally

Unless otherwise specified this ethical clearance is valid for 5 years and may be renewed upon application.

DATE 09.07.22

CHAIRPERSON



(Professor PE Cleaton-Jones)

*Guidelines for written 'informed consent' attached where applicable

cc: Supervisor : Prof PC Modi

DECLARATION OF INVESTIGATOR(S)

To be completed in duplicate and **ONE COPY** returned to the Secretary at Room 10004, 10th Floor, Senate House, University.

I/We fully understand the conditions under which I am/we are authorized to carry out the abovementioned research and I/we guarantee to ensure compliance with these conditions. Should any departure to be contemplated from the research procedure as approved I/we undertake to resubmit the protocol to the Committee. I agree to a completion of a yearly progress report.

PLEASE QUOTE THE PROTOCOL NUMBER IN ALL ENQUIRIES...

.....